

FREEMAN MILLER

Cerebral Palsy



Springer

Cerebral Palsy

Freeman Miller, MD

*Co-Director, Cerebral Palsy Program
Alfred I. duPont Hospital for Children
Nemours Foundation
Wilmington, Delaware*

Cerebral Palsy

With CD-ROM



With 1116 Illustrations, 777 in Full Color

Illustrations by Erin Browne, CMI



Springer

Freeman Miller, MD
Co-Director, Cerebral Palsy Program
Alfred I. duPont Hospital for Children
Nemours Foundation
Wilmington, DE 19899
USA

Library of Congress Cataloging-in-Publication Data

Miller, Freeman.

Cerebral palsy / Freeman Miller.

p. ; cm.

Includes bibliographical references and index.

ISBN 0-387-20437-7 (hc. : alk. paper)

1. Cerebral palsied children—Rehabilitation. 2. Movement disorders in children. 3.

Cerebral palsy. I. Title.

[DNLM: 1. Cerebral Palsy—rehabilitation—Child. 2. Cerebral Palsy—surgery—Child.

3. Disabled children—rehabilitation. WS 342 M647ca 2004]

RJ496.C4M535 2004

618.92'836—dc22

2003065734

ISBN 0-387-20437-7

Printed on acid-free paper.

© 2005 Springer Science+Business Media, Inc.

All rights reserved. This work may not be translated or copied in whole or in part without the written permission of the publisher (Springer Science+Business Media, Inc., 233 Spring Street, New York, NY 10013, USA), except for brief excerpts in connection with reviews or scholarly analysis. Use in connection with any form of information storage and retrieval, electronic adaptation, computer software, or by similar or dissimilar methodology now known or hereafter developed is forbidden.

The use in this publication of trade names, trademarks, service marks, and similar terms, even if they are not identified as such, is not to be taken as an expression of opinion as to whether or not they are subject to proprietary rights.

While the advice and information in this book are believed to be true and accurate at the date of going to press, neither the authors nor the editors nor the publisher can accept any legal responsibility for any errors or omissions that may be made. The publisher makes no warranty, express or implied, with respect to the material contained herein.

Printed in Singapore. (AI/KYO)

9 8 7 6 5 4 3 2 1

SPIN 10948378

springeronline.com

Preface

Cerebral palsy is a lifelong condition that affects the individual, family, and immediate community. Therefore, the goal of allowing the individual with cerebral palsy to live life with the least impact of the disability requires complex attention to the individual and the family. Furthermore, society needs to be sensitive and to accommodate individuals with disabilities by limiting architectural impediments and providing accessible public transportation and communication. The educational system provides the key means for helping the individual prepare to function in society to his or her maximum ability. In many ways, the medical care system probably has the least significant role in preparing the child with cerebral palsy to function optimally in society. However, the medical care system is the place where parents first learn that their child has developmental issues outside the expected norm. It is almost universally the place where parents also expect the child to be made normal in our modern society. In earlier times, the parents would expect healing to possibly come from the doctor, but also they would place hope for healing in religion. As this belief in spiritual or miraculous healing has decreased, a significant font of hope has decreased for parents of young children with disabilities.

The text aims to help the child with cerebral palsy to develop into an adult in whom the effects of the disability are managed so that they have the least impact possible on adult function. This intention is in the context of the fact that the magnitude of improvement in the disability that occurs with ideal management of the musculoskeletal system during growth may be only a small improvement. Probably the more significant aspect of good musculoskeletal management through childhood is helping the child and family to maintain realistic hope for the successful adult life of the growing child. This aim requires the medical practitioner to get to know the child and family and to communicate in a compassionate way realistic expectations of the child's function. For many reasons, the greatest difficulty in providing this kind of care is the limited time practitioners have to spend with the individual patient. There is also the sense, especially among orthopedic physicians, that cerebral palsy cannot be cured (cannot make the child function normally), and thus it is a frustrating condition with which to work. The physician must maintain a balance between communicating hopelessness to the patient and family; and feeling the need to do something, usually a heel cord lengthening, because the parents are frustrated that the child is not progressing. All medical decisions, including a surgical option, should always consider both the short- and long-term impact. With every decision the medical practitioner should ask, "What will be the impact of this recommendation by the time the child is a mature adult?" This is the most difficult perspective, especially

for young practitioners with little experience. This text is intended to provide this insight as much as possible.

Another issue is the poor scientific documentation of natural history and treatment response in cerebral palsy, which has become clearer to me in the course of writing this book. With little scientifically based natural history and few long-term studies, much of what is written in this text is expert-based observation. The goal of writing this is not to say that it is absolute fact, but to provide the starting point of gathering information with the hope that others will be stimulated to ask questions and pursue research to prove or disprove the concepts.

The research, which is of help in treating children with cerebral palsy, needs to be planned and evaluated with consideration of its long-term impact on the child's growth and development. All treatment should also consider the negative impact on the child. As an example, a number of moderately good studies have analyzed the impact of wearing ankle orthotics on the young child. Although the orthotics may provide an immediate benefit by improving the child's gait, there is probably no long-term benefit. Thus, if the child develops a strong sense of opposition to wearing the brace at 10 years of age because of peer pressure, the brace wear cannot be justified on a cost-benefit analysis.

It is also important to consider the quality of the scientific evidence, ranging from double-blinded protocols to case reports, but it is equally important not to get hung up on this being the final answer. For example, excellent double-blinded studies show that botulinum toxin decreases spasticity and improves gait for a number of months. Therefore, these studies need to be considered in the context of our goal, which is to give the child the maximum possible function at full maturity. Because no evidence currently suggests that botulinum has either a negative or a positive effect on this long-term goal, the family and physician should decide together if botulinum injection has a positive cost-benefit ratio, as its effects will last only for approximately 6 months. In comparison, no double-blind studies show that Achilles tendon lengthenings improve gait three or six months after the surgery, and no such studies are needed because the goal of surgery is to make an improvement in gait several years later and to have improvement at maturity. Most important is that surgery create no disability at maturity. From this perspective, it would be much more useful to have a good controlled case series with a 15-year follow-up than a double-blinded study with six months follow-up.

This book should stimulate research that will improve the knowledge base which is focused on the long-term outcome of treatments. However, just because the scientific knowledge base is poor does not mean that we should not apply the best knowledge available to current patients. In addition to research, an individual professional can best extend his or her knowledge base through personal experience. This means that the child and family should be followed over time by the same practitioner with good documentation. By far, my best source of information has been the children whom I have followed for 10 to 20 years with videotapes every year or two. Practitioner experience is extremely important for augmenting the relatively poor scientific knowledge base for musculoskeletal treatment. Careful ongoing follow-up is also crucial to providing hope for the families and the individuals with cerebral palsy.

How to Use This Text and CD

The text of *Cerebral Palsy* is set up in three sections, with the first section containing 11 chapters that deal with specific aspects of cerebral palsy from

the perspective of managing the motor impairment. The first four chapters address primarily global issues of the child and family. The fifth chapter provides an overview of the medical and community care system and philosophy. The sixth chapter addresses the myriad options of equipment encountered in the treatment of the musculoskeletal impairment, and the seventh addresses the problems related to gait. The last four chapters are related to problems encountered in anatomical regions. These chapters also include management of the deformities and management of complications of medical treatment. These chapters are followed by treatment algorithms relevant to the issues discussed within the chapter. Also included in the chapters are patient case examples. Many of the case examples have videos and are designated by a video symbol. Each case has a unique name assigned to the patient and the video is accessed by opening the CD followed by opening the movies section, then opening the video with the same name. The second section of the book includes descriptions of techniques in rehabilitation often used with children with cerebral palsy. The third section is a surgical atlas with the procedures organized by anatomical area.

The CD included with this text is opened with a Web browser. Because the data on the CD is coded with XML and JAVA, only browsers released after 2002, such as Netscape 7.0, Explorer 6.0 or Safari, will be fully able to access this data. Some of the text in the book is organized in topics and is displayed in the section entitled “Main.” All references on the CD have the abstract available on the CD by activating the link associated with the reference. Cases can also be activated from these references in the Main section. There is also a section called “Cases,” which lists all the cases by name as listed in the text of the book. Following these cases are short quiz questions, which can be used to test understanding or study the material on line. There is also a section called “Quizzes,” which lists the quizzes by name of the cases. These quizzes can be opened and answered referring to the full case descriptions. The answers from the quizzes will be tabulated to keep a running total of correct answers for each session. After a quiz is accessed, it will also change color to remind the reader that he has already reviewed that quiz. The section entitled “Decision Trees” is the treatment algorithms, which are present at the end of each chapter in the book. These decision trees are set up so that area of interest is linked to the text in “Main” for further reading. The section called “Search” is an electronic index to search for specific subjects within the chapter of the section “Main.” Because of space limitations, only individual chapters can be searched at one time. So if you want to search for “crutches,” you first should activate the Durable Medical Goods chapter, and then search. The results of the search allow you to directly link to the area of interest. The section “History” keeps a running history of the areas that have been assessed, so if you want to return to an area you were reading earlier in the session you can open the history and it will allow you to return to that area. The section “About” includes information on the use of the CD and acknowledgments.

In summary, the CD includes videos, case study quizzes, and reference abstracts, which are not included in the book. The book includes significant portions of text not included on the CD, sections on rehabilitation techniques, and a surgical atlas. The book and the CD are intended to complement each other but each can also be used alone.

Acknowledgments

The production of this book and CD was only possible because of an extensive network of support that was available to me. The support of the

administration of the Nemours Foundation, especially the support of Roy Proujansky and J. Richard Bowen in giving me time to work on this project was crucial. It was only through the generous support in caring for my patients by my partners and staff, Kirk Dabney, Suken Shah, Peter Gabos, Linda Duffy, and Marilyn Boos, that I was able to dedicate time to writing. I am very grateful for the generous material provided by all the contributors and for the extensive and extremely important role of the feedback given to me by the consultants. In spite of having an extremely busy practice, Kirk Dabney still found time to read all of the first section, making very valuable improvements, and writing major sections of the upper extremity chapter. With his wide experience, Michael Alexander made an excellent contribution in the editorial support of the section on rehabilitation. The task of writing and editing would have been impossible without the dedicated work of Kim Eissmann, Linda Donahue, and Lois Miller. Production of the CD involved a significant amount of detailed editing and HTML coding, most of which was performed by Linda Donahue. To add a personal touch to the cases, a unique name was assigned by Lois Miller. The CD required a great effort of technical programming to make it work intuitively on all computer formats. Tim Niiler patiently persisted with this frustrating task until it all worked. Videos were masked and formatted by Robert DiLorio. Production of the graphics was a major effort in understanding the complex material in which Erin Browne excelled. This production would have been impossible without her dedication to understanding the concepts and bringing them to visual clarity. I would also like to thank the staff of Chernow Editorial Services, especially Barbara Chernow. Without the long support through out the evolution of this book by Robert Albano and his staff at Springer, this project would also have been much more difficult. And finally, I am most grateful for the many families and children who have allowed me to learn from them what it is like to live with the many different levels of motor impairments. It is to the families and children that I dedicate this work in the hope that it will lead to improved care and understanding by medical professionals.

Freeman Miller, MD

Contents

Preface.....	v
Contributors	xi

Section I Cerebral Palsy Management

1 The Child, the Parent, and the Goal	3
2 Etiology, Epidemiology, Pathology, and Diagnosis	27
3 Patient Management	51
4 Neurologic Control of the Musculoskeletal System	95
5 Therapy, Education, and Other Treatment Modalities	151
6 Durable Medical Equipment	181
7 Gait	251
8 Upper Extremity	387
9 Spine	433
10 Hip	523
11 Knee, Leg, and Foot.....	667

Section II Rehabilitation Techniques

1 Neurodevelopmental Therapy	805
<i>Elizabeth Jeanson</i>	
2 Strengthening Exercises	806
<i>Diane Damiano</i>	
3 Balance Interventions.....	808
<i>Betsy Mullan</i>	
4 Electrical Stimulation Techniques	809
<i>Adam J. Rush</i>	
5 Hippotherapy	810
<i>Stacey Travis</i>	
6 Aquatic Therapy	811
<i>Jesse Hanlon and Mozghan Hines</i>	

7	Assistive Devices	818
	<i>Mary Bolton</i>	
8	Seating Systems	821
	<i>Denise Peischl, Liz Koczur, and Carrie Strine</i>	
9	M.O.V.E. TM (Mobility Opportunities Via Education) Curriculum.....	828
	<i>Kristin Capone, Diana Hoopes, Deborah Kiser, and Beth Rolph</i>	
10	Occupational Therapy Extremity Evaluation.....	831
	<i>Marilyn Marnie King</i>	
11	Intrathecal Baclofen Pumps	851
	<i>Maura McManus</i>	
	References	858
 Section III Surgical Techniques		
1	Upper Extremity Procedures	865
2	Spinal Procedures	894
3	Hip Procedures	913
4	Knee Operative Procedures	955
5	Foot and Ankle Procedures	979
	Index	1025

Contributors

Associate Editors

Kirk Dabney, MD
Michael Alexander, MD

Contributors

Mary Bolton, PT
Kristin Capone, PT, MEd
Henry Chambers, MD
Diane Damiano, PhD
Federico Fernandez-Palazzi, MD
Patricia Fucs, MD
Jesse Hanlon, BS, COTA
Mozghan Hines, LPTA
Diana Hoopes, PT
Elizabeth Jeanson, PT
Marilyn Marnie King, OTR/L
Deborah Kiser, MS, PT
Liz Koczur, MPT
Maura McManus, MD, FAAPMR, FAAP

Betsy Mullan, PT, PCS
Denise Peischl, BSE
Beth Rolph, MPT
Adam J. Rush, MD
Carrie Strine, OTR/L
Stacey Travis, MPT
Joaquin Xicoy-Forges, MD

Consultants

Steven Bachrach, MD
John Henley, PhD
Douglas Heusengua, PT
Harry Lawall, CPO
Stephan T. Lawless, MD
Gary Mickalowski, CPO
Edward Moran, CPO
Susan Pressley, MSW
James Richards, PhD
Mary Thoreau, MD
Rhonda Walter, MD



SECTION I

Cerebral Palsy
Management

The Child, the Parent, and the Goal

Cerebral palsy (CP) is a childhood condition in which there is a motor disability (palsy) caused by a static, nonprogressive lesion in the brain (cerebral). The causative event has to occur in early childhood, usually defined as less than 2 years of age. Children with CP have a condition that is stable and nonprogressive; therefore, they are in most ways normal children with special needs. Understanding the medical and anatomic problems in individuals with CP is important; however, always keeping in mind the greater long-term goal, which is similar to that for all normal children, is important as well. The goal for these children, their families, medical care, education, and society at large is for them to grow and develop to their maximum capabilities so that they may succeed as contributing members of society. This goal is especially important to keep in perspective during the more anatomically detailed concerns discussed in the remainder of this text.

How Different Is the Child with CP?

When addressing each of the specific anatomic concerns, the significance of these anatomic problems relative to the whole child's success needs to be kept in the proper context. The problems of children with CP should be evaluated in the perspective of normal growth and development similar to any normal children with an illness, such as an ear infection, who need medical treatment. However, keeping the specific problems of children with CP in the proper context is not always easy. The significance of this proper context is somewhat similar to the significance of having a child do spelling homework on Wednesday evening to pass a spelling examination on Thursday. Likewise, practicing the piano is necessary to succeed in the piano recital. Even though each of these acts is important toward the final goal of having a confident, educated, and self-directed young adult who is making a contribution in society, the exact outcome of each event may not be all that important in the overall goal. Often, the success of a minor goal such as doing well on a specific test is less important than a major failure, but the measure of failure or success may be hard to recognize until years later. As with many childhood events, the long-term effect may be determined more by how the event was handled than by the specific outcome of the event.

For children with CP, in addition to all the typical childhood experiences is the experience of their CP treatment. Different children may experience events, such as surgery and ongoing treatment (including physical and occupational therapy), very differently. The long-term impact of these events from the children's perspectives is often either negative or positive, depending on

their relationship with both therapists and physicians. These children have physical problems, which are the major focus of this text; however, CP affects the whole family and community. These relationships and how the CP affects families and communities are discussed in greater detail in this chapter.

The process of growing and developing involves many factors. One of the most important factors in children's long-term success is a family caretaker. Likewise, for children with CP, families may be impacted by the CP as much as the children with the physical problems. It is very important for medical care providers to see the problems related to CP as not only involving the children, but also involving the families. Society is realizing more that the education of normal children works best when the family care providers actively participate. Likewise, providing medical care for children with CP must consider their whole families. The outcome for these children will be determined largely by their families, just as the success of normal children's education is determined by their families. The importance of family does not provide an excuse for medical care providers or educators to become pessimistic if they do not perceive the family is doing its part. In this circumstance, professional care providers still must give as much as possible to each child but recognize their place and limits in the care of these children. Medical care providers who fail to recognize their own limits in the ability to provide care often will become overwhelmed by their sense of failure and will burn out quickly.

Family Impacts of the Child with CP

A healthy liaison should be developed between children with CP, the family unit, and the medical care providers. Cerebral palsy is a condition that varies extremely from very mild motor effects to very severe motor disabilities with many comorbidities. In addition, there are great variations among families. To provide proper care for children with CP, physicians need to have some understanding of the family structure in which the children are living. Because of time pressures, this insight is often difficult to develop. Families vary from young, teenage mothers who may have the support of their families, to single parent families, to families with two wage earners and other children. All the pressures of caring for a child with a disability are added onto the other pressures that families of normal children have. Because most children with CP develop problems in infancy and early childhood, families grow and develop within the context of these disabilities.

Often, the father and mother will react differently or come to different levels of acceptance. It is our impression that these different reactions may cause marital stress leading to high levels of divorce, most frequently when the children are 1 to 4 years old. Although this is our impression, there is no clear objective evidence that the divorce rate for these families is higher than in the normal population. Another high time of family stress is during the teenage or young adult years for those individuals with severe motor disabilities. Often, as these individuals are growing to full adult size and the parents are aging, it becomes very apparent to the parents that this is not a problem that is going away, nor are these young individuals capable of going off to college and making a life of their own.

The response of an individual family varies greatly with the wide variability of severity of CP. Many families develop a stable and very supportive structure for their disabled child. Physicians and other medical care providers may be amazed at how well these families deal with very complex medical problems. For many of these families, however, the medical com-

plexities have accumulated slowly and are themselves a part of the growth and development phenomena. With multiple medical treatments often provided by many different medical specialists, a high level of stress develops in almost every family.

For the medical professional, continuing to be aware of this stress and listening for it during contact with families is important. Families with less education and limited financial resources may do remarkably well, whereas a family with more education and more financial resources may not be able to cope with the stresses of a child with a severe disability. It is extremely difficult to judge which family can manage and which family will develop difficulty, so it is important not to become prejudiced either for or against specific families. Medical care providers should continue to be sensitive to how the family unit is managing to deal with their stresses. Some families will be seen to be doing well and then suddenly will become overwhelmed in the face of other family stress. This stress may be illness in other family members, financial pressures, job changes, marital stress, and, most commonly, the effects of aging on the parents, siblings, and individuals with CP.

Care-Providing Community

Children with CP develop in supporting communities, which vary with each individual child. There are four general segments of these caring communities, with the family or direct caregivers being the primary relationship. This primary relationship is surrounded by community support services, the medical care system, and the educational system (Figure 1.1). The community support includes many options such as church, Scouting, camping,

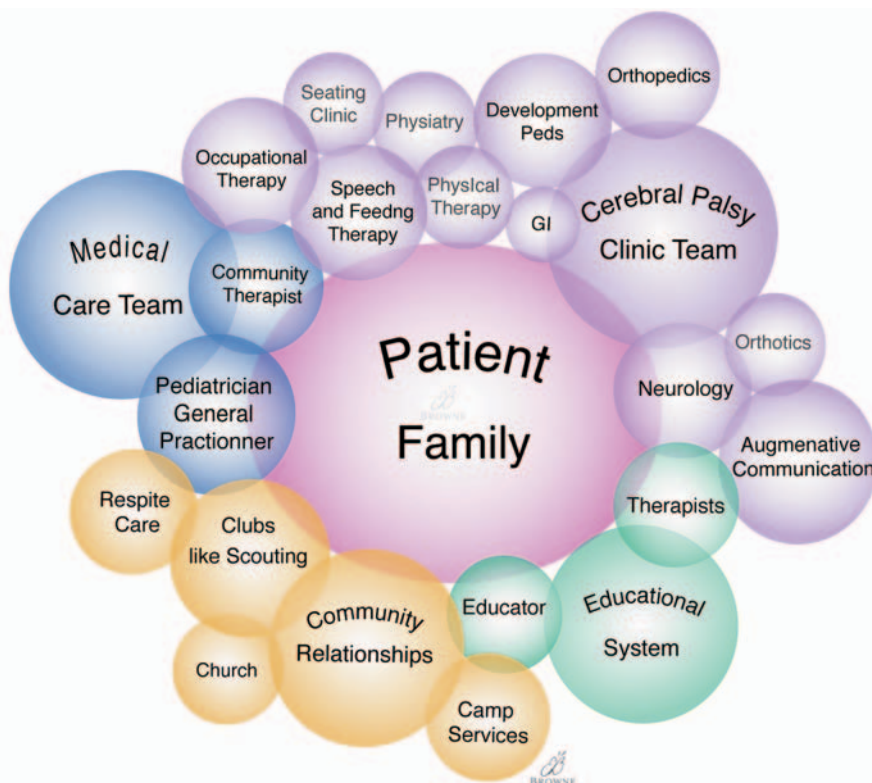


Figure 1.1. A large and extensive care team surrounds the family with a child who has cerebral palsy. These care providers are roughly organized around the educational system, primary medical care provider, the cerebral palsy specialized medical team, and community support services. Significant overlap and good communication provide the best resources to the child and the family.

respite services, and recreational programs. The educational system includes both educational professionals and therapeutic professionals, especially physical and occupational therapists. The focus of this text is to address the medical issues, so there will be no specific discussion of these support services, except to remind medical professionals that other services provide crucial roles in the lives of children and their families. The organization of the medical care system tends to organize around the general medical care and the specialty care for the problems specific to CP.

It is very important for families to have an established general medical care provider, either a pediatrician or family practice physician. Families must be encouraged to maintain regular follow-up with a primary care physician because very few orthopaedists or other specialists have the training or time to provide the full general medical care needs of these children. Standard immunizations and well child care examinations especially will be overlooked. However, most families see their child's most apparent problem as the visible motor disability and will focus more medical attention on this disability at the risk of overlooking routine well child care. The physician managing the motor disability should remind parents of the importance of well child care by inquiring if the child has had a routine physical examination and up-to-date immunizations. A physical or occupational therapist will provide most of the medical professional special care needs related to the CP. The specialty medical care needs are provided in a specialty clinic, usually associated with a children's hospital.

Cerebral Palsy Clinic

Another way to organize the management of these well child care needs is with a multidisciplinary clinic in which a primary care pediatrician is present. The administrative structure for setting up a clinic to care for children with CP is not as well defined as it is for diseases such as spina bifida. Spina bifida, meningomyelocele, or spinal dysfunction clinics are all well-established concepts and are present in most major pediatric hospitals. These clinics, which are set up to manage children with spinal cord dysfunction, have a well-defined multidisciplinary team. This team works very well for these children because they all have similar multidisciplinary needs ranging from neurosurgery to orthopaedics, urology, and rehabilitation. However, this model does not work as well for children with CP because their needs vary greatly. These needs range from a child with hemiplegia who is being monitored for a mild gastrocnemius contracture only to a child who is ventilator dependent with severe osteoporosis, spasticity, seizures, and gastrointestinal problems. It is impossible to have all medical specialists available in a clinic setting, especially in today's environment where everyone has to account for their time by doing productive work, described mainly as billable time.

There are two models currently being used in most pediatric centers for the care of children with CP. One model has a core group of clinicians who see the children, often including an orthopaedist, pediatrician, or psychiatrist, social worker, physical therapist, and orthotist. The second model consists of families making separate appointments for each required specialist. The advantage of the first model is that it helps families coordinate their child's needs. The major disadvantage is that it is costly and not reimbursed by the fragmented American healthcare system. The advantage of the second system is its efficiency to healthcare providers; however, there is often no communication between healthcare providers, and the responsibility of coordinating care from many different specialists thus falls to families.

From a practical perspective, considering the cost restriction of the healthcare environment, the best system is some blending of the two clinic models. We use this blended model, and it works for many patients with CP and their families. We schedule outpatient clinics where an orthopaedist and pediatrician share the same physical office space; however, each child is given an individual appointment with each physician. If there are only musculo-skeletal concerns, only the orthopaedist is scheduled to see the child. However, if a child also has additional medical needs, the pediatrician is seen before or after the orthopaedic appointment. Orthotics, rehabilitation engineering for wheelchair services, nutritionists, social workers, and physical and occupational therapy are available in very close proximity to this outpatient clinic. If a child had a recognized problem before the clinic visit, appointments would have been made to see any of these specialists. However, if the problem is found at the current visit, such as an orthosis that is too small, this child can be sent to the orthotist and be molded on the same day for a new orthotic. This clinic also has a special coordinator to help parents schedule appointments with other specialists such as dentistry, gastroenterology, or neurology.

This structure is most efficient for medical care providers; avoids duplication of services, such as having a physical therapist evaluate a child who is getting ongoing community-based therapy; and can potentially provide maximal efficient use of the parents' time. The main problem arising with this system is that it requires cooperation between many areas in the hospital. This model only works if the needed specialists are all working on the same day and are willing to work around each other's schedules. For example, holding the CP clinic on a day that the dental clinic is closed or the orthotist is not available does not work. Although individual appointments are made with specialists, schedules often are not maintained perfectly, so if the orthopaedic appointment is for 10 a.m. but the child is not seen until 11 a.m., the time of the next appointment with a neurologist, all the schedules are affected. Making this system work requires flexibility by all involved.

One area of efficiency that the medical care system pays little attention to is the parents or caretaker's time. Most caretakers have to schedule a whole day to take a child to a physician appointment because it means taking the child out of the school, usually driving some distance, seeing the physician, then returning home. This system of actively trying to schedule a number of appointments on the same day allows parents to make use of the whole day, avoiding more days out of work for the parent and out of school for the child.

Coordination between team members is accomplished by weekly team meetings where outpatient children with specific needs, along with pending and present in-hospital patients, are discussed. No matter what administrative structure is used for the outpatient management of children with CP, because of the diverse population and needs, there are always individuals who will not fit the structure. Therefore, an important aspect of providing medical care to this patient population is to have some flexibility in the delivery system.

Family Care Provider and Professional Care Provider Relationship

The specific organizational model for providing care is not as important as the fact that the medical care provided to the child with CP must always be

provided to the family–child unit. This relationship may be somewhat different for educational professionals than for medical care professionals. This discussion focuses primarily on the medical care professional relationship, specifically on the care of the motor disabilities provided by a physician.

The first aspect of treating children with CP is ensuring that the families have heard and come to some level of acceptance that their child has a problem called CP, which is permanent and will not go away. Hearing and acknowledging a diagnosis is a process that requires families first to come to terms with hearing the words and, second, to internalize these words. This process may take many years, with families initially acknowledging that there is a problem, but still expecting a cure soon. In the initial session with families to discuss this diagnosis, it is important that physicians allow plenty of time to answer all their questions, do not demand that they immediately accept the physicians' words, and avoid definitive words that bring a sense of hopelessness to families. During this discussion with families, there is little role for the use of absolutist terms like "never," "will not," "cannot," "will die," or "will never amount to anything." These terms often strike families as extremely cruel and threaten to remove all their hope, which they desperately need. Having time to answer all a family's questions and allowing them to have their own doubts is important. As the physician relationship develops with a family, especially in the context of a clinic for CP, the families will slowly come to their own realization. However, this process of coming to terms with the diagnosis may be impacted by the circumstances and situations surrounding the etiology.

Family Response Patterns

All families come to terms with their children's problems in their own way; however, there are several problems that are based on mechanisms surrounding the inciting event or the time of the diagnosis. In general, most families struggle to understand why this happened to their children and who is at fault.

Obstetric difficulties surrounding delivery can be the clear cause of CP. However, many of these birthing problems are probably due to a fetus that was already sick. Nevertheless, the birthing problems often focus the parents on looking for someone to blame, frequently the obstetrician. Some families can come to the point where they can release this need to blame; for others, it may lead to finding a legal solution by way of bringing a legal suit against the individual or organization perceived to be at fault. These legal pursuits are often encouraged by lawyers, and for many families, this only leads to more disappointment when some of the legal efforts are unsuccessful. For families who win legal judgments, there may be some sense of justice; however, the difficulty of caring for a child with a disability continues, and the need to come to terms with why this happened does not disappear by receiving money from a successful lawsuit.

Some parents, who have difficulty dealing with why this happened to their child, will be very suspicious of the medical system and will be perceived as being very difficult. There is a tendency for medical care providers, doctors, nurses, and therapists to avoid contact with these families, which often leads to more stress because the families feel that they are being avoided. This kind of very suspicious family, especially with underlying unresolved anger related to the initial diagnosis, needs to be kept exceptionally well informed and have frequent contact with the senior attending physician.

When a child is hospitalized, it is important to have the attending physician meet with the family frequently and always keep them apprised of changes and expected treatment. This level of communication with families sounds very simple; however, we have seen many families who endured a series of terrible events in hospitals, such as oversights or staff failure to recognize an evolving event that the family already pointed out. When these situations are brought up with staff, such as nurses and residents, there is a tendency for the response to be “they brought it on themselves.” This kind of thinking is unacceptable because lack of contact with the senior responsible medical staff is usually the main cause.

It is important for medical staff to recognize this pattern of behavior in families and respond very consciously by increasing communication and frequent contact. Again, the primary responsibility for this contact rests with the senior treating physician, who must display confidence, knowledge, and control of the situation to comfort the family. These families are very perceptive of physicians and care providers who do not have experience and confidence in dealing with their children’s problems. Often, these families have considerable experience in hospitals and notice when things are overlooked or symptoms are not addressed in an appropriate time (Case 1.1).

Dealing with Blame

Medical care providers must not get into situations where they inadvertently inflame this need to blame someone for the cause of these children’s CP. When parents give their perception of the history of the inciting event, it should be accepted as such without comment. Medical care providers should not tell parents how terrible the person they blame was or anything else that gives the impression that the CP could have been avoided if only this or that were done. This kind of postmortem evaluation of past medical events helps medical practitioners to learn; however, a detailed dissection of long-gone biomedical events to look for a person to blame seldom helps the families to come to terms with their children’s disabilities. By far, most of these families’ “need to find someone to blame” is a stable enduring part of their lives, and if the treating physician acknowledges this need and focuses their concerns on the children’s current care and situation, the blame issue tends to fall to the background.

There is no need for the orthopaedic physician caring for these children’s motor disabilities to get an extensive history of the birth and delivery directed at understanding the etiology of the CP from the families, so long as the diagnosis of CP is appropriate. Instead, the families’ mental energies should be directed at the goal, which is to help their children be all they can be, given the current circumstances. However, trying to convince the parents that they have to give up looking for a cause or a person to blame is also futile. If the parents are totally immobilized and cannot move forward, arranging psychotherapy may be worthwhile; however, most parents will perceive this as another attempt to sweep away the problem of who is responsible.

Another common scenario for the diagnosis of CP is when a parent or grandparent recognizes some slow development in a child. This child was then taken to see the family doctor or pediatrician who reassured the family that they were overreacting. Often, these families end up going to their primary care provider two, three, or four times to hear the same response, that is, that they are just overreacting. The child is a little slow, but there is nothing to worry about. These families often want to lay the blame for the CP upon the



Case 1.1 Susan

Susan was born after a normal pregnancy and delivery at term and was discharged home from the hospital as a normal newborn. At 3 weeks of age, her grandmother thought that her head looked abnormal, and Susan was taken to a pediatrician where a workup revealed hydrocephalus. A shunt was placed at 4 weeks of age, followed by some complications. After this time, she was noted by her parents and grandmother to be less strong and less interactive. However, she did well, and by age 3 years was crawling, rolling, and talking. At age 3 years, she developed severe seizures and was hospitalized. During this hospitalization, she had a rather severe overdose of anti-seizure medication along with other subsequent complications and lost the ability to crawl, roll, and talk. Her parents started patterning therapy when she did not rapidly regain these functions. She also started to develop increased spasticity and had more trouble with her trunk control.

By age 6 years, Susan had an adductor lengthening and was developing scoliosis. She was started in a body jacket to help control her scoliosis, and by age 8 years, she had a painful dislocated hip. After the family searched for several different opinions, they elected to go ahead and have the hip reconstructed. Because Susan had substantial complications with loss of neurologic function on several previous admissions, her parents were perceived as being extremely anxious during the hospitalization. The operative procedure and the recovery phase of the hip reconstruction went very well and the family was very gracious.

By age 9 years, she needed to have additional soft-tissue lengthenings of her right shoulder for a painful dislocation as well as for progressive varus deformity of the feet. The family was less anxious during this procedure than they had been with the prior procedure because they were more comfortable with the staff.

By age 12, the scoliosis had progressed substantially, requiring a posterior spinal fusion. The family was very anxious about this very large procedure. Their anxiety was perceived by some staff as being overreactive; however, considering the history of their experience with past medical treatment, we felt it was appropriate. At the time of the posterior spinal fusion, the shunt tubing was noted

to be broken; however, she was no longer dependent on her shunt so shunt repair was not performed.

By age 13 years, she developed more lethargy and a shunt revision was recommended. During this shunt revision, she had severe complications including an infection that required the shunt to be externalized. The external drainage was not controlled carefully enough and, as a consequence, the ventricles collapsed, causing intracranial bleeding. This episode caused substantial neurologic functional loss, so she was now less able to interact socially with her parents on top of her very severe spastic quadriplegic pattern motor disability. In addition, her seizures increased substantially. This episode made her parents extremely anxious about medical treatment, especially about the fear of developing complications and having functional loss.

Shortly after the shunt problems, she was noted on routine medical examination to have a retinal detachment requiring surgery. This surgery occurred without any complications. She continued to have problems with her seizures, and her parents were anxious to have control of the seizures, while at the same time to allow her to regain some of her alertness and contact with her parents, which they much enjoyed.

This family was often perceived by nurses and house staff as being exceedingly difficult to deal with because they were so anxious and always wanted to observe and understand specific treatments and know exactly which medications were being administered. This family was extremely dedicated to the care of their daughter, and the anxieties that they expressed were very understandable considering their history. Often, medical care providers, especially physicians and nurses, were not aware of this history and therefore did not understand the parents' anxieties. This anxiety tends to make nursing staff and medical staff try to avoid the parents, which just greatly increases their anxiety level. These parents had more than one hospitalization per year on average with their daughter and were very aware of what her proper medical management should be. They were very astute in picking up inexperience in both the nursing and medical staff and would become much more anxious when they sensed this inexperience or discomfort in dealing with their daughter.

physician, believing that this delayed diagnosis is why the child currently is so severe. There is almost no circumstance where a delayed diagnosis will be of any significance. It is important for these parents to have their concerns about the delayed diagnosis acknowledged, but then they must be reassured that this delay did not, in any way, cause their child to have a greater severity of CP. Some of these families will have difficulty developing other trusting relationships with physicians and may call, especially initially, for many minor concerns until confidence in their physician is developed.

Sometimes CP is the result of an accident or event in childhood, such as a toddler with a near drowning, or a child with a closed head injury from a motor vehicle accident in which the parent was the driver. In these situations, the parents often feel a substantial amount of blame for causing their child's disability. This self-blame and guilt may be even more difficult for a parent to come to terms with than blame focused outward. One response to the inwardly focused blame is to search for extraordinary cures, demand more therapy, or get more devices. This behavior seems to be one of "making it up to the child." It is helpful to reassure the family that things besides more therapy or more devices, such as maximizing the child's educational ability, will help the child.

Giving and Dealing with Prognosis

Another experience frequently reported by parents whose children were in neonatal nurseries is the comment that the children probably will not survive, and, if they do, will be vegetables. This comment has been reported to us by parents of children who end up with hemiplegia as well as children with quadriplegia. We believe this comment stems from the great difficulty of making a specific prognosis of outcome in the neonatal period. Also, some physicians tell families the worst possible outcome, believing that when the children do better, the families will be grateful for their good luck. However, this explanation almost never has the intended outcome, and much more commonly the families perceive these comments as the physician being incompetent or deceitful. Often, these families will interpret attempts by later physicians to discuss prognosis or expected results of surgery as being too pessimistic. For these families, it is important to be as realistic as possible; however, their optimism may cause some disappointment as their expectations of greater outcomes are not realized. Generally, these families do come to appropriate expectations, but continue to have some negative feelings about their neonatal experience.

An important aspect of giving prognosis or information that is requested by families is to always acknowledge that it is imperfect. Requests to know if a child will walk or sit should be answered as honestly as possible, always avoiding absolutist terms such as "never," "cannot," or "will not."

Giving the Diagnosis

Another common problem surrounding diagnosis of children with CP is failure to give the parents a diagnosis. A common example of this is a mother of a 5-year-old who is unable to sit and brings the child to see the orthopaedist to find out why the child cannot walk. The history reveals a normal pregnancy and delivery; however, by age 12 months, the child was not sitting, so the mother starting going to doctors to find out what was wrong with the child. She has seen three neurologists and a geneticist, has had skin

biopsies, muscle biopsies, computed tomography (CT) scan, magnetic resonance imaging (MRI) scan, and many blood tests, but everything is normal. The mother hears from these doctors that they can find nothing wrong with her child; however, what the doctors probably told the mother is that the medical tests are normal and they do not know what caused the child's current disability.

Families need to be told what is wrong with their child. This type of family is easily helped by explaining that the child has CP. Physicians should clearly explain that even though they do not understand why the child has CP, it is the diagnosis, which they know exactly how to treat. Taking time and providing information to these families will stop the endless and futile search for "why" and allow them to focus on caring for and treating their children. This situation is caused almost entirely by physicians not being clear in communication with parents and the particular aversion by some physicians to giving a diagnosis of CP. This aversion is very similar to wanting to avoid telling a patient that she has cancer, and therefore telling her that she has a nonbenign growth whose cause cannot be explained. In this way, CP is like cancer in that a physician often cannot determine the etiology; however, the treatment options are well defined and should be started immediately.

Medical Therapeutic Relationship to Child and Family

There are many different types of therapeutic relationships that work for families and their children; however, there are some patterns that work better than others. These patterns each have their risks and benefits as well. The major therapeutic relationships in the treatment of motor problems of children with CP include the parents, the physical therapists, and the physicians. The parents will spend the most time with their children and will know them best. Often, the parents recognize developmental gains and day-to-day variability in their child's function first. Physical therapists will spend the most therapeutic time during treatment with children and will bring the experience of similar children. This in-depth experience with similar children allows therapists to help parents understand the expected changes as well as teach parents and children how to maximize their function. The orthopaedist treating the motor disability will have the least experience with an individual child, but will have the broadest experience with many children to understand the expectations of what will occur. The physician's experience with each child, however, will be much more superficial and the physician depends on the parents' and therapists' observations of the children's function over time and the variability of function during the day. Recognizing these individual strengths will allow the parents', therapists', and orthopaedists' perception of individual children to be combined to make the best therapeutic judgment.

The Physical Therapist Relationship

The role of the primary treating physical therapist, especially for the young child between the ages of 1 and 5 years, will incorporate the typical role that the grandmother and the general pediatrician play for normal children. In addition, the therapist fulfilling this role must have knowledge and experience

in dealing with children with CP. This role model involves time spent teaching the parents how to handle and do exercises with their child. This role also involves helping the parents sort out different physician recommendations, encouraging the parents, and showing and reminding parents of the positive signs of progress in the child's development. When this role works well, it is the best therapeutic relationship a family has. The positive aspects of this role are providing the parents with insight and expectations of their child, reassuring the family that they are providing excellent care, and being readily available to answer the family's questions.

The "grandmothering" role of the therapist has associated risks. One of the greatest risks in our current, very unstable medical environment is that a change in funding or insurance coverage may abruptly end the relationship. An abrupt change can be very traumatic to a family. The therapist must be careful not to be overly demanding of the family, but to help the family find what works for them. Occasionally, a therapist may be fixated on a specific treatment program and believe that it is best for the child; however, the parents may not be in a situation to follow through with all this treatment. The parents feel guilty, and the therapist may try to use this guilt to get them to do more.

The physical therapist in this role as a therapeutic "grandmother" can help parents sort out what medical care and choices are available. The therapist can help parents by attending physician appointments and making the parent ask the right questions, which is often not possible because of funding restrictions. The physical therapist must not give specific medical advice beyond helping parents get the correct information. Therapists with extensive experience should recognize that they have great, detailed, and deep experience with a few children and that generalizing from the experience of one child is dangerous. We have heard therapists tell parents on many occasions that their child should never have a certain operation because the therapist once saw a child who did poorly with that surgery. This type of advice is inappropriate because one child's experience may have been a rare complication of the operation. Also, there are many different ways of doing surgery. This would be like telling someone to never get in a car again after seeing a car accident. A more appropriate response to the family would be giving them questions to ask the doctor specifically about the circumstance with which the therapist is concerned and has experience.

Another physical therapist therapeutic relationship pattern is the purely clinical relationship in which the therapist thinks the family is incompetent, unreliable, or irresponsible and only wants to deal with the child. Almost invariably, this same therapist next will complain that the family and child never do the home exercise program or that the child is not brought to therapy regularly. This relationship may work for a school-based therapist or a therapist doing inpatient therapy, but it leads to great frustration for both the therapist and family when it is applied to an outpatient-based, ongoing developmental therapy. In this environment, the therapist must try to understand and work within the family's available resources.

The Physician Relationship

Families of children with CP often have a series of physician relationships and tend to choose the physician with whom they are comfortable, who responds to their needs, and who is able to help them with their child's problems. As pediatric orthopaedists, many of our patients will report to their schools and emergency rooms that we are their child's doctors. We strongly

encourage families to have family doctors or general pediatricians to care for well child care needs and minor illnesses. With the changing healthcare payers, some families have changed family doctors every year or two and the physician who cares primarily for the musculoskeletal disabilities of a child often becomes defined as the child's doctor.

The musculoskeletal problems of CP are well known and are relatively predictable; therefore, a major part of the treatment is educating the family of what to expect. For example, a nonambulatory 2-year-old child who is very spastic has a high risk of developing spastic hip disease. This risk needs to be explained to parents so they know that routine follow-up is important and that, if spastic hip disease is found, there is a specific treatment program. At each visit, this plan is reviewed again. Diligent attention to this individual education process gives parents a sense of confidence about the future and helps prevent the development of a nihilistic family approach that nothing can be done for their child.

Because families usually start to see the CP doctor when the children are about age 2 years, and in our clinic stay until age 21 years, a long-term relationship is developed. Keeping a healthy therapeutic relationship, understanding and taking into consideration the family's strengths and limits, is important. In addition to helping the family understand what to expect with their child, continuing to support the family as much as possible is very important. One easy way to give the family positive feedback is to focus on the positive things that the child has accomplished, such as better physical functioning, good grades, good behavior, gaining weight, growing taller, and being nicely dressed. There is a tendency for parents to only hear negative things from doctors, such as a catalog of all the things the child cannot do.

Another aspect of the therapeutic relationship is recognizing that this is not a family relationship. Many of our patients are very happy to see us and we enjoy seeing them; however, as they grow and develop, their doctor should be a positive influence but not their main adult role model. These children should not be seen more than every 6 months unless there is an active treatment program such as one following surgery. One goal of the medical treatment of these children should be to have as little direct impact as possible on their normal lives so that they grow up having experiences similar to normal children. To this end, medical intervention should be limited as much as possible and should be episodic so that it more closely mimics normal childhood medical experiences, such as fractures or tonsillitis. Frequent trips to a doctor's office or to a clinic are also very time consuming for families. There are almost no musculoskeletal problems that need to be monitored more than every 6 months.

Recognizing the strengths and weaknesses in families and trying to work within their limits to provide medical care for children with motor disabilities is important. The medical system is limited to working within the confines of what the families and school environment can provide, especially for children with severe physical disabilities. The state social service protection agencies seldom get involved or are very helpful to families, except in rare dire circumstances.

When the Doctor–Family Relationship Is Not Working

Medical care providers need to understand that personalities are such that one individual can never meet everyone's needs. This does not mean that as soon as the doctor–family relationship becomes difficult, it is not working.

At this time, the relationship needs to be discussed and the physician should be open about giving the family permission to go to another doctor. Some families will just leave without saying anything and others will feel guilty about wanting to leave. Physicians must be honest with themselves because this situation tends to make a physician feel like a failure. There may be a combined sense of relief that the family left and a sense of failure and anger that the family does not trust their physician. These are normal feelings that the physician should acknowledge and not place blame on themselves or the family.

When the Family Chooses Medical Treatment Against the Physician's Advice

Families may seek a second opinion for a specific treatment recommendation. This desire to get a second opinion should not be seen by the primary treating physician as a lack of faith or confidence. The family may require a second opinion for insurance purposes or, for many families, they just want to make sure they are getting the correct treatment. Usually, getting a second opinion should be viewed as a very prudent move on the family's part and should be encouraged. Families should be given all the records and support that are needed for them to get a meaningful second opinion. If this second opinion is similar to that given by the primary physician, the family is often greatly comforted in moving ahead. However, there is still variability in medical treatment for children with CP, so depending on the family's choice of opinions, the recommendations may be slightly to diametrically opposed.

In a circumstance where the recommendation of another physician differs significantly, the primary physician must be clear with the family and place the second opinion in the perspective of their recommendation. Sometimes the words used may sound very different, but the recommendations are very similar. In other circumstances, the recommendation may be diametrically opposed and the primary physician must recognize this and explain to the family the reasons for their recommendation. When recommendations are diametrically opposed, clear documentation, including the discussions concerning the other opinion, is especially important. This situation has a high risk for disappointment. Often, families have great difficulty in choosing between divergent opinions, even when one opinion is based on published scientific data and the other opinion is completely lacking in any scientific basis (Cases 1.2, 1.3). Therefore, a family may base their decision on other family contacts, a therapist's recommendations, or the personality of the physician.

Physicians must understand that it is the family's responsibility and power to make these choices; therefore, with rare exception, no matter how medically wrong the physician believes these decisions are, the family must be given the right to choose. Only in rare, directly life-threatening circumstances will a child protective service agency even consider getting involved, and then this involvement is usually very temporary. With a long and chronic condition such as CP, temporary intervention by a child protective agency generally is of no use in interacting with families. With clear documentation of the recommendations, the physician must let the family proceed as they choose; however, we always tell them that we would be happy to see them back at any time. When they undergo treatment against their primary physician's advice and return, usually after several years, the physician should not make the previous situation a conflict. The family usually feels guilty and may not want to discuss past events. Occasionally, they will come back and



Case 1.2 Judy

Judy was born premature as one of twins and weighed 1300 g. She was in the neonatal nursery for many weeks. Her development was noted to be significantly delayed early on, and her CP was recognized within the first 2 years of her life. By school age, Judy was not able to walk, but was able to do some speaking, and there was concern about her educational ability. At age 7 years, she was seen by a developmental pediatrician for an educational assessment. This pediatrician thought that she had excellent cognitive ability, but also noted that she was developing significant contractures, and recommended follow-up with a pediatric orthopaedist. However, she was not seen by a pediatric orthopaedist until age 10 years, when she started to develop some pain in the right hip. At this point, she was in a regular school and was complaining of pain in the hip during the school day. An evaluation demonstrated a completely dislocated right hip and severe subluxation of the left hip; however, this hip was an excellent candidate for reconstruction because, at age 10 years, she had substantial growth remaining. Hip reconstruction was recommended to the family and details were given. For reasons that were never quite clear, this family pursued many other options in trying to deal with their daughter's painful dislocated hip and eventually decided on a treatment that they had located through unknown sources, which consisted of having a spinal cord stimulator implanted in her spinal cord. In addition to the spinal cord stimulator, other alternative medicine treatments were pursued. The hip pain would get better intermittently and then would flare up, requiring her to be in bed for several days. By 14 years of age Judy had periods of relative comfort between bouts of severe pain, until age 15 when the pain became more constant and severe. By age 15 years, as she entered high school with normal cognitive and educational achievements, the pain got so severe that she could no longer sit during the school day. At this point, her parents kept her home in bed and gave her a variety of different pain medications. She was out of school for 1 year, spending most of her time in bed, when her parents finally came back with a request to have her hip reconstructed because they now perceived she could no longer deal with the pain.

At this point, except for getting a brief history, her

parents were told simply that reconstruction was no longer possible, and she now required some palliative treatment. Her parents were assured that good treatment was available to get rid of her pain; they were informed of the treatment options, and it was strongly recommended that these options be pursued. Surgery was scheduled emergently and was completely successful in alleviating her pain.

This is an example of a family who for unknown reasons chooses alternative medical treatments instead of well-recognized appropriate medical treatment. This type of behavior may be very difficult for a physician to accept. This family only saw us once when their daughter was 10 years old, and then did not come back for more treatment. In these situations a physician can only make the recommendations, but cannot force the families to follow through with treatment. This girl clearly would have been much better served by a reconstruction at age 10 years; however, the family had complete control. This family's choice of treatment was not inappropriate enough legally whereby the physician would have gained anything by reporting the family to child protective services or making any other efforts to try to force them to have treatment. There are many different types of alternative medical treatments that families may pursue, some of them performed by a physician, such as spinal cord stimulators, which provide absolutely no benefit to this kind of spasticity or pain. There is nothing that the primary caring physician can do except try to persuade the family and then accept their decisions. However, it is very important to always leave the family the option of coming back when they are ready and then provide appropriate treatment, as was done in this situation.

Six weeks after this girl's surgery, at which point all her hip pain was gone, the family noted that she was having difficulty sitting because of her scoliosis. They were now very keen on moving ahead and having the scoliosis corrected. This is a circumstance where although the family feels extremely guilty and are often very hesitant to return because of fear that the physician will be angry with them, once the appropriate treatment has been performed and is successful, the family will become very committed to continuing with appropriate medical care.



Case 1.3 Rhonda

Rhonda was born following a normal pregnancy and normal delivery. She was perceived to be normal until 18 months of age when her development was noted to be substantially slow and a full evaluation demonstrated an infantile cytomegalovirus (CMV) infection. She continued to make progress and by age 3 years had started walking independently and was speaking. She had low muscle tone with some difficulties with balance. She was doing well in a special education class environment until age 9 years, when she had sudden complete loss of hearing in both ears. An evaluation demonstrated that this hearing loss was in response to the CMV infection. By age 13 years, she had developed severe scoliosis that was making her ambulation difficult. At this point she was quite healthy, and although she had not regained any hearing, she was a full community ambulator. The posterior spinal fusion was performed without difficulty, and the family was told that based on her excellent general health, a fairly quick recovery was anticipated, with her being ready to leave the hospital in approximately 7 days.

However, in the intensive care unit (ICU), on the first day following surgery she became quite hypotensive, requiring a substantial bolus of fluid as well as a dopamine for blood pressure support. Blood pressure support was required for 5 days, and she then developed respiratory problems and was on ventilator support for 5 days. Following extubation, she continued to have pulmonary problems needing positive pressure respiratory support at night. In the meantime, she also developed a mild pneumonia requiring antibiotic treatment. Instead of being discharged from the hospital in 7 days, she was discharged from the ICU to the floor 13 days postoperatively.

During this time, the family became anxious because it was medically difficult to make specific predictions about what to expect. The family was kept informed and, overall, they were able to relax as slow progress was made in the ICU. Each day, the family saw that she was stable or slightly better. Gains were made, such as discontinuation of the dopamine for her blood pressure support, then discontinuation of the ventilator. This progress was followed by needing fewer respiratory treatments as her pulmonary status gradually improved. Being able to see these gains, although slow, gave the family hope and understanding that things were progressively improving.

By postoperative day 10, she had developed some superficial wound separation and very minimal drainage; however, she was afebrile because she was being treated by antibiotics for her pneumonia. The family was informed

that this wound opening was not uncommon, especially after having been extremely edematous, and the mild wound drainage was not a concern.

By postoperative day 17, this wound drainage was not decreasing and instead was increasing. The patient was still afebrile, was continuing to make good progress with her respiratory status, and was able to be up walking in physical therapy. However, based on the amount of drainage and the appearance of the wound, it was possible that this could be a deep wound infection. The family was told that the wound did not look good, and that if after 2 more days the drainage did not substantially decrease, a more vigorous exploration would be done. On postoperative day 19, the drainage increased slightly; therefore, a more detailed digital inspection, trying to determine the depths of the wound, was undertaken. The deep fascia was noted to be open at the far superior aspect of the wound, and the family was informed that this was a deep wound infection. The girl needed to be returned to the operating room, and the wound surgically cleaned out, then treated with open packing and dressing changes. At this time the family was told that she would now be in the hospital for an additional 4 weeks on intravenous antibiotics and wound dressing changes, followed with probably 2 weeks of home intravenous antibiotics. The family was already very anxious about all the complications in the ICU, and now the deep wound infection was another major setback. However, after the parents went home and discussed the significance of this new problem with an understanding of the exact timetable that was required, they were able to make family plans. They came back to the hospital the following day and had more discussions concerning details about the planned treatment. After making plans with the specific information they were given, they shared that they had made arrangements for their other children and were comfortable and relaxed with the plan. They were prepared for the 4 weeks, and the remainder of the treatment was very uneventful.

This case demonstrates how important it is to keep the family well informed as complications are occurring. To give the family the information, the physician has to recognize the complication and develop a clear treatment plan. There is a tendency, especially in situations where there have been multiple complications and the family is very anxious, for the physician to not want to give the family more bad news. Ignoring problems like deep wound infections will not make them go away, and the problem

will continue to be frustrating. When a clear treatment protocol with the expected outcome is outlined, and the family is informed that although this is a substantial setback, it should not compromise the long-term outcome

of their child's treatment in any way. In this specific case, it was equally important to reassure the family that the spine fusion was successful in spite of the current problem and that the rod did not need to be removed.

blame the physician for the problems because they have transferred the blame for the recommendation (Case 1.4). Nothing will be gained by bringing up these past problems with the family, and the focus should be to move on with the problems at hand as they present themselves.

Recommending Surgery

For children who have had regular appropriate medical care, the need for specific orthopaedic procedures is usually anticipated over 1 to 2 years, and as a consequence is not a surprising recommendation. We prefer to have these discussions in the presence of the child. For young children, there is no sense that something is being hidden from them. Children in middle childhood and young adulthood can take in as much as possible, allowing us, as their physicians, to directly address their concerns as well. For younger children, those under age 8 years, their main concern is that they will be left alone. We reassure them that we make a major effort to allow the parents to stay with them during preinduction in the surgical suite and again in the recovery room. We also reassure children that their parents will be with them throughout the whole hospitalization. As children get older, especially at adolescence, there is often an adult type of concern about not waking up from anesthesia or having other severe complications leading to death. These individuals may have great anxiety, but have few of the adult coping skills that allow the rationality to say that this surgery is done every day and people do wake up. Some of these adolescents need a great deal of reassurance, most of which should be directed at trying to get them to use adult rational coping skills. If adolescents are having problems with sleeping or anxiety attacks as the surgery date approaches, treating them with an antianxiety or sedative agent is very helpful.

Some adolescents and young adults with mental retardation develop substantial agitation over surgery. Parents of such children are usually very aware of this tendency and may wish to not tell them about having surgery until the day before or the day of surgery. Although this is a reasonable practice for individuals with severe mental retardation who are not able to cognitively process the planned surgery, approaching children who are cognitively able to process the event in this way is only going to make them distrustful of their parents and doctors.

In preparing children and families for surgery, it is important to discuss the expected outcome of the surgery with them. Part of this discussion must focus on what will not happen, specifically that their child will still have CP after the surgery. If the goal is to prevent or treat hip dislocation, showing radiographs to the families helps them understand the plan. They also need to be told what to expect of the procedure from a functional perspective, such as "Will the child still be able to stand? Will the child be able to roll? Will the child's sitting be affected? Will the child's walking ability be affected?" For children in whom the surgery is expected to improve walking, showing families videotapes of similar children before and after surgery helps them get a perception of what level of improvement is anticipated.



Case 1.4 Patricia

Patricia was born at 35 weeks weighing 2250 g. She had a relatively normal postnatal course except that she was noted to be very good and slept a lot, even requiring awakening occasionally to eat. However, by 19 months of age, she had significantly decreased tone in her lower extremities and trunk, but had increased tone in her right upper extremity with some spasticity and was diagnosed as a right hemiplegic pattern CP. By age 4 years, she was able to sit but had very spastic lower extremities, which caused scissoring and equinus when she was standing. She was able to sit on a tricycle and pedal. At this time, the parents first heard about dorsal rhizotomies and were very interested in pursuing this method to decrease the spasticity. By age 5 years, she was walking handheld, but scissoring substantially, and the parents were pursuing various opinions concerning the dorsal rhizotomy. By age 6 years, the parents had gotten a recommendation to use a transcutaneous nerve stimulator on the upper right, very spastic extremity. A course of this stimulation was undertaken even though the child objected because of the discomfort, but the parents persisted for several months until it was clear that there was no benefit.

At age 7 years she was able to stand but could not do independent transfers, although she was doing standing transfers with considerable scissoring. She was not able to walk independently without someone guarding her. The parents continued to get various conflicting opinions on the merit of a dorsal rhizotomy from several dorsal rhizotomy evaluation programs. Finally the family decided to have the child undergo a dorsal rhizotomy at age 7 years. After 1 year of intense rehabilitation, the mother was very depressed and angry with herself and with the physicians. After an extensive discussion, the mother volunteered that she was blaming herself and also the physicians, both those who recommended for and against the procedure, for her daughter having undergone a dorsal rhizotomy. She believed the rhizotomy caused her daughter to lose function in spite of an extremely intense amount of physical therapy work and stress over the year following the surgery.

After further discussion, the mother was encouraged and began to see this experience as an attempt by herself and her husband to choose what was right for their daughter. The mother was slowly able to acknowledge how difficult it is for a family to make decisions when there are varying medical opinions about a procedure, especially a new procedure where there are few data available, such as the dorsal rhizotomy in the late 1980s. The mother was able to come to terms with feeling badly about her daughter

having the surgery, and she stopped blaming herself and the physicians because she understood that everybody was trying to do what they thought was best with the knowledge they had available at the time. The mother was encouraged to focus forward because, following dorsal rhizotomy, some of the spasticity does return and her daughter probably would slowly regain some of the lost function. The functional loss was specifically identified as the inability for independent stance, for good assisted transfers, and for household ambulation while being held by her hands.

Over the next 3 years, some tone did return and this girl was able to do some minimal standing transfers; however, she has become very heavy, making it difficult for her and her family. She underwent reconstructive surgery of her right upper extremity, which improved her ability to use the right extremity to hold on and assist with transfers. Seven years after the dorsal rhizotomy, she developed a severe kyphosis at the site of the rhizotomy that required a posterior spinal fusion. This development caused her parents some renewed agitation about their daughter having undergone a procedure that they still felt was very detrimental. This combination of the family struggling to deal with their daughter's disability as she is becoming full adult size, and trying to find past blame for the cause of some of the disability, has made it somewhat difficult for the girl to come to terms with her own disability.

After the posterior spinal fusion, she developed a substantial depression and anxiety syndrome with a period of pain, difficulty with sleeping, and poor appetite. Initially, she was started on amitriptyline to help with the poor diet and sleep. This medication helped by substantially improving her diet; however, she continued with significant amounts of anxiety and the amitriptyline had to be increased over a 2- to 3-month period instead of being decreased. She was referred for a psychiatric consultation for better pharmacologic management of her depression and anxiety. The improved pharmacologic management, as well as some counseling with the parents, has greatly assisted this young woman in making the transition to young adulthood.

This case is an example of parents who try very hard to find the latest and best treatment, and after extensive consultation with conflicting opinions, make a decision that does not turn out well. This decision-making process can inflame the process of coming to terms with the child's disability further, making the parents feel that they are

themselves partially to blame. This concept of who is to blame and why this has happened seems to get magnified at adolescence, especially with development of major deformities and surgery, such as a posterior spinal fusion. These issues often lead to family stress, including depres-

sion in both the child and family members and marital stress, and may aggravate substance abuse. It is important in such families that the family stresses are identified and that good psychiatric consultation be obtained for both psychologic and pharmacologic management.

A Plan for Managing Complications

Discussion of possible complications is also important; however, the expected outcome should be honestly approached. Some surgeons tend to have very pessimistic expectations with regard to expected outcome and complications. Surgeons with this approach soon overwhelm themselves and their families with their assessment of the poor balance between the expected outcome and the possible complications. Most surgeons who have a large CP practice tend more toward the overly optimistic approach in which the outcomes clearly will be worth the risk of the complications. The risk of an overly optimistic approach to families occurs when there are complications. These families may be surprised and angry and find it difficult to deal with the unexpected. It is difficult for physicians to have the perfect balance, but each physician should be aware of their own tendency. Usually, an honest assessment and feedback from partners will identify which personality trait, either optimistic or pessimistic, a physician tends to use when approaching families. By recognizing this tendency, surgeons can be more sensitive to what families are hearing and make suggestions to moderate this perception.

There are families who for some reason or another have not been obtaining appropriate orthopaedic care for their children. Then, when these children are adolescents, they may come to see a CP surgeon with a painful hip dislocation, severe scoliosis, or other deformities that are in a severely neglected state. Some of these families are surprised to hear that only a surgical procedure will be the appropriate treatment. Some families may be very resistant to surgery and will want to try everything else. These families must understand that only surgery will correct the problem, but the surgery seldom has to occur on an emergency basis. If a surgeon perceives a family's hesitancy, and attempts to mollify them by suggesting that a brace, injections, or some other modality be tried even though it will provide no long-term benefit, the family will likely hear uncertainty in the physician's approach.

Families may miss the message completely that only surgery will address the problem when they are appeased by nonsurgical treatment. Giving children temporizing measures to provide relief of pain is appropriate; however, doctors must be clear to families that these measures are only providing temporary pain relief and are not treatments. By giving families a little time with the use of these temporary measures, physicians can develop a relationship with the families. There are situations where medical and psychiatric treatment may be required before the surgical treatment can occur. For all these reasons, it is important to be clear about the required treatment, its expected outcomes, and then to outline the full treatment plan. As this treatment plan is undertaken, the relationship a physician has developed with children and families will allow them to be confident that the recommended treatment can occur in a safe and effective way.

When Complications Occur

When treatment of a child does not go well, the orthopaedist must first recognize this as a complication. The judgment of recognizing a complication is one of the most difficult to develop and some physicians may never do it well. Many complications, especially in orthopaedics, do not present with the drama of a cardiac arrest. In orthopaedics, a more typical example is the presentation of a deep wound infection. Every wound with a little erythema and a mild superficial drainage is not a deep wound infection. However, when a deep wound infection is present, it should be acknowledged as such. These families should be told of the complication and a definitive treatment plan should be described (Case 1.3). For this process to work, physicians first have to acknowledge the complication to themselves. We have seen many physicians who cannot bring themselves to acknowledge the magnitude of the complication. Likewise, we have seen physicians who overreact to relatively minor problems that will resolve if left alone.

Finding a balance requires physicians to be honest with themselves and be aware of their own tendency toward optimistic or pessimistic ends of the spectrum. The optimist tends to see the complication as minor variance of normal, whereas the pessimist tends to be overly concerned that any wound change may be a deep wound infection. By being aware of one's own tendency, as experience is gained, an approach to diagnosing and acknowledging complications and then making specific treatment plans will be developed. Complications tend to make physicians feel like failures, and a good retrospective evaluation of the treatment course may demonstrate errors of judgment or execution. These errors should be viewed as learning experiences and opportunities to teach oneself as well as others.

A significant number of the case histories in this book are careful analyses of complications that have occurred in our practice. It is important that the approach to analyzing a complication is to determine the exact cause of the complication when possible so that it may be avoided in the future. Saying that "I will never do that operation again" is an inappropriate response to complications. This response comes very close to that of people who say they will never get in a car again after they have had a car accident. Our goal is to always have a complication-free treatment and recovery for every patient; however, we learn the most from careful analysis of our complications and poor outcomes.

Once physicians acknowledge the complications to themselves, the families then need to be told. Families may react with quiet acceptance, frustration, or anger. These feelings are often the same feelings that physicians have about the same complication. If physicians are willing to share some of their frustration and concern about the complications, it often helps families to put the problem in perspective. It is very important to explain to families what to expect from a complication. This explanation should include a detailed outline of the expected treatment plan. If a complication arises that physicians are not comfortable treating, getting a second opinion from, or seeking the help of, another physician is very important. This step should be explained carefully to families. Frequent contact with families is very important, especially if they develop considerable anger and anxiety, because if they feel that the doctor is trying to avoid them, these feelings often increase.

Complications should be managed very much like the initial decision to have an operation. First, specific problems should be carefully defined to families. Next, the range of options and expected outcomes, with respect to the short- and long-term implications, should be placed forward as specifically

as possible. As much as possible, families should be told the detailed expected timeline and exact treatments. For instance, if repeat or additional surgery is expected in the future as a consequence of a complication, this should be laid out for families. If antibiotics are to be used, families should be told for how long and what factors will be monitored to determine a good outcome. This kind of detail gives families a sense that there is someone in charge with experience in dealing with these complications and helps them deal with the fear of the unknown, which the complications often bring to the foreground.

Complications need to be recorded in detail in the medical record and should reflect all the objective observations and alternatives that were considered. This record is not the place where blame should be directed. What is observed to have occurred should be documented objectively without re-writing history. For example, if the toes are found to be insensate and without blood flow in a child who has had a cast on a foot following surgery, this should be reflected in the medical record, followed by a recording of the immediate action taken, such as removing or opening the cast, and the outcome of that action, such as the improved and returned blood flow to the toes. There is no reason to speculate that the cast was applied too tightly, or that the nursing staff failed to elevate the cast, and so forth. This kind of analysis is important, but should be done after the patient is treated appropriately and there has been time to reflect on the whole situation. Often, these initial assessments are incomplete and wrong and most frequently are written to protect the writer. Later, during a more thorough investigation or legal action, these assessments only make it appear as if the writer was trying to cover up or shift blame to someone else.

During stressful treatment periods, especially when dealing with difficult complications, it is very important to ask partners and other colleagues to evaluate the patients and give unbiased opinions. A treating physician can develop a biased view, especially in the face of complications where one would not like to acknowledge personal culpability. Involving other colleagues also gives families the sense that their physician really is trying to keep all options open. If these consultants do have different opinions, these opinions should be discussed between the physicians first, then the options should be outlined for families with a unified recommendation wherever possible. Giving families different treatment recommendations and expected treatment outcomes from several different consultants should be avoided.

The Final Goal

The goal in treating children with CP is for them to grow and develop within the context of a normal family. Their medical treatment and medical condition should be an experience just as a normal part of who they are. For example, a 6-year-old child who fractures her femur will have a 6-month treatment course until most of the rehabilitation is completed. This occurrence will remain a definite event in the child and family's growth and development; however, when she is graduating from high school and going off to college, this medical event probably will have faded into many other growing-up experiences. This is the pattern that we want to try to mimic in children with CP (Case 1.5).

In the past, children might have spent 30% to 50% of their growing-up years in hospitals having and recovering from surgeries trying to make them walk better or to make them straighter, which was very detrimental. Mercer Rang termed this the "birthday syndrome," in which children were in the hospital for most of their birthdays, and nurses were baking their birthday



Case 1.5 Emily

Emily was born premature at 28 weeks weighing 1500 g. She was in the hospital for 2 months following birth. Following her discharge, she was recognized to have increased tone in her lower extremities with some developmental delay early on. By age 4 years, she was developing substantial contractures and had an adductor, hamstring, and tendon Achilles lengthening. She was noted to have rather severe neural deafness. In addition, several eye surgeries were performed in childhood. She started school with some educational support and special treatment for the deafness, but was noted to have excellent cognitive functioning. She succeeded in school with assistance of special support for her hearing disability. At one point, she was sent to a boarding school specializing in teaching children with hearing disabilities. However, after 1 year, she missed interaction with her family and returned to the normal school setting.

She had two additional medical treatments, one at age 10 years for additional muscle lengthening, and one at age 13, which consisted of a triple arthrodesis of her feet, hamstring lengthenings distally, and a rectus transfer at the knee. She continued to walk in the community with a combination of Lofstrand crutches and a walker. Around the house, she would walk holding on to furniture. During her high school years, she developed a mildly increased crouching gait pattern and was placed in a ground reaction ankle foot orthosis (AFO), which she disliked. However, she acknowledged that the braces allowed her to walk easier so she would use them for ambulation in the community. In high school, she did very well both academically and socially. By age 16 years, she was working as a camp counselor for children with hearing disabilities during the summer; at age 18 years she obtained a driver's license. At age 18, following graduation from high school, she entered college. Her goal on entering college was to become a teacher; however, after a little over 1 year in college, she became tired of the college scene and was interested in going to work and being closer to her family and community.

In her high school years, her crouching gait pattern increased slightly during the adolescent growth spurt but then leveled off as her growth completed. On several occasions, we had recommended additional muscle lengthening and realignments to assist her in having a more upright posture. She was always clear that she was not having any pain with walking, she was doing well walking, and she herself was not interested in any more surgery. At the time of these discussions, she would always listen carefully to the recommendations. Because she perceived herself as doing well, she could see no benefit in having surgery.

Emily, in spite of having two substantial disabilities, the diplegic pattern CP, and a significant hearing disability, was able to have a childhood and adolescent experience very similar to her age-matched peers. She is an excellent example of success in reaching our real goal of treatment, because she has responded to many of the stresses of growth and development similar to her age-matched peers, even to the point of dropping out of college and deciding that she would rather go to work. It is especially significant that after she dropped out of college, she has worked for several years now as a teacher's aide, a job she greatly enjoys. She continues to have the goal of returning to college and becoming a teacher. We are quite confident that in time she will accomplish this goal because she has a strong sense of who she is and a strong sense of what she wants to do. Most of this has come from an excellent family environment in which she was given strong structure but also allowed to express herself. She is an example of an individual who did not end with the ideal medical treatment because the crouched gait pattern she currently has as a young adult could probably be improved; however, it has been her choice to not pursue further treatment. The positive assessment we can make as physicians is that the medical care that was provided has not interfered with her growth and development as a competent functioning adult.

cakes and having birthday parties for them rather than their families at home.¹ Many of these children came to see the hospital staff as a second family (Figure 1.2). This seldom happens currently because of greatly shortened hospital stays and improved diagnostic abilities. For most children with CP, all orthopaedic management should ideally be done with only two major surgical events during their growth and development. This ideal is not possible

Figure 1.2. The typical approach to the surgical treatment of children with CP was to perform a surgery almost every year. This concept often led to children spending a great deal of time in the hospital, to the point where the nursing staff would become “pseudo-parents,” more often celebrating birthdays with the children than the children’s own families.



to achieve in all children but should continue to be the goal. Striving for decreasing the number of orthopaedic operative events in children’s lives and moderating the amount of other medical treatments to only those that will have definite and lasting benefit should be continued. For example, an ambulatory child with normal cognitive function should not be having physical or occupational therapy at any time that interferes with their education. Therapeutic goals should be planned during summer months or in ways that do not interfere with education.

Twenty years ago, the use of inhibition casting was popular. It was believed that this technique decreased contractures and managed spasticity. These children were in leg casts for 8 weeks, often requiring trips to the clinic to change the cast every 2 weeks. After 2 or 3 months, the whole process would have to be repeated. If families could tolerate the stress, although few did, these children would be in a cast for 30% to 50% of their growing years. The time and behavioral stress placed on these families meant that a large part of their lives revolved around their children’s medical treatments. When these children graduated from high school, they tended to see all these casting events as a major focus of their growing-up experience instead of the more normal childhood growing experiences, such as going to the beach, going to Disney World, or other parties and events.

In young adulthood, the success of the whole individual with CP is determined much more by the family and the individual’s educational experience than by the activities of the medical treatment. The medical care system can help children and families cope with the disability and allow individuals with CP to function at their maximum ability. However, the medical care system also must recognize that too much focus on perfection of function may cause damage to the growth and development of the children and family unit, especially in the social, psychologic, and educational domains. Achieving this balance varies with each child and family. For example, many successful young adults without disabilities do not have the ideal maximization of their physical function because the focus of their interests is sedentary activities. Just as with these nondisabled young adults, there is great variation in how important maximizing physical function and appearance is to each individ-

ual with CP. When young adults are truly able to make informed and well-articulated decisions, then they have arrived at a level of success in young adulthood. Just as with nondisabled adolescents and young adults, the medical care providers should stress the importance of good physical conditioning; however, trying to enforce a specific level of physical activity against the person's wishes tends not to be very productive. Individuals with disabilities should be allowed to make these decisions in the same way that individuals without disabilities are allowed to decide, even if their physician thinks it is not in their best interest. Therefore, the final goal is to encourage the development of individual adults who are as competent as possible to make their own decisions, who develop the confidence to make those decisions, and are then willing to make decisions and live with the consequences. Always in the context of this final goal, we as orthopaedic physicians want the individual's physical impairments minimized as much as technically possible.

Reference

1. Rang M. Cerebral palsy. In: Morrissy R, ed. *Lovell and Winter's Pediatric Orthopedics*, Vol. 1. Philadelphia: Lippincott, 1990:465–506.

Etiology, Epidemiology, Pathology, and Diagnosis

Cerebral palsy (CP) is a static lesion occurring in the immature brain that leaves children with a permanent motor impairment. The lesion may occur as a developmental defect, such as lissencephaly; as an infarction, such as a middle cerebral artery occlusion in a neonate; or as trauma during or after delivery. Because brain pathology in all these etiologies is static, it is considered CP. Many minor static lesions leave no motor impairment and do not cause CP. Many pathologies, such as Rett syndrome, are progressive in childhood, but then become static at or after adolescence. These conditions are not part of the CP group, but after they become static, they have problems very similar to those of CP from the motor perspective. Other problems, such as progressive encephalopathy, have very different considerations from the motor perspective.

Saying a child has CP only means the child has a motor impairment from a static brain lesion, but says nothing about the etiology of this impairment. Some authors advocate using a plural term of “cerebral palsies” to imply that there are many kinds of CP.¹ There is some validity to this concept, similar to the term “cancer,” in which many specific pathologic types of cancer, each with a different treatment, are recognized. Although applying this concept to CP is appealing from the perspective of determining etiologies and understanding the epidemiology, it provides very little help in actually managing the motor impairment. From the cancer analogy, for example, the specific cellular type and stage of breast cancer are important to know to prescribe the correct treatment. With CP, knowing the cause does not help treat a child who has a dislocated hip. The treatment is based on the diagnosis of CP, as opposed to a muscle disease, spinal paralysis, or a progressive encephalopathy. The original cause of the CP does not matter. Therefore, the concept of “cerebral palsies” is not used in the remainder of this text, and the term cerebral palsy will not carry any information on specific etiology. Although the etiologic information has little relevance in the management of motor impairments, it is of limited importance in some children for giving a prognosis. The etiology can be important to families in terms of genetic counseling with respect to the risks of future pregnancies, and it is important as an outcome measure for nurseries and epidemiology.

Physicians who manage the motor impairments must always maintain a healthy suspicion of the diagnosis of CP, as sometimes a dual diagnosis may be present or the original diagnosis may be wrong. When progression of the impairments and disability, along with a child’s maturity, do not fit the usual pattern of CP, more workup is indicated. For example, a child may be diagnosed with diplegia because he was premature and had an intraventricular hemorrhage, but, by age 6 years, the physical examination demonstrated very

large calves with much more weakness and less spasticity than would usually be expected. This child would need to be worked up for muscle disease with the understanding that he can have both Duchenne's muscular dystrophy and diplegic pattern CP. Alternatively, the child's history may have been a red herring and he does not have CP, but does have Duchenne's muscular dystrophy. There are children born prematurely who have intraventricular hemorrhages but are completely normal from a motor perspective.

Etiology of Cerebral Palsy

As noted previously, there are many causes of CP, and knowing the exact etiology is not very important for a physician managing the motor impairments. The etiology may be important when considering whether a child is following an expected course of maturation and development. Also, parents find the etiology important because it is part of coming to terms with the larger question of why the CP happened. Many etiologies can be separated into a time period as to when these insults occurred. For more detailed information on the etiologies of CP, readers are referred to the book *The Cerebral Palsies* by Miller and Clarke,¹ which provides much greater detail on this specific topic.

Congenital Etiologies

A whole group of congenital developmental deformities lead to CP. These deformities result from defects that occur in normal development and follow patterns based on failures of normal formation (Figure 2.1). A defect of the neural tube closure is the earliest recognized deformity leading to survival with motor defects. The most common neural tube defect occurs in the spine and is known as meningomyelocele. However, this lesion typically does not cause CP, but instead causes spinal-level paralysis. In the brain, the neural tube defect is called an encephalocele, and may be anterior, with a major mid-face or nasal defect. Anterior encephaloceles occur most commonly in Asia, whereas posterior encephaloceles most often occur in Western Europe and America and affect the posterior occiput.¹ The cause of this regional difference is unknown; however, just as folate used during pregnancy has been found to protect against myelomeningocele development, it is believed to protect against the development of encephalocele as well.¹⁻³ Some encephaloceles are related to larger syndromes, such as Meckel's syndrome.⁴ This syndrome includes encephalocele with microcephaly, renal dysplasia, and polydactyly and is due to a defect on the 17th chromosome, specifically in the homeobox gene (HOX B6). This information suggests that many of these deformities may have unrecognized genetic causes. Most children with significant encephaloceles have very significant motor impairments, usually quadriplegic pattern involvement with more hypotonia than hypertonia.

Segmental defects in the brain are called schizencephaly, meaning there is a cleft in the brain.⁵ These schizencephalies vary greatly, from causing minimal disability to causing very severe quadriplegic pattern involvement, usually with spasticity and mental retardation. Several patients with severe forms have genetic defects in the homeobox genes.

Primary proliferation defects of the brain lead to microcephaly. However, there are many causes of microcephaly, most involving toxins or infections, which are discussed later. Conditions in which the brain is too large are called megalencephaly, which should not be confused with macrocephaly, meaning a head that is too large. Megalencephaly is caused by

A

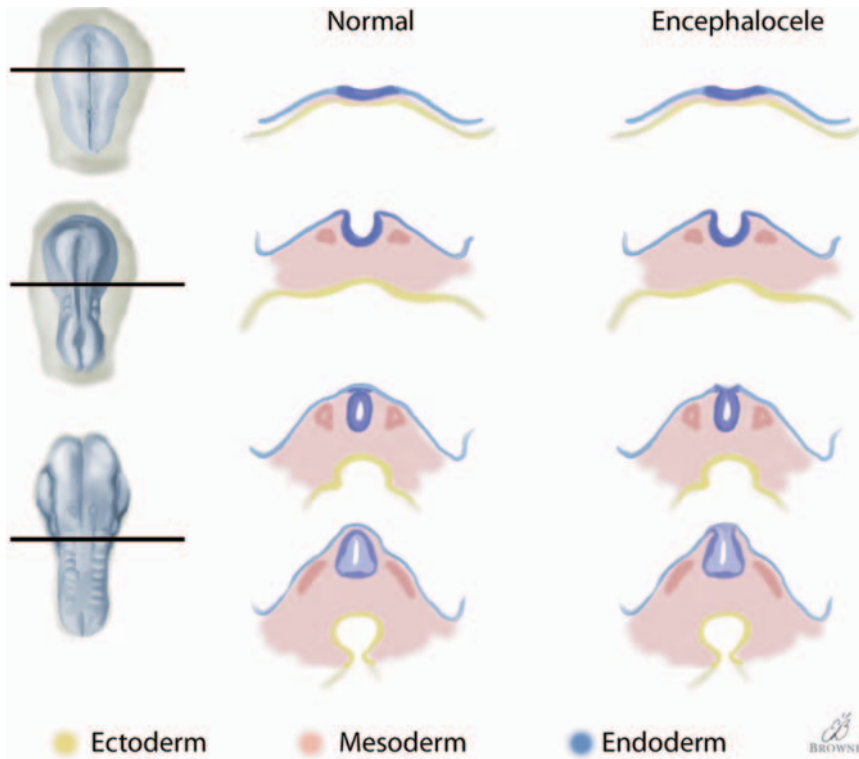


Figure 2.1. In the earliest stage, the neural plate differentiates from the ectoderm, then enfolds to create a neural tube. Failure of this enfolding causes neural tube defects (A). During the embryonic stage, this neural tube develops complex folding with the formation of flexures. During the period of 30 to 100 days of embryonic life, the brain demarcates and develops the cerebral hemispheres. During the rest of gestation, there is a large growth of mass and cell specialization (B).

B

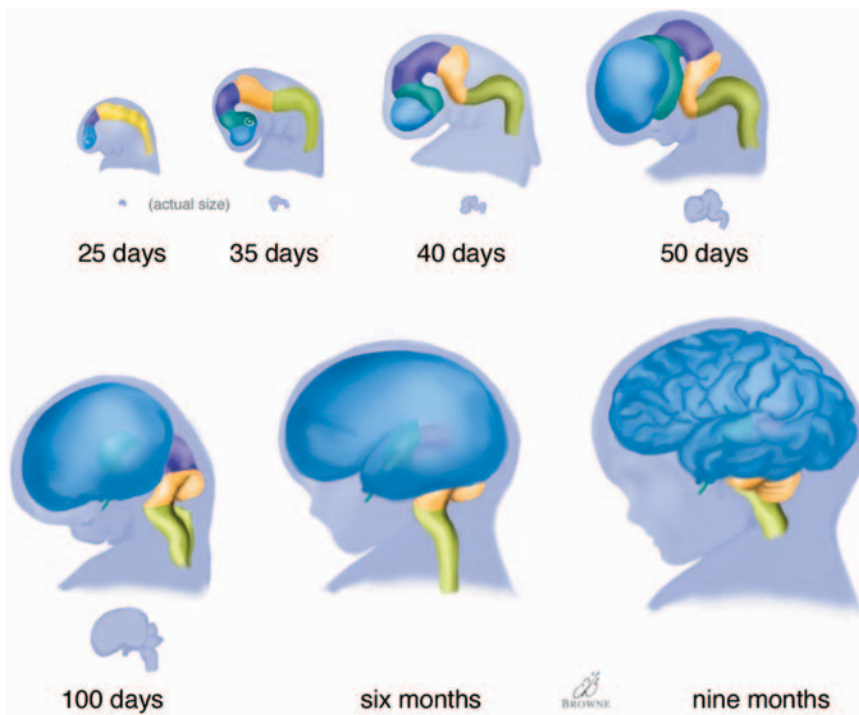
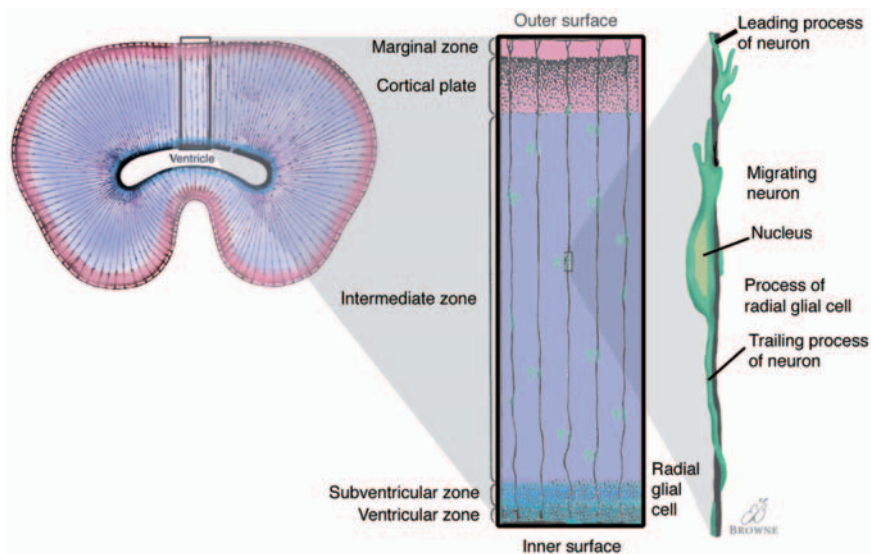


Figure 2.2. As the brain matures, the cells proliferate centrally and migrate toward the cortex. During this migration, trailing connections remain to the deep layer. This migration is an important element in the formation of the gyri of the cerebral cortex. Defects in the migration lead to a smooth brain surface called lissencephaly.



cellular hyperproliferation, usually in syndromes such as sebaceous nevus syndrome, whereas macrocephaly most often is due to hydrocephalus.

During development, the neurons migrate toward the periphery of the brain, and a defect in this migration pattern leads to lissencephaly, meaning a smooth brain, or a child with decreased cerebral gyri. Lissencephaly usually leads to severe spastic quadriplegic pattern involvement, but there is a significant range of involvement. Lissencephaly is X-linked in a few cases. The opposite of too few gyri seen in lissencephaly is polymicrogyria, in which there are too many small gyri (Figure 2.2).¹

A large and variable group of children have differing degrees of cortical dysgenesis, which is a disorder of brain cortex formation. This disorder may be called focal cortical dysplasia and presents mainly with seizure disorders. The motor effects may vary from none to very severe and from hypotonia to hypertonia.

Another part of normal development of the brain in the neonatal and prenatal period requires formation of the synapses and then subsequent remodeling of this neuronal synapse formation. As the cells migrate into the correct position and initially form their synapses, many of these premature synapses need to be remodeled through the influence of external stimuli for normal function to develop. The classic demonstration of this principle was shown in the experiment in which eyes of kittens, one each kitten, were sewn closed at birth. The eye that was denied light stimulation became cortically blind; however, the opposite eye that did get light and normal stimulation became overrepresented in the cortex of the brain.⁶ This experiment has become the basis for treating and understanding amblyopia, or lazy eye, in children. The synaptic remodeling and formation, also called synaptic plasticity in older ages, continues throughout life and is the basis for much of learning. The nature of this synaptic remodeling potential changes with age as demonstrated by the example with the kittens. If the kitten whose eye was sewn shut is denied light stimulation until a certain age, it can no longer recover the ability for sight in that eye.⁶

This concept of synaptic formation and remodeling has been the basis of some therapy programs, specifically the patterning therapy proposed by Doman and Delacatta.⁶⁻⁸ There is no scientific evidence to suggest that the human gait generator can be accessed and impacted in the same way one can

treat lazy eye at an early age in children. However, there is a general understanding that significant seizure activity in a young child may prevent synaptic remodeling through excitotoxic injury, which leads to CP. Inappropriate synaptic formation and remodeling, or remodeling alone, has been implicated as the major neurologic anatomic pathology in Down syndrome, Rett syndrome, autism, and fragile X syndrome as well as many cases of ataxia, idiopathic spasticity, and mental retardation in which there is no other recognized etiology.¹

Neonatal Etiologies

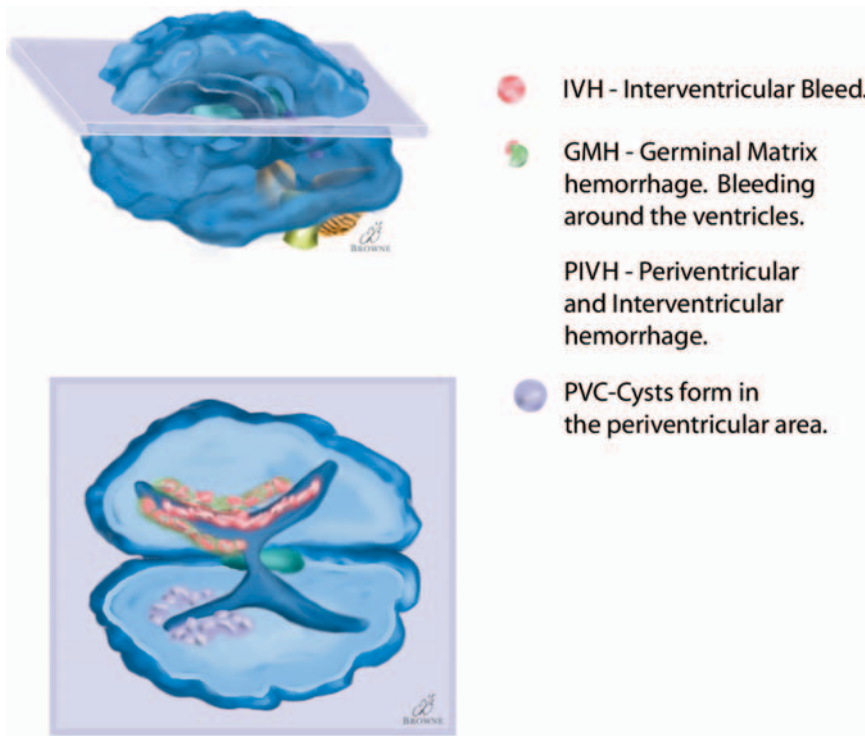
Neonatal and prenatal causes of CP are mainly related to prematurity and birthing problems, which lead to various injury patterns. However, the immature brain has much more equipotentiality or plasticity, both of which are terms used to define the much greater ability of an uninjured part of the immature brain to assume the function of an injured part. This potential of the immature brain to reassign function makes the response to injury much different than in the mature brain.

Prematurity and brain hemorrhages are much better understood since the widespread use of cranial ultrasound, in which the infant brain can be imaged through the open anterior fontanelle. This image provides an excellent view of the ventricles and the periventricular white matter. This is the area where hemorrhages occur, and major risk factors for developing hemorrhages are younger gestational age and mechanical ventilation. Bleeding in the ventricle is called intraventricular hemorrhage (IVH), and bleeding in the periventricular area is called germinal matrix hemorrhage (GMH), or it may be combined in a term called periventricular-intraventricular hemorrhage (PIVH). A common grading system for the severity of these hemorrhage patterns includes grade I with germinal matrix hemorrhage only, grade II with hemorrhage in the lateral ventricle and dilation of the lateral ventricle, grade III with ventricular system enlargement, and grade IV with periventricular hemorrhage and infarctions (Figure 2.3). Reported prognostic significance of these grades varies greatly, and the general consensus is that premature infants with no PIVH have a better survival prognosis than those with PIVH.¹ Also, in group studies, the more severe the grade, the higher the risk of developing CP, as demonstrated in a study that reported the risk of CP was 9% in grade I, 11% in grade II, 36% in grade III, and 76% in grade IV.⁹ However, different studies vary significantly, so good consensus values are not currently available.

These cerebral hemorrhages evolve from GMH and IVH, which develop in the first 72 hours after birth. The brain bleeds then resolve, and periventricular leukomalacia (PVL) develops 1 to 3 weeks after birth in some children. Periventricular leukomalacia in the form of periventricular echogenicity (PVE) may be seen on ultrasound, but does not develop cysts. If cysts develop, it is called cystic periventricular leukomalacia (PVC). In general, infants with PVC have the highest risk of developing CP and infants with PVE have the lowest risk.¹⁰ In one study, 10% of children developed CP if they had PVE; however, 65% developed CP if they had PVC.⁹ Again, these numbers vary between studies. The general trend is that premature infants with more severe bleeds have a worse prognosis for survival and a higher risk for developing CP; however, there are no specific parameters that fully predict risk of developing CP or, much less, predict the severity of CP in an individual child.

Hypoxic events occurring around delivery, usually in full-term infants, also lead to disability. These events have been termed hypoxic-ischemic

Figure 2.3. Bleeding in the immature brain occurs primarily around the ventricles, which have many fragile vessels. Intraventricular hemorrhage (IVH) means bleeding into the ventricles. Germinal matrix hemorrhage (GMH) means bleeding into the tissue around the ventricles. Periventricular intraventricular hemorrhage (PIVH) means bleeding into both areas. Periventricular cysts (PVC) form in these same areas as the acute hemorrhage resolves.



encephalopathy (HIE). The causes of this hypoxia may vary from obstetric dystocias to other anoxic and low-flow states in the neonate. In severe cases of HIE, subcortical cyst formation develops and is called multicystic encephalomalacia. In general, when this cystic pattern forms, the prognosis for good function is poor, with most of these children developing severe quadriplegic pattern involvement with severe mental retardation. Some of these children develop cysts in the thalamus and basal ganglia, which may lead to dystonia.¹

Neonatal stroke occurring in the preterm or full-term infant usually involves the middle cerebral artery and presents as a wedge-shaped defect in one hemisphere. These defects may develop as cysts, which, if very large, are called porencephaly or porencephalic cysts. In general, if these wedge-shaped defects are small, the children may be normal; however, a significant defect especially with a cyst usually presents as hemiplegic pattern CP. Even with large cysts, these children's function, especially cognitive function, may be quite good.

Postnatal Causes of Cerebral Palsy

Postnatal causes of CP may overlap somewhat with the prenatal and neonatal group; however, postnatal trauma, metabolic encephalopathy, infections, and toxicities are considered as etiologies in this group. Although the data are difficult to assimilate, between 10% and 25% of CP cases have a postnatal cause.^{11,12}

Child abuse or nonaccidental trauma causing brain injury in a young child may be due to blunt trauma with skull fractures or fall into the pattern of shaken baby syndrome. Shaken baby syndrome occurs usually in a child less than 1 year of age when a caretaker shakes the baby back and forth to quiet the crying. This vigorous shaking causes stretching, shearing, and tear-

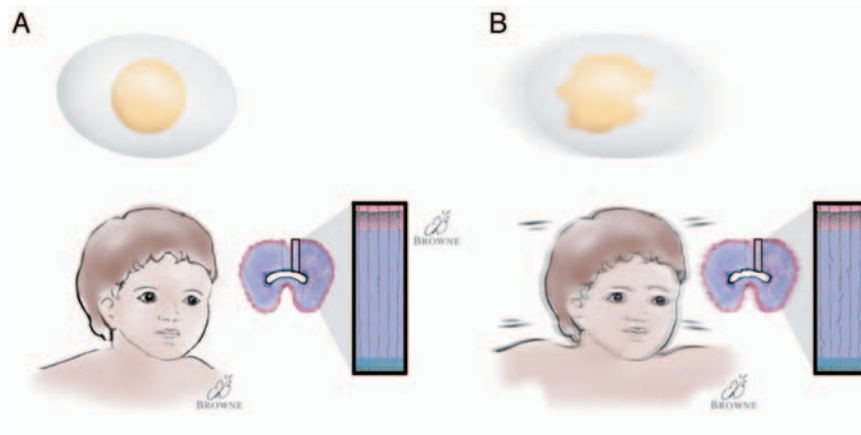


Figure 2.4. Shaken baby syndrome creates an injury in which axons are disrupted by the shear forces created from the violent shaking of the head. The brain of the baby is like an egg in which the liquid center is enclosed in a solid outer shell. By vigorous shaking, the egg yolk can be broken without breaking the shell of the egg. In the same way, vigorous shaking of a baby's head can cause tissue disruption. This shearing stress disrupts brain tissue, especially the long migrating axons of the cerebral cortex. The trauma of the shaken baby does not usually cause a skull fracture and may not even cause intracranial bleeding, but it often causes severe long-term neurologic impairment because of the cellular disruptions.

ing of the long axons and capillaries in the cortex of the brain (Figure 2.4). If these babies survive, they often have a severe spastic quadriplegic pattern involvement with a poor prognosis for improvement.⁵ Even children with less severe motor involvement often have a concomitant profound mental retardation.

Blunt head trauma may also occur from child abuse, falls, or motor vehicle accidents, and it involves the direct injury as well as the secondary injury from brain swelling. Most children with blunt trauma recover and have no motor defects.¹³ However, if there is a unilateral bleed, these children are often left with a hemiplegic pattern motor disability. The more severely involved children are usually left with a severe quadriplegic pattern involvement and do not become functional community ambulators. Many children with motor impairments from closed head injuries have ataxia as a major impairment.

Children with closed head injuries will make substantial improvement for 1 year after the injury and only in rare severe cases should surgical treatment of secondary problems, such as contractures, be considered during this year. Also, many children continue to improve even through the third year after injury; therefore, it is probably best not to consider the lesion static until 3 years after the injury.¹⁴ Even then, these lesions continue to evolve in some individuals, with the well-recognized syndrome in which early spasticity resolves but then dystonic movements later develop in the previously spastic limb. This syndrome has been reported to occur up to 9 years after closed head injury, even when it seemed that all the spasticity had resolved.¹⁵ We have seen recurrent dystonia become most severe during and after puberty, as the hormonal surge somehow makes it worse.

Metabolic encephalopathy has a wide variety of causes, most extremely rare. It is impossible to give a comprehensive review in this text, and when specific cases are encountered, it is important to obtain disease-specific up-to-date recommendations from the subspecialized expert who is managing the care of the child. Also, the neuro-orthopaedist should have a good reference text available, such as the Aicardi text *Diseases of the Nervous System in Childhood*.¹⁶ The metabolic disorders can be divided into storage disorders, intermedullary metabolism disorders, metallic metabolism, and miscellaneous disorders (Table 2.1).

It is extremely important for physicians caring for children's motor problems to understand the expected course of the disease. For example, many of the storage disorders are progressive and these children have limited life expectancy, which limits attempts to correct motor impairments that are not

Table 2.1. Metabolic neurologic diseases.

Name	Primary defect	Typical course	Significance for surgical management
Storage diseases	intercellular accumulation	Most of these have no treatment and are progressive	
Gangliosidoses	Hexosaminidase defect, multiple types	Each type has its own course	
Tay–Sachs disease	HexA and HexB nonfunctional due to chromosome 15 defect	Short-term survival in childhood	
Sandhoff’s disease	Type O gangliosidosis	Clinically like Tay–Sachs	
GM1 gangliosidosis	Multiple subtypes, beta-galactosidase deficiency	Rare cases and variable effects	
Gaucher’s disease	Multiple types, beta-glucocerebrosidase deficient	Outcome is variable, based on the subtype, from rapid course with death in early childhood to relatively mild involvement	Most patients have hepatosplenomegaly Be especially aware of significant splenomegaly Also, bone lesion from the storage disease may be present
Niemann–Pick disease	Sphingomyelinase deficient, multiple subtypes	The more severe types have rapid degeneration and death; some mild types may have minimal involvement and life into middle adulthood	Bone marrow may be involved, and some patients develop a peripheral neuropathy
Fabry’s disease	Sex-linked deficiency of ceramide trihexoside	Foam cells with vacuolated cytoplasm develop in muscles, nervous system, kidneys	Death is usually from cardiac or renal failure Females are less affected May begin as severe muscle pain Renal failure may occur
Metachromatic leukodystrophy	Cerebroside sulfatase deficiency, multiple types	Often presents as a gait disorder in childhood May initially look like a neuropathy Adult forms present as behavior problems	
Krabbe’s disease (globoid cell leukodystrophy)	Beta-galactocerebrosidase deficiency	Age of onset, and survival, are variable	May present with slow-onset hemiplegia or diplegia
Mucopolysaccharidosis	All have deficiencies of lysosomal glucosidase or sulfatase	Often the neurologic problems are less severe than the systemic ones	Bone marrow transplantation is used to treat a number of these conditions
Hurler’s syndrome	—	Severe neurologic retardation	Severe dwarfism Cervical instability
Scheie’s syndrome	—	Types, very mild to minimal problems	Hydrocephalus may develop
Hunter’s syndrome	—	Severe dwarfism	Mild to moderate neurologic involvement
Sanfilippo’s syndrome	—	Severe progressive neurologic involvement	Minimal skeletal problems
Morquio’s syndrome	—	Variable forms but marker bone involvement	Cervical instability may cause spinal cord compression
Maroteaux–Lamy’s syndrome	—	No neurologic involvement Severe dwarfism	Nerve entrapment syndromes are common Mild to severe bone and neurologic involvement
Sly’s syndrome	—	Very variable	Mild to severe bone and neurologic involvement
Mucopolipidosis, sialidosis, glycoprotein metabolism deficiency	—	Many types, all very rare	
Sialidosis type one	Also called cherry red spot myoclonus syndrome	Slow progression No other involvement	Late onset Has a pure intention myoclonus that slowly gets worse with age
Mucopolipidosis IV	—	Failing vision and mental delay after normal infancy	May develop dystonia

Table 2.1. Continued.

Name	Primary defect	Typical course	Significance for surgical management
Mannosidosis	Alpha-mannosidase deficiency	Several types, usually with cognitive limits and minimal progression	
Fucosidosis	Fucosidase deficiency	Progressive mental retardation	Develop significant spasticity
Galactosialidosis	Neuraminidase and beta-galactosidase deficiency	Develops progressive myoclonus and extrapyramidal signs	Thoracolumbar spinal deformity may be present
Salla disease	Sialic acid transport deficiency	Mental and motor retardation, progressive	Course varies
Aspartylglycoaminuria		Has mental deterioration in late childhood or adolescence	Causes bone deformities, mitral valve insufficiency
Pompe's disease		Hypotonia	Severe mental retardation Early death
Batten disease (infantile form)	Neuronal ceroid-lipofuscinosis	Severe brain atrophy	Anxiety and autistic behavior Death after a prolonged vegetative state Has repetitive hand movements that may be confused with Rett syndrome
Spielmeyer–Vogt–Sjogren (juvenile form)		Condition starts in middle childhood	Slower course Death in 15–30 years
Kufs' disease (adult form)		Present with behavioral changes and dementia	
Amino acid metabolism	Many causes, only those more relevant included		
Phenylketonuria (PKU)	A defect in the hydroxylation of phenylalanine to tyrosine; the defect may occur in one of two enzymes or two required cofactors	Untreated children develop severe mental retardation and self-abuse	With early dietary treatment most of the symptoms can be avoided Requires treatment until age 4–8 years
Hyperphenylalaninemia (HPA)	Same as PKU		
Maple syrup urine disease	Organic aciduria; many subtypes	Disease varies from rapid progression to later onset or minimal progression	May cause acute coma Treatment varies by the specific defect Most of these conditions cause most of the problems during periods of stress when the body may depend on protein metabolism for energy source; this is especially true during major surgical procedures and can usually be avoided by using high-glucose infusion such as a 10% glucose solution intra- and postoperatively Blood pH level needs to be monitored and urine should be monitored for ketosis If proper precautions are not taken, ketoacidosis, hyperammonemia, and hyperlacticemia may develop and cause cerebral edema with further neurologic injury
Glutaric aciduria	Glutaryl-CoA dehydrogenase deficiency	Several types	Untreated neurologic effects leave the child with severe dystonia Cognitive process more preserved Stress causes a ketoacidosis, which causes brain injury Neurologic effects can be avoided with early dietary treatment Must take all the same precautions as noted for maple syrup urine disease

(continued)

Table 2.1. Continued.

Name	Primary defect	Typical course	Significance for surgical management
Homocystinuria	Cystathionine beta-synthase deficiency	Cause mental retardation and spasticity	Develop dislocated lens Also have thromboembolic disorder May present with a Charlie Chaplin-like walk Other common bone deformities include pectus, genu valgum, biconcave vertebra, epimetaphyseal widening Because of the thromboembolic problems, even children should probably have anticoagulation during surgical procedures
Sulfite oxidase deficiency		During infancy children have poor feeding, severe seizures, and present with quadriplegic pattern motor involvement Usually die in early childhood	
Tyrosinemia		Present with liver failure and neuropathy	Also often complain of severe leg pain Course is variable
Tetrahydrobiopterin deficiencies (“malignant HPA”)	Same pathway as PKU and HPA	Children have progressive deterioration even with appropriate dietary treatment Children have progressive spasticity and limb rigidity Sometimes with dystonia or athetosis	Clinical course is variable
Nonketotic hyperglycinemia	Glycine accumulates because it cannot be metabolized	Course is usually with severe seizures and short-term survival, although some develop a more typical spastic CP pattern	
4-Hydroxybutyric aciduria	GABA neurotransmitter metabolism error	Presents with a static hypotonia and ataxia	
Urea cycle disorders	Ammonia accumulation causes brain injury	There are a number of different deficiencies, all with a similar presentation, but with varying severity	These conditions are like maple syrup urine disease in that during stress periods, such as acute sepsis or major surgical procedures, patients must be protected from high protein metabolism, which will cause the ammonia level to raise, running the risk of developing cerebral edema; this can be prevented with high-glucose fluid infusion, usually using 10% dextrose
Citrullinemia			Hepatomegaly common
Argininosuccinic aciduria			Often have brittle hair Hepatomegaly common
Arginase deficiency			Usually presents as a quadriplegic pattern CP with progressive spasticity
Vitamin metabolism disorders	Many are autosomal dominant inherited		
Multiple carboxylase deficiency	Impairment of the biotin recycling pathway	Skin rash, hypotonia, seizures, ataxia	Symptoms improve with high-dose biotin treatment
Vitamin B ₁₂ metabolism defect		Anemia, seizures, microcephaly, pancytopenia, malabsorption Variable presentation	
Folate metabolism defect		Similar to B ₁₂ deficiency	

Table 2.1. Continued.

Name	Primary defect	Typical course	Significance for surgical management
Lactic acidosis (respiratory chain disorders)	Defect in the terminal step of the energy production cycle		The workup and diagnosis of many of these conditions require a skeletal muscle biopsy because the muscle is often involved This biopsy is also how to study mitochondrial function
Mitochondrial cytopathy		Usually presents in early infancy or early childhood with delayed motor skills, fatigue, muscle pains	The response is variable, from long static period to spontaneous improvement to sudden deterioration
Multisystem disorders			
Kearns–Sayre syndrome		Normal at birth	Develop headaches, mental retardation, peripheral neuropathy
Mitochondrial myopathy	Ragged red muscle fibers	Often present with stroke-like symptoms between childhood and young adulthood	High incidence of heart block and, if surgery is planned, the team needs to be prepared to insert a cardiac pacemaker
Alpers syndrome	Many different defects are probably causing this clinical syndrome	Autosomal recessive condition of progressive spastic quadriplegic pattern CP syndrome	
Leigh syndrome	Syndrome defined by necrotizing encephalomyelopathy Probably has multiple molecular causes	Course is extremely variable but usually progressive, although there may be long static periods	
Lactic acidosis			
Pyruvate dehydrogenase deficiency	Defect of pyruvate entry to mitochondria	Presents with highly variable hypotonia, seizures, failure to thrive	Some die in early childhood and others survive long term with a severe quadriplegic CP pattern
Mitochondrial fatty acid defects		Very variable with muscle weakness, cardiomyopathy, seizures	
Carnitine deficiency	Because of inability to metabolize protein, depends on glucose for energy	Presents in childhood with muscle weakness and cardiomyopathy	Under stress, such as major surgery, must give high-glucose infusion or there will be no energy even for the heart to function
Peroxisomal disorders	All have autosomal recessive inheritance		
Zellweger syndrome		Hypotonia	Poor swallowing Failure to thrive Develop severe equinovarus feet and flexion contractures Stippled calcification in the bones, especially the patella
Adrenoleukodystrophy		Same as Zellweger but milder form	
Refsum's disease		Similar but is the mildest form	
X-linked adrenoleukodystrophy		Variable, but males are always more affected than females	
Rhizomelic chondrodysplasia punctata		Rhizomelic dwarf with joint contractures	Calcification in the epiphysis and soft tissues Also with mental retardation
Wilson disease	Disorder of copper metabolism	Early on have facial masking, then develop tremor	Later develop a Parkinson-like presentation with psychiatric problems Have hepatic dysfunction When giving medication, must consider liver function
Lesch–Nyhan syndrome	X-linked	Very variable course and usually presents with hypotonia, torsional dystonia, mental retardation, self-abuse	Develop gouty arthritis
Enzyme defect allowing			

seriously disabling. Alternately, many disorders of intermedullary metabolism have acute insults during toxic events before the diagnosis has been made. With proper management, these disorders become static and mimic similar children with CP.

These metabolic disorders often require very specific management protocols during surgery. An example of such a condition is glutaric aciduria type 1, which presents with infants who are normal. When an infant experiences a stress, such as a childhood illness with a high fever, an acidosis develops that causes damage to the brain, especially the putamen and caudate areas. This insult leaves the child with a wide range of spastic and movement disorders, often with significant dystonia.¹⁷ This neurologic disorder is static if the proper dietary management is carried out; therefore, the orthopaedist can approach this child similarly to a child with CP. However, these children must be prevented from becoming acidotic during operative procedures by infusing high levels of glucose, usually using a 10% dextrose solution as the intravenous fluid.

A wide variety of infections leave children with permanent neurologic deficits. Most of these deficits are static and therefore definitely fall into the CP diagnosis group. Prenatal and neonatal viral infections are the most common infectious cause of CP. Cytomegalovirus (CMV) leaves 90% of children with mental retardation and deafness, but only 50% develop CP or motor defects. Children who develop congenital rubella infections very commonly will have mental retardation; however, only 15% develop CP.¹ Neonatal herpes simplex infection has a high mortality rate, and 30% to 60% of survivors have some neurologic sequelae, although CP is not common. In utero varicella zoster infection causes high rates of CP. This same high rate is seen in lymphocytic choriomeningitis, which is a rodent-borne arenavirus. All these conditions cause neurologic insults that are static and should be treated as CP. Infections with human immunodeficiency virus (HIV) may cause neurologic sequelae; however, this is a progressive encephalopathy and these children should be treated anticipating a very short life expectancy. The most common parasite is *Toxoplasma gondii*, which is an intracellular parasite whose most common host is the household cat. With aggressive medical treatment, the infection can be eradicated, and approximately 30% of children are left with CP and mental retardation. Neonatal bacterial meningitis may be caused by many organisms and may be very severe, with as many as 30% to 50% of survivors having CP.¹ In our experience, most of these children who survive bacterial meningitis and have CP will have very severe spastic quadriplegic pattern involvement.

Temporary neurologic deficits are caused by many toxic agents, with alcohol being the most commonly encountered. Alcohol almost never causes a static neurologic deficit. Also, children with prolonged anoxic events, such as near drowning, near hanging, or near asphyxia, can make remarkable recoveries. However, when these children do not recover completely, they are usually left with extremely severe neurologic deficits and are among the most neurologically disabled individuals in our practice. These children tend to be relatively healthy and, in spite of severe neurologic deficits, tend to grow and thrive physically with good nursing care. One child in our practice has been ventilator dependent for 10 years from an anoxic event at age 9 months.

As noted in the beginning of this chapter, knowing the exact etiology is not always important to care for children's motor disabilities; however, it is important to understand whether these lesions are static or not. Also, parents may be more relaxed if physicians have some understanding of the specific etiology, if known, of their children's problems.

Epidemiology

Because of the wide variety of causes of CP, the exact numbers from different studies do not completely agree. However, there is remarkable similarity in the prevalence across the world, from Sweden in the 1980s with a prevalence of 2.4 per 1000¹⁸ and 2.5 per 1000 in the early 1990s,¹⁹ 2.3 per 1000 from Atlanta,¹¹ and 1.6 per 1000 in China.²⁰ Considering the difficulty in making specific diagnoses, and especially finding mild cases, these numbers probably reflect much more variation in counting than clear differences in prevalence. A report from England, which is representative of many studies, shows that there has not been much change in prevalence over the past 40 years. However, the patterns of CP have shifted more toward diplegia and spastic quadriplegia and away from hemiplegia and athetosis.²¹ This change probably reflects increased medical care with better obstetric care and some increased incidence from survivors of neonatal intensive care units. Also, multiple births have increased with increasing maternal age,²² and these multiple births have a substantially higher risk of developing CP. The reported prevalence rate per pregnancy for singles is 0.2%, for twins 1.5%, for triplets 8.0%, and for quadruplets 43%.²³

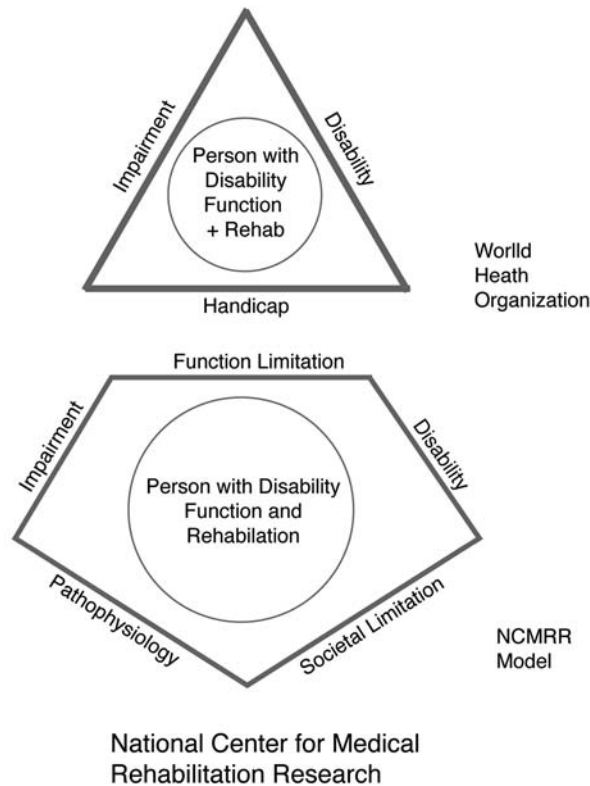
Terminology and Classification

Although understanding the specific etiology of CP is not very helpful for physicians treating motor problems, by segmenting this very diverse condition by cause, patterns that are useful in planning treatment can be identified. There are many ways of classifying CP, one of which is by etiology. However, for the treatment of motor disabilities it is much more important to classify children by anatomic pattern and specific neuromotor impairments than by the cause of the CP. Classifying CP in this way provides a framework in which to discuss the functional problems of individuals in their whole environment.

A framework for understanding individuals with limited motor function has been agreed to at an international forum held in 1980, organized by the World Health Organization (WHO). The report is entitled “Classification of Impairments, Disabilities and Handicaps.”²⁴ In this report, the term “impairment” defines the primary lesion and pathology, such as the problem with the brain that caused the spasticity, and includes the direct effects of the spasticity, such as the dislocated hip caused by the spastic muscles. “Disability” is used to mean the loss of function that individuals experience because of the impairment; therefore, the inability to walk or sit well is a disability arising from the impairment. The “handicap” is the result of limits in the environment and society, which limit individuals as a result of their specific disability. Therefore, an individual who uses a wheelchair has a handicap if he wants to visit a friend and the only way into the house is up a long flight of stairs. This inability to socialize is the handicap and, for many adults, is what impedes them from being integrated into full society of jobs, friends, and social entertainment.

In 1993, the National Center for Medical Rehabilitation Research (NCMRR) added to the WHO classification by dividing impairments into “pathophysiology” and “impairment.” In this classification, “pathophysiology” refers to the primary problem, such as the brain lesion, and “impairment” refers to the secondary effects, such as spasticity and the dislocated hip. “Functional impairment” was added to reflect the inability to do activities

Figure 2.5. The WHO initially developed a model for disability that was later expanded by the USA National Center for Medical Rehabilitation Research. The concepts of both models are similar, with a focus that expands the understanding that problems of function are related beyond the isolated anatomic problem of an individual person.



such as walking that is a direct result of the impairment. “Disability” has retained almost its original meaning, and “handicap” has been renamed “societal limitations” to clarify where the problem of the limitation arises.²⁵ Although there are some merits to the changes NCMRR made to the WHO report for research purposes, the complexity does not work well in thought of daily practice; therefore, in the remainder of this text, the WHO definitions and terminology are used (Figure 2.5).

Anatomic Classification

The most useful primary classification for children with CP is based on the anatomic pattern of involvement. This involvement is the first classification used by physicians treating motor impairments, as it gives a very general sense of severity and a general overview of what patients’ problems likely are. Classification into hemiplegia, which involves one half of the body; diplegia, which involves primarily the lower extremities with mild upper extremity involvement; and quadriplegia, which involves all four limbs, is most useful. In general, individuals with hemiplegia and diplegia can walk, and those with quadriplegia use wheelchairs as their primary mobility device. For patients who do not clearly fit these patterns, many other names have been suggested. Double hemiplegia has been suggested for children with upper and lower extremity involvement that is much more severe on one side than the other. Triplegia has been suggested for individuals who have a hemiplegic pattern on one side and a diplegic pattern in the lower extremities. There are rare children who appear to have hemiplegia and diplegia, which would make anatomic sense, so this term triplegia has some merit; however, it does not aid in treatment planning.

Monoplegia is used when one limb is primarily involved; however, from a motor treatment perspective, these children are treated as if they had mild hemiplegia. In North America, the term paraplegia implies a pure lower extremity paralysis and is used only for spinal cord paralysis because almost all children with brain origin disability will also have some upper extremity involvement, although it may be very minor. Pentiplegia is occasionally used to define the most severely impaired individuals who have no independent head control. This term adds little over the use of quadriplegia in planning motor impairment treatment; therefore, it has not gained widespread use.

Evolutionary Pathology

Even though there are many causes of CP, there are few recurring anatomic patterns of involvement because damage to specific areas, regardless of how the damage occurs, creates similar patterns of impairment. However, a specific region of brain injury can cause variation in the impairments because the initial injury also overlies normal development, which continues after the injury. Because all these injuries occur in the young and immature brain, growth and development over time affects the impairment. A brain injury occurring in early pregnancy, meaning most congenital syndromes, has a different presentation than an injury occurring in a 4-year-old child.

The first aspect of this pathology is to understand the presence of very early primitive reflexes that should disappear as normal children grow. The cutaneous reflexes, mainly finger and toe grasp, occur with stroking of the skin on the palm or on the sole. The sucking and rooting reflexes are similarly initiated with stroking of the face and lips (Figure 2.6). The labyrinthine reflex is a response to the inner ear being stimulated by changing a child's position (Figure 2.7). When held prone, a child will flex, and when placed supine, a child will extend. The proprioceptive reflexes are initiated by stimulating the stretch receptors in the muscles and the position sensors in the joints. This reflex creates the asymmetric tonic neck reflex (ATNR) such that when the head is turned to one side, the leg and arm on that side extend (Figure 2.8). The symmetric tonic neck reflex (STNR) causes the arms to flex and

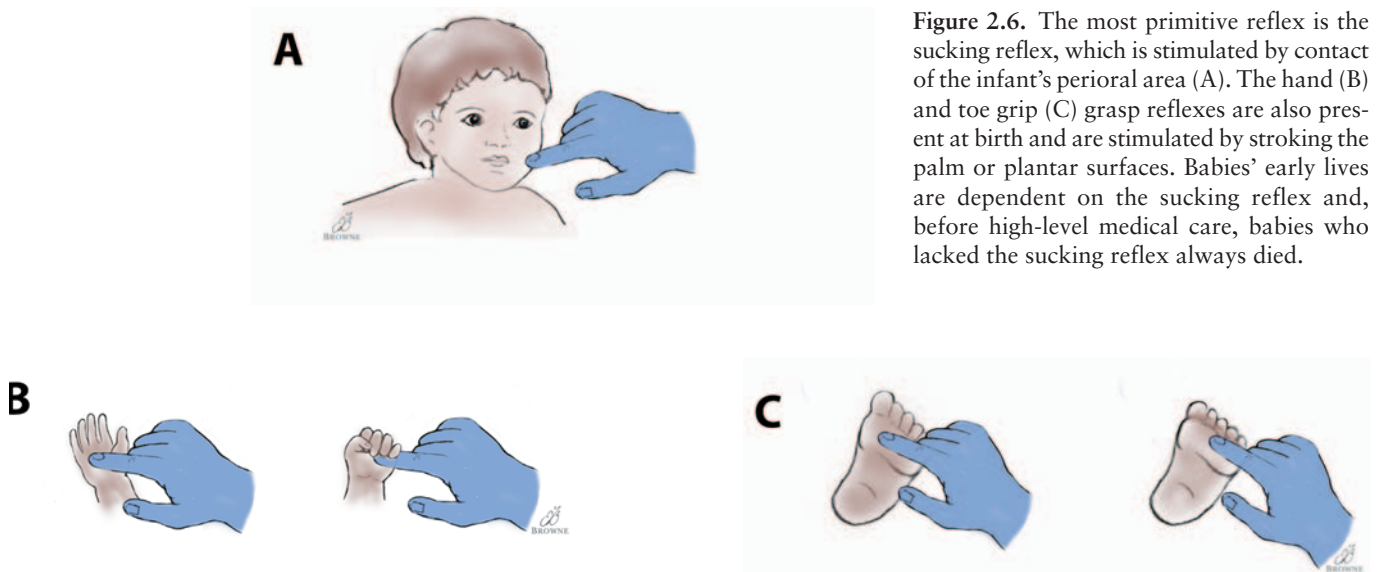


Figure 2.6. The most primitive reflex is the sucking reflex, which is stimulated by contact of the infant's perioral area (A). The hand (B) and toe grip (C) grasp reflexes are also present at birth and are stimulated by stroking the palm or plantar surfaces. Babies' early lives are dependent on the sucking reflex and, before high-level medical care, babies who lacked the sucking reflex always died.

Figure 2.7. The tonic labyrinth reflex shows the baby with abducted shoulders, flexed elbows, adducted extended hips, and extended knees and ankles. This posture primarily occurs with the baby in the supine position.

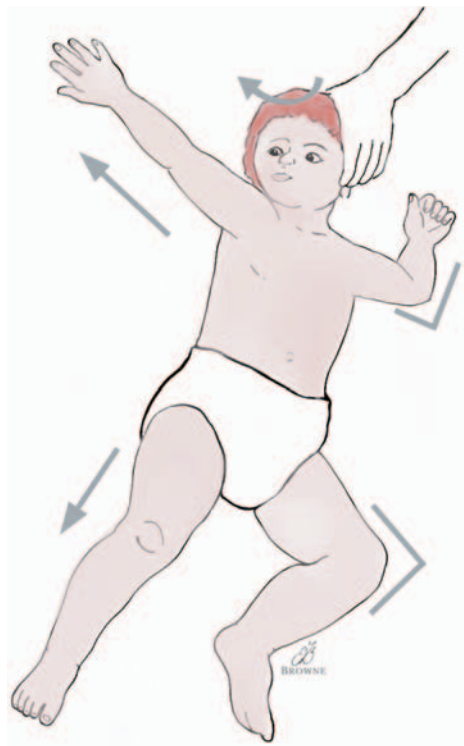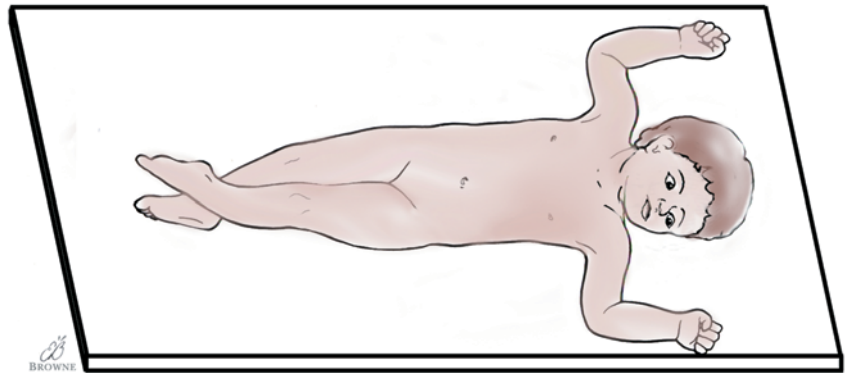
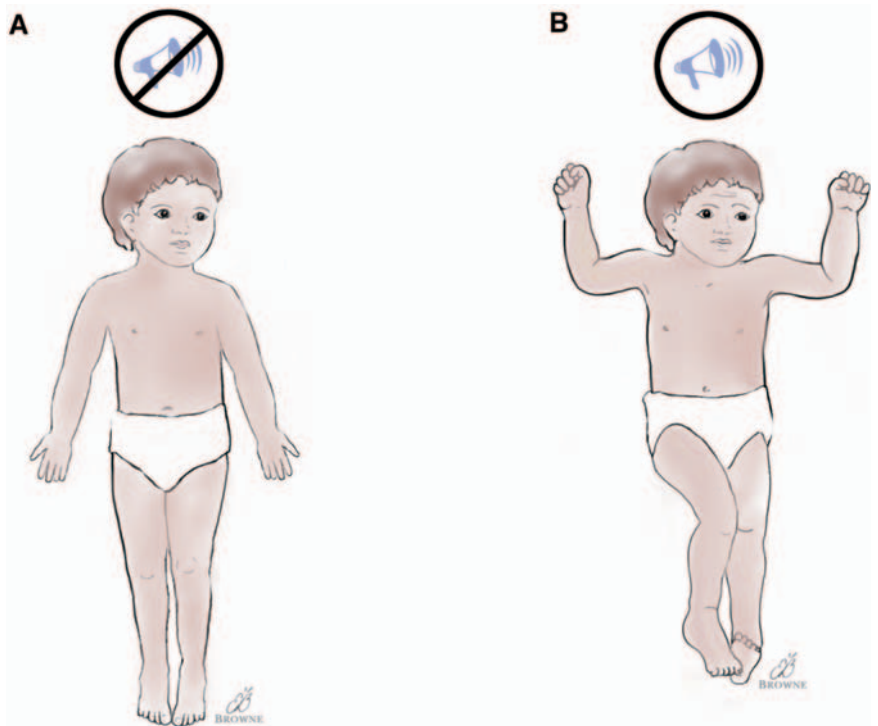


Figure 2.8. The asymmetric tonic neck reflex is activated by turning the child's head. The side to which the face turns causes the shoulder to abduct with elbow and hand extension. The leg on the same side also develops full extension. On the opposite side, the shoulder is also abducted but the elbow and hand are fully flexed and the leg is flexed at the hip, knee, and ankle. By turning the head to the opposite side, the pattern reverses.

Figure 2.9. The Moro reflex is initiated with a loud noise, such as a hand clap, that causes the child to have full extension of the head, neck, and back. The shoulders abduct and the elbows extend. The legs also have full extension. After a short time, the pattern reverses and the head, neck, and spine flex; the arms are brought to the midline; and the legs flex.



the legs to extend when the neck is flexed, and the opposite happens when the neck is extended. Both the ATNR and the STNR are suppressed by age 6 months.²⁶ The moro reflex is a sudden abduction and extension of the upper extremity with finger extension when a child is lifted, followed by shoulder adduction, elbow flexion, and closing of the hand as the child becomes comfortable again (Figure 2.9). Usually, this reflex is absent by 6 months of age. The parachute reflex occurs when a child is held upside down and lowered toward the floor. If the response is positive, which should occur by age 12 months,²⁶ the child should extend the arms in anticipation of landing on the hands (Figure 2.10). The step reflex, also known as foot placement response, occurs when the dorsum of the foot is stimulated; the child will flex the hip and knee and dorsiflex the foot in a stepping response. Usually, this reflex is suppressed by age 3 years (Figure 2.11). It is important to separate this reflex stepping, which some parents occasionally discover, from volun-

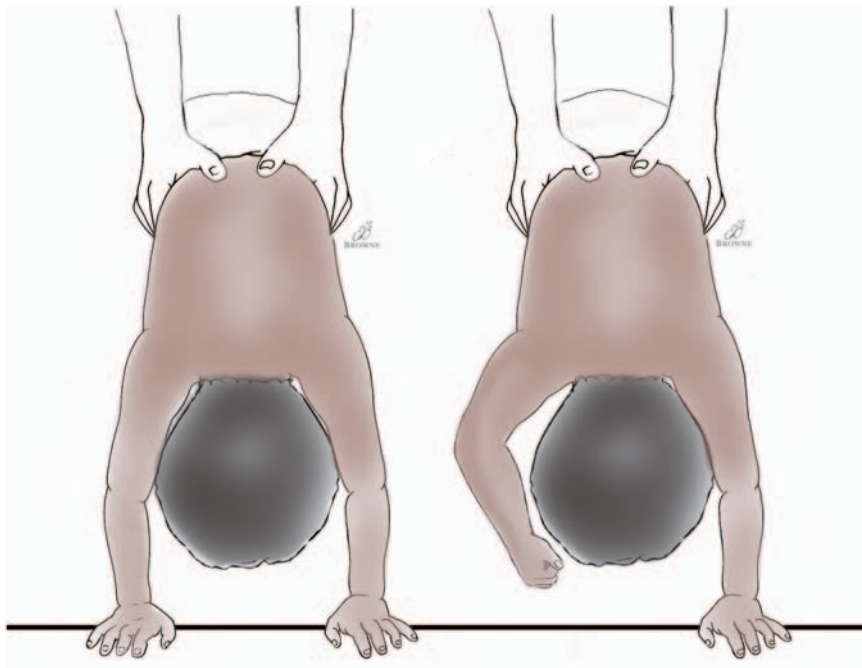


Figure 2.10. The parachute reaction is initiated by holding the child at the pelvis and tipping him head down. As the child is lowered toward the floor, he should extend the arms as if he were going to catch himself with his arms. This self-protection response should be present by 11 months of age. If the child has hemiplegia he will often only reach out with the extremity that is not affected. The affected extremity may remain flexed, or will extend at the shoulder and elbow but with the hand kept fistled.

tary step initiation. So long as a child's only stepping is the step reflex, the prognosis for achieving full gait is limited.

Although the presence of these reflexes after they should have disappeared is a negative neurologic sign, we have not found them helpful in making a specific prognosis as outlined by Bleck, who reported that the presence

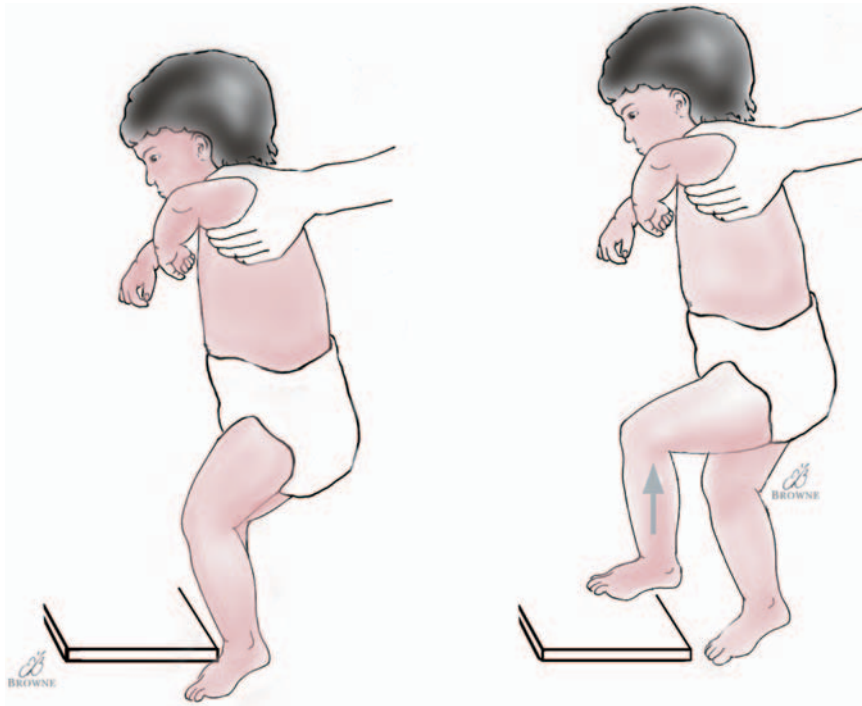


Figure 2.11. The foot placement reaction or step reflex is initiated with the child held under the arms or by the chest. When the dorsum of the foot is stimulated at the edge of a table, the child will flex the hip and knee, simulating a stepping action.

of two or more abnormal reflexes at age 7 years means a child has a poor prognosis to walk 15 meters independently. If one abnormal reflex is present, prognosis is considered guarded, and if no abnormal reflexes are present by age 7 years, the prognosis for walking is good.²⁶ Clearly, the absence of a parachute reflex at 18 months of age with persistent ATNR is not a good combination; however, it is not an absolute bad prognosis either. The presence of significant hyperextension reflex response, demonstrating opisthotonos, is a bad prognosis for functional gain because learning control to overcome this extensor posturing is very difficult. Instead of using these rather poorly defined abnormal reflexes at age 7 years, we have found that children who are walking at age 7 should continue to walk equally as well after completion of growth; therefore, if one desires to know how well a child will walk, look at the child walking, not his abnormal reflexes. Only a minimal improvement in ambulatory ability can be expected after age 7 years in children who have had appropriate therapy and orthopaedic corrections and have the musculoskeletal system reasonably well aligned. There are exceptions to the rule that gait function has plateaued by age 7 to 8 years, and these are usually seen in children with severe cognitive deficits. The most significant exception to this rule we have seen is a 12-year-old child with severe mental retardation who refused to weight bear before age 12, then started independent ambulation at age 12.5 years.

Deviation from Normal Development

As children mature from infancy to adolescence, there are many factors occurring in tandem, all of which come together in full-sized and normal motor functioning adults. To help develop a treatment plan for children with CP, it is important to have a concept of normal development. All innate normal motor function, such as sitting, walking, jumping, running, reaching, and speaking, is a complex combination of individual motor skills that allow development of these activities of daily living. Other activities, such as playing a piano, dancing, gymnastics, and driving a car, require much more learning and practice to remain proficient. These motor activities all include volitional motor control, motor planning, balance and coordination, muscle tone, and sensory feedback of the motion.

As babies mature from infancy to 1 year of age, neurologic maturity develops rapidly from proximal to distal. To demonstrate, children first gain head control, then develop the ability to weight bear on the arms, followed by trunk control and the ability to sit, then develop the ability to stand (Table 2.2). This progressive distal migration of maturation includes all the parameters of the motor skills. An early sign of abnormalities may be the use of only one arm for weight bearing, different tone in one arm, or a different amount of muscle tone between the arms and the legs. Children who move everything randomly, but are not doing volitional movements at the age-appropriate time, may be cognitively delayed. Children who show an early preference for one side or mainly use one side will probably develop hemiplegic pattern CP. Children who do not develop distal control for standing or sitting will probably develop quadriplegic pattern CP. These deviations in normal developmental milestones are usually the first signs of neurologic problems. Each individual child has their own rate of development; therefore, when contemplating the diagnosis of CP, it is important to consider the upper range of normal instead of the mean, which is quoted in most pediatric books (see Table 2.2).

Table 2.2. Normal developmental milestones.

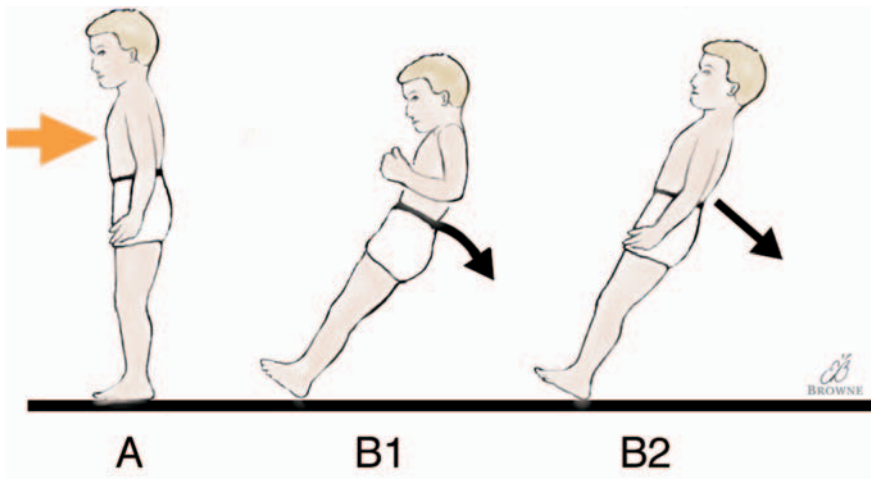
Gross motor skill	Mean age of development	Abnormal if not present by:
Lifts head when prone	1 month	3 months
Supports chest in prone position	3 months	4 months
Rolls prone to supine	4 months	6 months
Sits independently when placed	6 months	9 months
Pulls to stand, cruises	9 months	12 months
Walks independently	12 months	18 months
Walks up stair steps	18 months	24 months
Kicks a ball	24 months	30 months
Jumps with both feet off the floor	30 months	36 months
Hops on one foot with holding on	36 months	42 months

Source: Adapted in part from *Standards in Pediatric Orthopedics* by R.N. Hensinger.²⁷

Patterns of CP can be categorized further by using the elements of motor function required for normal motor task execution. This categorization has direct implications for treatment. All mature motor activities should be under volitional control with a few exceptions of basic responses, such as the fright response or withdrawal from noxious stimuli (e.g., burning a finger). Motor activities that are not completely under volitional control are termed “movement disorders” and can be separated into tremor, chorea, athetosis, dystonia, and ballismus. Tremor, a rhythmic movement of small magnitudes that usually involves smaller joints, is not a common feature in children with CP. Chorea involves jerky movements, most commonly including the digits, and has varying degrees of magnitude of the range of motion. Athetosis is large motions of the more proximal joints, often with an extensor pattern predominating. Fanning and extension of the digits is included as a part of the proximal movement. Each patient has a relatively consistent pattern of athetosis. Dystonia is a slow motion with a torsional element, which may be localized to one limb or involve the whole body. Over time, the motions vary greatly, and the pattern may completely reverse, such as going from full-extension external rotation in the upper extremity to full flexion and internal rotation. Dystonia can be confused with spasticity because, within a very short time period, if the changes are not seen, the dystonic limb looks very similar to a spastic contracted limb. Ballismus, the most rare movement disorder, involves random motion in large, fast patterns focused on the whole limb.

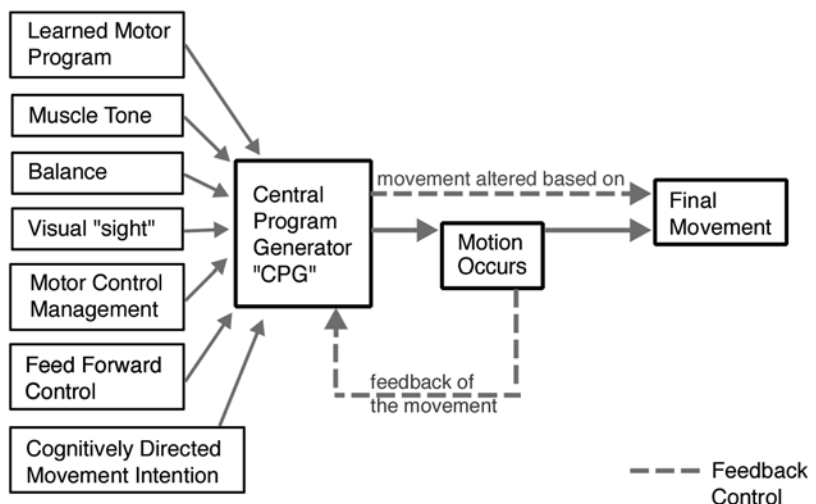
Motor control and planning of specific motor patterns requires a combination of learning to plan the motor task and then execute the functional motor task. This concept is best visualized in the context of a central motor program generator, which suggests that, like computer software, there is a program in the brain that allows walking. For the more basic motions such as walking, the central program generator is part of the innate neural structure, but for others, such as learning gymnastic exercises, it is a substantially learned pattern. Children who do not have function of this basic motor generator for gait cannot walk, and there is no way to teach or implant this innate ability. If there is some damage to the brain involving the central motor generator, gait patterns such as crouched gait more typically develop, which probably represents a more immature version of bipedal gait. These gait problems are discussed further in the chapter on treating problems of gait in children with CP (see Chapter 7).

Figure 2.12. A normal child will demonstrate equilibrium reactions such that they will respond by extending the arms in the direction of the expected fall to catch themselves or by flexing forward into a ball if they are falling backward (B1). By an automatic reflex, the child will move the head in the opposite direction of the fall to prevent striking the head as the primary area of contact. A child lacking these equilibrium responses will fall over like a falling tree with no protective response when given a small push (B2). This is a very poor prognostic sign for independent ambulation, although some children can learn to control this response with appropriate therapy.



Balance, which means the ability to maintain one's position in space in a stable orientation, is required for normal motor functioning. A lack of balance causes children to overcompensate for a movement and be unable to stand in one place. Ataxia is the term used to mean abnormal balance. Also, feedback to the motion and position in space is important for maintaining motor function. In children with CP, sensory feedback may be considered part of the balance spectrum as well, but the problems that are usually considered in this spectrum do not typically come under the umbrella of ataxia. For example, when a child stands and starts to lean, the lean should be perceived and corrected. Children with ataxia often overrespond by having excessive movement in the opposite direction. Additionally, there are children who do not recognize that they are falling until they hit the floor, and as a consequence, they tend to fall like a cut tree (Figure 2.12). This pattern of sensory deficiency makes it extremely dangerous for affected children to be upright and working on walking because of the risk of sustaining an injury from a fall.

Figure 2.13. The control of human gait is very complex and poorly understood. There is some combination of feed-forward control, in which the brain uses sensory feedback and prior learning to control movement, with a closed-loop feedback system in which the brain responds by altering the control signal based on the sensory feedback of how the anticipated movement is progressing. Many movements probably use a combination of feed-forward control and feedback control.



Another important aspect of normal function is muscle tone. Muscles can respond appropriately only when they generate tension; therefore, their ability to function properly requires that this tension be carefully controlled. Based on increasing understanding of controller theory developed in the field of robotics research, the inherent stiffness that adds resistance to motion is important in developing fine motor control. Motor control is a very complex area involving learning and sensory feedback with several different patterns (Figure 2.13). Normal muscle tone is probably a key element of motor functioning. Abnormalities in motor tone are the most common motor abnormalities that occur in children with CP. Increased motor tone is called spasticity. A more complete, classic definition of spasticity is a velocity-dependent increase in resistance to motion or clasp-knife stiffness, such that the tension releases with a constant torque. Usually, hyperreflexia is part of this syndrome. The opposite end of spasticity is hypotonia, which means decreased muscle tension when the joint is moved.

Making the Diagnosis

There are no agreed-upon diagnostic criteria to make the diagnosis of CP in individual children. When a child is not meeting developmental milestones, has persistent primitive reflexes, or has significant abnormalities in the elements of motor function, a diagnosis of CP can be made. The history should clearly demonstrate that this is a nonprogressive lesion and is nonfamilial. If abnormalities in developmental milestones are marginal, the term developmental delay is the appropriate diagnosis. This diagnosis implies that these children will likely catch up with their normal peers. The diagnosis of developmental delay is not appropriate for a teenager who has mental retardation and cannot walk. Developmental delay typically does not refer to major abnormalities involving elements of motor function.

Making the diagnosis of CP in a very young child may be risky unless the child has severe and definitive disabilities. There is a well-recognized phenomenon of children occasionally outgrowing CP. For this reason, we prefer to make the diagnosis in young children only when it is clear and without doubt, but wait until at least age 2 years for children who have more mild and questionable signs. Making the diagnosis is important from families' perspectives so they know what is wrong with their children; however, making the diagnosis usually does not affect treatment.

Often, how much workup should be done before the diagnosis is made is questionable, with no definitive answer. In a premature child who has been following an expected course, no workup is indicated. If a child has hemiplegia with no recognized cause, but has a typical course, it is very unlikely that a magnetic resonance imaging (MRI) scan will show anything that will impact the child's treatment. The imaging study is obtained to rule out other treatable causes such as tumors or hydrocephalus, and the imaging studies are of very little use in making a prognosis or definitive diagnosis (Case 2.1). An aggressive workup of a child may be indicated when parents are interested in knowing the risk of recurrence in another baby. These children need a full neurologic workup, sometimes including skin and muscle biopsy, to rule out genetic diseases. A referral to a knowledgeable geneticist is recommended because there is some increased risk of a second child also having neurologic problems, even if no definitive diagnosis can be made. This increased risk is probably related to an as yet undiagnosed chromosomal anomaly that causes the CP in many children.



Case 2.1 Medical Imaging

The difficulty in making predictions extends to medical imaging, such as MRI or CT scans, during childhood. In a population, statistically more severe structural changes mean more severe motor and cognitive neurologic disability, as demonstrated by this MRI of Shawn, a boy with severe mental retardation and spastic quadriplegic CP (Figure C2.1.1). Other individuals may have equal cognitive and motor severity with a near normal MRI (Figure C2.1.2). There are also many individuals with severe structural changes on the MRI who are similar to Lauren, who is cognitively normal and has a triplegic pattern CP but ambulates using a walker (Figure C2.1.3). These cases demonstrate how important it is for physicians caring for children not to develop prejudices concerning an individual child's function based on imaging studies.

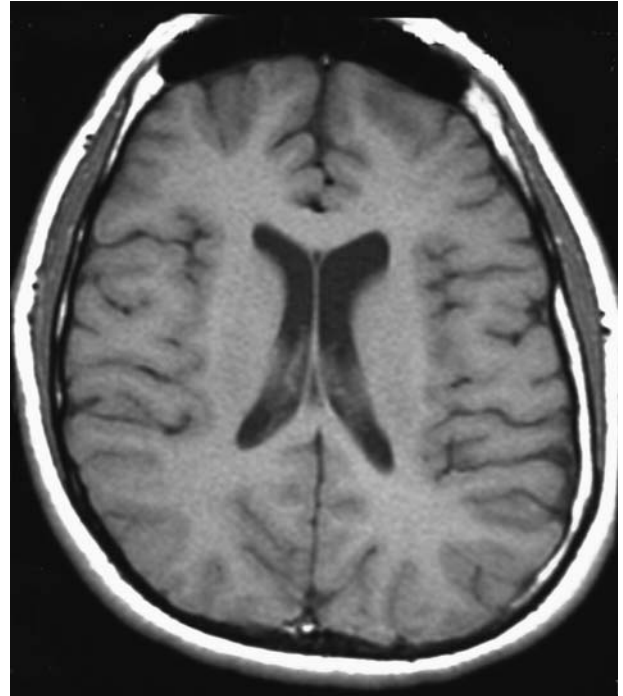


Figure C2.1.2

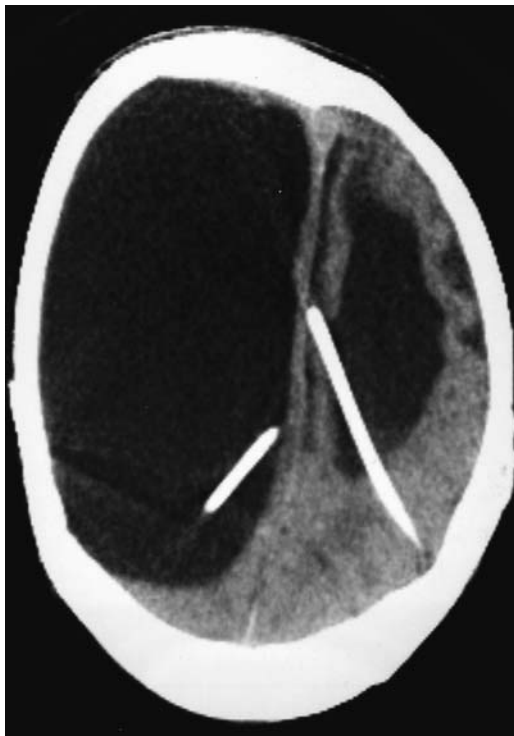


Figure C2.1.1

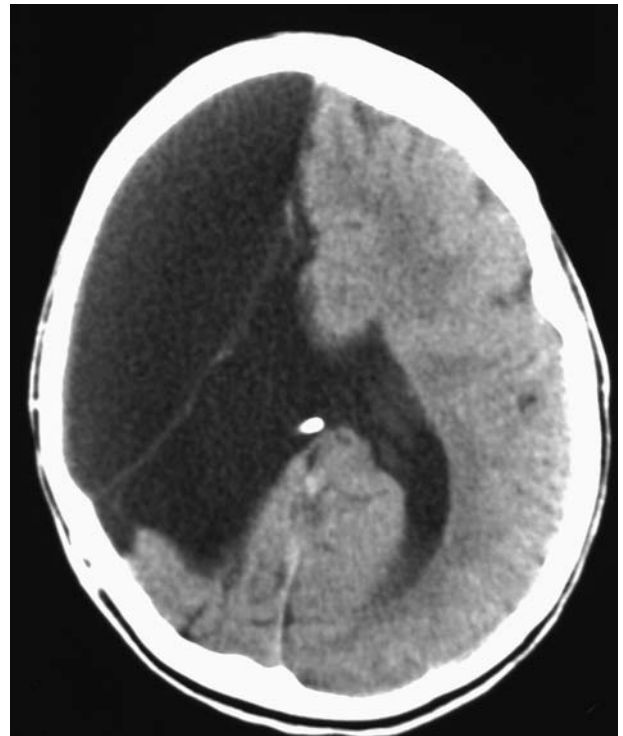

Figure C2.1.3

References

1. Miller G, Clark GD. *The Cerebral Palsies: Causes, Consequences, and Management*. Boston: Butterworth-Heinemann, 1998.
2. Use of folic acid for prevention of spina bifida and other neural tube defects—1983–1991. *MMWR Morb Mortal Wkly Rep* 1991;40:513–6.
3. Prevention of neural tube defects: results of the Medical Research Council Vitamin Study. MRC Vitamin Study Research Group [see comments]. *Lancet* 1991;338:131–7.
4. Salonen R, Paavola P. Meckel syndrome. *J Med Genet* 1998;35:497–501.
5. Lindenberg R, Freytag E. Morphology of brain lesions from blunt trauma in early infancy. *Arch Pathol* 1969;87:298–305.
6. Hubel DH, Wiesel TN. The period of susceptibility to the physiological effects of unilateral eye closure in kittens. *J Physiol (Lond)* 1970;206:419–36.
7. Jurcisin G. Dynamics of the Doman-Delacato creeping-crawling technique for the brain-damaged child. *Am Correct Ther J* 1968;22:161–4.
8. Kershner JR. Doman-Delacato's theory of neurological organization applied with retarded children. *Except Child* 1968;34:441–50.
9. de Vries LS, Eken P, Groenendaal F, van Haastert IC, Meiners LC. Correlation between the degree of periventricular leukomalacia diagnosed using cranial ultrasound and MRI later in infancy in children with cerebral palsy. *Neuropediatrics* 1993;24:263–8.
10. de Vries LS, Regev R, Dubowitz LM, Whitelaw A, Aber VR. Perinatal risk factors for the development of extensive cystic leukomalacia. *Am J Dis Child* 1988;142:732–5.
11. Murphy CC, Yeargin-Allsopp M, Decoufle P, Drews CD. Prevalence of cerebral palsy among ten-year-old children in metropolitan Atlanta, 1985 through 1987. *J Pediatr* 1993;123:S13–20.
12. O'Reilly DE, Walentynowicz JE. Etiological factors in cerebral palsy: an historical review. *Dev Med Child Neurol* 1981;23:633–42.
13. Jaffe KM, Polissar NL, Fay GC, Liao S. Recovery trends over three years following pediatric traumatic brain injury. *Arch Phys Med Rehabil* 1995;76:17–26.
14. Mahoney WJ, D'Souza BJ, Haller JA, Rogers MC, Epstein MH, Freeman JM. Long-term outcome of children with severe head trauma and prolonged coma. *Pediatrics* 1983;71:756–62.
15. Lee MS, Rinne JO, Ceballos-Baumann A, Thompson PD, Marsden CD. Dystonia after head trauma. *Neurology* 1994;44:1374–8.
16. Aicardi J. *Diseases of the Nervous System in Childhood*. Oxford, England: Cambridge University Press, 1992.
17. Baric I, Zschocke J, Christensen E, et al. Diagnosis and management of glutaric aciduria type I. *J Inher Metab Dis* 1998;21:326–40.
18. Hagberg B, Hagberg G, Olow I, van Wendt L. The changing panorama of cerebral palsy in Sweden. VII. Prevalence and origin in the birth year period 1987–90. *Acta Paediatr* 1996;85:954–60.
19. Hagberg B, Hagberg G, Olow I. The changing panorama of cerebral palsy in Sweden. VI. Prevalence and origin during the birth year period 1983–1986. *Acta Paediatr* 1993;82:387–93.
20. Liu JM, Li S, Lin Q, Li Z. Prevalence of cerebral palsy in China. *Int J Epidemiol* 1999;28:949–54.
21. Colver AF, Gibson M, Hey EN, Jarvis SN, Mackie PC, Richmond S. Increasing rates of cerebral palsy across the severity spectrum in north-east England 1964–1993. The North of England Collaborative Cerebral Palsy Survey. *Arch Dis Child Fetal Neonatal Ed* 2000;83:F7–12.
22. Keith LG, Oleszczuk JJ, Keith DM. Multiple gestation: reflections on epidemiology, causes, and consequences. *Int J Fertil Womens Med* 2000;45:206–14.
23. Yokoyama Y, Shimizu T, Hayakawa K. Prevalence of cerebral palsy in twins, triplets and quadruplets. *Int J Epidemiol* 1995;24:943–8.
24. World Health Organization. *Classification of Impairments, Disabilities, and Handicaps*. Geneva, Switzerland: WHO, 1980.

25. National Institutes of Health. Research Plan for the National Center for Medical Rehabilitation Research. NIH Publication Vol. 93-3509. Bethesda, MD: NIH, 1993.
26. Bleck E. Orthopedic Management in Cerebral Palsy. Oxford: Mac Keith Press, 1987:497.
27. Hensinger RN. Standards in Pediatric Orthopedics. New York: Raven Press, 1986.

Patient Management

In spite of the large variety and severity of medical problems in children with cerebral palsy (CP), many families start to think of the neuro-orthopaedist, who is an orthopaedic physician who has developed special expertise in neurologic disorders, as their child's primary doctor. The pediatric orthopaedic physician who sees a large number of these children develops a broad understanding of the medical problems. However, families must be encouraged to maintain regular follow-up with a primary care physician because very few orthopaedists have the training to provide the full general medical care needs of these children. Standard immunizations and well child examinations especially may be overlooked. However, most families see their child's most apparent problem as the visible motor disability and focus more medical attention on this disability at the risk of overlooking routine well child care. The physician managing the motor disability should remind parents of the importance of well child care by inquiring if the child has had a routine physical examination and up-to-date immunizations. Although children need to have good primary care, the orthopaedic physician should also develop some understanding of the common medical issues related to CP because it often is not clear how the musculoskeletal problems and problems in other systems are interacting.

Outpatient Management

Most physician contact with children and families occurs in the outpatient clinic; therefore, this environment should be comfortable and meet the needs of the musculoskeletal evaluation. This facility requires enough space so children's mobility can be evaluated. Children who can walk or run must be observed doing this activity in an area that is large enough. In general, the office space should include examination rooms where children and families can be evaluated in private. These rooms need to be large enough to accommodate a large wheelchair in addition to several seats for parents and an examination table. A room 4 m by 4 m works well, and any room smaller than 3 m by 4 m is very difficult. There should be a large hallway or open area like a therapy gym with a 10-m-long by 3-m-wide area where a child's gait can be observed.

A primary aspect of the outpatient management is to obtain a good history of how a child's function is changing over a 6- to 12-month time frame. Asking questions such as "What can the child do now that she could not do at her last birthday, or Christmas, or last summer?" helps parents focus their thoughts. Also, getting good histories concerning pain patterns, and listening

carefully to what parents feel is happening, can give useful clues to problems. When parents perceive a problem, they need to feel that the physicians heard their concerns, which is a major element of the history. There is tendency in a busy clinic to focus on what seem to be the clear problems and not listen to what parents are concerned about.

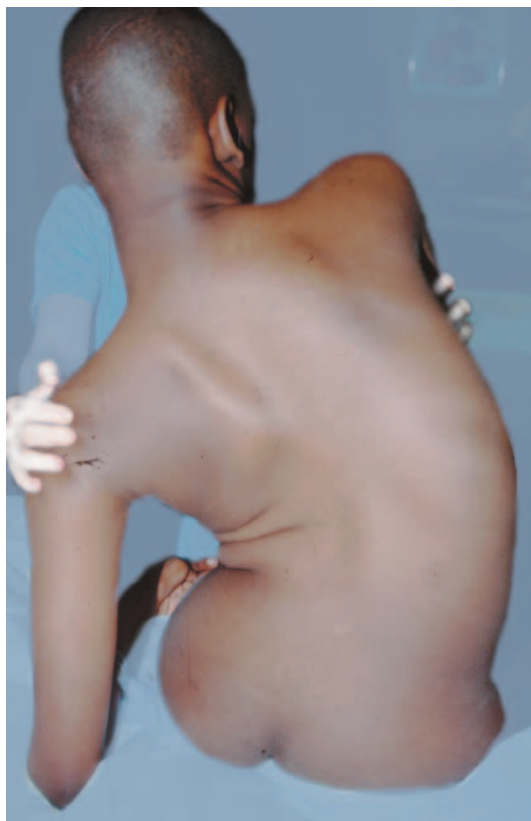Physical Examination

The other major aspect of the outpatient evaluation is the physical examination, which needs to focus on the important elements relevant to the child's function. That means, if the child is using a wheelchair, careful evaluation of the fit of the wheel and the support it is providing is an integral part of the physical examination. Careful evaluation of orthotics for fit and function is important. The child's functional ability is assessed by seeing how she can stand, how much support she needs to sit, and how she crawls. If the child is ambulatory, a careful assessment of the gait is a mandatory part of the physical examination. It is as inappropriate for an orthopaedist to do an outpatient evaluation of an ambulatory child with CP without a careful gait assessment as it is for an ophthalmologist to do an evaluation of vision without ever looking in the eyes. Assessing muscle tone and motor control often is best accomplished by holding and handling the child if this is age appropriate.

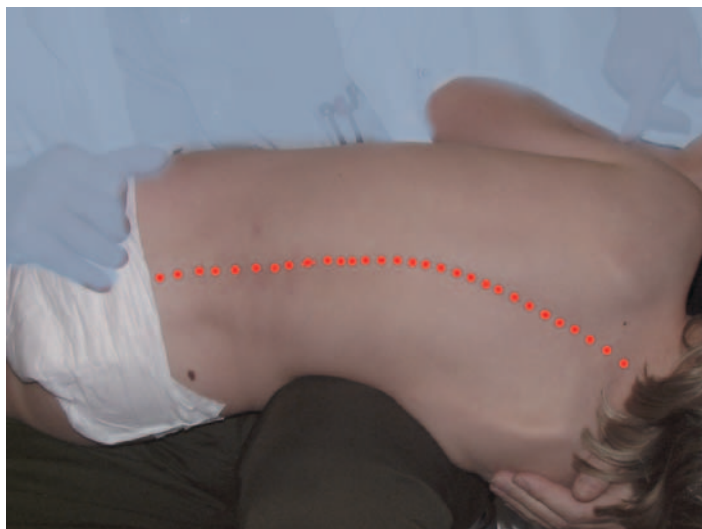
Specific regional evaluation should start with a spinal assessment focusing both on flexibility and deformity. The spine examination should be performed with the child sitting, with side bending for the flexibility evaluation (Figure 3.1). The child should be relaxed and cooperative for the flexibility

Figure 3.1. Examination of the spine should be done with the child undressed and observing the back in a sitting position. (A) Flexibility of the spine is best evaluated by side bending the child over the knee if the size of the child allows. (B) If this side-bending maneuver does allow the spinous processes to correct at least to a straight line, then the residual curve has substantial stiffness.

A



B



evaluation. In young children, careful monitoring of the supine extended hip and hip abduction is important (Figure 3.2). This is the most important screening evaluation of the hip in the prevention of hip dysplasia. The other important hip assessment is measuring hip rotation, which should be done with the child prone and the hip extended (Figure 3.3). This position is the most functional position in ambulators and provides for consistency of the evaluation. Assessment of hip flexion should have the contralateral hip in relative extension to avoid having apparent hip flexion through the lumbar spine (Figure 3.4). Hip extension is measured in the prone position with the contralateral hip flexed over the end of the table, or in the supine position with the contralateral hip flexed to prevent pelvic motion (Figure 3.5). At the knee, the primary measure is the popliteal angle (Figure 3.6). The amount of fixed knee flexion contracture also needs to be measured and recorded. Ankle dorsiflexion with knee extension and with knee flexion are key measures in determining the source of equinus (Figure 3.7). The rotational alignment of the lower leg is best assessed in the prone position where the transmalleolar axis and the thigh–foot axis are measured (Figure 3.8). In the upper extremity, specific routine angle measurements have less direct impact on treatment decisions; therefore, the focus is on the functional problems encountered. Except for the basic measures of the hip, knee, and ankle, a large aspect of the physical examination of a child is directed at the specific functional impairments caused by the individual's pattern of neurologic involvement.

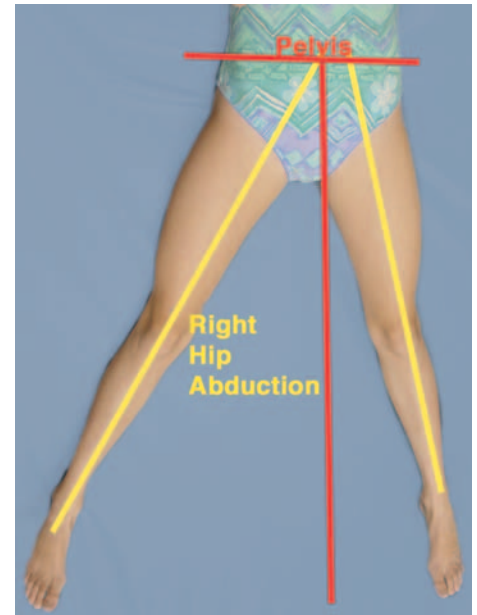


Figure 3.2. The child should be relaxed in the supine position with the hips and knees extended. The hip abduction is performed without much force, and the amount of each side is measured by palpating the iliac crest to make sure that the pelvis is not rotating. Care is taken to measure each side hip abduction independent of the other side because tilting of the pelvis can mask significant symmetry. Children less than 8 years old need an anteroposterior supine radiograph of the pelvis every 6 to 12 months if the hip abduction is less than 45° on either side.

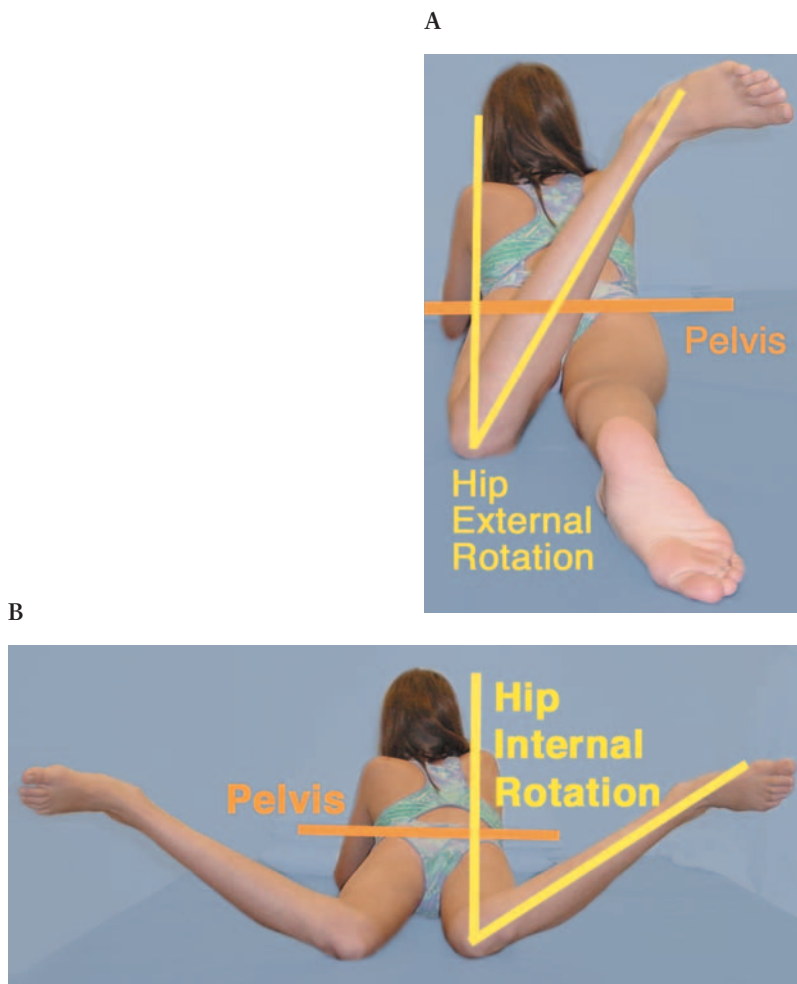


Figure 3.3. Hip rotation should be assessed with the child prone with the hip extended. This is especially important because the major problem of hip malrotation during gait occurs with the hip near full extension. External rotation is measured with the knee flexed 90° and making sure the pelvis remains level with the table surface (A). Internal rotation is assessed in the same way, but rotating in the opposite direction (B).

Figure 3.4. Hip flexion is measured with the contralateral hip in extension and lordosis reduced to normal range. Total flexion is than measured without forceful further push toward flexion.

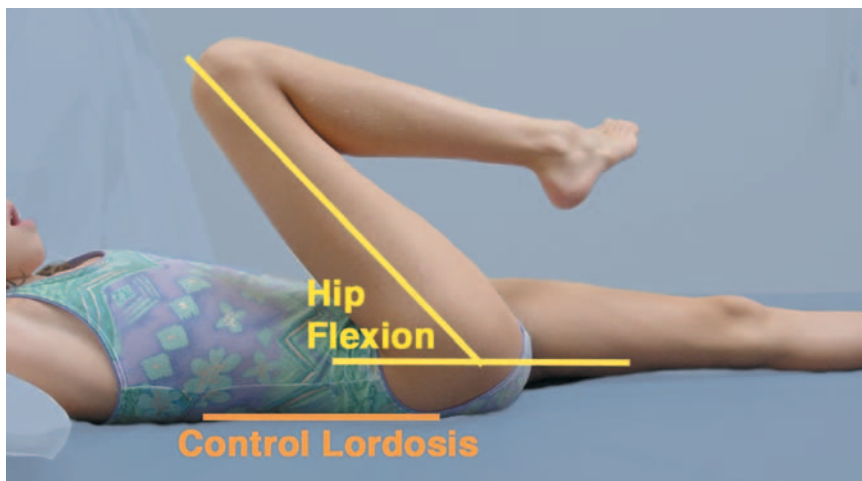
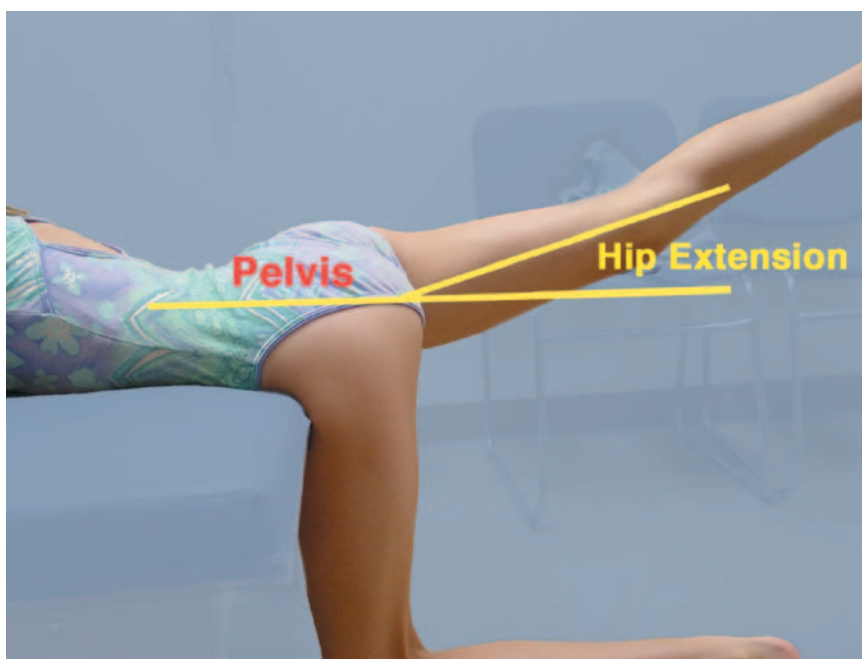


Figure 3.5. Hip extension can be measured several ways, but the technique of dropping the contralateral leg off the end of the table works well for many children. This helps to control the lumbar lordosis, which is very difficult to separate from a hip flexion contracture or lack of hip extension.



Managing the Child with Quadriplegic Pattern Cerebral Palsy

Making the diagnosis in the child with quadriplegic pattern CP is not usually difficult because of the severity of the neurologic involvement; however, this is the group in which one most often continues to try to find an etiology for the problem. There are physicians, especially neurologists, who do not want to give the diagnosis of CP. However, it is very helpful for the parents to be given a diagnosis, allowing them to relate to other families with similar problems. Children with quadriplegic pattern involvement are most likely to have many associated medical problems. Coordinated medical care is especially important for these children.

The orthopaedic problems in early and middle childhood revolve around getting children weight bearing and preventing hip dislocation. These children should start being followed by an orthopaedist at around 18 to 24 months

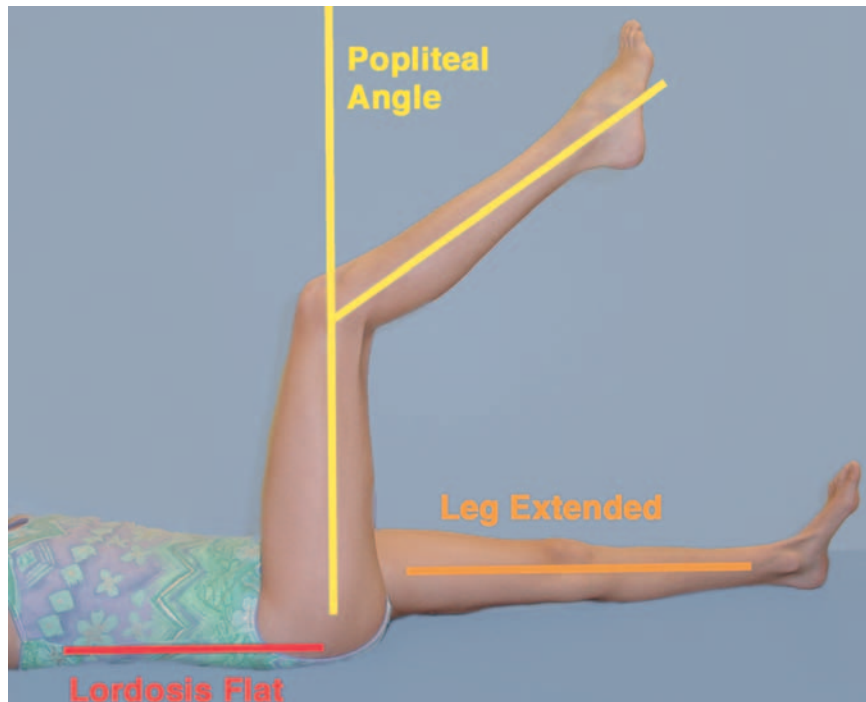


Figure 3.6. The popliteal angle is measured at the knee with the contralateral hip and knee in full extension. The hip on the side to be measured is then flexed to 90° and the knee slowly extended until the pelvis starts to move. This is the point when the angle should be measured. The measurement of the popliteal angle is not the angle at the point of maximum knee extension because this only measures how much the knee can extend with maximum pelvic rotation.

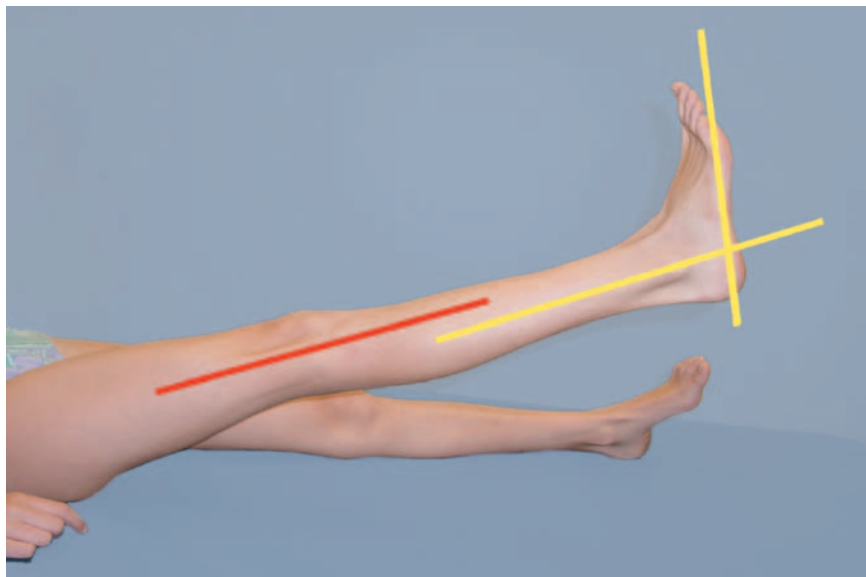


Figure 3.7. Ankle dorsiflexion needs to be measured both with the knee in full extension as shown in this image, and the dorsiflexion should be measured with the knee flexed at least 45° to relax the gastrocnemius muscle. The measurement with the knee extended measures the length of the gastrocnemius muscle, and ankle dorsiflexion with the knee flexed measures the soleus length. In normal individuals, there is little difference; however, in some children with CP there is a large difference.

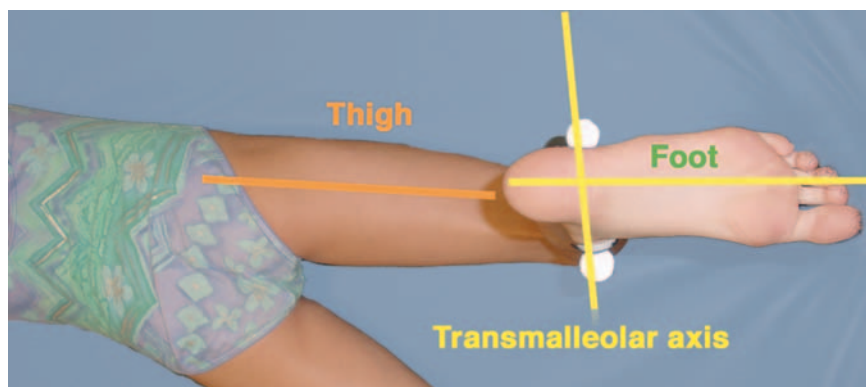


Figure 3.8. The leg rotational profile is assessed with the child in the prone position and the knee flexed 90°. The thigh-foot alignment gives a measurement of the overall alignment of the leg and foot. Normal should be 0° to 15° external. A more specific measurement of tibial torsion is measuring the transmalleolar to thigh angle.

of age because this is when the risk of spastic hip disease begins. This age is also when a standing program should be started. Most children should be followed every 6 months for a musculoskeletal evaluation. By the time these children have scoliosis corrected at puberty, much less change occurs over time and the follow-up can be lengthened, often to 1 year or more. Usually, solid ankle-foot orthoses (AFOs) are fitted at approximately 24 months of age so weight bearing in a stander, with a goal of standing for at least 1 hour per day, can begin. Children with adequate motor control of their head should be started in a prone stander, and those who do not have good head control should be placed in a supine stander. As these children enter late childhood to prepuberty, scoliosis becomes the main concern.

As these children go through puberty, their increased height and weight often make their care much more difficult for caretakers, causing anxiety about how they will be cared for as they become full adult size. This issue should be addressed by a social worker familiar with state laws and available resources. Because of multiple medical problems and total custodial care requirements, the parents or caretakers often have significant periods of stress or just fatigue. Parents should be educated on the available options, especially what options they have if they get to the point where they acutely cannot cope with their growing child. If available, this resource should ideally be through a prearranged respite care provider, but few of these are available. The only option may be the hospital; however, it often helps the parents just to know what their options are.


The problems the caretakers focus on may not be the problems the physician focuses on, and often they are diametrically opposed. Nutrition and feeding are areas physicians are often concerned with, especially when a child is very small and malnourished; however, from the parents' perspective, oral feeding of the child may be the most positive interactive experience the child and parent have. Also, the parents may be happy for the child to stay small, so that they are easier to lift and transfer. For these reasons, parents may resist interventions, such as gastrostomy tubes, to make the child grow heavier and make feeding easier, all of which would be very positive from the physician's perspective.

Feeding, Growth, and Weight Problems

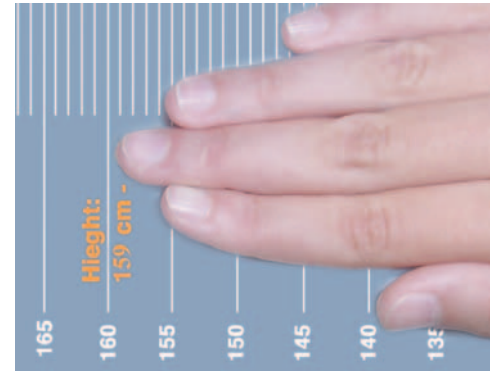
A major problem for many children with CP is poor nutrition. Many primary care physicians in the community do not have the physical equipment in their offices to weigh and measure children who cannot walk, and many do not have a good knowledge base or an available nutritionist to help them assess current food intake or dietary needs. Part of the evaluation in a CP clinic should be to measure the height and weight of these children. Weight is easy to get with an appropriate scale, which should always be available in this type of clinic environment. Height measurement is more difficult and less reliable for individuals who cannot stand. If scoliosis is present, standing height is also not reliable. In these children, armspan measurement, which needs no conversion if children are able to fully abduct the shoulders and extend the elbows, wrists, and fingers, should be used. However, for many children with CP, this abduction and extension is not possible and there are several other measures for doing segmental heights.^{1, 2} We prefer to use the forearm ruler (Figure 3.9), which has a conversion factor built in and allows plotting height on a regular growth chart.³

Because children should be seen every 6 to 12 months to monitor their motor impairments, height and weight can be monitored easily and the primary care physician apprised of the data. Many children with more severe

A



B



patterns of involvement will not be growing at a normal rate and may have quite abnormal caloric needs.⁴ Most children should gain some weight from 1 year to the next during childhood. If not, a nutritional assessment should be considered by evaluating the nutritional intake through a formal calorie count and, in some cases, measuring the caloric requirement.

Another general medical issue that should be brought to the attention of the parents is the need for routine dental care. Children over age 2 years, especially children with CP, should have routine dental care for teeth cleaning and monitoring teeth and gum health. Gingival hyperplasia is widely blamed on antiepileptic medications, especially Dilantin[®]; however, this problem is widespread in children with oral motor problems because of poor clearance of saliva. This gingivitis needs good dental care and treatment to prevent dental caries, which are also more common in children with abnormal motor function.⁶

Osteoporosis and Osteopenia

Poor bone structure development is related to poor overall growth and development and is a problem primarily in nonambulatory children with quadriplegic pattern involvement. The bones tend to be thin with an overall decreased bone mass, called osteoporosis, and a decreased bone mineral density, described as osteomalacia. The cause of poor bone formation is multifactorial and occurs primarily in nonambulatory children because bones do not develop normal strength and size unless a normal amount of stress is applied to them. The diameter of the tubular bones, such as the femur, and the bone's cortical width largely grow to their determined size based on the stress the bone experiences during growth. The exact required amount and nature of this stress is unknown, but it probably requires a combination of maximal compressive and torsional stress as well as a stress-time history. Bones need to have a stress of approximately one to two times body weight applied at least a certain number of times every day. Also, bones need to experience at least body weight for a certain number of hours, such as 3 hours, in every 24-hour period.^{7, 8} The best documentation on how important bearing weight is for the proper development of bones comes from the effect of weightlessness in space.⁹

There is some evidence that increased physical activity in children with CP can increase the bone mineral density in the femoral neck in a period as short as 8 months.¹⁰ Weight bearing for children with CP who are nonambulatory also makes good sense¹¹; however, there is no hard evidence that

Figure 3.9. The forearm ruler is calibrated in such a way that the elbow is flexed 90° and the hands and fingers are extended (A). The height can then be read at the tip of the long finger (B). This ruler is easy to use, requires no conversion math, and allows the height to be plotted on a standard growth chart. This is not an absolute measure of height, and for best practice should not be intermixed with other measures of height.



Case 3.1 Amanda

Amanda, an 11-year-old girl with spastic diplegia, was evaluated for surgery to correct severe tibial torsion. She had never had a fracture but was being treated with phenobarbital for seizures. Preoperative radiographs of the tibia (Figures C3.1.1, C3.1.2) showed clear evidence of rickets. Biochemical assessment showed phosphorus, 3.5 (normal, 3.6–5.6); serum calcium, 8.5 (normal, 8.5–10.5); parathyroid hormone level, 217 (normal for vitamin D and calcium level); vitamin D-25 hydroxy, 6 (normal, 17–54); vitamin D-1,25 hydroxy, 64 (normal, 25–65);

alkaline phosphatase, 391 (normal, 73–322). By history, Amanda was noted to live in a family where she ate very little meat, dairy products, or green vegetables. A diagnosis of nutritional vitamin D-deficient rickets was made. Amanda had the surgery at the same time she was treated for the rickets with calciferol 0.5 ml daily and Tums (600 mg calcium) daily. After 4 weeks of treatment, the vitamin D-1,25 was 59 (normal, 17–54) and the vitamin D-25 was 19 (normal, 25–65). The osteotomies healed and the ricketic changes rapidly resolved.

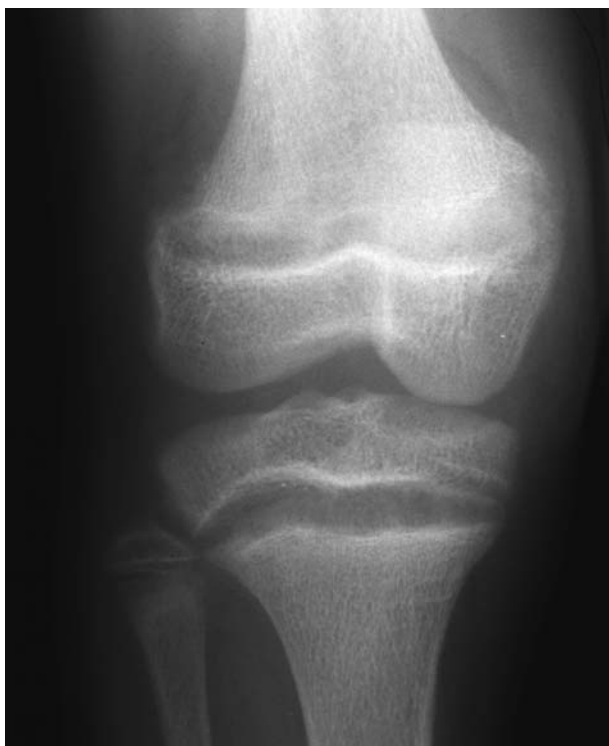

Figure C3.1.1

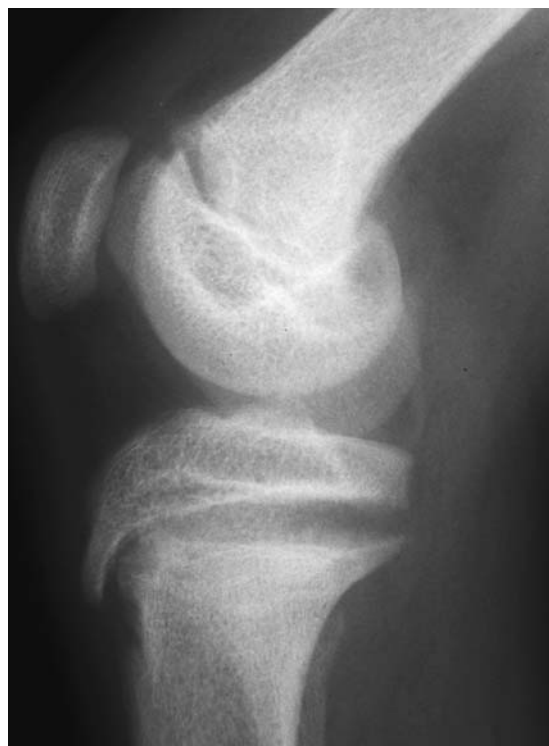

Figure C3.1.2

it makes a difference. In addition to not being weight bearing, many of these children have a limited diet and have reduced sunlight exposure. Therefore, they are also at risk for developing vitamin D deficiency^{12–15} and calcium deficiency (Case 3.1).^{16, 17} Other factors that lead to decreased bone mass are the use of antiepileptic medications¹⁸ and abnormal growth hormone regulation.¹⁹ The effect of osteopenia, osteoporosis, and osteomalacia is a high rate of low-energy fractures.

Low-Energy Fractures

Fractures in nonambulatory children with CP are very common, usually presenting with a history of very low trauma and often with no clear evidence of trauma. Because of the diffuse and unclear history in an individual who cannot do anything for herself, the question of intentional abuse is raised.²⁰ Nonaccidental trauma does occur in children with CP; however, in our experience, it has been rare and usually not related to an isolated trauma event. When a caretaker harms a child with CP, it is more often recognized as a combination of neglected feeding with weight loss or poor general hygiene, related to significant caretaker frustration. The problem with isolated single fractures is that it is very difficult to determine accidental trauma from non-accidental trauma because almost all these fractures are very low energy.

Common histories include a time line in which there was an event where the child really cried approximately 24 hours before she was seen, such as during dressing, but the caretaker was able to calm her after a short time. Following this, she seemed fine until the next diaper change or position change, when she again cried for a short time. Because this crying goes on episodically for 24 to 72 hours, parents or caretakers seek medical attention. Often, the child will be taken to an emergency room or family doctor, where parents are asked about a history and relate that the child cried with each diaper change or other change in the lower extremity position. The mother may think the child's hip is hurting. A radiograph is obtained, but no fracture is seen so the child is taken home. The pain continues until the caretakers again return for another physician examination. Eventually, someone, often a caretaker, examines the child carefully and finds a swollen knee that is warm. A radiograph is now done of the knee and the fracture is identified. If this process goes on for a week or more, the child may start getting sick, and an examination may demonstrate pneumonia, which occurs in some children if fractures are untreated.

Sometimes, the attention is directed at the pneumonia and the fractures that were the initial etiology can get completely overlooked (Case 3.2). Also, children with gastrointestinal problems often have a flare-up in their gastrointestinal symptoms, probably due to the trauma and increased spasticity (Case 3.3). We have seen cases where all the attention was on the gastrointestinal problems and the fracture was overlooked for quite some time. Because untreated and ignored fractures cause severe swelling and erythema, the fracture may also be misinterpreted as an infection (Case 3.4).

Diagnosing Low-Energy Fractures in the Noncommunicative Child

An important aspect in diagnosing low-energy fractures in noncommunicative children is getting a good history and then doing a full examination, with the child completely undressed so the joints and skin of all four extremities can be seen, palpated, and checked for temperature changes. Light percussion of each long bone using a reflex hammer helps to find bone tenderness. All areas of suspicious tenderness, swelling, and increased temperature should have a radiograph taken. In making the diagnosis, knowing what is said in the history helps to focus the attention, and in spite of the history often having a nonspecific character, it is still remarkably consistent. The locations of these fractures are also remarkably predictable.

From the perspective of frequency, most of these fractures occur in the metaphyseal regions of long bones.¹¹ In our experience, 50% occur at the distal femoral metaphysis, and 30% at the proximal tibial metaphysis, with



Case 3.2 Matt

Matt, a 4-year-old boy, was initially brought to the emergency room by his mother with a complaint that he had been uncomfortable and had increasingly severe episodes of hypoxia over the past several days. An evaluation in the emergency room showed pneumonia, and Matt was admitted to the hospital where the pneumonia got progressively worse over the next week. However, under aggressive medical management, the respiratory problems slowly resolved and Matt's respiratory function and general responsiveness slowly improved. In the third week of the hospitalization, as Matt was progressing toward a more normal level of responsive level, his mother noticed that his thigh seemed swollen and she felt he was having pain when she moved him (Figure C3.2.1). His mother's complaints were ignored until Matt was felt to be ready for discharge 3.5 weeks after admission. His mother then

refused to take him home until he was evaluated by her orthopaedist. In the orthopaedic evaluation, Matt was found to be lying with abducted hips with thighs that appeared swollen and with mild tenderness. Radiographs that demonstrated bilateral femur fractures of approximately 4 weeks old were obtained (Figure C3.2.2). Although this case is an extreme example of missing a significant fracture, which almost definitely was the event that caused the pneumonia, missing these fractures in emergency rooms and medical office examinations is common. Teaching parents how to recognize fractures seems to work better than expecting general medical doctors to learn this technique.

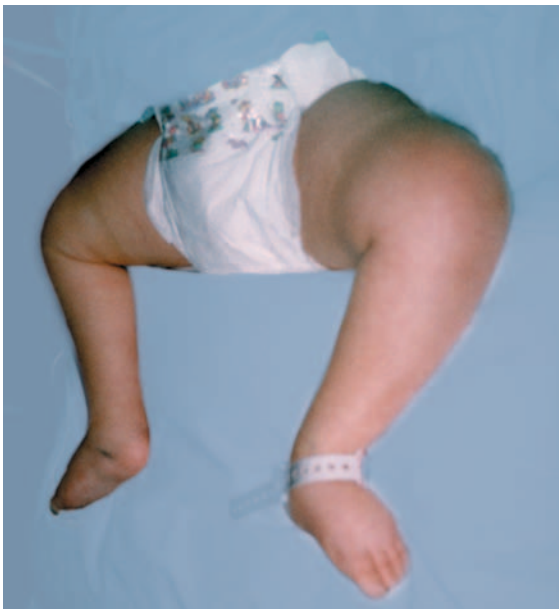

Figure C3.2.1

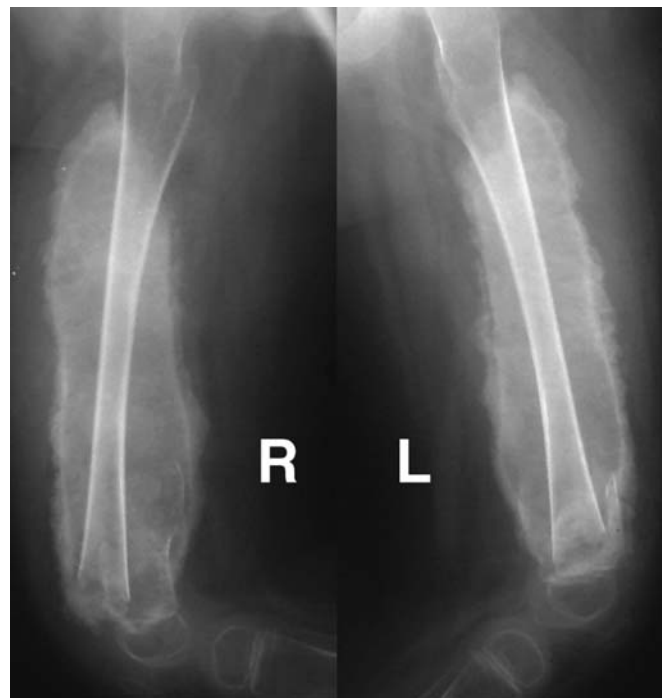


Figure C3.2.2

the proximal humeral metaphysis being the next most common site. Fractures also occur at the distal tibial metaphysis, femoral shaft, and tibial shaft. Of the small bone fractures, the talus and calcaneus are most common. For specific fractures, the typical history for the distal femur and proximal tibial metaphyseal fractures is that some activity that usually involves leg motion, such as dressing, position change in the wheelchair, or physical therapy stretch-



Case 3.3 William

William, a 12-year-old with a severe quadriplegic pattern involvement, had a long history of increasing gastrointestinal mobility problems and multiple fractures. A relatively simple femur fracture was recognized by the parents (Figure C3.3.1), and William was treated with a soft cast. However, over 8 hours, he would not tolerate any feeding, and he was brought back to the hospital and admitted for monitoring. Over the next 4 days, a complete ileus was present and he became septic and died. This history demonstrates the importance of being aware of other problems the child may have, and informing parents and other medical team members of the potential these relatively minor fractures can have on other systems.

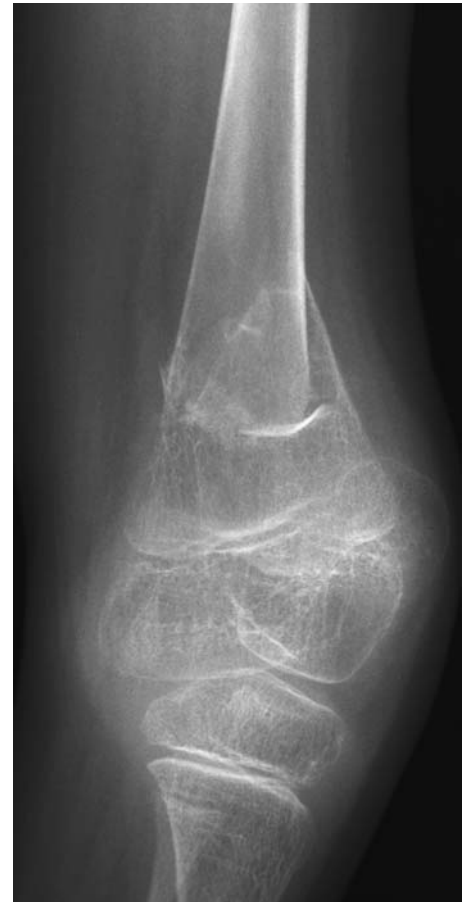

Figure C3.3.1

ing, occurred at a time when some discomfort was expressed by the child. Fractures of the proximal humerus usually occur at either dressing or bathing events or during physical therapy stretching (Case 3.5). Femoral shaft fractures are most commonly spiral fractures. A common presentation is an individual who had sudden pain when she was turned in bed. One leg was probably caught up in the sheets or under the other leg. Fractures of the feet are usually related to stretching exercises or trying to apply an orthotic to a foot when a child is very upset and spastic.

We have seen several special situations on many occasions in which fractures occurred. One situation was a history of sudden back pain while riding a school bus. The child was strapped in the wheelchair in the back of the bus, and when the bus bounced after hitting a pothole, the child had sudden pain. This bouncing produced compression fractures of the spine (Case 3.6). Another situation is children, either when using electric wheelchairs or being



Case 3.4 Mike

Mike, a 14-year-old boy, presented to a general hospital emergency room with a complaint by his mother that he had had increased lethargy and general discomfort in the past several weeks. She had kept him home from school because she thought he had the flu. An examination in the emergency room found that he had an oral temperature of 39.5°C and demonstrated a swollen and warm left thigh. The white blood cell count was elevated at 14,000, but there was no leukocytosis. A radiograph demonstrated a periosteal reaction, and a bone scan was obtained that demonstrated greatly increased uptake in the left thigh. Blood cultures were obtained and the thigh was aspirated and specimens were sent for culture. Mike was started on broad-spectrum antibiotics, and after 5 days there was no change in the temperature, erythema, or the local condition of the leg. All cultures showed no growth. Mike was then transferred for a pediatric orthopaedic consultation, and a radiograph of the knee demonstrated a metaphyseal fracture, which was healing (Figure C3.4.1). He was placed in a soft cast, discharged home, and was afebrile in 48 hours with greatly increased comfort.

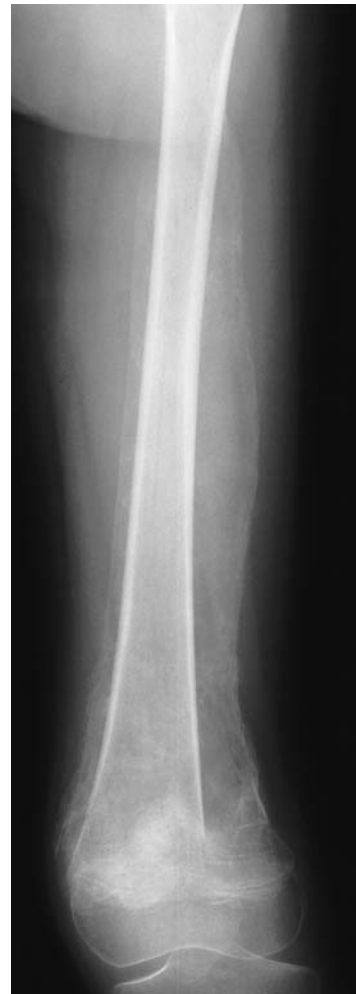

Figure C3.4.1

pushed by caretakers, who caught one of their feet because the foot was not strapped to a footrest on their wheelchair. With these feet caught on the lateral side of the door jam, spiral shaft fractures of the tibia typically occur. We also have had several patients who developed femoral neck fractures during therapy stretching exercises, usually after they had a posterior spinal fusion, and there is an attempt to stretch out hip extension contractures (Case 3.7). There are two stress fracture patterns that are relatively common in children with CP, and they occur at the patella and the metatarsals. These fractures are not related to osteopenia, but are due to classic chronic repeated mechanical stress injury of the bone, and are addressed in Chapter 11.



Case 3.5 Bill

Bill, a 12-year-old boy with severe quadriplegic pattern involvement, was brought to the clinic with a complaint by his caretaker of apparent discomfort during dressing and bathing. Upon physical examination the discomfort seemed localized at the right shoulder. A radiograph (Figure C3.5.1) showed a typical metaphyseal fracture, which was treated with an arm sling, and his caretaker was asked not to put this arm into a shirtsleeve for 3 weeks.

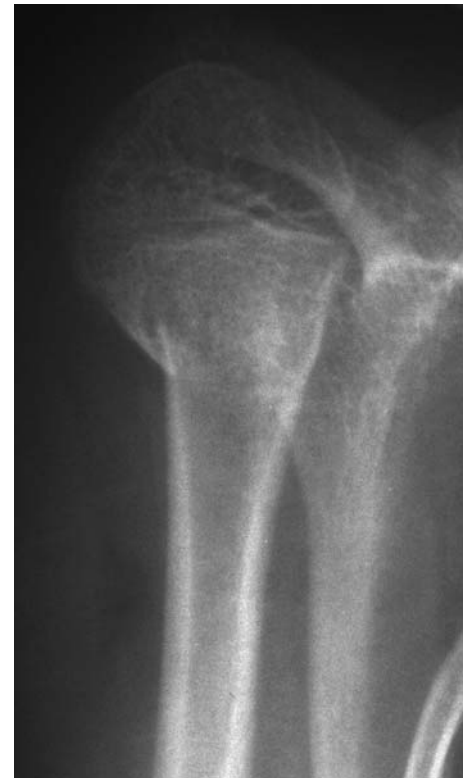

Figure C3.5.1

Treatment of Fractures

The most important aspect in treating fractures is to diagnose the fracture. As already noted, this requires a careful history, full examination, and appropriate radiographs. The radiographic changes may be very subtle and always must be correlated with a careful physical examination. In these low-energy fractures, a radiologist who has not examined the child will often miss the fracture. The typical mild fracture has only a small cortical buckle, and unless the projection happens to be in the correct plane, the fracture may not be evident. If the child has bone tenderness with an appropriate history, a fracture should be presumed to be present. There is no need to obtain a bone scan or any other test if the child has bone tenderness even with a normal radiograph, as these minimal fractures are very common, easy to treat, and almost always resolve without problems. If after 4 weeks of treatment the bone is still tender, then a bone scan and other testing are indicated.

A fracture around the knee can be treated with a soft bulky cast made of thick cotton roll covered with a small rigid plaster splint (Figure 3.10). Perfect alignment of these fractures is not needed because they remodel and almost always occur in children who are nonambulatory. The same treatment



Case 3.6 Emma

Emma, a 12-year-old girl, was riding in the back of the school bus in her wheelchair when the bus hit a pothole, causing a severe bounce. She was restrained in her wheelchair but complained of severe back pain immediately, and was taken to the emergency room where radiographs of her spine were obtained (Figure C3.6.1). Three compression fractures were produced at the apex of her natural kyphosis, which is the common fracture pattern with this mechanism of injury. This injury usually occurs in adolescents with increased kyphosis and poor trunk control. Initially, symptomatic care with supine positioning and analgesia is the required treatment and, as the pain subsides, the child is mobilized with an orthosis that prevents trunk flexion.

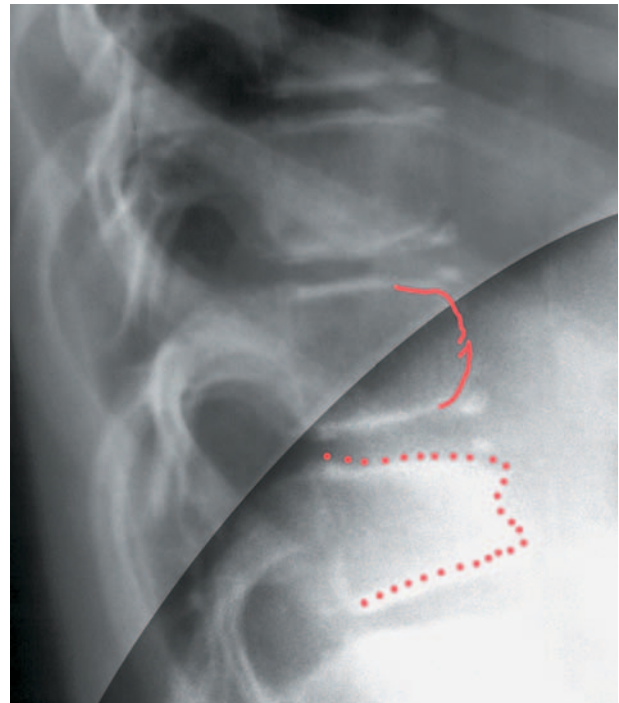


Figure C3.6.1

is adequate for all foot and tibia fractures. Femoral shaft fractures are usually wrapped with a thick layer of soft cotton padding and then a high lateral extension along the lateral aspect of the abdomen is added, or a single leg spica wrap is used. If an adolescent is very large or very spastic, flexible intermedullary nailing may be considered, but this is seldom needed. These fractures tend to heal very quickly, with metaphyseal fractures usually completely healed in 4 weeks and shaft fractures in 6 to 8 weeks. Fractures in ambulatory children should generally be treated in the same way that a fracture would be treated in a normal child without CP.

Repeated fracture at another location is very common within 2 to 3 months after a low-energy fracture in a child with severe osteopenia (Case 3.8). This repeated fracture apparently occurs because the calcium is mobilized from other bones to heal the original fracture. While being treated for the original fracture, these children are usually handled in ways that substantially decrease the mechanical stress on the other bones, such as being prevented from standing or weight bearing. Caretakers should be informed of the risk of repeat fractures and be taught how to diagnose low-energy fractures, as the knowledge in this area among general medical physicians and emergency room physicians is very scant.

After the fracture has healed, these children should return to physical therapy and their standing program. Obtaining as much weight bearing as



Case 3.7 Emily

Emily, a 12-year-old girl, had a posterior spine fusion with a unit rod 6 months earlier, when her father brought her to the clinic with the concern that her hips were becoming painful. She was very spastic with extensor posturing. Her father reported that he had been working on stretching Emily's hips by having her do sit-up motions on the floor, with her legs straight out in front of her as he pushed up on her trunk to flex her hips. He had had to stop this in the past week because of the apparent hip soreness. On physical examination both hips were painful to motion; however, the right hip had a very free range of motion, but the left was still limited to 80° of flexion. A radiograph of the pelvis showed bilateral femoral neck

fractures (Figure C3.7.1). Because the left hip fracture was moving freely, was completely displaced, and much less painful, it was elected to leave it and only place pins in situ in the left femoral neck (Figure C3.7.2). A follow-up 5 years later showed a complete nonunion of the right femoral neck and a healed fracture on the left (Figure C3.7.3). Both hips were painfree and she had excellent sitting ability. Range of motion in both hips was reduced, but was adequate for sitting and personal hygiene. This case demonstrates the importance of reminding parents to use limited force on doing stretching, especially after spine fusion, which greatly increases the lever arm advantage for doing hip stretching.

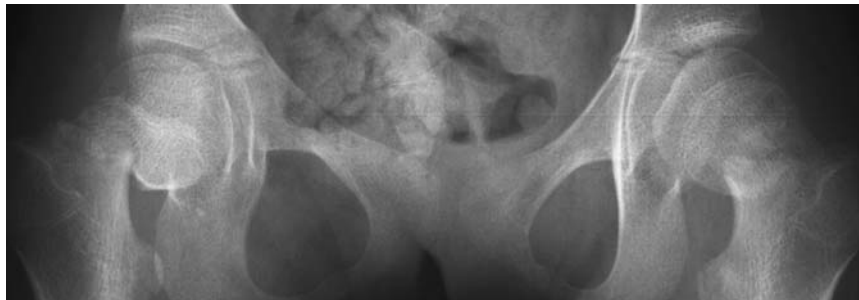

Figure C3.7.1

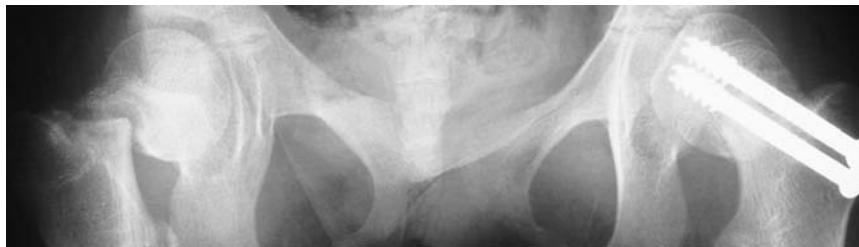

Figure C3.7.2

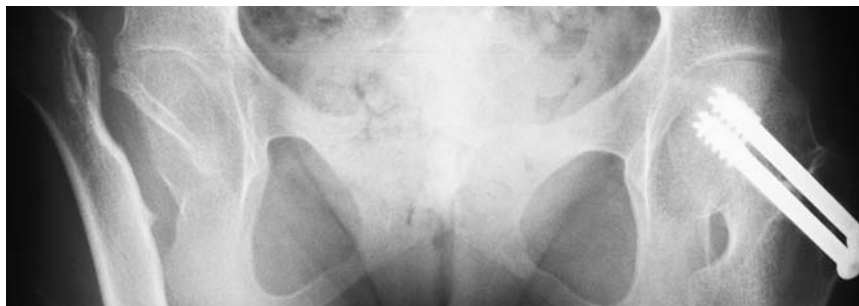

Figure C3.7.3

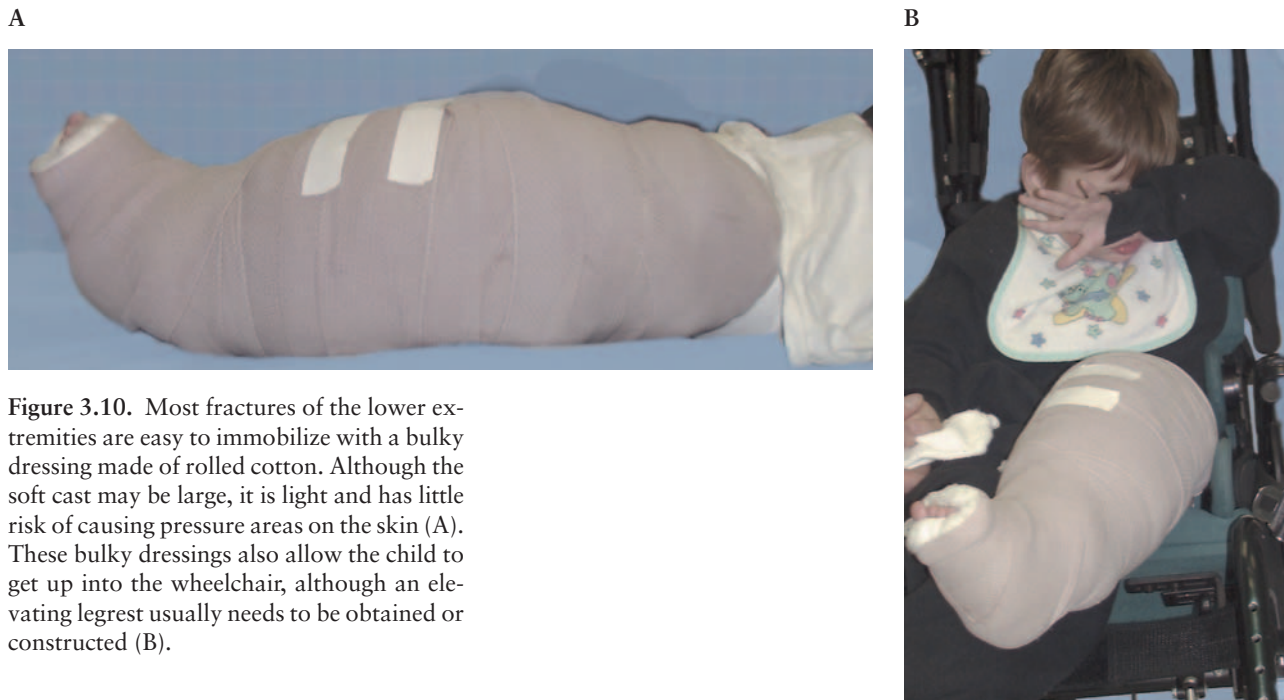


Figure 3.10. Most fractures of the lower extremities are easy to immobilize with a bulky dressing made of rolled cotton. Although the soft cast may be large, it is light and has little risk of causing pressure areas on the skin (A). These bulky dressings also allow the child to get up into the wheelchair, although an elevating legrest usually needs to be obtained or constructed (B).

desired in children placed in standers is difficult because standers, by the nature of the devices, provide a lot of weight support. It is also difficult to keep a child with a quadriplegic pattern CP in a stander for more than 1 to 2 hours a day. Our recommendation to parents is to try to get at least 1 hour per day of weight bearing. It makes good rational sense that even this short period of weight bearing in a stander would be better than nothing. Another problem that occasionally arises is caretakers who become exceedingly cautious with the child because the fracture clearly occurred during a specific activity such as physical therapy stretching or dressing. This greatly increased caution will only decrease the stress on the bones and further aggravate bone mineral loss. It must be explained to the therapist and caretakers that they should be careful to avoid fractures, but that it is very important to keep stretching and stressing these children's bones.

Treating the Osteoporosis and Osteomalacia

Pathologically low bone mass should be investigated in nonambulatory children with spastic quadriplegia after the fracture has healed. All children over age 5 years who are nonambulatory with quadriplegic pattern CP should be considered at risk for low bone density, with those children on antiepileptic medications having the highest risk. The treatment should first focus on nutritional assessments,^{16, 21} especially dietary intake of calcium and vitamin D. The workup for all children should start with a complete 3-day dietary intake history, which is then evaluated by a dietitian. The diet should then be augmented with calcium and vitamin D to the Recommended Daily Allowance (RDA) for the child's age.

Children who have had fractures and those who are nonambulatory with quadriplegia and are on seizure medications should have a bone mineral density evaluation with dual-energy X-ray absorptiometry (DXA).²² Because of the difficulty of having the children hold still for the DXA and the presence of contractures and metal from surgical procedures, full DXA scans may be



Case 3.8 Kyle

Kyle, a 10-year-old boy, developed a metaphyseal femur fracture in the same leg that had a tibial metaphyseal fracture 6 weeks earlier (Figure C3.8.1). These fractures were followed with five additional fractures over the next 18 months (Figure C3.8.2). The fractures healed well with exuberant callus, which seemed to further deplete the mineral from other areas of his bones, increasing his

fragility. This pattern of recurrent fracturing is relatively common, and can usually be interrupted by limiting the immobilization as much as is comfortable, and starting weight bearing on the uninvolved side. Kyle was treated with intravenous pamidronate for five cycles, and over the next 4 years, has not had another fracture.

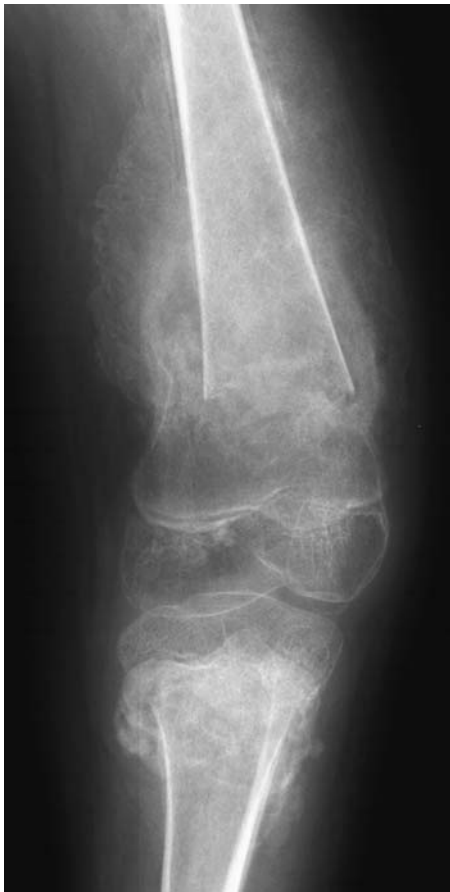

Figure C3.8.1

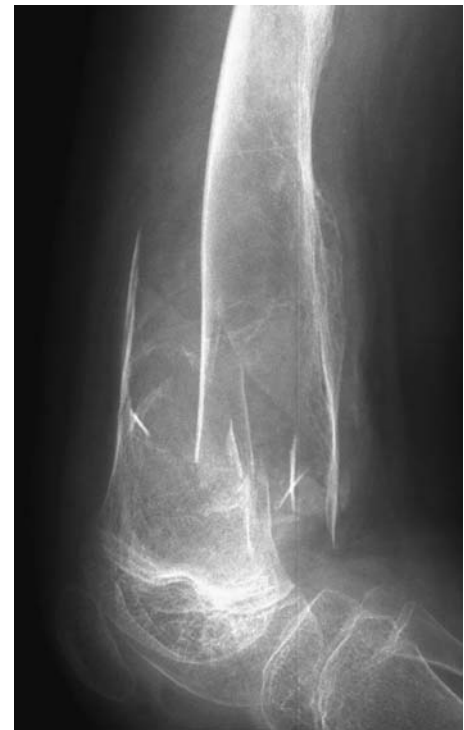

Figure C3.8.2

difficult to evaluate. We currently believe the full-body scan is best if it can be obtained and the child has no metal implants. Many children need sedation to obtain a good scan. A lumbar spine scan may also be obtained as a good correlation of the bone density, and we have been using the isolated distal femur scan because this is the area where most of the fractures occur. The validity of the distal femur is still not proven. This density evaluation

should be normalized to age-matched normals to be of diagnostic use. This same group of children should also have a metabolic workup including serum and urinary calcium levels, and 25-hydroxyvitamin D, parathyroid hormone level, alkaline phosphatase, and phosphorus levels should be obtained.^{13, 15} If calcium or vitamin D are low, or the parathyroid hormone level is slightly elevated, additional dietary supplementation with calcium and vitamin D is needed. If the DXA scan is less than 2.5 standard deviations below normal, the dietary supplementation should be increased to two times RDA; however, with this increase in calcium, spot urine checks for calcium and creatinine need to be performed with the goal of keeping the calcium creatinine ratio less than 0.2. It is important to monitor calcium output in the urine because renal and bladder calculi can develop when children are given large doses of calcium and vitamin D, especially when the metabolic workup is normal. When children with severe dietary deficiency in calcium or vitamin D are treated with dietary supplementation, they have dramatic improvement in bone mineral density and a decrease in fracture rate.¹³ If all the metabolic and nutritional parameters are normal, treatment using calcium and vitamin D has shown some improvement in children taking antiepileptic medications as well.¹²

For those children who have been treated with dietary supplementation and develop a second or third low-energy fracture within 2 years and whose DXA scan is more than 2.5 standard deviations below age-matched normal children, treatment with bisphosphonate is indicated. Currently, pamidronate disodium is the best choice in these children. The bisphosphonates are safe in children and do not affect long-term bone growth.²³ Although the current data on the effectiveness of these drugs in children with CP are limited, we have had several dramatic responders with complete cessation of fracturing after treatment with pamidronate disodium (see Case 3.8). A major problem of this treatment is that it needs to be given as an intravenous infusion over 3 days every 3 months for at least 1 year or until the DXA scan is above -2.5 standard deviations for age-matched normal children. Another option is to use olendronate, an oral bisphosphonate; however, the oral drugs tend to irritate gastroesophageal reflux, which many of these children have, can cause gastric upset and nausea, and have variable absorption in the gut.

Nonoperative Pain in the Noncommunicative Child

One of the major problems in caring for noncommunicative children who have severe motor and cognitive disabilities is determining the source of pain. This is really an extension of the problem noted in making the diagnosis of fractures in this same population. A caretaker typically brings the child to the physician with a complaint that the child is uncomfortable and has had changes in her activities of daily living. The child may refuse to eat, sleep, sit, or stand. Often the parents will have some idea of where she hurts, or they may have no idea. The initial history should focus on exactly when the child seems most uncomfortable and if this is related to any activities, such as movement, feeding, or postural changes. The next part of the workup should be a very careful, complete examination of the child when completely undressed. Starting at the head, check for ventriculoperitoneal shunts and if the reservoir is supple, tap on the sinuses to see if they are tender, check the ears for inflammation, palpate the teeth for acute abscesses, check for nasal drainage that might indicate sinusitis, check the chest, palpate the abdomen for tenderness or mass indicating severe constipation, move the hips, and



Case 3.9 Jack

Jack, a 15-year-old boy with severe mental retardation and ambulatory diplegia, was brought by his mother with a complaint that he had refused to walk after having an upper respiratory infection, from which he had not been able to recover. His mother felt that he had pain in his feet, or maybe in a hip. A complete physical examination was performed, which demonstrated no evidence of acute or chronic pain source. Because of severe behavioral problems and known problems of sleep apnea, Jack required a general anesthesia to do a bone scan (Figure C3.9.1). The scan demonstrated uptake in the sinuses, and a CT scan of the head documented sinusitis. After appropriate treatment of the sinus infection, Jack returned to his routine limited community ambulating.

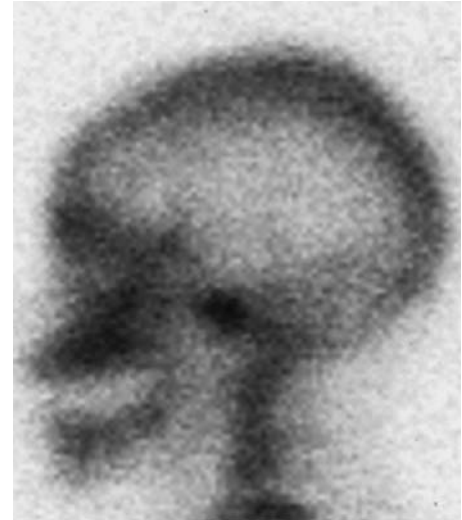


Figure C3.9.1

carefully examine each major joint and bone with palpation and percussion for erythema and swelling. Any positive findings should be worked up as appropriate (Case 3.9).

When nothing is found on physical examination, an anteroposterior radiograph view of the abdomen and hips should be obtained to make sure there is no significant hip pathology that could explain the pain. The radiograph will also help rule out severe constipation, which can be a cause of the pain. A full-body bone scan should be obtained next. The bone scan will help identify occult fractures missed by physical examination, major obstructions of the urinary tract, or other sites of inflammation such as sinusitis and dental infections (Cases 3.10, 3.11). If the bone scan is completely normal, a full gastrointestinal workup is indicated, focusing especially on esophagitis and reflux. This workup usually requires an endoscopy to rule out problems. If the child has a ventriculoperitoneal shunt, an evaluation of the shunt is required, usually with a radiograph of the tubing and a computed tomography (CT) or magnetic resonance imaging (MRI) scan of the brain. If there is any question about the condition of the teeth, a full dental examination and radiographs should be obtained. If the child has seizures, an evaluation of the seizures occasionally requires a 24-hour electroencephalogram. This extensive workup will identify the cause of the child's discomfort in almost every case, usually with a very specific diagnosis. In rare cases, where no source of the problem can be found, the child may suddenly stop being uncomfortable for no more reason than can be determined why she started being uncomfortable initially.

The two most common sources of pain in noncommunicative children are the hip and the esophagus. At the hip, the pain is usually due to a subluxated or dislocated hip that has become inflamed with a pattern of an acute



Case 3.10 Morgan

Morgan, a 15-year-old girl with quadriplegia and fixed abduction contractures of the hips (Figure C3.10.1), presented to the clinic with her mother complaining that, since approximately 1 week ago, Morgan refused to eat and did not tolerate sitting up in her chair. At times she spent long periods crying when she was lying in bed. Her mother felt she was in pain. On physical examination Morgan was crying constantly and seemed somewhat uncomfortable when she was moved, although it was difficult to tell because she could not be consoled to a position of quiet. A radiograph of the pelvis was made that showed some protrusio of the acetabulum from the ab-

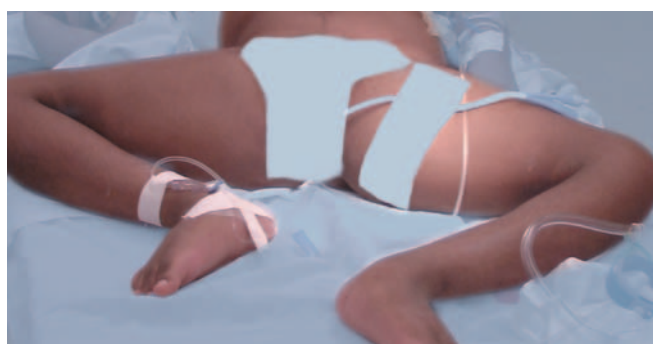

Figure C3.10.1

duction contractures and a halo around both legs of the implanted unit rod (Figure C3.10.2). The radiograph was not thought to be abnormal except for the protrusio and the possibility of mild early degenerative joint changes. A bone scan was obtained (Figure C3.10.3), which showed increased uptake in the right acetabulum. More focal radiographs were obtained of this area, and a fracture of the medial wall of the acetabulum was noted (Figure C3.10.4). By avoiding pressure on the acetabulum and keeping her at bed rest for 3 weeks, her pain rapidly resolved and she returned to comfortable sitting for the whole day.

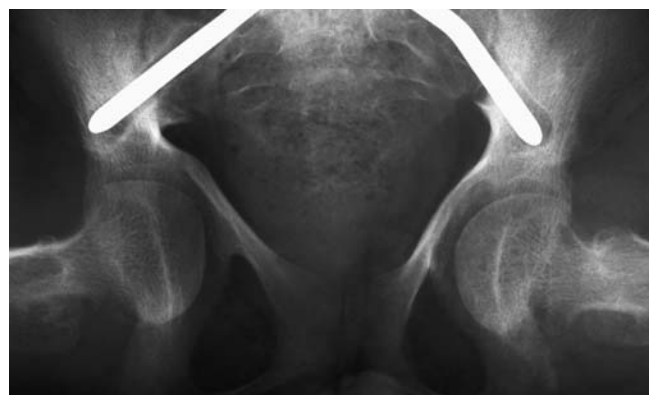

Figure C3.10.2

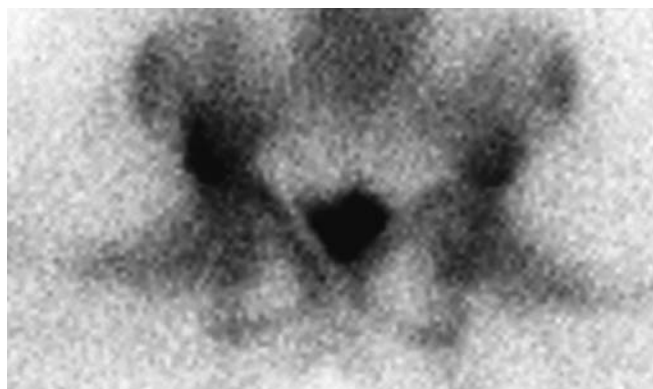


Figure C3.10.3

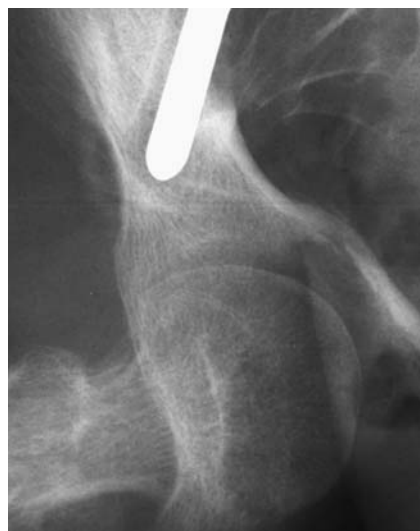

Figure C3.10.4



Case 3.11 Daniel

Daniel, a 10-year-old boy with severe quadriplegia, presented to the clinic on referral from another physician. His parents said Daniel would cry for hours on end in a pattern that they felt indicated pain. He could not be consoled, and no position, movement, or time of day seemed to correlate to the pain. The physical examination did not indicate any source of pain, and a radiograph of his pelvis showed normal hips and no significant constipation. A whole body bone scan showed an obstructed kidney (Figure C3.11.1). Urologic treatment resolved the pain.

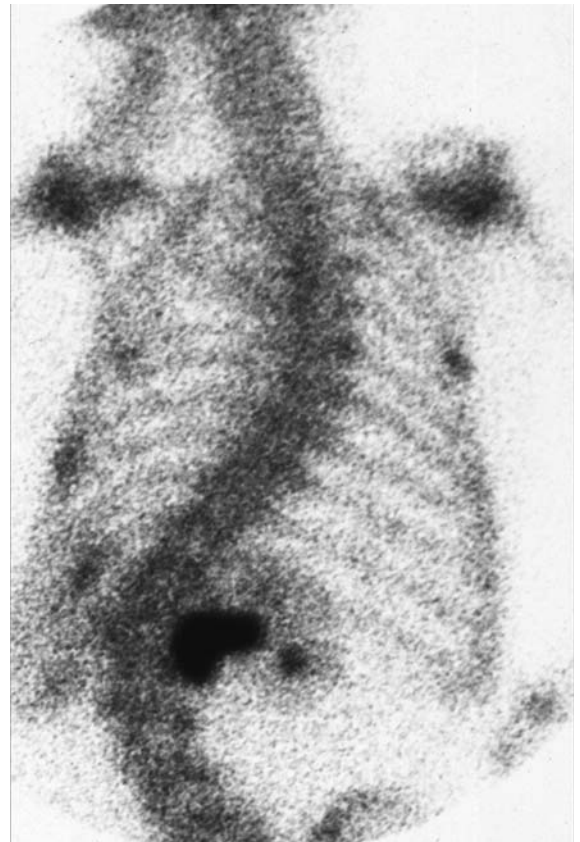


Figure C3.11.1

inflammatory degenerative arthritis. The first level of treatment for the hip pain is stopping all motion and standing therapy and giving oral anti-inflammatory medications. However, there is a high incidence of esophagitis and gastritis in this population so the oral antiinflammatory should be used only when it is clear that there is no concurrent gastrointestinal problem. Hip pain and gastrointestinal pain are frequently concurrent because any pain will increase the spasticity, which will then further increase hip irritation and gastric reflux. For example, if a child has a dislocated hip that occasionally has a little discomfort, the hip may be fine until the esophagitis develops, which increases the spasticity due to gastrointestinal pain. This increased spasticity places more force across the hip with degenerative changes, which then causes an acute inflammation in the hip, causing more pain. This increased pain then further irritates the gastrointestinal system, causing more gastrointestinal distress. The same scenario can also start with the hip.

To adequately treat this pain complex, both problems need to be addressed through a cooperative treatment program between the gastroenterologist

and the orthopaedist. Commonly, the child is passed back and forth with each specialist blaming the other area for the majority of the problem. This avoidance treatment approach does not help the family or the child. A typical response of the orthopaedist after the child has been examined is that she does have a little hip pain, but that this is not the real problem and the family should see the gastroenterologist. The parents next take the child to see the gastroenterologist who says that she does have a little reflux and prescribes some medication, but feels that the real problem is not gastrointestinal pain but is probably more likely pain from the hip. Many parents get passed around in this fashion and become very frustrated. It is very important for these children who develop pain and cannot communicate to have a coordinating physician who also understands the complex problems. Because these problems often involve different anatomic systems, it is important for the physician working with these children to also have some understanding of the issues that are present from other specialists' perspectives.

Gastroesophageal Reflux and Aspiration

Gastroesophageal reflux is a syndrome in which the gastroesophageal sphincter is incompetent and allows the stomach contents to reflux into the esophagus. This problem is extremely common in children with quadriplegic pattern CP, probably because the neuromotor function is affected directly or indirectly by the encephalopathy. Also, there is a poorly defined interaction between gastroesophageal reflux and scoliosis. When the stomach contents reflux, the acidity causes inflammation in the esophagus, which leads to pain that is described by individuals who can communicate as "heartburn." The pain is most common several hours after feeding. The pain may also be associated with posturing of the neck, often with a torsional element appearing similar to cervical dystonia. When the reflux is severe, gastric contents may come all the way back up into the mouth and the child will be noted trying to swallow it back down again. If the child has poor oral motor control, the stomach contents may be aspirated into the lungs, causing chronic aspiration syndrome with reactive airways disease. Even when no direct aspiration occurs, reactive airways disease may be present secondary to the esophagitis, which is mediated through vagal nerve irritability, caused by the inflammatory process in the esophagus.²⁴ Gastritis and peptic ulcers are also common in this patient population, and are often secondary to *Helicobacter pylori* infections. The treatment of mild to moderate gastroesophageal reflux is with a smooth muscle agonist such as cisapride and an H₂ blocker such as cimetidine or ranitidine. If there is no response in 4 to 8 weeks, additional workup with endoscopy and muscle biopsy is often indicated. If this biopsy is inconclusive, a 24-hour pH probe may be done to measure the acid in the lower third of the esophagus.

The conservative treatment for hip pain is resting the joint by stopping unnecessary movement. If the pain is severe and it is unclear if the gastrointestinal system is involved, injecting the hip joint with bupivacaine and a deposteroid can be very helpful. The bupivacaine will demonstrate how much pain relief comes with anesthesia of the hip joint, and the steroids are a safe way to temporarily decrease inflammation in the presence of gastritis or esophagitis. The hip should then be treated with reconstruction or palliation as described in Chapter 10, which discusses hip problems (Case 3.12). It is important that the treatment of the hip and gastrointestinal system is done concurrently, rather than one specialist waiting to address the remaining problem after the other fixes his problem. The gastrointestinal problems occasionally occur combined with a rapid increase in scoliosis in which



Case 3.12 Danielle

Danielle, a 17-year-old girl with severe quadriplegia, was evaluated because her caretakers felt she was having severe hip pain limiting her sitting tolerance, which made transfers difficult. The physical examination demonstrated pain with any significant motion of the right hip, and a radiograph showed a dislocated hip with severe degenerative changes (Figure C3.12.1). She was started on naproxen, 375 mg twice a day. One week later the caretakers reported significant improvement in her comfort,

but with some residual pain. The naproxen was increased to 500 mg twice a day and the caretakers felt she was now very comfortable. Nine months later while still on naproxen, she developed a severe gastrointestinal bleed from a gastric ulcer requiring a prolonged hospital course. Following this, the hip pain returned, and she was then scheduled for palliative treatment of her hip with the implantation of shoulder prosthesis (Figure C3.12.2).

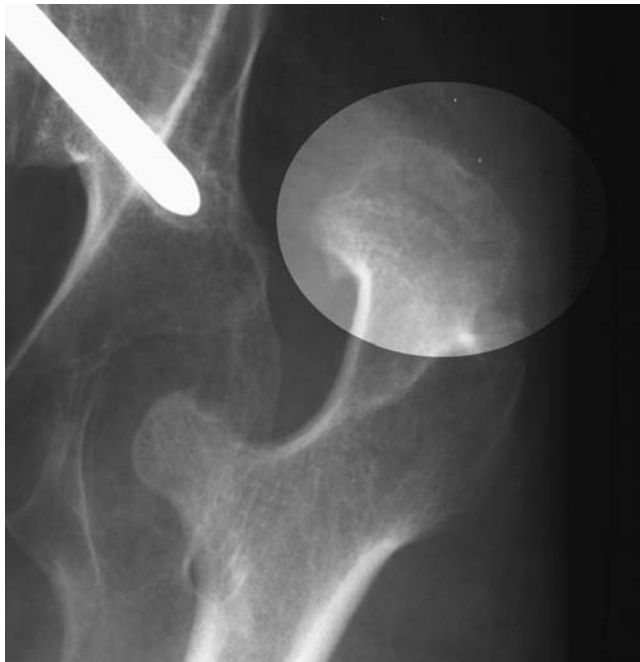

Figure C3.12.1

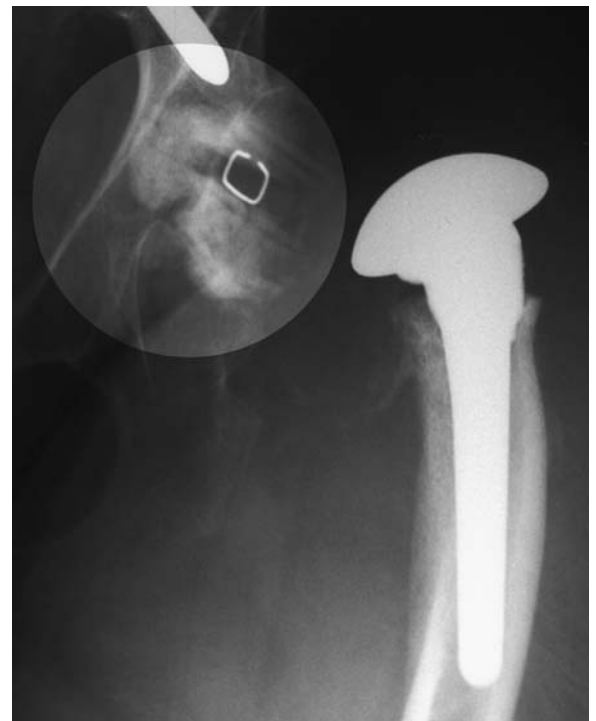

Figure C3.12.2

both the scoliosis and the gastrointestinal system are causing discomfort. When the gastrointestinal problem is under medical management, a spinal fusion should be done. In some cases, the spinal fusion will stop the gastroesophageal reflux completely; however, in other cases, the reflux will get worse. This worsening reflux can still be managed medically. When reflux does not improve, the next treatment is surgical reconstruction of the gastroesophageal junction by fundoplication. This procedure is easier and probably longer lasting when the spine is corrected first. There are no published data on the advantage of correcting the spine first, but this has been the experience of our facility.



Case 3.13 John

John, an 8-year-old boy with severe quadriplegia, presented with definite hip pain on physical examination; however, the hips were normal on radiographs and there was no pain relief with injection of the hip joint. The gastrointestinal workup was also normal. John had a ven-

triculo-peritoneal shunt, which was believed to be functioning well by the neurologists. After 2 months, John developed a severe abdominal distension, and it became clear that he had a chronic infection in his ventriculo-peritoneal shunt when he developed severe ascites.

Other Common Problems Incurred and Encountered in the Workup of Pain in the Noncommunicative Child

Although the most common cause of discomfort or pain in noncommunicative children is by far the gastrointestinal system combined with hip or scoliosis pain, other problems do occur. There may be problems with ventriculo-peritoneal shunts including shunt occlusion or peritonitis. Peritonitis associated with a shunt catheter may be very difficult to diagnose early in the course (Case 3.13). Many noncommunicative children spend considerable time reclined and are at more risk for developing sinusitis. The sinusitis is often very hard to diagnose and initially shows up as an increased uptake on the bone scan. Sinusitis may present with behavior changes, such as refusing to sit or to stand, instead of crying in pain (see Case 3.9). Abscesses of the teeth may have an element of increased drooling or biting associated with the discomfort. An acute surgical abdomen may be very difficult to diagnose and usually leads to the child's death if not correctly diagnosed before the child comes to see the orthopaedist. Constipation is another common problem in nonambulatory children that can cause severe chronic discomfort. The constipation may also lead to urinary incontinence or urinary retention. Urinary calculi may be a cause of intermittent severe pain.

Genitourinary Problems

Most urinary problems in children with CP do not present as part of an unknown pain problem syndrome, although this can happen. The most common genitourinary problem is undescended testicles in boys with spasticity. Often, these boys are not carefully checked throughout middle childhood when orthopaedists see them most frequently. Recognizing undescended testicles is easy if the boys are examined, especially if the examination is done during a concurrent hip examination while the child is under anesthesia for hip or lower extremity surgery. The boys should be referred to a urologist for an evaluation if the testicle cannot be palpated. The treatment of undescended testicles is not clear cut in boys with CP, especially if they have severe quadriplegic pattern involvement. An occasional child will present with a recurrent urinary tract infection, and it is important to remember that children with CP need the same urologic workup as normal children.

Another common urologic question is whether children with CP can gain bladder and bowel control. In children who can communicate and who have sufficient cognitive ability to comprehend, bowel and bladder control should be present by age 5 or 6 years. If this does not occur, referral to a urologist for examination and urologic evaluation is indicated. Although bladder dys-

function is not common, it does occur. This dysfunction may be upper or lower motor neuron neurogenic bladder dysfunction, suggesting that occasionally children who are treated as having CP have a combination of CP and spinal cord dysfunction.²⁵

Problems with Temperature Regulation and Poor Peripheral Blood Flow

Problems with temperature regulation are relatively common in children with CP, again primarily those with quadriplegic pattern involvement. Their core body temperature will drift toward the ambient room temperature. Caretakers have to be especially careful not leave them in the sun during the summer or core body temperature can rise above 40°C without these children expressing discomfort. The same is true about keeping them warm when it is cold, which means monitoring them in an air-conditioned room as well. We have seen children on several occasions with body temperatures as low as 32°C just from sitting in air-conditioned rooms or vehicles without being well dressed.

The most common manifestation of this temperature instability is the great variability of temperature of the extremities, especially the feet. There may be times when the feet are cold to the touch and have a blue cadaveric appearance, often alternating with a flushed erythematous appearance (Figure 3.11). This appearance often raises concern with school nurses and therapists, who then refer these children to the family doctor, who is also unclear about the problem. Although these feet look and feel at times like they are completely without blood flow, very similar to adults with severe peripheral vascular disease, this is a completely benign condition. These same feet, when these children come out of a warm bath, will look nice and pink. The parents will report that in the morning the feet are generally warm and pink if they have been well covered all night with sheets. These apparently very bad-looking feet, when seen during the day in a doctor's office, are best treated by keeping on a warm pair of socks and shoes and recommending that shoes not be removed during the day for schoolteachers and aides to look at the feet. We have seen several hundred feet with this bad appearance and do not know of any child who ever had problems with ulceration or dying toes from this condition. There is no need to limit the amount of time these children stand and there definitely is no need for anyone to be looking at their feet when they are standing. The only situation where color and coldness of the limb should merit concern is if the limb continues to have a cyanotic, cadaveric appearance when it is warmed to body temperature. We had one child

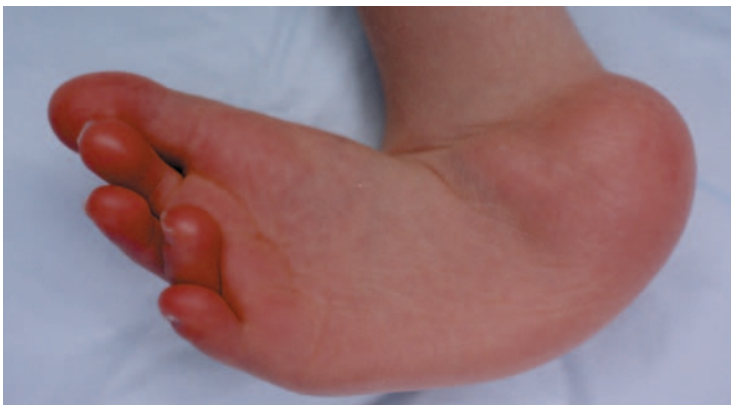

Figure 3.11. Many children with quadriplegic pattern CP have feet that looked very red and inflamed or very cold and blue with cadaveric appearance. This vascular dysfunction needs no treatment and does not lead to skin ulceration or other problems related to poor blood flow.

who developed necrosis of the tips of her toes and fingers, but the color change was due to concurrent small vessel disease from lupus and not from the changes secondary to CP. This girl's feet never changed color even when they were warmed up.

Maturation

In children with severe encephalopathic changes in the brain, there is also injury to the pituitary hypophyseal axis, causing hormonal changes. This is one reason for short stature in some individuals, as the growth hormone regulation is affected. Most of the children so affected are totally dependent for their care and movement; therefore, most caretakers are happy that they stay small. In the rare child who is ambulatory, short stature should be investigated by checking growth hormone levels, and augmenting the growth hormone with exogenous hormone should be considered. A common effect of the hormonal axis dysfunction is premature puberty. Typically, this presents with children starting to get pubic hair as early as 3 or 4 years of age. This early start of puberty is minimal and does not progress rapidly. Another common effect of faulty central hormonal regulation is prolonged puberty, so even though the first signs of puberty start early, full maturation may not be reached until the late teenage years or even early twenties.

Almost all individuals do go through full puberty, with females having menstrual cycling. Caretakers occasionally ask about stopping menstrual cycles because of the concern about the young woman becoming pregnant through a man taking advantage of her, or the caretakers find the personal hygiene very difficult to maintain. Menstrual cycling can be stopped through medication treatment with progesterone injections; however, it is not possible from a legal perspective to consider hysterectomy or any other permanent surgical solution. Legal guardians can consent for all medical care, but they are precluded from consenting, without a court order in most states, to a surgical procedure that will render an incompetent adult sterile unless the procedure is being done for medical reasons, such as treating a tumor. A typical consequence occurred when a mother convinced a gynecologist to perform a hysterectomy on her daughter and the surgeon lost her hospital privileges as a result.

When Things Are Not Going as Well as Expected

Another very important aspect of outpatient management of children with CP is always maintaining a very keen outlook for other diseases. It is very common for physicians and parents to presume that new problems arising with a child are due to the CP unless the new symptoms are very obvious. We have many examples of children who come to the CP clinic with a complaint that the family doctor believed was related to the CP but in the end is a new problem. There are two broad categories that have to be kept in mind related to this issue. First, it is always important to question if a child really has CP or, if a correct diagnosis has never been made these new symptoms may now allow a correct diagnosis to be made. These new symptoms and diseases are most typically progressive neurologic disorders that were thought to be static or so slowly progressive that the progression had not been recognized previously.

Recognizing that children with static brain lesions do change as they grow is important, and some of these changes can lead to decreases in motor function if they are not managed appropriately. These patterns are easy



Case 3.14 Kaela



Kaela, an 12-year-old girl with ambulatory diplegia, was evaluated because her mother felt she did not want to walk as much, and she complained of knee pain. Kaela did not want to go to school, and her mother thought she was worse in the morning. She had femoral derotation osteotomies 18 months ago with good recovery until the past month. Upon physical examination she was noted to walk with a mild crouch and a premature heel rise (Kaela—video). This gait pattern seemed to be slower than on the previous examinations. Physical examination demonstrated popliteal angles of 50° , mild gastrocnemius contractures, with ankle dorsiflexion of -5° with knee extension. Full knee extension was present and there was mild diffuse tenderness of both knees. A diagnosis

of patellofemoral stress reaction was made, and she was treated with oral antiinflammatories and solid ankle AFOs to protect her extensor mechanism. After 1 week, her mother reported improvement in her gait so the treatment was continued. Three months later, Kaela again returned with a history that she was worse even with the treatment. An examination at this time demonstrated mild bilateral knee effusion and increased temperature of the knees. A rheumatoid factor was negative but the erythrocyte sedimentation rate was elevated at 80. A rheumatology consultation agreed with the diagnosis of rheumatoid arthritis, and treatment with methotrexate was started. The symptoms rapidly resolved, and she returned to her previous level of function.

for the experienced neuro-orthopaedist to pick up. The most common problems are increased weight gain causing increased knee flexion contracture, hamstring contracture, plana valgus feet that finally stop a child from walking, and a severe crouched gait pattern that develops in a child who was previously an excellent ambulator. These mechanical motor problems are all correctable and predictable. Except for these mechanical problems, children with CP should never lose substantial motor or cognitive function. If they do lose function from other than the problems listed above, a diligent investigation for another disease is required. This investigation usually requires MRI of the brain and spinal cord, skin and muscle biopsy, and full metabolic evaluation. A related problem is that physicians, such as neurologists who have no history with a particular child, will need to be convinced that there is an actual neurologic deterioration. Videotapes of all ambulatory children should be obtained as part of the permanent medical record because they provide an excellent documented subjective evaluation of the children's level of function. Also, parents are encouraged to bring family pictures that might show the change in function, which is especially helpful if the changes have been very slow.

The second group of children who are referred with new problems that are thought to be secondary to their CP may turn out to have completely new problems in addition to CP. It is important to remember that children with CP have no immunity to all the other diseases that affect the human race. Therefore, with a patient population of 3000 children, we should see all the diseases that 3000 normal children get in addition to the CP-specific problems. Some of these concurrent diseases may be a real diagnostic challenge. For example, a child with diplegic pattern CP who develops rheumatoid arthritis typically is first thought to have a much more common high stress reaction in the knee joint with a possible stress fracture of the patella as the cause of the pain (Case 3.14). By keeping an open mind that everything is not CP, eventually the presence of the rheumatoid joint becomes much more evident. It is important for orthopaedists to at least keep an open mind and

Table 3.1. Diseases in our cerebral palsy clinic patients not related to cerebral palsy.

Rheumatoid arthritis
Systemic lupus erythematosus (SLE)
Dermatomyositis
Lyme's arthritis
Astrocytoma of the brain
Non-Hodgkins lymphoma
Acute lymphocytic leukemia
Osteomyelitis
Spinal cord tether
Spinal cord astrocytoma
Colitis
Meckel's diverticulum with obstruction
Colicystitis and colangitis
Renal and bladder calculus
Renal obstruction
Renal failure requiring dialysis
Cystic fibrosis
Charcot-Marie-Tooth disease
Duchenne's muscular dystrophy

ask for referral and opinion from other specialists when they think a problem is not due to CP. Because of the wide variety of illnesses (Table 3.1), making the specific diagnosis may not be possible, but at least considering the other options will allow a more appropriate workup to be done.

Diplegic and Hemiplegic Pattern Involvement

Outpatient management of children with diplegia and hemiplegia usually starts with follow-up by an orthopaedist at 18 to 24 months of age. Typically, the major concerns are related to spasticity, muscle contractures, and the ability of these children to walk. Continuing to monitor the hips in all children who have spasticity involving the hip muscles is important. Although spastic hip disease is most common in children with quadriplegic pattern involvement, it occurs in children with diplegic and severe hemiplegic pattern involvement as well. Orthotics are typically limited to AFOs, usually starting with a solid ankle variety and moving to an articulated orthotic as ambulatory ability is gained. Outpatient follow-up for children with diplegia and hemiplegia should be every 6 months in the early stages of the diagnosis and during rapid growth and development; however, for children with mild involvement, this follow-up can be extended to once annually. The general goal is for the children to be as brace free and mobile as possible by the time they enter first grade. This aim allows them to integrate into school and be involved with peers. For most children with diplegia and hemiplegia, the therapies, especially school based, should be limited to nonacademic times only. Children who are functioning normally from a cognitive perspective should not have any of their education interrupted by therapies or other medical procedures, except when it is absolutely necessary. When necessary, these therapies or procedures should be episodic, and not an ongoing activity for the whole school year. Just as therapy in school should be limited so education is not impacted, physicians' office visits and surgery should also be limited as much as possible to avoid interrupting education.

Surgical Management

A very important aspect of the outcome of surgical procedures, especially from the perspective of the amount of trauma caused to children and families, is determined by the quality of the postoperative management. A surgeon may make an excellent preoperative assessment of a child with good planning for the surgical procedure followed by a flawless technical performance of this procedure; however, the outcome may be perceived very negatively by the parents. One of the biggest complaints of parents is severe postoperative pain and spasticity that was not addressed to their satisfaction. We have heard stories of parents being told that children with CP cannot have much pain medication because it cannot be used with seizure medications. Proper management of children in the postoperative phase is as important as the technical performance of the surgery. Surgeons must do most of this management themselves because nonsurgical physicians seldom have the experience and understanding of the specific surgical procedures required to have an expectation of the amount of pain a child may have. Postoperative pain and spasticity management must also consider the neurovascular function of the limb, and it needs to be coordinated with an immediate postoperative physical therapy program. There is a definite benefit, however, of having a medical team that understands the problems of children with CP assist in the postoperative management, especially for medical problems such

as seizures, reactive airways disease, and gastroesophageal reflux. A child's postoperative pain and spasticity management should have very high priority, allowing the other medical problems to be addressed while the child is kept comfortable.

Preoperative Assessment

Preoperative assessment should be based on the size of the surgery that is planned. For example, a posterior spinal fusion warrants much more diligent medical workup than simple muscle lengthening. In spite of the amount of preoperative workup, it is important to recognize that general anesthesia has its own risk, so there must be an appropriate preoperative anesthesia evaluation.

The nutritional state of these children is always a consideration. Having absolute parameters for specific procedures is very difficult; however, a child's body weight and weight for height are prime indicators to monitor. A child's physical examination and a determination of how much body fat is present are considered as well. Only for very large procedures, such as posterior spinal fusions or for children who appear extremely malnourished, is obtaining specific laboratory tests, such as serum protein, albumin, and prealbumin levels, necessary.

The definition of good seizure control can vary from one child to the next. It is important that the neurologist managing a child's seizures is comfortable that the child is under adequate seizure control. Also, if antiepileptic medication levels have not been checked within the last month, they should be checked as part of the preoperative blood testing. Generally, it is wise to delay surgery if the neurologist recommends major acute changes in anti-epileptic medications.

Many children with CP have ventriculoperitoneal shunts, some of which were placed during infancy. If there are no symptoms related to shunt malfunction, such as behavior changes, headaches, or vomiting, additional preoperative workup for shunt function is not usually indicated. The exception is spinal surgery because it creates very large changes in a child's body shape and may put extra tension on a ventriculoperitoneal shunt. Therefore, a preoperative evaluation of shunt function should be considered if not evaluated in the previous 1 or 2 years (Case 3.15).

Gastroesophageal reflux is an especially common medical problem in nonambulatory children. This gastroesophageal reflux should be under maximum preoperative medical management with a good plan for postoperative medical management for all levels of surgery. Part of the gastrointestinal malfunction involves reflux combined with chronic aspiration commonly leading to reactive airways disease, occasionally with significant wheezing. This reactive airways disease should also be under maximum medical management. The anesthesiologist should know about this disease and a postoperative treatment protocol should be in place. There are occasional children who have reactive airways disease without chronic aspiration, but their management is the same.

Intraoperative Management: Special Anesthesia Concerns

With respect to age and size of children with CP compared with normal children, the administration of general anesthesia is very similar. However, there are several concerns specific to CP of which anesthesiologists should be aware. The first concern is that children with CP tend to have low body temperatures or drop their body temperatures under anesthesia faster than normal children. Some children with severe quadriplegic pattern involvement have relatively poor body temperature control and tend to drift to the ambient



Case 3.15 Ashley

Ashley, a 12-year-old girl with spastic quadriplegia, was evaluated before spine surgery with a sitting anteroposterior spine radiograph (Figure C3.15.1). A break in the ventriculoperitoneal shunt tubing was noted and she was referred for evaluation, which concluded that she was no longer shunt dependent. Four months after the posterior spine fusion, she developed evidence of hydrocephalus and required shunt revision.

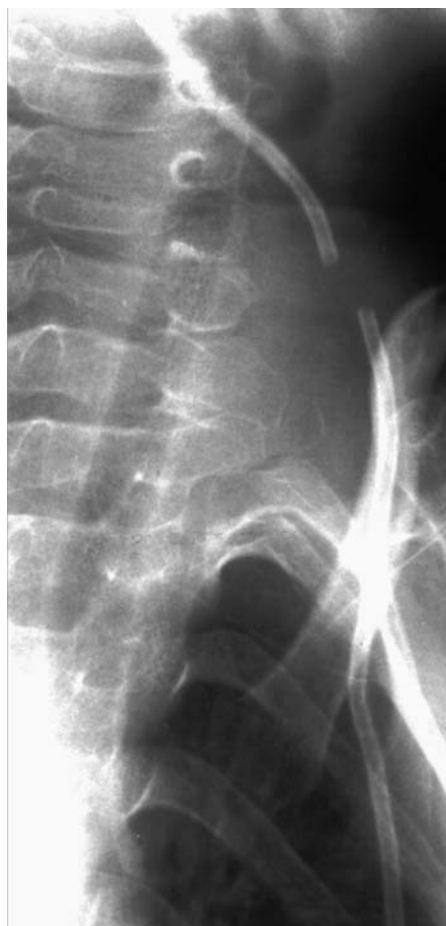

Figure C3.15.1

room temperature. These individuals, if they are brought in as outpatients, may present to the operating room with a body temperature of 34°C, or occasionally even lower. There are no specific criteria on exactly how warm a child should be before entering the operating room. However, it is our policy that the preinduction temperature be 36°C because during induction and at the beginning of the operative procedure, a child's temperature may drop 2° or 3° if care is not taken to keep them covered, keep the room temperature high, and use heating lights. Another significant difference found in children with substantial spasticity is resistance to the neuromotor blockade drugs. This resistance is the result of changes in the neuromotor junction as a result of the chronic spasticity. Immediate preoperative prophylactic antibiotics are recommended for all children with CP who undergo bone surgery or surgery that involves a groin incision.

Postoperative Management

A primary management objective postoperatively should be to limit the amount of pain and spasticity that the child experiences. Extreme pain and spasticity especially should be avoided because they make gaining control even more difficult and require higher doses of medication. A typical scenario is a child who is recovering from anesthesia and develops muscle spasms, which are extremely painful in the freshly operated limb. The pain from these spasms initiates other spasms, becoming a vicious cycle where the increasing spasticity causes increasing pain, which further increases the spasticity. The preferred management is to avoid this increasing spiral of pain and spasticity right after surgery by using a combination of morphine and diazepam, which is very safe. In an unreported review of this postoperative management algorithm on more than 3000 cases, we had fewer than 10 cases developing oversedation requiring reversal and no deaths. In the last several years we have started to use more epidural anesthesia, continuing the epidural catheter for postoperative pain management. When the epidural anesthesia works well, it allows children to be comfortable without such heavy sedation; however, it does require a higher rate of urinary catheterization. The use of postoperative epidural analgesia has to be undertaken very cautiously after major extremity surgery in which a restrictive cast was applied. The level of anesthesia provided makes the diagnosis of compartmental syndrome and pressure-induced skin necrosis difficult.

In the acute postoperative period, especially the first 24 to 48 hours, it is wise to do spot checks of oxygen saturation or use an oxygen saturation monitor in the patient's room. If constant monitoring of the oxygen saturation is used, the alarm is set at 85% saturation. This setting is especially important if the child has reactive airways disease or is becoming extremely sedated. Prophylactic antibiotics are used for all bone surgery and surgery in the groin for 24 hours postoperatively. We usually give three doses of a first- or second-generation cephalosporin.

Pain and Spasticity Management

It is important in the postoperative period to recognize that there are two reasons why a child might not have adequate air exchange or hypoxia related to diazepam and morphine drug levels. Clearly, if the child is oversedated to the point where she cannot control the upper respiratory tract and has a decreased respiratory drive, the cause is high drug levels. The other cause of poor air exchange is a child who has such severe spasms that the intercostal muscles are preventing movement of the chest wall. In this situation, the problem is insufficient drug levels. In the first situation when the child is oversedated, she will be very loose and is usually quiet and not crying. In the second situation where spasticity is present, the child will be very tight and stiff and often crying or trying to cry. Although the child may not be making any noise because she cannot exchange air, it is still apparent from viewing the child that she is uncomfortable. In this circumstance, it is important that increased diazepam and morphine are given to control the pain and spasticity so the child may relax and start breathing. Many families have told us stories of how the child was breathing very poorly in the postoperative phase and the doctors told the parents that she could not be given any pain medication because her breathing was too poor. The child consequently had to be reintubated and placed on a ventilator until comfort was reestablished. This scenario can be avoided completely by physicians who understand how to manage the problems of pain and spasticity in this postoperative phase.

The following is our specific algorithm for postoperative management of all children with CP, except those undergoing posterior spinal fusion. To gain the best results from this postoperative management routine, it should be adhered to fairly rigidly. Even slight adaptations seldom work well. The intravenous fluid rate should be between 5% and 10% over the requirements for body weight. The diazepam should be started in the recovery room as soon as the child is awake enough or is starting to experience spasms. The diazepam should be given rectally for slower and more uniform absorption at a dose of 0.1 to 0.2 mg/kg every 6 hours for 48 hours. If the spasms continue after the first dose, a second dose may be given after 3 hours, or the initial dose increased but generally kept at an every-6-hour level. The correct level of diazepam is present when the child has no spontaneous spasms and when she is lightly touched on the bare skin, spasticity is not initiated. The half-life of diazepam is very high and a substantial part of the drug is sequestered in fat stores, so when administered every 6 hours, the effect should increase slowly with very little chance of creating an overdose. After 48 hours, the standing order for the diazepam is discontinued and the child is allowed to take it every 6 hours as needed for spasticity. The same dose of diazepam on the same schedule is administered if an epidural catheter is used for postoperative pain management. Using diazepam in this case is extremely important or spasms will occur when the epidural catheter is discontinued, which make postoperative acute physical therapy very difficult.

If an epidural block is not used, morphine is given at a dose of 0.1 to 0.2 mg/kg every 3 hours for pain. The dose is increased only if the pain is not coming from active spasms. It is important to ascertain the source of the pain because if the pain is from ongoing spasticity, it is much better to increase the diazepam first because it is much more effective against spasticity than morphine. For adolescents, we prefer to use the patient-directed analgesia machine (Table 3.2). After 48 hours, or when the child starts oral feeding, acetaminophen with codeine is used for pain control on an as-needed basis. The patient should be discharged home with a prescription for acetaminophen with codeine for home use as well as diazepam for use for spasticity, which often occurs at night.

If an epidural catheter is used for postoperative pain management, it is usually left in place for 48 to 72 hours. Again, as noted previously, it is important to use the diazepam and epidural analgesia concurrently even if there is not much spasm so that when the epidural is discontinued, acute physical therapy can begin effectively. The use of perioperative epidural and postoperative analgesia using opioids has been reported in children with CP.²⁶ We have also used local anesthetics, such as bupivacaine hydrochloride, and from our experience and the experience of others,²⁷ the use of postoperative epidural anesthesia for pain control provides excellent pain relief. However, there are two major problems with using epidural anesthesia for pain control. One problem is that urinary catheterization is often needed and therefore may increase the risk of a urinary tract infection. A second major problem occurs if the catheter placement is such that it moves or no longer functions in the acute postoperative period. This catheter problem often causes an acute and severe increase in the child's level of pain, causing them to get far into the pain and spasticity spiral before the pain is effectively controlled. These epidural failures have created some of our most unhappy patients because they end up requiring very large doses of morphine and high doses of diazepam before they are finally made comfortable.

Monitoring the neurovascular function in a limb in the postoperative period may be somewhat more difficult because many children are unable to move their toes in casts and may not be able to respond appropriately to

Table 3.2. Postoperative drug management.

<p>Diazepam: start with loading dose of 0.1 to 0.2 mg/kg in recovery room</p> <ul style="list-style-type: none"> • Give 0.1 to 0.2 mg/kg every 6 hours per rectum for 48 hours <ul style="list-style-type: none"> • If still having spasms during this time add an additional dose and by slow elevation can increase to 0.4 mg/kg • After 48 hours give same dose of Diazepam orally on an as-needed-only schedule to control spasticity • Give parent prescription of Diazepam to use at home for the first 2 to 4 weeks <p>Morphine: give 0.1 to 0.2 mg/kg every 3 hours intravenously as needed to control pain</p> <ul style="list-style-type: none"> • If child is over age 6 years, physically able, and cognitively understands, morphine is given by patient-controlled analgesia (PCA) at the following dose: <ul style="list-style-type: none"> • If child weighs 15 to 30 kg, give 1.0 mg every 10 min with 4-hour lock-out of 8 mg (0.2 to 0.4 mg/kg) • If child weighs 30 to 60 kg, give 1.5 mg every 10 min with a 4-hour lock-out of 12 mg • If child weighs >60 kg, give 2.0 mg every 10 min with a lock-out of 16 mg <p>Codeine: Usually give with acetaminophen; start when the child is tolerating oral feeding; give parent prescription to use at home</p> <ul style="list-style-type: none"> • Give 0.5 to 1.0 mg/kg every 3 hours to a maximum single dose of 60 mg

questions regarding the sensation. Monitoring the color and capillary fill of the digits is important. The child's level of pain and the amount of pain medication required are also good indicators of any possible problems. Children who cannot respond to requests of normal sensation should not be pinched or have other noxious stimulus applied to their extremity on a routine basis to check sensation. This stimulus only adds to their discomfort and does not provide any meaningful monitoring of the limb. The use of epidural anesthesia may also make monitoring the neurovascular function more difficult, especially if major surgery has been performed on the foot or calf, which is then placed in a cast. We have had several skin pressure ulcers in which epidural anesthesia was used. The epidural probably blocked a pain response that would have been recognized and the cast opened, had only morphine been used. We believe the use of epidural anesthesia is a relative contraindication for some cases based on the location and magnitude of the surgical procedure, especially considering the possible risk of compartmental syndrome.

Seizure Management

During postoperative management, it is extremely important to remember to restart the antiepileptic medications in a child who has seizures. If the child does not receive one or several doses of the antiepileptic medication around the time of the operative procedure, there is seldom a problem because the high dose of diazepam used is a very effective antiepileptic. Using diazepam provides double coverage in this acute postoperative period as well. Of the common antiepileptics used in our area, we prefer to give phenobarbital and Dilantin (phenytoin) by an intravenous route until the child is taking oral medication well. Tegretol (carbamazepine) and valproic acid are given rectally. Most antiepileptic medications that are not available to give intravenously can be given rectally until the child is eating. However, if there is a substantial concern about giving an oral antiepileptic rectally, the use of the high-dose diazepam will provide adequate antiepileptic control for most children. Surgeons who care for children with CP must understand some of the significant side effects of the antiepileptic medications most used in their practice area. Many antiepileptic medications have a risk of leukopenia and hepatitis. An especially important, although rare, problem for children receiving the fatty acid antiepileptics [Depakote (divalproex sodium)] is the risk of a low platelet count and increased problems with bleeding. The use

Table 3.3. Table of drugs: seizure medicines.

Class	Generic name	Trade name	Major side effects	Drug interactions on seizure medications: (>) increases the seizure drug effect (<) decreases the seizure drug effect	
Barbiturates	Phenobarbital Primidone Mephobarbital	Luminal Mysoline Mebaral	Sedation Irritability	Propoxyphene > Chloramphenicol >	Acetaminophen > Vitamin D <
Hydantoins	Phenytoin Ethotoin Mephenytoin Phenacemide	Dilantin Peganone Mesantoin Phenurone	Low vitamin D Gingival hyperplasia Ataxia Sedation Increased seizures	Cimetidine > Aspirin, ibuprofen > Antacids <	Vitamin D < Meperidine <
Succinimides	Methsuximide Phensuximide Ethosuximide	Celontin Milontin Zarontin	Anemia Leukopenia Nausea and vomiting		
Benzodiazepines	Diazepam Clonazepam Clorazepate Lorazepam	Valium Klonopin Tranxene Ativan	Sedation Ataxia Hypotonia		
Iminostilbenes	Carbamazepine Oxcarbazepine	Tegretol Trileptal	Hepatitis Leukopenia Low thyroid Low vitamin D	Propoxyphene > Erythromycin > Cimetidine >	Theophylline < Doxycycline <
Fatty acids	Valproic acid Divalproex	Depakane Depakote	Hepatitis Pancreatitis Leukopenia Low platelet count Nausea and vomiting	Acetylsalicylic acid >	
Oxazolindione	Trimethadione Paramethadione	Tridione Paradione			
Amino acid	Gabapentin	Neurontin	Leukopenia		
Phenyltriazine	Lamotrigine	Lamictal	Hepatitis		
Carbonic anhydrase	Acetazolamide	Diamox			
Dicarbamate	Felbamate	Felbatol	Aplastic anemia Hepatitis Anorexia Weight loss Insomnia Headache		

Source: Data abstracted from *The International Consensus Handbook*.²⁸

of erythromycin with an iminostilbene (Tegretol) antiepileptic may cause the blood level of the antiepileptic to rise dangerously high. Also, many antiepileptics react with cimetidine, propoxyphene, and meperidine hydrochloride. Because of these reactions, we prefer to stay with morphine and codeine (Table 3.3).

Mobilizing the Child

Many children will not want to eat or drink much in the first 24 hours postoperatively. The primary consideration at this time is to get these children comfortable; therefore, a lack of appetite is of little concern. If the amount of drugs required to make a child comfortable also makes her very sedated, 3 or 4 days may pass before she has an interest in feeding. The timing of feeding and the amount of feeding in the postoperative period for children who had posterior spinal fusions is a major concern because the procedure is so large that they should have only a very short period of fasting. Other children with CP generally will be eating well by 3 or 4 days postoperatively, and this is of minimal concern. Getting children out of bed and moving them in physical therapy helps their appetite to return. However, there are some

children who do not eat well in the hospital, and often their parents will have had prior experiences where they ate much better at home. It is appropriate to discharge these children home if they are completely stable, with careful follow-up with the parents to make sure that they do start eating sufficiently. This poor feeding can be an especially difficult problem if the family or caretakers are unreliable. In this situation, it is very important to follow these children closely as outpatients to make sure that they are not losing weight. Also, an attempt should be made to initiate bowel movements with the use of a suppository or enemas before discharge because of the chronic nature of constipation in many children with CP.

Acute postoperative physical therapy is generally initiated at a child's bedside for very gentle positioning and range of motion as tolerated on the first postoperative day. By the second postoperative day, most children are comfortable enough to be transferred to the physical therapy department and start a program of increased range, progressing to standing and gait training as determined by the specific surgical procedure and their functional abilities. Each child should have a discharge goal established, such as comfortable range of motion and comfort when being handled by their parents to being able to independently transfer and ambulate. Once these defined goals are accomplished, the physical therapy treatment program is continued on an outpatient basis. Before discharge, follow-up arrangements are made for outpatient therapy either in the child's home or close to her community, with a minimum of three visits per week for 4 to 16 weeks, until the midterm goals based on the operative procedure are accomplished.

Later Postoperative Problems

Some children with CP tend to have very tenuous sleep cycles. These children often have problems sleeping when conditions vary from their regular routine. For these children and occasionally for children not otherwise recognized as having sleep disorders, the surgical procedure may upset their sleep routine severely. Often, a family will try for approximately a week and when unable to get the child to sleep at night, they will call the physician's office for help. By this time the family is very tired because the child is often not only not sleeping at night, but is also most uncomfortable during the night hours. Many of these children take catnaps throughout the day. The acute treatment should be for the family to try to keep the child involved and engaged during the day to prevent her from falling asleep. At night, the child should be given diazepam 1 hour before bedtime, which is repeated again in 4 hours if she is not sleeping. If the child is having discomfort, acetaminophen with codeine should be added to help with the pain. Also, an attempt to get the child back to normal activities of daily living, such as returning to school, may be important in reestablishing the sleep pattern. If the difficulty with sleep continues 4 weeks after surgery, a major change in the medical management is indicated. The diazepam should be discontinued, and for younger children under age 10 years, chloral hydrate should be given at night to help with sleep. If possible, it is better to switch the pain medication to a nonsteroidal antiinflammatory such as ibuprofen or naproxen. For the older child over age 10 years, the use of amitriptyline is preferred. Poor feeding is often associated with this sleep disorder, and the amitriptyline not only provides pain relief and improves sleep but also stimulates appetite. Amitriptyline may need to be continued for 3 to 4 months (Table 3.4; Figure 3.12).

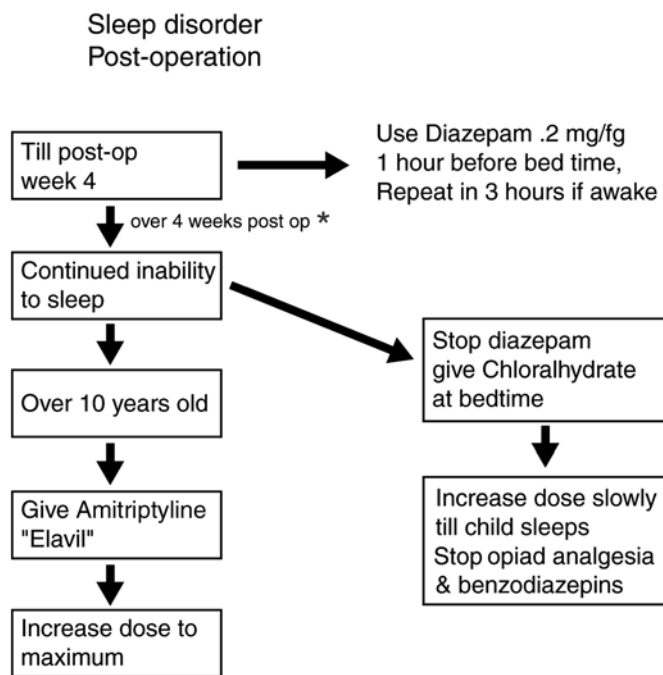
Constipation is a chronic problem for many children with CP and occasionally may be very severe in the postoperative phase. It is very important that families do not ignore this problem because it can also lead to poor feeding, problems with sleep, and general discomfort. If chronic constipation is

Table 3.4. Drugs for sleep after initial postoperative recovery.

Drug	Starting dose (at bedtime)	Maximum dose	Comments
Diazepam	0.2 mg/kg	0.3 mg/kg	This is the main drug to use during the first 4 weeks; encourage parent to give 1 hour before bedtime and repeat in 4 hours if child is still awake
Chloral hydrate	50 mg/kg	100 mg/kg; use no more than 1.5 g	This is the primary drug for younger children less than 10 years of age; very safe
Amitriptyline (Elavil)	10 mg	100 mg bid for child over 50 kg	Used only for older children over age 10 years Make sure the child does not have heart block; EKG may be needed if child has never had rhythm strip, although most of the children are postoperative and have had a strip during surgery Causes constipation and increases appetite

EKG, electrocardiogram

Figure 3.12. Disruption of the sleep cycle is relatively common after surgery. The treatment is based on the severity level.



*1. Also encourage keeping child awake in afternoon
 2. Try to return to school
 3. Increase physical activity

ignored, it may get so severe that in-hospital treatment is required for disimpaction. Families should be encouraged to use suppositories, oral stool softeners, and enemas as needed so these children have a bowel movement at least every second or third day.

Commonly Used Medications

The surgeon who treats children with CP should have a good knowledge of the most commonly used medications that may be encountered during the management of these children. Some of these medications, such as the antiepileptics that are not primarily used to treat the motor problems, need to be managed in the postoperative phase. Other medications are used in the postoperative phase to keep children comfortable. It is important to understand the characteristics of the individual medications as well as their interactions (Table 3.5).

Of all the drugs that are used during the surgical treatment of children with CP, the benzodiazepines are most commonly used to manage the acute spasticity caused by the surgery. Diazepam (Valium) is our preferred drug in this class because it has a relatively long half-life of greater than 13 hours and it is stored in the fatty tissues from which it is released relatively slowly. Diazepam also has active metabolites that recirculate through the liver where they are metabolized. The net effect of the long half-life, fatty tissue storage, and active metabolites gives diazepam an effect for up to 100 hours after full

Table 3.5. Commonly used drugs with special comments.

Diazepam has a half-life greater than 13 hours because it will store in the fatty tissues and then slowly release. The metabolites are active and recirculate through the liver where they are again metabolized; this means there is often an effect for up to 100 hours after full loading of the drug.²⁸ Other commonly used benzodiazepines do not have as many active metabolites. Clonazepam (Klonopin) or Lorazepam (Ativan) especially have few of these active metabolites that prolong the half-life. Also, giving diazepam intravenously causes very rapid absorption in the fatty tissue of the brain followed by quick release, which gives a very high peak effect but with a quick loss of effect.

Amitriptyline (Elavil) is excellent for sleep disorders. Start with a low dose of 10 mg bid and work up to maximum dose 100 mg bid. Very few children need the maximum dose. Make sure child has no heart block; child should have an EKG if there has never been a rhythm strip during surgery. The main side effects are dry mouth, constipation, orthostatic hypotension, increased appetite, and weight gain.

Morphine sulfate has very few drug interactions except those that are common to the other opioids, such as respiratory depression and constipation. It is easily reversed with naloxone (Narcan) or naltrexone.

Mood stabilizers are often used in children with CP and mental retardation. Tegretol, Depakote, and benzodiazepines are the most commonly used, and these drugs have the same effects and problems as noted in their use for seizures. Buspirone (Buspar) is being used more commonly. It has very few side effects and is mostly used for behavior control and as an anti-anxiety agent.

Stimulants are very commonly used in pediatrics and include amphetamine (Benzedrine), D-amphetamine (Dexedrine), and methylphenidate (Ritalin). These drugs have no significant recognized side effects or drug interactions that might cause problems during or after a surgical treatment. These drugs can be stopped while the child is recovering, but after the child is taking a normal diet they should be restarted. The hyperactivity for which these drugs are usually prescribed will be well controlled with the high dose of diazepam.

Naltrexone is a relatively new treatment for some children with severe mental retardation and self-injurious behavior, such as head banging or self-biting. Naltrexone is an opiate antagonist competitively blocking the opiate receptors. If these children need significant pain medication, such as following an acute fracture or surgery, they need to be treated with a nonsteroidal anti-inflammatory (NSAID), such as ibuprofen or naproxen. For more severe pain, only Ketorolac injections are available as an injectable NSAID. The Naltrexone should then be discontinued so opiates can be used if an event with significant pain, such as surgery or a major fracture, occurs.²⁸

loading with the drug.²⁸ Other commonly used benzodiazepines, such as clonazepam (Klonopin) and Lorazepam (Ativan), do not have active metabolites that prolong the half-life. However, giving diazepam intravenously causes a very rapid absorption of the drug in the fatty tissue of the brain, creating a very quick bolus effect but then a quick release, with the high early effect being quickly lost. For this reason, using diazepam intravenously in the postoperative phase is not advised because of the danger of oversedation from the high bolus effect. Diazepam has very few other side effects except for sedation. Sedation is almost always seen when effective antispasticity drug levels are achieved, and as such, this drug has very limited use in the chronic management of spasticity. When diazepam is used together with morphine and oversedation and respiratory depression occurs, the reversal of the opiate (morphine) by naloxone hydrochloride usually provides enough reversal so that the respiratory status will be stable.

In addition to treating the spasticity after surgery, it is also very important to have adequate analgesia because the benzodiazepines have no analgesic effect. Morphine is a very old opiate that is hard to beat for effectiveness and has very few complications and other drug interactions. Morphine can be used very safely in children with all levels of CP. Morphine should be given through a slow intravenous drip, which is safe and effective. If there are appropriate monitors, such as in the intensive care unit, then giving morphine intravenously at a higher rate is also a good alternative. Morphine may be given safely subcutaneously, which allows for good absorption. Morphine is given in the same dose for all routes, whether it is given by rapid intravenous push, by intravenous drip, or by subcutaneous injection. For children over age 7 years who are cognitively able, the morphine may be administered by patient-controlled analgesia machines. The use of patient-controlled administration (PCA) with the standing diazepam dose can keep a patient very comfortable. Usually, we give a dose of 1 mg every 10 minutes for a child who is over 20 kg in weight, 1.5 mg for a child over 30 kg, and 2 mg for an adolescent over 50 kg. The maximum 4-hour lock-out is set between 0.3 and 0.4 mg/kg. Although PCA has been reported to be safe in general pediatric populations,^{29–32} there are no reports of its use in children with CP. The use of an additional continuous infusion of morphine is not helpful in adolescents undergoing musculoskeletal surgery,³³ and we have not found a need for its use. There are no reports on using PCA by a parent to administer morphine, and we have not used PCA in this manner because we are concerned about the safety. Based on verbal communication, we are aware that some pediatric facilities have found parent-administered PCA to be safe and effective.

After the acute postoperative pain has been managed and the child is feeding, we favor the use of codeine combined with acetaminophen as an oral analgesic. This combination is available as an elixir and in tablets with either 15 mg codeine (Tylenol 2), 30 mg codeine (Tylenol 3), or 45 mg codeine (Tylenol 4). The number 3 tablet is most commonly used. This drug combination is effective, safe, and has few side effects except for constipation. Other options for oral pain medications include nonsteroidal antiinflammatories (NSAIDs) such as ibuprofen or naproxen, or the synthetic opioids such as propoxyphene or oxycodone hydrochloride. Both these latter two are also available in formulations with acetaminophen and are marketed as Darvaset and Percoset. These synthetic opioids have some occasional antiepileptic drug interactions.

Other drugs that surgeons will either have frequent contact with or whose use they should be aware of include drugs used to treat behavioral problems. Mood stabilizers are often used in children with CP and mental retardation. The most common of these include Tegretol, Depakote, and the

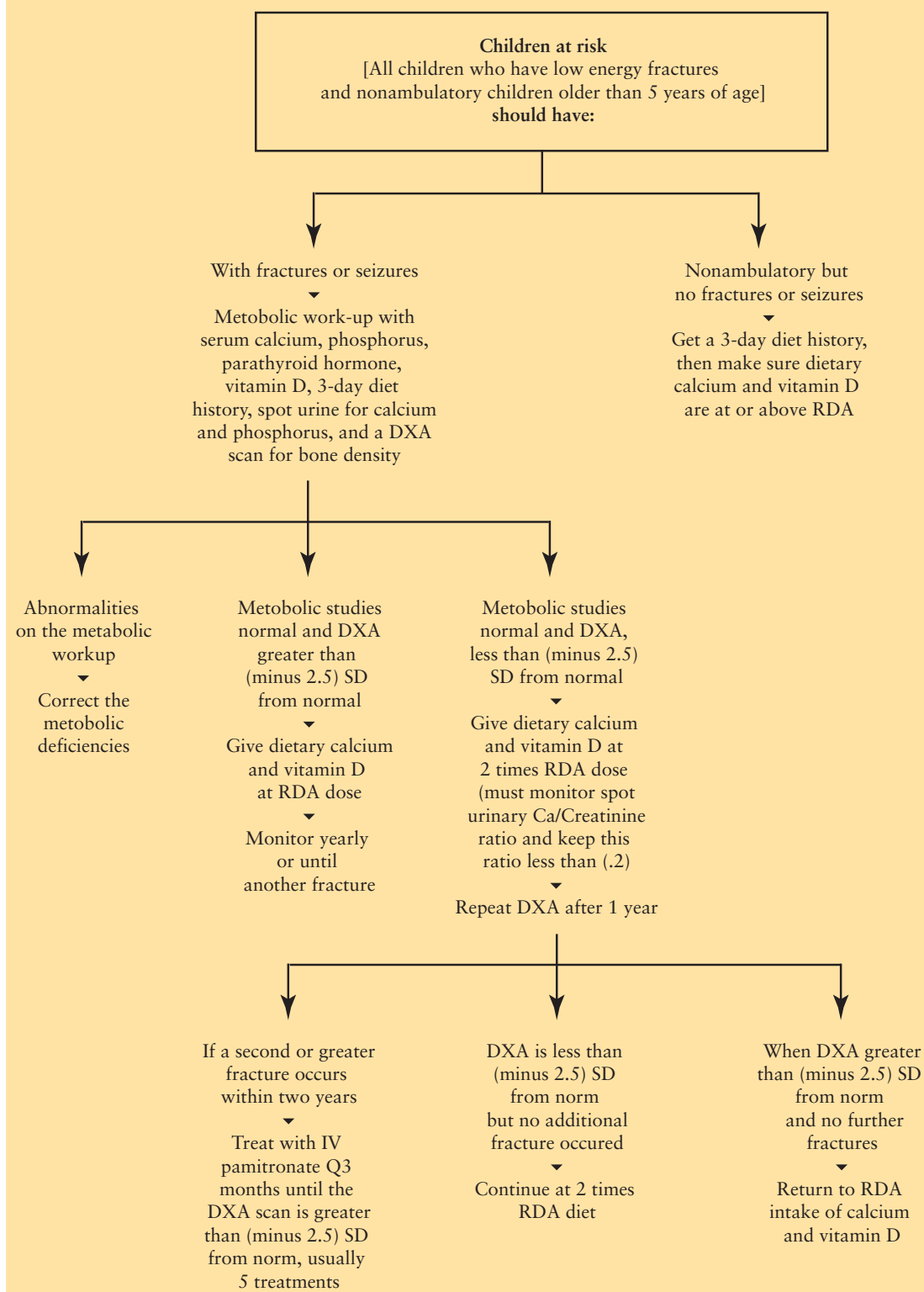
benzodiazepines, and they have the same effects and problems as those used for seizure treatment. Buspirone hydrochloride (Buspar) is being used more commonly in this group of patients as well. Buspar has very few side effects and is mostly used for behavior control and as an antianxiety agent. Stimulants are used very commonly in pediatrics for attention deficit disorder, with the most common drugs being amphetamine (Benedrine), dextro-amphetamine (Dexedrine), and methylphenidate hydrochloride (Ritalin). These drugs have no significant recognized side effects or drug interactions that might cause problems during or after surgical treatment. The drugs can be held until the child is recovering, but after the child is taking a normal diet, they should be restarted. The hyperactivity for which these drugs are prescribed will be well controlled with the use of high-dose diazepam, which is typically used in the immediate postoperative period.

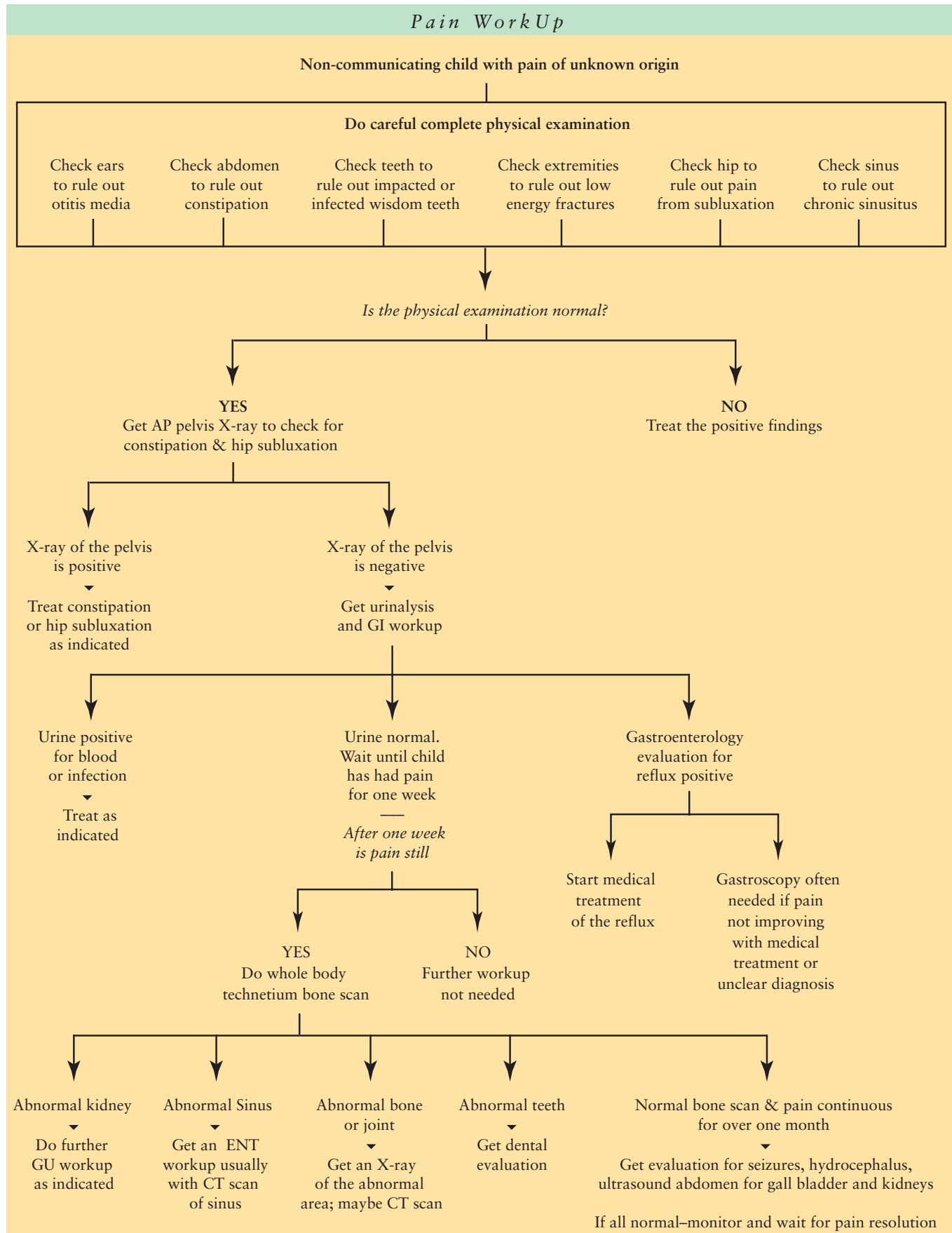
A new treatment for children with severe mental retardation and self-injurious behavior, such as head banging or self-biting, is naltrexone. Naltrexone hydrochloride is an opiate agonist similar to Narcane (naloxone hydrochloride), which competitively blocks the opioid receptors. If these children need significant pain medication, such as for an acute fracture, they need to be treated with an NSAID such as ibuprofen or naproxen. For more severe pain, Ketorolac (tromethamine) injections are the only injectable NSAID available. In this event, the naltrexone hydrochloride should be discontinued so opioids can also be used.^{34, 35}

Ketogenic Diet for Seizure Control

A very old treatment for seizures that has seen a great resurgence is the use of the ketogenic diet. The ketogenic diet is a very rigid diet in which the individual gets all her calories from proteins or fats, completely avoiding carbohydrates. This treatment has a well-documented efficacy that is similar to the best pharmacologic treatment.^{36–38} The exact mechanism by which the ketogenic diet works to prevent seizures is not well recognized; however, the presence of ketones in the blood is important. Usually, the diet is maintained for 2 years, during which time the antiepileptics are reduced or eliminated. The diet is difficult for some children to tolerate and for some families to maintain; therefore, there is a substantial dropout rate. During the time the child is on the ketogenic diet, she may need surgery, such as hip muscle lengthening, hip reconstruction, or scoliosis correction. There is no published literature on doing surgery in children being treated with the ketogenic diet. We operated on eight children, including spinal fusions and hip surgery, during the time they were on the ketogenic diet. It is mandatory that all drugs used while the child is on the ketogenic diet are completely free of carbohydrate carriers, which are very common, especially in elixir preparations.³⁹ During anesthesia and immediately postoperatively, the blood glucose needs to be monitored so it does not drop dangerously low. For children having a posterior spinal fusion, central venous hyperalimentation can be prepared, which will maintain the ketogenic state of the child and provide sufficient calories. We have had one postoperative spinal infection that we were able to manage successfully and clear the infection without hardware removal while the child was on the ketogenic diet. It is very important that the nursing service has good education and assistance from dietitians for direction on what the child may and may not eat. Managing a child on the ketogenic diet also requires the active participation of a pharmacist who is aware of all the ingredients of all medications and can give direction concerning specific drug preparations with reference to the presence of carbohydrates.

Osteoporosis Treatment in Children with CP





References

1. Stevenson RD. Use of segmental measures to estimate stature in children with cerebral palsy. *Arch Pediatr Adolesc Med* 1995;149:658–62.
2. Stevenson RD, Hayes RP, Cater LV, Blackman JA. Clinical correlates of linear growth in children with cerebral palsy. *Dev Med Child Neurol* 1994;36:135–42.
3. Miller F, Koreska J. Height measurement of patients with neuromuscular disease and contractures. *Dev Med Child Neurol* 1992;34:55–60.
4. Stallings VA, Charney EB, Davies JC, Cronk CE. Nutrition-related growth failure of children with quadriplegic cerebral palsy [see comments]. *Dev Med Child Neurol* 1993;35:126–38.
5. Galas-Zgorzalewicz B, Borysewicz-Lewicka M, Zgorzalewicz M, Borowicz-Andrzejewska E. The effect of chronic carbamazepine, valproic acid and phenytoin medication on the periodontal condition of epileptic children and adolescents. *Funct Neurol* 1996;11:187–93.
6. Nielsen LA. Plaque and gingivitis in children with cerebral palsy: relation to CP—diagnosis, mental and motor handicap. *Tandlaegernes Tidsskr* 1990;5:316–20.
7. Frost HM. Bone “mass” and the “mechanostat”: a proposal. *Anat Rec* 1987;219:1–9.
8. Frost HM. The role of changes in mechanical usage set points in the pathogenesis of osteoporosis. *J Bone Miner Res* 1992;7:253–61.
9. Schultheis L. The mechanical control system of bone in weightless spaceflight and in aging. *Exp Gerontol* 1991;26:203–14.
10. Chad KE, Bailey DA, McKay HA, Zello GA, Snyder RE. The effect of a weight-bearing physical activity program on bone mineral content and estimated volumetric density in children with spastic cerebral palsy. *J Pediatr* 1999;135:115–7.
11. Brunner R, Doderlein L. Pathological fractures in patients with cerebral palsy [comment]. *J Pediatr Orthop B* 1996;5:232–8.
12. Jekovec-Vrhovsek M, Kocijancic A, Prezelj J. Effect of vitamin D and calcium on bone mineral density in children with CP and epilepsy in full-time care. *Dev Med Child Neurol* 2000;42:403–5.
13. Lee JJ, Lyne ED, Kleerekoper M, Logan MS, Belfi RA. Disorders of bone metabolism in severely handicapped children and young adults. *Clin Orthop* 1989;297–302.
14. Matthews SJ, Versfeld GA. Rickets in cerebral palsied children: a report of two cases. *J Pediatr Orthop* 1986;6:717–20.
15. Shaw NJ, White CP, Fraser WD, Rosenbloom L. Osteopenia in cerebral palsy. *Arch Dis Child* 1994;71:235–8.
16. Duncan B, Barton LL, Lloyd J, Marks-Katz M. Dietary considerations in osteopenia in tube-fed nonambulatory children with cerebral palsy. *Clin Pediatr (Phila)* 1999;38:133–7.
17. Haas RH, Dixon SD, Sartoris DJ, Hennessy MJ. Osteopenia in Rett syndrome. *J Pediatr* 1997;131:771–4.
18. Sheth RD, Wesolowski CA, Jacob JC, et al. Effect of carbamazepine and valproate on bone mineral density [see comments]. *J Pediatr* 1995;127:256–62.
19. Klimenko VA, Dudin MG, Danilova NA, Lapchenkov VN. [Role of hormonal factors in the regulation of bone tissue metabolism in children with cerebral palsy]. *Ortop Travmatol Protez* 1991; 37–41.
20. Lee JJ, Lyne ED. Pathologic fractures in severely handicapped children and young adults. *J Pediatr Orthop* 1990;10:497–500.
21. Henderson RC, Lin PP, Greene WB. Bone-mineral density in children and adolescents who have spastic cerebral palsy. *J Bone Joint Surg [Am]* 1995;77:1671–81.
22. Harcke HT, Taylor A, Bachrach S, Miller F, Henderson RC. Lateral femoral scan: an alternative method for assessing bone mineral density in children with cerebral palsy. *Pediatr Radiol* 1998;28:241–6.
23. Brumsen C, Hamdy NA, Papapoulos SE. Long-term effects of bisphosphonates on the growing skeleton. Studies of young patients with severe osteoporosis. *Medicine (Baltim)* 1997;76:266–83.
24. Roy C, Silverman A, Alagille D. *Pediatric Gastroenterology*. St. Louis: Mosby, 1995.

25. Edelmann CM. *Pediatric Kidney Disease*, Vol. II. Boston: Little, Brown, 1995.
26. Brenn BR, Brislin RP, Rose JB. Epidural analgesia in children with cerebral palsy. *Can J Anaesth* 1998;45:1156–61.
27. Nolan J, Chalkiadis GA, Low J, Olesch CA, Brown TC. Anaesthesia and pain management in cerebral palsy. *Anaesthesia* 2000;55:32–41.
28. Reiss S, Aman MG. *Psychotropic Medications and Developmental Disabilities: The International Consensus Handbook*. Columbus, OH: The Ohio State Nisonger Center, 1998.
29. Arms DM, Smith JT, Osteyee J, Gartrell A. Postoperative epidural analgesia for pediatric spine surgery. *Orthopedics* 1998;21:539–44.
30. Ellis JA, Blouin R, Lockett J. Patient-controlled analgesia: optimizing the experience. *Clin Nurs Res* 1999;8:283–94.
31. Walson PD, Graves PS, Mortensen ME, Kern RA, Torch MA. Patient-controlled versus conventional analgesia for postsurgical pain relief in adolescents. *Dev Pharmacol Ther* 1992;19:32–9.
32. Weldon BC, Connor M, White PF. Pediatric PCA: the role of concurrent opioid infusions and nurse-controlled analgesia. *Clin J Pain* 1993;9:26–33.
33. McNeely JK, Trentadue NC. Comparison of patient-controlled analgesia with and without nighttime morphine infusion following lower extremity surgery in children. *J Pain Symptom Manag* 1997;13:268–73.
34. Aman MG, Langworthy KS. Pharmacotherapy for hyperactivity in children with autism and other pervasive developmental disorders. *J Autism Dev Disord* 2000;30:451–9.
35. Chabane N, Leboyer M, Mouren-Simeoni MC. Opiate antagonists in children and adolescents. *Eur Child Adolesc Psychiatry* 2000;9:144–50.
36. Freeman JM, Vining EP, Pillas DJ, Pyzik PL, Casey JC, Kelly LM. The efficacy of the ketogenic diet—1998: a prospective evaluation of intervention in 150 children. *Pediatrics* 1998;102:1358–63.
37. Kinsman SL, Vining EP, Quaskey SA, Mellits D, Freeman JM. Efficacy of the ketogenic diet for intractable seizure disorders: review of 58 cases. *Epilepsia* 1992;33:1132–6.
38. Schwartz RM, Boyes S, Aynsley-Green A. Metabolic effects of three ketogenic diets in the treatment of severe epilepsy. *Dev Med Child Neurol* 1989;31:152–60.
39. Feldstein TJ. Carbohydrate and alcohol content of 200 oral liquid medications for use in patients receiving ketogenic diets. *Pediatrics* 1996;97:506–11.

Neurologic Control of the Musculoskeletal System

Children with cerebral palsy (CP) have a large variety of motor impairments, all of which are secondary to the encephalopathy. These impairments, which directly emanate from the encephalopathy and the disability that results, are well recognized as specific problems; however, the pathophysiology connecting the encephalopathy to the impairment and the disability is not well defined. The treatment goal of children with CP is to allow them to function in their environment, ideally the larger society, to the best of their abilities. These children continue to have CP, and the changes made by the medical treatment are directed at decreasing these disabilities by altering the secondary impairments. To alter the impairments in ways that decrease the disability requires that the interaction of different impairments in a given individual must be well understood. An understanding of the neurologic control of motor activity is required to place a construct around these impairments.

Controlling the Motor System

One of the most basic functions of living organisms is the ability to control and move the body in space. After cognitive and reasoning abilities, motor function is what most defines an individual as a human being. There are wide variations of motor function in which some individuals, such as athletes, focus most of their activity on motor skills and others focus more of their attention on cognitive skills. However, even individuals such as writers who are primarily engaged in cognitive activity still depend on motor function to relate and transmit their cognitive achievements. In children with CP, loss of motor function is a major part of the disability. Motor function involves almost all tasks of living including speech, swallowing, upper extremity function, and all mobility. It is helpful to have some conceptual construct of how control of the motor system works to develop treatment strategies.

A common framework for understanding motor control is learning the anatomic structure and function of each part of the nervous system. Most physicians will remember this approach from their medical school classes. This system is too complex to yield an understanding of how the neurologic system really controls motion in a way that can be applied usefully to treat a child. This anatomically based approach aids understanding the difference between spinal cord injury and brain injury in a few children. This approach also helps explain the difference between hemiplegic and diplegic pattern CP involvement. With the anatomic approach, the nervous system can be divided into central and peripheral. The central structures include the spinal

cord and brain, and the peripheral system includes the peripheral motor, sensory nerves, muscles, bones, and joints.

Anatomic Motor Control Structure

Central Motor System

Cerebral palsy, by definition, requires that the pathologic lesion be in the brain. Therefore, the spinal cord presumably does not have a primary lesion, although there are children in whom this may not be true. The control of motion is either volitional or automatic. Most activities are volitional; however, reflex responses, such as withdrawal after accidentally touching a hot stove, are automatic responses. This type of automatic response occurs as a relatively simple neuronal reflex at the spinal cord level. All volitional motion initiates in the cerebral cortex and is transmitted to the peripheral motor nerves through the cortical spinal tracts traversing the internal capsule and the spinal cord. These transmissions are not simple commands but are highly modulated based on inputs from many other areas. The components that make up the basal ganglion are extremely important modulators of motion. The cerebellum also monitors sensory input and further modulates motion, especially smoothing the motion pattern. The relative function of each of these structures has been somewhat defined by classic lesioning experiments in animals and close observation of naturally occurring lesions in humans.^{1, 2} The very complex modulation occurring in the brain is not well understood in a way that can help explain the problems in children with CP. Some problems of movement disorders have specific patterns that can be linked to specific problems in the basal ganglion³; however, even these are usually complex and not focal isolated lesions (Figure 4.1). The spinal cord is not only a series of connecting ascending and descending tracts like a telephone cable, but it also has a very important modulating layer of interconnecting neurons in the motor control system. Some of these interconnections are modulated by descending tracts and others are modulated by interconnections within the spinal cord. For example, when the plantar flexors are stimulated to contract during the simple Achilles tendon reflex, another interconnection in the spinal cord suppresses function of the dorsiflexors, causing them to remain quiet. The specific role of these rather simple connections in complex activities such as walking is not well defined, and the pathologic role of these reflexes in CP is even more difficult to understand.

Peripheral Motor Control

The peripheral motor system includes the nerves and musculoskeletal system. The peripheral motor nerves carry the impulses that cause muscles to contract and the sensory nerves carry this information to the central system. The sensory information includes tendon tension, muscle length, joint position, and cutaneous sensation. In children with CP, there is no primary lesion in any of these peripheral systems; however, the effects of the central pathology cause these systems to develop in abnormal ways. These abnormal changes, such as lack of muscle growth, in the peripheral motor system can be positively affected. These secondary responses to the primary central nervous system defect are the cause of many problems in children with CP.

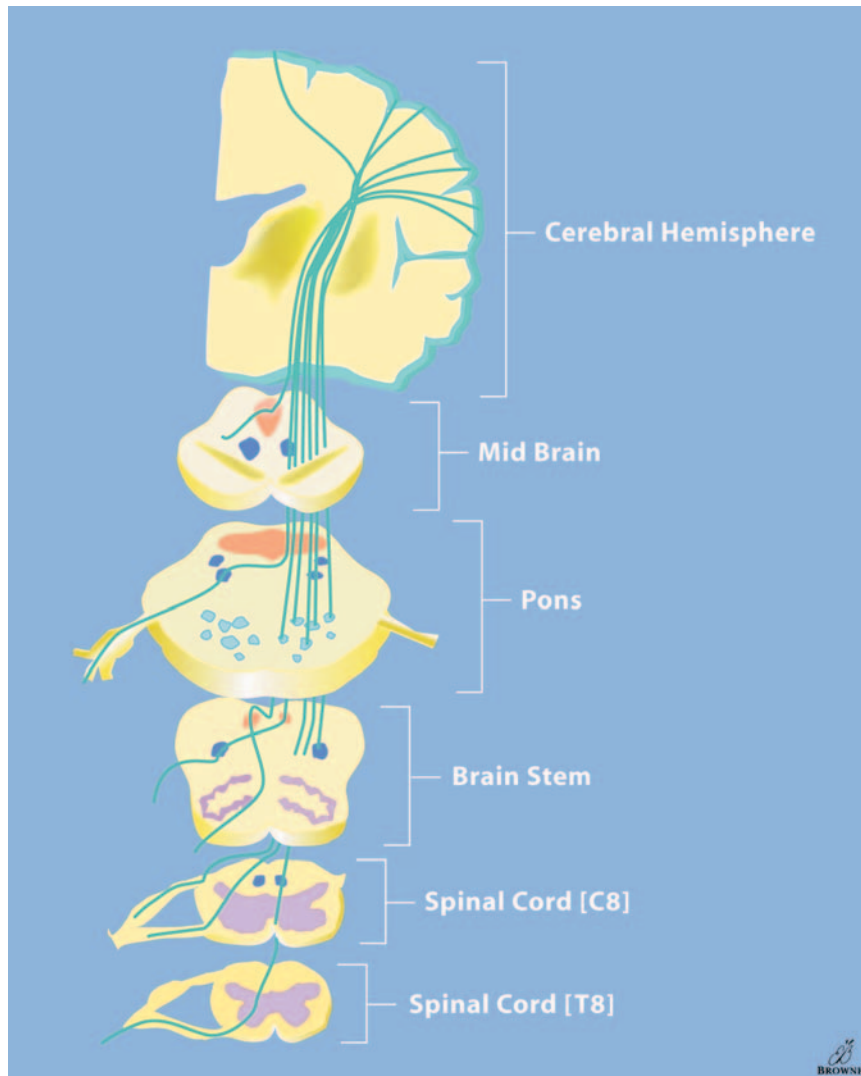


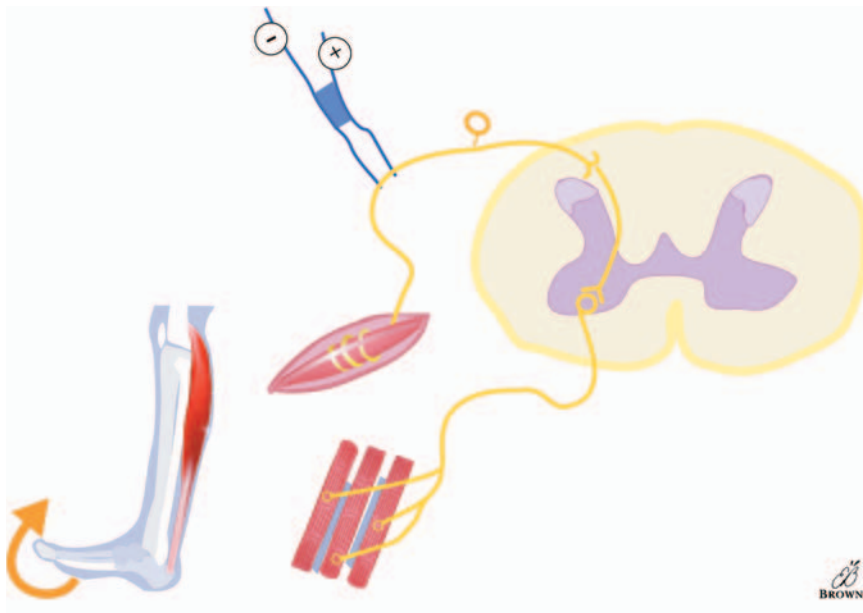
Figure 4.1. Although the cerebral spinal tracts transmit information from the cerebral cortex to the peripheral muscles to cause motion, there are many modulating influences especially from the basal ganglion, cerebellum, and spinal cord. These modulating influences are not well defined as to the specific changes that occur in children after different brain lesions.

Development of the Anatomic Structure

Central Nervous System

The early development of the central nervous system begins with the neural tube structure, which folds and then is followed by development of the anterior part of the brain. By 9 to 17 weeks of gestation, interconnections from the brain to the muscles have developed and the fetus is beginning to make flexor movements. By 18 to 30 weeks, extension movements are routinely seen.¹ By the time the baby is born, she has vigorous kicking and sucking movements and hand and toe grasp. During this time, the anatomic synapses are undergoing considerable remodeling, which is best understood in the development of sight where external light stimulation is needed to develop a normal central neurologic system. The role of external musculoskeletal movement on the maturation of the central nervous system is unknown. Maturation of the central nervous system motor skills, especially in areas such as balance and the ability to learn complex motor skills, are not complete until middle childhood.

Figure 4.2. The H-reflex is initiated by low-level electrical stimulation of the afferent muscle spinal fiber in the same muscle. The H-reflex has the same pathway as the stretch reflex and causes a contraction in the same muscle that was stimulated; however, it is easier to control the timing and quantity of the stimulation.



Peripheral Motor System

The peripheral motor system has some primitive function by the ninth week of gestation; however, at birth this system is a long way from being mature. The nerve conduction velocity at birth is 28.5 m/s and by adulthood it reaches 82 m/s. However, because of the large amount of length growth, the H-reflex at the ankle still goes from 15 seconds at birth to 28 seconds at adulthood, even though there is increased velocity (Figure 4.2). Also, skeletal muscle fiber types change to a more mature mix and the whole system has to increase greatly in size. Abnormalities in this growth and development will be considered when the specific pathologic patterns are evaluated.

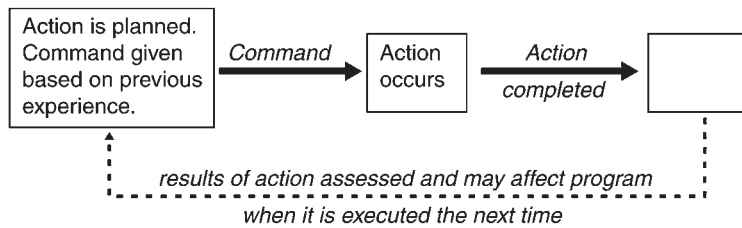
Controller Mechanisms and Theory

As was already noted, it is quite easy to understand the concept of simple nerve reflexes, such as the knee reflex; however, this concept has not led to an understanding of how the central nervous system controls human gait. New understanding of ways to conceptualize the neuromotor control come from computer sciences and mathematics. The role of these theories, and the benefit they provide, is in helping to place the function of a child with CP in a context that can be understood clinically as the child is growing and continuing with neurologic maturation.

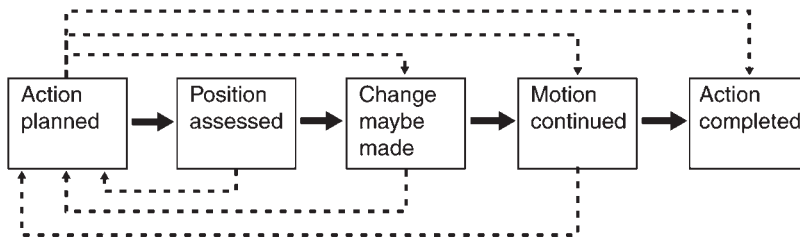
Sensory System Feedback Versus Feed-Forward Control

To conceptualize how the central nervous system controls motor function, a framework of what is possible needs to be considered. Either the system can alter function in response to the sensory information it receives, or it can cause a motion and then learn what has occurred from the sensory feedback system. Constantly changing the motor instructions based on sensory feedback is called feedback control, and ordering a muscle activity and then receiving the effect of that activity from a sensory perspective is called feed-forward control. These two models are important aspects of control theory

Feed-Forward Control



Feedback Control



BROWNE

Figure 4.3. Feedback control depends on constant sensory input, which directly modulates the action in progress. Feed-forward control uses the sensory information to learn and calculate how much muscle activity is needed to make a specific movement occur. The sensory feedback cannot alter the activity in progress but is added to the learning progress for the next activity cycle.

to understand how sensory information is processed and incorporated (Figure 4.3). Other terms that are very similar are closed-loop control, which is almost the same as feedback control. Open-loop control means there is no control once the activity is initiated, which is slightly different from feed-forward control in which a delayed reaction can cause impact on the activity. Firing a bullet from a gun is open-loop control because the shooter has no ability to impact the path of the bullet after it is fired.

Another example of this concept is demonstrated best by the control system present in driving a car or firing a rocket. The control primarily used in driving a car is feedback control in which the driver, when going around a corner, will steer into the corner and constantly correct the turn based on sensory feedback received of how the car is progressing. With this type of control, if the car is going too far to the left, the driver turns more to the right and if the car is going too far to the right, the driver turns back to the left. In this way, the activity of driving around the corner can be accomplished with minimal prior experience and knowledge about the specific corner; appropriate adjustments are made as the task progresses. Launching a rocket is an example of feed-forward control in which the engineer knows where the rocket is to go, then calculates a trajectory. From the knowledge of the trajectory, and the rocket's weight, a calculation of how much fuel is needed and the angle of launch can be made. After all the calculations are completed, a program is given to the rocket's engines. Then, when the rocket is started, it will execute this program to follow the predetermined course based on the programmed engine thrust and angle of launch. There is minimal feedback or ability to change directions 2 seconds after launch if it is determined that the rocket is going in the wrong direction. There is, however, usually the ability to explode the rocket if it is perceived to be going off target. This rocket launch is an example of feed-forward control.

Neurologic control uses both feed-forward and feedback control. An example of feed forward is jumping, where a determination is made similar to a rocket launch in which the brain calculates the amount of muscle force needed and then orders the muscles to contract, generating the required force. Many aspects of walking are feed forward in pattern, although this is

less clear at times. Feedback systems are predominantly used for activities with which one has little experience and wants to make changes as the activity is progressing, such as drawing a picture or painting. Many functions probably contain some mix of feed-forward and feedback control.

Understanding feedback mechanisms is somewhat difficult, especially because the concept of muscles is that they are either activated or not activated. Based on the understanding of neural anatomy, all feedback is similar to the knee reflex where the threshold of sensory of stimulus is reached and a fixed contraction occurs. However, staying with this concept makes it difficult to understand how complex feedback would work as feedback is experienced in a much more controlled response than the single synapse reflex. From the area of computer engineering, this feedback can be conceptualized in terms described as fuzzy feedback. This description uses a mathematical concept of fuzzy logic based on graded response options.⁴ When a stimulus is received, the response does not need to be all or none, but is chosen rather from a gradation of options; for example, five options of muscle activation. These options might be a maximum contraction, a moderate contraction, an average contraction, a low contraction, or no response. Although it is hard to relate this type of fuzzy control directly to the neuroanatomy, it is functionally a better conceptual model to understand feedback control in the motor system than the all-on or all-off concept that simple neuroanatomy would suggest. This fuzzy control, or rheostatic-type control, is developed through the multiple levels of modulation and with many muscle fibers in each muscle. Variable whole-muscle activation can be obtained by firing varying numbers of muscle fibers.

Controller Options: Maturation Theory

In considering neurologic control theory, motor activities that most people experience in daily life can be understood in a simplistic way similar to the function of a computer. In this context, it seems natural to think about the computer as a model for the nervous system. For example, in this model the hardware is the anatomic structure in which a software program is placed. Using this analogy, the software program for the brain is called a motor engram² or a central program generator (CPG).¹ The term central program generator is used here because it is more descriptive of the motor control concept. The CPG would be equivalent to a word processing program, which has complex but fixed responses to all inputs. Some of these responses are direct, such as the keyboard response occurring when a specific key is pushed and commanding the word processing program to place a specific letter where indicated. Other instructions are more complex responses, such as a predetermined series of steps when a macro in the word processing program is executed. Using the analogy of the computer in understanding motor control, it is also presumed that most of these movement responses are remembered by either the genetic encoding of a motion, such as sucking or stepping, or are developed through a learning response, such as learning to ride a bicycle. The CPG is developed in a process of maturation by a combination of genetic encoding and direct learning. This understanding of the function of the CPG is called the maturation theory of motor control.¹

Controller Options: Dynamic Systems Theory

The concept of dynamic systems self-organization has arisen from many disciplines of natural science, and has more recently been applied to understanding human motor control. An example of this application of dynamic

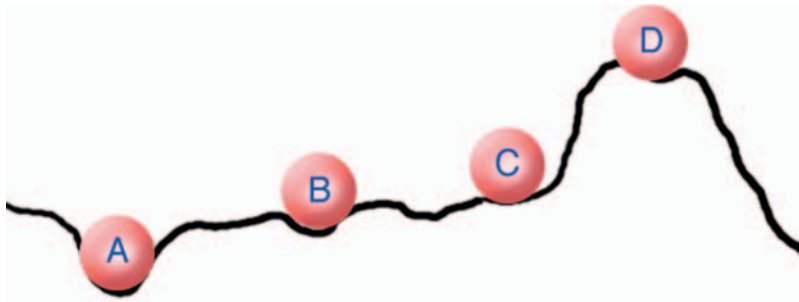


Figure 4.4. The concept of chaotic attractors is easy to visualize as a landscape over which a ball is rolled. There may be many areas where the ball could stop and be stable; however, a relatively small force would dislodge the ball and start it rolling again. There are a few deeper valleys in which the ball might roll and require a lot of force to start it rolling again. Each of these landscape depressions simulates a chaotic attractor of varying strengths.

systems theory is the understanding of the flow of fluids, such as the flow of a river or the flow of fluids through a pipeline. As the speed and pressure of the liquid flow changes, the flow pattern reorganizes itself from a smooth laminar flow where the center of the water column has the highest velocity to the slowest velocity at the periphery, which is in contact with the immobile walls. At some point, this flow reorganizes into turbulence. This turbulence looks totally disorganized; however, in dynamic theory, it has reorganized itself into another control system, which is responding to demands placed on the structure. This changing state from nonturbulent to turbulent is highly nonlinear and is a transition from one state to another, both of which are stable.

Understanding this kind of system reorganization required the development of a new branch of mathematics called chaos theory.⁵ In chaos, there are attractors, which are defined as regions or states that are stable or relatively stable (Figure 4.4). For example, there is a rapid transition in fluid flow between turbulent and nonturbulent flow. The fluid does not like to remain a mix of the two states; in other words, the fluid is attracted to one state or the other with varying strengths. This concept of attractors can be used to understand motor control. An example in human gait is walking speed, in which not all velocities have equal preference from standing to maximum running. The chaotic attractor of normal adult walking velocity tends to be strong, between 100 and 160 cm/s. If a person cannot walk close to 100 cm/s, they will often walk at a comfortable speed, then stop and wait for a while, then walk at a natural speed, then stop again. Standing and not moving is another velocity attractor. On the other hand, if an individual has to go faster than 160 cm/s, they typically break into a running gait pattern with a preferred comfortable speed between 250 and 300 cm/s. For speeds around 200 cm/s, most individuals alternate between running and walking because these speeds are more comfortable than trying to stay at an in-between level of not quite walking and not quite running comfortably. Most adults experience and respond to these velocity attractors by altering their speed to be in one of the three stated gait patterns.

Another feature of these attractors is that they may be very stable or somewhat unstable. An example of an unstable attractor is the body position taken in the middle of a jump. This position is an unstable attractor because the body cannot stay this way for long before it has to move to the next attractor, which is the response for landing. Understanding and defining these attractors in motor control can be very helpful in understanding response to growth and development as well as responses to treatment. To clarify the understanding, the term chaotic attractors is used in the remaining text to define these attractors, although the more classic mathematical term used in chaos theory is strange attractors.⁵ In medicine, the area where chaotic theory has been applied most is in understanding variability of heart rate.

This principle is demonstrated especially well by the change from a variable heart rhythm to ventricular fibrillation. These two states of heart rhythms are both stable because they are not easily changed without significant external force.

The concept of dynamic systems theory for motor control also aids understanding of how individuals end up doing similar tasks with variable but similar patterns. For example, if a walking child is asked to pick a cookie up off the floor, the pattern used likely will be either predominantly bending at the hip and spine with the knees straight, or flexing the hips and knees keeping the spine straight. With all the muscle and joints available, there are almost endless variations of how a task can be accomplished; however, there is a chaotic attractor toward two or three patterns of motion to accomplish a given task.

The Cause of Chaotic Attractors

Understanding the anatomic or mechanical origin of these chaotic attractors is very difficult, and based on chaos theory, there are too many variable inputs to the system to specifically define these attractors; therefore, they are usually defined as a region. For example, a chaotic attractor draws normal human walking velocity to a relatively stable attractor of around 100 to 160 cm/s. The strength and definition of this attractor are related to the length and mass of the legs, the speed of muscle contraction, the speed of nerve conduction, and the environment. It is impossible to define the exact center of this chaotic attractor because it is based on many things, from the environment to the individual's behavior and mood. Using this concept of dynamic systems theory, a framework exists for understanding why different movement patterns develop in children with CP. For example, children with diplegic pattern involvement frequently develop a crouched gait at adolescence. Depending on what treatment is chosen, the child may continue in the crouched pattern or may revert to a back-kneeing pattern. This gait change is an example of the chaotic attractor organizing the child's motion. The important thing for the surgeon to understand is that the system does not want to organize around normal knee extension, which is the physician's treatment goal.

Another important concept arising from dynamic systems theory is that the control system is self-organizing and there is no need for a CPG or genetic encoding or learning. The example from physics is that the fluid does not need genes, learning, or software to decide to reorganize from turbulent to nonturbulent flow. Another area where dynamic systems theory is widely used is in understanding weather patterns. The weather patterns organize systems, such as high-pressure areas with sunny days or severe storms, in patterns that can be explained with dynamic systems theory, again all without learning, genetic code, or software programs. This organization develops around chaotic attractors, each of which can be characterized somewhat; however, all the inputs and impacts to define this attractor cannot be described. Because dynamic systems theory requires no encoding program, such as a CPG, it is directly opposed to the maturation theory of motor control. Reports of the ability of mechanical robots to self-organize around movement patterns and studies with animals suggest that dynamic theory has some basis as an organizational structure of motor control.¹

A Unified Theory of Motor Control

The goal of having a concept of motor control is to help in treatment of children with motor control problems, and perhaps to develop a conceptual

context to test theories in an experimental format. There is a need to combine both the maturation and dynamic systems theories. One way of combining them is to separate the functions of the motor control system into subsystems. There is a subsystem for balance that includes the sensory feedback areas, another system for controlling muscle tone, and a third system for motor pattern control. Other aspects of these subsystems might include sight, oral motor function, and hearing. The three defined subsystems having the most direct impact on the motor systems related to the musculoskeletal system are our focus, although sight is clearly a very important aspect of motor control by providing feedback to the motor control system.

With each of these subsystems, there is a basic level of organization programmed by genetic encoding and learning. Above some level of basic function, dynamic systems theory best explains actions. Some of the patterns coming out of dynamic systems theory may be further refined through learning, especially activities that depend heavily on feed-forward control. An example is an athlete's activity, such as learning to broad jump. After middle childhood, with a fully mature neurologic system, maturation to execute the concept of jumping has developed. When a child is asked to jump as far as she can, the natural general pattern, which is probably determined by dynamic control organizing the activity around the chaotic attractor or series of attractors that are not very stable, will be used. However, if the individual wants to become a champion broad jumper, they must work on a specific pattern and be able to execute this pattern consistently within a very narrow range. This part of the activity now becomes a maturation activity around defining a specific CPG, which helps to explain why the basic pattern is seen, but also allows for refinement. Also, much more energy is required to change the basic pattern than to refine the current pattern.

When considering individual pathologic problems, the neurologic aspects of the motor impairments can be separated into abnormalities of the three subsystems of motor control. These subsystems are muscle tone, motor planning, and balance. The variety of abnormalities in these three subsystems leads to almost all the motor problems in children with CP. Some children have impairments in only one area, such as a spastic gastrocnemius in child with a hemiplegic pattern involvement. Others, such as children with severe quadriplegic pattern involvement, have significant abnormalities in all three subsystems.

Disorders of Muscle Tone

Muscle tone is defined as the stiffness of the muscles or the limb as one tries to passively move the limb. This stiffness has a spring characteristic, which is stiffer with small movements than with large movements and is defined as a nonlinear response to movement.⁶ The exact origin of this tone comes from the passive stiffness emanating from the shape of the soft-tissue envelope, friction in the joint and soft tissue, and may also have an undefined active neuronal element. In studies using the leg drop test, a difference has been seen between an awake and alert child compared with the same child under neuromotor blockade anesthesia. In normal individuals there is less muscle tone under anesthesia than when they are awake, which strongly suggests that there is an active stiffness in the muscle that is not due to contraction induced by the motor neuron, as this stiffness is occurring with a silent electromyogram (EMG) (Miller et al., unpublished data, 2001).

In addition to nonlinear passive and active spring stiffness, tone in the limb also has a component of viscoelastic dampening, which is velocity-dependent

resistance to movement. This dampening effect works very similar to a shock absorber in a car. The dampener also has a nonlinear response to varying velocity and position of the limb. The function of the viscous dampener is to provide passive tone in the normal motor system so the movement is smoothed. Muscle tone here is defined as some tension in the muscle while it is not actively contracting. This tone probably provides an important functional factor to the muscle. If the muscle is completely loose, without tension, it would have a slower response and the fine control would be lacking.

Also, there is some undefined important aspect of this tone in allowing the muscle to maintain its strength and to regulate its growth in childhood. A second major aspect of muscle tone is the motion-induced stretch reflex, which is commonly known as the knee or ankle jerk reflex. This is a monosynaptic reflex induced through stretch reception of the receptors in the muscles. The stretch reflex synapse can be modulated to sending from the brainstem and cerebral white matter by the vestibulospinal and reticulospinal pathways.⁷ It is through these spinal pathways that monosynaptic reflexes are modulated through a large variety of experiences, such as changes in the person's mood, environment, and the activity being performed.

Motor Tone

Normal motor tone has many important but poorly defined functions in the control of the motor system. Most of these functions are defined by problems caused when the motor tone is too high or too low. In general, high tone is called spasticity or hypertonicity and low tone is called hypotonia. The classic definition of spasticity typically includes an increased sensitivity of the normal stretch reflex in addition to a velocity-dependent increase in resistance, which initiates a muscle contraction to resist the motion.⁸ This widely reported and often-repeated description of spasticity, which includes the velocity-dependent feature, sounds like a definition of an increase of the viscous dampening of normal muscle tone, but it is not. This description is typically used as another definition of hyperreflexia, which is part of the syndrome. There are no reports documenting that spasticity is related to velocity of angular joint motion in the mechanical sense of the change of the joint angle over time. The term velocity is used in a general way to mean movement. Also, there is a variability to spasticity that has been defined as a clasp-knife, release, and catching characteristic. Spasticity is difficult to explain, and it is not clear if all the characteristics used to describe it are different aspects of the same response or totally different responses occurring in the same muscle. The syndrome of altered muscle tone is extremely easy to recognize but much harder to define. In this way, spasticity is like pornography, which has been described by a supreme court justice as "hard to define but easy to recognize when you see it." Movement patterns, especially dystonia, may be difficult to differentiate from spasticity when the child is seen for only a short time; however, the presence of the secondary changes, especially in the muscle, usually allows the differentiation to be easily made.

Measuring Muscle Tone

Muscle tone is such a basic aspect of motor control that there have to be ways for it to be quantified. The most common method has been the use of the Ashworth scale.⁹ This scale is a manual scale that evaluates resistance to motion of a specific joint; however, it only considers hypertonicity. The scale has been modified to include more levels and to allow assessment of hypo-

Table 4.1. Ashworth scale and modified Ashworth scale.

Ashworth Scale:	
Score	Description of the muscle tone
1	No increase in normal tone
2	Slight increased tone with a catch with rapid joint motion
3	Increased tone but the joint is still easy to move
4	Considerable increase in tone making passive movement difficult
5	Limb is rigid, movement is difficult
Modified Ashworth Scale:	
Score	Description of the muscle tone
00	Hypotonia
0	Normal tone, no increase in tone
1	Slight increase in tone manifested by a slight catch and release or minimal increased resistance to joint range of motion
1+	Slight increase in tone manifested by a slight catch and minimal increased resistance to joint range of motion for more than half the joint range
2	More marked increase of tone through most of the whole joint range, but the affected joint is easily moved
3	Considerable increase in muscle tone; passive movement difficult but possible
4	Affected joint is stiff and cannot be moved


tonia in a scale called the modified Ashworth scale (see Table 4.1). This scale is the most widely used scale for assessing spasticity; however, it is very subjective and at times difficult to separate limb stiffness resulting from muscle stiffness as opposed to the stiffness induced by spasticity.

Other methods for assessing spasticity include the leg drop test in which the leg is allowed to swing over the edge of a table and the oscillations and magnitude of the movement are measured. This test only works in a child with mild to moderate spasticity and requires excellent cooperation from the individual being tested. Many mechanical movement devices have been designed to move and measure the torque generated by the movement as methods for measuring spasticity. None of these systems has gained wide acceptance for clinical use.¹ Many people have tried to record the EMG activity; however, it is impossible to determine any force data from electromyography. Another very old technique is to measure the H-response, which is a nerve potential recorded in the motor neuron that occurs when a sensory nerve in close proximity is stimulated. The amplitude of this H-wave is thought to reflect the excitability of the alpha motor neuron (Figure 4.5). This measurement has been correlated to hyperreflexia, but does not correlate well with the Ashworth scale^{7, 10}; therefore, we still are using the modified Ashworth scale for clinical evaluation of spasticity.

Spasticity

Spasticity is the most common presentation of all neurologic alterations in children with CP. Increased muscle tone expressed as spasticity must be a very strong chaotic attractor to the organization of residual activity in a child with a central neurologic injury. It is very difficult to understand what the components of the system are that make this spasticity such a strong attractor. Because it has persisted in humans but is seldom seen in animals, this

Figure 4.5. The effect of spasticity on the growth and development of skeletal muscle results in a muscle that has fewer muscle fibers, shorter fiber length, and a longer tendon. This aberration results in a muscle that is weaker because of decreased cross-sectional area and has less excursion, resulting in decreased joint range of motion because of the shorter fiber lengths.



suggests that there is a functional benefit to spasticity. Even though spasticity is a strong chaotic attractor, any judgment about its benefit or harm to an individual cannot be made. From modern robotic research, it is known that adding stiffness to joints helps improve fine motor control; and also everyone has experienced a tendency to stiffen when wanting to do very fine delicate movements with their hands. It seems most conceivable that, on the whole, when the neurologic system loses some function but its organization still has the ability, muscle tone will increase to allow function with a lower degree of neurologic control. Therefore, when treating children with spasticity, the basic supposition is that muscle tone is good and the amount of muscle tone should be modulated for their maximum benefit.

Effects of Spasticity on Nerves

Because the lesion in CP is central, all other more distal changes are presumed to be secondary. The best recognized change in spasticity is hyperreflexia, which occurs because of a decreased inhibition from the cortical spinal tracts. As a normal child grows, the rate of muscle contraction and the ability to increase power by cerebral cortex modulation continues to increase until the child is approximately 10 years old.¹ Although this change has been well documented by studying the ability of increased rapid alternating movements in children and adults,¹¹ it is not clear where these changes occur. In CP, this more immature pattern of slow corticospinal and pyramidal tract potentials persists.¹ There is an increased latency and a decreased ability to recruit large numbers of motor fibers at the same time.¹² Some of this activity is modulated through changes in the excitability of the spinal motor neurons, which are also sensitive to joint position or, probably more specifically, muscle length. The strength of the ankle reflex is very sensitive to ankle joint position as measured by the H-reflex, which is initiated through stimulation of a peripheral sensory nerve. This change is much greater than can be explained by mechanical positioning.¹ As noted earlier,

there has to be some tension in the muscle while the muscle is at rest for it to function properly. Some of this tension seems to disappear when the individual is under neuromotor blockade anesthesia. It has been postulated that active neuronal stimulation is required to maintain this muscle tone¹; however, no direct evidence of this has been found. It is this element of increased neurologic stimulation not generating an active EMG that seems to increase most when tone increases in CP. Because many of these children also demonstrate abnormalities in temperature regulation and blood flow in the extremities, some regulatory abnormality in the sympathetic nervous system may be involved. At this time, however, there is no direct evidence to support this theory.

Effects of Spasticity on Muscles and Tendons

Hypertonia and hypotonia have the most dramatic secondary effects on the muscle. The well-observed effects of spasticity on skeletal muscle include decreased longitudinal growth of the muscle fiber length, decreased volume of the muscle, change in motor unit size, and change in the fiber type and neuromotor junction type. In the mouse model, the spasticity causes loss of approximately 50% of the longitudinal growth of the muscle fiber, resulting in contractures.¹³ Muscles in children with CP are always very thin in addition to being short, which means that these muscles are also weak, as a muscle's strength is related to its cross-sectional area. Understanding strength has been an extremely confusing topic in spastic muscle evaluation. The mechanical definition of strength is defined by how much load a structure can support. When discussing strength of a limb, such as the strength of plantar flexion at the ankle, the strongest ankle tends to have a severe fixed flexion contracture, but this is not the strength for which most clinicians are looking. Usually, the term strength is used to describe the ability to move a load or to do work, which is called active strength, whereas the contracture is a passive strength. By creating a significant contracture, the spastic muscle has great passive strength but low active strength compared with normal muscles. Active strength is altered more in spastic children because of the difficulty of avoiding co-contraction, as there is less antagonist inhibition in spasticity. Motor units tend to get larger and have slower responses with longer latency periods combined with a large shift to the slow-twitch type 1 fibers.^{12, 14} All these changes mean the muscle responds slower during contraction, and combined with the changes in the nerve, has a longer latency period. Children with spasticity were recently found to be resistant to succinylcholine, and on further investigation, it was found that the neuromotor junction contains immature subunits. The effects of spasticity on skeletal muscle are pervasive and often experienced by neuro-orthopaedists; however, a physiologic explanation of how increased tone causes all these changes is still unknown.

There is a grave need for basic research and understanding of muscle response to spasticity. In a major textbook containing 1936 pages of descriptions related to muscle embryology, physiology, and muscle diseases, not one mention of the impact of spasticity on muscle was found.¹⁵ Yet, surely more people have myopathic changes secondary to spasticity than all the other primary muscle diseases combined. In the context of dynamic control theory, these changes seem to be revolving around a strong, stable attractor whose basic factor seems to be a damaged motor control system, which is slowing the response time, stiffening the system, and providing passive strength in the face of absent active strength. This stable chaotic attractor may also be organizing around the functional benefit of the organism, which

can now support weight in stance and is able to move in space, although at a slower rate than normal. Although there are no good detailed explanations at this time from the maturation perspective of exactly what determines these changes, they all make sense in the dynamic control model. The major problem of this chaotic attractor is that it seems too stable and there is an over-reaction in many children, with the changes in themselves becoming functionally limiting and causing problems.

Effects of Spasticity on Bones

Changes in the bones caused by spasticity are modulated by muscular changes. The most common effects are dislocated hips; scoliosis; foot deformities, such as planovalgus feet or equinovarus feet; bunions; knee contractures; and elbow, shoulder, and wrist joint contractures. Torsional malalignments of the femur and tibia are common as well. A major part of this text discusses the management of these deformities. These secondary deformities, such as dislocated hips, have been very well defined and have clear mechanical etiologies.¹⁶ These deformities all have clear and strong pulls to develop toward easily understood chaotic attractors. In the hip, on one side the muscle will become contracted causing adduction, and on the other side, it will become contracted in abduction. Therefore, both hyperadduction and hyperabduction are stable attractors. With a decreased level of fine motor control and spasticity, the neutral position of the hip is not a stable region. This concept also applies to other affected joints.

Functional Effects of Spasticity on Sitting, Gait, and Activities of Daily Living

There are many functional effects of spasticity, some of which help children and some of which cause major problems. For children who are ambulatory, the spasticity causes typical spastic gait patterns. These gait patterns are discussed in Chapter 7. Children who are able to do minimal weight bearing for transfers or household ambulation are often greatly aided in these activities by the spasticity, which provides the strength and stability for weight bearing. These same children may have problems relaxing in seating positions and therefore are difficult to seat. They may also have so much spasticity that activities of daily living, such as dressing and toileting, are difficult. Each child requires a careful assessment of the specific problems and benefits caused by the spasticity. There is a tendency for family members and some clinicians to equate the spasticity to CP. It is often difficult for them to see the benefits provided by the spasticity.

Treatments

When planning for treatment of the spasticity, the benefits and problems should be carefully considered. Everyone must realize that no matter how successful the treatment of the spasticity is, the child will still have CP. It should always be kept in mind that the goal in treating spasticity is to never remove all muscle tone. It is much better to conceptualize spasticity treatment similar to treating hypertension. Clearly, the treatment of hypertension would not be successful if all the blood pressure were removed. There is considerable similarity between no blood pressure and no muscle tone. The ideal treatment of spasticity would be a situation where the tone is decreased only at the time and in the anatomic area when and where it causes problems. The spasticity would then be preserved in all situations in which it is helping the

child. It is also important to remember that some of the secondary effects in the muscle noted above may also have direct effects from the primary lesion. For example, the strength of a muscle contraction is mediated by the cerebral cortex impulse. Therefore, in a child with CP, this ability to modulate strength may be a primary deficiency due to the brain lesion. After the child has been evaluated with an assessment of the specific benefits and problems of spasticity, available treatment options should be considered.

The treatment of muscle tone may be applied at different locations in the neuromuscular system. Treatment options start in the central nervous system with the use of medications, electrical stimulation, or surgical ablation. In the peripheral nervous system to the level of the muscle, medication and ablation are the main choices. At the muscle level, medication, electrical stimulation, or surgical lengthening are the treatment options.

Oral Medication Affecting the Central Nervous System

Oral medication treatments tend to impact both the spinal cord and brain where gamma-aminobutyric acid (GABA) receptors are the main inhibitory receptors of the motor control system (Table 4.2). The two major drugs are diazepam and baclofen. Both these drugs block GABA at the main point of action. Baclofen is an analog of GABA and binds to the receptors but does not activate GABA. The activity of diazepam is more diffuse. Baclofen has poor absorption across the blood–brain barrier. Both drugs have a very high rate of accommodation, meaning they are effective initially but lose their effectiveness over several weeks. This accommodation effect can be overcome with larger doses; however, the use of higher doses makes the complication rate higher. The use of both these drugs orally for chronic control

Table 4.2. Spasticity medications.

Drug	Trade names	Benefit for spasticity	Side effects
Baclofen	Lioresal	Useful in some patient groups; in CP seldom has a lasting benefit when given orally, but very effective by intrathecal administration	Causes sedation, sudden withdrawal, psychosis; rapid drug tolerance develops in the oral doses
Diazepam	Valium	Very useful for acute postoperative spasticity management, little use for chronic management Oldest effective antispasticity drug	Has long and somewhat variable half-life, very sedating; tolerance develops with chronic use
Chlorazepate	Tranxene	Little use in CP; is an active metabolite of diazepam; may have less sedation but no other demonstrated benefit for spasticity management	Same as diazepam
Clonazepam	Klonopin, Rivotril	Has a quick absorption and an 18-hour half-life; may also be less sedating than diazepam; is useful for single-dose nighttime treatment of complaint-related sleep difficulty due to spasms	Same problem of drug tolerance as diazepam
Ketazolam	Loftran	New shorter-acting benzodiazepine, no CP data	Claimed to have less sedation
Tetrazepam	Myolastin	New drug, no CP data	Claimed to be less sedating
Dantrolene	Dantrium	Works by decreasing muscle fiber excitability; has no effective use in children with CP	Is hepatotoxic so liver enzymes must be monitored; causes muscle weakness
Tizanidine	Zanaflex, Sirdalud	Blocks the release of neuroexcitatory amino acids; no CP data; personal experience is that there is rapid tolerance, similar to baclofen	Causes dry mouth, sedating; may cause drop in blood pressure
Clonidine	Catapres, Dixirit, Catapresan	Blocks alpha-agonist activity in the brainstem and spinal cord; no data in CP spasticity	Causes a drop in blood pressure and heart rate
Cannabis	Cesamet, Marinol	Effective to reduce adult spasticity but no data in children	Significant psychotropic effects and is addictive
Cyclobenzapine	Flexeril	Widely used to treat back muscle spasm, but studies have shown no effect on spasticity	Not indicated because it is not effective

of spasticity has not been successful in children with CP. The acute use of diazepam in the postoperative period is very useful and safe. Alpha-2-adrenergic receptors have primarily agonist function in the spinal and supraspinal regions. Tizanidine and clonidine hydrochloride are drugs that block these receptors. Although there is some evidence that this type of drug is effective in decreasing spasticity of spinal cord origin,¹⁷ their use in children with CP has little or no experience and no published data. Personal experience with tizanidine suggests that it has very similar problems as the other oral antispasticity medications, which are a significant rate of sedation and a high accommodation effect. Other drugs acting at other sites in the central nervous system have the potential for decreasing spasticity. There are only incidental reports of use of these drugs and no documentation of their use in children with CP. Blockade of voltage-sensitive sodium channels can be done with lamotrigine and riluzole. Serotonin antagonists such as cyproheptadine decrease tone. Glycine is an inhibitory neurotransmitter that can be given orally and is absorbed by the brain. Cannabis has been shown to decrease spasticity through an unknown mediator.¹⁸

Intrathecal Medication Administration

Over the past 20 years, an interest in administering medication directly into the intrathecal space, especially in the spinal canal, has developed. Because there is a general perception that spasticity originates in the spinal segments, a high dose of drug concentrated in this region of the nervous system should be given. This route was initially developed to administer morphine¹⁹ but was quickly applied to administer baclofen.²⁰ The intrathecal pump is battery powered and implanted in the abdomen, and an intrathecal catheter is introduced into the intrathecal space in the spine. This catheter is tunneled subcutaneously around the lateral side of the trunk to the anterior implanted pump site and connected to the pump. The pump is controlled with an external radiowave-mediated controller, and the pump reservoir is filled by direct injection through the overlying skin (Case 4.1). The primary medication used to manage spasticity by intrathecal pump administration is baclofen. The administration may be continuous, or the pump can be programmed to have higher doses over a short time, then be turned off for a period of time, and go to lower doses.

The use of intrathecal administration of baclofen is very new, having only been approved by the FDA for use in children in 1997. At the time of approval, there were fewer than 200 children with implanted pumps. In the past 4 years, these pumps have become much more common. These pumps have the great advantage of being adjustable and can be discontinued if the results are not thought to be worth the trouble. Usually, a careful assessment with a listing of the caretakers' concerns is made. If the child has not had a spinal fusion, a trial dose may be done with 75 to 100 mg injected as a bolus dose in the epidural space. Then the child is monitored by caretakers and the medical team and a joint decision is made as to the benefits. For especially difficult cases, an indwelling catheter, which can be left in place for several days, may be used so the dose can be adjusted. This implanted catheter is used for children with greatly variable tone, or individuals in whom adjustable doses of baclofen are to be monitored.

The initial recommendation was to do a series of three injections on consecutive days starting with 25 mg, then 50 mg, then 100 mg on the third day.²¹ We have not found this algorithm very useful and prefer to give 75 to 100 mg or use the inserted catheter.²² Children either respond or do not respond, and the small dose differences in the prior recommendation add little to understanding their effect. Also, the recommendation that children be tried



Case 4.1 Letrisha

Letrisha, an 8-year-old girl with severe spastic quadriplegia and mental retardation, was totally dependent for all care needs. Her mother's complaint was that she had difficulty with diapering, dressing, and bathing her. Sometime she did severe extensor posturing that made seating difficult. She slept well, was fed by gastrostomy tube, and had seizures several times a day, which were felt to be in good control for her, and weighed 16.7 kg. A baclofen trial was given with 75 μg injection of baclofen, which provided excellent relief of the spasticity. A pump was then inserted with good spasticity relief. (Figure C4.1.1, C4.1.2). Over 6 months, she continued to have rapid accommodation to the drug; however, a plateau dose of 650 μg was reached that continued to control her spasticity. After having the pump for a year, her mother still noted that diapering was difficult because of contractures of the hip adductors. She then had an open adductor tenotomy. She had little body fat and the pump was prominent on her abdomen but caused no problems (Figure C4.1.3).

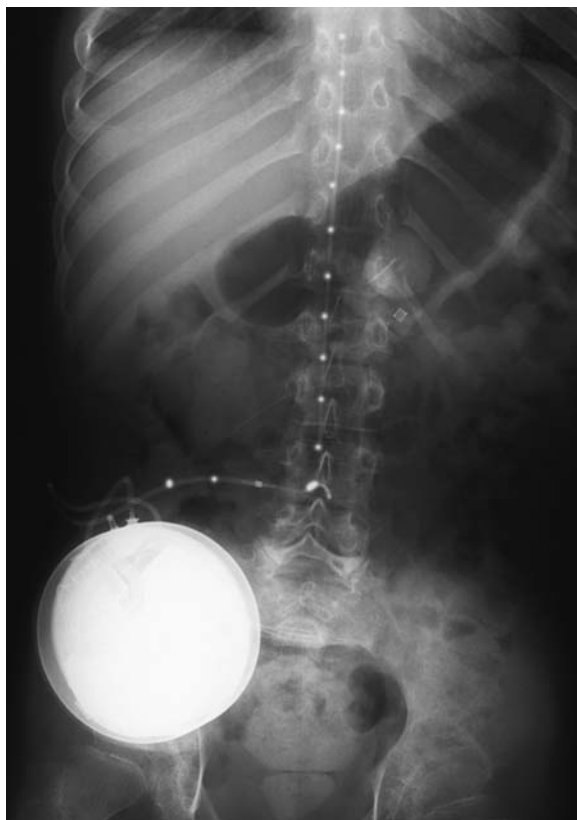

Figure C4.1.1

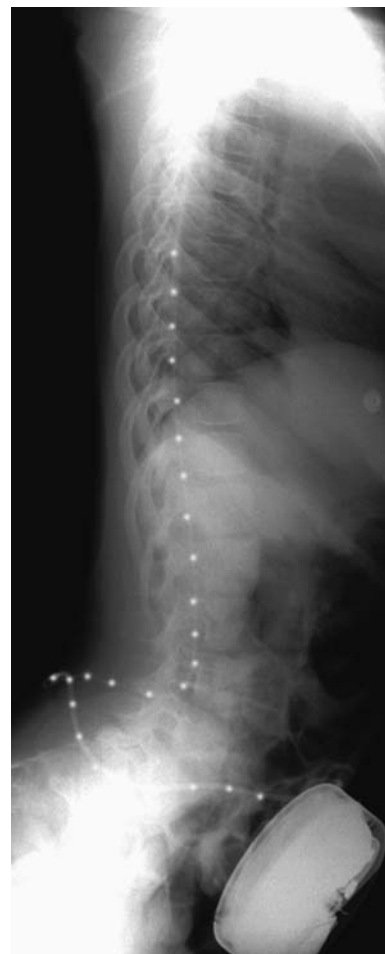

Figure C4.1.2

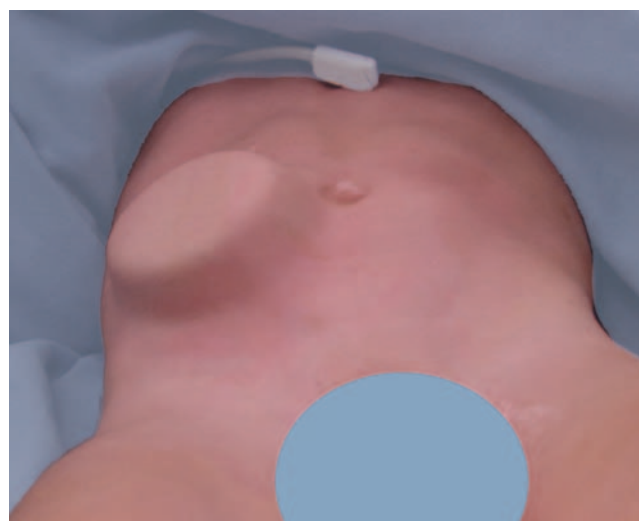


Figure C4.1.3

on oral baclofen²¹ has little merit, as there are no data suggesting that it is helpful in children with CP. Our experience has been that oral baclofen is almost never of any benefit. The algorithm our colleagues and we use for intrathecal baclofen is to do a clinical evaluation, followed by one injection trial, then implant the pump and adjust the dose to the child's needs. We never use the small 10-ml pump because it is only minimally smaller than the 18-ml pump but has a capacity that is almost 50% less. This capacity becomes very significant when the child requires a high dose of baclofen, such as 1000 mg per day. If the 10-ml pump is used, it must be filled every 20 days if the 2000 mg/ml concentration for baclofen is used. This type of dose is not uncommon, and the size of the child is in no way related to their baclofen needs.

The outcome of administering baclofen via intrathecal pump is a clear reduction in spasticity in most children. After the initial implantation, it may take 3 to 6 months before a constant level of drug that will keep the spasticity decreased is found. The drug accommodation effect is well known in the oral use of baclofen and happens with intrathecal dosing as well; however, when a certain dose is reached, this accommodation effect no longer occurs. The required dosing for individual children varies greatly and is not related to body size. The dose requirements vary from 100 mg to 2000 mg per day. The correct dosing can be determined only by slowly increasing the dose and evaluating the effect on the child. After spasticity reduction has been accomplished, the functional gains are extremely variable, with the clearest gains occurring in children with quadriplegic pattern involvement based on subjective reports from caretakers. These caretakers report improved ease of dressing and other activities of daily living.^{23, 24} Improved sleeping has been noted in many of our patients, as well as behavior improvements. Improved sitting and upper extremity use is also reported by families.^{25, 26} All these functional gains are subjective reports that usually make the families very happy with the device. The use of intrathecal administration of baclofen in ambulatory children has very minimal experience and is used mostly in older children with severe gait disturbances.^{26, 27} To date, none of these reports has included any quantitative gait evaluation. Our experience as well as the experience reported to us from a few other laboratories suggest that children's speed is not changed much; there may be some increased range of motion at the knee, but there is a tendency to drift into more of a crouched position. All these results are based on isolated cases and are very dependent on the dosing amount.

Complications with the use of the intrathecal pump vary; however, the rate is significant. Incidence of infection has been reported as between 0% and 25%.^{23, 25, 28} Mechanical catheter problems have been reported as well, including catheter breakage, disconnections, and kinking.^{20, 23, 25} Pump pocket effusion and persistent cerebrospinal fluid (CSF) leakage have also been reported.²⁵ The acute withdrawal of baclofen, if it is given either intrathecally or orally, may cause children to have hallucinations and acute psychosis.²⁹ The complications of the baclofen pump are generally easy to treat and do not have permanent consequences. Most infections that involve the pump require that the pump be removed and the infection cleared; then the pump can be reinserted. We have been able to treat an infection in one child without removing the pump, and there is one report in the literature where intrathecal vancomycin hydrochloride was used and the pump was saved.³⁰

An important technical detail that will avoid wound problems over the pump in thin children is to make sure the incision used to insert the pump is very proximal so none of the scar resides over the pump or catheter after implantation. This means that the incision to insert the pump may be at the level of the lower ribs. All wound problems we have encountered have been

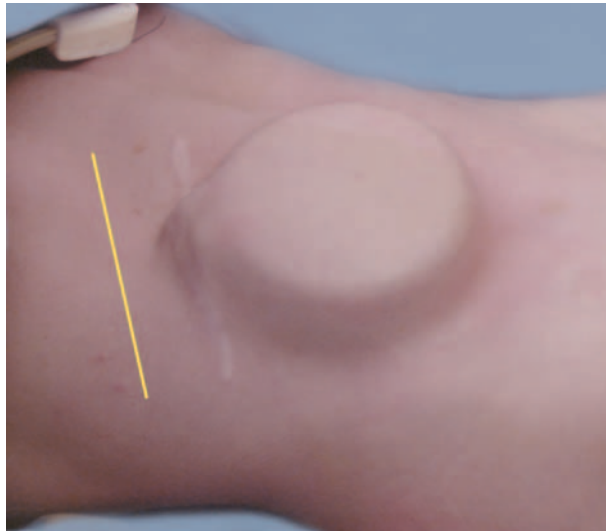


Figure 4.6. The incision for the baclofen pump should be higher than the expected placement site of the pump. When the incision runs across the connectors of the pump, as shown in this picture, there is a higher risk of wound breakdown. Ideally the incision should be well away from the pump pocket, as shown by the *yellow line*.

in cases where the incision ended crossing the underlying pump, usually at the junction where the catheter inserts into the pump (Figure 4.6). Inserting the pump under the external oblique fascia is another option that will help with soft-tissue coverage. The major problem with catheter complications is diagnosing the problem. Sometimes children are not responding as expected, or suddenly stop responding, to the baclofen. If this occurs, there may be a possible catheter problem. The first study should be a radiograph to evaluate the catheter. Sometimes the radiograph will be able to visualize catheter discontinuity. If the pump inserted has a side port for catheter injection, an attempt can be made to aspirate from the catheter, or inject a radiopaque material, and get a radiograph. We almost never use this pump in children because it is too prominent. The pump can be emptied and injected with indium and then scanned after the indium is calculated to have reached the spinal fluid. If this is not positive and there is a serious concern, the child should be taken back to the operating room, the anterior catheter pump connection exposed, and the catheter removed. It should now be possible to obtain CSF from the catheter. If not, the posterior catheter has to be exposed, disconnected, and whichever section is not patent should be replaced.

Another complication that may occur is in a child who maintains a CSF leak after insertion of the catheter. The initial treatment is to leave the child in a supine position for up to 2 weeks to see if this leak resolves. The primary symptom from this CSF leak is a severe headache and nausea. Most of the time the leak stops. We had two children who continued to leak. One of these children had a posterior spinal fusion in which the fusion mass had been opened. This wound again was opened, and the fascia was placed over the dura with closure of the bone defect with methyl methacrylate. If an opening in the fusion mass is done to insert the catheter, the bone defect is now routinely closed with cranioplast. If the child has not had a spinal fusion, an epidural blood patch may be tried. This patch works well if a leak occurs following a trial injection; however, it has not been successful in stopping leaks around inserted catheters. In this situation, the insertion site may also need to be exposed and the catheter insertion site covered with a fascial patch.

If there is a sudden malfunction of the implanted pump, it will stop functioning instead of pumping too much. This safety feature of the pump has not been reported to fail. In this circumstance, if there is a question of pump

function, the pump needs to be replaced. The battery that powers the pump has an implanted life ranging from 3 to 5 years. When the battery loses power, the whole pump has to be replaced. The catheter does not need to be replaced. If there is any question as to whether a child's pump is functioning or there is a catheter malfunction, the child should be placed on oral baclofen to prevent the withdrawal psychosis that occurs in some children. Baclofen also has an antihypertensive effect³¹; however, this is seldom a significant problem. There may be a sympathetic blockade-type effect decreasing the overreacting peripheral basal motor response that creates blue feet when the feet get cold.³²

Another well-documented effect of baclofen in rats is a decrease in the number and frequency of penile erections.^{33, 34} There is one report involving adult males with spinal cord injury-induced spasticity treated with intrathecal baclofen. In this report, a significant number of men reported a decreased time and rigidity of erections, and two men reported losing the ability to ejaculate.³⁵ One of our patients was a young man whose main complaint with intrathecal baclofen was a decreased quality of his erection and a prolonged latency period between erections. This complication should be mentioned to patients for whom it might be a concern.

A small group of children require a very high dose of intrathecal baclofen, sometimes 2000 to 3000 mg per day. Also, some children who are on a lower dose suddenly need increased doses if their spasticity is increasing 6 months to 2 years after the implantation. If a child has had an increasing need for baclofen, or is requiring a sudden increase in baclofen after having been stable, catheter malfunction should be considered. After the full workup for catheter malfunction, or after demonstration that the catheter is functioning, another option for dosing is to use a drug holiday. In this treatment, the intrathecal baclofen is reduced and then slowly decreased to zero to avoid a withdrawal psychosis. The pump may be left in the turned-off position for 1 month and then the drug slowly reintroduced. This drug holiday should allow the nervous system to redevelop a sensitivity to the drug. Another way to use this concept of a drug holiday is to give large intrathecal boluses several times a day instead of continuous dosing. Therefore, instead of giving a continuous dosing rate of 2000 mg, the child may be given 1000 mg just before bedtime, and then another 1000 mg over a 30-minute period the first thing in the morning. These different dosing regimens may provide a better benefit in some children compared with continuous administration.

The current role of intrathecal baclofen in the treatment of children with severe spasticity is primarily in nonambulatory children. From a theoretical standpoint, this treatment should also be ideal for the 3- to 8-year-old spastic ambulatory child for whom a rhizotomy could be considered. The size of the pump and the need for long-term maintenance, with filling at least every 3 months, has made it difficult to convince parents and physicians that this is a good treatment option. Also, there are no objective published data that allow one to develop confidence. This question would be an excellent project for a well-controlled study similar to the randomized rhizotomy studies.^{36, 37} The other problem is the current pump has very poor design features, such as having a very superficial catheter connection site, making it a site for skin pressure, and the pump is much more bulky than is really necessary. As better engineered pumps are designed and medication that has more stability is found, so that the pump only needs to be filled every 6 months to 1 year, the intrathecal pump will become an even better option, especially for high-functioning children. Also, there are other medications that may be even better choices than baclofen; however, each of these needs to be trialed and tested in children with spasticity.

Rhizotomy

Central nervous system surgical approaches to reducing spasticity are most commonly done at the spinal cord level, with posterior dorsal rhizotomy being the most widely used procedure. This procedure involves cutting the dorsal sensory nerve rootlets, which contain the afferent sensory nerves, from the muscle spindles as well as other sensory nerves. By using peripheral motor stimulation and recording the electrical activity in the proximal sensory nerves, abnormal rootlets are identified and then sectioned. Many rootlets are not quite normal or not very abnormal, which makes choosing the abnormal ones very subjective. Evidence exists that there is no difference between selective nerve sectioning based on electrical stimulation and just random sectioning.³⁸⁻⁴⁰ Also, the number of rootlets that are cut is very important, so there usually must be a decision on what percentage of the rootlets will be sectioned based on the child's general level of spasticity. The operative procedure may be done as popularized by Peacock et al.,⁴¹ in which laminectomies are done from L1 to L5 and the rootlets identified at each level where they exit. The other technique, advocated by Fazano et al.,⁴² consists of a laminectomy only performed at T12 and L1; then the rootlets are separated just below the conus (Figure 4.7). There is no apparent difference between outcomes of the two procedures based on published reports; however, the Peacock technique is more popular in North America. Cervical

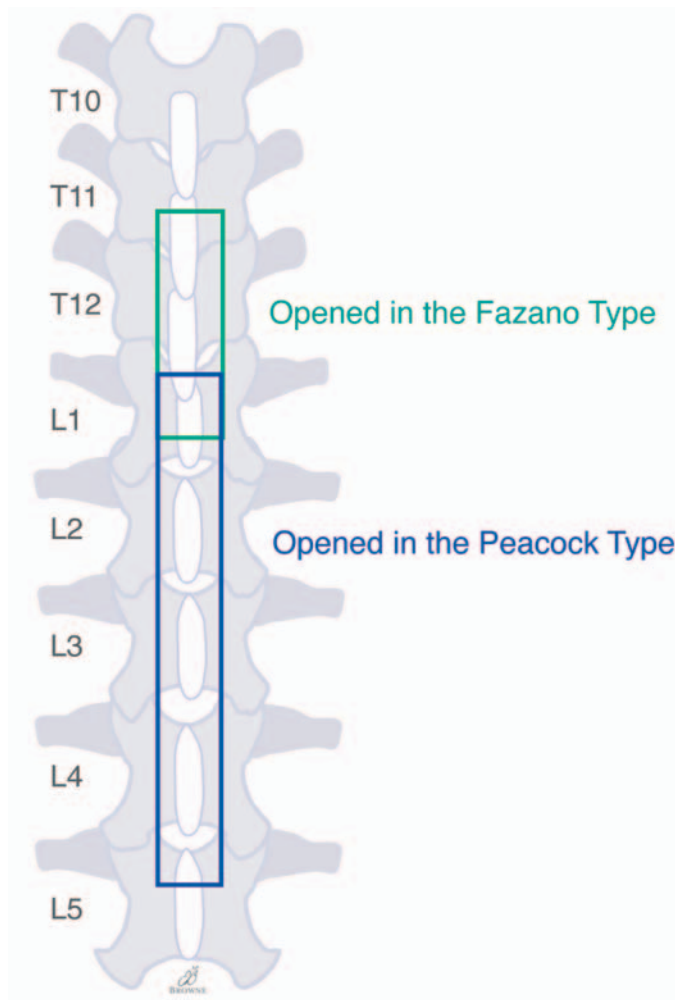


Figure 4.7. The Fazano technique involves doing only a T12–L1 laminectomy in which the rootlets are separated at the end of the conus. This exposure may lead to thoracolumbar kyphosis as a late spinal deformity. The Peacock approach involves a laminectomy from L1 to L5 with separation of the rootlets as they exit the spinal canal. The long-term spinal deformity, which occurs as a consequence of the Peacock technique, is progressive lumbar lordosis.

rhizotomy has also been promoted by some authors,^{43–45} but has never become popular except for in a few isolated centers. Rhizotomy has been described for 100 years, and has had a series of advocates and periods of popularity, but has never developed a stable level of acceptance in medical practice.

Outcome of Rhizotomy

Since the modern popularization of rhizotomy by Fazano and Peacock in the 1980s, there have been many reports in the literature of its use in children with CP. A search at the time of this writing revealed 111 citations, the majority reporting small, individual surgeon's experiences. There seems to be a universal agreement that spasticity is reduced acutely after the dorsal rhizotomy procedure. There are no studies with good follow-up to maturity; all the long-term studies consider 5 to 10 years as long term.^{46, 47} Most studies report outcomes at 1 to 3 years after the index procedure. Also, the majority of the studies have no controls with respect to other treatments or for the effects of growth and development. There are two well-designed studies that are very short term, 1 year or less, which randomized the children to a physical therapy-only group or a physical therapy and rhizotomy group.^{36, 37} Both these excellent short-term studies confirm the generally well-recognized fact that spasticity is reduced; however, one³⁷ reported no significant functional gains with rhizotomy whereas the other reported some functional gain.³⁶

The net result of these studies is that the functional problems of CP are not all, or maybe not at all, due to spasticity, which most people who work with children with CP have known for a long time.⁴⁸ There is a strong sense among parents and clinicians with little experience managing children with CP that spasticity is the root of all problems for these children during the growth and development period. Therefore, the general feeling is if spasticity were removed, everything would be better, which is the general tone of many articles reporting the outcomes of rhizotomy. There are no direct comparisons of rhizotomy to intrathecal baclofen, except for cost comparison.⁴⁹ One nonrandomized study compared orthopaedic surgery alone with rhizotomy.⁵⁰ Over a follow-up of 1 to 7 years, this study found the improvement in joint range of motion to be equal; however, children made better progress toward independent gait with orthopaedic surgery than with dorsal rhizotomy. Although there may be less need for orthopaedic surgery after a dorsal rhizotomy has been performed, others have shown that there definitely is still significant skeletal deformity occurring throughout development, possibly necessitating more orthopaedic surgery.⁵¹ Also, some new deformities are created, such as lumbar lordosis^{52–55} and a very unpredictable effect on hip subluxation.^{56, 57}

Complications from dorsal rhizotomy may include hip dysplasia and spine deformities including kyphosis, lordosis, spondylolisthesis, and spondylolysis.^{54, 55} This spondylolysis may be related to the postoperative back pain some children develop 6 months or more following rhizotomy.⁵⁸ It has been suggested that laminoplasty instead of laminectomy may be a way of reducing these abnormalities; however, there currently is no evidence that this makes a difference.⁵⁹ We have seen children who have the same problems after laminoplasty as laminectomy (Figure 4.8). Other reported complications following dorsal rhizotomy include heterotopic ossification of the hip if the rhizotomy is done concurrently with hip surgery.⁶⁰ Also, typical postoperative CP complications, such as bronchospasms, urinary retention, ileus, and aspiration pneumonia are reported.⁶¹ Decreased sensation and dysesthesias are also well-recognized problems.^{58, 61} Bowel and bladder dysfunction is related to cutting too many distal nerves and is a well-recognized complication.^{58, 61}

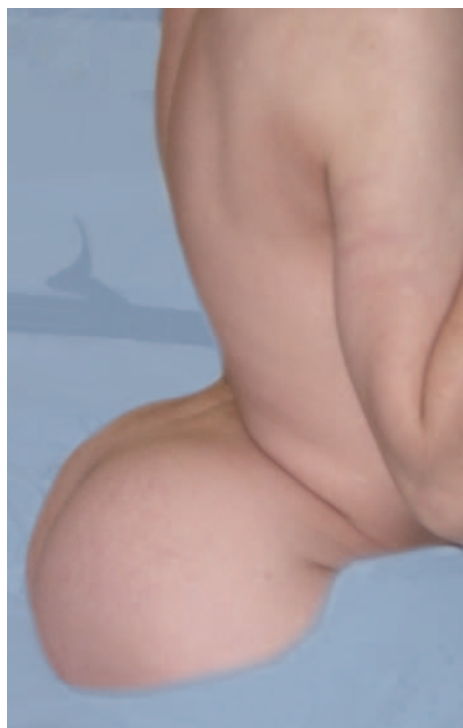

Figure 4.8. This boy had a dorsal rhizotomy with laminoplasty 4 years before this photograph. He did well for several years; however, during his adolescent growth period the lordosis increased rapidly. Over a period of 4 months, he went from having a severe cosmetic lordosis that was not painful to an increase of 30° in his lordosis accompanied by such severe pain that his sitting was limited to several hours a day. This is rather typical of the lordosis associated with rhizotomy.



Case 4.2 Kaitlyn and Hannah



Kaitlyn and Hannah are both 4-year-old girls with diplegia who had been walking independently for 18 months; however, they are unstable and had trouble stopping and standing without holding on or falling to the floor. The mother of Kaitlyn elected to have a dorsal rhizotomy, while the mother of Hannah elected to continue physical therapy for 1 more year and then have femoral derotation and gastrocnemius lengthening. For Kaitlyn, 1 year after the dorsal rhizotomy, she also had femoral derotation, hamstring, and gastrocnemius lengthenings. As these two

girls continue to mature both have done well, although Kaitlyn has had to work to overcome weakness that tended to limit her endurance for long-distance ambulation. As close as we could compare, these girls are very similar as 4-year-olds; however, Hannah, who had only orthopaedic surgery, may have had slightly less spasticity. This is a major problem in choosing the candidates for dorsal rhizotomy. Based on our experience, the child who does very well with a dorsal rhizotomy also does very well with only musculoskeletal surgery.

In summary, dorsal rhizotomy had a large burst of enthusiastic support from approximately 1987 through 1993. During this time, several thousand children had dorsal rhizotomies, and as individuals caring for these children develop more experience over time, and with the publication of two studies^{36, 37} showing marginal functional benefit, the enthusiasm has decreased rapidly. The current general opinion is that there is no significant role for dorsal rhizotomy in children with quadriplegia because the complication rate is too high and the risk of functional loss is too great. Also, in the quadriplegic pattern children, unless almost all the posterior rootlets are cut, much of the spasticity will return. We had to implant baclofen pumps in three children with quadriplegic pattern CP who previously had dorsal rhizotomies and had very significant return of their spasticity 5 to 10 years afterward. In the young child, aged 3 to 8 years, who is a very high functioning diplegic ambulator with no significant muscle contractures or bony deformity, a dorsal rhizotomy can still be considered a reasonable option. However, based on a nonrandomized study⁵⁰ of ambulatory ability, these same children probably will do as well and maybe better with only orthopaedic surgery. It has been our experience that as children grow and develop, gait patterns of those who had orthopaedic surgery are somewhat different than those who had rhizotomy; however, there is no major functional improvement with the rhizotomy. The children with rhizotomy have a gait pattern in which weakness predominates, and the children with orthopaedic surgery have stiffness as the predominating factor (Case 4.2) As yet, there is no real equal comparison with the baclofen pump; however, the advantage in the few cases we have is that the pump can be adjusted to get more or less spasticity based on the clinical assessment of the child's need. With the data currently available, and the improved development of the intrathecal pump, it seems likely that rhizotomy will again become less accepted as a treatment option for spasticity in children with CP.

Electrical Stimulation

Electrical stimulation of the central nervous system to decrease spasticity has a long history both in the brain⁶²⁻⁶⁴ and in the spinal cord.^{65, 66} In spite of the very positive comments in these reports, the unpredictability, high

complication rate, and minimal response have prevented this form of treatment from ever gaining wide acceptance. We have managed three children who had spinal cord stimulators implanted for spasticity control, and none of them has had any recognized benefit after the first several months. The use of implanted central nervous system stimulators for children with CP has enough experience in the community to safely say that it has no role, except in a very well-controlled research environment.

Myelotomy

Myelotomy, which involves cutting the spinal cord longitudinally either in the sagittal or coronal planes, was advocated extensively in the 1970s and 1980s.⁶⁷⁻⁶⁹ However, because of the unpredictable results and high complication rate, myelotomy has been abandoned completely and has no role in the management of children with CP.

Peripheral Nervous System

Another way to decrease spasticity is by intervention at the level of the peripheral nerves. The only options involve lesioning of the nerve, either chemically or by physical transection. This lesioning mainly involves addressing the motor nerves instead of the sensory nerves, which are addressed by a rhizotomy. Chemical lesioning is almost always at least partially reversible. The chemical agents range from short-acting to long-acting local anesthetics, alcohol, and phenol. The use of local anesthetics to block nerve transmission was usually advocated as a way of doing diagnostic tests to see if a child would benefit from a surgical lengthening procedure.^{70, 71} This concept makes little sense today because the blockade of nerves does not affect the contracture, which usually is the major problem to be surgically addressed. With today's modern diagnostic gait laboratories, this type of diagnostic evaluation has little use. In the 1970s, the use of alcohol was also advocated as a diagnostic and therapeutic way to reduce spasticity. Alcohol injections generally provide a decrease in tone for 1 to 3 months.⁷²⁻⁷⁴ Phenol is an even more caustic agent and will destroy the nerve, so the spasticity will stay reduced for 18 to 24 months⁷⁵; however, it is a very painful injection usually done under general anesthesia.⁷⁶ Both alcohol and phenol were very popular in the 1970s and into the early 1980s. Because of the toxic nature of these drugs and because the injections were painful, general anesthesia was required. With the availability of botulinum, there is only a rare role for their use to manage spasticity today. The use generally is in cases of botulinum immunity in which there are no other reasonable options (Case 4.3).

Direct surgical ablation of the motor nerve also has a long history as a means of reducing spasticity. Sectioning of the obturator nerve to decrease adductor spasticity at the hip is the most common indication.⁷⁷⁻⁷⁹ In general, this procedure should be done only in nonambulatory children, and then only the anterior branch of the obturator nerve should be sectioned. Anterior branch obturator neurectomy is typically done in adolescents with severe adductor spasticity, or in younger children with severe hip dysplasia in whom an attempt is being made to reduce the hip and allow the dysplasia to recover without doing hip reconstruction. Occasionally there may be a child in whom neurectomy is a reasonable option in the upper extremity,⁸⁰ where the flexor muscles can be denervated by dissecting out the motor branches of the ulnar nerve. Also, there is a recent report of doing gastrocnemius neurectomy to control ankle equinus⁸¹; however, this is not a good idea from a mechanical perspective, as the muscle would lose strength. Overall, for the control of spasticity, peripheral neurectomy has a minimal role in the management of spasticity in the child with CP.



Case 4.3 Joe

At age 4 years, Joe developed a mild bleed from a brain arteriovenous malformation. This condition was surgically treated, and following the procedure he was left with mild left hemiplegia. This appeared to be a typical spastic hemiplegia until he entered puberty at age 14 years. A significant dystonic movement disorder developed in his left upper extremity, in which the elbow would flex along with strong wrist and finger flexion. An attempted treatment with trihexiphenidyl was unsuccessful. The biceps, forearm flexors, and finger flexors were then injected with botulinum toxin, which provided excellent relief, allowing the limb to remain in good position. Repeat injections were performed every 4 to 6 months over the next 2 years with gradually diminishing effect. At this time, the dystonia was so severe that finger flexion was causing skin breakdown in the palm, which was very painful. Motor point injection alcohol of the biceps and finger flexors provided only 3 months of relief. The same motor nerves, as well as the motor branches of the radial nerve, were then injected with phenol. This injection caused a severe neuritic pain syndrome for 6 weeks because the phenol also affected the sensory nerves. This injection provided almost 12 months of improvement in the dystonic movement. However, elements of the dystonia returned. The shoulder tended to go into extension and abduction, which was very annoying, because as he walked in school the arm would suddenly fly into extension and abduction, hitting walls or other people (Figure C4.3.1.). This was extremely annoying and frustrating to him. Because of the severe pain from the previous phenol injection, he refused it and other phenol injections, actually requesting amputation of the limb. It was recommended that Joe go for an evaluation for possible central lesioning to decrease the dystonia; however, he refused this because he blamed his first brain surgery for all his current problems. With few other options left, he had a surgical denervation of the upper extremity, cutting the

suprascapular nerve, motor branches to the triceps, and deltoid muscles. At the forearm, the motor branches to the finger and wrist flexors and extensors were cut. Because it was difficult to cut all motor nerves without cutting sensory nerves, some isolated motor function remained and got stronger over the next year following the denervation. At this time, the tendons on several finger flexors, the wrist extensor, and the biceps were released.



Figure C4.3.1

Neuromotor Junction and the Muscle

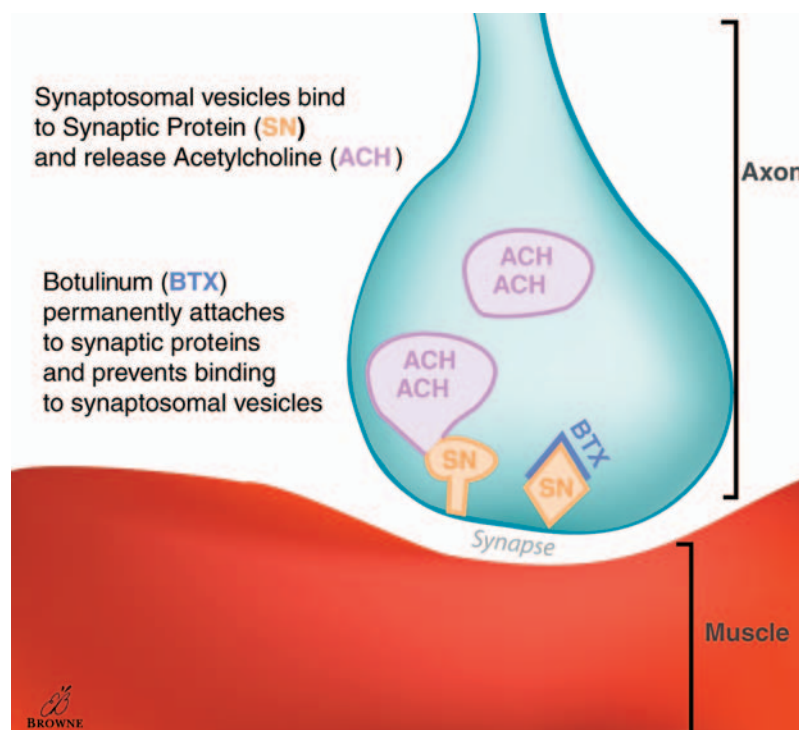
Decreasing tone at the muscle level by oral medication can be done with dantrolene sodium. The principal effect of dantrolene is an alteration of the calcium release from the sarcoplasmic reticulum. In addition to decreasing tone, dantrolene also decreases muscle strength.¹⁸ This drug has been found to cause an acute decrease in spasticity similar to diazepam.⁸² Dantrolene has significant complications: in addition to weakness, it can cause

irreversible hepatitis in some children, chronic fatigue and dizziness, diarrhea, and increased seizures.⁸³ The drug has also been found to cause variable functional gains and a rapid accommodation effect.⁸⁴ With this record of poor functional gain and high complication rate, it is rarely used in children with CP today.

Local Injections: Botulinum Toxin (Botox)

Botulinum toxin (Botox) is a neurotoxin that is extracted from *Clostridium botulinum*, an anaerobic bacteria that typically causes food poisoning. Botox was initially used to treat strabismus in 1973.⁸⁵ It was approved for use to treat blepharospasm in 1987, and since that time, has been approved to treat cervical and oral dystonia in adults. In spite of these being its only approved uses, there are 297 references cited concerning the use of botulinum toxin as a treatment drug. The uses of this drug include spasticity, dystonia, cystitis, essential hyperhidrosis, facial wrinkles, facial asymmetry, debarking dogs, bruxism, stuttering, headaches, back spasms, bladder spasms, achalasia, anal spasms, constipation, vaginismus, tongue protrusion, and nystagmus. There are very few drugs on the market today with such widespread use.⁸⁵ Botox is serotype A, and is currently the only available therapeutic toxin of the seven available serotypes, although there is research on types B, C, and E.⁸⁵ The botulinum toxin binds irreversibly to the neuromotor junction, preventing the junction from functioning. With the permanent blockade, the peripheral nerve sprouts a new fiber and forms a new neuromotor junction. This process requires approximately 3 to 4 months. After new neuromotor junctions are formed, normal motor function returns (Figure 4.9). The toxin is a large protein molecule approximately 150 kilodaltons (kDa) in size.⁸⁶ Botox is frozen to preserve the drug and its function and requires reconstitution with saline at the time it is thawed. Because it is a large molecule, the

Figure 4.9. Botulinum toxin affects the neuromotor junction by irreversibly binding to the synaptic receptors to which the synaptosomal vesicles bind. This prevents the synaptosomal vesicles from releasing the acetylcholine into the neuromotor junction; therefore, activation of this neuromotor junction is no longer possible.



solution should not be vigorously shaken or injected rapidly through a small-bore needle or the turbulence created could potentially denature some of the protein.⁸⁷ When Botox is injected into the muscle, it causes a decreasing gradient of denervation approximately 3 cm in radius from the injection site.⁸⁸ Therefore, Botox injected into the muscle will cause temporary denervation followed by reinnervation, which takes approximately 3 to 4 months. Significant weakness occurs with a decrease in spasticity. The effect of this decrease in active spasticity is clear; however, this drug has no effect on the fixed contracture that may also be present.

The role of Botox for children with CP is continuing to evolve; however, its main use is to control spasticity. Others have promoted Botox as a pain control drug to use postoperatively to decrease postoperative muscle spasms,⁸⁹ a concept that does make some sense, although we have no experience using Botox in this way. The major use of Botox to treat children with CP is to decrease localized spasticity in a situation where some functional gain is expected. The typical situation is a 3- to 4-year-old child with a very spastic gastrocnemius who has problems wearing an orthosis. The Botox injection allows much more comfortable brace wear. Botox can be used in the cervical paraspinal muscles for severe hyperextension, opisthotonic posturing, upper extremity contractures with severe spasticity, or in hamstrings or adductors with significant spasticity. Botox injection to the adductors is not recommended as a treatment of spastic hips, except in a closely controlled clinical research trial, because there is a well-documented treatment that yields excellent results and deviation from these guidelines may increase the risk that more children will need hip reconstructions. A dose of 5 to 10 units per kilogram of weight is typically used and can be divided between two or three sites. The dose should be diluted with 1 to 2 ml saline per 100 units of Botox and injected with a small (25- to 27-gauge) needle into the neuromotor junction-rich zone of the target muscle. This zone is generally at the junction of the proximal and middle one-third of the muscle. The injections are usually done in a fan-shape fashion to help diffusion and only local topical anesthetic is used, such as Emula cream (Figure 4.10). Care should be taken not to inject the drug intravascularly; however, this has never been reported as a significant problem. Parents should expect the maximum effect to become present in 48 to 72 hours. It is possible to reinject other muscles in 4 weeks, by which time all the drug will be tissue fixed or degraded. There are almost no significant side effects except for mild pain at the injection site, similar to a vaccination. Some clinicians are using much higher doses without apparent side effects; however, the FDA approval is for only 5 units/kg of weight per day, and it is not approved for use in children at the time of this writing.

Botox is a short-acting drug by the nature of the way the neuromotor junction recovers. This character of the drug is good if the result of an injection is not considered beneficial; however, it is usually a drawback because the injection does provide a positive effect, which is subsequently lost. Repeat injections after 3 to 6 months are possible, but an immunity to the toxin develops in many children.⁹⁰ In our experience, most children have about 50% less benefit with each subsequent injection, and all children whom we have treated with more than four or five injections have developed complete immunity. This immunity is very frustrating for the child and family because the drug initially provided a very positive beneficial effect (see Case 4.3).

The typical effect of botulinum toxin is to decrease spasticity and strength in the injected muscle, with the tone and strength recovering in the subsequent 3 to 6 months. Some families report a much longer beneficial side effect; however, most studies looking at objective findings see little change

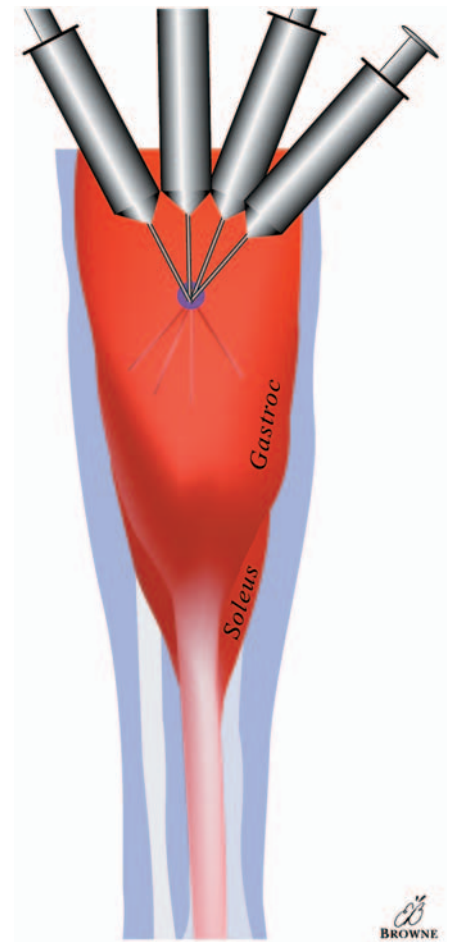


Figure 4.10. Botulinum toxin is diluted with 1 to 2 ml saline and injected into the neuromotor junction-rich zone of the muscle to be blocked. This neuromotor-rich zone is usually in the proximal one-third and two-thirds junction area. The botulinum is injected in a fan-shaped pattern with an understanding that it diffuses over approximately 3 cm from the injection site. For the gastrocnemius, separate medial and lateral injections may be made.

after this initial positive effect.⁹¹ There may be longer-lasting functional gains in some children,⁹² which may suggest that there is a reorganization that occurs such that the patient may settle around a slightly different chaotic attractor. This kind of temporary change may also allow physical therapy to have a positive effect on the individual's motor control system to shift the dynamic function. Also, many clinicians believe that Botox should be used in conjunction with other modalities, such as therapy, bracing, or casting.⁹³ Because of its temporary nature, this concept has good merit as a way of trying to gain more long-term functional improvement. However, if considerable effort with multiple modalities only pushes a child slightly away from a very stable chaotic attractor, the long-term prognosis is poor because the child will settle back to where she was when the efforts started. It is unclear at this time how often Botox can benefit a child by truly moving the dynamic motor control to a substantially new attractor area. Another major problem with botulinum toxin is that it is extremely expensive. As more companies develop other serotypes, perhaps competition will cause the price to drop.

Local Injection: Alcohol and Phenol

Injections into the neuromotor junction region with alcohol and phenol were also popular for a time, especially in the 1970s.^{2, 75, 76, 94} Alcohol and phenol have the same problems when they are injected into the neuromotor junction as when they are used for neurolysis. In addition, if large volumes of the drugs are injected into muscles, intramuscular fibrosis can develop. The use of alcohol and phenol for neuromotor junction injections is rarely indicated for the treatment of spasticity in children today.

Direct Surgical Treatment of the Musculotendinous Unit

A very common and old treatment of spastic muscles is lengthening of the tendon, thereby releasing the contracture. In reality, the contracture is due to a muscle that has not grown sufficiently to its anatomically required length. The classic wisdom often repeated is that muscle tendon lengthening does not directly treat spasticity but only addresses the secondary effects of decreased muscle growth.^{2, 7} This understanding of the effects of muscle tendon lengthening is only partly true because the hyperreflexic component of spasticity depends on the specific length and tension where the muscle is being stimulated.¹ Thus, the muscle is much more sensitive to initiate a hyperreflexive contraction when the most sensitive region of the length-tension curve is under tension. For an example, with the gastrocnemius having its most sensitive length-tension curve set at 20° plantar flexion, hyperreflexia demonstrated clinically as clonus will be easily initiated in 20° of plantar flexion. By lengthening the tendon and allowing this most sensitive aspect of the muscle length to rest at 10° of dorsiflexion, there will be significant decrease in the spasticity or the ability to initiate clonus when the ankle is at 20° of plantar flexion. By this method, lengthening the tendon has direct functional effects on the spasticity by moving the sensitive region to an area where it is less likely to be initiated during an activity such as gait. Also, lengthening the muscle will give it the ability to generate active plantar flexion moment at the place in the joint range where it is needed, instead of in significant plantar flexion in which children get little additional mechanical advantage from the contraction. This complex effect of muscle length is discussed further in the section on gait. Adjusting muscle length through the use of tendon lengthening is one of the primary options for treating the major secondary muscular effects of spasticity and also has some direct impact on the spastic response of the local muscles.

Orthotics

There has been much discussion in different venues of tone-reducing orthotics, specifically the use of various orthotic designs, such as elevated toe plates, peroneal arch, calcaneal bar, and ankle articulations. All reported studies that objectively evaluated these claims have not found any benefit beyond the mechanical constraint these orthoses provide.⁹⁵⁻⁹⁷ Based on these published data, there is no direct evidence of an impact on tone by the use of orthotics. There may be some benefit to decreasing sensory input and thereby decreasing muscle tone in some children. Also, based on subjective experience reported by many clinicians, there are a significant number of children, especially those with quadriplegic pattern involvement, whose motor control system shifts to a different chaotic attractor. For example, by keeping the ankle at neutral in an ankle-foot orthosis (AFO), a child has less extensor posturing and sits better, and has better arm control. This change in motor control is hard to directly relate to a reduction in spasticity; however, this change does occur. The orthotics have the opposite effect in some children. Often, these children are driven to push into more plantar flexion and hyperextension. These children get a sensory stimulus from the orthotic that drives them toward more of the extensor posturing attractor.

Special tone-reducing casts with molded-in pressure point areas in the soles and extended toe plates have been advocated as a technique for reducing spasticity.^{97, 98} Only small case studies have been reported that suggest a benefit with this technique.⁹⁹ However, it seems that the positive effects of wearing casts are directly related to the length of time they are worn.¹⁰⁰ It is well known that cast wear causes muscle atrophy and weakness, which is the likely effect seen and labeled as decreased spasticity in these children. In our experience, the benefit of casting usually is approximately one to two times the length of the cast wear time; therefore, if a child is in casts for 4 weeks, the benefits will last 4 to 8 weeks. Parents tire quickly of placing the child in casts and then having the effects quickly lost. Casting is very disruptive to the child's lifestyle because they cannot bathe, dressing is difficult, and the application of the cast is very time consuming. For these reasons, we do not find the use of tone-reducing casts of much benefit in children with spastic CP. The ankle orthotics, when they are fitting well, provide similar gains as the use of tone-reducing casts. There are many benefits of these orthotics over casts, including that the orthotic can be removed for bathing, the ankle range of motion can be maintained, and there is less muscle atrophy.

The use of serial casting continues to make good therapeutic sense in very spastic children in the acute recovery phase from closed head injury or any other circumstance where the spasticity is resolving. The use of casts in these children can provide a bridging effect until the spasticity resolves and they are easier to maintain in orthotics. The primary mechanism for decreasing spasticity by immobilization is probably immobilization atrophy of the muscles and perhaps some stretching of connective tissue. There are no convincing data available that suggest that it is possible, through immobilization techniques, to make spastic muscles grow longer.

Therapy

The use of physical therapy techniques, such as active and passive range of motion, are well-accepted treatment modalities in children with spasticity. There is no objective evidence that a specific therapy can impact the degree of spasticity permanently, although there are activities, such as horseback riding, that patients, parents, and therapists almost uniformly report to

decrease spasticity temporarily. This same effect has been reported to us by individuals while riding in boats or doing other rhythmic activities. The effects on spasticity by these activities are hard to explain, but we believe they occur and probably are mediated through complex cerebral cortex sensory perception and motor control program generator interactions. From dynamic motor theory, this may also result from pushing the individual toward a different chaotic attractor that is not very stable, and as soon as the perturbation has subsided, the stronger attractor comes back into force and the individual's motor control system settles back to where it was before the activity. This explanation best describes what patients report; however, it is not very helpful in conceptually understanding what is happening from an anatomic perspective.

Passive stretching is a widely-accepted modality for maintaining range of motion; however, objective documentation of the exact benefit is lacking. We have seen many children in patterning therapy programs where they were receiving passive range-of-motion exercises 18 to 20 hours a day. These children do have less spasticity and better range of motion compared with similar children who get very little passive range-of-motion stretching. However, it is unclear how much passive range of motion is required to get a significant benefit, because it is neither practical nor healthy for children's overall development to be doing 12 to 18 hours per day of passive stretching.

The use of vibrators, usually at 100 to 120 hertz, also has been shown to decrease muscle tone, and they are often used by individuals who feel stiff. Some patients with CP report that the use of a vibrator makes their muscles feel less tight.⁶ This feeling is a temporary phenomenon and may be related to similar benefits that others report from deep muscle massage.

A Global Approach to Managing Spasticity

There are many options available to treat spasticity. In developing an algorithm, clinicians first have to remember and educate families that spasticity is not CP, and by removing spasticity, the CP will not be cured. Also, the spasticity is an exaggeration of a normal phenomenon, muscle tone, which is an extremely important aspect in normal motor function. Therefore, the goal is never to remove all muscle tone, but to adjust the tone so it provides maximum functional benefit to the individual.

The first function of an evaluation for spasticity treatment is to tally the negative and positive aspects of the spasticity. Based on the specific problems the spasticity is causing, the clinician can choose from the available treatment options. First, the clinician needs to determine whether these problems are due to a global increase in spasticity or to increased spasticity in a local region, such as one joint or one limb. For example, the increased tone in the gastrocnemius of a hemiplegic child has very different implications compared with a child who has severe total body involvement and has problems being seated in a wheelchair.

For local problems that involve two to four specific muscles, the focus should initially be on local treatment. Examples of such localized spasticity are spastic wrist flexors and elbow flexors, equinus foot position, and spastic hamstring muscles causing knee flexion contractures. After identifying the problem as local, the clinician has to decide if it is supple spasticity only with full underlying joint range of motion, mainly a fixed muscle contracture due to a short muscle, or a combination of both supple spasticity and fixed contracture. If the problem is dynamic spasticity with no underlying contracture, then the primary treatment options are botulinum toxin injection and an

orthotic. If the problem is a fixed contracture, the only option is surgical lengthening of the tendon. If the problem is mixed spasticity and fixed contracture, the options can be combined by starting with a trial of Botox and orthotics. To gain an adequate result when the Botox fails, a muscle lengthening should subsequently be done. By far the most common situation is children who fall into the mixed group with dynamic spasticity and contracture; however, there are also children who clearly fall into one or the other groups.

Children whose functional problems related to spasticity involve more than four muscle groups should be considered as the globally involved group. These children should be divided based on whether the problems are mainly caused by sleeping difficulties at night or daytime functional problems. The group of children with primarily nighttime sleeping problems is small, and it is never very clear whether these sleep problems are related to spasticity or whether they are a primary sleep disorder. This group, whose primary problem is nighttime sleeping, should be treated with a trial of oral antispasticity drugs, which occasionally work. Usually, diazepam is our first treatment preference, and we have several patients in our practice for whom this works well. Intrathecal baclofen also improves sleep and can be used if the oral trial fails. For children with daytime functional problems caused by global spasticity, the specific functional problems need to be identified. These functional problems may include difficulty with dressing, seating, and toileting or gait problems. This group should be further divided into those children with multiple functional problems and those with a single problem.

For children with multiple functional problems due to global spasticity, there usually are significantly more problems than functional benefits of the global spasticity. However, it is always important to consider what the functional benefits of the spasticity are for the individual child. If these benefits can be preserved, or are much less beneficial than the problems being caused by the spasticity, the main treatment option is the intrathecal baclofen pump.

For children with single functional problems, such as gait or problems with seating, attention should be focused on specific local treatments. For example, for children who have seating problems, a careful assessment of the seating system can often correct the problem by adjusting and providing a well-fitting seating system. For children whose primary problem is gait, a very careful assessment, usually requiring a full instrumented gait analysis, should be completed to fully understand the interactions of the spasticity, contractions, and skeletal malalignments, which all may be components of their gait impairment. For most children who are independent ambulators and have global increase in spasticity, the primary treatment is correcting the specific individual components of the disability, such as correcting bony malalignments, lengthening contracted muscles, and transferring muscles that are functioning in the wrong phase of gait. The use of intrathecal baclofen may be an option, although there is very little worldwide experience with its use in this population. For children who are ambulatory with diplegia, dorsal rhizotomy can be considered between the ages of 3 and 8 years in those individuals with no bony deformities or muscle contractures and only dynamic spasticity.

Children with global spasticity who are having significant upper extremity problems should usually be considered for surgical reconstruction. For children with global spasticity who have specific problems related to functional tasks of daily living, such as self-dressing or toileting, the first treatment should be an intensive evaluation by an experienced physical or occupational therapist. In summary, by combining all the options and careful assessment, children with CP can usually be treated in a way that makes the spasticity become a benefit and not a major component of their impairment.

Hypotonia

Hypotonia is defined as lower than normal muscle tone. Hypotonia occurs less frequently than spasticity in children with CP and, although it is still relatively common, it has not attracted the attention that hypertonia has. Hypotonia is most common in children with congenital CP, with lesions such as lissencephaly. Families usually perceive and describe the problem as the child being weak, which most children with hypotonia are. Also, there is a common confusion between hypotonia and hyperlaxity or hypermobility of joints. Each of these is a separate problem, but they are often interrelated. For example, a child with Down syndrome has hypotonia, meaning a decreased stiffness in the muscle, but also has connective tissue laxity. Together, these conditions allow for joint hypermobility. In children with hypotonia due to CP, it is usually associated with severe quadriplegic pattern involvement and mental retardation. These children have so little motor control that the system fails to even make an attempt to provide stability. Some children have hyperreflexia as a spastic feature but have low tone as a passive element. This group will be called the local mixed tone pattern. Also, there are children with definite increased tone and spasticity in the lower extremities but significant hypotonia with their trunk and head control. This group will be called the anatomic mixed tone pattern. The anatomic mixed tone pattern is very common during middle childhood, especially in nonambulatory children. Many of these children were initially hypotonic infants, which are much more common than hypertonic infants.⁶ Most of these hypotonic infants develop spasticity slowly, usually starting distally and progressing proximally.^{101, 102} This proximal migration of increased tone often helps the children to sit better as they get older.

The Effects of Hypotonia

Just as secondary effects of spasticity are noted, there are secondary effects of hypotonia. Muscles are the primary structures that are affected. The muscles tend to be weak, meaning they do not generate a high active force compared with a normal child, and they tend to be excessively long or do not have a good definite end feel during an examination as a normal muscle would. These hypotonic muscles are very thin and gracile when examined. Some children with severe hypotonia have a muscle that appears white during surgery. There are no data to define what these changes reflect at the histologic level. Other common changes in the limbs in hypotonic children are long gracile bones with osteopenia and osteoporosis. Joint hypermobility is often associated. There is no recognized measurement of hypotonia except the modified Ashworth scale, which assigns a single scale group to separate hypotonia from normal tone (Table 4.1).

Functional Problems and Treatment

The main functional problem is poor trunk and head control. The joint laxity and poor strength also leads to a high rate of joint dislocations at the hip and feet with the development of scoliosis. Because of the osteopenia, gracile bones, and osteoporosis, recurrent fractures become a problem in a few children.

Almost all the literature with respect to hypotonia and CP is concerned with diagnosing other common diseases.^{101, 102} As opposed to spasticity, the treatment options for hypotonia are very limited because hypotonia is a situation where there is not enough tone. In almost all situations of life, it is

harder to treat something that is not there than to remove something of which there is too much. This fact is well demonstrated by all the options that are available to decrease muscle tone in children with spasticity, whereas there is not one option available to increase muscle tone in hypotonic children. Stabilizing hyperlaxed joints is limited to either surgery or external orthotics. The main problem of poor sitting is addressed with well-designed seating to provide a stable, upright posture. Foot and ankle orthotics are used to stabilize the ankle and feet for standing in standers. These children often require supine standers because of poor head control. When the joint instabilities become severe, stabilization by fusion, such as posterior spinal fusion for scoliosis and foot fusion for planovalgus collapse, is commonly performed.

Movement Disorders

Movement disorders are primary problems related to the ability of children to develop and control motor movement as a pattern. The specific description of these deformities is somewhat confusing and varies among authors of different texts. Although there is a large body of scientific work evaluating the function and pathologies of the brain that lead to movement disorders, the complexities are so great that there is still no easy clear explanation of how motor control is managed in the brain.³ The pathology of these movement disorders has been localized to the basal ganglion and the communication process between the cerebral cortex and the basal ganglion. The primary lesion in most movement disorders is in the basal ganglion, as demonstrated by the development of posttraumatic dystonia.¹⁰³ Also, some movement disorders, such as ballismus, have been localized to occur primarily in the subthalamic nucleus. It is beyond the scope of this text to review all the biochemical and anatomic bases of movement disorders that are currently understood. Understanding the specific pathology in individual children may provide important treatment options, such as medication or surgery. However, in many children, it is impossible to specifically localize the pathology, or if it can be localized, it does not help in directly treating these children.

It is extremely important for the clinician treating these children to understand the difference between movement disorders and disorders of tone, meaning primarily spasticity. The treatments for these disorders are often diametrically opposed, especially the options that the orthopaedist would consider. A helpful approach for the orthopaedic clinician who deals with these children is to approach them through the conceptualization of dynamic control theory. In this approach, their function will tend to be drawn toward a chaotic attractor, which is called the movement disorder. Many of these patterns are not clearly separate from each other, and they may be best visualized as different strength attractors. The three movement patterns that can be used to categorize most children with CP are dystonia, athetosis, and chorea or ballismus.

Dystonia

Dystonia is a movement disorder that has a torsional component with strong muscle contractions with major recurrent movement patterns. An example of such a pattern is strong shoulder external rotation extension and abduction combined with elbow extension, then alternating with the opposite extreme of elbow flexion, shoulder internal rotation, adduction, and flexion. Dystonia may occur in a single limb, in a single joint, or as a whole-body

disorder. These movements cannot be volitionally controlled, although there is a sensory feedback element that sometimes allows them to be stopped or reversed. For example, a specific pressure point or body position may stop the forceful elbow and shoulder external rotation contraction. Sometimes, moving a finger passively will break up the forceful dystonic wrist flexion. There is no good anatomic understanding of how these sensory inputs function.³ The attraction to individual patterns is weak, which means various perturbations can push the system out of the pattern; however, the system is very unstable, being drawn to either another attractor or back to the same attractor again. These attractor positions in individual patients become very well recognized and can be described easily by the patients themselves as the positions to which their limbs seem to want to go.

As noted earlier, both dystonia and spasticity can be present in the same limb, although in our experience, this is not a common occurrence in localized limb dystonia. The presence of both is much more common in generalized dystonia. It is especially difficult to separate generalized dystonia from generalized spasticity, especially when it presents as extensor posturing with opisthotonic patterning. The difference exists because opisthotonic patterning originates primarily from brainstem defects as opposed to dystonia, which originates primarily from basal ganglion lesions. Also, the children with opisthotonic patterning are often in this hyperextended position all the time, including during sleep. Children with dystonia tend to be in a more relaxed and normal position during sleep. The secondary effects of dystonia and spasticity are also very different.

Secondary Effects of Dystonia

It cannot be overemphasized how important it is for the orthopaedist to identify isolated limb dystonia from spasticity because on the initial evaluation, for example, the limb may present in fixed wrist and elbow flexed position, which has an appearance exactly like a hemiplegic, spastic limb. This same position occasionally occurs with the foot in equinovarus or planovalgus, having the same initial appearance whether the child is spastic or dystonic. The major difference between spasticity and dystonia is determined by a good physical examination and patient history. On physical examination, it often becomes clear in the limb with dystonia that there is no fixed contracture and the muscle appears to be hypertrophic, like a child who has been a weight lifter. During the examination, the child's muscles will often release and have a temporary appearance of normal tone. When the muscle releases, the joint will have a full range of motion with no contracture present. This appearance is very different compared with a child with a spastic limb in whom the contracted deformity is stiff in all conditions and the muscle often has a short, thin appearance on physical examination. A child with a severe equinovarus positioning of the foot from spasticity will always have some level of muscle contracture present. The important question to ask in the history taking is if the foot or hand ever goes in any other position except the one that it is in now. If the problem is dystonia, the parents and the child often will say very readily that sometimes instead of the wrist being in a flexed position, it is stuck back with the fingers flexed but the wrist extended. The history of how the child positions when relaxed, the appearance of the muscles, and the sense of the child's underlying tone when relaxed are the important parameters to use in separating spasticity from dystonia. This distinction is especially true for a quadriplegic child, where the child with pure dystonia will often have very large well-formed muscles and no underlying contractures. A child with significant hyperextension posturing spasticity

often has significant contractures, sometimes of the extensor muscles of the neck and often of hip extensors and quadriceps of the knee.

Objective measurement of degrees of dystonia is an extremely difficult problem. There has been an attempt made to measure dystonia by the development of the Barry Albright Dystonia (BAD) scale, which focuses on generalized dystonia and mainly measures the stiffness of the child.¹⁰⁴ This scale is not much different from the Ashworth scale applied to the trunk, and as such really has no ability to separate dystonia from spasticity. This scale cannot be applied to isolated limb dystonias.

Treatment of Central Nervous System: Medications

The primary treatment of both generalized and localized dystonia is oral medication management. The available drug options are many and the rationale for use of a specific drug is not well defined. The available options include levodopa; anticholinergics such as trihexyphenidyl hydrochloride and diphenhydramine; and the benzodiazepines, baclofen, carbamazepine, and a large variety of dopamine receptor-blocking drugs. None of these drugs has a highly selective effect on dystonia, and the positive and negative effects of each drug have to be balanced, preferably by a clinician with experience in their use (Case 4.4).

Intrathecal baclofen has been reported to be beneficial to treat generalized dystonia; however, this is a group of children that includes extensor posturing and it is unclear whether the dystonia or the spasticity responded to the baclofen.²² In another study where there was a major attempt to separate the dystonia from the spasticity, the effects on the dystonic patterns were less reliable, especially with localized limb dystonia.¹⁰⁵ It has been our experience, in two children with localized limb dystonia, that the response is not very reliable (Case 4.5).

Treatment Options: Central Nervous System Surgery

Many reports going back 30 to 40 years describe destructive surgical procedures of the central nervous system, mainly pallidotomy, to treat dystonia. The results of these procedures have been unpredictable, with a tendency for the dystonia to return.¹⁰⁶ Using better stereotactic localization and improved localization, there is a renewed interest in lesioning procedures to treat dystonia.^{107, 108} So far, however, these are single cases or very small series, and the usefulness of basal ganglion lesioning remains unclear.

Treatment Options: Peripheral

Treatment at the level of the muscle has to be approached very carefully. Dystonia is a contraindication to muscle lengthenings or transfers. Dystonia is a very unstable motor control system, and a worse opposite deformity will invariably occur if muscle lengthenings or muscle transfers are performed. The peripheral treatment should be reversible and temporary or stabilizing in almost all cases. In the reversible category, the primary treatment is botulinum toxin injections into the main offending muscles. These injections are extremely effective because the muscle weakness also somehow decreases the initiation of the dystonia and decreases the attractor strength. The major problem with using Botox in children with CP is that dystonia is permanent and will require treatment injections every 4 to 6 months. Every child we have treated for dystonia has become immune to the Botox and it has lost all effect. Therefore, the treatment starts with impressive and wonderful



Case 4.4 Sarah



Sarah, a 7-year-old girl, was referred after having seen many other physicians. Her mother complained that she could not run or walk well. Sarah tended to get her feet tangled up and tripped over herself, according to her mother. Sarah herself was getting very frustrated and did not want to play with friends or go to school. The physical examination was completely normal, but observation

of her gait demonstrated great variability with torsional elements and hyper hip and knee flexion. Kinematics showed erratic variability with extremes that indicated different patterns, not a variation from a single mean (Figure C4.4.1). With the diagnosis of torsional dystonia, she was started on trihexyphenidyl, and after 1 month, almost all the symptoms resolved.

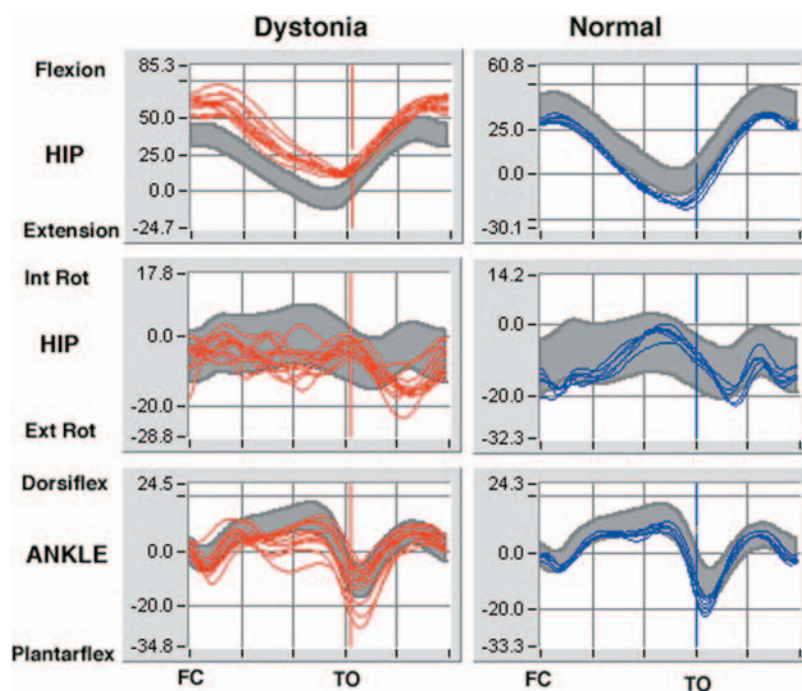


Figure C4.4.1

results and ends in approximately 2 years when it no longer provides benefit. Based on published papers, this immunity does not happen when smaller muscles are treated, such as eyelid treatment for blepharospasm.³ For very persistent and severe dystonia in children who are resistant to Botox, phenol injections are a reasonable option. However, development of hypersensitivity and sensory pain from the use of phenol blocks of nerves that contain sensory elements is a major problem. It is very difficult to block only the motor nerves and avoid all sensory nerves, especially in the upper extremities (see Case 4.3).

Peripheral Surgical Treatment

The primary treatment of symptomatic dystonic foot deformities is to stabilize the foot with a fusion and excise the tendons of the deforming muscles.



Case 4.5 Paul



Paul, a 15-year-old boy, was referred to the orthopaedic clinic by a psychiatrist who had been treating him because of depression and a conversion reaction with a very peculiar gait. Because of Paul's persistent complaint of feeling that his knee was giving away, there was a concern that he had some mechanical knee instability. This walking pattern had been slowly and intermittently getting worse since middle childhood when he started living with an aunt. She had no history of his early childhood. Paul stated that the problem was somewhat variable but seemed worse when he wanted to walk fast or run, and got worse when he was anxious. He expressed great frustration with the problem, especially with the left leg, which did not support him. On observation of his gait, he had a consistent instability of the left leg with hyperflexion and

some torsional control problem. His physical examination was completely normal with no joint contractures, no instabilities, and no increase in muscle tone. His muscle strength was excellent with manual muscle testing. On kinematic evaluation, he showed several patterns of motion with great variability that was clearly not around a bell-shaped distribution. A diagnosis of dystonia was made and he had trials of trihexyphenidyl, ankle orthotics, and botulinum toxin, all without significant benefit. Over this 2-year period, he continued to get slightly worse. After a positive trial of intrathecal baclofen, he had an intrathecal baclofen pump implanted that improved his gait pattern to some degree, but he complained of being weak when the drug dose was high enough to really suppress the movement.

This means, if there is a varus deformity with the tibialis posterior and peroneal muscles, these muscles should be excised and a triple arthrodesis performed. This approach is reliable and provides for a stable functional foot. Often, the child will need to use an orthosis because of poor control of the ankle plantar flexors and dorsiflexors. If these flexors are involved in the dystonic motor control deformity, they too may need to be excised; however, we prefer to leave them alone in the initial procedure to see if they will settle down after the foot is stabilized. The upper extremity is more difficult, but in severe cases the limb may need to be denervated and allowed to be flaccid. Also, doing fusions of the wrist and occasionally of the shoulder may be reasonable options. We had one adolescent who requested amputation of the upper limb, but a limb that is flaccid with sensation is a better cosmetic solution. Dealing with dystonia at the knee and hip is especially difficult, because it is not functional to denervate the muscles or fuse the joints. We did a rectus transfer on an adolescent whose knee stiffness was thought to be spastic but afterward was found to be dystonic. For 9 months after the rectus transfer, she held the knee in flexion when she tried to stand. Persistent physical therapy and orthotic use converted this patterning back to extension at about the time we were contemplating reversing the rectus transfer.

A Global Approach to Management of Dystonia

Treating dystonia in children can be very frustrating. Because dystonia is a relatively rare occurrence, treatment should be a combined effort of the individual who has experience with neurologic drugs and the clinician who has experience with peripheral motor management options. The initial management in most children should be to explore the possibilities of oral drugs because some children respond to very low doses and do well. If the oral medications fail, the whole body involvement group should be separated from the focal single anatomic area group (see Case 4.4).

For the whole body involvement group, a careful assessment should determine if these children really have dystonia or if their problems are due to spasticity and fixed contractures. If the problem is due to fixed contractures, releasing the contractures, usually hip flexor and knee extension contractures, and allowing them to get in a better sitting position may solve the problem. If the dystonia is the major aspect of the problem, the options to consider are intrathecal baclofen pump or a pallidotomy. At this time, the intrathecal baclofen pump is favored as the first approach if there is a positive response to a trial dose. If the intrathecal baclofen does not work, another reasonable option to consider is pallidotomy.

For children with localized dystonia who have failed oral medication treatment, a careful assessment of the area and level of maximal functional impairment is required. The first-line approach is an evaluation with the use of orthotics to stabilize the deformity. Orthotics are especially likely to work if the dystonia is affecting the foot. If this simple mechanical approach fails, the next line is to use Botox in the offending muscle; however, the family and child need to be warned that this is a temporary measure. After the Botox fails, an intrathecal baclofen trial is considered, or if the problem is localized to the foot, a fusion stabilization procedure is considered. If the baclofen trial is successful, a pump is implanted (see Case 4.5). If the pump is not successful, additional peripheral blockade using phenol may be an option. At this point, pallidotomy can also be considered as an option. If the pallidotomy is not an option, then further denervation and stabilization are the only remaining options.

Athetosis

Athetosis is a movement disorder presenting as large movements of proximal joints. Athetosis tends to be worse in the upper extremity with external rotation and abduction movements of the shoulder, often with extension and fanning of the fingers. The movement is induced by voluntary effort, although sometimes this effort is as remote as trying to speak. A variable amount of voluntary control is often improved in the context of more complex movements, such as a movement associated with walking. Athetosis is also a major component of the hyperkinetic pattern, which is the term used by some neurologists. Traditionally, athetosis has been associated with neonatal kernicterus and hyperbilirubinemia.¹⁰⁹ This direct relationship has become less clear as the treatment of kernicterus and hyperbilirubinemia has improved.¹¹⁰ There has been a significant decrease in the number of children with predominantly athetosis in the past 30 years.¹¹¹ The pathologic etiology classically involves kernicterus in the pallidum; however, investigations into cases with unclear etiology have found lesions also involving various parts of the basal ganglion. Children with isolated athetosis tend to have no intellectual deficits, but often have motor speech problems that make communication difficult. The natural history of athetosis is an infant who initially is hypotonic, then between 12 and 24 months of age, starts to have increased movement with an underlying hypotonia. As these children get to be 2 to 4 years old, the hypotonia resolves and many develop some level of increased tone that helps to modulate their movement. Typically, by age 5 years the full expression of the movement disorder is present.

Sensory Motor Effects of Athetosis

In individuals with athetosis only, there are almost no secondary effects in childhood. There may be some increased mobility of finger extension, espe-

cially at the metacarpal phalangeal joint. The muscles tend to be hypertrophic, although less so than with dystonia where the maximum contraction is held for a longer period of time. In athetosis, there is a large amount of motion but the muscle is not held in maximum contraction for an increased amount of time. The difference between athetosis and dystonia for the muscles is similar to the difference between a weight-lifting athlete and a long-distance runner. Dystonia is similar to weight lifting and athetosis is similar to running. Children with athetosis have a very high energy need,¹¹² as opposed to children with quadriplegic spasticity where the energy need is considerably less than normal. Athetosis usually involves significant problems of trunk control, with trunk hypotonia often significantly limiting a child's ability to gain sitting stability or to walk. Facial movements are usually part of the athetoid pattern, and are often associated with increased drooling. This movement disorder also appears to affect the vocal cords, causing a major motor speech impairment.

Treatment

The use of diazepam as an oral medication will decrease athetoid movement, but only at very high doses. Except for acute situations, such as following surgery, diazepam has little use because of the severe sedative effects at the dosage that controls the movement. There are no other medications that have gained widespread use. Baclofen is contraindicated because it will reduce the tone, which often makes the athetoid movements worse because the spasticity acts like a shock absorber to dampen the movements. Botox has little or no usefulness because of the whole-body nature of the athetoid involvement. There is rarely a single problem caused by one or two muscles.

There is a long history of central nervous system surgery, mainly ablative procedures^{43, 113} or implanted electrical stimulation¹¹⁴; however, none of these has demonstrated any consistent benefit in individuals with athetosis. Currently, there is no role for central nervous system surgery for athetosis.

Musculoskeletal surgery is limited to stabilizing joints where they might provide functional benefit. Fusion of the subtalar joint and spinal fusion for scoliosis are the most commonly indicated operative procedures. However, most children with athetosis only will need no musculoskeletal surgery. Many children have a mix of spasticity and athetosis, so they develop the secondary problems of muscle contractures from the spastic component. As the patient is evaluated to determine if the contracted muscle should be lengthened, caution should be exercised when trying to determine how much spasticity is dampening unwanted athetosis.

A common combination is a hamstring contracture with or without a knee flexion contracture, which makes it difficult for a young adult or adolescent to stand. Often, the standing is an important function for the adult-sized individual because it will allow one attendant to provide for their needs as opposed to needing two attendants to do a dependent patient lift transfer. In this situation, lengthening the hamstrings and knee capsule may provide a substantial functional benefit; however, the postoperative management may be very difficult, as the athetosis tends to get worse with pain. Although this can be a very difficult time for the patient, family, and medical team, it often provides excellent functional gain in the end. A major advantage is that the patient usually has excellent understanding of the goals and will be very willing to work hard to achieve the goals.

Undertaking a major surgical reconstruction in a child with severe athetosis and underlying spasticity requires a very experienced postoperative management team. Often, there is an element of great hesitation with families



Case 4.6 Nicholas



Nicholas, a 16-year-old male with severe knee flexion contractures and torsional malalignment of the left hip with planovalgus feet, was having increased difficulty in walking. He had normal cognitive function and was academically at the top of his high school class. It was recommended that he have a left femoral osteotomy, bilateral knee capsulotomies with hamstring lengthenings, and arthrodesis for planovalgus feet. After extensive discussion, he and his family agreed to proceed, although with a lot of hesitation. Postoperatively, he had severe spasms requiring very high doses of diazepam and morphine. On the left side, he also developed a sciatic nerve

palsy. After 1 week, the pain and spasms subsided and he started a long rehabilitation period requiring slow extension stretching of the left knee, as tolerated by the sciatic palsy. After 1 year of rehabilitation, he was standing and walking much more upright and he was very glad he had gone through the procedure. There were many times following the surgery where both Nicholas and his family felt like he would never recover from the surgery and the related complications. However, the sensory and motor defects of the sciatic palsy completely resolved, and the final expected outcome was similar to the expectations going into the procedure.

and young adults or adolescents to undertake any major surgical changes. This hesitation in families and patients often develops because of their own experience with the unpredictability of athetosis. They are hesitant to undertake a treatment that they fear will leave them even worse than they are currently. Many of these families and patients have also had experience with physicians who did not appreciate the unpredictable nature of athetosis and were not willing to listen to their experience with this condition (Case 4.6).

Because of the excellent cognitive function in most individuals with athetosis, their input into rehabilitation often significantly enhances the rehabilitation period because they will know what works and what does not work. This great insight by these patients in understanding of their own body can lead to a dynamic in which therapists feel the patients are not willing to listen or want to try something new. On the other hand, these patients may feel that the therapists are not listening and only want to follow a fixed therapeutic plan. This is the situation in which both the therapists and the patients have to listen to each other, and both have to be open to try different techniques to arrive at a maximum rehabilitation potential of each individual.

Another major musculoskeletal problem of athetosis is degenerative joint disease changes in the cervical spine from the increased cervical spinal mobility. We have never seen these changes as a problem in a child or an adolescent; however, they have been well reported to occur in middle age, although the exact incidence is unclear. There are many small series reporting myelopathy with this degenerative joint disease process as the cervical spine develops instability and subluxation.^{115–119} If there is any decreased motor function or change in motor function in an individual with athetosis, a full workup of the cervical spine including radiographs and MRI scans is required. The degenerative joint disease and the cervical spine instability usually require cervical spine fusion and decompression.

We have seen several children with athetosis who developed lumbar spondylolisthesis in childhood, and the only fusion for spondylolisthesis that we have done was in an adolescent with athetosis (Case 4.7). There is



Case 4.7 Zackery



Zackery, a 12-year-old boy, presented with a complaint of back pain, especially after walking long distance. A gait analysis showed very high variability in step length and most kinematic parameters (Figure C4.7.1). He had no fixed contractures on physical examination. A radiograph of his spine demonstrated L5 spondylolysis with

grade one spondylolisthesis (Figure C4.7.2). An attempt at conservative treatment with a lumbar flexion jacket for 6 months demonstrated no significant decrease in the pain; therefore, it was recommended to have a posterolateral arthrodesis from L4 to the sacrum. After this healed, all his back pain resolved.

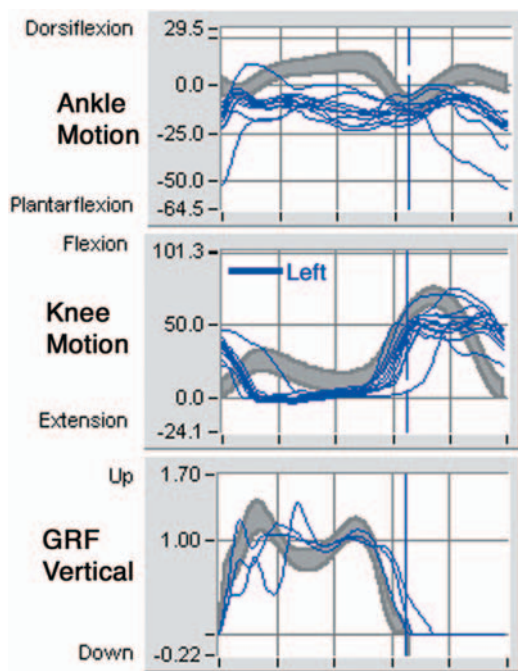


Figure C4.7.1

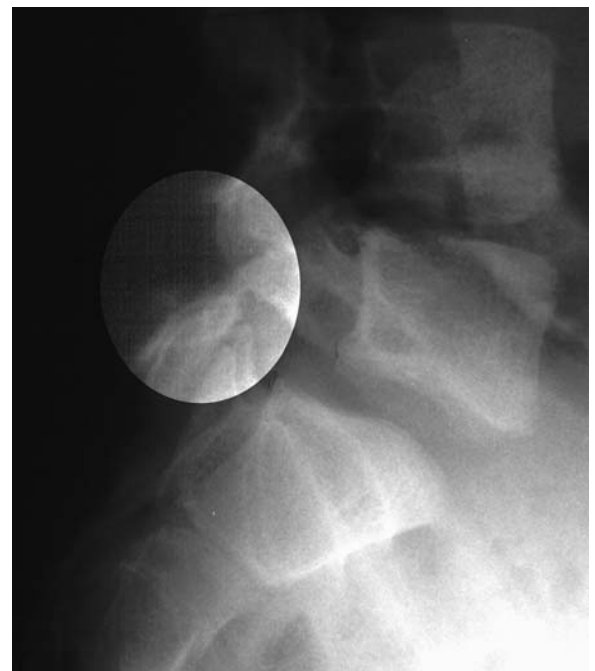

Figure C4.7.2

no specific information on the incidence of spondylolysis, or the incidence with which it progresses to an unstable spondylolisthesis.

Treatment: Therapy

The main treatment for a child with athetosis is excellent therapy by an experienced therapist. This treatment focuses on educating the family and working with the child to help them find what works and what does not work. Good seating is required to maximize upper extremity function; however, the family and therapist also have to allow the child to explore with bare feet and use her head as a motor control device. Because athetosis is usually worse in the upper extremity, there is a small group of children who have good control of their lower extremities and can do fine motor skills with their feet. Skills such as drawing, writing, and playing musical instruments are occasionally mastered. Unless the child is given options to explore these skills, they will not be recognized. The most common skill a child with athetosis can

learn is to use a joystick to drive a wheelchair. Because the function of these children is often apparent by the time they are 4 to 5 years old and they are very intelligent, they are the only candidates with CP for whom an early power wheelchair fitting is a reasonable option. The power wheelchair does require the family to have transportation to carry it and an adapted home. Also, many children benefit from the use of weights on the wrists when they are trying to do specific tasks with the upper extremity, or the use of ankle weights when they are working on walking. Weighted vests can also help some children during seated activities. These weights may provide dampening of the movement similar to the presence of spasticity, or there may be a more complicated control interaction. The weights do seem to move these children to a different and more stable chaotic attractor in the motor control abilities area. Each child is quite variable, requiring an experienced and patient therapist to try many options and ascertain which combination is working best for the individual child. Some parents become excellent at defining the specific circumstances in which their child can best function.

In summary, the treatment of athetosis primarily revolves around experienced therapists who can help these children access the most useful functional motor abilities and to allow them to express their generally high cognitive function. These children often benefit greatly from the use of augmentative speech devices, and as such need to have access to excellent assistive communication services. Musculoskeletal procedures are useful only to stabilize joints, and in rare circumstances, to treat the underlying spasticity when it causes more functional problems than benefits. There is rarely any role for medication in the treatment of athetosis.

Chorea and Ballismus

Chorea is a movement disorder defined by jerky, rhythmic, small-range movements. These movements are more predominant distally in the limb; however, they are present as proximal movements of the head and trunk as rhythmic, jerky motion as well. Ballismus is large movement based at the proximal joints, primarily the shoulder and elbow or hip and knee. These large movements are unpredictable, jerky, and often have a violent character to them. Some neurologists believe that chorea and ballismus are two ends of the same movement spectrum, and from the musculoskeletal treatment perspective, this concept works well. These movement patterns are the most rare of the movement disorders in children with CP. When these movement disorders are seen to be developing, especially if significant chorea develops, the diagnosis of CP should be questioned. If significant chorea or ballismus movements start to develop in children with CP, additional workup frequently defines a more specific diagnosis, often one with a degenerative process. These movement disorders may get slowly worse if there are no mechanisms for controlling them.

The primary pathology for chorea and ballismus occurs in the basal ganglion; therefore, many drug options similar to the treatment of dystonia are considered as the first line of treatment. There have also been positive reports of ablative surgery on the internal capsule.^{107, 108} There are no specific treatments for the musculoskeletal affects of ballismus and chorea in children with CP.

Summary of Motor Control Treatments

It is often very difficult to separate out exact treatment recommendations between the movement disorders, especially because there is not a clear patho-

anatomic basis of one movement disorder compared with another. These disorders are somewhat overlapping in their presentation, and probably reflect movement patterns best understood as chaotic attractors in dynamic motor control without a clear anatomic separation. An analogy of these patterns might be the difference between a wind and rain storm compared with a thunderstorm or a tornado. Each of these storms is a definite recognized pattern, all occur in the same geographic region, and the cause of each is similar and not completely understood. This same analogy applies between the movement disorders of dystonia, athetosis, chorea, and ballismus. These movement patterns are fairly different and recognizable although a pathoanatomic understanding of the exact differences is not clear. However, because the patterns can be recognized, specific treatment algorithms for each can be defined. From the musculoskeletal perspective, dystonia is a nonvolitional movement pattern that is difficult to treat because of the persistent nature of the symptoms and the strength of the muscle forces. Athetosis is more predictable and is often under some volitional control that can be accessed through physical therapy intervention. There is very little musculoskeletal treatment that is beneficial for chorea and ballismus.

Disorders of Balance

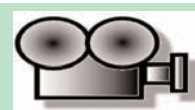Ataxia is a term used to describe poor balance in children with CP. Some children with CP seem to have an isolated ataxia, usually related to congenital cerebellar malformations.¹¹⁰ Often, these are normally developing infants until 12 months of age, when it is noticed that they are not progressing with their normal motor skills development. These children have delayed independent sitting and delayed walking, often not until 2 or 3 years of age. The problem with their balance is most clear in the development of independent walking, but as the children start doing fine motor skills, they demonstrate clumsiness in writing and other fine motor skills. Ataxia often affects speech as well.

Typically, the normal development of balance reaches its maximum in middle childhood and remains stable during the adolescent growth spurt; however, these children appear to be losing balance ability. This apparent loss of balance ability is due to the rapid height gain that occurs during the adolescent growth spurt. The poor balance is a demonstration of the balancing system having trouble controlling a taller structure that is mechanically harder to control than a shorter structure. This phenomenon is also seen in completely normal children and is usually called the adolescent clumsy stage of development. After a year at the end of maximum growth, the balancing system will again gain control and these children will typically have the same function they had at 8 to 10 years of age before the adolescent growth spurt started.

Although there are children with CP whose only problem is ataxia, it is much more common to have a mixed pattern of spasticity and ataxia, or hypotonia and ataxia. Many children with athetosis probably also have ataxia, but it is very difficult to separate out ataxia in the presence of significant athetosis. Having good balance requires that the individual have a stable physical base of support and a good sensory feedback system that can interpret where the body is in space and how its position should be corrected. The lack of a stable base of support is demonstrated by an individual's experience of walking on slippery ice where the physical base of support is poor. An example of decreased balance occurs when an individual is under the influence of alcohol, in which sensory feedback and interpretation are dulled.



Case 4.8 Kerstin



Kerstin, a girl who had a normal birth history and mild mental retardation, started walking independently at 4 years of age. She had made very little progress in the control of her gait, often having periods when she seemed to have more problems with her balance around periods of rapid growth. However, by the time she reached full maturity, her gait stabilized by being a little slower and

less variable. On physical examination she had normal reflexes, muscle strength, and motor control. This is the typical pattern of primary ataxia. The main treatment is to try to teach her to know her own limitations and to use assistive devices, such as crutches or canes, which she resists because she does not feel she needs them.

In the musculoskeletal treatment plan of children with ataxia, it is important to evaluate the components of balance, such as their base of support or their sensory feedback, that are contributing to most of their functional problems (Case 4.8).

Measurement of balance in children is difficult. Most of the balance studies in adults and children involve an assessment of postural stability by measuring the impact of different sensory systems, such as eyesight, the inner ear vestibular system, and joint sensory position feedback.¹²⁰ These types of measurements have not become commonplace in clinical evaluations of children. The gross motor function measure (GMFM) has become a common clinical evaluation tool for children with CP. Although this test does not specifically evaluate and measure ataxia, it has a significant component, especially in domain 4, where tasks such as single-leg stands are evaluated. These tasks require separating out balance from motor control problems based on subjective evaluation of these children. Also, on gait analysis, temporal spatial characteristics such as step length and cadence tend to have high variability in children with significant ataxia. Children with only spasticity but good balance have less variability than normal children, and those with predominantly ataxia will have much higher variability.

This variability is also true of trunk motion and the ability to walk in a straight line. Understanding balance deficits during walking is difficult because momentum can make unstable children look much more stable than they really are. An example is a child who seems to walk very well while walking; however, every time she tries to stop, she has to grab the wall or fall to the floor. This is the analogy of riding a bicycle where the rider is very stable due to the momentum of motion. However, if the rider stops the motion and tries to sit on the bicycle, she becomes very unstable. A child who can walk well only at a certain speed may be an excellent walker; however, developing good functional walking skills requires that an individual be able to stop without falling over.

Treatment of Ataxia

Therapy to help children with ataxia improve their walking should focus on two areas. First, they must learn how to fall safely and develop protective responses when falling. They should be taught to recognize when they are falling, direct the fall away from hazards, and fall forward with their arms out in front to protect themselves. Until these children develop a good pro-

tective response to falling, they should be wearing protective helmets and have supervision when walking. There are some children who cannot learn this protective response, and they will have a tendency to fall like a cut tree; this is especially dangerous if the individual has a tendency to fall backward, which places them at high risk of head injury. These children will have to be kept in wheelchairs except when they are under the direct supervision of another individual. The second area of treatment focus for children with ataxia should be directed at exercises that stimulate balancing. These exercises include single-leg stance activities, walking a narrow board, roller skating, and other activities that stimulate the balancing system. These exercises have to be carefully structured to the individual child's abilities, with the goal of maximizing each child's ability safely and effectively.

Walking effectively as an adult requires an individual to be able to alter gait, speed, and especially to slow down speed to reserve energy as she tires. This may mean using an assistive device, such as forearm crutches. For safety and social propriety, it is important that an individual can stop walking and stand in one place. Children who cannot learn to stop and stand in one place will have to switch to the use of an assistive device, usually forearm crutches, in middle childhood or adolescence. This step may seem like a regression to parents; however, it is moving the child forward to a more stable gait pattern that is socially acceptable and functional into adulthood. It is appropriate for 3-year-old children to run and then fall when they get to where they are going and want to stop; however, this method in a 13-year-old would be both unsafe for the child and socially unacceptable. Finding the appropriate device requires some trial and error. There are rare children who can use single-point canes. Three- or four-point canes are a poor choice because they slow the child too much and are generally very inefficient. Either forearm crutches or a walker are typically the best assistive devices for an individual child. Some children's ataxia is so severe that it requires the use of a wheelchair for safe and functional mobility.

Surgery for the Child with Ataxia

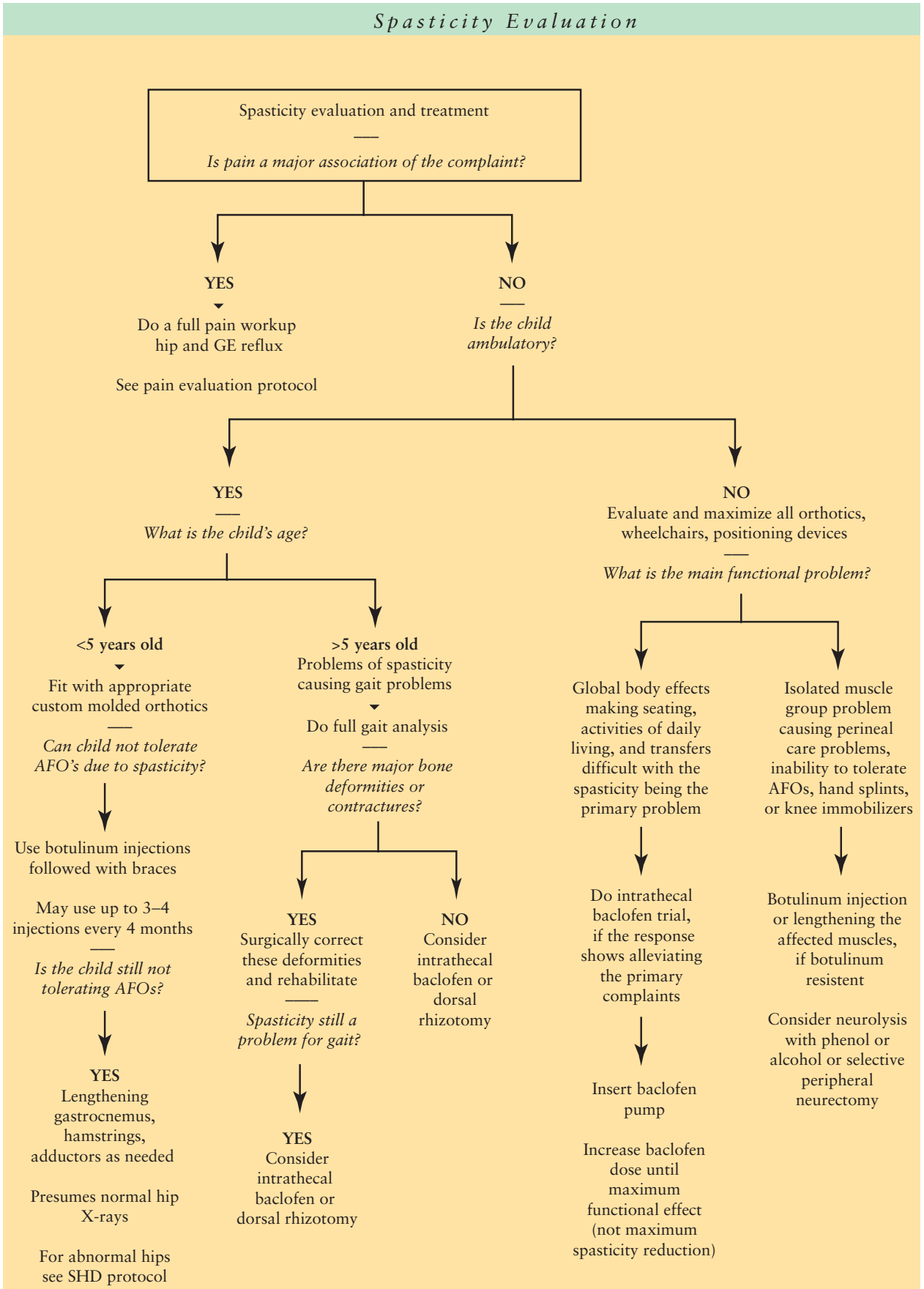
The sensory perception and processing of balance cannot be altered in any predictable known way with surgery; however, the mechanical stability can be altered. Mechanical stability means that children have a stable base of support upon which to stand. Children with severe equinus at the ankle, such that they can only stand on their toes, will be unstable even if their balance is otherwise normal. Other examples of mechanical instability are severe planovalgus or equinovarus feet, severe fixed scoliosis, or severe contractures of the hip and knee. In general, the spine, hip, and knee contractures need to be very severe before they substantially affect balance. Fixed ankle equinus is the most common situation that is seen in early and middle childhood. Many of these children walk very well on their toes when they are moving with sufficient speed; however, they have no stable ability to stand in one place; this means that the children have to hold onto a wall, keep moving around in a circle, or fall to the floor when they want to stop. When these same children are made more stable by lengthening the gastrocnemius muscle to allow their feet to become plantigrade, their walking velocity slows, but they can now stop and stand in one place. This trade-off of stability and stance versus the speed of walking needs to be explained to parents to avoid their disappointment in the slower walking. This kind of fast toe walking is not a reasonable long-term option for older children for the safety reasons already explained. The safety and social inappropriateness of this gait pattern have to be carefully explained to parents for them to understand the trade-off in stability for speed provided by gastrocnemius lengthening.

Orthotics

For young children with dynamic plantar flexion causing them to toe walk, correcting the plantar flexion with the use of orthotics provides the same improvements in stability as was described for surgical lengthening of tendons. By removing flexibility of the ankle, and especially by decreasing plantar flexion and toe walking, these children will be in a more stable position to focus on controlling large joints, such as the hip, knee, and trunk. Therefore, these children will gain better experience in upright stance required for stable walking. The use of orthotics is the primary stabilizing structure that is provided to young children, usually beginning at approximately 18 to 24 months of age and then gradually decreasing instability as they get older. The orthotics also have the advantage that they can provide children a period of stability when standing with their feet flat, as well as allowing them to have time when they are walking up on their toes. This toe walking allows them to experience the stability of momentum, which stimulates the young developing nervous system. These orthotics work especially well until these children are 5 to 7 years of age.

Summary of Treatment: Ataxia

Children with ataxia need a planned approach of treatment combining a therapy environment in which the balance, sensory, and integration systems are stressed so they can learn to maximize balancing function. These children also need to have their mechanical base of support stabilized to provide a stable base upon which they can gain confidence and learn to use their motor control skills. Mechanical stability is gained through the use of orthotics and assistive devices in young children, and as they get to middle childhood, selective muscle lengthenings can be utilized to improve their mechanical stability and stance. The treatment plan should always consider how safe these children are to avoid falls, which might cause them significant injury. Children with significant ataxia are at significant risk for falls that may cause permanent additional head injuries, and because of this risk, some children with ataxia need to be kept in wheelchairs or use protective helmets based on their ability to learn protective maneuvers and the severity of their ataxia.



Baclofen Pump Dysfunction Evaluation

Workup for poor spasticity response to intrathecal baclofen
(Spasticity increasing and not responsive to baclofen dose increases)

First - Decrease baclofen dose to nothing over 48 hours

Is there a change in the level of spasticity?

YES

Increase baclofen dose again

Go to at least 50% more
than previous high dose

Increase over several weeks

Is spasticity decreased?

YES

Further
workup not
needed

NO

Give baclofen drug
holiday by stopping the
pump for one to two
weeks, or try episodic
dosing on morning
and evening schedule

NO

Get an X-ray of the pump and catheter

The X-ray shows which of the following?

X-ray is normal

Does the pump have
an injection side port?

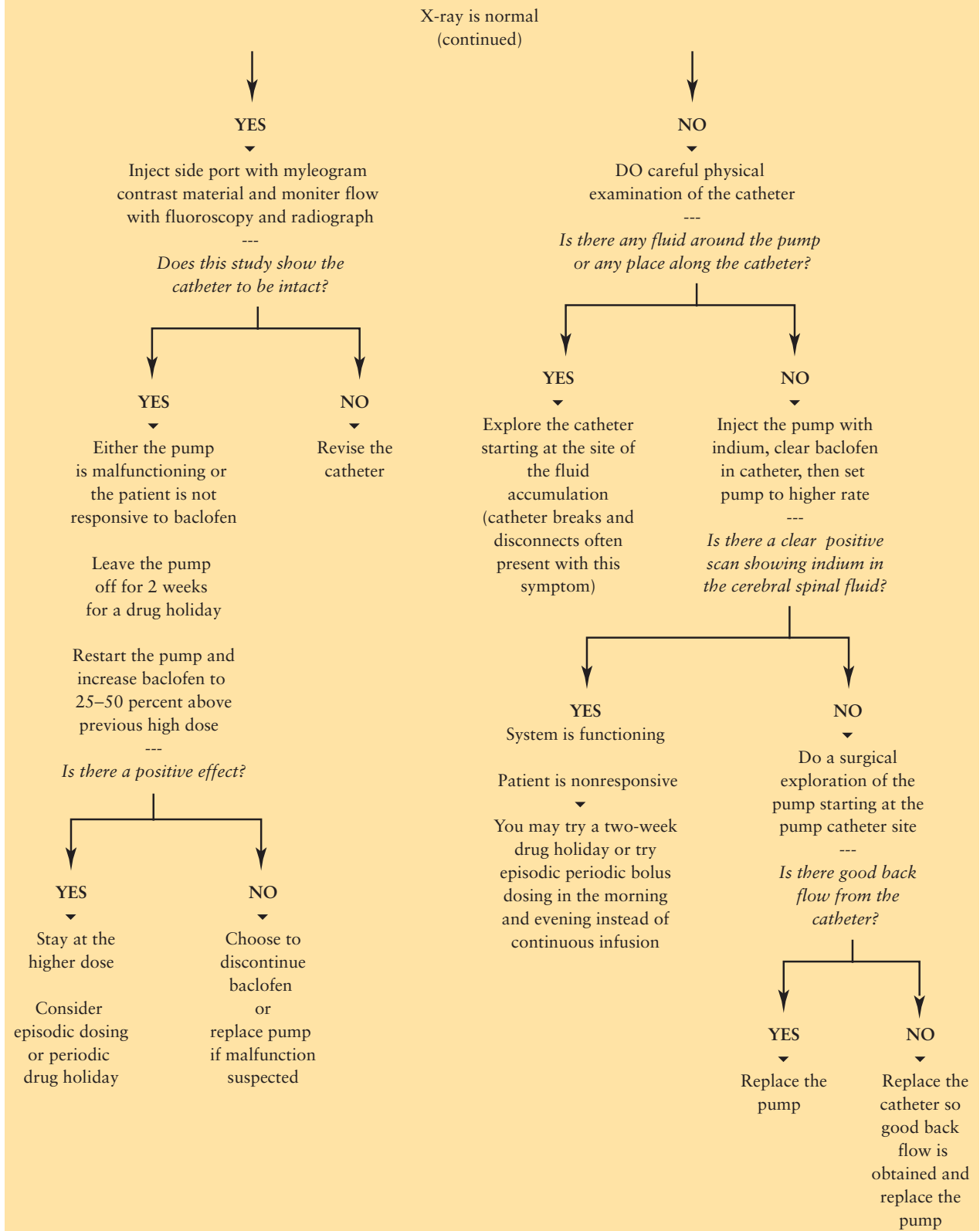
YES

NO

X-ray shows a break
in the catheter

Revise the catheter

Baclofen Pump Dysfunction Evaluation



References

1. Connolly KHF. *Neurophysiology and Neuropsychology of Motor Development*. London: Mac Keith Press, 1997.
2. Gage J. *Gait Analysis in Cerebral Palsy*. London: Mac Keith Press, 1991.
3. Fahn S, Marsden CD, DeLong MR. *Dystonia 3: Advances in Neurology*. Philadelphia: Lippincott-Raven, 1998.
4. Nie J, DA Linkens. *Fuzzy-Neural Control: Principles, Algorithms, and Applications*. New York: Prentice Hall, 1995.
5. Gleick J. *Chaos: Making a New Science*. New York: Penguin Books, 1987.
6. Walsh G. *Muscles, Masses, and Motion: The Physiology of Normality, Hypertonicity, Spasticity, and Rigidity*. London: Mac Keith Press, 1992.
7. Sussman ME. *The Diplegic Child: Evaluation and Management*. Chicago: American Academy of Orthopaedic Surgeons, 1992.
8. Engsberg JR, Ross SA, Olree KS, Park TS. Ankle spasticity and strength in children with spastic diplegic cerebral palsy. *Dev Med Child Neurol* 2000;42:42–7.
9. Ashworth B. Preliminary trial of carisoprodol in multiple sclerosis. *Practitioner* 1964;192:540–2.
10. Sehgal N, McGuire JR. Beyond Ashworth. Electrophysiologic quantification of spasticity. *Phys Med Rehabil Clin N Am* 1998;9:949–79, ix.
11. Lin JP, Brown JK, Walsh EG. The maturation of motor dexterity: or why Johnny can't go any faster. *Dev Med Child Neurol* 1996;38:244–54.
12. Dietz V, Berger W. Cerebral palsy and muscle transformation. *Dev Med Child Neurol* 1995;37:180–4.
13. Ziv I, Blackburn N, Rang M, Koreska J. Muscle growth in normal and spastic mice. *Dev Med Child Neurol* 1984;26:94–9.
14. Castle ME, Reyman TA, Schneider M. Pathology of spastic muscle in cerebral palsy. *Clin Orthop* 1979;223–32.
15. Engle AG, Franzini-Armstrong C. *Myology*. New York: McGraw-Hill, 1994:1936.
16. Miller F, Slomczykowski M, Cope R, Lipton GE. Computer modeling of the pathomechanics of spastic hip dislocation in children. *J Pediatr Orthop* 1999;19:486–92.
17. Nance PW, Bugaresti J, Shellenberger K, Sheremata W, Martinez-Arizala A. Efficacy and safety of tizanidine in the treatment of spasticity in patients with spinal cord injury. North American Tizanidine Study Group. *Neurology* 1994;44:S44–51; discussion S51–2.
18. Gracies J, Nance P, Elovic E, McGuire J, Simpson DM. Traditional pharmacological treatments for spasticity. Part II: General and regional treatments. *Muscle Nerve* 1997;Suppl 6:S92–S120.
19. Erickson DL, Blacklock JB, Michaelson M, Sperling KB, Lo JN. Control of spasticity by implantable continuous flow morphine pump. *Neurosurgery* 1985;16:215–7.
20. Zierski J, Muller H, Dralle D, Wurdinger T. Implanted pump systems for treatment of spasticity. *Acta Neurochir Suppl* 1988;43:94–9.
21. Albright AL, Cervi A, Singletary J. Intrathecal baclofen for spasticity in cerebral palsy [see comments]. *JAMA* 1991;265:1418–22.
22. Albright AL, Barry MJ, Fasick P, Barron W, Shultz B. Continuous intrathecal baclofen infusion for symptomatic generalized dystonia. *Neurosurgery* 1996;38:934–8; discussion 938–9.
23. Albright AL. Baclofen in the treatment of cerebral palsy. *J Child Neurol* 1996;11:77–83.

24. Almeida GL, Campbell SK, Girolami GL, Penn RD, Corcos DM. Multidimensional assessment of motor function in a child with cerebral palsy following intrathecal administration of baclofen. *Phys Ther* 1997; 77:751–64.
25. Armstrong RW, Steinbok P, Cochrane DD, Kube SD, Fife SE, Farrell K. Intrathecally administered baclofen for treatment of children with spasticity of cerebral origin. *J Neurosurg* 1997;87:409–14.
26. Albright AL. Intrathecal baclofen in cerebral palsy movement disorders. *J Child Neurol* 1996;11(suppl 1):S29–35.
27. Gerszten PC, Albright AL, Barry MJ. Effect on ambulation of continuous intrathecal baclofen infusion. *Pediatr Neurosurg* 1997;27:40–4.
28. Wiens HD. Spasticity in children with cerebral palsy: a retrospective review of the effects of intrathecal baclofen. *Issues Compr Pediatr Nurs* 1998; 21:49–61.
29. Kita M, Goodkin DE. Drugs used to treat spasticity. *Drugs* 2000;59: 487–95.
30. Bennett MI, Tai YM, Symonds JM. Staphylococcal meningitis following Synchromed intrathecal pump implant: a case report. *Pain* 1994;56: 243–4.
31. Sweet CS, Wenger HC, Gross DM. Central antihypertensive properties of muscimol and related gamma-aminobutyric acid agonists and the interaction of muscimol with baroreceptor reflexes. *Can J Physiol Pharmacol* 1979;57:600–5.
32. Rode G, Mertens P, Beneton C, Schmitt M, Boisson D. Regression of vasomotor disorders under intrathecal baclofen in a case of spastic paraplegia. *Spinal Cord* 1999;37:370–2.
33. Agmo A, Paredes R. GABAergic drugs and sexual behaviour in the male rat. *Eur J Pharmacol* 1985;112:371–8.
34. Leipheimer RE, Sachs BD. GABAergic regulation of penile reflexes and copulation in rats. *Physiol Behav* 1988;42:351–7.
35. Denys P, Mane M, Azouvi P, Chartier-Kastler E, Thiebaut JB, Bussel B. Side effects of chronic intrathecal baclofen on erection and ejaculation in patients with spinal cord lesions. *Arch Phys Med Rehabil* 1998;79:494–6.
36. Steinbok P, Reiner AM, Beauchamp R, Armstrong RW, Cochrane DD, Kestle J. A randomized clinical trial to compare selective posterior rhizotomy plus physiotherapy with physiotherapy alone in children with spastic diplegic cerebral palsy [published erratum appears in *Dev Med Child Neurol* 1997;39(11): inside back cover] [see comments]. *Dev Med Child Neurol* 1997;39:178–84.
37. McLaughlin JF, Bjornson KF, Astley SJ, et al. Selective dorsal rhizotomy: efficacy and safety in an investigator-masked randomized clinical trial [see comments]. *Dev Med Child Neurol* 1998;40:220–32.
38. Cohen AR, Webster HC. How selective is selective posterior rhizotomy? *Surg Neurol* 1991;35:267–72.
39. Logigian EL, Wolinsky JS, Soriano SG, Madsen JR, Scott RM. H reflex studies in cerebral palsy patients undergoing partial dorsal rhizotomy [see comments]. *Muscle Nerve* 1994;17:539–49.
40. Sacco DJ, Tylkowski CM, Warf BC. Nonselective partial dorsal rhizotomy: a clinical experience with 1-year follow-up. *Pediatr Neurosurg* 2000;32:114–8.
41. Peacock WJ, Arens LJ, Berman B. Cerebral palsy spasticity. Selective posterior rhizotomy. *Pediatr Neurosci* 1987;13:61–6.
42. Fasano VA, Broggi G, Barolat-Romana G, Sguazzi A. Surgical treatment of spasticity in cerebral palsy. *Childs Brain* 1978;4:289–305.

43. Heimbürger RF, Slominski A, Griswold P. Cervical posterior rhizotomy for reducing spasticity in cerebral palsy. *J Neurosurg* 1973;39:30–4.
44. Benedetti A, Colombo F. Spinal surgery for spasticity (46 cases). *Neurochirurgia (Stuttg)* 1981;24:195–8.
45. Benedetti A, Colombo F, Alexandre A, Pellegrini A. Posterior rhizotomies for spasticity in children affected by cerebral palsy. *J Neurosurg Sci* 1982;26:179–84.
46. Gul SM, Steinbok P, McLeod K. Long-term outcome after selective posterior rhizotomy in children with spastic cerebral palsy. *Pediatr Neurosurg* 1999;31:84–95.
47. Subramanian N, Vaughan CL, Peter JC, Arens LJ. Gait before and 10 years after rhizotomy in children with cerebral palsy spasticity. *J Neurosurg* 1998;88:1014–9.
48. Giuliani CA. Dorsal rhizotomy for children with cerebral palsy: support for concepts of motor control. *Phys Ther* 1991;71:248–59.
49. Steinbok P, Daneshvar H, Evans D, Kestle JR. Cost analysis of continuous intrathecal baclofen versus selective functional posterior rhizotomy in the treatment of spastic quadriplegia associated with cerebral palsy. *Pediatr Neurosurg* 1995;22:255–64.
50. Marty GR, Dias LS, Gaebler-Spira D. Selective posterior rhizotomy and soft-tissue procedures for the treatment of cerebral diplegia. *J Bone Joint Surg [Am]* 1995;77:713–8.
51. Carroll KL, Moore KR, Stevens PM. Orthopedic procedures after rhizotomy. *J Pediatr Orthop* 1998;18:69–74.
52. Crawford K, Karol LA, Herring JA. Severe lumbar lordosis after dorsal rhizotomy. *J Pediatr Orthop* 1996;16:336–9.
53. Mooney JF III, Millis MB. Spinal deformity after selective dorsal rhizotomy in patients with cerebral palsy. *Clin Orthop* 1999;48–52.
54. Peter JC, Hoffman EB, Arens LJ, Peacock WJ. Incidence of spinal deformity in children after multiple level laminectomy for selective posterior rhizotomy. *Childs Nerv Syst* 1990;6:30–2.
55. Peter JC, Hoffman EB, Arens LJ. Spondylolysis and spondylolisthesis after five-level lumbosacral laminectomy for selective posterior rhizotomy in cerebral palsy. *Childs Nerv Syst* 1993;9:285–7; discussion 287–8.
56. Greene WB, Dietz FR, Goldberg MJ, Gross RH, Miller F, Sussman MD. Rapid progression of hip subluxation in cerebral palsy after selective posterior rhizotomy. *J Pediatr Orthop* 1991;11:494–7.
57. Heim RC, Park TS, Vogler GP, Kaufman BA, Noetzel MJ, Ortman MR. Changes in hip migration after selective dorsal rhizotomy for spastic quadriplegia in cerebral palsy. *J Neurosurg* 1995;82:567–71.
58. Steinbok P, Schrag C. Complications after selective posterior rhizotomy for spasticity in children with cerebral palsy. *Pediatr Neurosurg* 1998;28:300–13.
59. Cobb MA, Boop FA. Replacement laminoplasty in selective dorsal rhizotomy: possible protection against the development of musculoskeletal pain. *Pediatr Neurosurg* 1994;21:237–42.
60. Payne LZ, DeLuca PA. Heterotopic ossification after rhizotomy and femoral osteotomy. *J Pediatr Orthop* 1993;13:733–8.
61. Abbott R. Complications with selective posterior rhizotomy. *Pediatr Neurosurg* 1992;18:43–7.
62. Cooper IS, Upton AR, Rappaport ZH, Amin I. Correlation of clinical and physiological effects of cerebellar stimulation. *Acta Neurochir Suppl* 1980;30:339–44.
63. Davis R, Schulman J, Delehanty A. Cerebellar stimulation for cerebral palsy—double blind study. *Acta Neurochir Suppl* 1987;39:126–8.

64. Schulman JH, Davis R, Nanes M. Cerebellar stimulation for spastic cerebral palsy: preliminary report; on-going double blind study. *Pacing Clin Electrophysiol* 1987;10:226–31.
65. Barolat G. Experience with 509 plate electrodes implanted epidurally from C1 to L1. *Stereotact Funct Neurosurg* 1993;61:60–79.
66. Hugenholtz H, Humphreys P, McIntyre WM, Spasoff RA, Steel K. Cervical spinal cord stimulation for spasticity in cerebral palsy. *Neurosurgery* 1988;22:707–14.
67. Cusick JF, Larson SJ, Sances A. The effect of T-myelotomy on spasticity. *Surg Neurol* 1976;6:289c92.
68. Ivan LP, Wiley JJ. Myelotomy in the management of spasticity. *Clin Orthop* 1975;52–6.
69. Padovani R, Tognetti F, Pozzati E, Servadei F, Laghi D, Gaist G. The treatment of spasticity by means of dorsal longitudinal myelotomy and lozenge-shaped griseotomy. *Spine* 1982;7:103–9.
70. Carpenter EB. Role of nerve blocks in the foot and ankle in cerebral palsy: therapeutic and diagnostic. *Foot Ankle* 1983;4:164–6.
71. Gracies JM, Elovic E, McGuire J, Simpson DM. Traditional pharmacological treatments for spasticity. Part I: Local treatments. *Muscle Nerve Suppl* 1997;6:S61–91.
72. Carpenter EB, Seitz DG. Intramuscular alcohol as an aid in management of spastic cerebral palsy. *Dev Med Child Neurol* 1980;22:497–501.
73. Hariga J. Treatment of spasticity by alcohol injection. *Dev Med Child Neurol* 1970;12:825.
74. Tardieu G, Tardieu C, Hariga J, Gagnard L. Treatment of spasticity in injection of dilute alcohol at the motor point or by epidural route. Clinical extension of an experiment on the decerebrate cat. *Dev Med Child Neurol* 1968;10:555–68.
75. Easton JK, Ozel T, Halpern D. Intramuscular neurolysis for spasticity in children. *Arch Phys Med Rehabil* 1979;60:155–8.
76. Griffith ER, Melampy CN. General anesthesia use in phenol intramuscular neurolysis in young children with spasticity. *Arch Phys Med Rehabil* 1977;58:154–7.
77. Matsuo T, Tada S, Hajime T. Insufficiency of the hip adductor after anterior obturator neurectomy in 42 children with cerebral palsy. *J Pediatr Orthop* 1986;6:686–92.
78. Root L, Spero CR. Hip adductor transfer compared with adductor tenotomy in cerebral palsy. *J Bone Joint Surg [Am]* 1981;63:767–72.
79. Sharma S, Mishra KS, Dutta A, Kulkarni SK, Nair MN. Intrapelvic obturator neurectomy in cerebral palsy. *Indian J Pediatr* 1989;56:259–65.
80. Keenan MA, Todderud EP, Henderson R, Botte M. Management of intrinsic spasticity in the hand with phenol injection or neurectomy of the motor branch of the ulnar nerve. *J Hand Surg [Am]* 1987;12:734–9.
81. Doute DA, Sponseller PD, Tolo VT, Atkins E, Silberstein CE. Soleus neurectomy for dynamic ankle equinus in children with cerebral palsy. *Am J Orthop* 1997;26:613–6.
82. Nogen AG. Medical treatment for spasticity in children with cerebral palsy. *Childs Brain* 1976;2:304–8.
83. Pinder RM, Brogden RN, Speight TM, Avery GS. Dantrolene sodium: a review of its pharmacological properties and therapeutic efficacy in spasticity. *Drugs* 1977;13:3–23.
84. Joynt RL, Leonard JA Jr. Dantrolene sodium suspension in treatment of spastic cerebral palsy. *Dev Med Child Neurol* 1980;22:755–67.
85. Jankovic J, Brin MF. Botulinum toxin: historical perspective and potential new indications. *Muscle Nerve Suppl* 1997;6:S129–45.

86. Brin MF. Botulinum toxin: chemistry, pharmacology, toxicity, and immunology. *Muscle Nerve Suppl* 1997;6:S146–68.
87. Brin MF. Dosing, administration, and a treatment algorithm for use of botulinum toxin A for adult-onset spasticity. Spasticity Study Group. *Muscle Nerve Suppl* 1997;6:S208–20.
88. Borodic GE, Ferrante R, Pearce LB, Smith K. Histologic assessment of dose-related diffusion and muscle fiber response after therapeutic botulinum A toxin injections. *Mov Disord* 1994;9:31–9.
89. Barwood S, Baillieu C, Boyd R, et al. Analgesic effects of botulinum toxin A: a randomized, placebo-controlled clinical trial. *Dev Med Child Neurol* 2000;42:116–21.
90. Greene PE, Fahn S. Use of botulinum toxin type F injections to treat torticollis in patients with immunity to botulinum toxin type A. *Mov Disord* 1993;8:479–83.
91. Koman LA, Mooney JF III, Smith B, Goodman A, Mulvaney T. Management of cerebral palsy with botulinum-A toxin: preliminary investigation. *J Pediatr Orthop* 1993;13:489–95.
92. Fehlings D, Rang M, Glazier J, Steele C. An evaluation of botulinum-A toxin injections to improve upper extremity function in children with hemiplegic cerebral palsy [see comments]. *J Pediatr* 2000;137:331–7.
93. Graham HK, Aoki KR, Autti-Ramo I, et al. Recommendations for the use of botulinum toxin type A in the management of cerebral palsy. *Gait Posture* 2000;11:67–79.
94. Tarczynska M, Karski T, Abobaker S. [Hip dislocation in children with cerebral palsy—the result of illness or treatment error]. *Ann Univ Mariae Curie Sklodowska [Med]* 1997;52:95–102.
95. Crenshaw S, Herzog R, Castagno P, et al. The efficacy of tone-reducing features in orthotics on the gait of children with spastic diplegic cerebral palsy. *J Pediatr Orthop* 2000;20:210–6.
96. Radtka SA, Skinner SR, Dixon DM, Johanson ME. A comparison of gait with solid, dynamic, and no ankle-foot orthoses in children with spastic cerebral palsy [see comments] [published erratum appears in *Phys Ther* 1998;78(2):222–4]. *Phys Ther* 1997;77:395–409.
97. Ricks NR, Eilert RE. Effects of inhibitory casts and orthoses on bony alignment of foot and ankle during weight-bearing in children with spasticity. *Dev Med Child Neurol* 1993;35:11–6.
98. Bertoti DB. Effect of short leg casting on ambulation in children with cerebral palsy. *Phys Ther* 1986;66:1522–9.
99. Cruickshank DA, O'Neill DL. Upper extremity inhibitive casting in a boy with spastic quadriplegia. *Am J Occup Ther* 1990;44:552–5.
100. Otis JC, Root L, Kroll MA. Measurement of plantar flexor spasticity during treatment with tone-reducing casts. *J Pediatr Orthop* 1985;5: 682–6.
101. Lesny IA. Follow-up study of hypotonic forms of cerebral palsy. *Brain Dev* 1979;1:87–90.
102. Nelson KB, Ellenberg JH. Neonatal signs as predictors of cerebral palsy. *Pediatrics* 1979;64:225–32.
103. Thajeb P. The syndrome of delayed posthemiplegic hemidystonia, hemiatrophy, and partial seizure: clinical, neuroimaging, and motor-evoked potential studies. *Clin Neurol Neurosurg* 1996;98:207–12.
104. Barry MJ, VanSwearingen JM, Albright AL. Reliability and responsiveness of the Barry-Albright Dystonia Scale. *Dev Med Child Neurol* 1999;41:404–11.
105. Ford B, Greene P, Louis ED, et al. Use of intrathecal baclofen in the treatment of patients with dystonia. *Arch Neurol* 1996;53:1241–6.

106. Gros C, Frerebeau P, Perez-Dominguez E, Bazin M, Privat JM. Long term results of stereotaxic surgery for infantile dystonia and dyskinesia. *Neurochirurgia (Stuttg)* 1976;19:171–8.
107. Lin JJ, Lin GY, Shih C, Lin SZ, Chang DC, Lee CC. Benefit of bilateral pallidotomy in the treatment of generalized dystonia. Case report. *J Neurosurg* 1999;90:974–6.
108. Vitek JL, Chockkan V, Zhang JY, et al. Neuronal activity in the basal ganglia in patients with generalized dystonia and hemiballismus. *Ann Neurol* 1999;46:22–35.
109. Kyllerman M. Reduced optimality in pre- and perinatal conditions in dyskinetic cerebral palsy—distribution and comparison to controls. *Neuropediatrics* 1983;14:29–36.
110. Acardi J. *Diseases of the Nervous System in Childhood*. Oxford, England: Mac Keith Press, 1992:1408.
111. O'Reilly DE, Walentynowicz JE. Etiological factors in cerebral palsy: an historical review. *Dev Med Child Neurol* 1981;23:633–42.
112. Johnson RK, Goran MI, Ferrara MS, Poehlman ET. Athetosis increases resting metabolic rate in adults with cerebral palsy. *J Am Diet Assoc* 1996;96:145–8.
113. Fraioli B, Nucci F, Baldassarre L. Bilateral cervical posterior rhizotomy: effects on dystonia and athetosis, on respiration and other autonomic functions. *Appl Neurophysiol* 1977;40:26–40.
114. Davis R, Barolat-Romana G, Engle H. Chronic cerebellar stimulation for cerebral palsy—five-year study. *Acta Neurochir Suppl* 1980;30:317–32.
115. Ebara S, Harada T, Yamazaki Y, et al. Unstable cervical spine in athetoid cerebral palsy [published erratum appears in *Spine* 1990; 15(1):59]. *Spine* 1989;14:1154–9.
116. Fuji T, Yonenobu K, Fujiwara K, et al. Cervical radiculopathy or myelopathy secondary to athetoid cerebral palsy. *J Bone Joint Surg [Am]* 1987;69:815–21.
117. Kidron D, Steiner I, Melamed E. Late-onset progressive radiculomyelopathy in patients with cervical athetoid-dystonic cerebral palsy. *Eur Neurol* 1987;27:164–6.
118. Nishihara N, Tanabe G, Nakahara S, Imai T, Murakawa H. Surgical treatment of cervical spondylotic myelopathy complicating athetoid cerebral palsy. *J Bone Joint Surg [Br]* 1984;66:504–8.
119. Wang PY, Chen RC. Cervical spondylotic radiculomyelopathy caused by athetoid-dystonic cerebral palsy—clinical evaluation of 2 cases. *Taiwan I Hsueh Hui Tsa Chih* 1985;84:986–94.
120. Watanuki K, Takahashi M, Ikeda T. Perception of surrounding space controls posture, gaze, and sensation during Coriolis stimulation. *Aviat Space Environ Med* 2000;71:381–7.

Therapy, Education, and Other Treatment Modalities

Almost all children with cerebral palsy (CP) will receive therapy and go to school. Most of the therapy has to be ordered by physicians as part of the medical treatment of the CP. Because education is a universal experience in the lives of these children, it behooves the physicians treating the motor impairments to have some understanding of the educational system. These children often receive therapy as early as in the neonatal intensive care nursery. This early therapy is provided in a medically-based construct. As the children get older, especially over age 3 years, the main intervention shifts to the educational system, and much of this therapy also shifts into the education milieu. As these children enter grade school, except for periods of acute medical treatment, education is predominant with therapy occurring within this context. During the children's growth and development, the therapists provide the best bridge between the education and medical systems. The final physical and emotional function and independence of these children depends on intervention by both the medical and educational systems; therefore, the bridging effect provided by the therapists is an important aspect. In addition to the standard therapy treatment in education, there are many treatment modalities that are promoted as beneficial for CP treatment. Some of these modalities may start as an alternative medicine approach, such as hippotherapy, but then develop acceptance within traditional medicine. Others, such as hyperbaric oxygen therapy, develop a reputation of possible benefit but, upon careful investigation, their validity is discredited. The physician who treats the motor impairments of children with CP should understand the techniques, goals, and expected outcomes of therapies they order while also understanding the educational context in which these children function.

Therapy

In this discussion, the term therapy applies to physical, occupational, or speech therapy, all disciplines trained in the milieu of the medical system, although these individuals often work in the educational system. These disciplines overlap significantly; however, each has a very defined area of expertise. Physical therapy focuses on gross motor function, such as walking, running, jumping, and joint range of motion. There is some overlap with occupational therapy, where the main focus is on fine motor skills, specifically upper extremity function and activities of daily living such as dressing, toileting, and bathing. This overlap between physical and occupational therapy occurs in the areas of seating and infant stimulation programs where both therapists perform the same function. Speech therapists focus on oral motor

activities such as speech, chewing, and swallowing. A subspecialist speech therapist will do augmentative communication evaluations. Speech and occupational therapy overlap in the area of teaching feeding skills to caretakers and self-feeding therapy for patients. The specific areas of practice of each of the therapy disciplines vary slightly among geographic regions and facilities. A major focus of all therapy is to maximize the individual's independence. The goal of this discussion on the therapy disciplines is not to promote a full review of each discipline, but to provide only the information that a physician who treats children concurrently with the therapist should possess. Also, most of this discussion is directed at the musculoskeletal motor impairments because that is the focus of this text; however, it must be remembered that speech and communication are usually rated as more important by individuals with disabilities.

Physical Therapy

Applying physical therapy to children with CP is common and has a large body of published data. Since 1990, there have been approximately 300 citations in the National Library of Medicine reporting the use of physical therapy in children with CP. Most of these papers report physical therapy being used in conjunction with other treatments, such as surgical hip reconstructions or lower extremity reconstructions for gait improvement, or following dorsal rhizotomy and Botox injections. Many of these reports are case series without controls to evaluate the index procedure, and most make no objective attempt to evaluate the impact of the therapy program separately from other modalities. The number of reports attempting to evaluate the impact of specific therapy programs is increasing; however, many contain few patients and no control groups.¹ The role of physical therapists, and the therapy they provide to these children, is very complex. Many reports presume that physical therapy is like medication in that it can be evaluated by having a control group with no treatment. This research approach has some merit if no effect is found, such as the evaluation of therapy in infant stimulation programs.² However, when a positive effect is found, the intimate, personal interaction that physical therapy requires with the children and parents makes it very difficult to sort out what effect the specific therapeutic regimen or a specific treatment had on the outcome. Recognizing these complex interactions has led to recommending more complex and global evaluations using multivariate analysis in research protocols.³ This trend in therapy research should be incorporated into the evaluation of all CP impairments because it has the potential to impart a better understanding of the effect of each modality in the treatment routine. For example, a treatment protocol where physical therapy modalities along with casting and Botox are used to treat gait abnormality in young children cannot be reasonably evaluated by any other means. Recognizing the complex interaction of physical therapy in its own right will lead to improved research techniques for other treatments as well.

The long history of physical therapy has been predominated by different theories of development and specific protocols to impact childhood development.⁴ Most of these therapy protocols were designed with a theoretical understanding that distal lower-level functions will influence higher-level cortical functions to develop. In this theory the spinal cord-mediated activities, such as single synapse reflexes and spasticity, have to be corrected first before the more primitive higher reflexes can be addressed. These primitive reflexes then have to be corrected before high-functioning cortical motor

activities, such as walking, can develop properly. This hierarchical theory of neurologic development has some base in animal studies. For example, the need for the eye to function properly before the optical cortex will organize and function appropriately is well documented.⁵ All the major therapy protocols developed and used in modern medicine before the 1990s were based on this hierarchical theory of development.⁴ These protocols are still widely used in pediatric physical therapy today, and are described briefly here because parents often ask for explanations of the relative importance of one therapy technique over another. The scope of this text, however, makes it impossible to give a full description of these techniques. In the 1990s, the theory of neurologic development was slowly changing to a more complex, circular theory in which subsystems are recognized to interact. In this theory, the psychological state and behavior of children are also recognized as being important in their motor function. Complex interactions exist between lower reflexes and cortical motor movement patterns, in which the interactions and impacts are both from the higher function to the lower function and vice versa.⁶ This change in motor development theory has required physical therapists to incorporate multiple facets of the therapy experience and has led to the therapist becoming more a teacher or coach and less a technician who applies a treatment to a child. However, this change in approach is not universally adapted, because neurologic pediatric physical therapy is a small subspecialty of the much larger physical therapy discipline. In general, physical therapists tend to have clinical aptitudes that are similar to those of orthopaedic surgeons. Clinicians with a treatment approach like to identify a specific problem, then apply a cure to make the problem go away. This approach was feasible in the early therapy protocols based on the hierarchical development theory; however, it often frustrated the child, the family, and the therapist. Developing a concept where the child, family, physician, and therapist are one team whose goal is to make the child as independent as he or she can be when growing up is a much more functional approach. With this approach, an experienced therapist is the ideal head coach of the team, because this is the individual who knows the child best from a medical perspective and has the best relationship with the child, family, educators, and physicians. Unfortunately, because of frequent changes in therapists, this role of head coach often falls to the family. For some families, this works well, but for others, it does not.

The therapist who takes on the role of coach of a child's motor impairment management team has to develop a good relationship with the family and child. In general, this relationship does not work well if the parent or child does not like the therapist. Also, the therapist has to have some understanding of behavior management techniques to get the most cooperation from a child. Being aware of medical and other family issues is also important. The physical therapist should understand how to access social services and medical help in the community that may be needed by the family. One of the problems of this expanded role of pediatric therapists is that many therapists do not believe they have the training needed to take on this role. Most physical therapy training programs are at the master's degree level; however, the amount of training in pediatrics is minimal in many programs where there is a much greater allure to sports medicine and other adult rehabilitation directions. This experience mirrors what happens in orthopaedic training. Currently, there are a few well-developed specialty training programs for pediatric therapists, and none as well organized as the fellowship programs in pediatric orthopaedics. The trend to standardize this pediatric training is moving ahead and should train therapists who are much better equipped to take on the role in which they are currently expected to function.

Major Therapy Protocols

All modern major therapy protocols were developed from a hierarchical understanding of neurologic motor development. Many of these protocols have high regional concentrations of use, often in the area in which the system was initially developed and popularized. The same theories of therapy are widely used among both occupational and physical therapy.

Neurodevelopmental Treatment Approach (NDT): Bobath Technique

The NDT treatment approach was developed in England in the 1940s and 1950s by Dr. and Mrs. Bobath based on their understanding of neurologic development and experience gained in treating children.⁷ Because of the well-developed concepts, clear rational approach, and the missionary zeal of its developer, the NDT approach has become the most widely used uniform approach of therapy worldwide. Based on the hierarchical concept of understanding development, this approach focused first on correcting abnormal tone through the use of range-of-motion exercises, encouraging normal motor patterns, and positioning. Second, abnormal primitive reflexes are addressed through the use of extinction by repeated stimulation.⁷ Then, the third goal is to work on automatic reactions, such as placing a hand out in front when a fall is anticipated as in the parachute response. Another example is neck flexion as the child is falling backward to prevent the head from hitting. Altering sensory input by careful handling and positioning is also an important aspect to achieving the first three goals.⁴ This aspect includes handling the child in patterns of normal movement and avoiding abnormal posturing. By having the child experience only normal movements, the brain will gradually remember the normal movements and forget the abnormal postures used by the immature brain. The requirement of very early treatment, under the theory that the more immature the brain is, the more it can be influenced to develop normally, is also stressed in NDT therapy. Another important aspect of this treatment is the insistence that the parents learn, and at all times apply, these correct handling techniques. In the earlier years of the technique, there was great focus on idealized movements, such as the perfect way to come to a sitting position from lying; however, focus has more recently been on functional patterns that work for the child.

The outcome of research has largely failed to show the benefits proposed by the founders of NDT techniques. Compared with other therapy techniques, or no therapy, there are few significant specific functional gains from the NDT approach.⁸⁻¹¹ There is one study suggesting earlier therapy is better, as predicted by NDT therapy¹²; however, more recent and better-controlled studies show no impact of earlier therapy versus no early therapy.^{2, 13} There is also no evidence that NDT therapy can impact spasticity or primitive reflexes or specifically improve higher motor functioning. Despite the marginal evidence for direct benefit, NDT still has a widespread use, with some therapists maintaining the missionary zeal of avoiding specific movements in a child, such as extensor posturing. These therapists also focus on the children having correct crawling before they can stand or walk, and having them walk correctly with a walker before they can walk independently. This kind of missionary rigidity is inappropriate, and parents can be informed that they do not need to feel guilty when things do not happen exactly as the therapist requests. Because the objective data supporting the efficacy of NDT treatment are marginal, there is very little role for enforcing these concepts rigidly, although they may be perfectly legitimate techniques to help teach children correct movement.

Sensory Motor Treatment Approach: The Rood Technique

The sensory motor treatment approach was developed by Margaret Rood in the United States during the 1950s. Ms. Rood was trained as a physical and occupational therapist. This approach uses the same hierarchical understanding of neuromotor development, and was developed in approximately the same time period, as the NDT protocols. The sensory motor technique depends heavily on tactile stimulation to facilitate movement. The overall goal of sensory motor therapy is to activate the movements at an autonomic level similar to how postural responses in normal individuals are activated. This activation requires superimposing mobility as produced by basic muscle responses onto stability, which is produced by tonic muscle responses. Sensory motor technique uses a series of eight clearly defined developmental patterns, which children are to learn in sequence. These patterns are supine withdrawal, rolling over, pivot prone, neck co-contraction, elbow weight bearing, all four weight bearing, standing, and walking. This system incorporates many concepts similar to NDT but focuses much more on tactile stimulation and more specific functional movement patterns, as outlined in the eight steps of development. This technique was not developed for use in children, but rather for rehabilitation following brain injury. The Rood technique has been widely applied to children with CP; however, there are no reports that specifically document its efficacy. Many of the parameters of sensory motor therapy have been integrated into the NDT approach as it is currently used.⁴

Sensory Integration Treatment Approach: The Ayers Technique

This treatment approach was developed in the 1970s by A.J. Ayers, who is trained as an occupational therapist. The basic goal of this therapy technique is to teach children how to integrate their sensory feedback and then produce useful and purposeful motor responses. The sensory integration approach tries to have these children access and integrate all their sensory input to use for functional gain. Activities such as catching a ball in different positions may be used as a way of stimulating and requiring integration of visual, vestibular, and joint proprioception feedback systems at the same time. This system's underlying theory is that sensory input followed by appropriate motor function will contribute to the improved development of higher cortical motor sensory function. For young children, a single system stimulation may be used. Typical stimulations include vestibular stimulation in a swing and tactile stimulation by stroking, rubbing, massaging, or swaddling. Educating the parents is recognized as an important aspect of the treatment, especially in helping parents understand these children's problems. However, most of the treatments are therapist directed or -performed. This technique has also been applied to children with mental retardation and Down syndrome. There are no papers documenting its efficacy in children with CP.⁴ The understanding of the importance of sensory integration, especially for children with tactile defensiveness, is usually incorporated in the modern therapy programs for children with CP.

The Vojta Technique

The Vojta technique was developed in Czechoslovakia by Dr. Vojta in the 1950s and 1960s. This approach is applied to young infants and requires an assessment of each infant by identifying four grades of central motor coordination disturbance. The goals of this approach are to prevent at-risk infants from developing CP and decrease the effect or severity of CP in those

who do develop symptoms. The basic treatment is to use proprioceptive trigger points on the trunk and extremities to initiate reflex movement, which produces rolling, crawling, and other specific functions. These massages and stimulations have to be done every day by the family, and the treatment is believed to be of most benefit in the first or second year of life.¹⁴ The efficacy of the Vojta technique has been reported as positive in uncontrolled studies,¹⁵ even causing a dislocated hip to reduce¹⁶; however, in studies compared with other approaches, there is no positive effect.^{4, 17} This technique continues to be widely practiced in Europe and Japan and is sometimes combined with acupuncture.¹⁸ The Vojta approach is used much less in North and South America.

Patterning Therapy: Doman–Delacato Technique

Patterning therapy was developed by G. Doman, a physical therapist; R. Doman, M.D.; and C. Delacato, an educator. This therapy was based on the theory of recapitulation of species developed by Temple-Fay in the 1940s.⁴ This theory espouses that during development, immature activities such as reflex activities start first, and that these activities will stimulate higher brain functioning activities to develop. Furthermore, doing the activity frequently will imprint it on the brain and stimulate the brain to develop the next higher function. Sensory integration and stimulation are included as well. In recapitulation theory in combination with the hierarchical development theory, children turn over first, then crawl, which stimulates walking with all four limbs. This four-limb walking then stimulates the brain to develop bipedal standing, in turn stimulating intellectual development. This protocol also includes stimulating children to make vocal sounds and specific sensory stimulation, somewhat similar to the Vojta technique. The concept of recapitulation comes from the belief that children start out moving first by crawling like a worm, then moving like a fish, followed by walking on all fours like a quadruped animal, until finally reaching the human phase of biped walking. A unique aspect of the patterning approach is a heavy focus on doing the therapy for many hours each day, 7 days a week, every week of the year. Parents are taught the techniques and are encouraged to mount a community effort to get volunteers into the home to continue the therapy for almost all these children's waking hours. This therapy requires a huge commitment by parents and often raises the parents' hopes above what is realistic to accomplish.

The patterning approach to therapy was especially popular in the 1960s and 1970s in California and in the Philadelphia area where there were specially developed centers. There is no scientific evidence that this approach yields any of the claimed benefits. We have had many patients whose parents pursued patterning therapy for a time at some level, usually less than recommended by the original approach. There is no evidence to suggest that neurologic imprinting works; however, the extensive amount of passive range of motion many of these children receive seems to prevent contracture development. Clearly, however, the benefits are not worth the cost in time and commitment for families. During the height of patterning's popularity, there were many severely disappointed parents, several ending in parental suicides. The high rate of inappropriate expectations among parents leading to severe problems led many medical societies to issue statements condemning patterning therapy.^{4, 19–21} Over the past 10 years, patterning therapy has almost disappeared, even in the region of Philadelphia, which was its last stronghold. Very little of this approach can be functionally applied, except to use it as an example of the damage that can be caused by an inappropriate therapy approach.

Conductive Education: Peto Technique

Conductive education was developed in Budapest, Hungary, in the 1940s and 1950s by Andreas Peto as an educational technique for children with CP. In North America and the rest of Europe, this has come to be viewed as a physical therapy approach. The children were treated by conductors in a facility where they lived full time. The treatment was based on educational principles in which motor skills that children could just barely perform were identified, then they were assisted over and over again until the skill was learned. This approach is the same as is typically used to teach the multiplication tables. Conductive education also includes a great emphasis on instilling a sense of self-worth and a sense of accomplishment in the children. The motor skills were performed with a series of simple ladder-type devices that can be used to assist standing, stepping, walking, and even sitting activities. This approach is only applicable to individuals with some useful motor function, but not such a high level of function that they are essentially independent ambulators. Based on this indication, approximately 35% of children with CP are candidates for conductive education.²² Studies of the efficacy of conductive education suggest that it is equal to standard therapy programs,²³ or may be slightly better at teaching motor skills.^{24, 25} The elements of the program that can be incorporated into the day school setting are a useful addition, and this approach to therapy fits into the more recent trends, which are focused on educational techniques rather than preconceived theories of neurodevelopment.

Electrical Stimulation

Electrical stimulation has always been a basic modality of physical therapy practice. The physical therapy department at Guy's Hospital in London in the 1840s was called the Electrical Department.²⁶ Electrical stimulation in children with CP can be functional electrical stimulation (FES) with neuromuscular electrical stimulation (NMES), or transcutaneous electrical nerve stimulation (TENS). Functional electrical stimulation means the electrical stimulation is done with the goal of causing a functional muscle contraction, such as stimulating the anterior tibialis muscle directly to cause a contraction that produces dorsiflexion. The main uses of FES in children with CP are for wrist extension and ankle dorsiflexion. The muscle may also be activated by stimulating transcutaneously or via percutaneous wires. A major problem with FES in children with intact sensory systems is the level of pain caused by this stimulation. In a group of individuals with hemiplegia, including mostly adults, the percutaneous stimulation is less painful and better tolerated than transcutaneous stimulation.²⁷ Most children are not greatly enthused by frequent stimulating wires being inserted into their muscles, which makes this percutaneous technique of minimal use in children, although there have been a few positive reports from small case series.^{28–31} Another study found no improvement in gait, although passive dorsiflexion improved.³² Because of the pain caused by FES, its minimal use is primarily in adolescents because they may be able to tolerate the discomfort. There have been no studies that suggest any long-term benefit, and unless long-term benefit can be demonstrated, there is no reason to cause a significant amount of pain by doing a therapy session with electrical stimulation.

Therapeutic electric stimulation (TES) is the use of electric stimulation below a level where muscle contraction occurs. The goal of TES is to stimulate muscle hypertrophy and strength. This technique has been widely promoted by Pape et al.³³ as a means of improving gross motor function, locomotion, and balance. This electrical stimulation is applied at night and is

worn during sleep hours. The level of electrical stimulation is just at or below the level a child can feel. No muscle activity is initiated, and the theory for how this stimulation causes muscle hypertrophy is based on the alleged increased blood flow. Daytime TES has been proposed using slightly higher stimulation at a level at which children can feel the stimulation, but where it is not uncomfortable and causes no muscle contraction. This level would be used during therapy sessions to assist in motor learning.²⁶ There has been little or no published literature to objectively evaluate TES except that published by the developers, and there is one study reporting that it was well tolerated for 1 year of use.³⁴ This technique has a potential for benefiting some children and would be an easy project for double-blind evaluation. Our experience is that there was very minimal functional benefit in the five or six children whom we followed while using TES over a period of time. At this time, there is no good clear indication for the use of either FES or TES in children with CP.

Tone-Reducing Casts

The concept of using casts as a method to decrease tone was initially proposed by Sussman and Kuszc.³⁵ This technique consists of applying casts with toe extension and molding insole pressure points, which are supposed to decrease spasticity and cause the muscle to lengthen. This concept, variously described as tone-reducing features, inhibitive casts, or serial casting, has been widely promoted in the physical therapy discipline; however, there is no objective evidence that it has any long-term benefit. Wearing casts and having frequent applications is very energy and time consuming for families. Whatever benefit these casts provide, the same can be gained from properly constructed ankle-foot orthoses (AFOs), as described in the section on orthotics. There is little role for the use of casts in children with CP for the treatment of chronic spasticity or contractures.

Muscle Strengthening

There has been a long-held tradition that children with spasticity should not be encouraged to do muscle-strengthening exercises; however, excellent studies by Damiano et al.^{36, 37} have shown clear benefits from minimal strengthening work. As few as three times a week for a 6-week period of strengthening led to improvement in crouch gait.³⁶ Although this was thought to be due to strengthening of the rectus femoris muscle, it was far more likely the result of the strengthening effect on the gastrocsoleus because crouch in midstance phase is not controlled by the rectus muscle. This work has, however, clearly shown positive effects, which has also been our personal experience. Based on this work, many therapy protocols, especially postoperative rehabilitation protocols, should include muscle strengthening as a component of the program.

Enforced-Use Therapy

Enforced-use therapy is based on the concept that potential function is not used because the functional component of the motor control is ignored through long-term disuse. This is the basis of the widespread use of eyepatch treatment of strabismus and amblyopia (“lazy eye”) in childhood. There have been periodic attempts to use this concept by short-term immobilization of the good arm in children with hemiplegia, but this practice has developed a reputation for only frustrating the child. The current concept of enforced-use therapy involves total immobilization with aggressive therapy directed at learning such functional tasks as eating and dressing. We are using this treatment in children with hemiplegia whose involved limb shows

promise of better functional use than the family is observing during daily activities at home. The current protocol uses a long arm cast, with the elbow flexed 70° to 80° so that the child cannot use the arm for feeding or reaching the face. The cast is left on for 4 weeks, during which time the child receives therapy 3 times a week. The parents also receive instructions to encouraging the child to be independent by forcing use of the hemiplegic arm. After the cast is removed, therapy is recommended for an additional 4 to 8 weeks. Based on limited experience, parents are reporting significant improvements in functional use of the limb. There does not seem to be a place for this approach in the leg, because walking by nature requires both limbs and is an enforced-use function. This approach to enforced-use therapy in children with cerebral palsy is new, and many questions need to be answered before specific recommendations for routine use can be formulated. No data currently exists to determine at what age child this works best, what level of physical disability responds best or worst, how long the benefit lasts, if there is a role for repeating the immobilization of the unaffected arm, or how long the arm should be immobilized. Based on current knowledge, enforced-use therapy looks like a useful treatment intervention, and many of the questions will likely be answered over the next several years to allow much better definition of the specific protocol and outcome expectations.

A Current Physical Therapy Approach

Current pediatric physical therapists are moving toward an intellectual construct of being a coach or teacher of a child's motor system instead of a molder of the brain as the child develops. This modern approach more often uses the understanding of dynamic motor control to structure tasks and change motor patterns. This new approach requires a broader view of the child and has to include an understanding of how he or she is functioning in the home, family, and school environment. This approach also places the therapist in a much better position to bridge the gap between the educational and medical systems. Another important focus required in this role as teacher or coach is a realistic assessment of the child's ability. For example, teachers have to routinely make realistic assessments concerning the functional ability of a child to learn specific material. Normal children have a widely variable ability to learn a level of mathematics at each age level, and teachers have to be aware of the level of the individual child. Some children in fourth grade may still be struggling to learn addition, while others are ready to learn geometry, but none would be ready to do calculus. In a community population of children, many will never be able to develop enough math skills to learn advanced calculus. Using this same analogy, the physical therapist needs to have a good ability to understand what the possibilities are for each individual child, while at the same time continuing to motivate the child to improve his motor skills. Understanding the child's functional possibilities means the therapist can avoid frustrating them with unreasonable demands and help their parents understand reasonable functional goals for the child.

The strategy for physical therapy is very dependent on age and functional ability.⁶ The general treatment approach varies significantly over the age spectrum. Added to the age appropriateness, the therapy plan should have specific objective, quantifiable short-term goals. Such goals include improving how long the child can stand on one leg, learning to jump, using a walker independently, or improving a specific amount on a global measure such as the Gross Motor Function Measure (GMFM). These specific short-term goals can help the therapist, child, and parents judge progress. Also, this type of goal setting is an important part in the reimbursement of therapy services

from insurance companies. Another part of the treatment plan includes teaching the family how to handle the child, teaching the child and family an exercise program, assessing the general function of the family in the home environment, and helping the family understand the long-term expectations of the child. A difficult aspect of the therapist's treatment plan is integrating the child's other medical treatments with fragmented medical care. The time constraint, which does not give the therapist time to attend medical appointments, leaves many therapists to gather this information from parents. Obtaining medical notes from physician visits can be another mechanism for the therapist to stay informed.⁶

Specific Age Periods

Infant

There has been considerable focus on the impact of early childhood infant stimulation programs, especially for infants from newborn intensive care units who are at risk for developing CP. The treatment program at this age, which is carried out by either a physical or occupational therapist, usually includes a combination of stimulation through handling the children, sensory stimulation through positional changes, and getting the children into correct seating. Many of the techniques used in infant stimulation approaches are combinations of NDT, sensory motor, and sensory integration approaches. Therapy frequency at this age may be two or three times a week; however, care should be taken not to place too high a burden on new parents with many medical visits. We have seen one very frustrated mother who was scheduled to see 21 medical practitioners for an 18-month-old child who had been discharged from an intensive care unit (Table 5.1). This number is far too much of a burden, and the therapists are in a good position to sense this and help parents decide what is reasonable. This is especially helpful when there are frequent team-generated treatment plans saying, for example, that a child should have four physical therapy treatment sessions in a week; however, due to the therapists' schedules, he will be scheduled to see three different therapists in 1 week. This is the worst kind of fragmented care, and it is very frustrating to parents. To parents and children, therapy is an intimate relationship and there is little benefit when it is scheduled based on whoever can be found to do therapy that day. Many of these parents will become very confused after hearing slightly different assessments from each therapist, often with different words to describe the same concern. This scenario is to be avoided; it is far better to have fewer sessions with a consistent therapist. The efficacy of early childhood therapy has not been well documented objectively, with most studies showing no or marginal measurable benefit.^{4, 13, 38, 39}

Early Childhood

At 18 to 24 months of age, there is usually no longer any question as to the diagnosis of CP. This period, from 1.5 to 5 years of age, is the age of primary motor learning and the time when therapy potentially has the most impact. This time continues to be crucial in the parents' coming to understand their children's disabilities as the impairments are slowly becoming more apparent. A close, consistent relationship with a single therapist is especially beneficial during this time. This is the period where setting concrete short-term goals works well because of the children's rapid maturation, and this is also when much of children's play and free exploration time is motor based if they have sufficient motor ability for self movement. There are many developing adaptive equipment needs that also have to be assessed, fitted, and ordered for the children during this phase. In early childhood, the phys-

Table 5.1. All the professionals treating a 2-year-old child who had a prolonged stay in the newborn intensive care unit.

1. Nurses evaluating the child but providing no direct care
 - Home visiting nurse
 - Special high-risk newborn program nurse
 - School nurse
2. Physical therapist
 - Home visiting therapist
 - Two school therapists
3. Occupational therapist
 - School therapist
4. Speech therapist
 - School therapist
 - Special feeding therapist
 - Home visiting therapist
5. Social workers
 - Home visiting social worker
 - Medical counseling social worker for high-risk newborns
6. Psychologist
7. Special coordinators
 - Neonatal special program coordinator
 - Early childhood program coordinator
8. Doctors
 - General pediatrician
 - Developmental pediatrician
 - Neonatologist
 - Neurologist
 - Orthopaedist
 - Neurosurgeon
 - Ophthalmologist

The mother was visiting 21 medical professionals, many at least once a week, who were often giving the mother conflicting recommendations.

ical therapist will be focusing on gross motor skills, such as walking, and the occupational therapist will focus on fine motor skills, such as writing, using scissors, and self-feeding. Adaptive seating is important in this period, especially for feeding, toileting, and floor sitting. In establishing a treatment approach, most therapists borrow from the three predominant approaches, combined with using a model of teaching a task that involves cognitive understanding and repetition. This early childhood period is also a time when concepts from dynamic motor theory can be employed, with the goal of trying to alter the system in ways that will allow a task to find a new chaotic attractor.⁴⁰ An example of this might be using an unstable support, such as a cane in walking, to see if a child will find a better movement pattern compared with the pattern used in a walker in which he can go fast, but with very uncoordinated lower extremities. Therapy frequency at this age is variable, usually between two to four sessions per week while progress is documented. Some children will develop periods of frustration, and it may be better to give them a break of several months, and then restart therapy again. Efficacy of early childhood therapy has also been difficult to prove, although an educational model has demonstrated some improvement,⁴¹ as has an NDT approach.⁴²

Middle Childhood

Middle childhood, from approximately 5 to 10 years of age, is when the focus of children's development is shifting from primary motor to cognitive

learning. Children with good cognitive function will be transitioning into school environments, where gradually more time is taken up with cognitive learning. In this period, therapy routines should be significantly reduced, especially if they start to interfere with cognitive learning. Many children at this age can have the frequency of therapy reduced to observer status, or even discontinued if gross motor skills have plateaued. This time is also when very specific treatment goals are addressed, such as learning to use crutches instead of a walker. In this approach, a period of intensive crutch training therapy would be scheduled with the end goal being teaching these children to use crutches. Another important task at this age is the transition to regular sports activities in the community. The therapist is in an excellent position to recommend an appropriate sport activity based on an individual child's functional mobility and community availability. Sport activities that are useful to consider are horseback riding, swimming, martial arts, skating, dancing, T-ball, softball, and bicycling. For children with limited cognitive ability, focus continues to be on motor learning during middle childhood. This is the age when many children with limited cognitive function and mild CP learn to walk. The same treatment approach used in early childhood can be continued into middle childhood for this group. Frequency of therapy may vary from one to three times per week. Efficacy of therapy for this age group has not been specifically reported.

Adolescence

For individuals with good cognitive function, this period from 10 to 16 years focuses on cognitive training and there is no role for ongoing maintenance therapy, except to address specific disabilities with a goal-focused therapeutic approach at a time when there is no interference with age-appropriate cognitive learning. For a few motivated individuals, this period during adolescent growth can be a time to push to new levels of independence. However, almost no situation exists where there is a justification for children in normal classrooms to be removed from, for example, spelling class every week to receive therapy. Clearly, the long-term benefit of spelling class is much greater than the benefit of therapy to the point where it would be unethical to even entertain this kind of scenario. Therefore, intellectually normal children, regardless of their physical disabilities, should not be routinely removed from academic classes to receive therapy. However, this is a time period when teaching specific tasks, using a cognitive-based approach, can be very beneficial. This teaching will be especially beneficial if they are tasks that children will integrate into their activities of daily living and continue to use. Once learned, adolescents maintain these tasks long term.⁸ Another important aspect of physical therapy for adolescents is learning to be responsible for their own stretching and physical activity. During adolescence is also the time when long-term functional motor skills can be defined, so it is important to help the family and the patient to understand these and develop plans to maximize independence within the context of these limitations. Whenever possible, the therapist should be fostering independence by encouraging the individual to get involved in appropriate physical activities and sports. Adolescents with limited cognitive ability will continue to focus on motor learning, and on rare occasions, it is possible to teach children to walk independently up to age 11 or 12 years. This means children with severe mental retardation should continue to be stimulated toward motor activities as well as other stimulation. Frequency of therapy is variable and almost always in the milieu of the educational system.

Young Adults

By young adulthood, there is little role for ongoing chronic physical therapy except to address specific functional goals. Individuals with good cognitive function should be doing their own stretching and physical activity routine if physically able, just as individuals with no disability are expected to take on their own responsibility for health and well-being. For individuals with limited cognitive ability, caretakers should be instructed on routine stretching and having a program of physical activity.

Therapy Settings

Child's Home

Home-based therapy is advantageous for the therapist to evaluate the home environment and set appropriate goals based on this environment. The home is often used for infant and early childhood therapy because children are comfortable here and it is convenient for new parents. The home setting is also useful for therapy immediately after surgery, when children may be uncomfortable moving into an automobile, or because their size and decreased function in the postoperative period makes physically moving them very difficult. The difficulty with home-based therapy is the limited availability of equipment and space in which to conduct the therapy. Also, much of the therapist's time is taken up with travel, which increases the cost of the therapy. Because of the increased cost, insurance companies will usually not pay for home therapy unless there is an extenuating specific reason why home therapy is required over therapy in a facility.

Medical, Clinic, or Outpatient Hospital Department

The ideal location for most therapy is an established physical or occupational therapy department. This location is especially important in early and middle childhood where gait training is the primary focus. This location is also ideal for postoperative rehabilitation because it provides the therapist with the equipment and space needed to do the therapy. Also, children come to this location expecting to work at therapy, and it is cost effective for the therapist's time. However, it may not be cost effective for the family, especially a family in which both parents work and the only times to do the therapy are during the daytime working hours.

Inpatient Hospital Rehabilitation

Before 1990, inpatient rehabilitation programs were commonly used for individuals with CP, especially for postoperative rehabilitation. These programs have decreased greatly because of the refusal of insurance companies to pay for the care as there is no good evidence that inpatient therapy is better than outpatient therapy. Today, the role of inpatient rehabilitation therapy is limited to very specific situations where multiple disciplines are needed in a concentrated time period. Such an example might be an individual with good cognitive function who has limited ability to receive therapy during the school year because of academic learning constraints, but would benefit from intensive therapy to assist with independence gaining skills such as self-dressing, self-bathing, improved walking, and wheelchair transfers. For the individual in late childhood or adolescence, an intensive 2- to 4-week inpatient therapy program can provide significant long-term yields. For this to be successful and for insurance companies to pay, a very detailed and specific goal has to be defined before the therapy stay. Both children and



Figure 5.1. The MOVE Program is an education-based program that depends heavily on assistive devices to teach mobility. These devices demonstrate the increasing overlap of the techniques used by therapists and educators.

parents need to have a desire and commitment to make the goals and then to follow through with the goals at home after the therapy admission.

School-Based Therapy

After age 3 years, many children with CP spend most of time during the day in a school environment and therapy is often provided in school. There has been a tendency to try to segregate educational therapy from medical therapy. Educational therapy is defined as therapy that furthers children's educational goals, whereas medical therapy is directed at treating medical impairments. In some situations, these differences are clear. For example, a child who needs postoperative rehabilitation therapy clearly falls into the medically required therapy group. On the other hand, the goal of sitting in a desk chair and holding a pencil to write a school lesson is clearly a physical skill that has to be addressed in some way for effective classroom learning to occur. There are, however, many therapies that fall between these two extremes, and it seems the definition is determined most by the availability of a therapist and the attempt of school administrations to provide minimum or maximum services. The extremes range from schools that will provide increased therapy even to help with postoperative rehabilitation, to the other extreme of schools that define any specific therapy recommended from an orthopaedist as medically based therapy.

This definition of what is educational therapy rests with the educational system and not the medical system, although developmental pediatricians are seen as experts on special education and can give medical opinions for education that the school system has to consider. School-based therapy is ideal for children and families because families are not burdened with having to take children to another facility or another appointment. Most educational-based therapy is low intensity and low frequency. Often, 30 minutes once a week is the planned therapy intervention. However, educational therapy can be the focus of the educational plans for children with limited cognitive abilities. A new approach called the Mobility Opportunities Via Education (MOVE) was developed by Linda Bidade in Bakersfield, CA, as a special education teaching program, and is being adopted in some schools. Through the use of adaptive equipment, the MOVE program is able to provide significant periods of time for weight bearing, even for large adolescents and young adults (Figure 5.1). These devices include standers, walkers, and various other positioning devices that are used throughout the day, directed at a specific overall motor stimulation program. The real focus of this program is to allow the children to acquire physical skills, such as standing, that will allow them to do weightbearing transfers and to maximize an individual's physical function in the community. This educational therapy approach seems most appropriate for children and adolescents with severe mental retardation and limited physical abilities; however, it is very important that the therapy not interfere with cognitive educational classes, especially for individuals with good cognitive function.

Special Setting

Special environments in which physical therapy also provides a valuable service include seating clinics where physical or occupational therapists serve as primary clinicians in the role of evaluating a child's specific seating needs. The gait analysis laboratory is another environment in which the therapist usually does most of the direct patient contact testing, such as the examination and placement of markers and EMG electrodes. After the data have been compiled, the therapist is a key member of the data interpretation team.

Occupational Therapy

The theories of therapy practice for occupational therapy mirror those of physical therapy. Many of the basic therapy approaches, such as the sensory motor and sensory integrative approach, were developed by occupational therapists and are the basis of much modern occupational therapy practice. The focus of occupational and physical therapy in early childhood and in the infant period greatly overlap. As a child gains more motor function, the occupational therapist's focus shifts to functional activities of daily living and fine motor skills with the upper extremities. Upper extremity splinting to improve function or prevent contractures are also important aspects of occupational therapy practice. The efficacy of occupational therapy also mirrors that of physical therapy, in which it has been difficult to document clear objective benefits. The focus of occupational therapy is also very dependent on the age and functional ability of an individual child. The therapy plan is similar to physical therapy, in which a therapist uses a learning approach based on a specific task as the goal. The goal is planned from an understanding of a child's function, the family structure, and the physical environment in which the child lives.

Age-Specific Goals

Early Childhood

The focus shifts during early childhood from initially working on activities such as self-feeding and removing clothes, to fine motor skills such as using scissors and early writing skills.

Middle Childhood

Fine motor skills development, especially writing, self-dressing, and toilet training, if it has not yet occurred, are the main focus. During this time, an assessment can be made of a child's ability to be a functional writer, and if it is determined that he cannot be a functional writer, an augmentative writing device should be prescribed. Typically, this would mean getting a computer and working with an effective interface with the computer to allow this to become the child's main output device. Another alternative may be the use of a dictaphone or a full-time aide who will do the writing for even more physically challenged children. The occupational therapist in the school setting often is the primary therapist working on these problems.

Adolescence

The main focus in adolescence are issues of independence. Based on individual evaluations, attempts are made for individuals to learn to do all their self-care needs, such as dressing, bathing, and cooking their own food. This is also when families start to understand what the individuals' specific, realistic, long-term goals for personal independence and self-care will be. For other children, it may be a time to focus on specific goals that are limiting their ability to be fully independent. For example, a child may be able to do all her own dressing, except putting on shoes. A specific therapy program aimed at solving this problem should be undertaken.

Young Adulthood

A major goal in young adulthood is to determine if an individual can drive a car. Many specific driving programs have been set up, often in coordination

with occupational therapy programs. Also, an assessment of occupational options should be occurring, which is another area of practice where the occupational therapist usually has significant input. During this time a vocational assessment is performed for those individuals with adequate cognitive function.

Special Setting

Occupational therapists work in seating clinics and feeding clinics. Their role in these clinics is to provide clinical expertise in evaluating children and recommend appropriate adaptations. In feeding clinics, occupational therapists may also be involved in feeding therapy programs. Occupational therapists have as large a role in the school therapy setting as physical therapists.

Speech Therapy

The speech therapist's main role is to address the speech and augmentative communication needs of children. Also, feeding and swallowing malfunctions are evaluated by speech therapists. Radiographic swallowing studies are often performed by a speech therapist in coordination with a radiologist. For children with complex oral motor dysfunction, many pediatric hospitals have multidisciplinary feeding clinics in which the speech therapist is a key member. Usually, these clinics are directed by developmental pediatricians and do not have much direct interaction with the orthopaedic treatment, except when maximum oral motor function is significantly impacted by a child's seating.^{43, 44} There may even be an impact on general motor function by altering oral motor function through the use of oral orthotics that enhance swallowing.^{45, 46} This significant impact on general motor function has not been confirmed independent of the developer of the oral orthotic.

Therapist Assistants

There are special associate degree programs that train individuals in physical and occupational therapy. These individuals are called physical therapist assistants (PTA) or occupational therapist assistants (OTA). These assistants may carry out a treatment program as outlined under the direction of a licensed physical or occupational therapist. The level of required supervision varies from state to state; however, a PTA or OTA may not practice independent of a fully licensed therapist. The function of the therapist assistant is very similar to a physician assistant's relationship with the supervising physician. Therapy departments also use therapy aides who typically have on-the-job training to do activities only under the direct supervision of a licensed therapist.

Physical Therapist and Orthopaedist Relationship

The two main medical practitioners in the treatment of children's motor impairments are the primary therapist and the physician. This team is most commonly a physical therapist and a pediatric orthopaedist; however, it may be an occupational therapist and a psychiatrist. We primarily address the

orthopaedic and physical therapy relationship, but the context is similar for the other disciplines. The orthopaedist's experience is usually based on many children with whom he has had superficial contact. This experience is reflected in the orthopaedic literature of CP, in which most published papers are based on specific problems, such as hip dislocations or scoliosis, and include large numbers of patients, often 50 to 100 cases. The experience of the physical therapist is usually with of a few individual children, in much greater detail. This experience is also reflected in the physical therapy published literature, which often includes case studies or series of 3 to 10 children. Based on this experience difference, each discipline develops a different perspective. The physical therapist often feels that the orthopaedist does not understand this specific individual child, while the orthopaedist feels that the physical therapist has a narrow focus not based on a wide enough experience. These different perspectives require that the physical therapist and the orthopaedist have discussions where each is honest about the perspective from which the decisions are being made. By having open discussions, children's best interests are served because both perspectives together usually yield the best treatment plan. Often, orthopaedists are deceived by short examinations of a child who is not performing in the typical and normal way. The physical therapist has a much better perspective on how the child functions day in and day out. It is, after all, the typical daily function that the orthopaedist wants to evaluate and the basis from which decisions should be made about bracing, surgery, or seating. Alternately, the physical therapy approach of placing great weight on single case study experience does not work well in orthopaedic decision making because one bad outcome based on a surgical complication should not be used to preclude considering that surgery. Yet, it is this typical case experience approach in which a therapist will say, "I once saw a child who had this operation and he did very poorly, so we would never allow any child we are treating to have that operation." This approach would lead a surgeon to never do surgery, and is not based on scientific principles. This is the area where the therapist needs to hear from the orthopaedist what a surgical procedure is expected to do and the complication risks that are involved.

Children's medical care is greatly benefited by good, open communication between the therapist and the physician. This communication, however, is often difficult to practice in real life. The telephone seems like the ideal instrument; however, finding times when both the therapist and the orthopaedist are available to come to the telephone is often difficult. Other alternatives should be considered as well, such as the use of e-mail, letters, and, whenever possible, direct face-to-face meetings. There are occasional families who request that the physician not communicate with their child's therapist. If this therapist is, for example, a school-based therapist with whom the family has no direct contact (meaning the school hired the therapist and the family has no say in who this person is), this request may be valid at some level. We still try to convince families that it would be in their child's best interest to have communication between the therapist and physician. However, if the therapist is a primary therapist that the family is engaging to see the child, and the same family has also chosen to see us as the orthopaedist, the request that the therapist and the orthopaedist not communicate is inappropriate. If the family does not agree that the therapist and physician can communicate, they should go to either a different therapist or a different orthopaedist. Almost all families will understand the importance of this communication if it is discussed in the context of the benefits it provides to the child.

Education

The integration of children with disabilities in the educational system was variable in the United States until 1975 when Federal Law PL 94-142, entitled “The Education for All Handicapped Children Act,” was passed. This law mandated free and appropriate public education for all children, including those with disabilities. This law led to the building of many schools for special education. This bill has been reauthorized in various forms and with many additions. In 1990, it was retitled “The Individuals with Disabilities Education Act” (PL 010-476). This bill and subsequent amendments, especially PL 99-457 and PL 94-142, have included infants, toddlers, and preschoolers with disabilities as part of the educational bill.

Most recently, part C of PL 105-17 has outlined the specific state-run services including early intervention that have to be provided for children from birth to age 3 years and states that children after age 3 years must be served by the school system. These acts require that the states provide appropriate education and associated services, which include occupational, physical, and speech therapy as needed for children to meet their educational goals. The school must also provide whatever adaptive equipment is needed for children to meet the educational goals set out. This law also states that these goals have to be individually defined in a structured individual education program (IEP) on a yearly basis, and that parents must be given feedback on how their children are progressing toward these goals on a frequency at least as often as other children are given report cards. The annual IEP has to include a definition of the specific special education program, the special services the child will receive, meaning therapies, and the adaptive equipment that is needed. The IEP must be explained to parents and caretakers in an annual meeting, and the parents or caretakers must agree that it is appropriate. If the parents disagree with the IEP as it is stated, they may try to negotiate. If this negotiation fails, they may appeal through an appeal structure that is defined in the special education act. The special education act also states that children’s education should be in the least restrictive environment, which means that whenever possible a child should be in a normal classroom with age-matched peers. These federal education laws have greatly improved the educational opportunities for children with CP.

These laws are administered by states but interpreted and executed by local school systems; therefore, there is great variation in the quality of the educational experience individual children receive. Because of the significant subjective evaluation involved and the interpretation of the legal code, there is much more variation in the educational experience of children with disabilities than the educational experience of normal children; this is true even though there is great variation in the educational opportunities in public schools across the United States. The pediatric orthopaedist has various levels of contact with the educational system and has to understand the general milieu of special education. In addition, the orthopaedist should have a general understanding of the local special education system in which he is practicing. By nature of the special education system as it is defined in the federal code, there are many areas of frequent conflict that involve the orthopaedist directly.⁴⁷ These areas of conflict are discussed in the following paragraphs.

Separation of Education and Medical Practice

Education and medical practice are separate in our society at almost every level, and this separation has led to frequent conflicts in the area of special

education. More specifically, special education law states that the educational system must pay for medical evaluations that are needed to determine children's educational goals and functions. The school system has to provide adaptive devices that are needed for children to gain an educational experience; however, the educational system does not need to purchase medical treatment required to maximize children's educational goals. The eye examination is a typical examination that the educational system is required to perform because visual acuity may be a major obstacle to a child's learning ability. If the eye examination demonstrates that the child needs eyeglasses, the school system has to pay for the glasses if the glasses are interpreted to be adaptive devices. However, if the glasses are interpreted to be medical devices, the educational system does not pay. This exact example has been litigated in several locations in various courts, and decisions have been handed down in both directions. These types of circumstances have spawned a whole legal subspecialty to help interpret and litigate areas of special education law.

What Is Medical Equipment and What Is an Adaptive Device?

The definition from the perspective of the educational system of what is educational and what is medical varies from state to state and even from school district to school district based on many reasons. Financial considerations in the educational system are often part of the reason to determine how aggressively the educational system pursues trying to shift costs to the medical payers. In general, wheelchairs, walking aids, and orthotics are considered medical equipment. Special desk seating, communication devices, writing aids, standers, and positioning devices used by children at school are considered educational devices. Devices such as standers or other adaptive equipment such as tricycles that children can also use at home may fall into either category.

Prescriptions

A major impact on the pediatric orthopaedist who manages children with CP is the need for many prescriptions, especially related to their needs in school. Although there is variability from state to state, most states require licensed therapists to provide therapeutic services only under a doctor's order. With this requirement, even therapists practicing in a school environment doing therapy to further children's education need to have a physician's prescription. If that prescription comes from an orthopaedist and is very specific for range of motion, gait training, or postoperative rehabilitation needs, with specific frequency requirements, the school administration can legitimately conclude that it is medically needed rehabilitation therapy and refuse to provide the services. The prescription that works best in the school environment is to order educationally based therapy and include specific restrictions and suggestions, such as a child's need to be in a stander every day for a certain maximum period of time.

The physician needs to understand his proper role as related to the educational system. The physician also needs to be able to clearly articulate that role to parents. A common parental concern is that the school is not providing adequate therapy to their child. In some situations this concern is true, and in others, the parents' enthusiasm for therapy and the expectations of how much benefit the therapy will provide are misunderstood. The orthopaedist should play a role in explaining to the parents that therapy is not indicated if that is his opinion, but he can also explain his role in ordering school therapy when he believes more therapy is required but the school

disagrees. The parents' usual response to the physician is, "You wrote the prescription, so the school has to do what you said."

A typical example of a parent demanding therapy and the school disagreeing is a child with good cognitive ability who is an independent ambulator. In general, a child with this level of motor function probably has more long-term side effects from therapy than benefits, especially if the therapy interferes with any academic classroom work. In this situation, the parents need to be educated and the school decision needs to be reinforced with the parents. The opposite example occurs with a middle school child with severe quadriplegia, who has made no motor gains over several years, and the school IEP plans to maintain motor function with classroom activities provided by a teacher and a schoolroom teacher's aide. The educator believes that the focus of this child's educational goals should be teaching him to use augmentative communication. The parents disagree and want everything to occur.

These are difficult subjective decisions and the orthopaedist may find himself siding with the parents; however, an aggressive response by letter or phone call will not help the parents' position because it will only give the school administration physical evidence that this need is medical rehabilitation. It is much more helpful for the orthopaedist to recognize that this is an educational decision, and offer the parents and school additional data as a way of helping the school and parents negotiate the disagreement. This negotiation will be more profitable with this approach than getting involved with a litigation.

Another major area where prescription need arises is obtaining adaptive equipment. All adaptive equipment purchased through medical reimbursement sources, such as private insurance or Medicaid, must include a medical prescription and usually a letter of medical need. Examples include orthotics, wheelchairs, and standers. If devices are purchased with educational dollars, no prescriptions are needed; these would typically include writing desks and computers used as augmentative writing devices. Many devices fall in between, such as augmentative communication, classroom standers, and floor positioning devices. The specifics of who pays for what may be negotiated at the state level between agencies, or in other states, debated at length, often to the major advantage only of the legal profession.

Physician–Educator Relationship

In almost all school environments in special education, administrators really try to provide the best services for the children in their care. A major constraint many special education systems work under is poor funding; however, cost may not legally be considered in determining what children need. The pediatric orthopaedist can be very helpful to further a child's education by providing documentation and prescriptions for the required services but at the same time must have a clear understanding of their limited role in determining the child's program. Annual visits to special schools are very beneficial to both the educator and the medical care provider. This kind of interaction helps both to understand the different environments, and it is helpful to have time for face-to-face conversation. The professionals in the educational system are very interested in staying up to date on advancing medical practice. Parents often ask for medical advice from the educational staff, just as parents ask educational questions from the medical staff. This kind of bilateral educational and communication process between the systems can only help children and families in the overall goal of allowing them to become all they can be.

Inclusive Education

The special education legislation currently requires that these children be educated in the least restrictive environment. The goal of this education is to encourage placement of these children in classrooms with their peers whenever possible.⁴⁷ This has also become a major political issue, with some parents narrowly interpreting this code to mean all children have to be in standard classrooms, with special education support provided in the classroom in the presence of normal children. The concept of this goal is valid but has limits. Because this is a very active current issue, parents frequently want to enlist the help or opinion of their orthopaedist. For many children, the correct placement is clear; for example, a child with ambulatory diplegia and good cognitive function should be in a regular classroom with their age-matched peers. Also, it is clear that a child who requires frequent nursing attention because of respiratory dysfunction and has no recognized accessible cognitive function is not served well in a standard classroom. This child also becomes a distraction to other children in the room who are trying to learn. Neither the child with the disability nor his age-matched peers gain anything from this experience. This movement toward education in the least restrictive environment has led to a great reduction in the number of special education schools that were built as a result of the 1975 legislation. Some children with severe impairments are placed in neighborhood schools and are being cared for by an on-the-job trained aide who sits with them in a classroom, with some occasional therapy services provided in the school. The therapists who provide this service often have little experience in working with children with CP.

Deciding which child is best served in a special school and which child is best served in a neighborhood school is a difficult decision for parents and children. Some of this decision depends on what services are available in the community. In general, it is much less expensive to provide services in the neighborhood school system, even for children who need a great deal of care, than providing for this care in a separate special education facility. The combination of a cheaper solution for the educational system and a politically active parent-based movement makes this concept of educating children in the least restrictive environment a very strong political and social movement. This movement has clearly benefited many children. As with most social movements, there are those children who have been hurt by the movement as well, and a basic directive of the early special education legislation was to provide for an individualized education program that best meets the individual child and family's needs. The role of the orthopaedist in this debate is marginal, but he should have an understanding of the issues involved as this often has a profound effect upon the children and their families. Case examples can help to demonstrate the impact these decisions have on some children (Cases 5.1, 5.2).

Transitional Planning and Guardianship

The special education legislation also requires the educational system to plan for transition from the school system, whose responsibility ends at age 21 years or with graduation from high school. This phase includes transition to sheltered workshops or adult day care as well as more traditional work and advanced educational opportunities, based on the abilities of each individual. Also, this transitional planning is supposed to include some education of the parents about the need to obtain guardianship for the young adult if



Case 5.1 Chandra

Chandra was a 12-year-old girl with combined spastic and athetoid pattern quadriplegia who had no oral speech and was totally dependent for all activities of daily living. Cognitive function was near age appropriate. Her parents felt strongly that she should be in a regular classroom with a teacher's aid and other required therapeutic support. Over several years, especially as Chandra en-

tered puberty, she became depressed and started having behavioral problems. After grade eight, her parents elected to have her move to a special education school that had an extremely high level of technical expertise. Her depression gradually lifted, her behavior stabilized, and she became a school leader over the next 5 years of her high school experience.

it is required.⁴⁷ For some environments, in facilities such as the Nemours Foundation and the Shriner's Hospital System, individuals also have to transition their medical care to adult services at this same time. This is a very stressful time for parents and young adults with CP. If the pediatric orthopaedic care has to end at age 21 years, this discussion should start several years earlier and the parents should be encouraged to see this as part of the same transition that the educational system is also working toward.

The need for guardianship must also be addressed for those individuals whose cognitive level precludes them from managing their own affairs. At age 18 years, individuals are considered adults, and from strict legal interpretations, if the individual has not been legally judged incompetent and a guardian assigned, the individual's guardianship rests with the State. This issue has special relevance for individuals who are clearly incompetent and are in need of a surgical procedure. Before age 18 years, a parent has to sign; however, after age 18 years, many parents think that it is clear that they will continue to be the guardian and to sign operative consents and other legal matters. The parents need to be informed that they have to get a court-ordered guardianship. The court will often need a statement from the physician, which



Case 5.2 Mary

A very similar case example is Mary, a girl who was in a special school until grade eight, then she transferred to a regular high school. Mary had a spastic quadriplegia and was almost totally dependent in activities of daily living; however, she was completely verbal. Her cognitive ability tested at marginal mental retardation. In her special school, she was a leader among the students because of her excellent verbal abilities. Upon transfer to the regular high school, she became depressed and developed significant behavioral problems. Some of the behavioral

problems had been apparent before entering regular high school but they became more severe. The whole high school career was a very traumatic experience for Mary and her family. It was not certain that this adolescent trauma would have been avoided in a special school environment; however, as demonstrated by these two case examples, inclusion in a regular school may create problems and does not universally benefit all students, as much of the current politically correct discussion would suggest.

is easy in many individuals and reasonable for the orthopaedist to provide the court in clear cases of incompetency. When the situation is not clear, such as a child who can speak and seems reasonable but has some mental retardation, it is better for the court to obtain more expert opinion. In these situations, it is better to allow the psychologic and psychiatric experts make the determination. If an individual who is over 18 years has a medical problem that requires surgery, the physician's knowledge of the family and the individual with CP often means that it is all right to proceed. However, if there is a legal challenge from another family member, or there is some other liability issue, the court may find that the person who signed the consent was not a legitimate guardian, therefore putting the surgeon at risk for having done an operation without a valid consent. Also, if there is any question about the competency of the individual who is over 18 years, and the individual has not been adjudicated, the best action is to obtain the signature of both the patient who will have the surgery and the accompanying parent.

Other Treatment Modalities

There are many different treatment modalities pursued by families of children with CP. Some of these modalities are closely coordinated with or incorporated into standard therapy services. Other treatments tend to be more focused in the area of sport and athletic activities. The real advantage of the athletic activities, which are usually done in the individual's community with age-matched peers or family members, is the integration of the child into the normal community activities. Therapy services, even in a school environment, always have some sense of medical treatment and involve only the child with the disability. Some of these activities are explored in the following pages.

Hippotherapy

Providing therapy treatment using horseback riding is called hippotherapy (Figure 5.2). Hippotherapy has a long history in Europe, with one review in 1975 reporting more than 150,000 therapy sessions.⁴⁸ The vertical movements



Figure 5.2. Hippotherapy is performed usually under the direction of a physical therapist using horseback riding. This therapy is usually performed in the location of a horse barn or farm, which has the additional advantage of providing the child with a different opportunity for social stimulation.

of horseback riding are thought to provide sensory stimulus, which decreases muscle tone. The shape of the horse's back also helps with stretching hip adductors and improves pelvic tilt and trunk positioning. Often, the therapist has the child riding facing forward and backward as a way of stimulating different aspects of the sensory system. Hippotherapy also provides an environment that is much more stimulating and psychologically uplifting than the sterile therapy treatment room. Published research studies have documented positive effects from horseback riding therapy. There was a decrease in spasticity immediately after the riding session.²⁹ There were also improvements in sleeping and bowel routines noted in the same study. Improvements in children's psychologic outlook have been reported as well.⁴⁹ A suggestion of improved ambulation skills with a more energy-efficient gait has also been reported.⁵⁰ There is enough evidence to conclude that hippotherapy is probably equal to other therapy approaches. However, the specific benefits of hippotherapy over standard therapy are not convincingly documented. Hippotherapy is a reasonable alternative to, or may be incorporated into, a standard therapy approach. A major obstacle for hippotherapy programs continues to be poor recognition of its benefit by secondary medical payors, requiring many of these programs to depend on donations or direct patient billing.

Horseback riding as an athletic endeavor is enjoyed by many children as well. We have one patient with hemiplegia who has been able to develop a national ranking in English-style riding competition. This is a very practical sport for children with CP who have enough motor skills that regular riding instructors can teach them horseback riding as a sport rather than as a therapy.

Hydrotherapy: Swimming

Therapy performed in water is called hydrotherapy. The effects of the water give children a feeling of weightlessness, which has been suggested as a way to reduce tone and allow these children to access better motor control.⁶ This modality is also used for postoperative rehabilitation to allow children to start walking with reduced weight bearing. Hydrotherapy is a reasonable modality for gait training, especially in a heavy child who may be able to walk in water with relative weightlessness from the floatation effects. Also, there is a technique for using the neurodevelopmental treatment approach to teach swimming to children with CP.⁵¹ There are no reports comparing hydrotherapy with standard therapy; however, one report suggested hydrotherapy and hippotherapy are equivalent but hippotherapy is cheaper.⁴⁹ Based on this report, hippotherapy apparently is cheaper because it is less expensive to buy a horse than build a swimming pool. Hydrotherapy is a reasonable adjunctive modality to use in planning a therapy program for a child.

Swimming as a recreational activity is excellent for individuals with CP. For many children who have a high-energy demand of walking in middle childhood, learning to swim and using this as the physical conditioning exercise is an excellent option. A major problem for individuals whose main motor ability is by wheelchair is finding an exercise technique that can be performed comfortably but still provide cardiovascular stress. Swimming is a primary option for many of these individuals. If a childhood swimming program teaches children to be comfortable in water and learn to swim, there will potentially be lifelong benefits. There are some children with diplegia who can learn to become competitive swimmers and even compete with normal age-matched peers.

Martial Arts

The martial arts are an excellent choice for some children, even those who require assistive devices for walking. The routines in martial arts are usually individualized for the speed at which a child can learn; many of the routines also stress balance reaction, stretching, and large joint range of motion. Also, there is a clear system for making progressive steps with awarding levels of achievement, which is a great motivator for many children. The training for the martial arts occurs in community locations with regular community peers, which is another major advantage. The main problem with the martial arts is the difficulty in finding instructors who are interested in teaching individuals with disabilities. Another problem of the martial arts for individuals who become very enthused about the sport is that at the higher levels of skill the motor impairments also make advancement very difficult.

Sports

Encouraging children with CP to get involved with typical age-matched sport activities is an excellent alternative to medically based therapy programs, especially for children with motor skills that allow them to enjoy the activity. Physical therapists are in an excellent position to recommend to families specific sporting activities that would likely work for their children. For ambulatory young children, the beginner soccer programs work well. For children with a need to work on balance and motor control, dance programs are an excellent option.

Acupuncture

Acupuncture with functional training has been reported to increase both children's motor function and cognitive function.⁵² However, objective evidence is not strong to support the use of acupuncture. Apparently, the acupuncture meridians are closely related to the Vojta massage points, and there is a suggestion that both techniques may be stimulating the same system.¹⁸ There may be a close relationship in these two theories of practice because there is a separate discipline of acupressure, which is alleged to have similar effects as acupuncture.⁵² Because very few children enjoy injections, the routine use of acupuncture is much too stressful compared with any suggested or implied benefit to recommend its use in minor children. The use of pressure point manipulation by acupressure causes no harm if it is not uncomfortable to the children; however, there is no clear objective benefit of acupressure.

Massage and Myofascial Release Therapy

A major aspect of the Vojta technique of therapy is stimulation through a series of massage points. There has been increased use of massage by some therapists, including borrowing techniques from chiropractors. Myofascial release therapy is one such technique that has been developed emanating from chiropractor practice. Although myofascial release therapy is not usually described as massage, it is in fact a massage program with a minimal joint range of motion component. There are no English-language reports on the specific efficacy of massage compared with no therapy or other therapy modalities. Benefit has been reported for massage, reflexology, and other manipulations that are widely used in Eastern Europe and Russia.^{53, 54} Based

on the available evidence, massage therapy seems to cause no harm if the therapy is comfortable and the children enjoy the therapeutic experience. If the therapy is in any way uncomfortable for these children, it cannot be justified based on currently available data.

Hyperbaric Oxygen Therapy

There has been increased interest in the use of hyperbaric oxygen therapy for children with CP under the theory that more oxygen will make the brain function better. A small study suggested a possible benefit⁵⁵; however, there have also been complications reported from this therapy.⁵⁶ Based on this minimal evidence of a positive impact, a well-designed study was conducted in Montreal. This as yet unreported study has apparently shown that there is a small benefit to the child by sitting with the parent in the hyperbaric oxygen chamber for approximately 10 hours each week. However, the addition of hyperbaric oxygen to the chamber adds no additional benefit. Based on these results, there is no role for hyperbaric oxygen therapy in children with CP.

Space Suit Therapy

Therapy with children in space suits, initially designed to counteract the weightlessness of space by being pressurized and add elastic resistance to movement, was first investigated in Russia in the early 1990s. This device has several versions but the ADELI suit has had the most reported use.^{35, 57} This therapy has been popularized as a therapy treatment modality in Poland and is focused on improving sensory stimulation by providing children with the ability to stand through the resistance of the additional joint stiffness. Also, this method theoretically allows children to learn movement and standing posture and balance strategies. All the outcome studies have reported changes in vestibular and postural control activities with gains reported on short-term evaluation.^{35, 57, 58} Because there are no objective functional gains reported, the measured effects are probably short term. In many patients we have examined after space suit therapy, we have not been able to determine any recognizable change. For American families with children who have CP, the opportunity to travel to Poland for 3 weeks seems to be a very positive experience. We suspect the opportunity to travel to Poland is more beneficial than the effect of the space suit. We would not recommend the use of the space suit in America because there is no evidence of functional improvement at this time.

Alternative Medicine

There are many alternative medicine techniques used to treat children with neurologic disabilities. Often, these practices arise out of local folk medicine. Many therapies used for the promotion of general health in health resort treatments are frequently promoted to those with disabilities. Such treatments as mud baths, reflexology, auriculotherapy, and various manipulations are promoted.^{53, 54} There are a few alternative therapies that seem to have persisted for a significant time period and have spread beyond a small local area into wider geographic representation. Craniosacral therapy and Feldenkrais therapy, discussed next, are two examples of such techniques.

Craniosacral Therapy

Craniosacral therapy was developed from the therapy practice of treatments promoted by Dr. William Sutherland, an osteopathic physician in the early

1900s. This theory and practice was picked up in the 1970s and 1980s by Dr. John Upledger, an osteopathic physician who has heavily promoted and further developed the current practice of craniosacral therapy. The underlying therapy is based on the rhythmic pulsation and flow of the cerebrospinal fluid, which is influenced by breathing. This rhythmic movement is supposed to cause movement of the cranial joints and, in the vibration effect, movement of every joint in the body. Therefore, the craniosacral therapist can perceive this movement anywhere in the body, but it is most noticeable in the cranium and facial bones. The therapy involves palpation of the area to be adjusted to perceive the rhythmic movement. Then, using very light pressure, this rhythmic movement is altered to a better state. This change allows the individual to be more relaxed and to generally function better. There are no medical reports evaluating the efficacy of craniosacral therapy.^{59, 60} Based on modern scientific understanding of anatomy, there is no theoretical reason to recommend craniosacral therapy, although a few reports of parents and children report a sensation of being relaxed and alert after therapy sessions. This effect is probably similar to typical effects reported secondary to the sensory stimulation of many massage techniques.

Feldenkrais Therapy

In the early part of the 1900s, Moshi Feldenkrais grew up in Russia and Palestine, then was educated in Paris where he received a Ph.D. in physics. During this time, he developed a relationship with Jigaro Kano, who is the developer of modern judo. From Dr. Feldenkrais' combined enthusiasm for Newtonian physics, especially with movements of mass, and the movements of judo, he devised a therapy technique that claims to increase intellect and general well-being and to improve motor function. The technique uses a therapist who gives verbal instructions on specific movements. These movements use positions and stretching specifically directed at increasing the individual's awareness, flexibility, and coordination. There are no medical reports evaluating this therapeutic approach. Based on reports of patients who have received Feldenkrais therapy, it does seem to involve many of the typical therapy positions often practiced as functional maneuvers, such as raising from the chair with a specific posture. These movements are combined with martial arts positions, which are often held for periods of time. The functional motor movements seem to be realistic as therapeutic approaches for some individual children; however, the theories and claims of benefits are totally unsubstantiated and unrealistic. There may be elements of this technique that an experienced physical therapist could use in a treatment plan. Feldenkrais treatment by an individual who is not trained in standard physical therapy is not recommended. There is a great risk of raising inappropriate expectations in families and patients, especially when the Feldenkrais technique is performed and advocated by individuals with no medical background.

References

1. Hur JJ. Review of research on therapeutic interventions for children with cerebral palsy. *Acta Neurol Scand* 1995;91:423–32.
2. Weindling AM, Hallam P, Gregg J, Klenka H, Rosenbloom L, Hutton JL. A randomized controlled trial of early physiotherapy for high-risk infants. *Acta Paediatr* 1996;85:1107–11.
3. Bartlett DJ, Palisano RJ. A multivariate model of determinants of motor change for children with cerebral palsy. *Phys Ther* 2000;80:598–614.
4. Harris SR, Atwater SW, Crowe TK. Accepted and controversial neuromotor therapies for infants at high risk for cerebral palsy. *J Perinatol* 1988;8:3–13.
5. Hubel DH, Wiesel TN. The period of susceptibility to the physiological effects of unilateral eye closure in kittens. *J Physiol (Lond)* 1970;206:419–36.
6. Campbell S. *Pediatric Neurologic Physical Therapy*. New York: Churchill Livingstone, 1991.
7. Bobath K. *The Neurophysiological Basis for Treatment of Cerebral Palsy*. Oxford: Spastics International Medical Publications, 1980.
8. Fetters L, Kluzik J. The effects of neurodevelopmental treatment versus practice on the reaching of children with spastic cerebral palsy. *Phys Ther* 1996;76:346–58.
9. Law M, Cadman D, Rosenbaum P, Walter S, Russell D, DeMatteo C. Neurodevelopmental therapy and upper-extremity inhibitive casting for children with cerebral palsy [see comments]. *Dev Med Child Neurol* 1991;33:379–87.
10. Law M, Russell D, Pollock N, Rosenbaum P, Walter S, King G. A comparison of intensive neurodevelopmental therapy plus casting and a regular occupational therapy program for children with cerebral palsy. *Dev Med Child Neurol* 1997;39:664–70.
11. Hullin MG, Robb JE, Loudon IR. Gait patterns in children with hemiplegic spastic cerebral palsy [see comments]. *J Pediatr Orthop B* 1996;5:247–51.
12. Aebi U. Early treatment of cerebral movement disorders: findings among 50 school children. *Helv Paediatr Acta* 1976;31:319–33.
13. Rothberg AD, Goodman M, Jacklin LA, Cooper PA. Six-year follow-up of early physiotherapy intervention in very low birth weight infants. *Pediatrics* 1991;88:547–52.
14. Jones RB. The Vojta method of treating cerebral palsy. *Physiotherapy* 1975;61:112–3.
15. Imamura S, Sakuma K, Takahashi T. Follow-up study of children with cerebral coordination disturbance (CCD, Vojta). *Brain Dev* 1983;5:311–4.
16. Schutt B. Juvenile hip dislocation and the Vojta neuro-physiotherapy. *Fortschr Med* 1981;99:1410–2.
17. d'Avignon M, Noren L, Arman T. Early physiotherapy ad modum Vojta or Bobath in infants with suspected neuromotor disturbance. *Neuropediatrics* 1981;12:232–41.
18. Stockert K. Acupuncture and Vojta therapy in infantile cerebral palsy—a comparison of the effects. *Wien Med Wochenschr* 1998;148:434–8.
19. Joint executive board statement. American Academy of Pediatrics and American Academy of Neurology. Doman–Delacato treatment of neurologically handicapped children. *Neurology* 1967;17:637.
20. Official statement. The Doman–Delacato treatment of neurologically handicapped children. *Arch Phys Med Rehabil* 1968;49:183–6.
21. American Academy of Pediatrics Policy statement: the Doman–Delacato treatment of neurologically handicapped children. *Pediatrics* 1982;70:810–2.
22. Bairstow P, Cochrane R, Rusk I. Selection of children with cerebral palsy for conductive education and the characteristics of children judged suitable and unsuitable [see comments]. *Dev Med Child Neurol* 1991;33:984–92.
23. Reddihough DS, King J, Coleman G, Catanese T. Efficacy of programmes based on Conductive Education for young children with cerebral palsy. *Dev Med Child Neurol* 1998;40:763–70.
24. Catanese AA, Coleman GJ, King JA, Reddihough DS. Evaluation of an early childhood programme based on principles of conductive education: the Yooralla project. *J Paediatr Child Health* 1995;31:418–22.

25. Coleman GJ, King JA, Reddihough DS. A pilot evaluation of conductive education-based intervention for children with cerebral palsy: the Tongala project. *J Paediatr Child Health* 1995;31:412–7.
26. Alexander MA, Molnar, GE. *Pediatric Rehabilitation: Physical Medicine and Rehabilitation*. Philadelphia: Hanley & Belfus, 2000.
27. Chae J, Hart R. Comparison of discomfort associated with surface and percutaneous intramuscular electrical stimulation for persons with chronic hemiplegia. *Am J Phys Med Rehabil* 1998;77:516–22.
28. Carmick J. Managing equinus in children with cerebral palsy: electrical stimulation to strengthen the triceps surae muscle. *Dev Med Child Neurol* 1995;37:965–75.
29. Exner G, Engelmann A, Lange K, Wenck B. Basic principles and effects of hippotherapy within the comprehensive treatment of paraplegic patients. *Rehabilitation (Stuttg)* 1994;33:39–43.
30. Scheker LR, Chesher SP, Ramirez S. Neuromuscular electrical stimulation and dynamic bracing as a treatment for upper-extremity spasticity in children with cerebral palsy. *J Hand Surg [Br]* 1999;24:226–32.
31. Wright PA, Granat MH. Therapeutic effects of functional electrical stimulation of the upper limb of eight children with cerebral palsy. *Dev Med Child Neurol* 2000;42:724–7.
32. Hazlewood ME, Brown JK, Rowe PJ, Salter PM. The use of therapeutic electrical stimulation in the treatment of hemiplegic cerebral palsy. *Dev Med Child Neurol* 1994;36:661–73.
33. Pape KE, Kirsch SE, Galil A, Boulton JE, White MA, Chipman M. Neuro-muscular approach to the motor deficits of cerebral palsy: a pilot study. *J Pediatr Orthop* 1993;13:628–33.
34. Steinbok P, Reiner A, Kestle JR. Therapeutic electrical stimulation following selective posterior rhizotomy in children with spastic diplegic cerebral palsy: a randomized clinical trial. *Dev Med Child Neurol* 1997;39:515–20.
35. Sologubov EG, Iavorskii AB, Kobrin VI, Barer AS, Bosykh VG. Role of vestibular and visual analyzers in changes of postural activity of patients with childhood cerebral palsy in the process of treatment with space technology. *Aviakosm Ekolog Med* 1995;29:30–4.
36. Damiano DL, Kelly LE, Vaughn CL. Effects of quadriceps femoris muscle strengthening on crouch gait in children with spastic diplegia. *Phys Ther* 1995;75:658–67; discussion 668–71.
37. Damiano DL, Abel MF, Pannunzio M, Romano JP. Interrelationships of strength and gait before and after hamstrings lengthening. *J Pediatr Orthop* 1999;19:352–8.
38. Kyllerman M. Reduced optimality in pre- and perinatal conditions in dyskinetic cerebral palsy—distribution and comparison to controls. *Neuropediatrics* 1983;14:29–36.
39. Palmer FB, Shapiro BK, Allen MC, et al. Infant stimulation curriculum for infants with cerebral palsy: effects on infant temperament, parent-infant interaction, and home environment. *Pediatrics* 1990;85:411–5.
40. Connolly KHF. *Neurophysiology and Neuropsychology of Motor Development*. London: Mac Keith Press, 1997.
41. Horn EM, Warren SF, Jones HA. An experimental analysis of a neurobehavioral motor intervention. *Dev Med Child Neurol* 1995;37:697–714.
42. Ottenbacher KJ, Biocca Z, DeCremer G, Gevelinger M, Jedlovec KB, Johnson MB. Quantitative analysis of the effectiveness of pediatric therapy. Emphasis on the neurodevelopmental treatment approach. *Phys Ther* 1986;66:1095–101.
43. Hulme JB, Bain B, Hardin M, McKinnon A, Waldron D. The influence of adaptive seating devices on vocalization. *J Commun Disord* 1989;22:137–45.
44. Hulme JB, Shaver J, Acher S, Mullette L, Eggert C. Effects of adaptive seating devices on the eating and drinking of children with multiple handicaps. *Am J Occup Ther* 1987;41:81–9.
45. Gisel EG, Schwartz S, Haberfellner H. The Innsbruck Sensorimotor Activator and Regulator (ISMAR): construction of an intraoral appliance to facilitate ingestive functions. *ASDC J Dent Child* 1999;66:180–7, 154.

46. Gisel EG, Schwartz S, Petryk A, Clarke D, Haberfellner H. "Whole Body" mobility after one year of intraoral appliance therapy in children with cerebral palsy and moderate eating impairment. *Dysphagia* 2000;15:226–35.
47. Effen S. The school. In: Dormans J, Pellegrino L, eds. *Caring for Children with Cerebral Palsy*. Baltimore: Brooks, 1998.
48. Riesser H. Therapy with the help of a horse—attempt at a situational analysis (author's translation). *Rehabilitation (Stuttg)* 1975;14:145–9.
49. Barolin GS, Samborski R. The horse as an aid in therapy. *Wien Med Wochenschr* 1991;141:476–81.
50. McGibbon NH, Andrade CK, Widener G, Cintas HL. Effect of an equine-movement therapy program on gait, energy expenditure, and motor function in children with spastic cerebral palsy: a pilot study. *Dev Med Child Neurol* 1998;40:754–62.
51. Harris SR. Neurodevelopmental treatment approach for teaching swimming to cerebral palsied children. *Phys Ther* 1978;58:979–83.
52. Zhou XJ, Chen T, Chen JT. 75 infantile palsy children treated with acupuncture, acupressure and functional training. *Chung Kuo Chung Hsi I Chieh Ho Tsa Chih* 1993;13:220–2, 197.
53. Babina LM. Health resort treatment of preschool children with cerebral palsy. *Zh Nevropatol Psikhiatr Im S S Korsakova* 1979;79:1359–63.
54. Mukhamedzhanov NZ, Kurbanova DU, Tashkhodzhaeva Sh I. The principles of the combined rehabilitation of patients with perinatal encephalopathy and its sequelae. *Vopr Kurortol Fizioter Lech Fiz Kult* 1992:24–8.
55. Montgomery D, Goldberg J, Amar M, et al. Effects of hyperbaric oxygen therapy on children with spastic diplegic cerebral palsy: a pilot project. *Undersea Hyper Med* 1999;26:235–42.
56. Nuthall G, Seear M, Lepawsky M, Wensley D, Skippen P, Hukin J. Hyperbaric oxygen therapy for cerebral palsy: two complications of treatment. *Pediatrics* 2000;106:E80.
57. Sologubov EG, Iavorskii AB, Kobrin VI. The significance of visual analyzer in controlling the standing posture in individuals with the spastic form of child cerebral paralysis while wearing "Adel" suit. *Aviakosm Ekolog Med* 1996;30:8–13.
58. Semenova KA. Basis for a method of dynamic proprioceptive correction in the restorative treatment of patients with residual-stage infantile cerebral palsy. *Neurosci Behav Physiol* 1997;27:639–43.
59. Green C, Martin CW, Bassett K, Kazanjian A. A systematic review of craniosacral therapy: biological plausibility, assessment reliability and clinical effectiveness. *Complement Ther Med* 1999;7:201–7.
60. Rogers JS, Witt PL, Gross MT, Hacke JD, Genova PA. Simultaneous palpation of the craniosacral rate at the head and feet: intrarater and interrater reliability and rate comparisons. *Phys Ther* 1998;78:1175–85.

Durable Medical Equipment

Durable medical equipment is the category of devices that are prescribed to ameliorate the disabilities from the motor impairments. Each of these devices, such as orthotics to assist with limb positioning or a seating system to assist with sitting, has very specific indications and contraindications. For physicians who care for children's motor impairments, many more prescriptions are written for durable medical equipment than for drugs. Because each durable medical equipment device has its own indications, contraindications, and risks, after a physician examination, a careful consideration of the risk–benefit ratio should be performed before a prescription is written. Many of these durable medical devices are very expensive, often ranging from \$1,000 for an orthotic to more than \$20,000 for a very sophisticated power wheelchair. It is the responsibility of the physician writing the prescription to understand the specific benefit the device is expected to provide and to know its contraindications and possible risks. It is the responsibility of both physicians and the durable medical equipment suppliers to inform patients and caretakers of the side effects and risks of the device. This process is exactly the same as used when physicians prescribe a drug, in which they are expected to understand the indications and contraindications of using specific drugs in specific patients whom they have examined. Just as physicians should not write prescriptions for drugs they are not familiar with, there is no place for them to write prescriptions for durable medical equipment that they do not understand. Therefore, when a new device becomes available, physicians have to spend time and effort to learn about the device before it can be prescribed. The regulation and oversight of durable medical devices by government agencies is slowly getting better; however, there is still considerable room for entrepreneurs to develop and market a device with little scientific background. This development is especially common in the area of orthotic design, where there is minimal objective documentation available even for well-established designs. This area requires care, consideration, and evaluation of individual patient response to gain experience with specific new device designs. Often, the advertising rhetoric has little basis in the physical facts of how patients respond. More commonly, the new device or design has a narrow application in which it does make an improvement; however, there is a tendency to generalize this improvement to all patients with cerebral palsy (CP), which does not work. The major categories of durable medical supplies that the physician who treats motor impairments must know about and be able to prescribe are orthotics, seating and mobility systems, and ambulatory aids.

Orthotics

The use of orthotic devices for children with CP has a long history, reaching its zenith just after the poliomyelitis epidemics of the 1950s. At this time, children were usually prescribed heavy, full hip-knee-ankle orthotics to control crouch and provide support. This practice came from the polio experience, which is a condition characterized by profound muscle weakness or paralysis. The very important difference between poliomyelitis and CP was not initially recognized. Although children with CP have weakness, the typical predominating problem is spasticity with decreased motor control and poor balance. These heavy braces do nothing to help children with CP move. Also, in this earlier era the use of heavy, stiff orthopedic leather shoes that were felt to provide good support to the foot was widespread; however, all these shoes did was cover up the equinus deformity so it was not visible. Invariably, the ankle was still in equinus when a radiograph was obtained with the foot in the shoe. With the advent of modern thermoplastics, lightweight, form-fitting plastic orthotics have become the norm.

Terminology

The terminology for prescribing orthotics can be confusing. The most general rule for spine and lower extremity orthotics is that the orthosis is named for the joints that are crossed by the orthotic. For example, an orthosis that covers the ankle and the foot is called an ankle-foot orthosis (AFO). Often, modifiers are added to make the name more specific. For example, the term molded may be added to AFO, which then becomes a molded ankle-foot orthosis (MAFO). The term MAFO is used to describe a plastic brace made from a mold produced from a cast of a child's extremity where the orthotic is to be fitted. Sometimes functional modifiers are added, such as ground reaction AFO (GRAFO), to describe an orthotic used to prevent knee flexion in the stance phase of gait. Upper extremity orthotics more commonly carry functional terms, such as a resting hand splint or a wrist orthotic. Many of these orthotic names are very regionally specific or in fashion because of specific marketing campaigns by orthotic manufacturers, and thus change over time.

Upper Extremity Orthotics

Upper extremity orthotics are used almost exclusively to prevent deformity or reduce contractures. The most common use of upper extremity orthotics is in children with quadriplegic pattern involvement who develop significant wrist and elbow flexion contractures. Using orthotics to stretch against these deformities may slow the development of more severe contractures; however, objective evidence to support this concept is not well documented. There is little or no harm from the use of these orthotics so long as the children are not uncomfortable and there is no skin breakdown caused by the orthotics. From a rationale perspective, the use of these orthoses during the adolescent growth period makes some sense. The orthotics may stretch the muscles and provide some stimulus for them to grow if the stretch can be maintained for many hours each day. The exact amount of time an orthotic should be worn to be beneficial is unknown, but 4 to 8 hours of brace wear a day are probably required.

Very few children get functional benefits from the use of upper extremity orthotics. Sometimes a very small thumb abduction orthosis will allow a child to hold a toy with finger grasp, which she could not do with the thumb in the palm. The benefit of upper extremity orthotic wear is not documented

objectively; therefore, a child's functional use of the limb should always be the determining factor. For example, if a child has a thumb-in-palm deformity that can be corrected with a thumb abduction orthotic but she refuses to bear weight or use the hand when the orthosis is applied, the orthotic should be abandoned.

Shoulder Orthoses

There are no useful orthotics for the shoulder. Attempts at abduction bracing of the shoulder are uniformly unsuccessful. An occasional child will have an abduction external rotation contracture of the shoulder with athetoid movement or spasticity that can be controlled using a wrist band and securing the forearm to the waist belt or lap tray of the wheelchair. Some children also develop shoulder protraction, and occasionally a parent or therapist will want to try a figure-of-eight shoulder retraction orthosis; however, the strength of this protraction cannot be overcome with a figure-of-eight shoulder orthosis because of its extremely poor mechanical advantage.

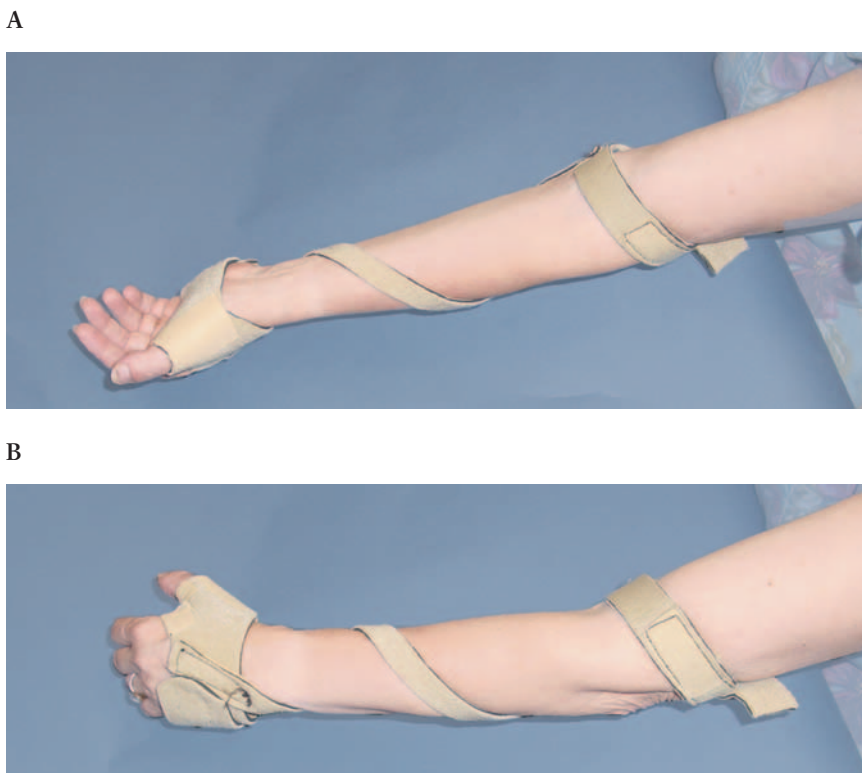
Elbow Orthoses

The principal deformity at the elbow that is amenable to bracing is flexion. In children with strong spastic flexion deformity, the use of a bivalve custom-molded high-temperature plastic orthotic is required. The use of fixed dial locks allows these orthotics to be placed in different degrees of flexion depending on the tolerance of the individual and their skin. Sometimes individuals can tolerate more extension on one day and less on the next. If the spasticity is weaker or the children are less than 10 years old, a low-temperature plastic orthotic that is molded to the flexor surface of the elbow with straps around the olecranon is simpler and much cheaper to construct. Usually, these orthotics are fabricated by an occupational therapist, and they can also be easily modified with a low-temperature heat gun if more or less flexion is required. There has been a recent commercial promotion to use elastic hinges at the elbow, which have continuous passive stretch on the elbow. No objective data exist to support this concept, and the standard teaching is that spastic and elastic do not mix. This saying comes from the usual finding that a constant elastic stretch on a spastic muscle usually continues to initiate the spasticity. A fixed stretch will allow the muscle to slowly relax and stop contracting. However, this dogma is not well substantiated by objective testing. Pronation contractures are very common in the forearm of children with spasticity. There are no orthotics that can effectively control a spastic forearm pronation deformity, although trying circumferential wraps are usually not uncomfortable for the child with a mild deformity (Figure 6.1).

Hand and Wrist Orthoses

Wrist and finger flexion combined with thumb abduction and flexion are very common deformities in children with CP. Wrist extension orthoses are used mainly after surgical reconstruction to protect the tendon transfers for some additional months after cast immobilization has been discontinued. Usually, these orthotics are volar splints, which maintain the wrist in 20° to 30° of wrist extension and are worn full time (Figure 6.2). These wrist splints seldom provide a functional benefit to children and are usually poorly tolerated for long-term use. In children or adolescents with hemiplegia, there is a major cosmetic concern about the appearance of the limb. The orthotic provides no functional gain and is very apparent; therefore, it is usually cosmetically rejected. Most children with good cognitive function object to wearing a wrist orthosis for more than a short postoperative period. A dorsal wrist extension splint is sometimes better tolerated; however, there is no

Figure 6.1. Using a soft foam material with Velcro closures, a circumferential wrap can be designed to provide some supination (A) stretch along with wrist dorsiflexion and thumb abduction (B). Many children with strong pronation spasticity do not tolerate these wraps.

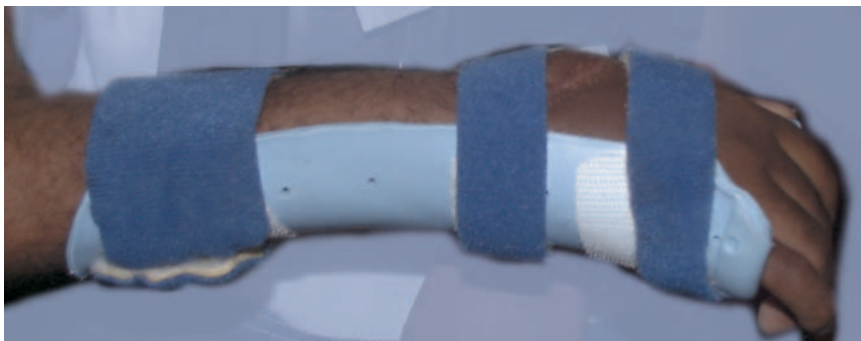

apparent improvement in function over the volar splint. The benefit of the dorsal splint is that it covers less of the palm and volar surface of the wrist and should therefore make more sensory feedback available to children during functional use. The disadvantage of the dorsal splint is that the force in the palm to extend the wrist is applied over a much smaller surface area, and if high force is required because of strong spasticity, the skin will often become irritated or develop breakdown.

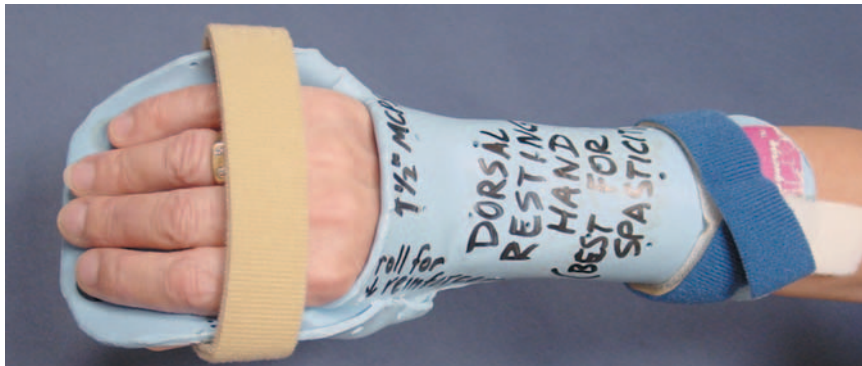Resting Splints

Resting hand splints, in which the wrist and fingers are all maximally extended to the comfort level of individual children, are good splints to help stretch the forearm muscles during the adolescent growth period. This splint may be made with a dorsal or volar forearm component (see Figure 6.2). The dorsal forearm component is easier to stabilize on the arm; however, it is often harder for caretakers to apply. The opposite is true if a volar forearm component is used. The resting hand splint can incorporate thumb abduc-

Figure 6.2. A splint that is entirely volar based can provide finger support or have the fingers free. This splint is very easy for caretakers to apply.



A



B

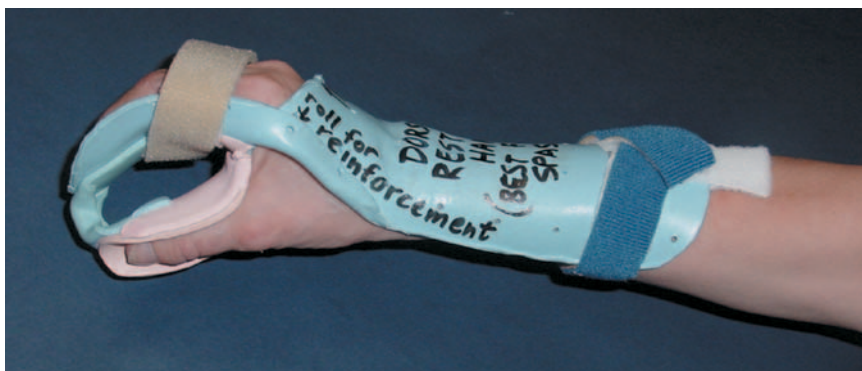

Figure 6.3. A dorsal-based resting hand splint will provide wrist dorsiflexion, finger extension, thumb abduction, and correction wrist ulnar deviation (A, B). The splint tends to be easy for caretakers to apply and is comfortable if no excessive stretch is applied at the time of construction. For postoperative support, the dorsal-based wrist extension splint is used during the day so that the child can start using active finger flexion.

tion and extension as well as finger abduction (Figure 6.3). Often, children tolerate these splints poorly immediately after initial splint construction. However, if the wear time is gradually increased, a goal of 4 to 8 hours per 24-hour period can often be achieved. This goal is ideal if children can tolerate the orthotic for this length of time; however, it is still worthwhile even if they can only tolerate the orthotic for 2 to 4 hours per day.

Thumb Splint

Thumb abduction and flexion is another common deformity. In most cases, this thumb deformity is combined with finger flexion and wrist flexion contractures, especially in children with quadriplegic pattern CP; therefore, the thumb deformity can be splinted using the global resting hand splint. For younger children with hemiplegia, thumb abduction can make finger grasp difficult. Using small, soft thumb abduction splints or low-temperature-molded abduction splints (Figure 6.4), the thumb can be positioned out of the palm in such a way that children can develop finger grasp. These splints should be limited to the absolute minimal amount of skin coverage possible because all skin coverage will reduce sensory feedback and the children will tend not to use their extremity.

Swan Neck Splints

Extensor tendon imbalance in the fingers may cause the fingers to become locked, with hyperextension of the proximal interphalangeal joint (PIP). This imbalance is most common in the long and ring fingers but occasionally occurs in the index finger. A metal or plastic figure-of-eight splint to prevent this hyperextension can be made (Figure 6.5). Usually, a plastic splint is used

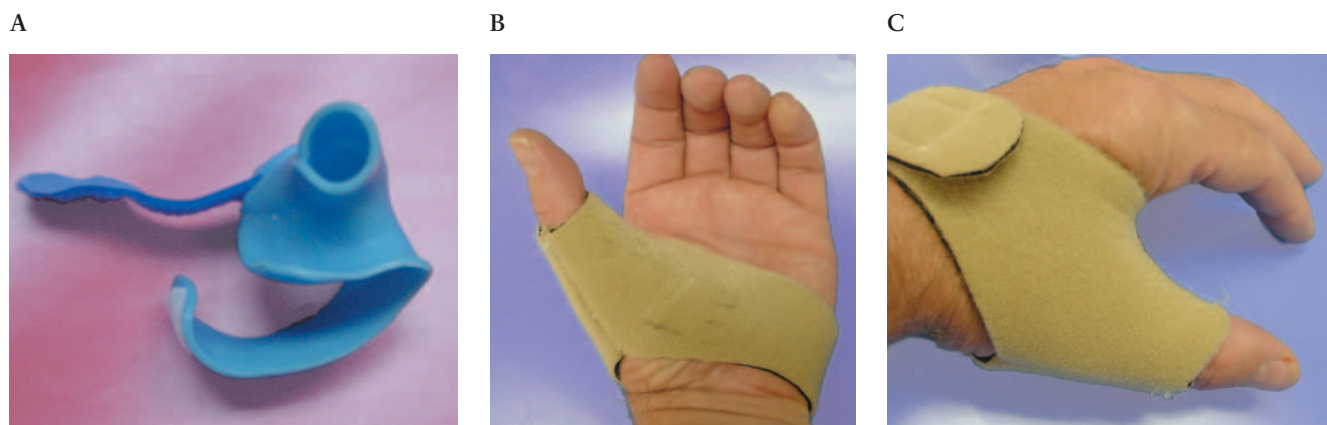


Figure 6.4. Thumb abduction splints can be constructed from a number of materials. Using low-temperature plastic, a well-molded splint can be formed (A). There are also many commercial splints available that are often more comfortable for the child (B, C). These are also available in different colors.

first and, if individuals find the splinting function beneficial, a metal splint is made, which is very cosmetically appealing because it looks like a cosmetic finger ring. In some individuals, these rings become uncomfortable because of the amount of force that the ring exerts over the very narrow area of skin. It is this narrow skin pressure that may limit the use of ring orthoses.

Spinal Orthoses

Soft Thoracolumbar Sacral Orthosis (TLSO)

Most children with CP who develop scoliosis are nonambulatory children with quadriplegic pattern involvement. The scoliosis is in no way impacted by the use of orthotics.¹ There is a role for the use of spinal orthotics to support sitting in children who are not independent sitters. The preferred orthotic is a soft thoracolumbar sacral orthosis (TLSO) with metal or plastic stays that are embedded in a soft plastic material (Figure 6.6). This soft material is well tolerated by sensitive skin and does not apply high areas of pressure. This soft TLSO works like a corset to support sitting. The orthotic may be worn over thin clothing so it is easy to apply and remove by caretakers. The TLSO is worn only at times when caretakers feel that the children have direct functional benefits. These orthotics are never worn during sleeping hours. Breathing may be restricted if the orthotic is too tight; however, the gain from upright sitting is approximately the same as the restriction from the orthotic.² For children with gastrostomy tube feedings, an abdominal

Figure 6.5. Finger proximal interphalangeal joint (PIP) joint hyperextension can be a difficult problem that is easy to control in some individuals with extension block splints. One type of commercially available splint is plastic-covered wire (A), and another common type is a molded figure-of-eight type plastic orthotic (B).

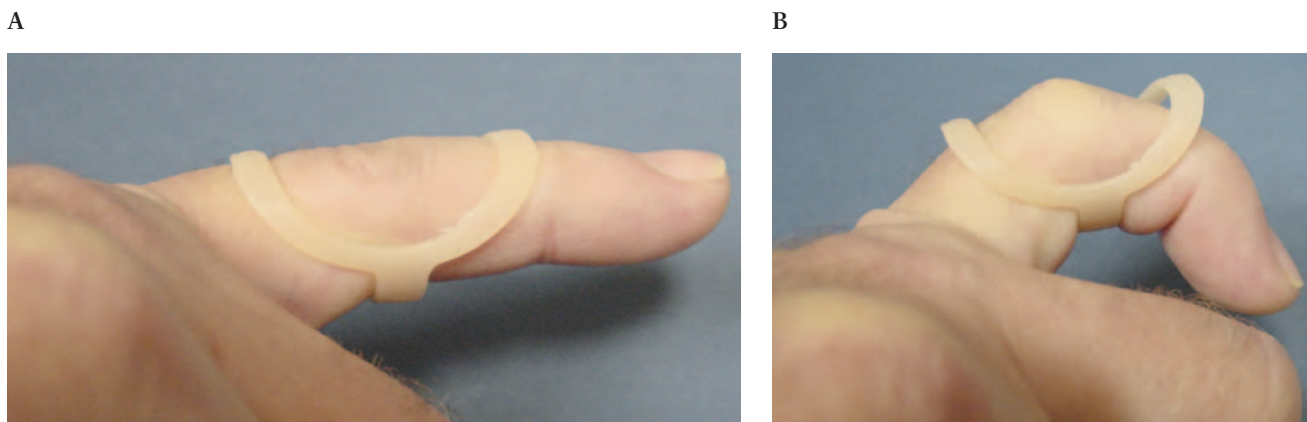

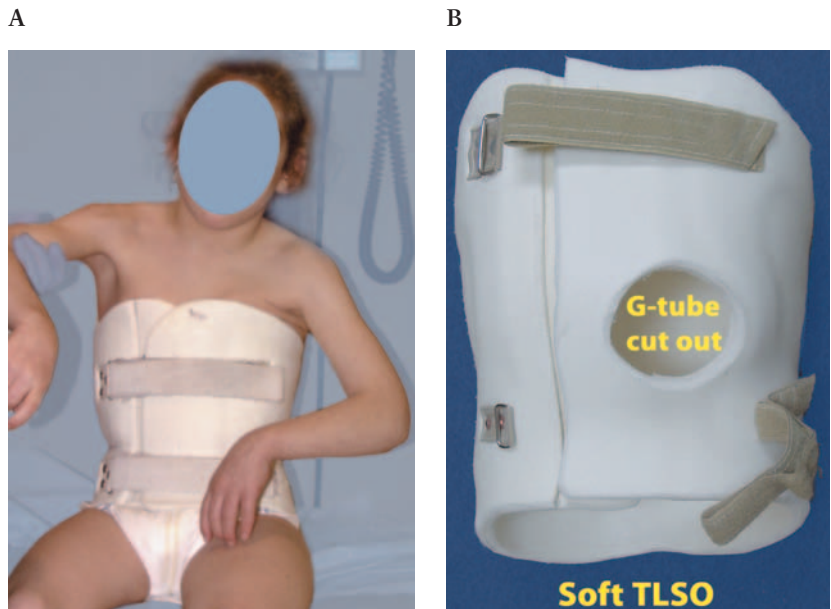


Figure 6.6. Although scoliosis in children with CP is not impacted by bracing, some children can sit much better with improved trunk support using a soft corset-type thoracolumbar sacral orthosis (TLSO). This orthosis is available in an off-the-shelf version; however, most children are more comfortable with a custom-molded orthotic (A). This orthotic is made with a soft plastic in which stiffer plastic stays are embedded to provide better support. The orthosis is only worn when it provides functional benefit, such as during sitting activities, and is never worn at night. If the child has a gastrostomy tube, the orthotic can be cut out to accommodate the tube (B).

cutout is required, which provides sufficient space and does not cause irritation. The indication for a soft TLSO is determined by the families' and caretakers' goals, with many families finding the adaptive seating working very well and thus no orthotic is needed. For families with children who sit in many different seats, the soft TLSO is especially helpful. The soft TLSO is made from a mold produced from a cast of the child's body. No attempt is made to get specific scoliosis correction, only to provide trunk alignment that maximizes children's sitting ability.

Bivalved TLSO

Usually, kyphosis is the result of truncal hypotonia and poor motor control. This deformity may slowly become fixed in some children; however, for most, it slowly resolves during adolescent growth. The initial treatment of kyphosis is by wheelchair adjustment and the use of a shoulder harness or anterior trunk restraint. However, there are children who do not tolerate the strong anterior trunk restraints or shoulder harnesses. Orthotic control of kyphosis requires the use of a high-temperature custom-molded bivalve TLSO (Figure 6.7). This orthosis must extend anteriorly to the sternal clavicular joint and inferiorly to the anterosuperior iliac spine. An abdominal cutout may be used if needed for a gastrostomy tube, but this should not be used routinely. The posterior shell needs to extend proximally only to the apex of the kyphosis. This orthotic provides three points of pressure to correct the deformity. Because kyphosis requires a very high force to correct the deformity, the orthotic will deform if it is not very strong. For this reason, the soft material construction of the scoliosis TLSO does not work for kyphosis. There are no data to suggest that the kyphotic-reducing bivalve TLSO has any impact on the progression of the kyphotic deformity; therefore, the orthotic is prescribed only for the functional benefit of allowing children to have better upright sitting posture and better head control. This orthotic should be used by children during periods of sitting when it is providing a specific functional benefit. The bivalve TLSO is never worn during sleep times. This bivalve orthosis is also constructed over a custom mold made from a cast of the child.

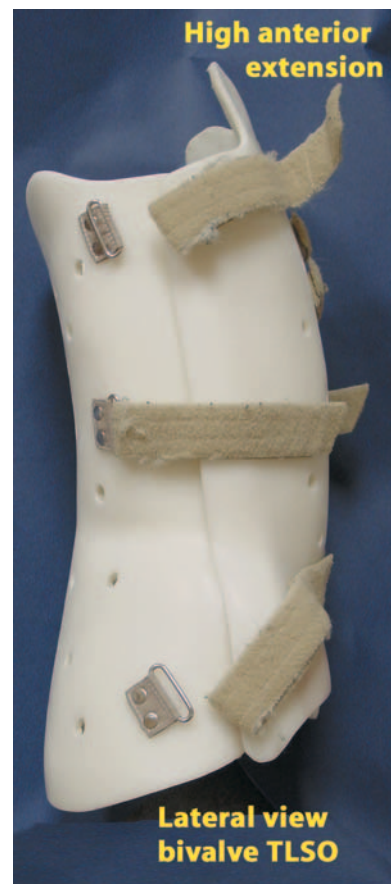

Figure 6.7. To control a kyphotic deformity, much stronger anterior support is required. The anterior aspect also needs to be high to the level of the sternal notch and low to the pubis; this requires a bivalve design in which there is an external shell of high-temperature plastic lined inside with a softer plastic.



Figure 6.8. For children who develop low back pain, usually from acute spondylolysis, a lumbar flexion jacket is required. This orthotic is higher in the back to prevent lumbar extension or lordosis and is low in the front and usually front opening. Many types of this orthotic are commercially available; however, many children need to be custom molded because the appropriate fit cannot be obtained from the available models.

Lumbar Flexion Jacket

Often, low back pain is the presenting symptom of acute spondylolysis and mild spondylolisthesis. If the pain is protracted, or the spondylolisthesis is acute, the pain should be treated for 3 to 6 months with a flexion lumbosacral orthosis (LSO) (Figure 6.8). This lumbar flexion orthosis is usually made from a low-temperature plastic that wraps around the lumbar spine and abdomen, maintaining the lumbar spine in flexion. The lumbar flexion orthosis may be molded directly on a child, or made from a mold produced from a cast. There are some commercially available lumbar flexion orthoses; however, they usually do not fit children well, especially children with CP whose body dimensions do not fit typical age-matched peers. This lumbar flexion orthotic should be worn full time for 2 to 3 months except during bathing. After this, the orthotic is worn only during the day for an additional 2 to 3 months, and then children are gradually weaned from the brace. Back pain should diminish very quickly after the initiation of the orthotic. Usually, within 1 week of full-time orthotic wear, children will report a significant reduction in their level of back pain. The spondylolysis may not heal during the brace wear and often remains; however, the pain almost always disappears and does not return.

Lower Extremity Orthotics

Hip Orthoses

The use of a hip abduction orthosis is often discussed in conferences; however, there are few objective data to support this use. The use of a hip abduction orthosis before surgical lengthening of the adductor muscles causes more harm than benefit based on modeling studies and objective reports.³ Therefore, abduction bracing of the hip should not be used to prevent hip dislocation before hip muscle lengthening surgery. Abduction bracing after muscle lengthening may improve the recovery of the hip subluxation; however, it may also increase the risk of severe abduction contractures.⁴ Therefore, in the balance, abduction bracing has little use after muscle lengthening. There is no objective evidence that abduction bracing is functionally beneficial to control scissoring gait in children with poor motor control. Rather than using large hip abduction orthoses, a much simpler and easier method to control scissoring gait is to use strings from the shoes attached to rails along the lateral sides of the walker. These strings will laterally restrain the feet so they do not cross the midline. A few walkers also have thigh guides (Figure 6.9). These lateral restraints are available with commercial walkers, or can be easily made with long shoestrings tied over the lateral edge of the walker frame.

Twister Cables

Internal rotation of the hip is very common in children with CP. There has been a long history of using twister cables or similar devices that are attached to waistbands proximally and to the feet distally, often via an AFO. These externally rotating devices have no published documentation of providing any functional benefit to children, or of aiding the resolution of the internally rotated gait either in the short term or in the long term. These externally rotating devices often slow children because they increase stiffness in the extremities. In this way, the use of these devices is somewhat similar to adding increased muscle tone or spasticity, of which these children usually have too much already. Also, the externally rotating stress tends to be concentrated at the knee joint, which is the joint with the least muscle force available to

resist the torsional stress that the orthotic applies. This external rotation force can potentially cause damaging stretching of the knee ligaments. Because there is no functional benefit and significant potential for harm, the use of rigid strong twister cables to counter internal rotation of the lower extremities should be abandoned.

Elastic Wraps

The use of elastic wraps has also been advocated to help control hip internal rotation. Usually, these wraps are attached to the proximal end of an AFO, wrapped around the thigh, and attached to a waistband proximally. These bands add relatively little force and almost no weight. Therefore, the negative effects of the twister cables are eliminated, and there are occasional children who seem to gain some minimal benefit from the use of these bands. These twister bands cause little harm and are reasonable to try in children who do not have strong spasticity or high fixed femoral anteversion but are mainly having internal rotation deformity of the hips secondary to poor motor control.

Knee Orthoses

Knee orthotics have a very limited use. Rarely, in children with back-kneeing that is causing knee pain or a worsening deformity, the only option may be limiting knee extension with a knee-ankle-foot orthosis (KAFO) using a free knee hinge that prevents hyperextension. Also, children with severe knee flexion contractures who have undergone posterior knee capsulotomies need to have prolonged postoperative bracing to prevent the recurrence of the flexion contractures. The best orthotic to use is a KAFO with a step-lock or dial-lock knee hinge so the knee can be gradually extended further as tolerated by the child (Figure 6.10). These orthoses cannot be used immediately

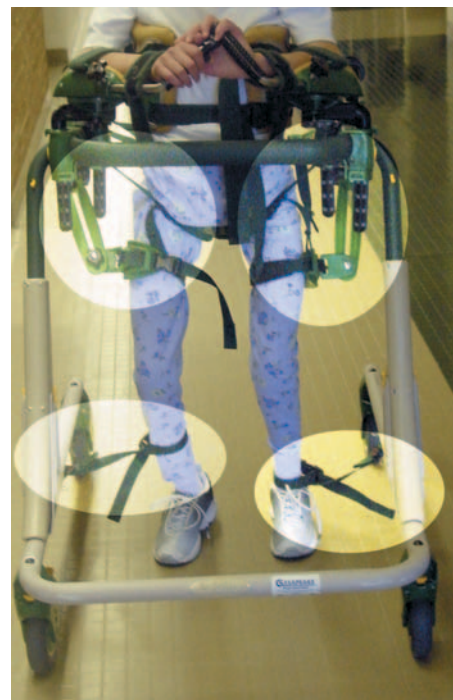

Figure 6.9. In general, hip abduction orthoses are too heavy to help children prevent scissoring. An excellent mechanism to control scissoring is to use the thigh and foot guides that are part of many gait trainers or walkers. Because almost all children who have substantial problems with scissoring require the use of a walker as an assistive device, this is a simple, effective, and easy solution.

A



B



C

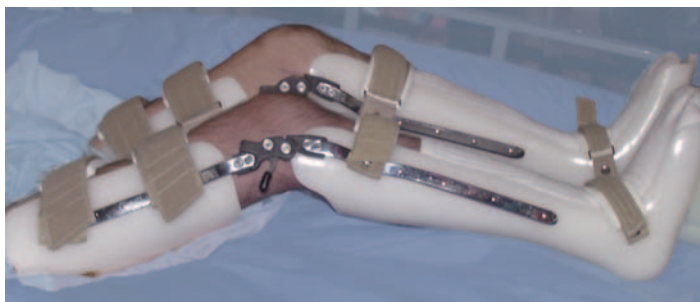


Figure 6.10. There are a few children with severe knee flexion contractures, especially those in whom surgical release is planned, who need progressive strong extension stretch. For these, a custom molded knee-ankle-foot orthosis (KAFO) with soft plastic lining (A) is excellent. A variable lock or step-lock knee hinge allows the child to spend time in varying degrees of extension (B). This orthotic is especially useful for a teenager in whom progressive stretching is desired (C).



Figure 6.11. A very common need is to provide a knee extension splint for a child with CP, and most of these can be addressed with a foam wrap that includes metal stays and Velcro enclosures. These commercially available knee immobilizers are cost effective, comfortable for the child, and easy for the caretaker to apply and remove.

postoperatively until the acute swelling subsides. For the first month, bivalve casts are usually used until children can tolerate the orthotic. The KAFO should be used for 12 to 16 hours per day after posterior knee capsulotomies, with the goal of having children sleep in the orthotic with their knee fully extended. After 6 months in the KAFO, and when their knee extension has remained stable, the orthotic can be slowly weaned and then discontinued sometime between 6 and 12 months postoperatively. The most common knee orthosis is the knee immobilizer, which is usually constructed of foam material in which plastic or metal stays are embedded. The orthosis is wrapped around the limb and held closed with Velcro straps (Figure 6.11). The knee immobilizer is used as a knee extension orthotic after hamstring lengthening or for nighttime splinting for hamstring contractures.

Ankle-Foot Orthoses

Ankle equinus is the most commonly recognized joint malposition in children with CP. Orthotic control of this equinus position has a long history and is the oldest treatment of the motor impairments of CP. The availability of modern thermoplastics has greatly increased the options for orthotic management compared with the old heavy metal and heavy leather shoe devices. The plastic braces provide a much larger skin contact, so the forces from significant spasticity are distributed over a larger surface area and are better tolerated. Because of wide size and shape variation of the feet in children, most of these orthotics should be custom molded for the best fit (Figure 6.12). The use of AFOs includes many different variations, and all the published studies have confirmed the mechanical effects of these orthotics. For example, if the ankle is blocked from going into equinus by the orthosis, there is decreased ankle range of motion and decreased ankle equinus.⁵⁻⁷ These same studies do not show predictable effects at joints not covered by the orthotic. Also, if the orthotic has a hinge that allows dorsiflexion, there is more dorsiflexion present than when the orthotic has a fixed ankle.⁶ There are no data to suggest that one type of orthotic or different design is better than any other. The concept of pressure points in specific molds to reduce muscle tone has no objective data to support their use. There is objective evidence that these orthotics can improve children's balance ability.⁸ Balance may be better with hinged AFOs than with solid AFOs.⁸ Others have found no difference between hinged and solid AFOs,^{6, 7} or between hinged and solid AFOs and tone-reducing designs.⁹ There is improved stability in the stance phase of gait^{10, 11} and improved ankle position in swing and at foot contact.¹² Also, improved stability by the use of AFOs in children who are coming to stand in the preambulatory phase has been documented.¹³ Based on these limited objective data, most specific prescriptions for foot orthotics require a consideration of the skills of the available orthotist and the specific mechanical goals desired in the individual child.

Confusing Terms

The terminology used in describing specific components of AFOs is very confusing. The term dynamic is used in the literature to mean an AFO with a hinge joint at the ankle; however, it is also used to mean a solid plastic AFO made of thinner, more flexible plastic that wraps around the limb to gain stability. Tone reducing is another term that is widely used but has no specific standard meaning. To avoid confusion, the terms dynamic and tone reducing are not used further in this discussion. Hinged or articulated will be used to mean an orthosis that contains a joint at the ankle, and the term wrap-around will be used to refer to the thinner plastic with a fuller circumferential mold.

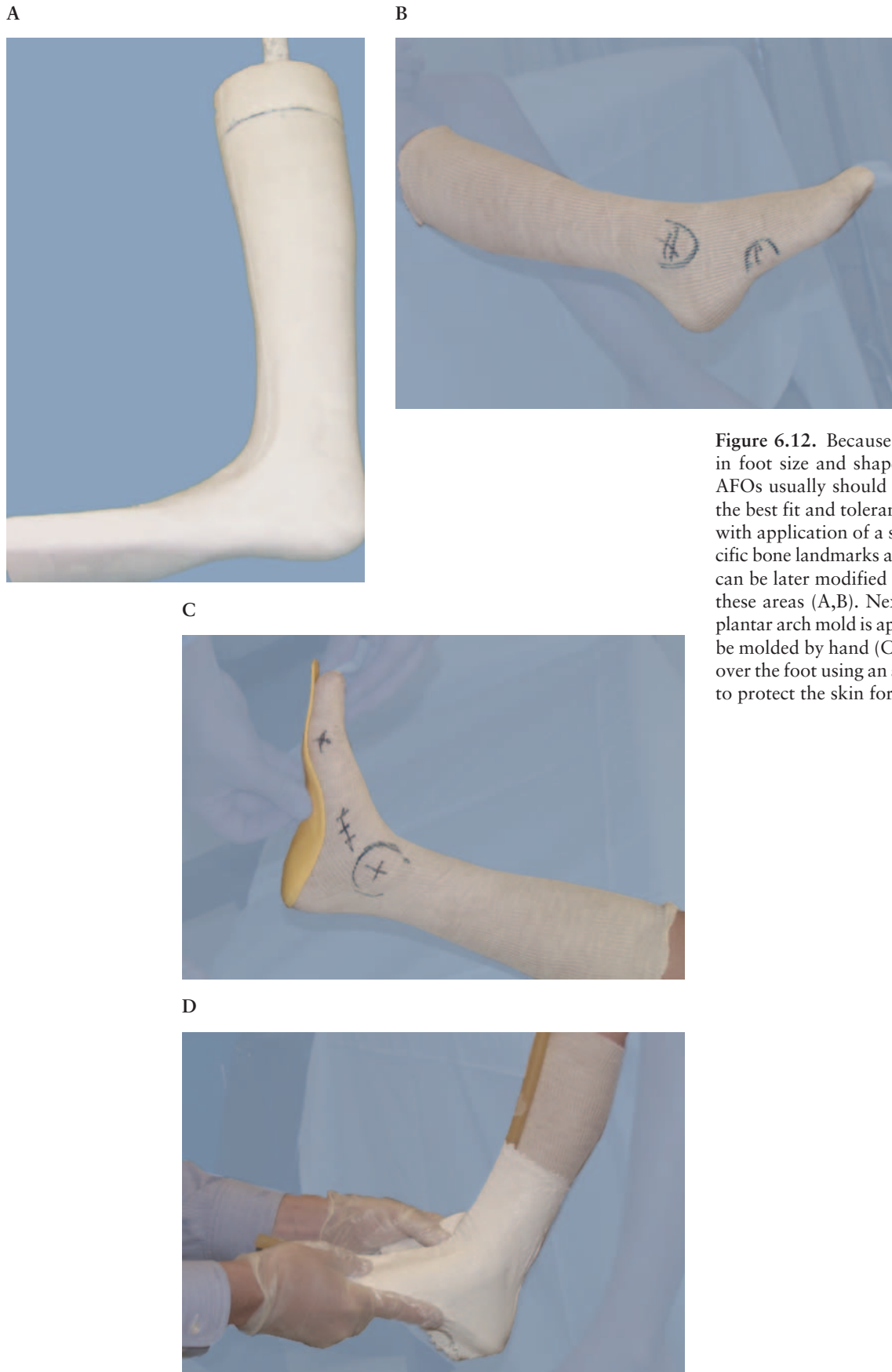


Figure 6.12. Because of the wide variation in foot size and shape in children with CP, AFOs usually should be custom molded for the best fit and tolerance. This process starts with application of a stocking on which specific bone landmarks are outlined so the mold can be later modified to prevent pressure on these areas (A,B). Next, either a premolded plantar arch mold is applied or the arch has to be molded by hand (C). Plaster is now rolled over the foot using an anterior rubber bolster to protect the skin for cast removal (D).

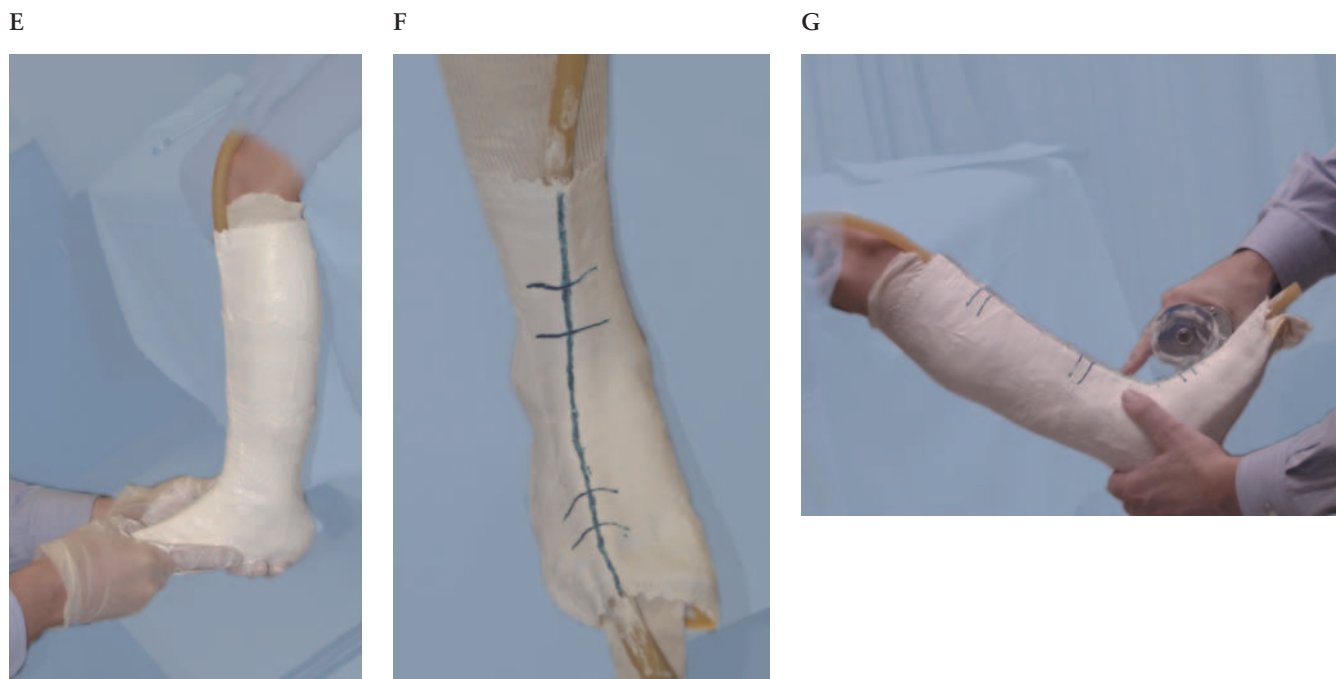
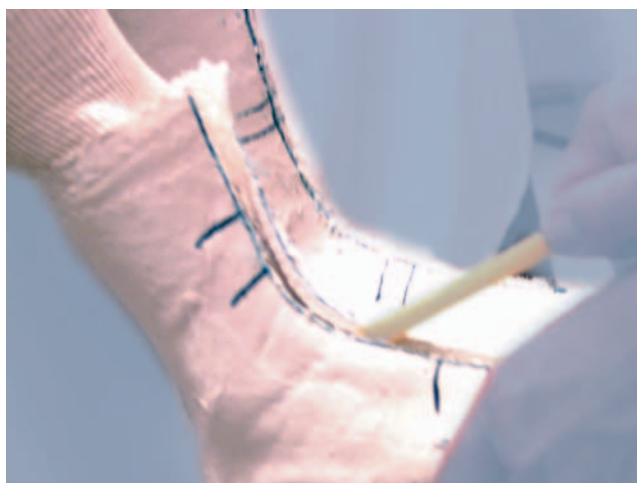

Figure 6.12 (continued). After the plaster has been rolled on the whole leg, the foot is carefully positioned and held by the orthotist in the desired corrected position until the plaster hardens (E). The plaster is now marked anteriorly where it will be cut; this will allow the cast to be closed accurately for pouring of the mold (F). The cast is now removed (G), and the bolster is removed, splitting the cast open (H).

H



AFO

A solid AFO with an anterior calf strap and an anterior ankle strap is the most versatile orthotic design and is the orthosis most often prescribed for children at the preambulatory stage, usually between the ages of 18 and 24 months (Figure 6.13). This orthotic provides stability to the ankle and foot to give a stable base of support for children to stand. This orthosis is reasonably easy for caretakers to apply and is lightweight. As children gain better stability and start to walk using a walker, usually between the ages of 3 to 4 years, the ankle hinge can be added to allow dorsiflexion but limit plantar flexion. This transition to a hinged AFO is contraindicated if children have severe planovalgus or varus foot deformity (Figure 6.14). The hinge will allow movement through the subtalar joint rather than the ankle joint and, as a consequence, will allow worsening of the foot deformity in the orthosis. Also, the hinged AFO is contraindicated if the children are

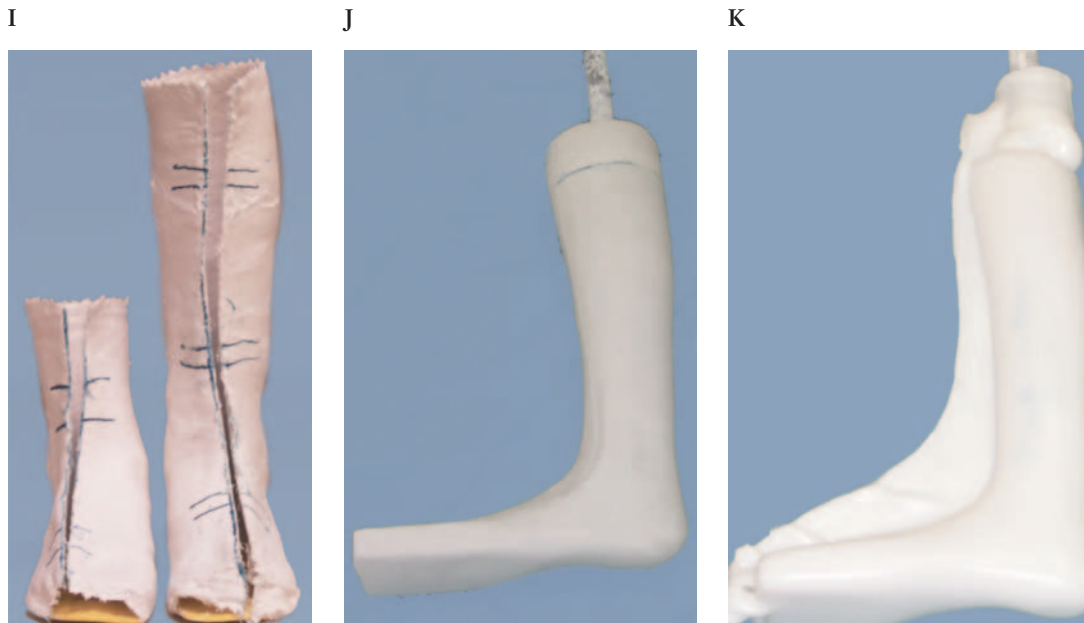


Figure 6.12 (continued). Following removal, the casts are inspected to make sure they are plantigrade and have the desired correction (I). The cast is then filled with plaster to make a positive mold, which has the relief areas increased further (J). The mold is then placed in a high-temperature oven over which a plastic cover is vacuum formed (K). The orthotic is then cut from the vacuum-formed plastic, trimmed, smoothed, and pads and straps applied.

developing increased knee flexion in stance or a crouched gait pattern. Most children who have good walking ability with diplegic and hemiplegic pattern involvement benefit from the transition to a hinged AFO at approximately 3 years of age. Most children who are marginal ambulators or non-ambulators will be best served by staying in solid AFOs. Hinged AFOs are preferred for children who back-knee because of gastrocnemius contractures. By setting the plantar flexion stop at 5° of dorsiflexion, these children will be forced into knee flexion in stance if they are independent ambulators. If they use assistive devices, such as walkers or crutches, they may still back-knee by allowing the forefoot to come off the floor. If this occurs, the shoe should have a good wide stable heel; however, in spite of this, some children will persist with back-kneeing and can be controlled only with a KAFO that blocks knee hyperextension directly.

Ground Reaction AFO

Controlling crouched gait with increased knee flexion and ankle dorsiflexion in stance phase is best done using solid AFOs with wide anterior proximal calf straps until children weigh 25 kg, usually at about 8 to 10 years of age. For children who are over 25 kg, the solid ankle ground reaction AFO, which is rear entry in the calf, is recommended (Figure 6.15). The use of this orthosis requires that the ankle can be brought to neutral dorsiflexion with the knee in full extension. If this cannot be accomplished, the orthosis cannot work and these children first need gastrocnemius and hamstring lengthening before the orthosis can be used successfully. The successful use of this orthotic requires that there be very little knee flexion contracture. Because this orthosis depends on the mechanics of an effective ground reaction force, the foot-to-knee axis has to be in a relatively normal alignment, meaning less than 20° of internal or external tibial torsion. This solid ground reaction AFO does not work with severe internal or external tibial torsion or severe foot malalignments. The ground reaction AFO only works when children are standing on their feet, and as such is useful only for ambulatory children. As these children get heavier, this orthosis becomes more effective; however, it also has to become stronger. As children approach 50 to 70 kg, the orthosis

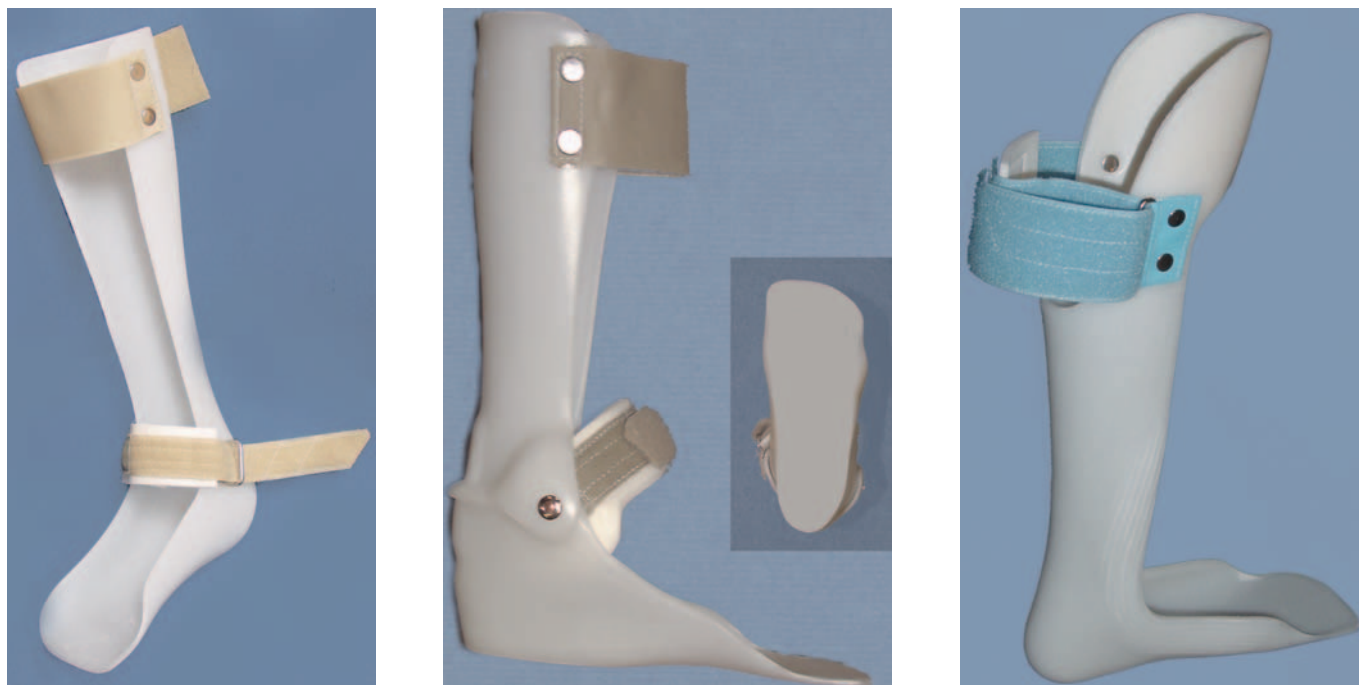

Figure 6.13 (left). The most basic AFO has a solid ankle, an anterior ankle strap, and an anterior calf strap. This is the preferred orthotic for preambulatory children and most marginal ambulators.

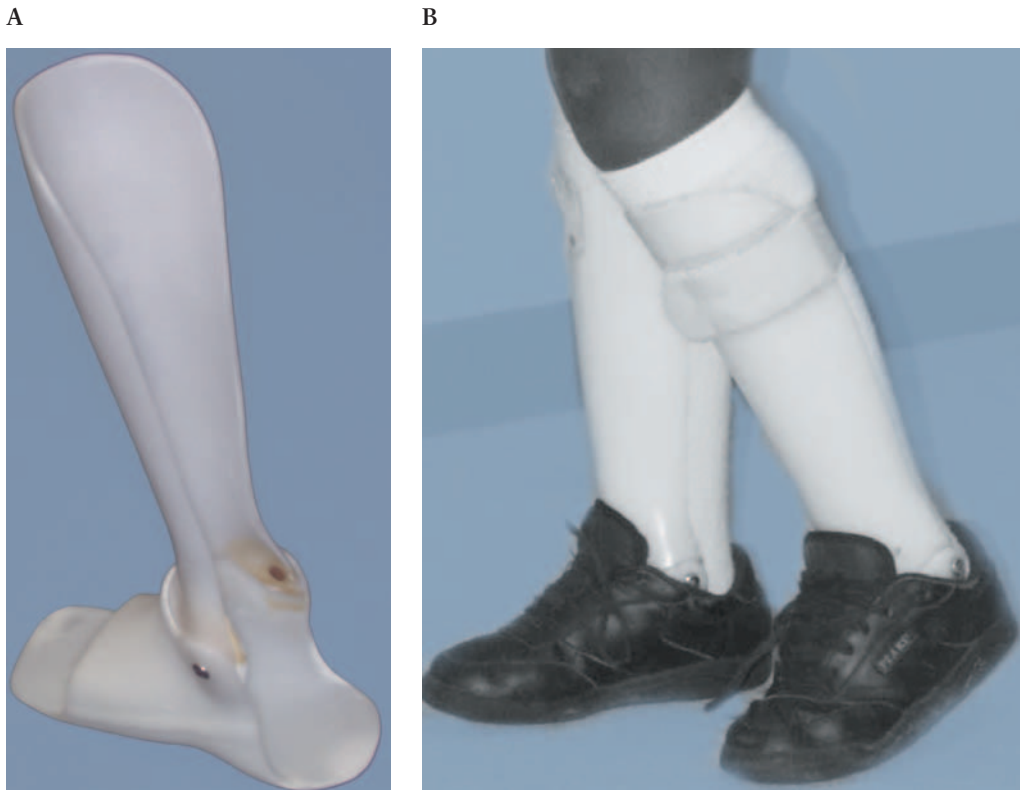Figure 6.14 (middle). As children gain ambulatory ability and the main goal of the orthotic becomes preventing plantar flexion, a plantar flexion-limiting ankle hinge joint can be added. The remainder of the orthotic is similar to the solid ankle, with perhaps a flat sole or additional arch molds added. These tone-reducing features have not been shown to change gait in any measurable way.

Figure 6.15 (right). The solid ground reaction AFO is entered from the rear at the calf level. This is an anticrouching orthosis and has very specific requirements to work. The knee must be able to fully extend, the ankle has to be able to dorsiflex to neutral with an extended knee, the foot progression angle must be within 30° of neutral, and the tibial torsion must be less than 30° . This orthosis depends on the action of the ground reaction force, and as such is only effective when the child stands or walks and if the child has enough weight, usually 30 kg or more.

has to be constructed with a composite of carbon fiber or laminated copolymer to withstand the applied forces.

Articulated Ground Reaction AFO

The ground reaction AFO may be hinged to allow plantar flexion but limit dorsiflexion (Figure 6.16). This orthosis is primarily used after surgical reconstruction of the feet and muscle lengthening as a bridge to allow development of increased muscle strength in the plantar flexors, with the long-term goal of individuals being free of an orthotic. However, some individuals continue to use this articulated ground reaction orthosis long term. The orthosis can be used before surgery on rare occasions; however, a prerequisite for using articulated ground reaction AFOs is normal foot alignment. The articulated ground reaction AFO is entered posteriorly into a circumferentially molded forefoot, but with no hindfoot control. If there is any planovalgus or varus hindfoot deformity, the foot will deform even more severely into planovalgus or varus under the strong force of the ground reaction moment. Because this articulated ground reaction AFO contains no resistance to prevent deformity, the orthotic is usually not tolerated because of significant skin pressure on the forefoot when any degree of planovalgus foot deformity is present. Older children weighing more than 25 kg who meet the other criteria will usually be very comfortable with the articulated ground reaction AFO, and the orthotic will be very effective in controlling crouched gait. However, it must be emphasized that this orthosis works only when all the indications are appropriate. Another option for using the articulated ground reaction AFO that may be useful in younger children who weigh less than 20 kg is to use the standard articulated AFO and then attach a posterior restraining strap, which prevents dorsiflexion at a certain predetermined amount (Figure 6.17). Often, these restraining straps are made of a fabric material and stretch over time, so they have to be reset fairly frequently. This design never works for heavy adolescents because there is no orthotic material that is strong enough to resist the force of dorsiflexion from the ground reaction AFO.



Half-Height AFO

The use of a solid AFO without an anterior calf strap is a design to control plantar flexion that will allow free dorsiflexion (Figure 6.18). If children use considerable dorsiflexion, their calves move away from the shank of the orthosis and can be very uncomfortable. Because it is uncomfortable when the calf presses against the edge of the orthotic shank, these solid ankle AFOs without anterior calf straps are usually cut low to only half the normal calf height. This design works well if children have very mild plantar flexion force and mainly need a gentle pressure reminder to prevent plantar flexion in swing phase or early stance phase. This design is contraindicated if there is strong plantar flexion spasticity or significant stance phase-back kneeling, as the orthosis does not provide adequate mechanical control of the ankle to control these deformities. Also, the half-height design can cause a high-pressure area in the posterior aspect of the calf, leading to a fracture of the subcutaneous fat and a permanent transverse line on the middle of the posterior calf (Table 6.1). Also, some children are irritated by their pant legs getting pinched between the orthotic and their skin. This half-height AFO brace design is very useful in middle childhood at a point when children almost do not need an orthosis, but still have a tendency to back-knee or to intermittently walk on their tiptoes.

Wrap-Around AFO Design

Other specific design features include the choice of the material for the orthotic. Most children's AFOs are custom molded and made of high-temperature, vacuum-formed thermoplastics. This material is available in several thicknesses, with a thickness chosen by the orthotist to meet the perceived demands based on the size of the individual child. Most commonly, this orthotic

Figure 6.16. The ground reaction concept can also be applied with the goal of increasing ankle plantar flexion while preventing crouching. This requires an orthosis that limits dorsiflexion and allows plantar flexion. The use of this rear-entry orthosis has all the requirements of the solid ankle ground reaction AFO, and in addition requires that there be no foot deformity (A). Because the rear entry does not allow any orthotic control of the hindfoot, varus or valgus foot deformities make this orthosis not useful. The most common reason to use this orthosis is following surgical reconstruction of severe crouch gait, in which the planovalgus was corrected and the goal is to gain improved plantar flexion strength with the eventual goal of the child becoming brace free (B).



Figure 6.17. There are a group of children who are smaller, especially with some plano-valgus foot deformity, in whom some ankle motion is thought to be beneficial. One alternative is to use a standard articulated AFO and attach a posterior restraining strap to prevent hyperdorsiflexion. Although this seems like a good goal, unless the child is very light, there does not seem to be any cloth material that can be attached to the orthotic that does not rapidly stretch out.

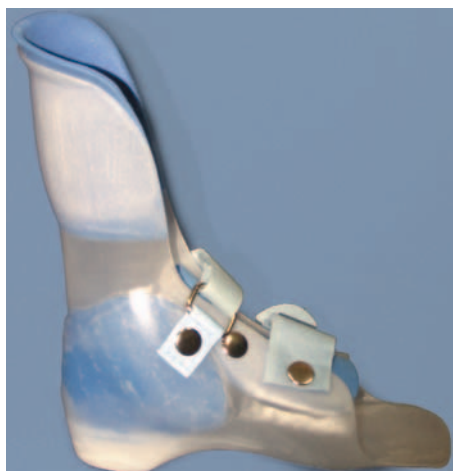

Figure 6.18. The use of a short calf segment with no anterior calf strap is an alternative to an articulated AFO. This design works well if the plantar flexion force is mild and the child just needs a little reminder to stay out of plantar flexion. If the child has strong plantar flexion, the calf segment will gradually erode a crease in the subcutaneous fat and can leave a permanent crease in the calf.

covers the posterior half of the calf and plantar aspect of the foot. The orthotic can be customized further with soft pad inserts (Figure 6.19), and it has some limited ability to be expanded by the orthotist by heating the material or being able to weld material on at the end of the toe plate or at the shank. Most of these orthotics can be made to fit for 12 to 18 months in growing children. Another design that has recently gained popularity is the use of a thinner thermoplastic plastic, which wraps circumferentially around the limb (Figure 6.20). The strength of the orthosis is gained from the circumferential wrap. This thin plastic tends to be more flexible and therefore deforms slightly when force is applied. Also, the circumferential wrap tends to apply a wider contact area to the skin, often distributing forces over a larger area of skin. The negative aspects of this thin plastic wrap-around technique is that the orthotic is difficult to apply to uncooperative children because caretakers have to use two hands to open the orthotic and to apply it to the foot. Also, it is difficult for some children to self-apply this orthotic for this same reason. Because the plastic is very thin and closely conforming, it cannot be modified for rapidly growing children and in some situations will only fit for 6 to 9 months. Because the plastic is also not very strong, it cannot be used in high-stress situations like ground reaction AFOs.

Anterior Ankle Strap

The design of the anterior strap is another variable feature, with some methods working better than others. All AFOs made for individuals with spasticity need an anterior ankle strap. For children with strong plantar flexion spasticity, the ankle strap should be fixed at the level of the axis of the anatomic ankle joint, then brought to the opposite side through a D-ring and wrapped back on a Velcro closure (Figure 6.21). This method proves to be the strongest direct force to control the plantar flexion. A figure-of-eight strapping may be used as well; however, this does not provide very strong control over the anterior ankle, although it does distribute the force over a larger area of skin. If children have varus deformity of the foot, the strap should be fastened on the inside of the lateral wall of the orthotic and brought through a medial D-ring. If the foot has a valgus deformity, the strap should be attached on the inside of the medial wall of the orthotic and a lateral D-ring should be used.

There are many variations of molds on the sole of the foot, none of which have any documented objective benefit (Figure 6.22). Some of these molds seem to make some subjective difference. Using an elevated toe plate seems to decrease the plantar flexion push in some children and helps in rollover in the forefoot in terminal stance in other children who are very functional ambulators. The only drawback of the elevated toe plate design is the difficulty of extending the orthotics to increase wear time because of growth. Also, the elevated toe plate cannot be moved once it is molded into place. Contouring for a medial longitudinal arch, a distal transverse arch, or a lateral peroneal arch is used by some orthotists. So long as these contours are not excessive, they may help to stabilize the foot in the orthotic, but they provide little other benefit that we can identify and no benefit that can be measured objectively.⁶

The distal extend of the orthotic has to be specified in the prescription. Almost all children with spastic deformities should have the orthotic extend to the tips of the toes to provide control of toe flexion. Almost all children with spasticity tend to have a toe flexor response when there is stimulation on the plantar aspect of the toes. The toes tend to always flex as if they were trying to hold or grab onto something. This is often the first area where children outgrow the orthotic and is the primary area that needs to be monitored for adequate AFO size. Children with hypotonia or predominantly

Table 6.1. Problem-based understanding of orthotics.

Anatomic problem	Proposed solution	Pros and cons of the solution
1. Flexed toes, spastic toe flexion	A. Biomechanical foot plate (BMFP) B. Standard foot plate to toe tips	Pro: BMFP - foot more stable and better rollover in third rocker Con: BMFP - not adjustable for growth, and need wider toe box in shoes
2. Forefoot abduction or adduction	A. Thin plastic wrap around B. Heavier plastic mold with distal side supports	Pro: good control, thin Con: difficult donning Pro: easy donning Con: bigger shoes needed
3. Hindfoot varus or valgus		
a. Mild deformity Causes mild discomfort walking No mechanical impact walking	A. University of California Biomechanics Laboratory (UCBL) wraparound B. UCBL solid plastic	<i>Wrap around:</i> Pro: good control, thin Con: difficult donning <i>Solid plastic:</i> Pro: easy donning Con: bigger shoes needed
b. Moderate deformity Discomfort walking Impacting mechanical stability walking	A. Supramalleolar orthotic (SMO)–ankle-foot orthosis (AFO) wraparound B. SMO-AFO solid plastic	<i>Wrap around</i> is more flexible and will allow collapse in the brace but may cause less skin pressure <i>Solid plastic</i> is stronger and will hold the deformity correction better because it is stronger and will not collapse, high skin pressure can occur, which may become painful
c. Severe deformity Significant discomfort Significant lever arm disease	A. Full-AFO wraparound B. Full-AFO solid plastic	
4. Ankle plantar flexion control		
a. Due to weak dorsiflexion Weak tibialis anterior	Full-height leaf spring AFO Half-height AFO	<i>Leaf spring:</i> Too flexible, will break quickly Too stiff will have no ankle motion
b. Poor muscle control Poor control in both medial-lateral and dorsiflexion	Full-height solid AFO Full-height articulated AFO	<i>Half height:</i> Pro: small for cosmesis Con: too much calf pressure can cause permanent skin mark
c. Spastic gastrocsoleus Causing toe walking		<i>Solid AFO:</i> Better foot control, tighter fit, and smaller brace with solid ankle
i. Poor control severe spastic	Full-height articulated AFO	<i>Articulated AFO:</i> Dorsiflexion in 2nd and 3rd rocker with muscle stretching with articulated ankle joint
ii. Some control moderate spastic	Half-height AFO	
5. Ankle dorsiflexion control		
a. With need to control plantar flexion, i.e., crouch gait with equinus in swing phase	A. Solid ground reaction AFO (GRAFO) B. Standard solid AFO with wide anterior calf strap	<i>GRAFO:</i> This can accommodate mild to moderate foot deformity but must have normal thigh-foot alignment in torsion. Child should weigh more than 30 kg and must have near full knee extension. <i>AFO:</i> Easy to don and works well for child less than 30 kg.
b. Active dorsiflexion and weak plantar flexion No foot deformity or torsional deformity	Anterior articulated ground reaction—Art GRAFO Art GRAFO	This rear-entry brace requires a normally aligned foot in both varus/valgus and torsion as well as near full knee extension.
6. Too much knee flexion in stance phase	Ground reaction AFO based on ankle control as noted above	Must have passive knee extension and adequate hamstring length.
7. Knee hyperextension in stance phase (back-kneeing)	Articulated AFO set in 3°–5° of dorsiflexion for plantar flexion block	Passive dorsiflexion must be possible.

ataxia often need only a distal extend to the base of the metatarsals or the base of the toes. In these hypotonic or ataxic children, there can be a detriment to extending the orthotic because it makes rollover in late stance phase more difficult.

Foot Orthotics

Orthotics that do not control plantar flexion and dorsiflexion of the ankle are called foot orthotics. None of these orthotics has any impact on ankle plantar flexion or dorsiflexion.⁶ The role of these orthotics is to control deformities of the foot, mainly planovalgus and equinovarus deformity. These orthotics are primarily used in children with hypotonia, or in middle childhood



Figure 6.19 (left). The solid AFO design can be modified by adding softer inside pads to protect bone protrusions or pressure areas.

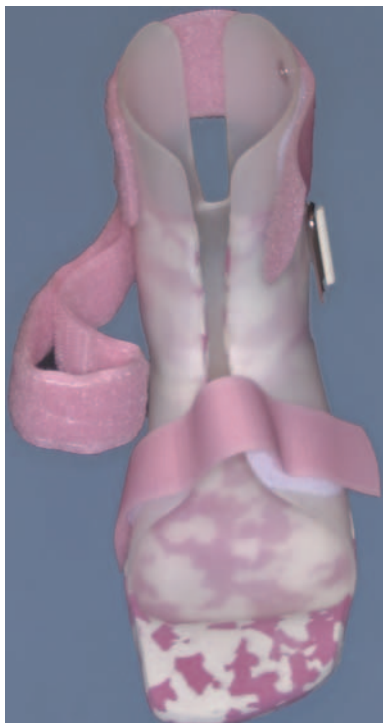

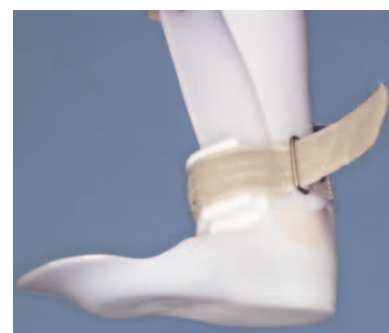Figure 6.20 (middle). An orthotic design that uses a thinner, more flexible plastic with a circumferential wrap can be used for many of the different designs. Its major limitation is that the thin plastic is weaker and gains strength by the circumferential wrapping nature of the design. It does not work for high-stress environments, such as ground reaction AFOs, and can be difficult to put on and take off, especially for children just learning to dress themselves.

Figure 6.21 (right). AFOs made for children with spasticity need a good stable anterior ankle strap that is directed across the axis of the ankle joint. One of the best options is a padded anterior ankle strap that loops through a D-ring fixed on the side opposite the main deforming force (A). If the child has a planovalgus foot, the D-ring is lateral and if the foot is varus, the D-ring is medial; this allows using the D-ring to provide leverage to tighten the strap and allows the Velcro to hold better (B).

A



B



and adolescents with spastic foot deformities. The supramalleolar design extends above the ankle on the lateral side with the goal of controlling varus or valgus deformity (Figure 6.23). The foot orthotic can have all the same design features and options that were discussed in the section on AFOs. Usually, an anterior ankle strap is used; however, in some older children with good ankle plantar flexion control, this is not needed. Also, the heel is typically posted on the side opposite the deformity. This means a lateral squaring of the heel is added for varus deformity so the ground reaction force will tend to counteract the deformity. The opposite is done for valgus deformity, in which a post is added to the medial side of the heel. This supramalleolar foot orthotic design also works well with the wrap-around thin plastic design; however, the same problems occur as noted with the standard AFO. It is more difficult for children to don the orthotic, and heavy children tend to collapse the orthotic the same way a shoe deforms with long-term wear. There is no clear choice between the thin plastic wrap-around design and the solid plastic half-mold design. Input from the families and children should be considered as well as the preference of the orthotists. Most children who need control of planovalgus or varus, but have good plantar flexion and dorsiflexion control of the ankle, should be fitted with a supramalleolar orthotic (SMO).

There are a few children, mainly those with hypotonia and ataxia, who have moderate planovalgus that is easily controlled but who can be fitted with an inframalleolar orthotic (Figure 6.24). This orthotic contains a good heel mold, a medial longitudinal arch mold, a heel post, and typically stops at the metatarsal heads proximally. These orthotics can be set into shoes, have no anterior ankle straps, and are very easy to don because they do not need to be removed from the shoe. Applying this orthotic is no more difficult than putting on children's shoes. The use of this orthosis in spastic foot deformities is limited because of its limited ability to provide corrective force. Another name that is used for this inframalleolar orthotic in some locations is a "University of California Biomechanics Laboratory" (UCBL) orthotic.

A



B



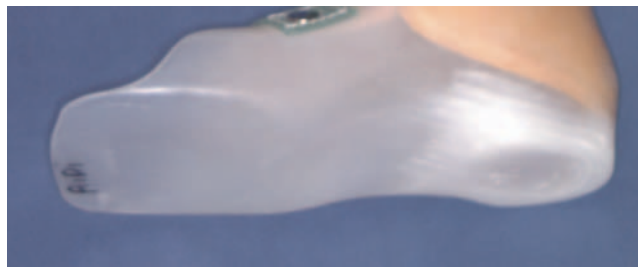C



D



E



F



Figure 6.22. The degree of contouring and molding of the plantar surface of the orthotic inspires a lot of discussion and strong feelings; however, objective data currently do not suggest that it makes much difference. The tone-reducing features are varied; however, they tend to include some combination of transverse metatarsal arch, medial arch, peroneal arch, and transverse calcaneal arch (A,B). When comparing the relatively flat sole often used (C) with the highly contoured sole, there is minimal functional difference. The same benefit can also be obtained by adding pads to the inside of the orthotic using a soft plastic (D). These pressure areas can also be molded directly into the orthotic. Some also like to square off the heel on the outside to give better control of the orthotic in the shoe (E). This feature makes application of the shoes harder than leaving the heel rounded, and less contouring on the toe plate allows easier extension of the orthotic as the child grows. Another technique used is to flatten the sole externally with a rubber material; however, this increases the height of the orthotic and makes shoe fitting more difficult (F).

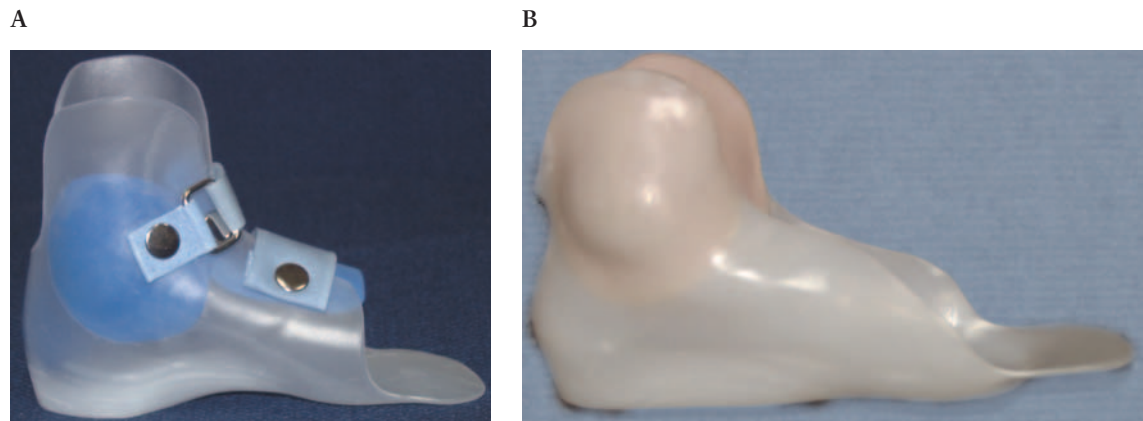


Figure 6.23. In-shoe foot orthotics are used primarily to control planovalgus or varus foot deformities. These can be constructed with the wrap-around design (A) or with the solid plastic, which sits in the shoe (B). Both of these are supramalleolar type and provide support for the foot.



Figure 6.24. For feet that need only mild support, an in-shoe arch support can be constructed, again either with the wrap-around thin plastic, or the heavier, no-deforming material; these are commonly called inframalleolar orthotics or “University of California Biomechanics Laboratory” (USBL) orthotics.

The use of shoe inlay arch supports have little role in the management of foot deformities in children with CP. The force of the collapsing foot is so high that the shoe and inlay orthotic make no impact. Orthotics to control toe deformities are also of little use, although some children find the use of soft toe spacers helpful to keep the toes from overriding and getting compressed in shoes.

Seating

The single most important device for children with CP who are nonambulatory is the wheelchair. For these children, the wheelchair is an ambulatory orthotic, and as they get older and bigger, they become more and more dependent on the wheelchair for mobility. For example, a 12-month-old child can be carried when the family leaves the home; however, a typical-size 12-year-old will not be able to leave the house without a wheelchair. This evolution of importance of the wheelchair occurs slowly to parents. Initially, parents may be very resistant to the concept of a wheelchair because it forces them to acknowledge the degree of their child’s disability, and having a wheelchair in public draws attention from surrounding people. This whole concept takes time for parents to come to terms with and to understand. It is important for physicians and physical therapists to have open discussions with parents of young children. By explaining this natural resistance, parents are given permission to feel hesitant about obtaining a wheelchair for their children. This discussion also allows parents to think realistically about their own fears and anxieties about being in public with a child who is clearly disabled. For children with good cognitive function, their response and that of their parents are often very different. Usually, at about 5 to 7 years of age, cognitively normal children will resist being in public in a device that looks like a baby buggy, and they would much rather be in a wheelchair, which they tend to see as a grown-up person’s chair. Children’s feelings have to be brought to parents’ attention because the parents may still be in the phase of wanting the baby buggy stroller because it does not draw as much attention and looks less “disabled.”

Considerations in Obtaining a Wheelchair

Many parents of children who have some ambulatory ability, but not sufficient functional ambulatory ability to function efficiently with community

ambulation, resist obtaining a wheelchair because of their concern that their child will then want to give up walking. There is no basis for this fear any more than a normal 16-year-old will stop walking or riding a bicycle after getting a driver's license. Initially, there is great novelty in the wheelchair; however, wheelchairs have many limitations, especially in homes, and children who have any ambulatory ability soon discover this and will abandon the wheelchair for their walker, crutches, or whatever other device works for them. These same children will also discover that going long distances, such as shopping in a shopping mall, is much more comfortable in the wheelchair than with very slow, labored walking using a walker. Also, parents soon discover the advantage of speed and flexibility the wheelchair offers. Parents should be encouraged not to feel guilty about using the wheelchair for convenience of mobility instead of pushing their children in every circumstance to walk. There is a time when children need to be encouraged to do exercise ambulation and to push walking ability; however, comfort and convenience in day-to-day activities have to be given importance as well. After all, it is important for therapists and physicians to keep in mind that having children with disabilities is not the full-time focus of families. These children will need to fit into the families' other demands and activities, even when this means doing less walking than some therapists or physicians might feel is ideal. There is no evidence that the function of individuals as adults is significantly determined by how much they are pushed to walk as children. Clearly, however, work on maximizing children's walking ability should not be ignored, but rather has to be balanced with the other demands of these children and their families.

Seating Clinics and Their Role

For children with limited ambulatory ability, the need for a wheelchair often becomes obvious. However, for some families who primarily keep these children at home, this need for a wheelchair will occur much later than for active families who take them into the community for many activities. The educational system now requires education to start at age 3 years, and often the school system may say that children have to get a seating system to come to school. It is also important to inform families that the seating system in the wheelchair has other benefits besides mobility. Proper seating has demonstrated improved respiratory function,¹⁴ improved speech ability,¹⁵ improved oral motor function during eating and feeding,¹⁶ and improved upper extremity function,^{17, 18} as well as improved comfort in sitting for these children. As parents come to understand the importance of good seating for the child's global function and interaction, they invariably will want to pursue the most appropriate seating system. Obtaining a wheelchair for children with CP should be handled in the same way that prescriptions for foot orthotics or medications are handled. No physician would send a patient to a pharmacy with an order to get medicine for their CP; however, there are doctors who will send parents to a store "to buy a wheelchair" for children with CP. This is totally inappropriate. In the 1970s, the importance of seating was recognized for these children who are nonambulatory and seating clinics were widely established.¹⁹ These seating clinics usually have input from a physician, physical or occupational therapist, rehabilitation engineer, and a wheelchair vendor. The seating clinic serves the function of assessing how the seating system will be used, the home situation of the family in which the wheelchair will be used, especially to make sure that the seating system and wheelchair will function in the home. Important in considering the seating system is the child's neurologic level of function and associated

musculoskeletal deformities. The assessment should consider the timing of future planned medical treatments such as spine fusions or hip surgery that dramatically impact the seating system. The clinic also needs to make sure families have adequate and appropriate transportation to be able to transport the seating system. Finally, the seating clinic will make specific recommendations for the type of wheelchair based on all these multiple concerns. These seating clinics have been set up in almost all major pediatric hospitals and in some large special education schools. Because of the multidisciplinary nature of the clinics, these evaluations are expensive, but compared with the cost of a wheelchair, the evaluations are an excellent investment. The final result of an evaluation in a seating clinic is a specific prescription for a wheelchair and seating system, which the vendor is then responsible to obtain and build for the individual child. Under the cost-cutting efforts of American health care, especially by health maintenance organizations, there has been an increased resistance to pay for seating evaluations. Because of poor initial evaluations and prescriptions, children will not only receive a less-appropriate seating system, but due to the need for many adjustments, often the cost of the final product is significantly increased over what an initial appropriate system would have cost.

In the 1970s and 1980s, many children with CP who needed seating and mobility systems were in special schools, where school-based therapists experienced in seating were often available to assist in the seating and mobility design planning for these children. There has been a great push to move these children to regular neighborhood schools, and thus experienced therapists are seldom available. If the children see a therapist, it is seldom one who has any special knowledge or experience in seating. This trend further raises the importance of the assessments in hospital-based seating clinics where the experience is available even if there is some increased initial upfront cost for the evaluation. In general, the short-term goals of the healthcare payers, however, do not consider the total cost over the life of the wheelchair and the wheelchair's effectiveness.

Another trend that is occurring is direct advertising to families by wheelchair manufacturers. This advertising leads especially to adolescents demanding a specific brand or type of wheelchair. If the chair is not appropriate for an individual, the seating team and physician must be clear about this and refuse inappropriate requests. Allowing an inappropriate wheelchair is no more ethical than giving a medication prescription to a patient just because she wants it even though the physician believes it is inappropriate for her.

Prescribing a Wheelchair

To evaluate and prescribe a wheelchair and seating system, multiple factors have to be considered. Children's age is often an important deterrent, especially because most children's wheelchairs are expected to last 3 years. After the end of growth and during adulthood, wheelchairs are expected to last 5 years. These expectations come from United States federal guidelines, which the states do not have authority to change. The needs of children and families have to be considered over this 3-year period, and the system should have sufficient growth potential to accommodate this time frame. When a specific system is being designed, the base with the wheels needs to be considered first and then the seating system considered separately. However, there are some seating systems that will fit only on certain wheelbases, so there is sometimes a need to negotiate this balance. The discussion should start first with the children's level of function.²⁰ Children should be categorized into those with some ambulatory ability, those who do standing transfers, and

those who require full dependent transfers. It is important to remember that the wheelchair needs of adolescents with spinal cord dysfunction-induced paraplegia are totally different from those of adolescents with CP. This difference is completely missed by many children, families, and even some vendors and therapists. Many of the wheelchairs that are heavily marketed directly to families are meant for the paraplegic spinal cord-injured population. These individuals have normal upper extremities, trunk balance, and trunk control. These patients do sliding transfers with no standing. Children and adolescents with CP almost never fit these parameters, because if they had normal or near-normal upper extremity control and normal trunk control, they would not use wheelchairs but walk with crutches or walkers.

Children with Some Ambulatory Ability

Childhood Needs

Children who are being considered for wheelchairs but ambulate in childhood usually ambulate with a walker; however, their ambulation is slow with high energy demands such that long-distance functional ambulation is limited. Most of these children have functional bilateral upper extremities and functional, although not completely normal, trunk and head control. Most are transported by parents in normal strollers until they are 5 to 7 years old. Typically, the first wheelchair is purchased when children are between 5 and 7 years of age and, because of functional upper extremities, this should be a wheelchair that children can push if their cognitive and behavioral function is such that they are responsible. If children are not responsible, then the chair design should be such that it can be locked or not pushed by them when they are sitting in the chair. This wheelchair should have swing-away or flip-up footrests so children can stand up out of the wheelchair. Adjustable armrests are required to allow children to help push themselves into a standing position (Figure 6.25).

Figure 6.25. A common first device many parents obtain is the stroller base wheelchair, which works well for rapid transport outside, such as shopping trips in early childhood (A). At middle childhood, if the child is safe and physically able to push a wheelchair, a standard large wheelchair should be obtained (B). If the child is unreliable but physically able to push herself, the wheelchair should be of the small wheel design to prevent the child from harming herself in the chair (C).

A



B



C



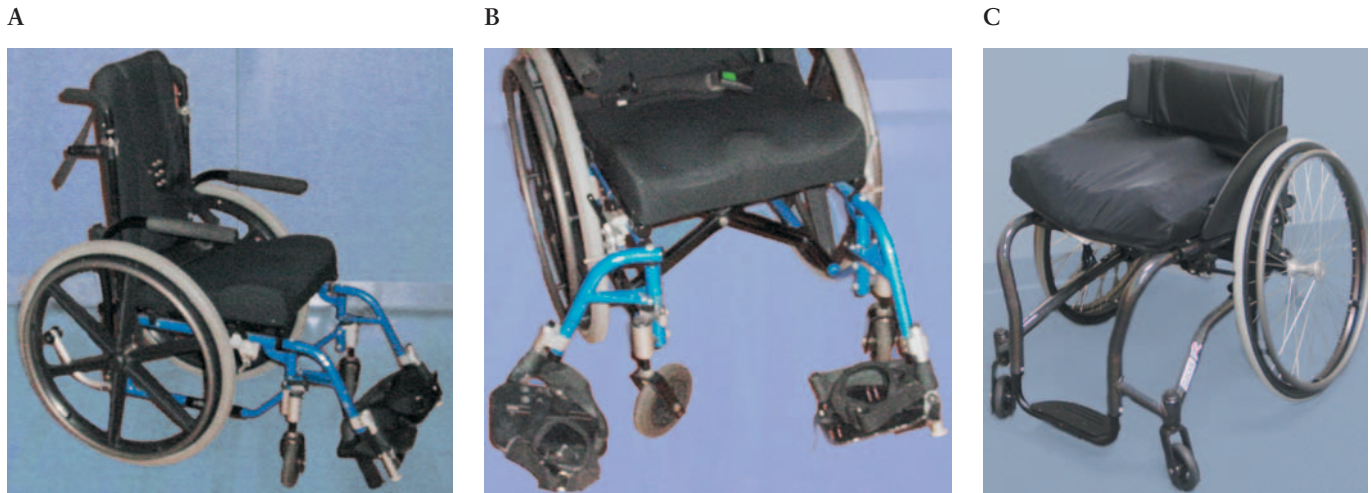


Figure 6.26. Adolescents who have some ability to ambulate, usually with the use of crutches, need a simple large wheelchair they can push (A). This chair should have swing-away footrests to make it easy for them to get out of the chair (B). Although these teenagers often are interested in a paraplegic-type design with a low back and fixed frame (C), this type of wheelchair is totally inappropriate for teenagers with CP who need a wheelchair. The teenagers with CP who need a wheelchair will always have some problems with trunk control and upper extremity control or they would be walking with crutches and would not need a wheelchair.

Typically, the seating system only needs a solid seat and solid back with a seat belt. Some children with marginal trunk control will need lateral chest support, and some may need a shoulder harness to assist with anterior trunk support. A headrest is needed only if the children are going to sit in the wheelchair during transportation in a van or on a school bus.

Adolescent Needs

A small group of children will be able to ambulate in the community until they start their adolescent growth, then their increased body weight will make walking so inefficient that it is no longer functional for long-distance community ambulation needs. Many of these adolescents will need a simple wheelchair, with a very simple solid seat and solid back, swing-away or flip-up footrests, and seat belt, in which they can propel themselves. This is also the group that will likely want the inappropriate paraplegic wheelchair (Figure 6.26). The wheelchairs should be lightweight and fold for flexibility so they can be used with different vehicles. Another group of adolescents, who are functional household ambulators but cannot functionally ambulate in the community, will also require wheelchairs. Many of these individuals have significant limitations in the function of the upper extremities. It is reasonable to consider power mobility for this group if their families have transportation available for a power wheelchair. If transportation is not available, a manual wheelchair is required. Wheelchairs for individuals who are functional household or minimal community ambulators should have crutch holders added if they use crutches. These holders allow children to carry the crutches on the wheelchair for circumstances when they need to get out of the wheelchair, such as for use of wheelchair-inaccessible bathrooms.

Children Who Are Exercise Ambulators and Transfer Standers

Childhood Needs

Children whose function is limited to exercise ambulation or standing transfers usually have their first mobility and seating system ordered at age 2 to 3 years when they enter the school system. Depending on these children's upper extremity function, a stroller base or a large wheelchair base may be ordered (see Figure 6.25). The stroller base may seat the children higher and make functional activities, such as feeding the children, easier for parents

and caretakers. If children have the upper extremity functional ability, cognitive ability, and behavioral stability, the self-propelled wheelchair should be ordered. The footrests can be solid or swing-away, based on the perceived ability of these children to come to standing from the wheelchair. Power mobility should be considered when children enter middle childhood, usually at age 7 to 9 years, as the second or third wheelchair is required. The decision of power mobility is based on children's upper extremity function and general cognitive function.

The seating system for these children needs to include good chest lateral support and usually anterior trunk support. The need for a supported headrest in this group is variable, and has to be assessed on an individual basis. A lap tray should always be ordered for use when children are sitting in the chair and engaged in upper extremity activities. The lap tray is also an important assist for postural control to prevent forward slouching. Especially for young children, the work surface to do upper extremity activities is almost never at the right height unless a lap tray is routinely used. This lap tray allows children to have the ideal level and most functional work area for fine motor skills activity development (Figure 6.27). Usually, these trays are attached to adjustable armrests so they can be raised or lowered to the correct height for the individual child.

Adolescent Needs

There is a group of adolescents with fair upper extremity function who can propel themselves in the community. However, it is much more common for adolescents who require a wheelchair for all community ambulation to have so little upper extremity function that self-propelling a wheelchair is not possible. If these individuals are otherwise appropriate, a power mobility system is preferred. At this age, it is very important to have flip-up or swing-away footrests as the caretakers now depend much more on standing transfers. Usually, the seating system must continue to have a similar construction, as described earlier. Again, some of these adolescents can use crutches for short household ambulation, and in these cases, the wheelchair should be fitted with crutch holders.

Children Who Are Dependent in All Transfers

Childhood Needs

Children who are fully dependent for all their transfer needs usually require significant supportive seating by age 12 months, and the first special seating and mobility system is typically obtained between the ages of 12 and 24 months. Usually, this first chair is a tilt-in-space stroller base with solid footrests. The seating system requires full chest laterals, anterior trunk support, and a headrest to assist with head control. A lap tray should be included because the system is often used as a feeding and seating system, and is a play area for these children's play stimulations and fine motor skills development. By the second or third wheelchair, usually obtained around 5 or 6 years of age, a standard wheelchair base is ordered. A completely supported seating system is still required. Often, a tilt-in-space base is helpful to allow children to tilt back and rest. These children are seldom candidates for power mobility consideration until late childhood or early adolescence. Exceptions to this are children with athetosis who often have excellent cognitive function and demonstrate sufficient hand function. Occasionally, children with these indications may be considered for power mobility as young as 4 or 5 years of age.

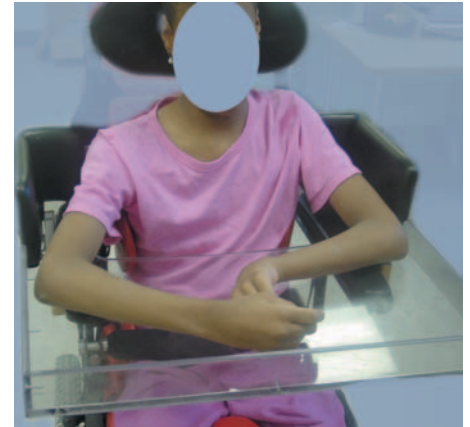

Figure 6.27. The lap tray is very important and should not be forgotten as part of the wheelchair. It is an important aspect of positioning to prevent the child from leaning forward. It is a work and feeding area for the child, and if the tray is made of clear material, it is easy to monitor the child's seating posture.

Adolescent Needs

Most of these children who are fully dependent in transfers will continue to require a fully supported seating system with headrests and lap trays through adolescence. Usually, at age 10 to 12 years, a final evaluation can be made to assess the possibility of these adolescents using power mobility. This age is also when skeletal deformities are most common and problematic to deal with from a seating perspective. As children are getting heavier and having some increasing deformities, the possibility of skin breakdown also becomes most predominant. Skin breakdown is especially problematic over the prominent sacrum and ischial tuberosities for individuals who are very thin. Contoured or specially padded seating may be needed.

Specific Components of Seating and Mobility

Obtaining a seating and mobility system for children requires making decisions about many specific components of the system. Each of these systems, such as the wheelbase of the chair, comes with general design options. For example, the wheelbase may have small or large wheels, and each design tends to be available with some variations from different manufacturers. Purchasing a wheelchair is in many ways similar to purchasing a vehicle to drive on the highway where one has to choose between an automobile, a pickup truck, a station wagon, or a van. With each of these categories, each manufacturer has different small variations but one often chooses the manufacturer based on availability of service, prior experience, and options such as color and price. Most people intuitively know that they would not go to a car dealership and ask for a vehicle without first making some basic decisions about their needs for the specific vehicle. In the same way, it is inappropriate for parents to go to a wheelchair salesman and ask to buy a wheelchair for their child. The remainder of the discussion on the components of seating and mobility is directed at general design features; however, there will be no discussion on the options offered by specific manufacturers because styles and models change as rapidly as automobile styles and models. The general difference between cars and pickup trucks, however, remains constant from year to year, as do the different categories of wheelchairs.

Wheelchair Base

The wheelchair base is available in a number of options, such as a stroller base, large wheels for self-propelling, single-arm self-propelling, small wheels, and power mobility. Each of these options has specific advantages and disadvantages.

Stroller Base

This base tends to have the least medical appearance and can sometimes visually pass for a standard baby buggy or toddler stroller, which appeals to some families. The primary use of the stroller base is in young children, less than 3 years of age, as their first wheelchair. Often, this base is lightweight and easy to collapse and thus place into car trunks, which is another advantage. Large strollers can also be purchased that can handle even adult-sized individuals. Some families find these strollers very helpful as backups to the standard wheelchair, which is often very heavy and hard to transport if the primary transport vehicle is not available. These large strollers often have sling seats and small wheels, which means that they can be used only for short-distance transportation on flat pavement. These strollers work well for parents who want to use them for trips to the store or to the doctor's office,

but cannot be the primary wheelchair because of poor seating support and because their use is limited to single-level flat surfaces. Most insurance companies and Medicaid payers will purchase only one wheelchair for a child, so if the company pays for a stroller, the company then will refuse to pay for the more appropriate wheelchair and seating system, which is also much more expensive. For this reason, it is better for the parents to purchase the stroller themselves if they are able and save the insurance benefit for the much more expensive system, which is what these children will be using most of the time. Because there are no strollers that can effectively be self-propelled, the stroller is seldom considered as the primary mobility system except in very young children, less than 3 years of age.


Standard Wheelchair Frame with Small Wheels

The standard wheelchair frame allows excellent flexibility in designing a seating system that meets children's needs. By using small wheels, usually 10 to 12 inches in diameter, the system still somewhat has an appearance of a stroller (see Figure 6.23C). For children with excellent arm function but cognitive and behavioral limitations that preclude self-propelling, this system prevents them from moving themselves. The major disadvantage of the small wheel is the increased resistance to rolling provided on uneven surfaces or soft ground. This resistance becomes a major concern when individuals with CP are very heavy, or when the family tries to use the chair on a surface other than completely flat pavement or a hard floor. The regular frame with small wheels is primarily indicated for early and middle childhood and for children who cannot or should not self-propel their wheelchair.

Standard Wheelchair Base with Large Wheels

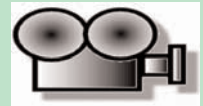A standard wheelchair frame with large wheels on the back and small wheels (casters) on the front is the most typical wheelchair used in middle childhood and adolescence. This wheelchair is the ideal setup for individuals who can propel the chair with both upper extremities. Also, it is the best setup for large patients or situations where families are often on uneven or soft surfaces. The larger the wheels, the easier the wheelchair is to roll over uneven and soft terrain. Also, it is easier to take the chair up and down stairs if the rear wheels are large. The major disadvantage of this chair setup from the parents' perspective is the chair's typical appearance of a wheelchair. For most children with CP, the front casters should also be large, meaning 4 to 5 inches in diameter (Figure 6.28). There is no role for the small 1- or 2-inch-diameter casters sold with paraplegic wheelchairs. The small casters are designed to rest the chair and to be in minimal contact with ground during

Figure 6.28. The front caster of the wheelchair is important to how easily the chair can be pushed in different environments. In general, the larger front casters (A) or the medium caster size (B) are the most functional for individuals with CP. The very small casters typical on wheelchairs for paraplegia have no role for children with CP (C). These small casters are designed mainly to rest on with the presumption that most propelling will be done with the front casters not even in contact with the floor.





Case 6.1 Shannon



Shannon, a 15-year-old girl with spastic diplegia, was brought for the first time to the CP clinic with her mother's complaint that she is doing almost no walking except in her own home and using her wheelchair for all community mobility. Shannon had never been taught to use crutches, but as she entered puberty and had more difficulty walking, someone gave her a paraplegic type of sports wheelchair, which she liked. Now at age 15 years, she complained of increased difficulty walking and knee pain. Her primary outside activity was playing wheelchair basketball. The significant physical examination findings included knees that demonstrated increased flexion at foot contact, late knee flexion, ankle equinus, and severe internal rotation of the hip (Figure C6.1.1). Although Shannon was not in favor of surgery, her mother wanted her to have the procedures, which included femoral derotation, hamstring lengthening, rectus transfers, and gastrocnemius lengthening. During the post-operative period, she was not very motivated to work with the physical therapy program and kept complaining of pain in the hip and knees. She continued to insist she could not walk and was totally dependent on her wheelchair, in spite of an energy cost of walking and a walking speed that was mildly elevated but not in the severe range (Table C6.1.1). Shannon had an excellent technical outcome of the surgery but a complete functional outcome failure. This failure was probably because she was allowed to become wheelchair dependent in early adolescence by poor medical advice in which she was given a wheelchair instead of being taught how to use Lofstrand crutches. Her social activity revolved around wheelchair basketball, so if she started to walk, she would have to give this up. Her mother wanted her to walk, so the wheelchair use was another way to assert independence from her mother and her mother's goals. By not walking, she has become extremely deconditioned to the point where walking was uncomfortable unless she was willing to endure rigorous rehabilitation.

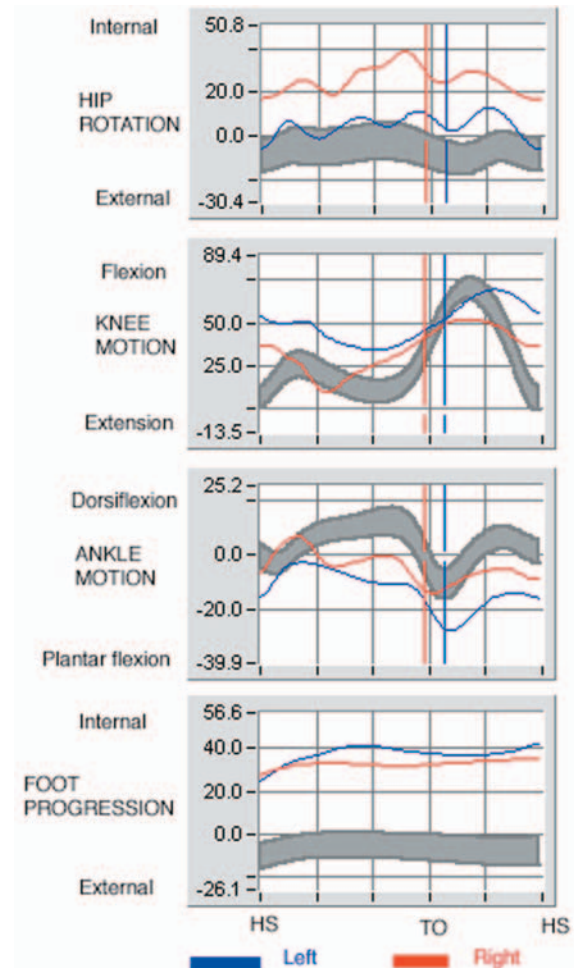


Figure C6.1.1

Table C6.1.1. Oxygen cost.

Parameter	Preoperative	Postoperative
Walking velocity (110–140 cm/s)	107	63
Oxygen cost (0.23 ml O ₂ /m/kg)	0.43	0.48
Heart rate (beats/min)	168	172
Respiratory rate (breaths/min)	47	57

mobility (see Figure 6.28). Few individuals with CP can handle a wheelchair with this dexterity or they would typically be walking and not using a wheelchair (Case 6.1). The standard wheelchair frame with large back wheels and large front casters is the ideal choice for most individuals from middle childhood to adulthood.

Standard Wheelchair with One-Arm Self-Propelling Feature

There are a few individuals with significant asymmetry in arm function such that they can propel a wheelchair with the use of only one arm. Depending on the level of cognition and motor function, individuals may be considered for either a manual self-propelling system or a power system. The standard manual self-propelling system has a double rim on the side of the functional limb, and by holding the rims together, the chair is propelled forward. Turns are made by differential turning of the rims. This system is very effective but requires a very functional and strong upper extremity with relatively good cognitive function. This chair design can be easily pushed from the back by attendants or caregivers and adds very little additional weight to the wheelchair. There are several other single-arm drive options available, using hand cranks or pumps for the single-arm drive mechanism. In many ways, these devices are easier for individuals to use and often provide better mechanical leverage; however, all these systems are very prone to breakdown, require the addition of a significant amount of extra weight to the wheelchair, and make it almost impossible for caregivers to push the wheelchair from the back. Parents almost universally come to hate these wheelchairs because of these problems. None of the currently available systems should be ordered for children with CP. The double-rim system is mechanically simple, does not get in the way of others pushing the chair, is relatively reliable, and therefore is the only reasonable choice for one-arm self-propelling.

Power Mobility

Power mobility is one of the most stimulating and freeing choices for the right children. This mobility allows children with CP, who often have not had the ability to move about under their own power, to suddenly be able to explore their environment. Developing personal freedom to move in space is a very freeing experience for these children. This mobility allows children to act like children. Although power mobility is a wonderful functional enhancement for appropriate children with CP, it is an option only for the minority of children with CP who are wheelchair dependent. The use of a power wheelchair comes with significant risks, problems, and dangers. Many children can manually learn to drive a car by the time they are 12 years old; however, our society does not allow driving on the road until children are 16 or 18 years of age because of the need for maturity in judgment and stability in behavior. Likewise, there are definite criteria that have to be present before children can be given a power wheelchair (Figure 6.29).

There are three major requirements that children have to meet before a power wheelchair should be prescribed. The first requirement is children need to have the motor ability to safely operate some switching mechanism to drive the wheelchair, have adequate eyesight, and be cognitively and behaviorally reliable to understand the dangers, such as road traffic and stairs. They must follow commands reliably, such as stopping if they are told to stop. Because power mobility is very expensive, it is never considered for short-term use during several months of postoperative rehabilitation, or for children who are expected to progress to functional ambulation over the next year or two. Children have to demonstrate that they can physically operate the power chair, which means a mechanism for switch interfacing must be found that works. There are many options for switch access, the most common being joystick use with the hand (see Figure 6.28B). Head switches, or a combination of leg and head switches, are also available and useful for children with CP. Mouth joysticks and oral sip-and-puff controls have very little use in children with CP because of uniformly poor oral motor control




Figure 6.29. A power wheelchair provides a significant amount of independence for children with CP (A). The use of the chair, however, requires specific criteria of cognitive ability, behavioral stability, and motor function. Specifically, the child has to be able to control the chair through some controller mechanism, with a joystick being the most common arrangement (B).

in the CP population with this level of motor involvement. These systems are mainly for use in high-level spinal cord injuries. It is not mandatory that the exact control system be set up before a power mobility system is ordered; however, it is not appropriate to order a power wheelchair with the goal of seeing if a way can be found for children to access its controls. These systems are simply too expensive, and there is good expertise available to make these determinations in a general way before a power wheelchair is actually ordered for an individual child.

The second obligatory factor related to physical ability requires that children be able to see where they are going. Ordering a power wheelchair for a blind child makes as much sense as giving a driver's license to a blind person. For children with marginal eyesight, a training period should be performed so they can demonstrate that their sight is adequate to safely see where they are going.

The third and very important factor in deciding if children are candidates for power mobility is their cognitive understanding and behavioral stability. Children need to understand the concept of backing up when in a corner, to learn to avoid stairs and other drop-offs, and to understand the danger of specific areas, such as roadways. They must reliably follow directions such as stopping when told to stop. Children must have enough behavioral stability to not use the wheelchair as a weapon to injure caretakers or other children. Only when all these requirements are met is it reasonable to order a power mobility system for a child. For children with CP, this usually starts between 7 and 9 years of age. There are occasional children with athetosis who are ready as early as age 4 years. There has been discussion about fitting children as young as 2 or 3 years of age with power wheelchairs; however, this is almost never appropriate for children with CP. The considerations of early power mobility are most appropriate for children with severe arthrogryposis, osteogenesis imperfecta, or congenital limb deficiency. Almost all

A



B



children with CP who could operate a power wheelchair this young will not need the wheelchair in a year or two as they will be walking. For young children who are marginal candidates for power mobility, other options include the purchase of battery-powered toy cars in which they can be seated with simple adaptations to see if they can drive the toys. Usually, using these toys has to be done under direct supervision of an adult for safety reasons. These toys are a cheap and simple way for children to gain early experience in operating a power mobility device (Figure 6.30). Many special schools have adapted toys in which children can also practice in a very limited, safe environment. On many occasions, ill-advised parents have obtained power wheelchairs for children as young as 3 years of age, but then found the chairs too heavy to push as transportation for the children because these power chairs cannot be pushed effectively as a manual chair. In the end, the power wheelchairs sit in the basement and parents have no seating or mobility system for their child. There is no excuse for this wasteful spending based on poor advice to parents if appropriate evaluations are performed and specific criteria are applied (Table 6.2).

Figure 6.30. Toy cars that are battery powered may be used for children who are young and marginal candidates for power mobility (A). These self-propelled toys tend to be safe and often need to be used with the supervision of an adult, which adds an extra layer of safety. Similar power bases are used in some schools to teach early mobility (B).

Table 6.2. Criteria to meet before ordering a child a power wheelchair.

1. Child cognitively understands concept of forward, backward, and turning side motions.
2. Child has demonstrated the ability to use a control switching interface, which will be used to operate the chair.
3. Visual acuity is sufficient to see surroundings where the chair will be operated.
4. Neurologic maturation is not expected to continue and allow functional independent ambulation.
5. Parents' home is accessible to power wheelchair.
6. Parents have a mechanism to transport power wheelchair.
7. If the parents are not able to transport the chair or have the chair in the home, a well-adjusted and fully adapted manual wheelchair is the first priority. Only when this is in place can a power chair be considered for school-only use, even if the child is otherwise an ideal power chair candidate.

There are some other hurdles that need to be overcome for children to effectively use a power chair. First, the family house has to be accessible, meaning no stairs are in the way of entering the house. Also, the doors need to be wide enough to accommodate the power wheelchair. If families are going to use the wheelchair when they are doing community mobility, there has to be a way to transport the chair, usually either a ramp or a wheelchair lift into a van. The school system likewise has to be accessible to children in power chairs, and wheelchair lift buses need to be available for transportation.

Choosing the Type of Power Base

After the full evaluation and the decision to move ahead with power mobility has been made, a choice has to be made about the specific type. In general, there are four options, including an add-on motor to a standard wheelchair frame, a permanent power mobility base for power mobility driving only, a deluxe power base with many other power option features, and a power scooter. The power add-on packs have the advantage of being a lightweight system that can be converted to a manual wheelchair when desired. In general, this is a system that works well if it is lightly used by individuals without heavy body weight. This add-on motor primarily brings the disadvantages of both systems together without the durability that many of the permanent power bases currently have developed. This system usually does not have enough power for heavy-duty use outside on uneven ground. This add-on power pack system is best suited for middle childhood when families are not quite prepared for power mobility. The permanent power mobility base is the best choice for most children with CP. In general, these systems are durable with good power for outdoor use. Again, a large wheel size improves the outdoor use and is an option that varies with different manufacturers. Some of these systems also have a center drive wheel, which provides for a tighter turning radius (see Figure 6.29). The deluxe power bases often offer a combination of seat elevation, power standing option, power leg rests, power recline, power tilt, and power floor sitting in addition to other features (Figure 6.31). There are only rare children for whom these options can be justified, and each child must be individually considered. Except for one manufacturer, these deluxe power bases have a poor history of durability with frequent breakdowns. These systems are expensive, typically costing over \$20,000 compared with approximately \$8,000 for a standard power

Figure 6.31. The deluxe power wheel base (A) allows power floor sitting (B), standing, seat raising, reclining, tilt-in-space, and foot elevation. These systems are expensive and often require a high level of maintenance.

A



B



wheelchair and seating system. The fourth power option is the scooter commonly used in nursing homes by the elderly. The only role for the power scooter is in young adults or adolescents who go to large high schools or colleges and whose ambulation speed is so slow that they are not able to get to the locations needed in the allotted time. Typically these scooters do not have the option of adding adaptive seating and are generally limited to sidewalks or hard surface mobility.

Wheelchair Frames

Wheelchair frames are usually available in lightweight tubular steel, or even lighter designs in carbon fiber composite, titanium, or aluminum. There is an extra cost for these lightweight materials compared with the standard metal frame, but these lighter frames are easier to lift into car trunks and move up and down stairs. These frames are also available as fixed frames, tilt-in-space, or reclining. Most children with reasonable hip control should get a fixed frame that is strong and lightweight. The tilt-in-space frame is used for individuals with severe quadriplegic pattern involvement who need periods of time when they can be tilted back to rest. This feature adds a significant amount of weight to the chair and makes it almost impossible to collapse it and place into the trunk of a car (Figure 6.32). The reclining back is used only for specific rare deformities in children with CP, most commonly for significant fixed hip extension contractures.

Footrests

Some wheelchair frames, depending on the specific design, do not have the flexibility to add different types of footrests. Therefore, obtaining the correct footrest has to be coordinated with choosing the specific wheelchair frame. The options in footrests include swing-away, flip-up, elevating, spring-extendable, and different shoe attachments. The swing-away feature is often the easiest for children who are able to get out of the chair unaided because the release for the swing-away is the easiest to reach (Figure 6.33). The flip-up feature is the most durable and simple but requires reaching almost to the floor, a task few individuals with CP can do when sitting in a wheelchair. Either swing-away or flip-up or both are the required features of wheelchairs for individuals who come to a standing position from a sitting position in the wheelchair. This task of coming to a standing position requires that the

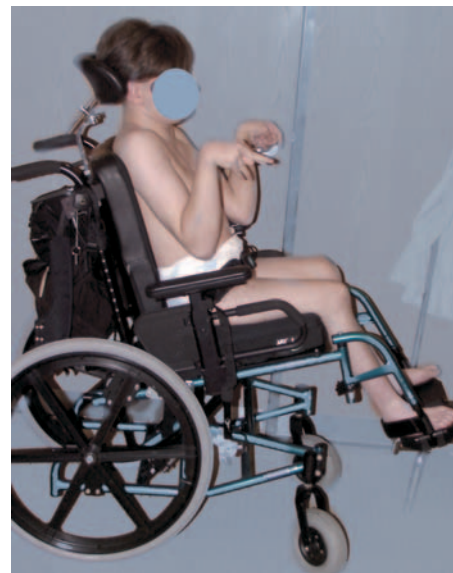

Figure 6.32. The tilt-in-space frame allows the child to lie back with loosening of the seating positioning. The tilt-in-space frame tilts both the seat and back at the same time compared with a reclining wheelchair, in which the back folds down but the seat stays in place.

Figure 6.33. It is very important to consider the needs of the child relative to their sitting knee angle. If the child has severe knee flexion contractures or hamstring contractures, the goal should be to obtain 90° foot hangers (A). However, if the child is large and the knees are relatively free, a better seating position may be obtained with 70° hangers, which are more common on larger wheelchairs because of the common interference with the front casters (B). The position of the foot plate on the hangers and the shoe tie-downs also have to be considered (C).

A



B



C






Figure 6.34. Armrests are almost always needed for children with CP because they almost universally need to use the arms to help with trunk balance. If the wheelchair is often pushed up to tables to work, study, or eat, the armrests should be flip-up in nature so they can be brought out of the way of getting under a table surface.



Figure 6.35. The typical drugstore wheelchair with a sling seat and sling back is always inappropriate for individuals with CP. If they need a wheelchair for long-term use, they will need more trunk support and better seating stability than this chair provides.

feet be placed in the midline under the seat for maximum ease. Elevating footrests allow the feet to be elevated, a feature that is needed only after injuries or surgery on the lower extremities for most children with CP. This feature adds weight and complexity and has a tendency to break down. Elevating footrests are rarely indicated as standard equipment on wheelchairs for children with CP. Vendors and wheelchair clinics should keep several pairs of elevating legrests available for rent during the brief postoperative period when these footrests are required. The spring-loaded, extendable feature allows footrests to lengthen when individuals push hard against the footrests. This feature has a place only rarely in adolescents who, secondary to behavior or spasticity, repeatedly push forcefully against the footrests, causing the solid tubes of the foot rests to fail frequently. If these individuals cannot voluntarily keep the feet on the footrests, which is common in many individuals with spasticity and athetosis, shoe holders and shoe tie-downs are required for the footrests (see Figure 6.33). This is an important safety feature that parents and caretakers have to be informed about, because one of the most common wheelchair-associated injuries is from feet getting struck as children are being pushed through doorways or other close quarters. We have seen multiple cases of fractured tibias, feet, and toes from feet being struck, especially on walls and door jambs, while individuals are driving power wheelchairs because they often cannot see their feet (Case 6.2).

Another aspect of footrests that has to be considered is the angle of the footrest hanger. Most hangers come in 70° and 90° options, although some frame designs can accommodate only one or the other (see Figure 6.33). Children with kyphotic posture and tight hamstrings have to be fitted with 90° hangers to inactivate the hamstring effect. Also, many individuals who have a tendency to do extensor posturing do better with full knee flexion to inactivate the extensor response, and they should also be placed in 90° footrest hangers. The advantage of the 70° hanger is that this position may be more comfortable for long-term sitting if there are no significant contractures. The 70° angle also allows a frame design with larger front casters, such that the casters do not hit the footrests. This design feature is often important for tall young adults, where it may be difficult to get enough length on the footrest hanger in the 90° position.

Armrests

The role of armrests on wheelchairs allows individuals to have a place to support the trunk with the upper extremities and provides a place from which to push up with the upper extremities when coming to stand. The armrests also provide a place to attach trays and power control switches. For individuals who are efficient in self-propelling with the upper extremity, armrests may be an obstacle and therefore are not needed. Because individuals with CP who use a wheelchair have problems with trunk balance and control, armrests are always needed (Figure 6.34). The armrests are an important aspect in getting proper positioning of the trunk balance and control; therefore, armrests should be adjustable, allowing them to be raised or lowered as needed.

Seating

The most important aspect for comfortable and maximum functional benefit of a mobility system for individuals with CP is proper seating. Almost all wheelchairs are sold with fabric-based sling seats and backs, which are inappropriate for all individuals with CP (Figure 6.35). Because of difficulty with trunk control, a solid seat and back are needed. In the 1970s, when the importance of seating was first recognized, two general approaches were



Case 6.2 Luke

Luke, a 16-year-old boy with a quadriplegia, was an excellent power wheelchair user. He did not like to keep his feet restrained in the shoe tie-downs. One day, as he was driving at his high school talking to another student, he caught his foot on the corner of the wall as he was turning into another corridor. He had severe immediate pain and heard an audible crack. He was brought to the hospital where a spiral fracture of the tibia was found (Figure C6.2.1).

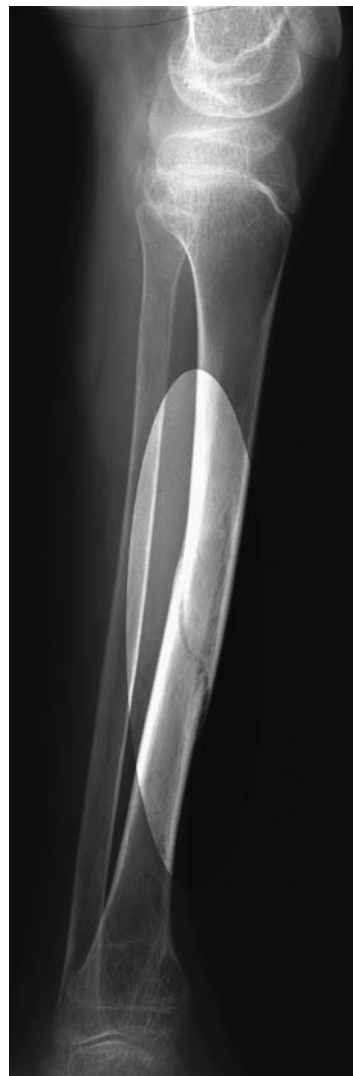

Figure C6.2.1

developed. One approach was to make form-fitting custom molds that would perfectly support individuals,²¹ and the other approach was to develop modular pieces that can be assembled to provide the support needed.²² The custom-molded form-fitting approach works well immediately after production with exactly the same clothing that children had on when molded. There are many problems with this concept. First, it is very expensive, and getting the correct mold is difficult if children are not exactly positioned correctly. It is difficult to make significant changes after the molds have been made, short of remolding the children. This system does not allow for different levels of clothing, such as clothing variation from winter to summer.



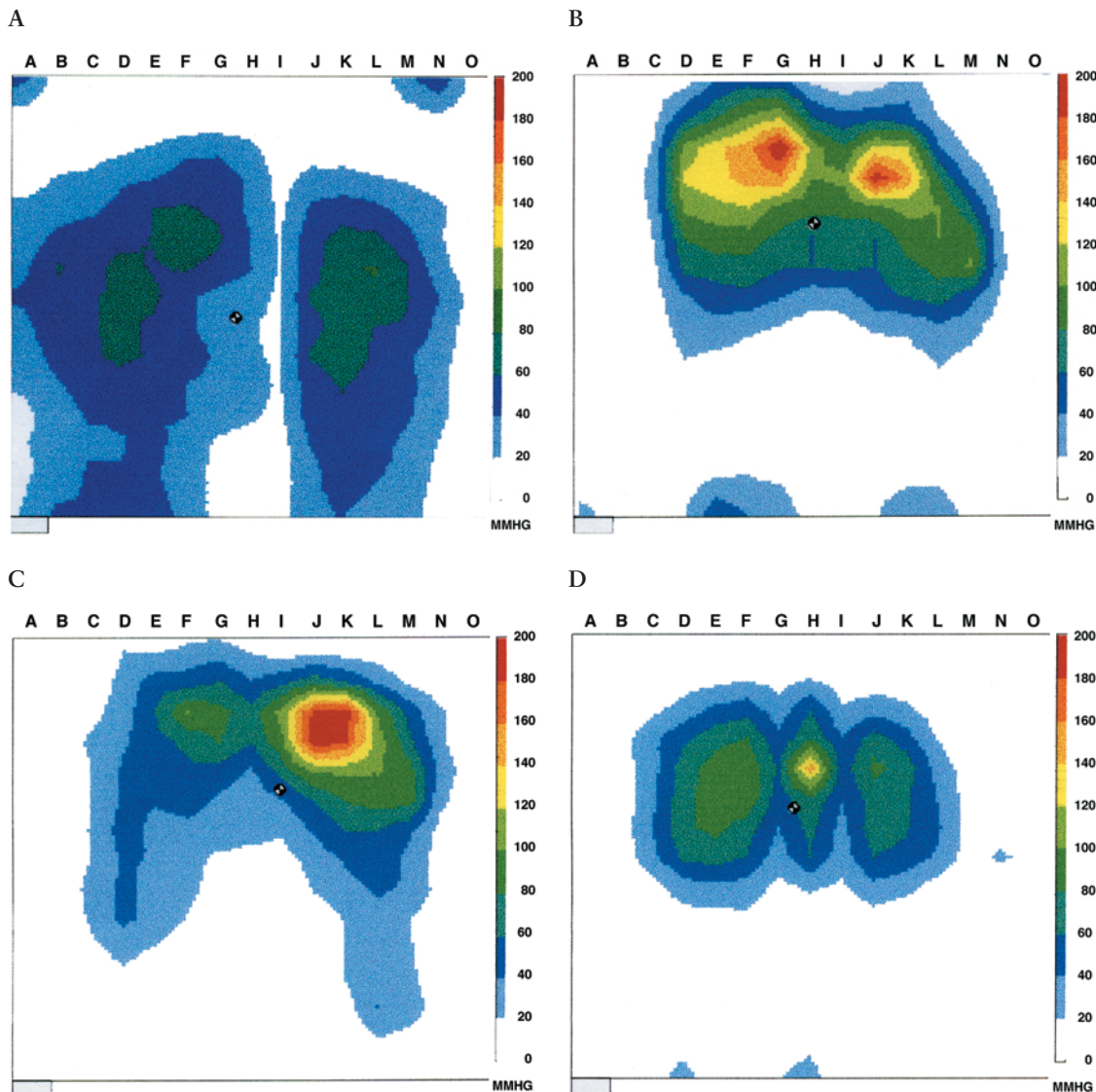
Figure 6.36. There are many different seats available as options for wheelchairs; however, most have some contouring, and many have anterior elevation to place more weight on the fleshy anterior thigh than the bony, more posterior iliac crests and sacral prominences.

In growing children, these molds only fit for 6 to 9 months and then have to be remade.²¹ The main advantage is that custom molding can accommodate any type of deformity. For children and adolescents with CP, these custom-molded seating systems have far too many problems and are much too expensive to have any significant useful benefit. The other seating design approach is to use premanufactured off-the-shelf components to build a custom modular seating system. The advantage of this system is its ease of modification for the desired seating position, adjustment for growth, and level of clothing wear. Today, because of the excellent availability of commercial modular components, this is the system most suited to almost all individuals with CP. The major drawback of the modular system is a limitation in accommodating some difficult positional problems. The custom molding concept can be added to make specific custom-molded components on the rare occasions when this is needed. This is an option available in many seating clinics or from major vendors.

The Seat

The seat should have a solid base with a thin layer of soft, durable, deformable material. The main deformable materials are gel pads or closed-cell t-foams. The closed-cell t-foam is excellent to build up areas of the seat, and because it is available in different levels of stiffness, it can also be used to provide areas of pressure relief. The gel pads are excellent because they flow away from high-pressure areas. The simple flat or mildly contoured closed cell t-foam seat is best for young and light children who weigh less than 30 kg. As children get heavier and the skin pressure per square centimeter of skin surface increases, the gel pads often provide better pressure distribution. An advantage of the solid closed-cell t-foam is that it always stays in place on the seat; however, it is only comfortable for children when they are sitting in the correct position on the seat. The gel, on the other hand, tends to move and flow so the seat has to have some way to restrain the gel pad, usually by attaching it to the seat using Velcro. Over time, this gel tends to flow out of the area where it is intended to provide pressure relief; therefore, the gel pad needs to be readjusted frequently. Also, using modular contouring pads in the seat helps to keep children centered on the seat. For some individuals who have a tendency to slide to one side, a solid hip guide restraint may need to be added. This hip guide can also be extended anteriorly for children who have excessive hip abduction. In summary, the seat needs to have a solid base to provide children a stable base on which to stabilize their limited trunk control (Figure 6.36). The surface should have enough soft padding to keep the children comfortable and prevent skin breakdown. Very deformable, air-filled seats or thick, soft cushions are to be avoided because they add to trunk and pelvic instability.

Occasionally, children will develop problems with skin breakdown over the sacrum, coccyx, or ischial tuberosities. These children need a detailed pressure mapping of their seat to define the positions in which the breakdown is occurring and to also define the specific areas that need relief (Figure 6.37). After the relief has been constructed, repeat mapping should be performed to demonstrate that the pressure relief has occurred. During this pressure relief mapping, it is important to check the pressure that occurs during other positions in which children spend significant amounts of time, specifically in positions such as side lying or supine lying. Often, these pressure sores are not coming from sitting, but are coming instead from lying, and pressure mapping of only the sitting position will miss the source of the problem.



Abduction Wedges

A strong adductor response is present in some individuals with spasticity, which sometimes causes crossing of the legs while sitting. This adductor response may make it hard to keep children centered on the seat. A small modular wedge may be added directly on top of the seat in cases where this tendency for adduction is mild. For more severe cases of adduction, a larger wedge that children cannot cross over needs to be added. This larger wedge should be removable or flip down, especially if these individuals do standing transfers (Figure 6.38). Also, the wedge often makes lift transfers difficult, and even in this situation, the design of the wedge should allow for it to flip down or be removed. These wedges need to have padded and rounded edges to prevent injury to the children. The abduction wedge should not be used to keep children back in the wheelchair. This concept has to be explained to the caregivers and parents, who often want to use these wedges instead of seat belts to hold children from sliding out of the chair. If the abduction wedge is used to resist hip extension posture or to keep children from

Figure 6.37. When there are problems with seating pressure, mapping of the contact surface is required. A normal pressure contact pattern has relatively symmetric distribution between the right and left side with no areas of high pressure, and good anterior distribution on the thigh (A). Some typical abnormal patterns include high pressure over the ischial tuberosities (red areas) in a child with no pressure on the thighs (B). Children with pelvic obliquity will develop high pressure unilaterally over the ischium (C). Children with lumbar kyphosis have posterior pelvic tilt and high pressure over the coccyx and sacrum, leading to possible skin breakdown (D).

A



B



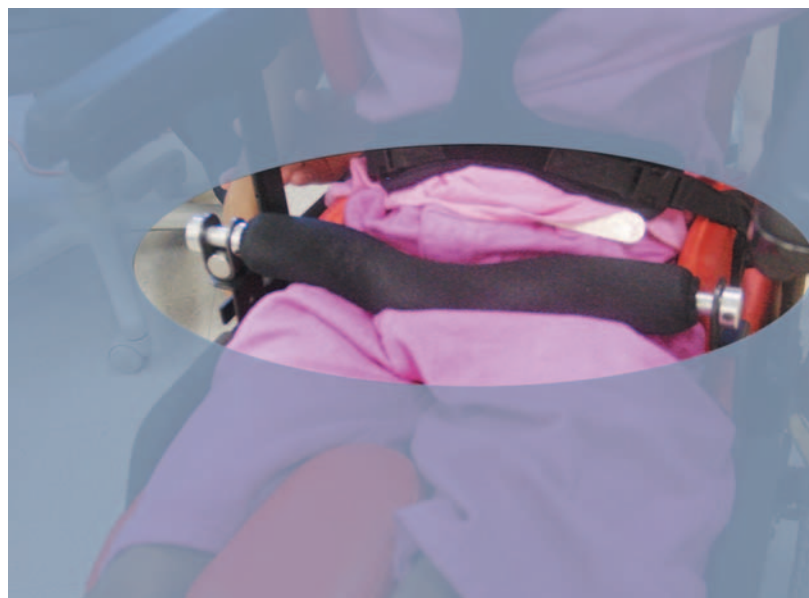Figure 6.38. Midline hip adductor wedges may need to be added for children who have a tendency to adduct the hips while sitting (A). If the wedge needs to be large to keep the knees from crossing over, it should be mounted on a flip-down hinge to allow the child to be transferred in and out of the chair with greater ease and safety (B). These wedges are not to serve as blocks against the child sliding forward in the seat. This is the role of a seat belt.

Figure 6.39. For some children, the extensor posturing tends to be so severe that more rigid restraint is required. The subanterior superior iliac spine (SUBASIS) bar works well if it is properly adjusted. This bar presses down onto the anterior thigh and not against the abdomen. With the child relaxed, the pressure on the anterior thigh should allow insertion of a finger between the bar and thigh; however, there should be no contact with the abdomen.

sliding forward out of the wheelchair, it will cause significant pressure and excoriation in the perineum.

Seat Belts and Restraints

All individuals with CP must have a seat belt added to the wheelchair and used at all times. The seat belt is a basic safety measure for individuals with poor trunk control, which means that it has to be applied to all individuals with CP in a wheelchair, because if they did not have poor trunk control, they would be walking. The seat belts may be a simple design, like a standard car seat belt. The belt should be fixed so that it crosses the hip joint center laterally, pulling posteriorly and inferiorly at approximately a 45° angle. Special consideration should be given to children with strong extensor posturing responses by fitting them with double-pull seat belts. This type of belt can be closed with a standard closure in the front, and then there are two pull belts on each side, which allow it to be snugly pulled down. These belts often need frequent readjustment, as they tend to work loose and lose their ability for tightening. Children who have behavioral problems and are unreliable but have enough motor function to release the seat belt should be fitted with a release buckle that they cannot open. On rare occasions in difficult cases, the belt may be fitted so it closes in the back of the wheelchair as a way of avoiding children releasing themselves. The opposite consideration should be applied for individuals who can transfer themselves, in that the belt-release mechanism must be of a design that they can manipulate. Another option for individuals with strong hip extensor posturing is to use a solid bar instead of a seat belt. These bars, called subanterior superior iliac spine bars (SUBASIS), are attached to the seat (Figure 6.39). These padded bars apply pressure primarily downward toward the seat on the anterior thigh just distal to the hip crease. The restraining pressure from these bars has to be on the anterior thigh and not against the abdomen. When these bars are properly positioned they are very comfortable and provide excellent control of posture. The main problem with some children is that these bars are difficult to get into position, and if they are not correctly positioned the bar tends to be uncomfortable. There is also a tendency for these SUBASIS bars to not be adjusted correctly, especially by vendors with poor under-



standing of their function. The correct adjustment of a SUBASIS bar is that it should be in contact with the anterior thigh when children are relaxed to the point where a finger can just be inserted between the bar and the anterior thigh. The SUBASIS bar should not be in contact with the abdomen when children are sitting relaxed.

Back

Most individuals with CP are best served by a simple flat solid back with a thin, soft padding layer as a covering. There are many modular pieces available, such as lumbar support pads and kyphosis contours, but these add no functional gain and may make individuals more uncomfortable. It is not important to have total contact against the back, so having some open area, especially in the lumbar region, causes no known problems or recognized discomfort. It is very important to keep the back high enough above the level of the shoulders, especially if there is a shoulder harness attached. There is no role for the very short, flexible backseat rests usually advertised with paraplegic-equipped wheelchairs (see Figure 6.26) because these greatly destabilize the already poor trunk control present in the CP population.

Lateral Trunk Support

Many, but not all, individuals with CP have significant instability in the trunk to the point where they require support to prevent from falling to the side. This lateral trunk support is usually fixed to a solid back. Some manufacturers sell lateral supports fixed by Velcro, and these uniformly fail over time, even in relatively small children. The lateral should be fixed solid to a solid back, but the attachment should be adjustable. For children who are very dependent on the lateral support and live in a climate of significant temperature changes, easy adjustment of the medial to lateral position of the trunk lateral is desirable. These are often called summer–winter chest lateral attachments. The disadvantage of the easy adjustment is that it requires caretakers to be attentive to the correct position of the lateral. The attachments of the lateral should also allow vertical adjustment to accommodate for growth and changing spinal deformity. The correct position of the chest lateral in most children is at the midchest level, and the width of the lateral should be approximately one third the height of the chest. The laterals should extend anteriorly far enough so that children do not move anteriorly out of the confines of the restraint. Usually, this position is approximately three fourths of the diameter of the chest wall. The lateral may be constructed with thin, soft pads or contours to the chest wall. For small children less than 30 kg, the flat laterals are simple and work well; however, as these children get heavier and apply more pressure, the contoured laterals may be more beneficial (Figure 6.40). A small group of children without scoliosis always lean to one side but have reasonable trunk and head control otherwise. These children may benefit from the use of only one chest lateral on the side they lean toward. This lateral seems to give them an area to lean against, which they may end up using primarily when they are tired.

Anterior Trunk Support

A tendency to drop into the kyphotic position when sitting is present in some individuals with poor trunk control. This tendency has to be controlled with an anterior trunk support that is available in designs of flexible fabric vests, flexible fabric straps, solid plastic straps, or solid anterior vest molds (Figure 6.41). There are no recognized functional benefits from any of these designs.²³ The function of the different designs seem to depend much more on the correct adjustment rather than the specific design. We have found that

Figure 6.40. Many children need lateral support on the chest to help them remain upright. These laterals need good stability, and it is helpful if they are articulated to swing away for transfers.



Figure 6.41. Many children need some chest restraint at some time to assist with upright sitting. There are a variety of different designs, although almost all fix over the shoulder and come in some anterior vest design (A). Distally, these vests should be fixed posterior and above the hip joint level. It is very important that the chair back be kept high superiorly so the shoulder straps do not depress the shoulders, because the goal is to pull the shoulders posteriorly, not for the straps to act as suspenders holding the wheelchair onto the child (B).

A



the fabric vest design works well for small children and the fabric strap design works better for older, heavier children. The most important aspect by far of the use of anterior supports is that the mechanical function of these systems is to pull the shoulders superiorly and posteriorly, which means the superior straps must be fixed above and behind the shoulders when the children are sitting upright. Many vendors, therapists, and parents see these straps as suspenders holding the wheelchair up against a child's bottom. We have, on many occasions, seen chairs fitting with the back 2 inches below the shoulders and then the vest harness tightened so it depresses the shoulder and encourages the children's spines to roll into kyphosis, exactly the opposite of the desired goal. Also, when children are growing fast, they should have the shoulder harness attachment adjusted every 6 to 9 months to maintain a proper fit. The inferior attachment of the anterior shoulder support needs to be fixed posteriorly to assist in creating a posterior vector at the

B



shoulder; however, this attachment point is not as crucial to good function as the proximal attachment. Another option that can occasionally be used in adolescence is a strap attached to the chest lateral crossing in front of the chest wall. These anterior chest straps only work if the force or tendency to fall into kyphosis is not very strong. These straps are especially useful in female adolescents with large breasts for whom the harness type of restraint is hard to use. The strap is placed immediately inferior to the breasts. Another very important aspect of controlling the anterior fall of the trunk is to have a lap tray and armrest placed in an elevated position. By using the upper extremity on the arm rest or lap tray, children are encouraged to sit upright. In some children, the tray may be placed as high as the nipple line, which will greatly encourage sitting upright.

Headrests

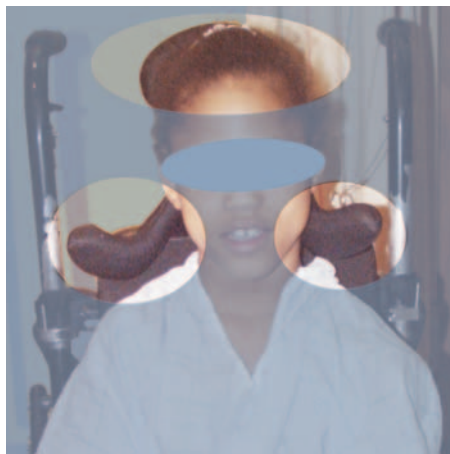Headrests provide two functions, first, to provide support for individuals with poor head control, and second, as a safety feature when riding in a vehicle. For children who have good head control but sit in a wheelchair while riding in a van or school bus, the headrest may be needed only during vehicle transportation. This headrest can be a simple flat extension of the back that can flip down or be removed easily when not needed. For individuals who need head control, a more elaborate system may be needed. If the only head control needed is to prevent hyperextension, a simple flat or mildly contoured headrest only may be required. If a lateral support is needed, a lateral extension, usually coming inferiorly and anteriorly, is preferred. These anterior extensions should be inferior far enough to avoid causing irritation to the ears (Figure 6.42). Proper anterior trunk control is important for the best function of these head restraints. To restrain the severe anterior drop of the head, a mobile forehead strap may be used. This system only works if the forehead has a shape with some ledge or protrusion, which will allow the strap to stay in place. A forehead shape with a posterior slope does not allow this system to work. Another approach to preventing anterior drop of the head is to use cervical collars that place the support under the mandible. Some of these are attached to the chair posteriorly and some are free floating on the children. The free-floating collars, either anterior opening or posterior opening, are safer and are more comfortable for children. These free-floating collars are excellent options for use in vehicles for individuals with marginal head control.

Figure 6.42. A very important component is the headrest. There are many different systems available, and often trial and error is required to find the one that works best. Many headrest systems have modular posterior and lateral sections (A). The lateral sections can be adjusted separately, which is helpful in children with significant asymmetry (B). The lateral parts provide good side-bending control (C), whereas the posterior element prevents hyperextension.

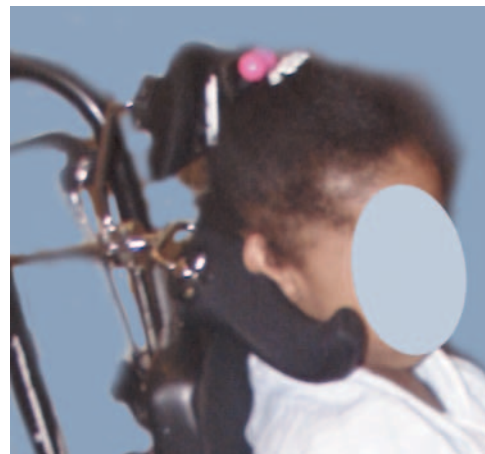
A



B



C



Back-to-Seat Position

The best position for the back-to-seat angle has been extensively debated, with many therapists feeling that individuals do better with the back inclined forward slightly, up to 20°, or the seat raised anteriorly 10° to 20°. All studies that have evaluated these different constructs have found that there is no consistent functional benefit from either position.^{17, 24, 25} Seating position, especially the back angle, however, does affect upper extremity function.¹⁷ In general, children with functional upper extremities should be seated straight upright to slightly inclined forward relative to the floor. Some individuals seem more comfortable with a seat that has anterior elevation of 5° to 10°, but these factors are variable and require individual evaluation. The seat-to-back angle should almost always be close to 90° or greater.

Tray

For individuals who spend most of their time in a wheelchair, the availability of a good stable lap tray is very important for sitting in an optimal upright posture and having a work surface that is always at the right height. Clear, plastic material is best because it is easy to clean, lightweight, and the child's position in the wheelchair can be monitored more easily while the tray is in place.

Attachments

It is very important for the seating clinic to do a good medical and social history to understand all the needs of caretakers and families for the use of the wheelchair. The wheelchair has to be adapted to carry all the things caretakers need when these children are taken out in the community because the caretakers cannot push a wheelchair and also carry a large bag of other things. This careful history should make sure that these things are not overlooked because commonly, when something is overlooked, it takes 6 to 12 months from the time the item is found to be missing until it is ordered, approved by the insurance company, and placed on the wheelchair. Crutch holders are often overlooked and should be added on the wheelchairs of all individuals who use crutches. Other overlooked items are augmentative communication attachment devices, feeding pump holders, and intravenous pump holders, which should be ordered when they are needed for the routine care of these children. Also, suction machines should have a place to be carried if they are required when these children leave the house. Wheelchair frames with respirator supports have to be special ordered if these children use a respirator. This kind of careful medical evaluation is part of the standard expected full seating evaluation.

Cosmetic Appearance

The major element in the choice of which automobile a person chooses to purchase is often based on cosmetic appearance. Likewise, in choosing a wheelchair, the cosmetic appearance is important to caretakers and to the individual wheelchair user. The ability to choose a color gives the user an important task in the process of selecting the system. Although function must not be compromised for the sake of cosmesis, it is important to consider the appearance of the system. Another area of cosmesis to consider is the durability of the seating system, especially the material the seating cover is made of and ease of cleaning. Because this seat is expected to last for approximately 3 years and will be used for long periods of time every day, high wear stress occurs. This high wear stress is an area where different manufacturers try to make improvements and experience gained by vendors, rehabilitation

engineers, and families can help guide a selection. It is recommended to families to be very suspicious of new materials with which no one has experience, because these materials will occasionally be found to function poorly, and it is typical for manufacturers not to know this until the first group of patients has tried them.

Making the Specific Wheelchair Prescription

Most insurance companies require physicians to sign a prescription and to dictate a letter of medical necessity to document why each specific component of this wheelchair is needed. Physicians who sign these prescriptions should have examined the children and understand the appropriateness and need of each component. Although the full list is usually compiled by the seating team, it is still the physician's responsibility to know that the system meets the needs of the individuals for whom it is ordered. Physicians who sign prescriptions for patients they have not seen or order things that they cannot evaluate because of insufficient knowledge of the equipment, disease process, or specific patient can be held liable for fraud.

An example of the prescription and letter of medical necessity that we use for the evaluation team, which allows physicians to evaluate each component and the specific rationale for which it was ordered, is included. This worksheet is also very helpful when writing a letter of medical need (see algorithms).

Seating Problems Related to Skeletal Deformities

Individuals with CP often have specific deformities that are an added challenge to the design of the seating system. Good communication with the treating physician is required when designing seating systems for specific significant deformities. If this communication is overlooked, great efforts will occasionally be made to develop complex seating systems to accommodate, for example, a scoliosis deformity only to find that by the time the system has been ordered, the child no longer has scoliosis because it subsequently has been corrected. This situation has occurred on several occasions in our patients, and there is no excuse for this kind of poor communication from an adaptive seating clinic. Also, it is important for the seating team to understand that some deformities are so severe that seating is impossible. This judgment is rarely made by wheelchair vendors who have some profit motive to sell a wheelchair. Also, these vendors usually have great enthusiasm for challenges and little judgment about what is realistically feasible. The other major misunderstanding held by some members of a seating system team is that the goal of wheelchair seating is to allow children to sit comfortably for as long and with as much function as possible. The goal of wheelchair seating is never to therapeutically correct the deformity. Although there have been multiple attempts to use wheelchair seating for this purpose, these attempts have universally failed in the long term.²⁶

Scoliosis

Scoliosis develops slowly in middle childhood, and during this time it is easy to maintain children in good seating posture. This sitting posture is maintained with three-point pressure by the use of offset chest laterals (Figure 6.43). Although this is a very simple and extremely functional concept, there is often great resistance by therapists and vendors due to misunderstanding the goal of the concept. First, it is important to understand that there is no great good that occurs by having chest laterals at the same height, except that it makes the wheelchair look more symmetric when it is not being

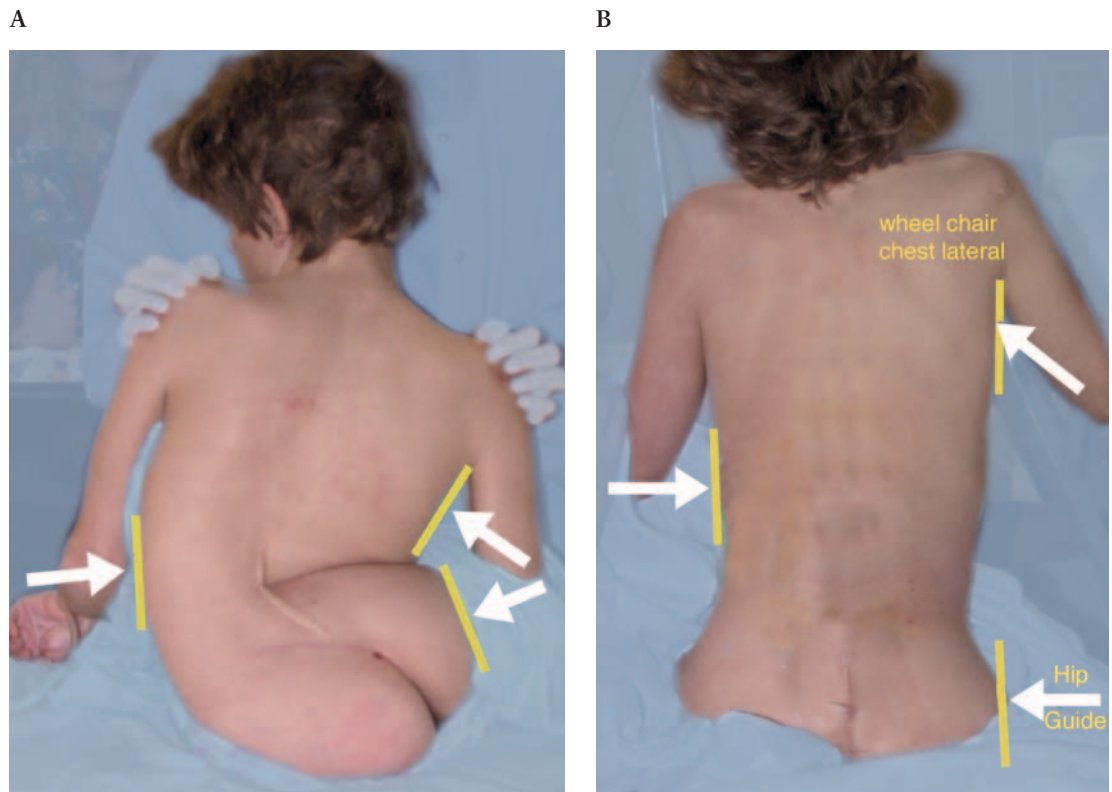


Figure 6.43. Scoliosis is a complex deformity, often including severe pelvic (A) and significant trunk rotation. In correcting this deformity, three-point pressure has to be constructed into the wheelchair with asymmetrically positioned chest laterals and a pelvic guide or block (B).

used. The side to which children fall, or the concave side of the scoliosis, needs to have the chest lateral raised until it is just below the axilla. Some therapists resist moving the chest lateral this high because of a concern that children will be hanging by the axilla. To some extent, hanging by the axilla does occur, but if the laterals are well padded, this does not cause children any harm. For children with scoliosis, even if the laterals are lowered, they will lean over until they hang on the lateral. The opposite side, or the convex side of the scoliosis, should have the chest lateral lowered to the inferior edge of the rib cage. The seat has to be constructed so children stay in the midline, and sometimes a third lateral point has to be added in the form of a lateral hip guide on the concave side of the scoliosis. As these lateral supports are brought to the midline, the scoliosis is corrected by three-point bending. The amount of correction that can be accomplished depends on the size of the curve and the stiffness of the scoliosis. At some point, the severity will increase so much that these children will no longer tolerate the pressure and this system has to be abandoned. Also, the scoliosis causes pelvic obliquity, which can lead to asymmetric seating pressure that needs to be monitored to avoid skin breakdown. For a short time as the scoliosis gets severe, children may be reclined back, and a foam-in-place back support can be used to accommodate the deformity. By this time, these children usually have very limited ability to be upright, and the next stage is to build a flat stretcher-type wheelchair in which deflatable Styrofoam bean bags are used for positioning. It is in this late stage of severe scoliosis when expensive futile attempts at seating often continue to be made after they are clearly no longer feasible (Case 6.3). Current surgical technology is such that severe scoliosis is rarely seen today, and only in children who have been medically neglected, or with parents who have chosen not to correct the scoliosis and plan to only provide comfort care with the expectation of short-term survival.



Case 6.3 Noah

Noah, an 18-year-old boy, was brought to the clinic after receiving no medical care for more than 10 years. He had not been in school. He recently had severe pneumonia, and the medical doctor referred him to the CP clinic for possible treatment. The main concern of his mother was that she needed a way to move him since she could no longer carry him, which was her main way of transporting him from room to room in the house. She never took

him out of the house. The physical examination demonstrated that Noah had severe malnutrition and a severe fixed scoliosis measuring approximately 180° , although the combined physical distortion and low bone density made it impossible to measure the curve (Figure C6.3.1). There were fixed hip and knee flexion contractures of 90° each (Figure C6.3.2). Because his mother wanted no treatment except a way to move him in the house, a

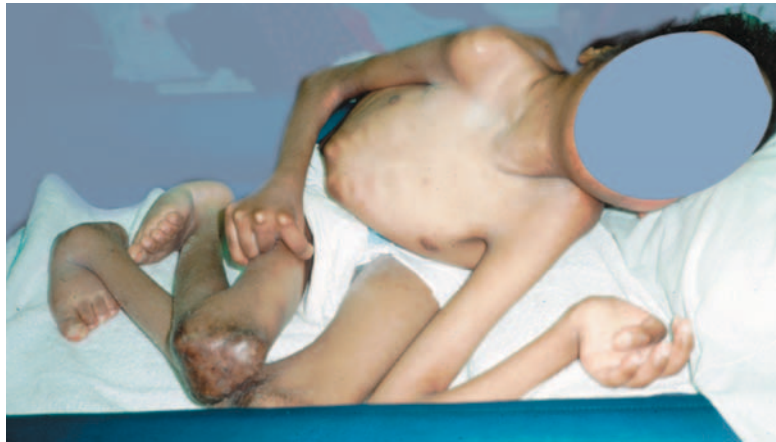

Figure C6.3.1

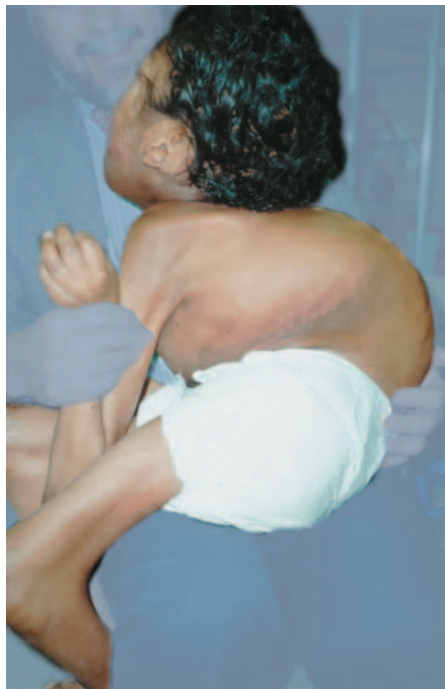

Figure C6.3.2

rolling stretcher that would go through her home doors was built on a wheelchair base, and she was given a deflatable bean bag positioning pillow to help position him (Figure C6.3.3). Noah presented in end-stage deformity in which very little else could be offered, even if his mother desired a more aggressive approach. With his re-

cent severe pneumonia, severe malnutrition, and severe end-stage scoliosis, we anticipated a very limited life expectancy, and he died 9 months later. The only seating option for such a child is some form of reclined stretcher with significant padding because seating is no longer possible (Figure C6.3.4).

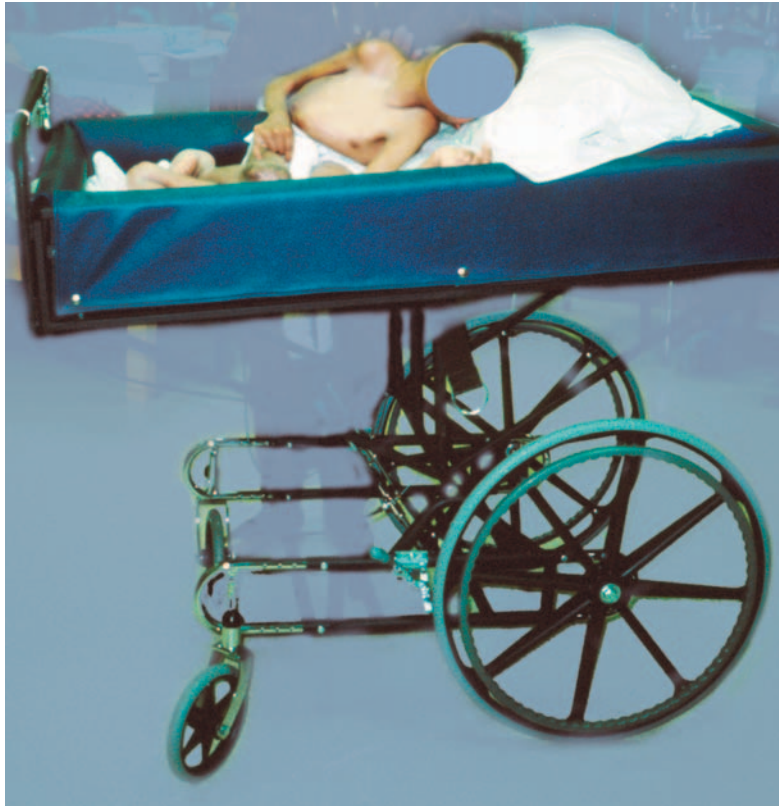

Figure C6.3.3

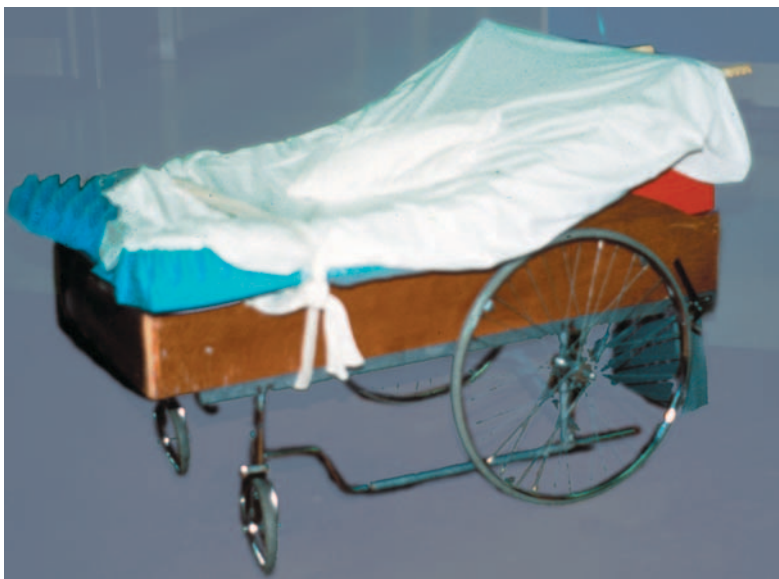

Figure C6.3.4

Kyphosis

Kyphosis in young children is relatively easy to correct because it is very flexible and easy to control with anterior trunk supports, an elevated lap tray, and 90° foot hangers. Hamstring contractures are often overlooked as a cause of kyphotic seating (Figure 6.44). These hamstrings can be inactivated by keeping the knees flexed to 90° to 100° by the use of a 90° footrest hanger and by keeping the footrests posterior. Also, it is important to keep the lap tray high enough so that the upper extremities help children to push themselves into an upright sitting position. It is reasonable to position the lap tray almost to the nipple line to keep children in a more upright position. As children get older, heavier, and the spine often becomes more stiff, this positioning correction of the kyphosis becomes more difficult. After the initial seating adaptations no longer work, serious consideration of surgical correction has to be entertained. Another seating alternative is to recline the seat back posteriorly and allow the hip to extend so children can get their heads into an upright position to look forward. This accommodation of the kyphosis, however, often feeds further into the kyphosis, and these children seem to draw forward more. Another problem with kyphosis is that children's heads drop forward into their laps. This dropping forward of the head seems to be an especially difficult problem in blind children, who have very little incentive to raise their heads and look forward.

Lordosis

Mild to moderate lordosis does not need to have any seating adaptations; however, for severe lordosis, seating is very difficult and there are few seating adaptations that are effective. Anterior elevation of the seat 20° to 30° to tilt the pelvis posteriorly may provide some short-term relief. Also, allowing the buttocks to extend posteriorly of the backrest so that children are sitting upright even with the severe lordosis makes children more comfortable and in a more functional seating position.

Hip Contractures, Dislocations, and Asymmetries

For mild cases of windblown deformity, the use of hip guides and abduction wedges can be used to obtain good positioning. Anterior knee blocks may be added, but these are usually not comfortable for the child (Figure 6.45). Severe windblown hip deformities and pelvic obliquities are very difficult to seat. For the severe deformities, surgical correction should be considered.

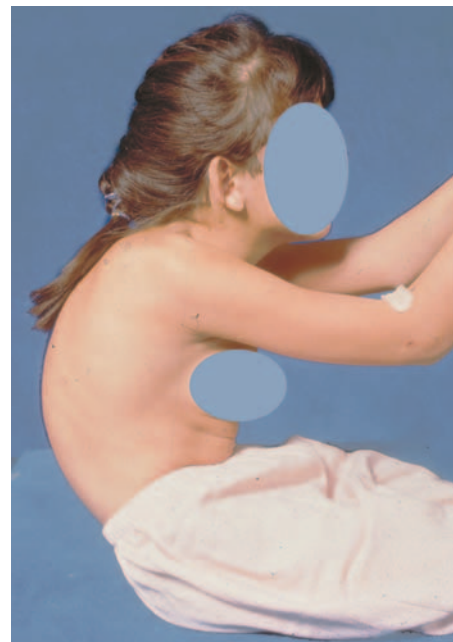

Figure 6.44. Kyphosis that occurs only during sitting and is flexible and not present while lying is often primarily caused by hamstring contracture or severe hamstring spasticity. In both, there is gentle compensatory spinal kyphosis, starting with a posteriorly tilted pelvis.



Figure 6.45. Anterior knee blocks may be used to control pelvic rotation that often occurs with windblown hip deformities. It is very difficult to get these blocks adjusted correctly so that they are comfortable for the child to use for a long period of time.

However, if surgical correction is not performed, the wheelchair needs to be significantly wider than would be needed based only on pelvic width. Typically, for these fixed deformities, 4 or more inches of additional width should be allowed to accommodate the hip deformity. These children will be seated eccentrically in the wheelchair at the side opposite the abducted hip. The abducted thigh and the adducted thigh will then extend over the midline to the opposite side of the seat. Often, attempts are made in seating clinics to keep both knees in the midline, with the result being that children's trunks spin so the adducted side of the trunk moves posteriorly, the abducted side moves anteriorly, and they end up sitting sideways in the wheelchair. Functionally, it is better to have the legs off center and the trunk centered; however, in practice a little bit of both often has to be accepted, especially when the deformities are severe. For severe pelvic obliquity, especially in heavy children, the seat may need to be built up on the side on which the pelvis is elevated.

Hamstring and Knee Flexion Contractures

Severe knee flexion contractures are usually addressed quite easily with the use of 90° footrest hangers to accommodate the knee deformities. In older and taller individuals, this may be more difficult and may require raising the seating system to allow the use of 90° footrest hangers.

Severe Foot Deformities

Severe foot deformities in adolescence can cause pressure and skin breakdown over bony prominences. Typically, these deformities are either severe varus or severe valgus foot deformities. The use of soft moccasin shoes and suspending the feet should be the primary treatment. The feet can be suspended by building an enclosed suspension-type footrest that looks like a padded open box, which prevents the lower extremities from swinging freely and swinging off to the side but does not put any pressure on the soles of the feet.

Seating During Transportation

Safe seating of individuals with disabilities has only attracted attention since the 1980s.²⁷ As states developed mandatory seat restraint laws for children, increased attention was directed to individuals with disabilities as well.²⁸ Younger and smaller children under 20 kg are most commonly transported in car seats with special seating if needed. Most young children, up to age 2 years, can be transported in standard children's car seats; then when they are too large and no longer fit, adaptive seats are required. Generally, these seats are of a similar design to regular infant car seats but are much larger (Figure 6.46). There are several companies that advertise that the standard wheelchair seat can be removed, placed on the automobile seat, and used for seating during vehicular mobility. From a practical perspective of the caretakers, this option does not work because these seats cannot be placed into the car with these children in the seats. These seating systems tend to be large and difficult to handle in and of themselves. Use of this system means that children have to be taken out of the wheelchair, the wheelchair has to be disassembled, and the seat has to be secured to the car seat, then the children have to be placed into the car seat again. The problem is that there is no place to put the children while the wheelchair is being disassembled except to lay them on the ground. Because of these difficulties, a separate car seat is required when children need this level of seating support for safe travel. For children over 20 kg in weight who have adequate trunk and head control, seating in a regular car seat is fine. The other option is to transport these children in wheelchairs; however, this requires a specially adapted van.



Figure 6.46. The car seats for children with disabilities are very similar to those sold for children without disabilities, except the special needs car seats are designed for much larger children.

Special Wheelchair Vans and Lifts

As children become adult sized, especially if they are fully dependent for lift transfers, routine transportation in an automobile becomes very difficult. It is easier to use a van that is equipped with a wheelchair lift or ramp. The wheelchair lift is the best solution but also is the most expensive, and this lift is not considered a medical device by medical insurance companies in the United States. Therefore, it is often difficult for families to afford to purchase a van and have a wheelchair lift installed. Also, when individuals are transported sitting in a wheelchair, approved tie-down systems and wheelchair frames that are approved for tie-down have to be used. These approved systems currently include most standard wheelchairs except for many strollers, which are typically not approved for tie-down or transportation of individuals in a vehicle.

Special Seating and Positioning

There are many different chairs manufactured to provide special seating for children with disabilities. Although there may be some functional advantage to using seats with barrel shapes in which children straddle the seat,²⁹ these special seats have relatively limited use. These special barrel or saddle seats are probably most beneficial if used in a school or therapy environment, where they can be shared by many children. Another problem that many parents have with all the different special seats is the limited space in the home. Before long, parents begin to feel that their house looks like a storeroom filled with medical equipment. A correctly adapted wheelchair can fill all these children's seating needs, although having other places where they can sit in the home has aesthetic value and may provide them with different levels of stimulation. The amount of additional seating should be determined by the needs of the individual child and the living environment of the family.

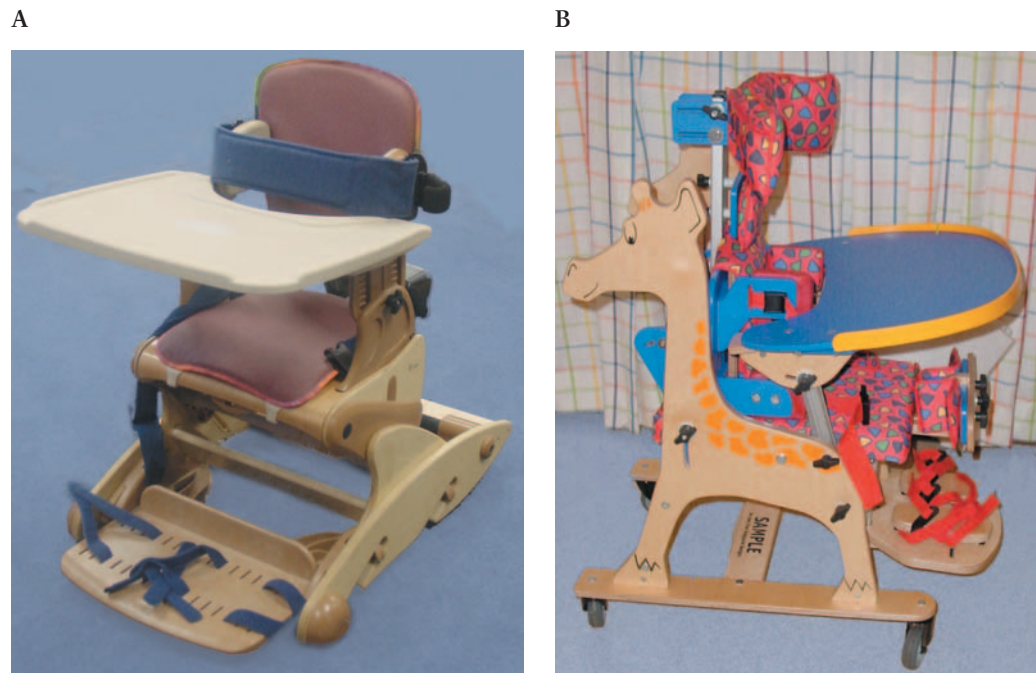


Figure 6.47. This chair is an example of a home feeding chair or a home adaptive seating chair, which provides the child an additional place to sit (A). Many of these chairs have a wooden frame and are relatively inexpensive compared with a wheelchair (B). These chairs can serve as an additional positioning device, but can never take the place of a wheelchair.

Feeding Seats

Appropriate wheelchairs should have children positioned so they can be fed easily. Some parents prefer to have a separate feeding chair because of the ease of cleaning, so the child can be at a better height for feeding, and be at the family table in a way that better incorporates them into the family. These are reasonable needs of caretakers to improve the care of children and are reasonable indications to order a feeding chair. Most feeding chairs are also relatively inexpensive (Figure 6.47).

Play Chairs

There are definite developmental benefits of allowing children to be in many different positions, such as spending time on the floor, sitting at a desk, and sitting in the wheelchair. Floor sitters and corner seats give some children this ability and are reasonable if they fit into the families' living space. This is the same for saddle seats, knee chairs, and barrel seats; however, it is inappropriate for families to get one of every kind of available chair. One or two of these special seats are reasonable. The appropriateness of these devices should be most determined by how these children function while sitting in these positions (Figure 6.48); these devices should be experienced by children in a school or therapy environment before they are ordered for the home. It is inappropriate to order these chairs just because parents saw a nice picture in a catalog. Equipment should not be ordered out of a catalog sight unseen unless a company will guarantee that they will take the devices back with a full refund within a certain time period if they do not meet these children's needs.


Toilet Seating

Children with CP who are cognitively able to understand the concept should be toilet trained by middle childhood. Toilet training children with spasticity and poor trunk control requires an adaptive seat with good trunk support and good footrests so they are comfortable sitting and not afraid of falling. Many different types of toileting seats are available. When children are ap-

A



B



proximately 4 years of age, an appropriate toilet seat should be obtained for families based on a trial-and-error evaluation of the individual child's comfort on the toilet seat. These toilet seats can be tried either in school environments if they are available, or through an occupational therapy evaluation in a pediatric hospital (Figure 6.49). As children reach adolescent size, most can use a standard toilet with some assistance. The availability of handrails in a bathroom is very helpful for many individuals.

Bath Chairs

Children who are not able to sit independently by 3 years of age should be measured for a bath chair. The simplest bath chair that works well for young children is an open-mesh sling seat that can be set into the bathtub (Figure 6.50). When children get too large to lift out of the bathtub, a shower chair can be used. Bath chairs, which are powered by the pressure of tap water, are available. These bath chairs allow children to sit in a sling seat in the water in the bathtub, but then can be raised to chair height to assist caretakers in lifting the children out of the tub. Another option for heavier children is to use a mesh-covered stretcher that sets above the bathtub and the caretakers can use a shower nozzle for bathing. This option works well for larger adolescents who are unable to assist with sitting. For individuals who are able to sit independently but are not able to stand independently, the use of a shower stall with a bench seat is the best alternative.

Desks

The use of adaptive desks in school is often a difficult issue. For children with good seating ability, which means most ambulatory children, sitting at a regular desk at school is expected. Sometimes the height of the desk may need to be adjusted. Children who require full trunk support should be seated in their wheelchair and not placed in a desk, which universally provides poor trunk support. Children who fall in between need individual evaluations. Children who are able to sit at regular desks often feel more included with their peers in the classroom. However, for children who are unable to support themselves and do not have good trunk stability, there is often decreased functional ability for fine motor skills, such as writing. For children who are between definitely needing the trunk support and definitely being able to sit

Figure 6.48. Other home positioning devices may include floor sitters (A) or side liers (B). The indication for these different positioning devices requires consideration of the benefit to an individual child and the available home space to use the device.




Figure 6.49. There are many variations of adaptive toilet seats available; however, toilet training is difficult if the child does not have a comfortable seating chair. Some devices are stand-alone potty chair designs with armrests and foot supports (A), while others have a more typical chair design but roll over a normal toilet (B). Good trunk stability imparted by armrests is important and, for some children, is all that is required (C).

at a desk, there is some advantage of them doing both. In this situation, children will spend some time sitting at the desk to stimulate balance and trunk control mechanisms, and then will spend time sitting in the wheelchair working on fine motor skills.

Floor Positioning Devices

Individuals with severe quadriplegic pattern involvement with no head or trunk control need some position changes throughout the day. These position changes should include getting children out of the wheelchair into different lying positions, such as side lying and prone positioning (see Figure 6.48). These individuals often need pillows or supports for side lying and prone lying. Wedges are often helpful to position these children into the prone position, which allows them to still have interaction with others in the room. These lying supports are most beneficial in school environments; however, some parents find them helpful in the home environment as well. For individuals with severe deformity, especially those with severe scoliosis, deflatable Styrofoam bean bags are the ideal positioning device. These bags can be reconfigured every time children are placed in different positions, and when they are deflated, they are very stable.

Standers

Children who are not able to ambulate with a device still benefit from being in a position other than sitting and lying. An upright standing posture will provide stimulation to the bones in the lower extremities, encourage children to work on head and trunk control, improve respiratory function by aerating different parts of the lungs, and stimulate gastric motility. In addition, children would be placed in a position to experience the world from the perspective of standing upright instead of sitting or lying. There is no research that specifically and objectively quantifies each of these benefits or defines

how much standing is required to gain these benefits. The exact position and amount of weight bearing and time of weight bearing is an especially problematic concern for children with severe osteoporosis and osteopenia who have an increased risk of fracture. The major cause of the decreased bone stock results from the bones getting no weight stimulation; however, how much stimulation is required and at what level has not been documented. Like most biological systems, a little stimulation presumably is better than none, but there probably is a therapeutic dose that needs to be reached to make a measurable impact. We recommend that the minimal goal is to get children to stand with as much weight bearing as possible for a minimum of 1 hour per day. For children who can tolerate standing, moving to 2 hours per day is desirable. The standing program should be initiated between 24 and 30 months of age. Some children do not like standing and parents need to encourage standing in connection with activities that they enjoy. For example, children may be allowed to watch a favorite video, television, or listen to specific music only while in the stander. As children get heavier and near adult size, placing them in standers may become too difficult for families. Continuing standing in the school environment is encouraged so long as standers that fit these individuals are available and the caregivers can get them into the stander (Figure 6.51). The specific stander that is most appropriate for a specific child depends on the child's level of function. Children who walk with walkers do not need to spend time standing as well unless the amount of walking is extremely limited to minimal therapy walking.

Prone Standers

Standers in which children lean forward and are supported on the anterior aspect of the body are called prone standers. This is the preferred stander for children who have acquired head control sufficient to hold their heads up while engaged in activities. Children should be inclined forward 10° to 20° with a tray on the front of the stander. This is the ideal position for children to use their hands for fine motor skills, such as writing and coloring. The main posterior restraint for the prone stander is a belt at the level of the buttocks and chest to hold children in place. These standers are also available with wheels, with the goal being that children can self-propel the stander around the room while being in an upright position. Self-propelling seldom works with individuals with CP who need to use a prone stander because few have sufficient arm coordination or strength to push themselves. These wheeled walkers are convenient for some caregivers who may use the wheels to push the stander with the children in place to different areas in the home, but they provide little direct functional benefit to the children.

Supine Standers

Standers in which children lean back for support are called supine standers. This design is used for children who do not have head control. In the supine stander, children's heads can be supported posteriorly as well. The principal anterior restraints are at the level of the knees, hips, and chest. As much upright positioning as can be tolerated is encouraged, usually with the stander reclined 10° to 20° . In this reclined position, it is not possible for children to do any significant fine motor functioning with the upper extremities; however, most children who require a supine stander do not have any upper extremity function (see Figure 6.51).

Parapodiums

Standing boxes or standers in which children are in an upright position and supported only at the pelvis, abdomen, or lower chest are called parapodiums.



Figure 6.50. Bath chairs or bathing frames can be constructed from PVC pipe or purchased from vendors. There are many types available.




Figure 6.51. Standers come in either supine or prone patient position. The standers may also be called “tilt boards” because many started as flat stretchers that could be tilted up at one end providing a basic supine stander (A). Newer designs hold the child with a few well-placed pads; however, the effect is still the same supine standing (B). For children with hand function and head control, the prone stander is preferred because it places the child in a more functional position. This can be a simple frame that leans on a regular table (C), or a more sophisticated free-standing device with its own attached tray (D). Standing boxes, or mobile standing boxes that the child can push, have been developed and work well for children with spinal cord dysfunction who have normal arm function; however, these devices have little role for children with CP, because if their arm function is that good they are even more functional in a walker (E).

These were specially designed for children with spinal cord paralysis who have good upper extremity and upper trunk control and function. Para-podiums are almost never appropriate for children with CP who require a stander. Children with CP who stand in the paraopodium tend to collapse into the device until they are hanging on its most proximal support. Para-podiums and standing boxes should not be ordered for children with CP.

Walking Aids

Most children with CP will, at some time during their growth and development, use a walking device. Most children who become independent ambulators will start ambulation with the use of a walker. Also, many children who can do standing transfers only will have a period of time when they can do some walking with a walking aid. Most children start standing by pulling to stand and holding onto furniture or toys. Most children are cognitively not able to effectively use a walker until approximately 2 to 2.5 years of age; however, many will be pushing toy baby buggies, wheeled chairs like office chairs, or other toys. As children start to do this type of assistive walking, a walker should be introduced, usually at 24 to 30 months of age. As children gain confidence, and through work in therapy, the use of the walker will increase. For children who have excellent lower extremity control and functional gait but are not able to walk independently, crutch use is introduced in therapy at approximately 5 years of age. Developmentally, even normal children can seldom learn to use crutches until approximately 5 years of age. Therefore, it makes little sense to try to get children with CP to use crutches much earlier. As children get to early adolescence, crutch use should be more strongly encouraged if the physical functional ability is present. There are very few young adults with CP who continue to use walkers for a significant amount of ambulation. Most individuals who use an assistive device and are functional community or full independent household ambulators will do so with crutches and not a walker. The walkers tend to be clumsy and difficult to transport. For a full-sized adult, the walker is often so wide that it does not easily fit through standard home doors.

Walkers

Walkers are available in a complex array of shapes and options; however, there are some basic styles that are important to consider when deciding which walker is appropriate for individuals. Even for therapists or physicians with significant experience, finding the best walker for children is still a combination of trial and error to see which walker these children prefer and which they can handle best. The most basic difference in walkers is they are either back- or front based. The front walker, or anterior-based walker, is pushed in front of children and the back or posterior walker is pulled along behind children. These walker styles are available in all sizes and many different frame constructs. In general, for children with CP, the posterior walker encourages a more upright posture and may improve walking speed. The posterior walker is the most common design used for children in early and middle childhood (Figure 6.52). The two exceptions are blind children and those with mental retardation who often cannot functionally use a posterior walker. Children with severe mental retardation may not be able to understand that the walker, which they cannot see, will still provide support. A developmental age of approximately 24 to 30 months is required to use a posterior

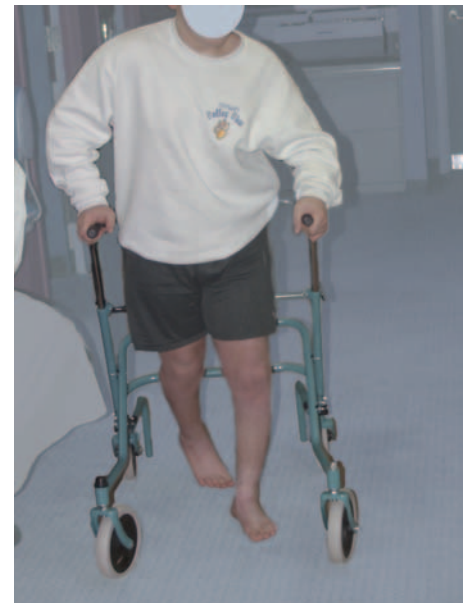

Figure 6.52. Gait assistive devices have many designs, each that tend to have benefits for an individual child. The most common posterior walker encourages children to stand more upright and may increase walking speed.



Figure 6.53. Simple forward walkers are also easier for children who have severe mental retardation to learn to use, but tend to encourage children to lean forward too much.

walker. For children with lower cognitive ability, the front-based walker works better (Figure 6.53). Blind children also tend to do better with a front walker. As children get older and heavier, the posterior walkers become very wide. If individuals cannot functionally use crutches by adolescence, conversion to an anterior walker allows for a more narrow based design and is often smaller and easier to transport. The variations between the benefits of children being in a more upright position are more obvious in childhood than in adolescence.

These anterior-based walkers for adolescents and adults may be fitted with articulating wheels and brakes, and some even have flip-down seats so individuals have a place to sit when stopped (see Figure 6.52). The standard height of walkers should be between the top of the iliac spine and the lumbosacral junction. The standard height of the handgrips between the iliac spine and the lumbosacral junction level can be altered based on an individual child's needs. The position of the handgrips is another optional element when ordering walkers. These handgrips may be either horizontal handgrips at the top of a standard walker height or elevated vertical handgrips. In a few children, even using a walker that allows leaning on the elbows works (Figure 6.54). In a population of individuals with CP who use walkers, the position of these handgrips makes no functional difference³⁰; however, there are individual children for whom this handgrip position can make an important functional difference. The simplest handgrip, if children can hold comfortably to this handhold, is the horizontal grip at the top of the walker. For children who want to have their arms in the high or midguard position and who cannot get their arms to their side, elevated vertical handgrips, often positioned somewhat toward the midline, are required. For children with a hemiplegic posturing upper extremity, an elevated arm platform with a vertical handgrip is required on the hemiplegic side.

The floor interface for walkers may be wheels or simple crutch tips. For children who have started to walk, the walker should start with crutch tips on all legs. As children gain confidence and speed of walking, posterior wheels may be added. These wheels usually lock in reverse so they can only turn when the children move forward. As children gain more ability, front wheels may be added. As children gain even more ability, free-turning front caster wheels can be added. The need for this different level of support has to be determined through trial and error based on how children are functioning and how the functional ambulation is changing. A major aspect of ongoing physical therapy treatment should be monitoring of children's changing development and ambulation ability. As this ambulation ability increases, the support provided by the walker should be decreased sequentially by the use of wheels that provide less resistance and stability of the walker on the floor. The advantage of these wheels is that they allow children to move faster. As more children are mainstreamed into neighborhood schools where there are fewer experienced physical therapists and where there is little equipment available, this kind of sequential support reduction as children are gaining ambulation skills often gets overlooked. Therefore, ambulation skills have to be more diligently evaluated by CP physicians during routine clinic visits.

Hip guides are another optional attachment that can be added to a walker. Some children continue to have difficulty with medial to lateral instability of the pelvis. Adding hip guides to keep the pelvis in the midline is a method to address this problem. These hip guides should be used only when children have a tendency to be very unstable or to consistently be pushing to one side of the walker.

Gait Trainers

Another type of walker that has many different variations is the gait trainer. Conceptually, this device works exactly like the infant ring walker, which would allow 8- to 9-month-olds to walk around the house before they have independent walking ability. Gait trainers by definition have some kind of seat that will support children if they do not hold themselves in a standing position (Figure 6.55). These walkers provide enough support so that children will not fall over even if completely relaxed. Many children seem to enjoy the movement ability in a gait trainer much more than being restrained in a stander. There is great controversy among some physical therapists with a concern that these walkers foster poor posture and do children great harm. This same view has been expressed about infant walkers.³¹ There is no objective evidence that a gait trainer can cause any harm or limit development of children. The major risk of children who can actually move the walkers is for the walkers to go down stairs, drop off a step, or tip over. Parents must be warned about these risks, especially if there are other children in the home who may open and not close basement doors or outside doors where children in walkers could go down stairs. These dangers are exactly the same as for infants in ring walkers. There are no clear documented benefits from the use of gait trainers; however, some children enjoy them very much and it does give them a chance to move in a way that they are not able to do otherwise (see Figure 6.52). These walkers may help provide some force on the bones and improve respiratory and gastrointestinal function similar to a stander.

Typically, the gait trainer is used for children from age 4 to 10 years with widely varying degrees of success. Parents are often very enthused about seeing children upright in a position where they are moving themselves. There is a sense among parents that this is the first step in children developing more independent gait; however, children almost never gain additional ability. It is very rare for children to move from a gait trainer to independent use of an unsupported posterior or anterior walker. At this time, there is no documented benefit that gait trainers help or harm children's functional motor development. Because of the many styles and shapes of gait trainers, a trial use should confirm that it functions before it is ordered for an individual child. If this is not possible, the company should give a guarantee that they will take the gait trainer back within a certain time frame if the child is not able to use the device. The gait trainer design should allow older and heavier children to be positioned in the walker without having to lift them up and over, as with the infant ring walker design. Also, many children seem to do better if positioned with a slight anterior tilt to the trunk similar to being in a prone stander. There are some large commercial gait trainers available that allow adolescent young adults to be placed directly from the wheelchair seated position and then raised to standing with a mechanical lift (see Figure 6.55). These gait trainers are mostly used in special schools that have a special movement educational program for adolescents with severe motor and cognitive limitations. The adolescents seem to enjoy this mobility and do very well with this kind of extensive motor stimulation. Other direct benefits of this kind of motor stimulation for cognitively limited adolescents are more difficult to quantify (Figure 6.56).

Crutches and Canes

Most adolescents who use assistive devices and are full community ambulators use single-point forearm crutches. These crutches are primarily used to

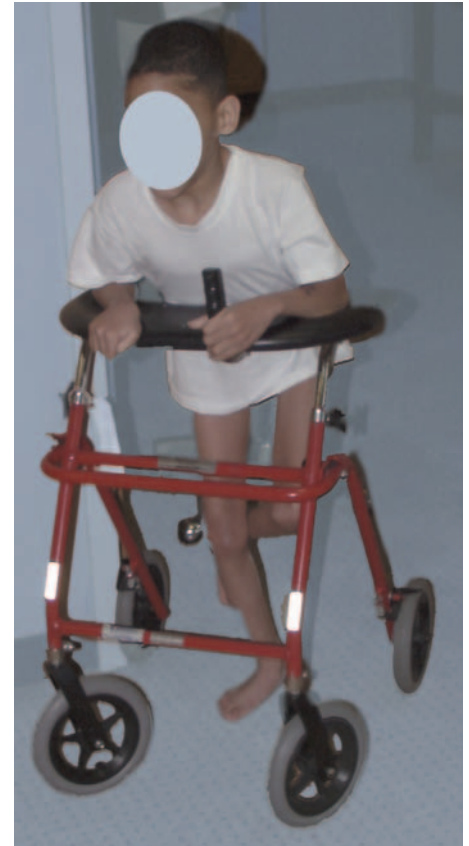

Figure 6.54. The forward-based walker allows better weight bearing on marginally functioning upper extremities.

A



B

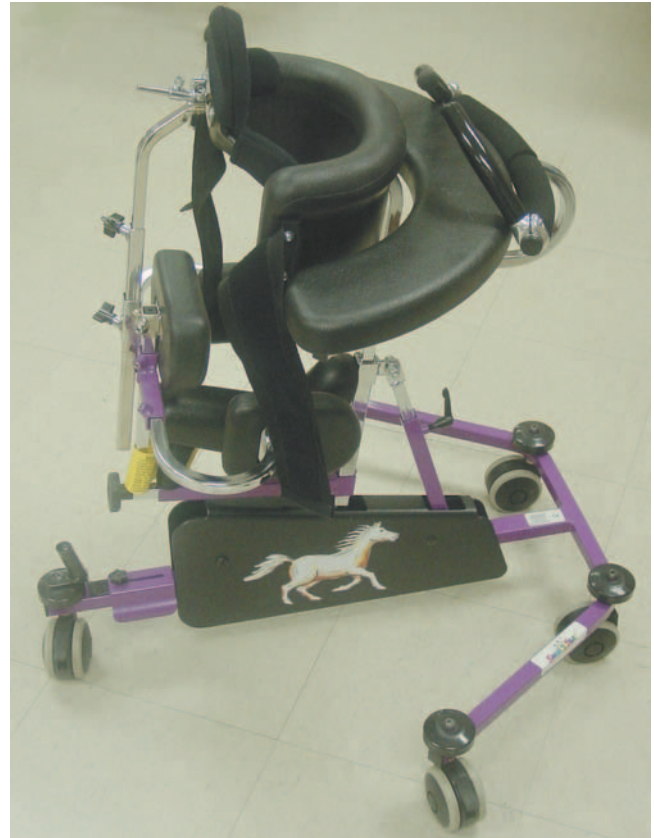
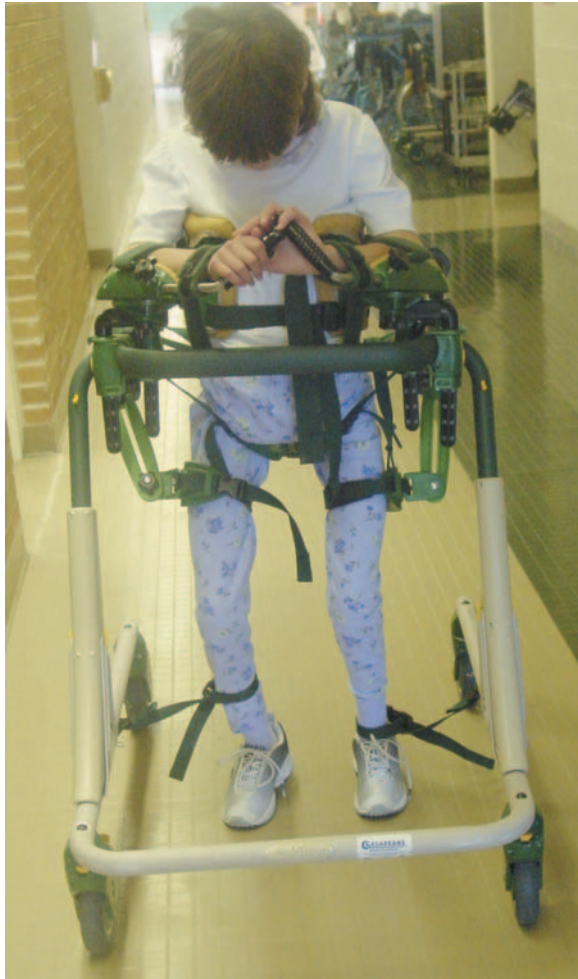
Figure 6.55. For children with more limited motor or balance function, there are many styles of gait trainers, from relatively simple walking frames (A) to frames with good armrests (B) and those with sophisticated armrests, hip guides, and foot guides (C).

augment individuals' poor balance and not to unload weight from the legs (Figure 6.57). The amount of weight applied to the crutches varies greatly. Lightweight forearm crutches are the best walking aids to assist with balance because they are easy to maneuver and, with the forearm strap, can even be held by the forearm while the hand is used for other functions, such as holding cups. Many of these individuals walk around the home holding on to furniture or using only one crutch. A fairly large group of excellent walkers with forearm crutches have a period of time in middle childhood, often between the ages of 7 and 10 years, when they have walked independently in the community without assistive devices. During this middle childhood period, the children fall often, but are able to keep up with their peers because going at a relatively fast speed works well with their poor balance, although their instability causes the frequent falls. As individuals grow heavier and much taller, there is often a period in adolescence when they may find walking more difficult and have to start using crutches. Using crutches may seem like a setback to children and parents; however, when it is pointed out that these adult-sized individuals with crutches are now walking without falling all the time, the parents and the adolescents can see the major benefit of crutch use for community ambulation. Using crutches does not mean that these individuals' walking ability has deteriorated, it primarily means that the walking functions and actions of 8-year-olds are not socially acceptable for 16-year-olds. Also, falling at age 16 years hurts much more than falling at age 8 years, when children are much smaller. It is a grave mistake to put a falling child in wheelchair without trying to teach them crutch use. This

C



D



Figure 6.55 (continued). Gait trainers are also available with built-in hydraulic lifts, which allow use by larger and heavier adolescents (D).

step sometimes causes the child to become a permanent wheelchair user when she could well have been a community ambulator with crutches had she been given the appropriate therapy training with the crutches before becoming psychologically wheelchair dependent (see Case 6.1).

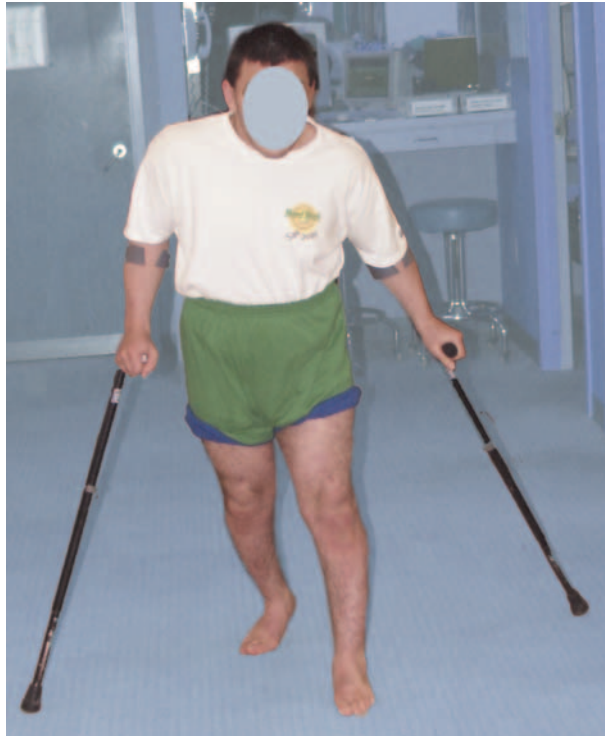Other assistive devices, such as single-point or three-point canes, may be used on occasion in physical therapy to stress the balance development of growing children. The same function can be applied to the use of three- or four-point forearm crutches. Individuals with CP can seldom use one or two single-point canes effectively, and when they try to use three- or four-point canes or crutches, gait slows greatly. Also, with these three- or four-point canes or crutches, there is great postural instability unless the surface is perfectly level and flat, which is exactly the major problem with which these individuals are struggling. Individuals who cannot use single-point forearm crutches in general need to stay with walkers and often are switched to anterior walkers at adolescence.

Standard axillary crutches have no use for children with CP because the fixed position required of the upper extremities is often difficult to maintain, and it is very difficult for individuals with CP not to just hang on the axillary bar.



Figure 6.56. Although gait trainers may pose some safety risk to children with CP and there is not good documentation of long-term benefit, many children really enjoy the opportunity to be able to move under their own force.

Figure 6.57. Forearm crutches are the most versatile assistive devices that an adolescent with CP can use if they are not independent ambulators. These are available in various colors and are lightweight.



Patient Lifts

A major problem occurs when adolescents grow to the point where parents can no longer lift them. If children's physical disabilities require a full dependent lift, this often creates a significant strain on the caretakers, especially during rapid adolescent growth. One solution that is often requested by caretakers is to obtain a patient-lifting device. There are two general types available. One is a lift that rolls on the floor and has to roll underneath the device from which the children are being lifted. These lifts usually lift children with a sling that has been placed underneath them. After children are lifted by the device, the lifting device can then be rolled to a different location where they can be lowered. The second patient lifting system is attached to a ceiling and runs on tracks mounted on the ceiling. Patients are lifted using a similar sling seat but then rolled along the tracks. The system that rolls on the floor requires a hard surface with no carpet. Also, the device from which individuals are lifted has to be open to allow the lifting device to roll underneath. This means beds and wheelchairs are usually appropriate; however, individuals cannot be lifted out of bathtubs with this type of lifting device. Also, these floor rolling devices have wheels that are very small and are often very hard to push, especially if the individuals lifted are very heavy. Most caretakers find this style of floor rolling lift very difficult to use and often more trouble than beneficial, unless there is absolutely no other way to move the individuals. The ceiling-mounted system is very easy for caretakers to use and to push; however, it is limited to the location where it is installed. In general, the ceiling-mounted lift system is highly praised by caretakers. The ceiling-mounted system can be installed so that individuals can be lifted out of the bath, onto the toilet, out of the wheelchair, and onto the bed. This system can be installed in a bathroom and bedroom combination and is very functional. Another disadvantage with the ceiling-mounted patient lift is that it can be installed only if families own their homes and if they are willing to

make significant structural changes to allow the installation of the system into the ceiling. Another major disadvantage for families is that this system, because it is installed in the home, is considered a home modification by insurance companies and is usually not a covered benefit. In comparison, the floor rolling system, which does not work very well, is not attached and therefore can be considered a medical device and not a home modification.

Other Durable Medical Equipment

There are other devices for which physicians may be asked to write prescriptions: these include communication devices, home environmental controls, home modifications, and diapers. Augmentative communication is a large complex area, which is almost impossible for physicians to keep up with. There are augmentative communication specialists who are usually specially trained speech therapists. Many of these systems are obtained through school systems so there is no need for a medical prescription. If requests for prescriptions are made and physicians believe, on the basis of their knowledge level, that the children have the cognitive ability and physical need for the device, physicians should obtain a full evaluation. This evaluation should include a description of the testing that was performed and the rationale for the specific devices requested. This report should also document that the children have demonstrated an appropriate physical and cognitive ability to use the system. Home environmental control switches, stair lifts, and home modifications such as door widening and special bathroom installations are very appropriate methods of ameliorating the disability from motor impairments. Physicians are seldom in positions to make specific recommendations; however, prescriptions or letters of medical need that such modifications are appropriate because of these children's motor impairments may help families obtain resources to get this work done. These modifications are never covered by medical insurance; however, with a letter of medical need families can deduct the cost as a medical expense in some cases on their tax returns. These deductions should only be made on the recommendation of a tax specialist. Some insurance plans will cover the cost of diapers after a certain age if children are not toilet trained. These diapers need a prescription, which is an annoyance because the need is self-apparent; however, families have to get this paperwork and a family physician or other physicians caring for these children to provide this prescription to help families access the appropriate supplies. Another area where families often ask for recommendations or prescriptions are special play equipment such as tricycles. Some of these can be set up as therapeutic devices (Figure 6.58); however, it is often difficult to find adequate documentation to get medical coverage for these devices. A device such as a wheel swing may add to children's normal childhood experience, but again it is very difficult to justify these as medical devices (Figure 6.59).

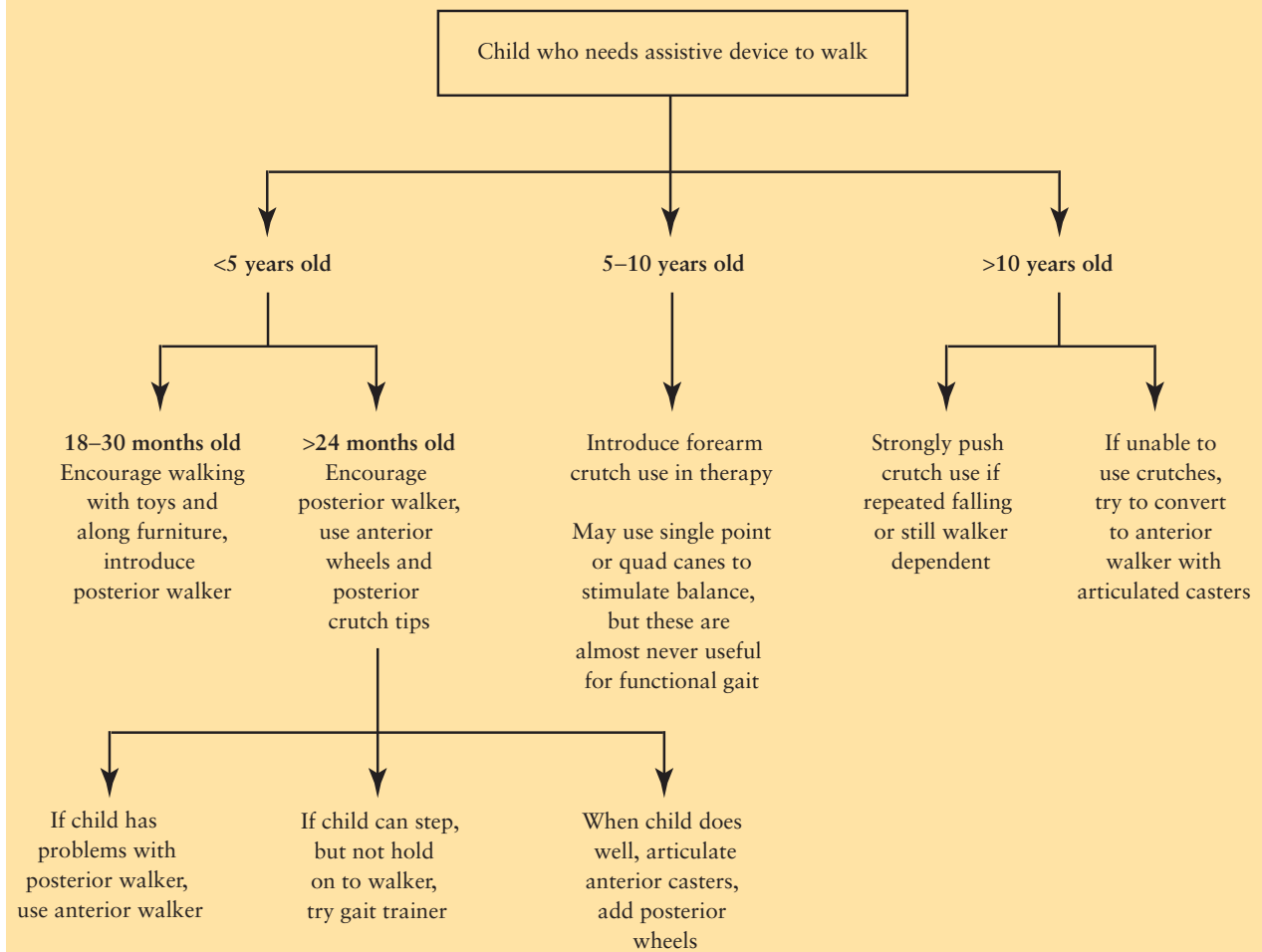


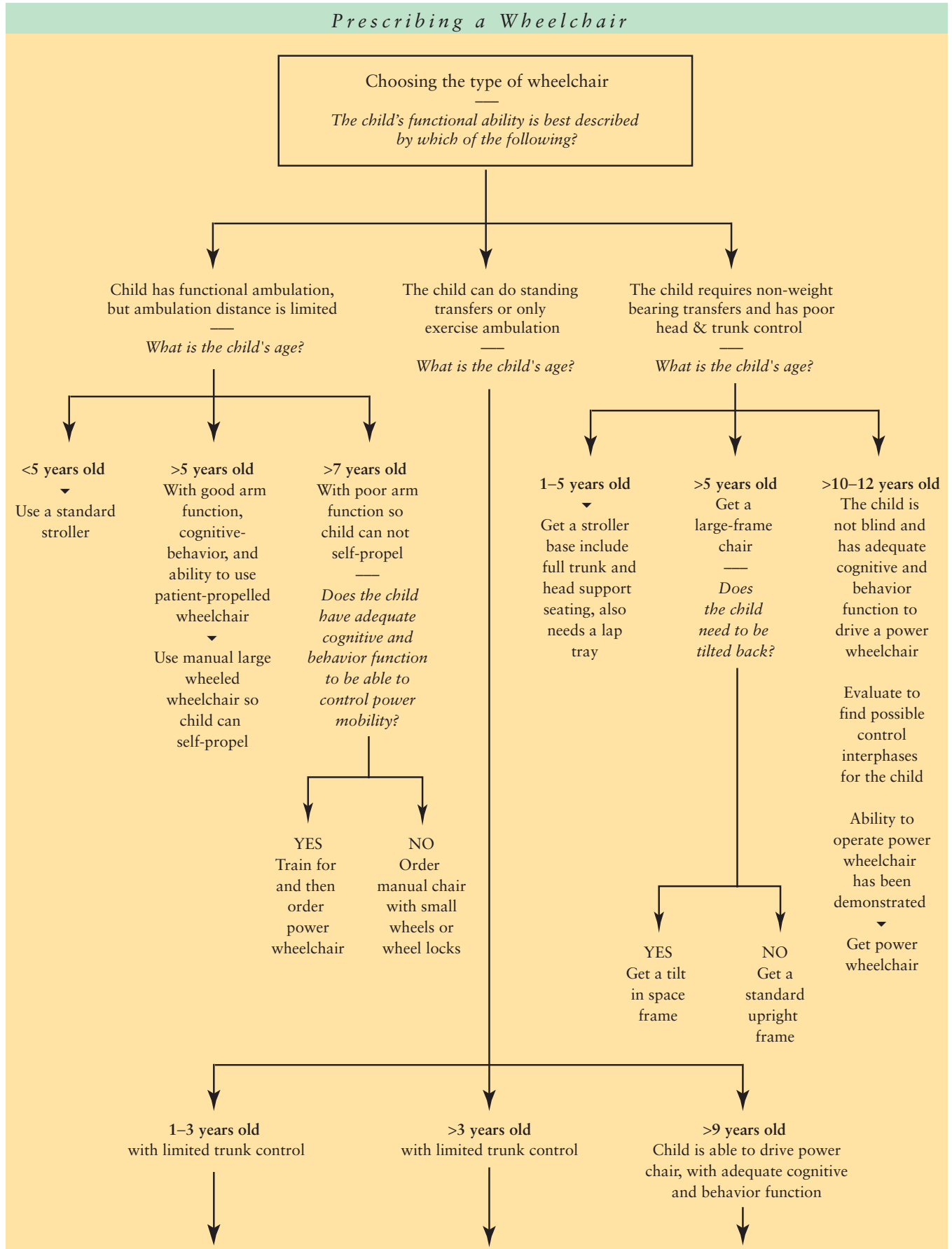
Figure 6.58. Other devices that tend to bridge the gap between therapy and play are therapeutic tricycles, which may provide excellent endurance training and balance development.

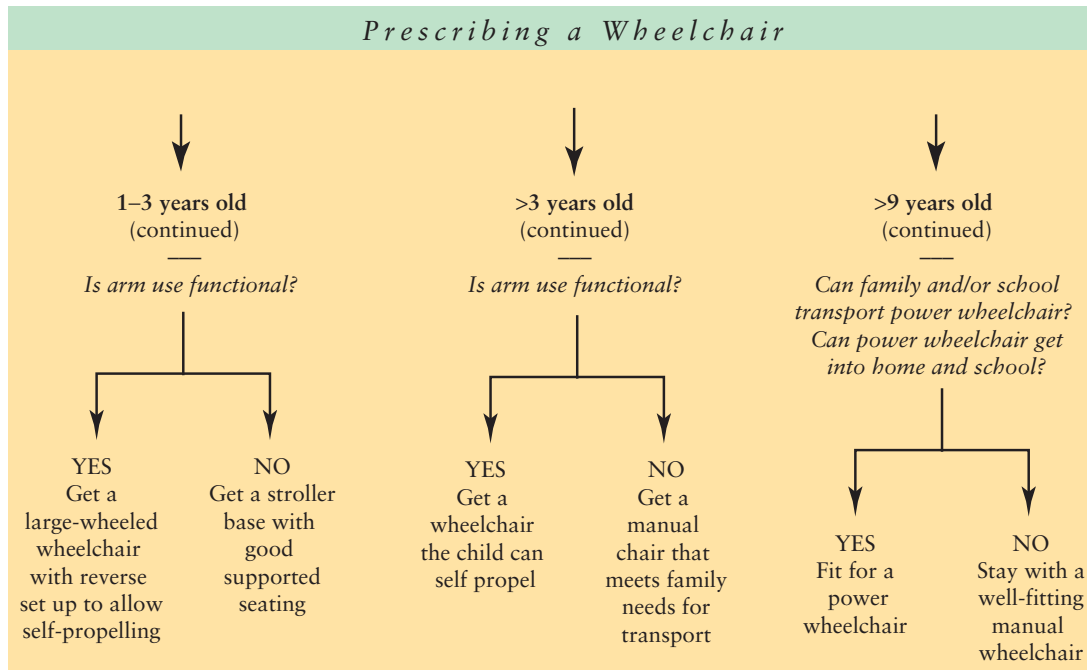


Figure 6.59. A wheelchair swing can also provide excellent stimulation for some children who have little chance for such normal childhood activities as experiencing a swing.

Assistive Devices

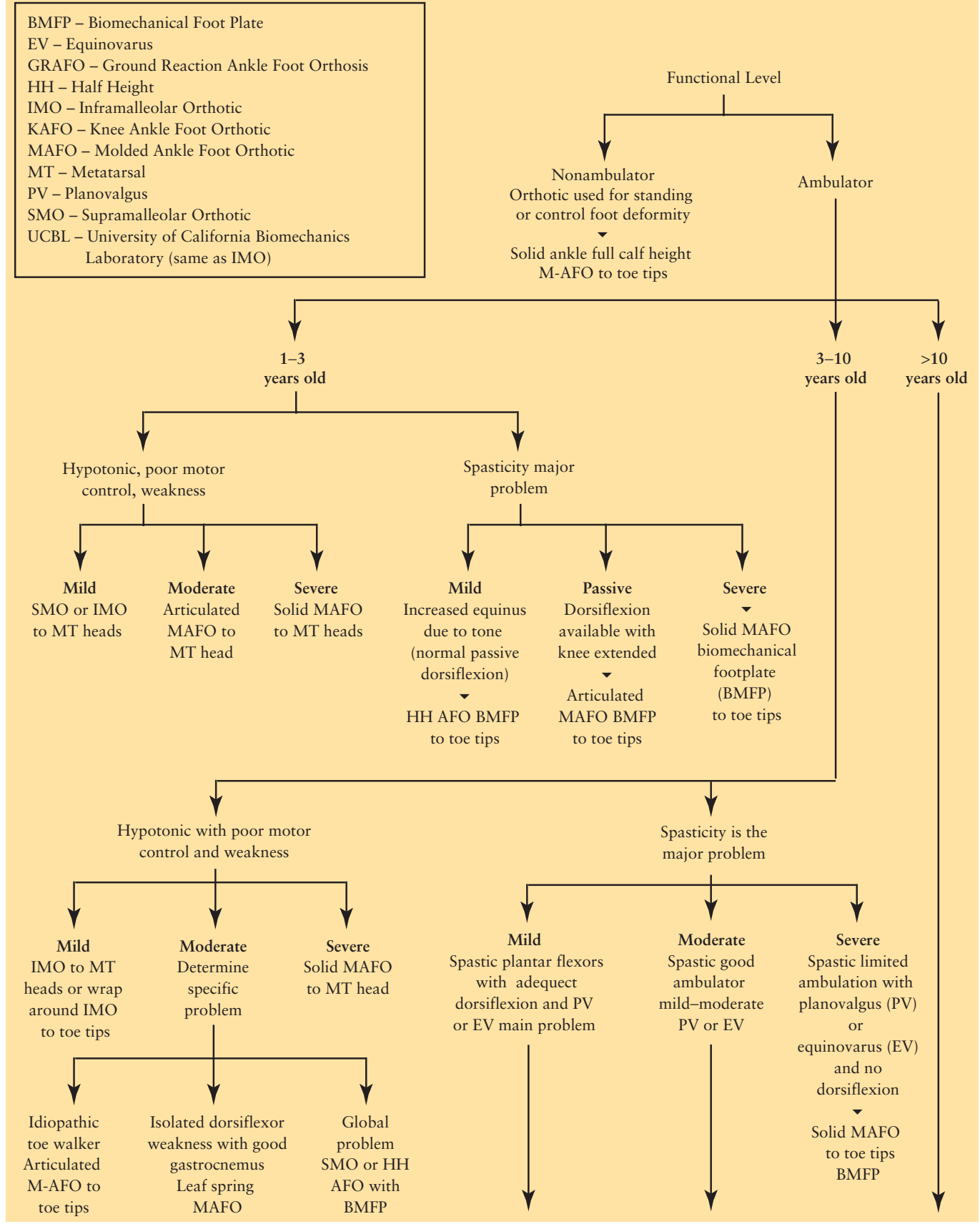




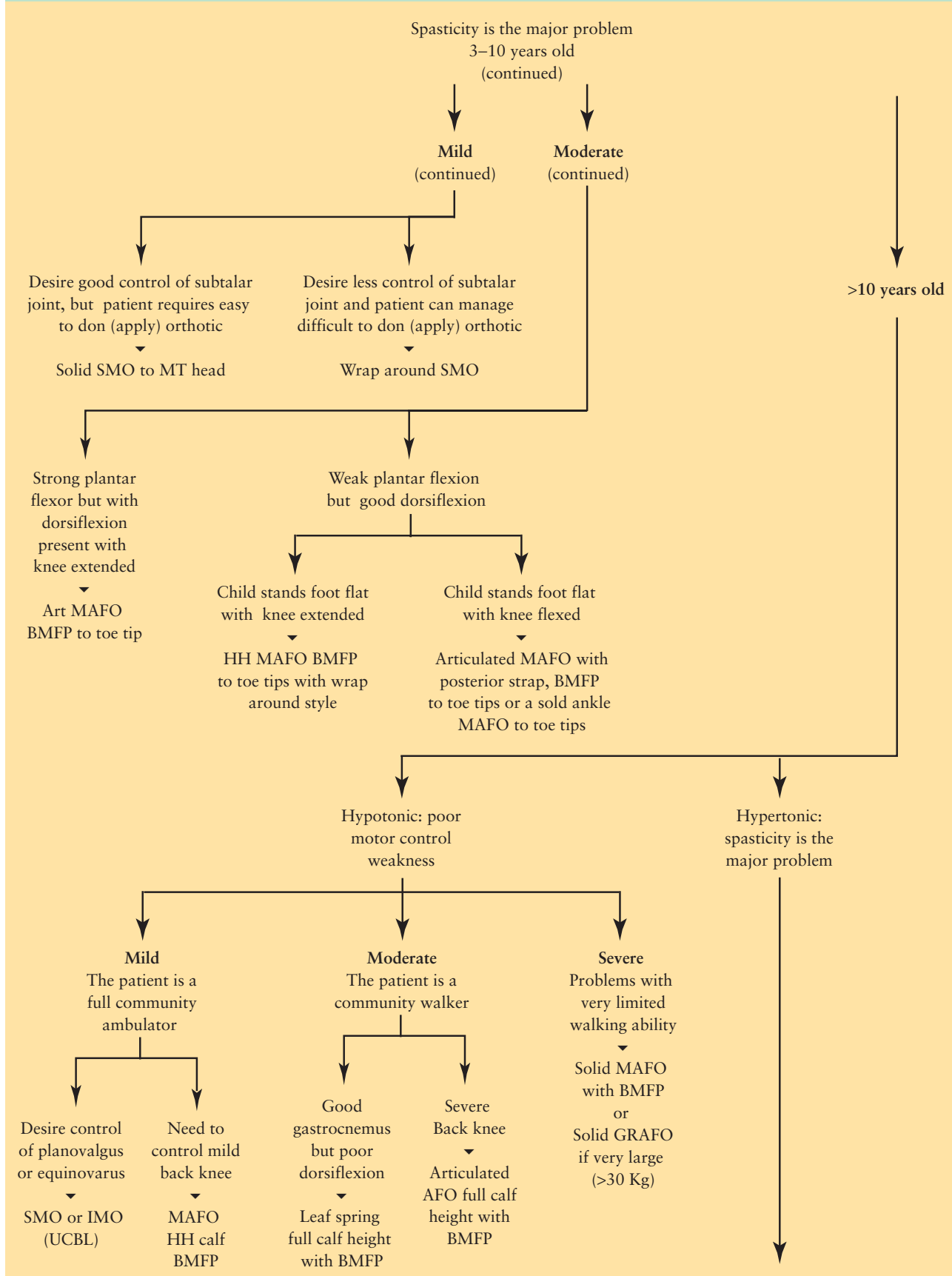


Neuromuscular Foot Orthotic Prescriptions

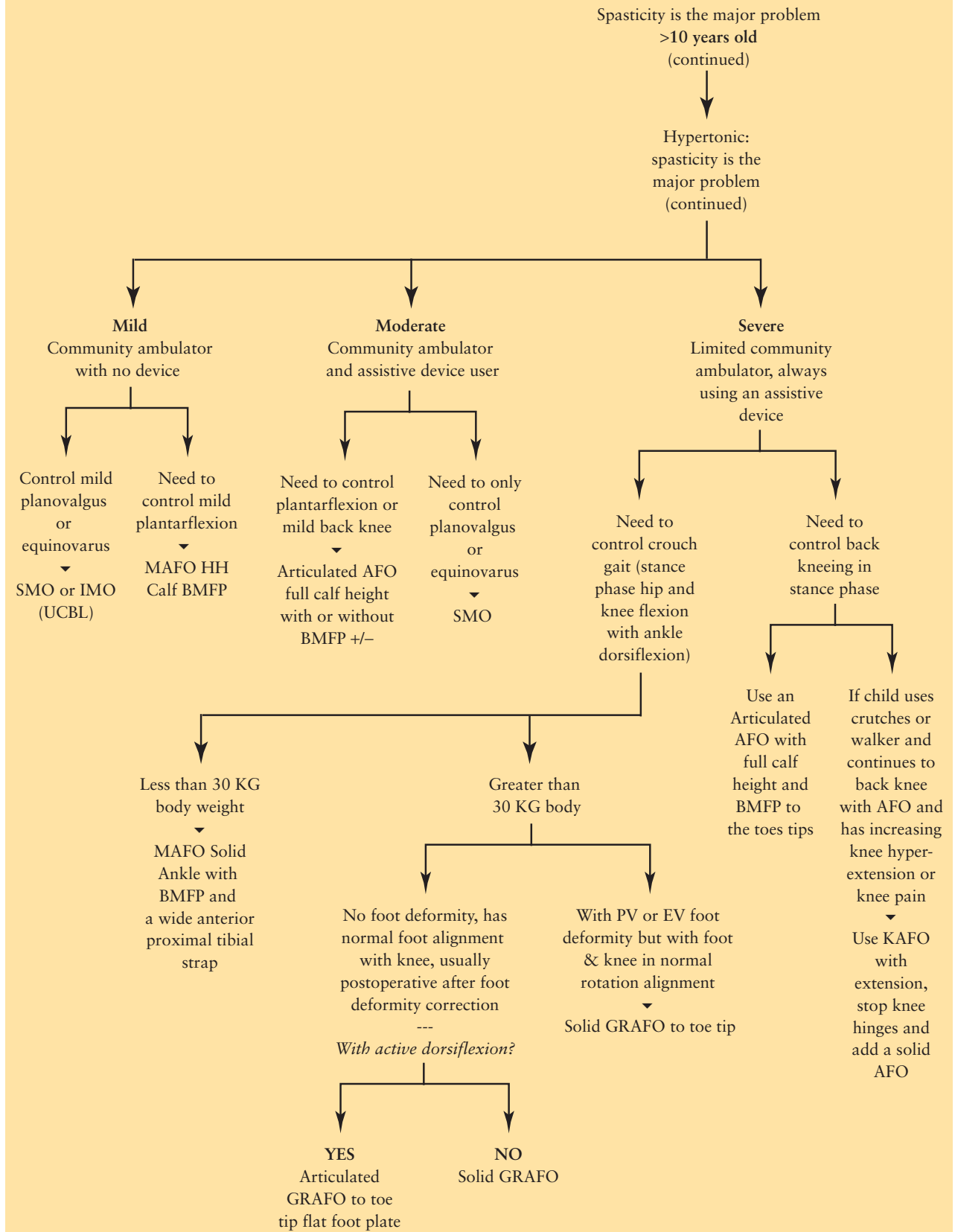
BMFP – Biomechanical Foot Plate
 EV – Equinovarus
 GRAFO – Ground Reaction Ankle Foot Orthosis
 HH – Half Height
 IMO – Inframalleolar Orthotic
 KAFO – Knee Ankle Foot Orthotic
 MAFO – Molded Ankle Foot Orthotic
 MT – Metatarsal
 PV – Planovalgus
 SMO – Supramalleolar Orthotic
 UCBL – University of California Biomechanics Laboratory (same as IMO)



Neuromuscular Foot Orthotic Prescriptions



Neuromuscular Foot Orthotic Prescriptions



References

1. Miller A, Temple T, Miller F. Impact of orthoses on the rate of scoliosis progression in children with cerebral palsy [see comments]. *J Pediatr Orthop* 1996;16:332–5.
2. Leopando MT, Moussavi Z, Holbrow J, Chernick V, Pasterkamp H, Rempel G. Effect of a soft Boston orthosis on pulmonary mechanics in severe cerebral palsy. *Pediatr Pulmonol* 1999;28:53–8.
3. Miller F, Slomczykowski M, Cope R, Lipton GE. Computer modeling of the pathomechanics of spastic hip dislocation in children. *J Pediatr Orthop* 1999;19:486–92.
4. Szalay EA, Roach JW, Houkom JA, Wenger DR, Herring JA. Extension-abduction contracture of the spastic hip. *J Pediatr Orthop* 1986;6:1–6.
5. Carlson WE, Vaughan CL, Damiano DL, Abel MF. Orthotic management of gait in spastic diplegia. *Am J Phys Med Rehabil* 1997;76:219–25.
6. Crenshaw S, Herzog R, Castagno P, et al. The efficacy of tone-reducing features in orthotics on the gait of children with spastic diplegic cerebral palsy. *J Pediatr Orthop* 2000;20:210–6.
7. Radtka SA, Skinner SR, Dixon DM, Johanson ME. A comparison of gait with solid, dynamic, and no ankle-foot orthoses in children with spastic cerebral palsy [see comments] [published erratum appears in *Phys Ther* 1998;78(2):222–4]. *Phys Ther* 1997;77:395–409.
8. Burtner PA, Woollacott MH, Qualls C. Stance balance control with orthoses in a group of children with spastic cerebral palsy. *Dev Med Child Neurol* 1999;41:748–57.
9. Ricks NR, Eilert RE. Effects of inhibitory casts and orthoses on bony alignment of foot and ankle during weight-bearing in children with spasticity. *Dev Med Child Neurol* 1993;35:11–6.
10. Abel MF, Juhl GA, Vaughan CL, Damiano DL. Gait assessment of fixed ankle-foot orthoses in children with spastic diplegia. *Arch Phys Med Rehabil* 1998;79:126–33.
11. Hainsworth F, Harrison MJ, Sheldon TA, Roussounis SH. A preliminary evaluation of ankle orthoses in the management of children with cerebral palsy. *Dev Med Child Neurol* 1997;39:243–7.
12. Ounpuu S, Bell KJ, Davis RB III, DeLuca PA. An evaluation of the posterior leaf spring orthosis using joint kinematics and kinetics. *J Pediatr Orthop* 1996;16:378–84.
13. Wilson H, Haideri N, Song K, Telford D. Ankle-foot orthoses for preambulatory children with spastic diplegia. *J Pediatr Orthop* 1997;17:370–6.
14. Nwaobi OM, Smith PD. Effect of adaptive seating on pulmonary function of children with cerebral palsy. *Dev Med Child Neurol* 1986;28:351–4.
15. Hulme JB, Bain B, Hardin M, McKinnon A, Waldron D. The influence of adaptive seating devices on vocalization. *J Commun Disord* 1989;22:137–45.
16. Hulme JB, Shaver J, Acher S, Mullette L, Eggert C. Effects of adaptive seating devices on the eating and drinking of children with multiple handicaps. *Am J Occup Ther* 1987;41:81–9.
17. Nwaobi OM. Seating orientations and upper extremity function in children with cerebral palsy. *Phys Ther* 1987;67:1209–12.
18. Reid DT. The effects of the saddle seat on seated postural control and upper-extremity movement in children with cerebral palsy. *Dev Med Child Neurol* 1996;38:805–15.
19. Medhat MA, Redford JB. Experience of a seating clinic. *Int Orthop* 1985;9:279–85.
20. Rang M, Douglas G, Bennet GC, Koreska J. Seating for children with cerebral palsy. *J Pediatr Orthop* 1981;1:279–87.
21. Colbert AP, Doyle KM, Webb WE. DESEMO seats for young children with cerebral palsy. *Arch Phys Med Rehabil* 1986;67:484–6.
22. Treffler E, Hanks S, Huggins P, Chiarizzo S, Hobson D. A modular seating system for cerebral-palsied children. *Dev Med Child Neurol* 1978;20:199–204.

23. Treffler E, Angelo J. Comparison of anterior trunk supports for children with cerebral palsy. *Assist Technol* 1997;9:15–21.
24. McPherson JJ, Schild R, Spaulding SJ, Barsamian P, Transon C, White SC. Analysis of upper extremity movement in four sitting positions: a comparison of persons with and without cerebral palsy. *Am J Occup Ther* 1991;45:123–9.
25. Nwaobi OM. Effects of body orientation in space on tonic muscle activity of patients with cerebral palsy. *Dev Med Child Neurol* 1986;28:41–4.
26. Gibson DA, Albisser AM, Koreska J. Role of the wheelchair in the management of the muscular dystrophy patient. *Can Med Assoc J* 1975;113:964–6.
27. Stout JD, Bandy P, Feller N, Stroup KB, Bull MJ. Transportation resources for pediatric orthopaedic clients. *Orthop Nurs* 1992;11:26–30.
28. Paley K, Walker JL, Cromwell F, Enlow C. Transportation of children with special seating needs. *South Med J* 1993;86:1339–41.
29. Cristarella MC. Comparison of straddling and sitting apparatus for the spastic cerebral-palsied child. *Am J Occup Ther* 1975;29:273–6.
30. Levangie PK, Guihan MF, Meyer P, Stuhr K. Effect of altering handle position of a rolling walker on gait in children with cerebral palsy. *Phys Ther* 1989;69:130–4.
31. Holm VA, Harthun-Smith L, Tada WL. Infant walkers and cerebral palsy. *Am J Dis Child* 1983;137:1189–90.

Gait

Treatment of the motor effects on ambulatory ability are the most common musculoskeletal problems that the orthopaedist has to address when treating children with cerebral palsy (CP). There are only a minority of patients whose motor function is so limited that ambulation is of no concern. From children with the most mild effects of hemiplegia to children with quadriplegia who are just able to do standing transfers, lower extremity function for mobility is usually a major concern of parents. The first task in the orthopaedic treatment plan is to individually identify how significant the gait impairment is to a child's whole disability. The second task is to determine if treatment of the impairment is likely to improve this child's function. The final goal is to explain the treatment plan to the parents and children and to inform them of the specific functional gains that can be expected and the associated risks. Normal human gait is one of the most complex functions of the human body, and gait is clearly the most complex impairment treated by pediatric orthopaedists. To understand and develop a specific treatment plan for children with gait impairments due to CP, orthopaedists have to have a good understanding of normal gait, understand measurement techniques used to evaluate gait, and be able to evaluate pathologic gait.

This discussion starts with an overview description of the basic scientific concepts required to understand gait. This basic science background is crucial to understanding normal gait and is even more important to understanding the pathologic gait of children with CP. The goal of this text is not to provide a comprehensive review of all the basic science of gait. For individuals who have had limited exposure to the scientific understanding of human gait, more detailed texts with much more information are available. To understand normal gait, the textbook *Gait Analysis*, written by Jacquelin Perry, is strongly recommended.¹ For a better mathematical understanding, the text *Human Motion Analysis*, edited by Harris and Smith, is recommended.² *Gait Analysis in Cerebral Palsy*, written by James Gage, is directed more specifically at the treatment of CP.³

Basic Science

The basic science of gait involves neuromotor control; global mechanics of the musculoskeletal system; and the mechanics and physiology of the structural subsystems including connective tissue, muscles, and bones. The basic concepts of motor control are discussed in Chapter 4 on motor control and tone. The concepts from that section, which will be used to understand motor control of gait, focus predominantly on the theory of dynamic motor

control, in which the system may express some level of fuzzy control but is drawn to chaotic attractors of differing strengths. This discussion will also use the underlying assumption that there is a central program generator with a combination of feed-forward and feedback control. A basic assumption of gait treatment includes the concept that little can be done to selectively influence the central program generator, although providing an improved biomechanical environment should allow the central program generator to provide the best possible control of gait. Another assumption is that most of the primary pathology in gait abnormalities in CP is located in the central program generator, and because it cannot be affected directly, the outcome of gait treatment is not expected to be a normal gait pattern. Therefore, the defined goal is always to improve the gait pattern functionally toward normal. With these underlying assumptions, the mechanics of how this central program generator's directives become the physical motion of walking will be examined.

Biomechanics

To understand a discussion of biomechanics, a clear and concise understanding of the terms has to be present (Table 7.1). Motion or movement, can mean either physical translation of a person or a segment of a person through space. Motion is also used to define angular rotation around a point. Temporal spatial measurements are related to movement of the whole person and include velocity, which is the amount of motion per unit time, usually defined in centimeters per second (cm/s). Temporal spatial measurements also separate elements of whole-body movement by the phase of gait defined by global mechanics. Angular motion around the individual joints is defined as kinematic measures. Usually, these measures are plotted as degrees of joint motion in clinically defined joint planes, such as degrees of flexion. The first derivative with respect to time of angular rotation per unit time is joint velocity, the second derivative is joint acceleration, and the third derivative is joint jerk.

The forces and their characterizations involved with gait are called kinetic measures. The kinetic measures include the force measured in newtons (N). The weight of an object measured in kilograms (kg) is similar to mass measured in newtons (N) as defined by Newton's second law. This definition states that a given external force (F) is required to move a given mass (m) at a specific acceleration (a) ($F = ma$). Gravity, which is the attraction of two bodies toward each other, is a force we call weight, which has an important impact on human movement. Force is also generated by chemical reactions in muscle and may be absorbed by a chemical reaction of muscle and the elastic action of soft tissues and bone. To change the state of a mass from rest to motion, a force has to be applied to satisfy Newton's second law. In mechanics, this means there is a force that causes a predictable reaction of an acceleration for a given mass. Constant velocity does not require a force, except to overcome friction and other negative forces acting on the body. The application of force over a distance is defined as work and is usually measured in joules. The capacity to perform work is called energy. The capacity of a moving body to perform work is called kinetic energy, which is released when there is a drop in the velocity. An example is a 1-kg weight lifted 1 m, and then allowed to drop; gravity will produce work through the acceleration and kinetic energy will be released when the object strikes the ground. This principle of force being applied over a distance is used to define the angular motion that occurs at joints as well. With angular motion, a force

Table 7.1. Description of biomechanical terms.

Term	Description
Temporal spatial characteristics:	Changes in the body or body segments related to the gait cycle.
Gait velocity:	Change in distance per unit time of the whole body during gait.
Step:	The gait cycle of one limb; the distance one foot moves with each gait cycle.
Cadence:	The number of gait cycles per unit time.
Stride:	Gait cycle of the whole body that equals two steps.
Stance phase (support time):	The time as a percent of time the foot is in contact with the floor during one step cycle.
Swing phase:	The time as a percent of time the foot is <i>not</i> in contact with the floor during one step cycle, or if there is toe drag, the time when the foot starts to move forward.
Initial double support:	Starting at heel strike or foot contact, time until the opposite limb starts swing phase.
Second double support:	Starting at heel strike or foot contact on the opposite limb, time until the index limb starts swing phase. Each step has two double supports; however, each stride also has only two double supports.
Step width:	The distance in the transverse plane of how far the feet are separated during double support.
Kinematics:	Measurement of the displacement of the body segments during gait, usually defined as angular change of the distal segment relative to its proximal articulated segment, or motion relative to a global coordinate system.
Joint velocity:	Amount of joint motion per unit time.
Joint acceleration:	Change in the velocity per unit time.
Joint jerk:	Change in the acceleration per unit time.
Kinetics:	Measurement of the forces acting upon the body segments.
Joint moments (torque):	Force applied at a defined distance from a point that generates rotation motion if it is not opposed (force times distance).
Joint force (joint reaction force):	The force a joint experiences defined in three planes and three moments.
Joint power:	Net joint moment times the joint's angular velocity.
Normalized kinetics:	Dividing the kinetic measure by the body weight in kilograms to obtain a number that can be compared over growth and to different-sized individuals.

of a specific magnitude is applied at a distance from the center of the angular motion, and is called a moment or torque. Unless an equal and opposite moment is applied, a joint motion occurs. This distance from the center of the joint motion to the application of the force is called the moment arm. Joint power is the application of the moment over a specific distance per unit time, which is defined in units called watts. Angular joint power is defined as being positive when motion, which is produced by concentric or shortening contractions of muscle, occurs. Angular joint power is negative when the motion is being controlled by an eccentric or a lengthening contraction. Absorption of power is the typical term used instead of negative power.

The term strength is very confusing as it is used in clinical care related to muscles. Often, strength is used in some combination to mean how much force a muscle can apply, how much work it can do, or how much angular power it can generate. All these definitions of strength are very confusing in

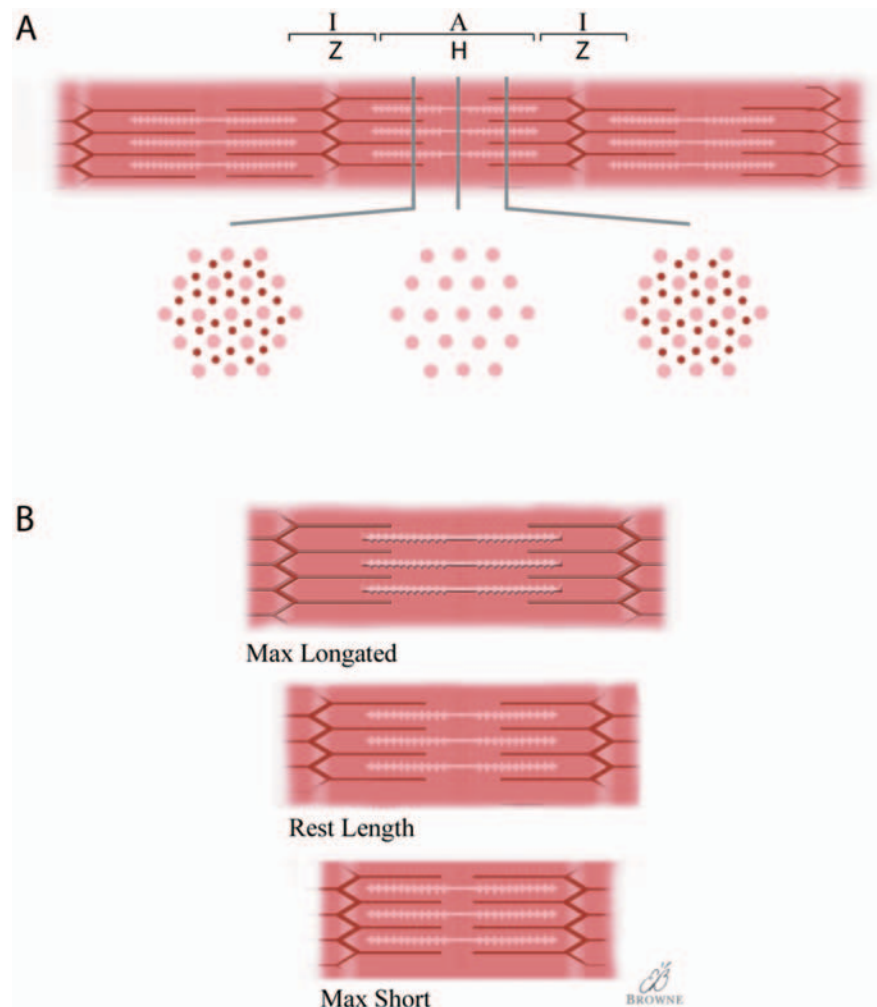
the clinical literature. For the remainder of this discussion, the term strength is to be used unless it is used to mean force unrelated to any time or distance parameters. The best way to use strength is to define the total limit of stress (force per unit area) or strain (length change per unit length) in a specific given environment. For example, it would be technically correct to say that a board of the same size and shape is stronger if it is made of steel rather than wood. Application of these mechanical concepts of understanding the function of the mechanical subsystems will be important to combine all parts into a functional, whole musculoskeletal system.

Muscle Mechanics

Energy Production

Based on the understanding of Newtonian physics, a change in movement state cannot occur unless there is an output of energy. In the human body, this output of energy occurs through the muscles, which are constructed of small subunits called sarcomeres (Figure 7.1). Sarcomeres have actin and myosin subunits that form chemical bonds, causing the actin and myosin subunits to overlap when they are stimulated by electrical depolarization produced by the motor neuron. The chemical energy needed for this shortening action of the sarcomere may be produced by aerobic metabolism, where

Figure 7.1. The microanatomy of the muscle fiber starts with sarcomeres, which are the building blocks of the muscle fibers. The sarcomeres are made of thin actin molecules that slide over the thicker myosin. With maximum elongation, there is only a small area of overlap. At rest, the fibers have approximately 50% overlap, and at full contraction, there is complete overlap. The chemical reaction causing this overlapping of the actin and myosin is the force-generating mechanism of muscle. In cross section, the fibers are stacked to provide a maximum number of contacts of the actin to the myosin fibers.



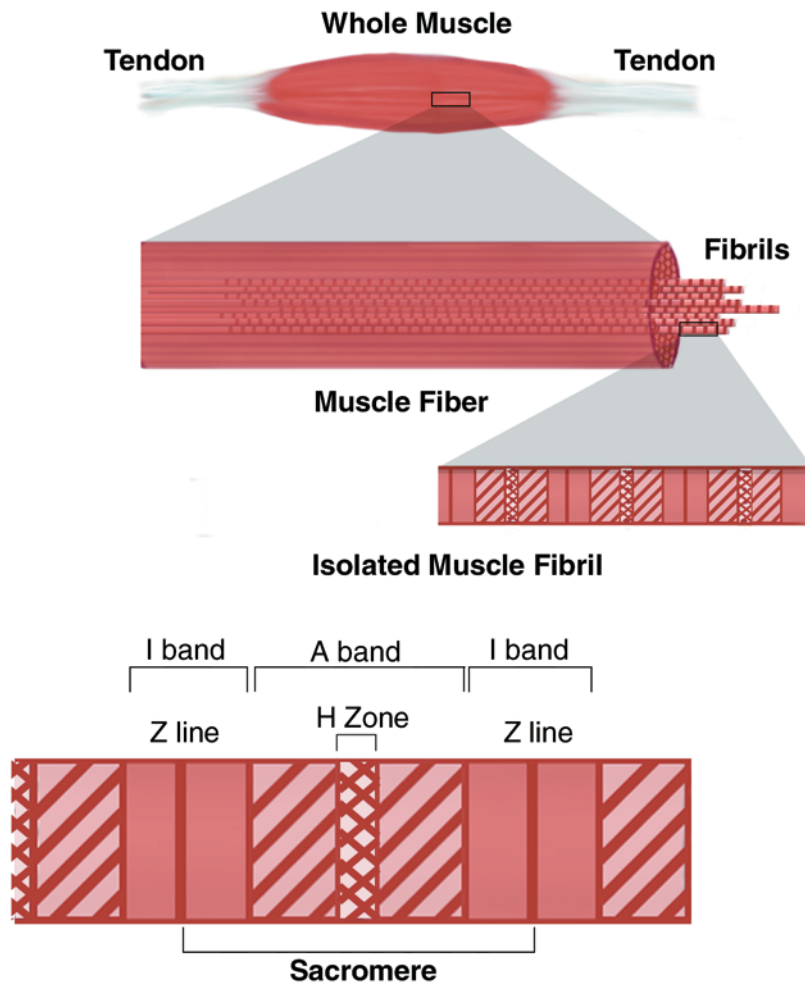
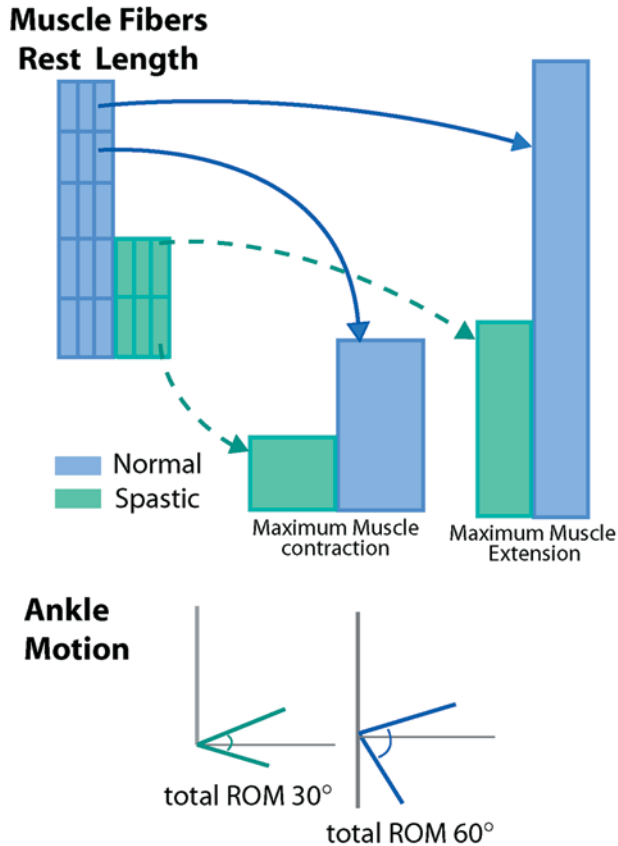


Figure 7.2. The sarcomeres are then combined end to end to form myofibrils, which are combined parallel to each other to form muscle fibers. Many muscle fibers are then combined into a single muscle attached at each end to a tendon.

oxygen is consumed through glycolysis of glucose in which adenosine triphosphate (ATP), carbon dioxide, and water are produced. Alternatively, energy can be produced by anaerobic metabolism using glycolysis of glucose in which ATP and lactic acid are generated as by-products. Another mechanism allows the enzymatic breakdown of phosphocreatine with the production of ATP and creatine. The chemical directly used by the sarcomere is ATP, which binds to the myosin and provides the energy for the cross-bridging to actin. The chemical details of sarcomere function and the energy production are well understood from a biochemical perspective; however, this energy production process is seldom a basic problem for children with CP. Sarcomeres are then combined into muscle fibers; the specific diameter of the fiber is determined by how many sarcomeres are placed together in the transverse plane (Figure 7.2). The diameter of muscle fibers varies from approximately 20 micrometers (μm) in hand intrinsic muscles to 55 μm in leg muscles.¹ The length of the fiber is the length of the muscle. Many muscle fibers are combined into one motor unit, which is controlled by a single motor neuron. The number of muscle fibers per motor neuron varies from approximately 100 in hand-intrinsic muscles to 600 in the gastrocnemius muscle. Thus, a hand-intrinsic muscle may contain approximately 100 motor units and the gastrocnemius contains approximately 1800 motor units.¹ Each motor unit is controlled by one motor neuron. The muscle fibers in each individual motor unit are dispersed throughout the whole body of the muscle.⁴ Each motor

Figure 7.3. The length of the muscle fiber is determined by the number of sarcomeres placed end to end. This muscle fiber length determines the muscle excursion length and therefore the active range of motion of the joint. For example, if the gastrocnemius usually produces 60° of active ankle joint range of motion, and the muscle loses 50% of its fiber length, it can generate only 30° of active ankle range of motion.



unit has only one mechanism of action, which is either contraction or no activity. The large number of motor units present mutes this all-or-nothing response in the whole muscle. Therefore, the level of muscle force that can be generated is based on how many motor units can contract simultaneously.

Force Production

The amount of force that a muscle can generate is based on the cross-sectional area of the muscle; however, the amount of work and power a muscle can generate is based on the total mass of the muscle. Adding sarcomeres side to side and expanding the diameter of the muscle fiber builds up the cross-sectional area, thereby increasing the force-generating ability of the muscle. However, by adding sarcomeres end to end, the total excursion of the muscle fiber increases so the force can be applied over a longer distance. Another way to understand this is a muscle with a longer muscle fiber allows greater joint range of motion (Figure 7.3). At the next level of the micro-anatomy, the addition of more muscle fibers to the whole muscle adds to the force-generating capacity of the muscle because it increases the cross-sectional area. However, this increased cross-sectional area does not increase the excursions length of the muscle or the joint range of motion through which the muscle can function. Selective control is improved by reducing the number of muscle fibers per motor unit. In normal individuals, the difference between 100 fibers per motor unit in the hand-intrinsic muscles compared with 600 fibers in the gastrocnemius demonstrates why there is much better fine motor control of the hand intrinsic muscles than of the gastrocnemius muscle. Many things affect muscle fiber size in both length and cross section. These complex effects are magnified during the growth years.

Fiber Types

Another aspect of muscle physiology is the presence of different muscle fiber types. The fiber types are defined by histochemical staining. Type 1 fibers are slow twitch, with a high capacity for oxidative metabolism. Type 2 muscles are divided into two subtypes, types 2a and 2b. Type 2a also has a high capacity for oxidative metabolism and type 2b is primarily anaerobic metabolism. Type 1 fibers are slow twitch and type 2 fibers have a faster twitch response.⁴ Fiber types 1 and 2a are more fatigue resistant than type 2b fibers. In other words, aerobic metabolism provides for better endurance, but anaerobic metabolism provides for better short bursts of high force with fast fatiguing, although not all the data support a clear distinction in fatigue ability between the histochemically defined fiber types.⁵ The strength or ability to generate force is not significantly different between the fiber types.⁶ Each motor unit is made up of similar fiber types.⁶ The slow-twitch oxidative type 1 muscle fibers are ideal for submaximal force generation required over long periods of time. Type 2 fibers are ideal where high bursts with maximal contraction are required for short periods of time. For example, long-distance runners have increased type 1 fibers and weight lifters have increased type 2 fibers.

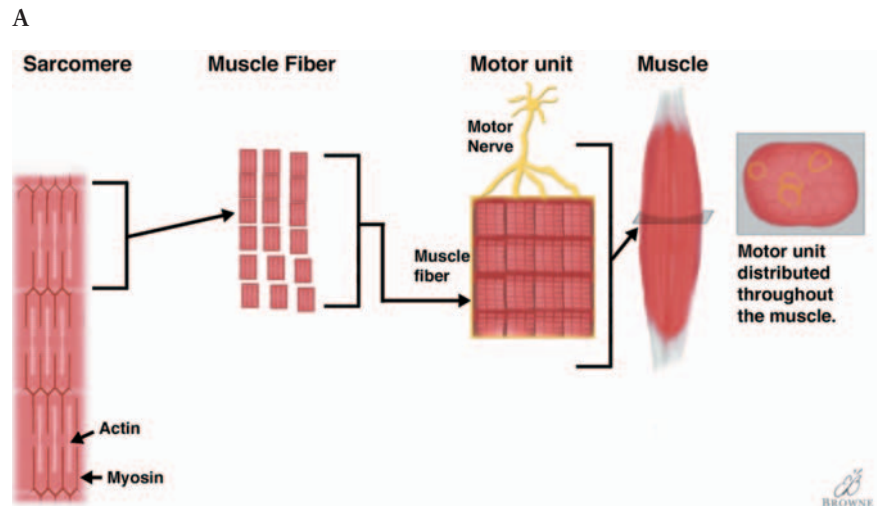
Muscle Anatomy

All the muscle fibers are combined into motor units, which are structured to make whole single muscle units. The individual muscle fibers can be anatomically combined to make an individual muscle with varying degrees of fiber orientation. The fibers may be oriented with a pennation angle relative to the tendon, or the fibers may be aligned straight with the line of action of the tendon (Figure 7.4). An example of a bipennate orientation is the deltoid muscle or gluteus muscle. A unipennate structure is most common in other muscles of the lower extremity. The pennation angle is another way in which the force is increased, but it works over a shorter distance. For a few muscles, the pennation angle is important in considering the amount of muscle force generation, but for most muscles that cause problems in children with CP, there is no need to worry about the pennation angle because it is small and has relatively little effect. The muscle can generate force while it shortens, while it lengthens, or while its length is static. The mechanism of force generation is the same for all situations and involves an all-or-none response by many motor units within the muscle. However, for example, if the same 100 motor units contract, the amount of energy required is very different depending on the effect in the muscle. A concentric contraction, in which the muscle is shortening and doing positive work, has the highest energy demand. Eccentric contraction, in which the muscle is lengthening and doing negative work or absorbing power, requires three to nine times less energy than a concentric contraction. Isometric contraction uses an intermediate amount of energy.³ As a general rule, muscles that do the work of moving have to produce angular joint acceleration and do active work by concentric contraction. Muscles that decelerate, or act as shock absorbers or transfer energy, are eccentric acting muscles in which power is absorbed. Isometric muscle contraction predominantly works to stabilize a joint or to help with postural stability.

Muscle Length–Tension Relationship (Blix Curve)

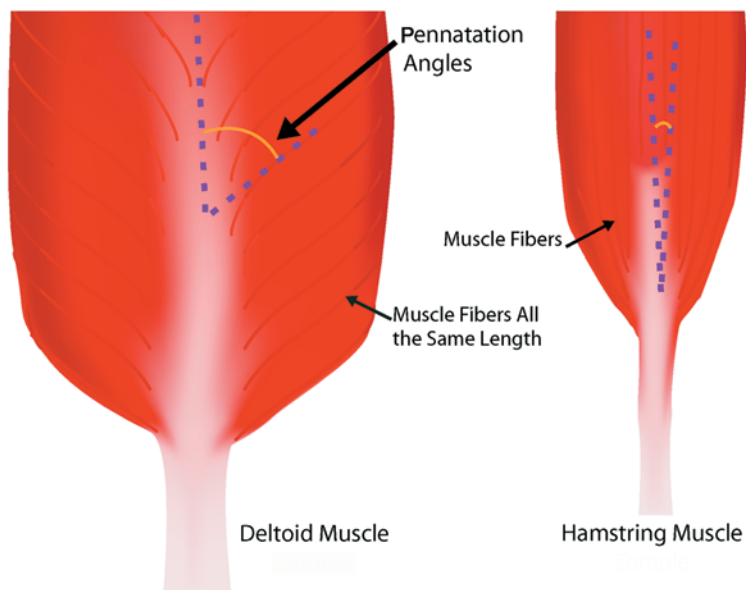
Another important aspect of a muscle's ability to generate force is the length position in which the muscle fiber is stimulated relative to its resting length.

Figure 7.4. The arrangement of the muscle fibers in the muscle is another variable in determining the excursion length of the muscle and the amount of force the muscle can generate at the joint level (A). The angle at which the muscle fiber inserts into the tendon is called the pennation angle, which can be very high for a muscle such as the deltoid. For most muscles of ambulation that have long muscle fibers, the pennation angle is so small that it has little impact on the force generated (B).



B

Muscle Fiber Orientation



Thus, when a muscle is at resting length, the actin and myosin are in the relaxed position with slight overlap, and in this position, the muscle can generate its maximum force. If the muscle is distracted so that the sarcomeric subunits have less overlap, the muscle strength will decrease. Also, if the muscle is at an increased shortened position, it will use maximum force-generating ability because of too much overlap at the sarcomere level. This phenomenon has been defined by the Blix curve, or the muscle length–tension curve, and has been presented in many textbooks as a key mechanism to understand a muscle’s response in generating force (Figure 7.5). An understanding of a muscle’s length relative to the Blix curve is especially important when planning muscle-lengthening procedures. Although less clearly

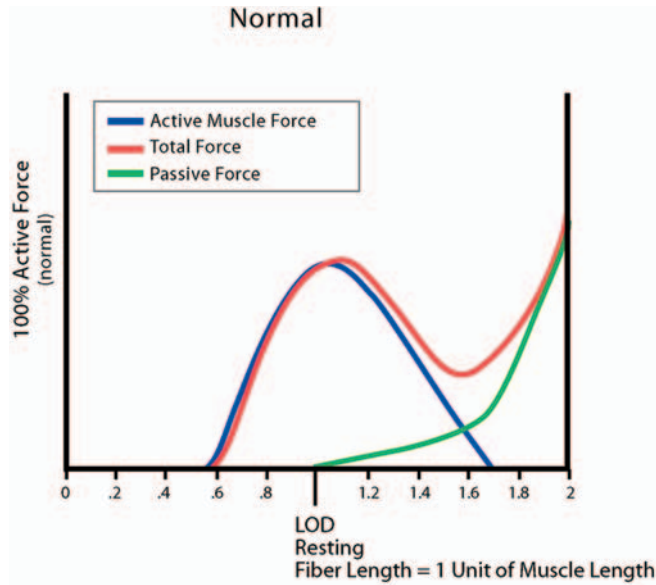


Figure 7.5. The muscle fiber length–tension curve (Blix curve) is crucial to understanding the muscle force-generating ability. At rest length the muscle has the ability to generate the highest amount of active force. As the muscle shortens, this ability to generate force decreases to zero at approximately 60% of rest length. As the muscle lengthens, the active force-generating ability also decreases and reaches zero at approximately 170% of rest length. However, as the muscle lengthens, the passive collagen elements provide a passive restraint to further lengthening, thereby increasing tension as the muscle is lengthened. This increases until approximately 200% of rest length, when the muscle starts to physically fail.

defined, increased resting tone in a muscle will also increase the amount of force the muscle can generate when it is stimulated.⁷

The biomechanical response that the muscles in children with CP develop affects the force-generating ability. This force-generating ability is altered by changes in muscle fiber size, fiber pennation angles, length of the fiber relative to its resting length, and the cross-sectional size of the whole muscle.⁸ The longitudinal excursion of a muscle depends primarily on the length and the pennation angle of the muscle fibers. Endurance or fatigability of a muscle depends on the muscle fiber type, especially its primary metabolic function, which is either oxidative or anaerobic, and the muscle fiber's velocity of contraction, meaning specifically whether it is concentric, eccentric, or isometric. A muscle's selective control is altered mainly at the muscle level by the size of motor units. This means that an individual muscle has less selective control when its motor units increase in size, such as expanding from 500 to 800 fibers per motor unit. The amount of angular joint force produced by a given muscle is further defined by the mechanical anatomy, such as the course of the tendon, the moment arm length from the center of motion to the tendon insertion, and the angular velocity of the motion.

Alteration of Muscle Mechanics

Normal mechanics of a muscle unit change over time under the influence of many factors. Areas that are of specific concern in the treatment of children with CP are the influence of growth and development, the impact of muscle tone change, and the impact of stretching and strengthening stimuli.

Muscle Control

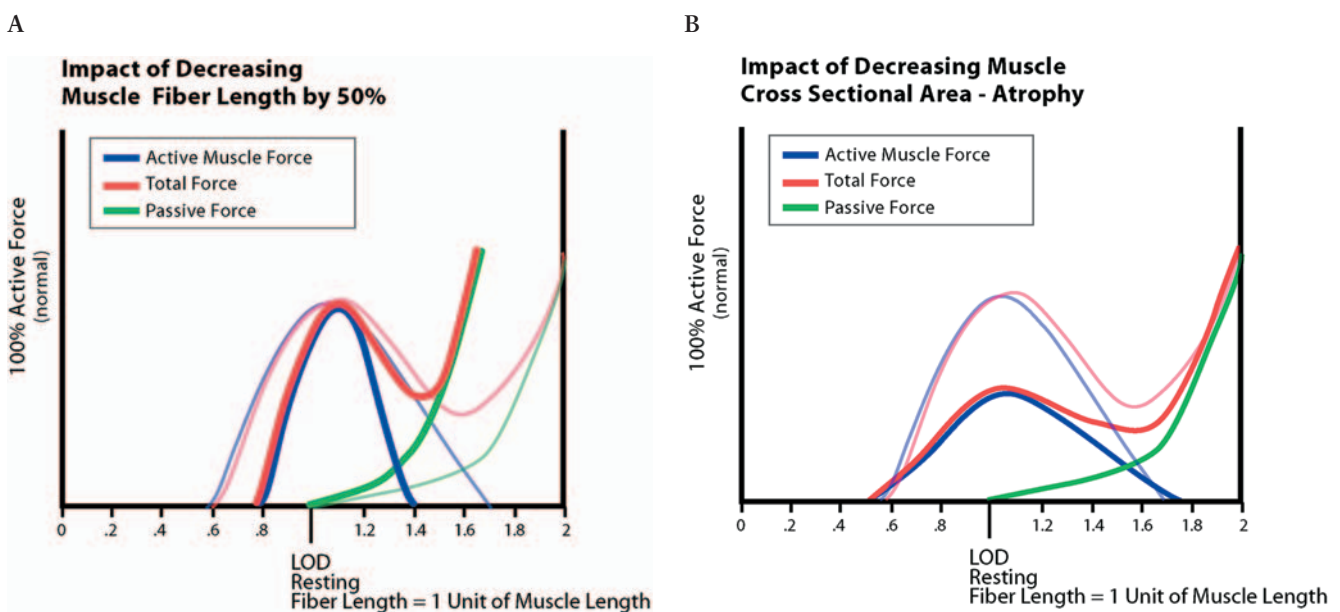
Each group of motor units is controlled by one motor neuron that can only contract or not be active. Variable control of muscle contraction is gained by how many motor units are contracting in concert. In normal individuals, each gastrocnemius has approximately 1800 motor units; therefore, the brain, via the central program generator, has a choice of how many motor units to fire at a specific time.¹ If the central program generator is damaged, it cannot handle as many input and output choices. The number of motor units can

Figure 7.6. Muscle shortening seen in children with spastic CP leads to the frequently observed decreased joint range of motion. This shortening of the muscle fiber also leads to significant changes in the length-tension response of the muscle. The impact of decreasing the muscle fiber length is seen to cause a great narrowing of the length-tension curve, meaning that the muscle can generate effect force over a much shorter range as well. This change concentrates the muscle force-generating ability into a very narrow range of joint motion (A). In addition, many children have decreased muscle diameters, causing muscle weakness defined as having a decreased ability to generate maximum force. This atrophy or weakness causes the peak tension of the length-tension curve to be decreased (B).

be decreased, but the muscle stays the same size if the muscle fibers are enlarged and the number of fibers per motor neuron is increased. The central program generator also has to consider any change in fiber types, from fast twitch to slow twitch, as to the muscle's impact on activation of a specific motor unit. These fiber types are determined through motor neuron interaction.³ The strength generated by each fiber is about the same.⁶ It is not clear how this feedback occurs or what the factors are that cause the motor neuron to switch fiber types; however, there is documentation suggesting that in spastic muscles there is also a decrease in the number of mechanoreceptors within the muscles.⁹ It is clear in children with CP and spasticity that there is reorganization with an increase of type 1 muscle fibers and a decrease in type 2 muscle fibers.^{10, 11} There is an especially large loss of type 2b fibers, which are the anaerobic metabolism fibers. Therefore, the muscles in children with spasticity organize toward slower-twitch, fatigue-resistant fibers, which are organized into larger motor units having fewer mechanoreceptors. All these motor units add together to form a situation with fewer variables that the central program generator needs to control. Although the physiologic drivers for these changes are not well defined, this change of fewer variables and fewer inputs is very sensible in the context of dynamic motor control. There is no evidence that any of these changes can be reversed in children with CP because the real problem resides in the central program generator, which probably cannot be impacted. The primary pathology is in the central program generator; therefore, there is less control available, so secondary muscle alterations are of primary benefit to children's overall function.

Muscle Force-Generating Capacity

In young children, the cross section of the muscles is much larger compared with their body size than in adults. For example, a 2- to 3-year-old child who is 90 cm tall may have a gastrocnemius with a radius that is approximately one half of what it will be at maturity when he is 180 cm tall (Figure 7.6). At age 2 years, this child may have a radius of 2 cm in his gastrocnemius for a cross section of the gastrocnemius of approximately 12 cm². By maturity, the radius will double and he will have a cross-sectional area of approximately 50 cm². The muscle can generate 2 kg tension force per square centi-



meter. Therefore, the 90-cm-tall boy weighing 12 kg generates 25 kg of force in his gastrocnemius, whereas by adulthood he will generate only 100 kg of force for a 70-kg weight. This means the power of his gastrocnemius will drop from more than 200% of body weight to 140% of body weight. This percent drop also demonstrates the importance of avoiding severe obesity because this same individual will only generate the same amount of gastrocnemius force if he weighs 70 kg or 100 kg; this has significant implications when comparing toe walking in a 3- or 4-year-old with toe walking in an adult-sized individual. This force discrepancy is one reason why adults are not long-distance toe walkers in the same way many younger children are. As children grow, the cross-sectional area of their calves grow at approximately the same rate as height, and the area of muscle is defined by the radius. However, weight is defined by the expansion in length and width, which mathematically means it is the cube of expansion. Therefore, most young children generate high force for their weight, and as they grow older and heavier, their force-generating strength-to-weight ratio gradually decreases. Here, muscle strength is defined as the force-generating ability of a muscle, which is also impacted by repeated heavy loading. As a muscle experiences load, it increases the cross-sectional area of the muscle fibers as the primary mechanism of increasing muscle diameter. If a muscle is not used, the diameter of the muscle decreases as it thins the muscle fiber. This change implies that the body wants to avoid carrying extra muscle mass that is not needed. Therefore, muscle strength is increased with resistive weight training in which work and power are expended, although isometric contractions also increase muscle girth.

Children with CP are generally weaker, specifically meaning they have an inability to generate tension in the muscle.¹² The cause of this weakness is multifactorial; however, the lack of repeated maximal loading from play and activities of daily living is one significant factor. The inability of the neurologic system to cause coordinated contraction of all motor units in the same muscle may be another reason. As these children grow and the effect of increased mass becomes more problematic, there is a major boost in muscle mass and cross-sectional area development with the onset of puberty. Only at this time is there a measurable difference in the strength of the muscle. The growth hormones and androgens stimulate this development, which occurs at some level in nonambulatory children as well. The impact of testosterone is more dramatic than estrogen; therefore, males have larger and stronger muscles. Muscle-strengthening exercises as a treatment of muscle weakness, which is present in almost all children with CP, have traditionally been contraindicated because the effects of spasticity might be worse. This theory is clearly false and is related in part to misunderstanding strength. The strength of a contraction of a muscle or joint defined as the ability to move the joint against resistance during a physical examination has little relationship to the active force generated by an isolated contraction of a specific muscle. Recent work by Damiano and associates has shown that it is possible to do weight resistive training with children with CP, and also that there is a measurable increase in muscle force-generating ability with no recognizable side effects.^{13, 14} Therefore, children who have functional deficits related to strength have no contraindication to strength training with resistive exercise. Some functional gain may develop, which is true especially for situations such as following surgery or casting where children have developed disuse atrophy.

Muscle Excursion

Muscle excursion is the difference between the maximum shortening and maximum lengthening of a muscle. The midpoint is called the rest length.

Muscle excursion is directly related to the available joint range of motion. As a muscle's physical length shortens, the associated joint loses range of motion. Also, as children grow, muscle length has to keep up with the increasing length of bone for it to continue to generate the correct amount of force. There is no known condition in which a muscle grows too long. The problem in CP is that muscles do not grow enough. As a consequence, the associated joints lose range of motion, which is called a muscle contracture. Contracture is a poor word because it leaves the impression that a muscle has somehow pulled into itself such that it could be pulled out of its contracted position. This concept is wrong, and what the term really means is that the muscle fibers are too short and have a decreased level of excursion. The stimulus for in vivo growth of muscle is poorly defined, but it is some combination of stretching to the maximum over a frequency or time period. This stimulus is almost exclusively a mechanical factor that is altered by an increase in muscle tone. The increase in muscle tone probably prevents children from stretching the muscle in a relaxed state during activities such as position changes in bed during sleep. If a joint is immobilized, the muscle will shorten, but it will lengthen again after release of joint immobility if the joint has a good range of motion. The length growth of a muscle occurs by muscle fibers adding sarcomeres at the muscle-tendon junction, very similar to the growth plate in bone.^{15, 16} A muscle can also shorten by removing sarcomeres in this growth plate area, a trick the bone growth plate has not learned.

Increasing Excursion

The clinical treatment of shortened muscles known as contractures has traditionally focused on stretching range-of-motion exercises done with passive and active stretching. There is no doubt that children with no ability to do self-movement need to have their joints moved and these muscles stretched. For ambulatory children who are active ambulators and are growing fast, the goal of trying to avoid the muscles getting shorter and shorter by stimulating muscle growth through stretching is reasonable; however, the objective data to support the efficacy of this are minimal. Based on our examination of children in patterning therapy where they receive many hours of passive range-of-motion exercises, we believe it is possible to make muscles grow. However, the amount of passive range-of-motion stretching required is so disruptive to the lives of families and the other activities of these children that muscle contractures are far less disabling than the therapy to prevent the contractures. Stretching is like many exercise programs done for general health, meaning a little is better than none; however, there is an amount that makes a significant difference. We do not know how much stretching in the relaxed position is required; however, it is probably in the range of 4 to 8 hours per day.

Other treatments to make muscles grow are poorly documented. There are reports in the literature that claim that muscle growth occurred based on increased range of motion after Botox injections¹⁷; however, others, with careful assessment, have not found this to be the case.^{18, 19} Muscles in spastic mice have been demonstrated to lose half their length as the spastic limbs grew.¹⁶ Static stretch in a brace or a cast probably has some effect; however, this is not well documented. In an unpublished study, we tried to stretch hamstring muscles in children with the use of knee immobilizer splints. A splint was used every night on one leg but not the other. There was a measurable improvement in the popliteal angle, suggesting increased length in the muscle. However, the major problem was that only 30% of the children could follow through a 12-week wearing time on one leg only, which suggests that nighttime splinting does not have good acceptance with families or children.

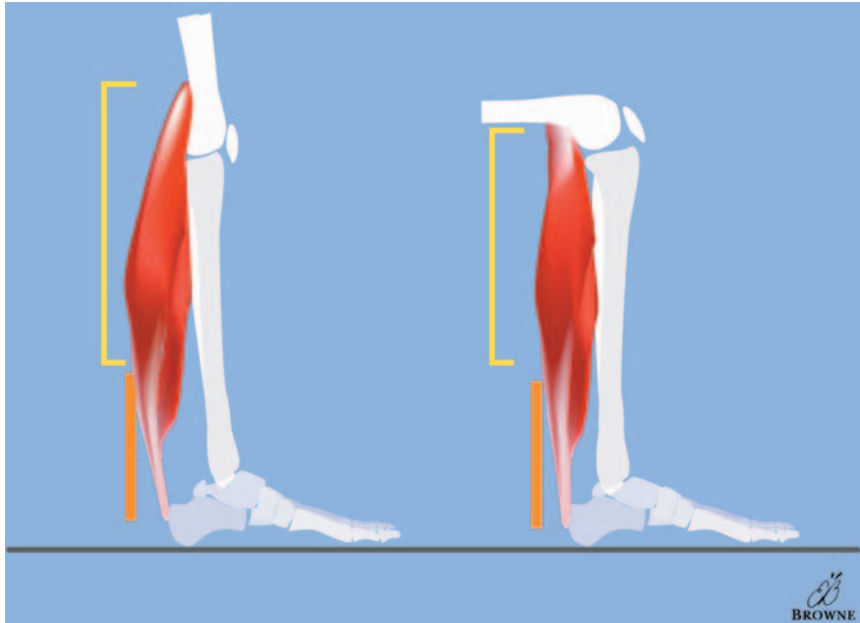


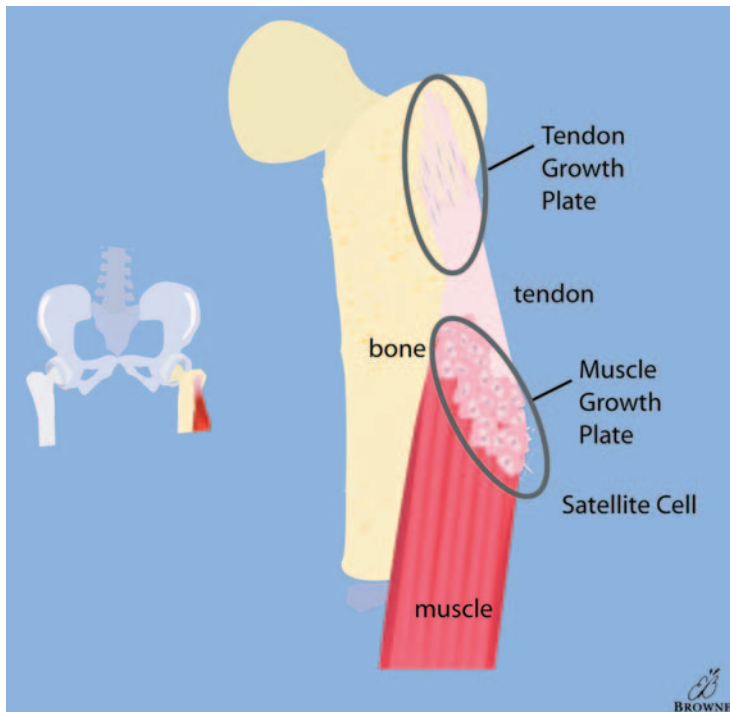
Figure 7.7. When the goal is to stretch the gastrocnemius, it is very important to realize that this cannot be done without also keeping the knee extended. This means nighttime ankle bracing without bracing the knee into extension is worse than not bracing because it only stretches the soleus, which is usually not contracted, and allows the gastrocnemius to further contract because the child will sleep with severe knee flexion.

Also, the splinting has to stretch the muscles. Many therapists believe children should wear ankle-foot orthotics (AFO) at night to stretch the contracted gastrocnemius. However, if only AFOs are used, children will flex the knee and only the soleus gets stretched, further increasing the length difference many children already have between the gastrocnemius and soleus muscles (Figure 7.7). Stretching the gastrocnemius requires the use of a knee extension splint and a dorsiflexion splint, a combination that is bulky and adds to the poor acceptance. The use of casting adds other problems, especially muscle atrophy. One of the most efficient ways to shrink the size of a muscle is to rigidly immobilize the joint in a cast so the muscle has no motion possible. No documentation is available to show that a muscle grows longer if immobilized under tension in a cast; however, based on knowledge of how muscle grows, it probably does grow longer in addition to developing severe atrophy. The severe atrophy and temporary nature of the clinical length gain make the use of casting for chronic management of short muscles in children with CP a poor choice. The major problem in the research of muscle growth is the difficulty of measuring muscle growth separate from tendon growth. The mechanical stimuli for growth of these two different anatomic structures, muscles and tendons, somewhat overlap and the effort to cause muscle growth probably causes tendon growth as well.

Connective Tissue Mechanics

Short muscles in CP are clinically well recognized; however, the problem of excessive length of the tendons is often not recognized. The high-riding patella is an exception. However, surgeons who operate on the tendons frequently see tendons that are much too long, as if these tendons were trying to make some adjustment for the very short muscles (Figure 7.8). Tendons grow by interstitial growth throughout, but most of the growth seems to occur at the tendon–bone interface.²⁰ Tendons also increase their cross-sectional area through growth, which increases the strength of the tendons. The stimulus for increased tendon growth and tendon cross-sectional area growth is not well defined, but depends heavily on the force environment. The regulation of length growth is heavily influenced by tension, but the

Figure 7.8. Tendons have a growth plate-like structure at the tendon–bone interface and at the muscle–tendon interface, this structure is a high concentration of satellite cells that contribute to muscle growth. In addition, the muscles and tendons also have some interstitial growth ability.



specific stimuli that cause growth are not well defined. Tendons contain mechanoreceptors called Golgi tendon organs, which give feedback to the brain and also influence the sensitivity of muscle spindles.²¹ This scenario suggests that tension on a tendon makes the motor neuron more sensitive to fire through its modulation by the muscle spindle. In the presence of spasticity with continuous low-level tension, this system may be altered to accommodate for chronic stimulation, possibly by the system dropping mechanoreceptors.⁹ Therefore, the stimulus for growth may also cause the response to decrease the number of mechanoreceptors so that the stimulation of a muscle is decreased.

Another connective tissue effect that has been long recognized and recently better quantified is the increase in connective tissue in the muscle in the presence of spasticity.²² This increase is responsible for the increase in the stiffness of the muscle and may also be related to decreased excursion. This process of increasing connective tissue seems to get worse with increasing magnitude of spasticity, increasing exposure time to spasticity, and increasing age of the patient. This is another component of what is defined as the contracture, but is the least understood element of this pathology. We know of no treatment to impact this process.

Growth of the Muscle–Tendon Unit

The current understanding of growth regulation of a muscle–tendon unit is that the muscle fibers grow in response to stretching of the sarcomeres while they are not actively firing. This stretch has to occur for some amount of time each day. The tendon grows in length by summation of the total tension over time. The specific pattern of maximum to minimum tension is unknown. Another factor that is important but not well understood is the influence of motion, which both muscles and tendons need to have for healthy growth. Defining the specific stimulus for growth of tendons compared with muscles would be a useful research project. These two structures balance themselves

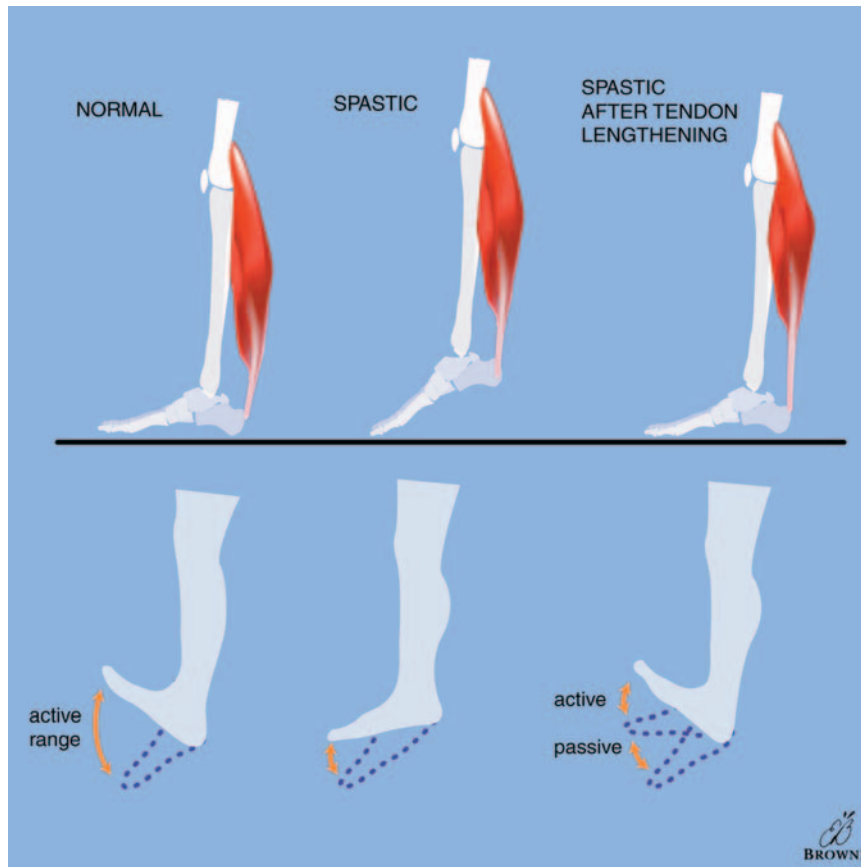


Figure 7.9. The length of the muscle fiber directly determines the active total joint range of motion; however, the muscle rest length plus tendon length defines where that active range of motion occurs. Therefore, if the active range of the ankle is from -20° of dorsiflexion to 60° of plantar flexion, there is no definitely known mechanism to lengthen the muscle fiber and create an active range of muscle activity from 30° of dorsiflexion to 60° of plantar flexion. However, by lengthening the Achilles tendon, we can move the 40° active range to 10° of dorsiflexion to 30° of plantar flexion, a much more useful position of the muscle's active range of motion. This is the principal function of tendon lengthening in short spastic muscles.

out as if one were trying to make up for the other's deficiency. The physical impact of a short muscle is to decrease joint range of motion. The physical impact of tendon length is to determine the anatomic range in which a muscle can apply its reduced range-of-motion activity. For example, a 50% decrease in the muscle fiber length of the gastrosoleus will reduce the available range of motion from 60° to 30° . The length of the tendon then will determine if active range of motion occurs from -15° dorsiflexion to 45° plantar flexion or if the active range of motion will occur from 10° dorsiflexion to 20° of plantar flexion. The tendon length is the surgically approachable aspect of this problem (Figure 7.9). By lengthening the tendon, surgeons can choose where to place the active range of motion; however, there is no way of increasing the active range of motion, which would require increasing muscle fiber growth. Usually, if the tendon is found to be shorter than would be functionally ideal, the opposing tendon will be long. For example, with the short gastrosoleus, the tibialis anterior almost always has a tendon that is causing its active range of motion to also function in equinus. By lengthening the short tendon of the gastrocnemius, the too-long tibialis anterior tendon will spontaneously decrease its muscle fiber length and tendon length. Shortening tendons is seldom required, and except for a few upper extremity tendons, does not work well. This also means if surgeons do a little too much lengthening, the body will adjust the tension by altering the muscle fiber length and, to a lesser degree, the tendon length. This mechanism can function only if the muscle-tendon unit is intact, and it cannot function if the tendon is completely transected. If the tendon is transected and becomes thin from experiencing no force, the muscle will become severely atrophied with very short fibers.

The ideal goal of treatment in children with spastic CP would be to make muscles grow and tendons shrink. The muscles are normal, and as the bones grow, the muscles grow too, but not enough to keep up with bone growth. The tendons make up the difference. The strong flexor muscles usually develop relatively short tendons, which are still longer than normal, and the extensor muscles, which are short, develop excessively long tendons. The only treatment with confirmed efficacy is surgical lengthening of the relatively short tendons. Other treatments, such as passive range of motion, splinting, and Botox injections, may have short-term benefits that can delay the need for surgical lengthening.

Bone Mechanics

Bones are the strong, supportive structures that provide the structural frames on which all mobility depends. Ambulatory children have few problems with the strength of bones; however, this is a major concern for nonambulatory children. Osteopenia and osteoporosis are major problems and are largely related to decreased force experienced by the bones. These problems were discussed at length in the metabolic bone discussion. The stimulus for length growth occurring at the growth plates is the result of hormonal, genetic, and mechanical factors. The hormonal factors may be abnormal for children whose apophyseal pituitary axes were involved in their original CP lesions. This involvement primarily occurs in children who are nonambulatory; however, we have several patients who ambulate independently and were found to have growth hormone deficiency. Children's height should be routinely measured, and when they fall below the fifth percentile on the growth chart or have no growth over 1 year, referral for full endocrinologic evaluation is recommended. A much more frequent effect causing diminished growth in one leg is the decreased force exposure, which occurs in the involved limb of children with hemiplegia. The hemiplegic limb is usually 1 to 2 cm shorter by the conclusion of growth. If this difference is more than 2 cm, a leg equalization procedure may be needed.

Another area of force effects on bone is the prevention of infantile bone shape maturation into adult-shaped bone configurations. This bone maturation occurs through the influence of the muscle action, causing remodeling effects on the growing bone through Pauwel's law.²³ The lack of remodeling frequently leaves children with an infantile bone shape, such as increased femoral anteversion or tibial torsion. Although unclear, there are suggestions that in very young children, under age 5 years, abnormal forces can cause the bones to develop abnormal torsion.²⁴ Careful attention to correcting the abnormal forces in early childhood is especially important to prevent recurrence or a new deformity. However, there is no evidence to suggest that correcting these forces can cause correction of infantile torsional deformities.

Joint Mechanics

The joints require motion for normal development during childhood. The ligament and joint capsules, which provide stability to the joints, have interstitial growth throughout their entire length.²⁵ However, over time if there is no motion, the structures tighten and restrict joint range of motion. In children with CP, this occurs very slowly. For example, hamstring contractures, which prevent full knee extension, only very slowly allow the development of a fixed knee contracture; however, by adolescence and after puberty, this process occurs much faster. Also, these flexion contractures are much more amenable to stretching out in young children. During childhood growth, many

joints are very sensitive to abnormal joint reaction forces. These abnormal forces may cause substantial abnormalities in the development of the joints and, in some cases, lead to joint dislocation. Joint dislocation is a prominent problem at the hip and is a lesser problem in the other joints. The specific joint problems are addressed in the sections devoted to those joints. Children with spastic CP have a tendency to have short muscles, which translates into decreased joint range of motion. The decreased range of motion subsequently leads to fixed joint contractures, even when there are no structural joint deformities.

Joint Motor Mechanics

Often, the mechanics of a single joint are based on the specifics of the involved joint; however, the only active way to move a joint is by the muscle attached to that joint. These muscle–tendon units attach in the bone and work by creating a moment through a moment arm. An excellent example of this is the knee, where the hamstring muscles attach to the tibia by being posterior to the joint’s center of motion. A moment arm is created and a tension force is applied to create a moment that may cause motion. The moment created is called the strength of the hamstring in clinical scenarios (Figure 7.10). The amount of strength, or joint moment, that is created includes the percent of the muscle’s contraction, the cross-sectional area of the muscle, the position of the muscle fiber length on the Blix curve, the direction and velocity of the change in the muscle fiber, and the moment arm of the muscle. Another variable is muscle fiber configuration with the degree of pennation of the fibers to the line of action of the muscle. In the hamstring muscles, this variable is of no significance because of a very low pennation angle. Some of these variables can be actively altered, and others are structural variables. The variables that can be actively altered are the percent of muscle firing, the moment arm length, the position on the Blix curve, and the velocity of length change. The variables with the structural characteristics that can change over time are the diameter of the muscle through muscle

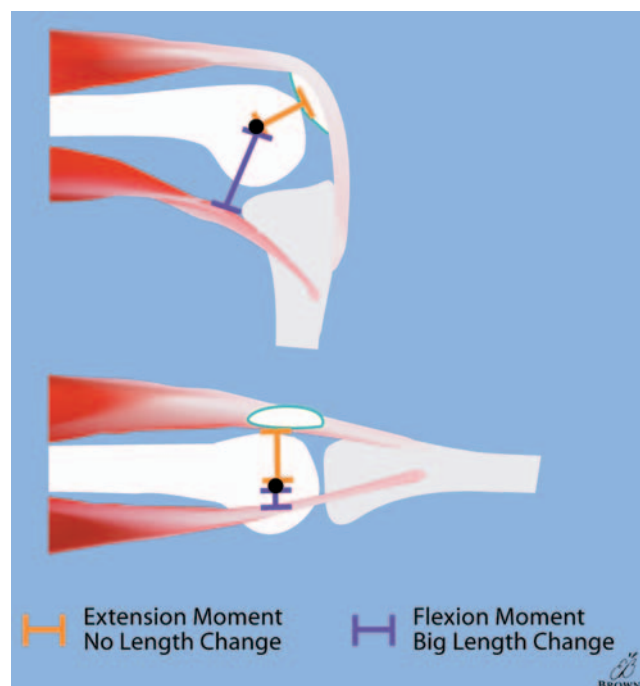


Figure 7.10. To understand the force-generating ability of the muscle, it is very important to understand the concept of stable versus changing moment arms. An example is the quadriceps, which has a relatively consistent moment arm length independent of the joint position. The hamstrings, on the other hand, have a moment arm that is very dependent on joint position with the moment arm being very short at knee extension and very long at full knee flexion. Thus, the impact of a hamstring contracture very quickly becomes more significant as the degree of knee flexion increases.

hypertrophy or growth, the position on the Blix curve by the addition or subtraction of sarcomeres, and the moment arm length by bone shape change and tendon length.

Single-Joint Muscles

From the perspective of the central program generator, muscle activation that crosses a single joint requires consideration of the impact of at least three variables, including the percent of motor units to activate, the current length of the fiber that will define the moment arm and the Blix curve location, and the velocity of muscle fiber shortening. The system also has to consider its longer-term organization caused by structural alterations. From the treatment perspective, the major alterations are made in the structural variable. A major element in the clinical assessment of children is trying to understand if these structural changes are positive to the function of the joint and the whole-body motor system or if this structural change is now part of the pathology of the impairment that is increasing the disability. The intellectual understanding of muscles that cross single joints, such as the short head of the biceps femoris, is relatively easy. The force generated is easily modeled, leading to a clear understanding of the effects; however, in children with CP, these single joint crossing muscles cause far fewer problems than the muscles that cross multiple joints.

Multiple-Joint Muscles

Multiple-joint muscles, such as the rectus femoris and the gastrocnemius, comprise most of the problematic muscles. With these muscles, it is extremely hard to conceptualize a clear understanding of an individual muscle's function at a specific time in the gait cycle of a child. For example, the long head of the biceps femoris crosses the hip and knee joints; therefore, the number of variables in the control algorithm more than doubles, because now the hip position and knee position have to be considered for each variable (Table 7.2). This complexity is relatively apparent, and it is easy to understand why control of these muscles is most problematic for the central program generators of children with CP. These multiple-joint muscles tend to function predominantly as energy transfer muscles and in deceleration; this means multiple-joint muscles are used predominantly in situations that require eccentric contraction. In approaching these muscles as a treating physician, an attempt needs to be made to understand as many of the variables in the control scenario as possible. However, dynamic control theory seems to work better to understand the process. The easy example of this is

Table 7.2. Factors that have to be controlled during a contraction of the semitendinosus compared with the vastus.

	Semitendinosus	Vastus
Active change	Eccentric or concentric or isometric Muscle fiber length Muscle tension Tendon length Moment arm at the knee that changes Position of the knee joint to determine moment arm Moment arm of the hip that moves Position of the hip joint to determine moment arm Position of the hip and knee to determine muscle fiber length Direction and velocity of hip and knee joint motion	Eccentric or concentric or isometric Muscle fiber length Muscle tension Tendon length Moment arm at the knee that is static Position of the knee joint only to determine muscle fiber length Direction and velocity of only knee joint motion
Long-term changes	Fiber types Muscle resting fiber length Size of the motor unit	Fiber types Muscle resting fiber length Size of the motor unit

the spastic rectus muscle, which may contract too long in the swing phase, causing knee stiffness and subsequent toe drag. Although this is the most common cause of toe drag in children with CP, there are many other variables in the cause of knee stiffness related to other abnormal contraction patterns and to the amount of power output to cause knee flexion. However, in clinical study, we see patients who have no problems with decreased or delayed knee flexion in swing phase, whereas other children who have almost the same examination and input data demonstrate a significant knee stiffness in swing phase with toe drag as a major complaint. This scenario suggests that there is a strong attractor to walk with enough knee flexion to be functional or, alternatively, fall into the stiff knee gait pattern. Although this pattern varies, it is unusual to see children in whom it is unclear if the pattern is present. If children have a stiff knee gait, it may be harder to decide if the problem should be treated, which basically means making a decision about how strong the attractor is to keep the stiff knee gait pattern of these children. Most muscle pathomechanics in the treatment of gait in children with CP involves trying to understand the complex interactions of these multiple-joint muscles.

Global Body Mechanics of Human Gait

Human walking is a complex interaction between the central nervous system and the peripheral musculoskeletal system. Understanding the combined function of the mechanical components of the musculoskeletal system in a way that produces functional gait requires an assessment of what the whole organism has to accomplish to be able to ambulate. For example, it is not enough to understand how the muscle generates tension and then translates it into joint power. This joint power has to occur in a well-orchestrated fashion. The elements of the whole body that are important in the production of functional gait require individuals to have the ability to conceptualize where they want to move. Individuals have to have sufficient energy available for mobility, their bodies have to be able to balance themselves, their central program generators have to be able to provide motor control, and their mechanical structures have to be stable to support the force output. The airplane can serve as an analogy to human walking in which the determination of where the airplane should fly is an administrative decision made during the creation of flight schedules. The crew arrives on the airplane after being given the information of where to go, and it is the responsibility of the crew to make sure that they have enough fuel that can get to the engines to use as energy. While the airplane is sitting on its wheels, it is very stable; however, this stability has to shift into a stability of momentum of air flight controlled by gyroscopes, which monitor the in-flight balance. The crew, through the available computer, has to control the engine speed and airplane direction as the most direct control of the system. Each mechanical component of the airplane has to function or the crew has to make adjustments for a malfunction. For instance, if one engine stops, the plane can still fly, but appropriate adjustments have to be made. Just as with airplane flight, the musculoskeletal subsystems have to always be considered when evaluating the global gait function of individuals.

Cognitive Subsystem

Occasionally, children will present with the question from parents of why they do not walk. After a full history, it may be determined that these children



Case 7.1 Caleb



Caleb, a 4-year-old boy with mild diplegia, was brought in for an evaluation because of his parents' concerns that he was not able to advance to independent ambulation. He had no contractures on physical examination, had walked with a reverse walker for 2 years, but was unable to stand without holding on with his arms. He appeared to be cognitively age appropriate. He used articulated AFOs with a dorsiflexion posterior strap, which limited him to 10° dorsiflexion. In physical therapy he worked to learn to use quad canes that were weighted. His parents

were mostly interested that he progress to independent ambulation. After the evaluation, his parents were told that the primary problem was his poor balance, and he was old enough to learn to use crutches, which would likely be the assistive device he would use at maturity. Continuing to use the canes is a good stimulus for balance development but these devices are never functional ambulatory aids. Two years later, after training in therapy and a lot of practice, he was very proficient with crutches.

have severe mental retardation, which may be the reason for not walking. These children may not have conceptualized the idea of getting from one place to another or be willing to try new ways of mobility such as getting up off the floor. For example, a child with a cognitive level of 3 to 6 months will not even try to walk, even though this same child's motor development may be such that he could walk from a motor perspective. Many of these children will slowly develop insight with stimulation to the point where they will stand up suddenly and start walking. The oldest child in whom we have seen this occur was just short of her 13th birthday. This kind of dramatic late beginning of walking never occurs if the major impairment limiting walking is in any other subsystem except the cognitive system.

Balance Subsystem

Balance is required for children to ambulate, and this is often the difference between independent bipedal ambulation and ambulation in a quadruped pattern with a walking aid. Balance is a complex function, in which most of the research has been reported with standing²⁶ or sitting balance studies.²⁷ The concept of balance during ambulation is hard to define, but it is primarily measured by high variability in step lengths, step widths, and joint range of motion. Often, the transitions in movement, such as stopping and standing or starting from a sitting position, are especially difficult when balance is a major impairment (Case 7.1).

Energy Production

Ambulation always requires an output of energy as fuel for the muscles. Even downhill walking, which in many mechanical systems can generate energy, requires more energy than it generates with human gait. Children must have the energy available for the musculoskeletal system to use or walking is not possible or comfortable (Case 7.2). A typical reason for low energy supply is a walking pattern that consumes more energy than children can generate (Case 7.3). Another common cause is poor cardiovascular conditioning, which limits the amount of energy available to the musculoskeletal system.



Case 7.2 Kimberly

Kimberly, a 12-year-old girl with significant hypotonia, was evaluated because her parents complained that she had decreased walking endurance. On physical examination, general muscle weakness and hypotonia were noted. Her videotape demonstrated a gait pattern typical of hypotonia. On assessment of her energy requirements of walking, she was found to have walking velocity of 85 cm/s with an oxygen cost of 0.12 ml oxygen per kilogram of body weight per meter of distance covered. This

was 2.3 standard deviations below the mean, indicating that her energy efficiency was much better than normal children of her size. In spite of this energy-efficient gait, her main complaint was decreased endurance. Although there was no known diagnosis in Kimberly except hypotonia, we made the presumption based on her energy use that there was a deficiency in the way the muscle used energy; therefore, her limited endurance was due to primary muscle pathology, not mechanical in efficiency.



Case 7.3 Collette

Collette had severe diplegia, and during middle childhood and adolescence, had many operative procedures to correct femoral anteversion, crouched gait, and stiff knee gait. She attended a regular high school, which required long walks between classes. In middle childhood she used a posterior walker and was later switched to Lofstrand crutches, which she used exclusively by high school. During high school, in the period of her adolescent growth, she developed knee pain and complained about increased fatigue. An oxygen consumption test showed that she walked with a very slow velocity of 78 cm/s with an oxygen cost of 0.52 ml O₂/kg/m (0.27 normal predicted), which was 3.9 standard deviations above the normal mean. Based on the complete analysis, there were no me-

chanical inefficiencies that could be corrected, and it was recommended that she get a wheelchair to use for long-distance ambulation. She obtained a wheelchair and used it in school for many months until her knee pain resolved. However, she was very unhappy in the wheelchair because she believed she was gaining weight, felt herself becoming more deconditioned, and did not like to sit when talking to friends who were standing. She decided to walk with her crutches, which she did throughout high school, and she completed a university nursing degree walking with her crutches. As a young adult in her mid-twenties, she said she still had a wheelchair somewhere, but she did not quite remember where it was because she never needed it.

Motor Control

Motor control is an extremely important aspect of developing good walking skills. Individuals with significant motor control disorders, or the inability to develop motor control, will have significant problems with gait. This aspect is discussed at length in Chapter 4 on neurologic control.

Structural Stability

The mechanical mobility system includes the muscles, bones, and tendons. The interaction of these structural elements is the primary focus of much of the remainder of this chapter because it is the area where the most opportunity is present to make alterations in the system to functionally improve children's

gait. As understanding of the mechanics of walking in individual children is gained from a clinical perspective, the defined methods of measuring the effects of different subsystems also have to be understood.

Measurement Techniques Used in Gait Analysis

Measuring human walking with techniques that delineate the functional components is called gait analysis. This analysis is a critical process in understanding the problems of children with abnormal gait. The analysis needs to be performed with the same scientific understanding and organization upon which modern medical practice is based. For example, physicians treating hypertension have to understand the physiologic basis of hypertension, do a workup to determine the specific etiology of hypertension in an individual patient, then plan the treatment, which is followed by an ongoing evaluation of the response to the treatment. Usually, this means the patient is given medication and the response of the medication is monitored by periodically measuring his blood pressure. This same workup and treatment outline is applied to the treatment of gait abnormalities in children with CP. This process can only be done with an appropriate understanding of the physiology of each of the subsystems involved in the creation of human gait. For this reason, descriptions of the response of the central nervous system, muscles, connective tissue, and bones are detailed. The next step in this process is to understand gait as a functional entity, which requires an understanding of the components of the gait evaluation process. This evaluation process follows the modern medical evaluation model currently used in almost all medical disciplines, which means physicians always start with a history and physical examination, then order additional tests as indicated by the initial data. With gait, the additional tests include recording of a videotape, kinematic and kinetic evaluation, understanding muscle activation patterns with electromyogram (EMG) and pediabarograph, and measuring the energy demands of walking.

History

Patients' histories should include an understanding of the etiology of the CP if one is known. A history of the developmental milestones related to ambulation, such as when did these children start cruising and when did independent ambulation start, should also be included. The recent functional history is important, and it should include issues such as how frequently do the children fall, how often do they wear through shoes, and have they gotten better, worse, or stayed the same in the last 6 to 12 months. The parents or caretakers should always be asked what their concerns are relative to the children's ambulatory problems (Table 7.3).

Physical Examination

The physical examination needs to focus on the aspects that are important in understanding the etiology of the gait problems, including evaluation of global functions, such as balance, independent motor control ability, muscle strength, muscle tone, muscle contractures, and bone alignments (Table 7.4).

Global Function Measures

In routine clinical evaluation the specific measurement of global gait function is recorded by noting functional abilities such as children's ability to walk

Table 7.3. Elements of the history that are important in gait treatment decision making.

History questions	Information applications
Was the child premature?	Prematurity has more predictable spasticity, usually with diplegic pattern involvement.
What is the known cause of the CP?	Some causes, such as middle childhood trauma, have a different course.
How has the child changed in the last 6 to 12 months?	It is important to consider if the child is improving, static, or diminishing in physical skills.
What is the child's level of cognitive function?	This can give a level of expectation of future improvement with therapy or the ability to do self-directed therapy.
Does the child wear orthotics and for how much time each day?	If the orthotics are being worn but are ineffective, other treatment is indicated.
Does the child object to orthotic wear?	Some adolescents refuse orthotic wear because of cosmetic concerns and this has to be considered.
Does the child use an assistive device in the home?	A good idea of the child's function at home and in the community is important to consider.
Does the child use an assistive device in the community or school?	A good idea of the child's function at home and in the community is important to consider.
Does the child use a wheelchair? If yes, when?	This, again, is a part of understanding the function of the child, and a child using a wheelchair as primary ambulation is hard to change to ambulation.
Does the child complain of pain? If yes, when and where?	This can be a major limitation on function.
What are the concerns of the family?	The family will not be happy with any treatment outcome if their concerns are not addressed.
What are the child's concerns if he or she is mature enough to have an opinion?	Also, addressing the child's concerns, especially if he or she is an adolescent, is important. These concerns are often different from the parents' concerns.
What have been the previous musculoskeletal surgeries and treatments?	Future treatment has to consider prior treatment.

independently, to walk with one hand held, or to hop on one foot. A specific set of parameters that also relate to motor development should be monitored (Table 7.5). For a more in-depth gait analysis, the use of the Gross Motor Function Measure (GMFM) is recommended. The whole GMFM measure can be used, but we prefer to use only the fourth dimension, which is the standing dimension of the GMFM that focuses on standing and transitional movements. These movements are of most interest to orthopaedists, especially in children who are being evaluated for gait problems. This measure gives a numerical score and is useful as a general measure of children's balance, motor control, and motor planning. Other more specific tests of balance or motor planning are available, but currently these are mainly used for research purposes and not for standard diagnostic clinical evaluations.

Motor Control

Individual muscle motor control is tested on routine evaluation by noting in general terms if children can make steps on command, move the foot on command, and stand on one leg with the hand held. For more detailed gait analysis, an assessment of each major muscle group in the lower extremities should be made. For example, a child is asked to extend the knee, and if knee extension is performed as an isolated movement, it is rated as good. If the knee can be extended, but only associated with joint motion, such as hip extension or plantar flexion with the knee extension, it is rated as fair. If no voluntary focal movement of the specific joint occurs, it is rated as poor motor control (Table 7.6). Children with cognitive limitations that are so severe that they do not understand the concept cannot be rated.

Table 7.4. Physical examination parameters.

Parameter	Full gait analysis	Routine clinical evaluation
Global Motor Function Balance (GMFM)	GMFM may use only standing dimension.	Record what general functions, such as single leg and standing, hopping, or running, a child can do.
Muscle strength	Do manual muscle testing of the major muscles of the lower extremity.	Record general comments of good to poor strength.
Passive joint range of motion	Do goniometer measurements of all major joint motions in lower extremity. Record ROM of hip abduction, rotation, popliteal angle, knee extension, ankle dorsiflexion with knee extended and knee flexed.	Record ROM of hip abduction, rotation, popliteal angle, knee extension, ankle dorsiflexion with knee extended and knee flexed at each outpatient clinic visit.
Motor control	Record active motor control of major lower extremity motions.	Make a general comment of motor control, such as good or poor.
Motor Control		
<i>Grading Score</i>	<i>Description</i>	
Good	Patient can isolate individual muscle contractions through the entire available passive range of motion upon command.	
Fair	Patient is able to initiate muscle contractions upon command, but is unable to completely isolate the contraction through the entire available passive range of motion.	
Poor	Patient is unable to isolate individual muscle contractions secondary to synergistic patterns, increased tone, and/or decreased activation.	
Muscle Strength		
<i>Grading Score</i>	<i>Description</i>	
1	Contraction visible in the muscle but no visible movement of the joint.	
2	Can do partial arc of motion with gravity reduced.	
3–	Can do complete arc of available joint motion with gravity reduced.	
3	Can move joint through available range against gravity.	
3+	Can move joint through available range against gravity with minimum additional resistance.	
4–	Can move joint through available range against gravity with definite additional resistance.	
4	Able to move joint through available range against moderate resistance.	
4+	Able to move joint through available range against increased moderate resistance.	
5	Able to move joint through maximum resistance expected for the specific muscle.	

Table 7.5. Level of ambulatory ability.

Mobility Function:	
1.	Independent community ambulation, uses no assistive device or wheelchair
2.	Ambulation with assistive device such as walker or crutches, uses a wheelchair less than 50% of the time for community mobility
3.	Household ambulation, uses a wheelchair more than 50% of the time for community mobility
4.	Exercise ambulation, uses a wheelchair 100% of the time for community mobility
5.	Primary wheelchair user in home and the community, does weightbearing transfers in and out of wheelchair
6.	Wheelchair user, dependent for transfer

Table 7.6. Motor control grading.

Good	Patient is able to isolate individual muscle contraction through entire available passive range of motion upon command.
Fair	Patient is able to initiate muscle contraction upon command, but is unable to completely isolate contraction through entire passive range of motion.
Poor	Patient is unable to isolate individual muscle contraction secondary to synergistic patterns, increased tone, and/or decreased or absent activation.

Muscle Strength

Strength of each major muscle or muscle group in the lower extremity is tested with a 0 to 5 rating scale (see Table 7.4). Testing the muscle strength in children with spasticity can be difficult. We use the standard term of resistance until children cannot sustain the load. The strength levels of moving against gravity may be difficult to determine with spasticity present, as co-contraction severely limits motion, not in the technical sense of muscle weakness, but because the agonist cannot overpower the co-contraction of the antagonist. It is best to stay with a narrow definition of strength assignment, but make comments if the strength is strongly affected by spasticity or co-contraction. Strength testing depends on voluntary motion of children who can give their full effort. If the children's behavior or severe mental retardation preclude this level of cooperation, strength testing cannot be completed. When strength testing children weighing 15 kg compared with adolescents weighing 80 kg, a subjective assessment of their appropriate strength has to be made by the examiner. This makes the strength examination somewhat more subjective and focuses on the importance of the examiner having extensive pediatric experience.

Muscle Tone

Muscle tone is another important aspect in monitoring the assessment of gait impairments. In routine clinical evaluations, gastrocnemius and rectus spasticity provides a general overview. Also, subjective comments about the relative importance of the spasticity and the children's support, as well as problems that the spasticity is causing, should be noted. For more detailed assessments, the major motor groups in the lower extremities should have numerical assessment of spasticity. The modified Ashworth scale is preferred because it provides more options and allows notation of hypotonia (Table 7.7).

Passive Range-of-Motion Assessment

Muscle contractures are monitored by routinely recording specific measures made in the same fashion. These measures often include specific joint range of motion as accurately as the clinician can determine. Notation should also be made with regard to the source of the contracture, especially if it is believed to be a muscle contracture or a fixed joint-based contracture. Bone deformities and length should be noted as well. The specific joint examination should include a back examination with comments of scoliosis as determined by the forward bend test, significant lordosis, or kyphosis present in standing or sitting. At the hip, knee, ankle, and foot, standard joint ranges of motion are recorded.

Table 7.7. Modified Ashworth scale.

00	Hypotonic.
0	No increase in tone.
1	Slight increase in tone manifested by a catch and release or by minimal resistance at the end of range of motion.
1+	Slight increase in muscle tone manifested by a catch followed by minimal resistance throughout the remainder (less than half) of the range of motion.
2	More marked increase in muscle tone through most of the range of motion, but affected part easily moved.
3	Considerable increase in muscle tone, passive movement difficult.
4	Affected part rigid.



Figure 7.11. The most common gait measurement system requires that the individual being measured is instrumented with retro-reflective markers that are imaged by multiple video cameras. The markers define specific anatomic body points, which the computer program uses to calculate joint motion.

Videotaping

In the assessment of gait in developing children, the simplest and cheapest method also provides the most data needed for routine clinical decision making. A videotape of these children should be made in an open area with a predetermined format. The format requires that the children be undressed to only thin underwear or swimming suits. The videotape is made with a frontal and a rear view, then with both right and left lateral views. The videotape should include gait with bare feet, with the shoes and orthotics that are typically worn, and the children should be asked to run. Also, different assistive devices are included as appropriate. Usually, the videotape is 1 to 2 minutes long and is seldom more than 3 minutes long. A storage and retrieval system for the videotapes must be available so they can be retrieved for each clinic visit. At each visit, the video is reviewed as the children's gait is observed. On routine evaluations, a videotape is always made at the first evaluation, and a new videotape is added as changes are noted with each examination. When children are under age 3 years, a new videotape is typically made every 6 months. From 3 to 12 years of age, a new videotape is made every 12 months, and over 12 years of age, approximately every 2 to 3 years. This time table is individualized to each child and a new videotape is made only when some change is noted based on a subjective clinical evaluation of the child and of previous videotapes.

Kinematics

During kinematic evaluations, the motion of each joint is measured as the children walk. These measurements are used to provide additional information to help make major interventional decisions, such as surgery or difficult orthotic decisions. Also, the kinematic evaluation is important as a measure of children's response to treatment. Kinematic evaluations are performed only as part of a full gait analysis. The modern interest in measurements of human motion started in the first half of the 1900s with the use of stop-frame video pictures from which each angle could be drawn to assign measures from one frame to the next. With improvement in camera technology and computers, this same concept is still the primary method of measuring joint range of motion during gait. The process is now completely automated, so it is fast, efficient, reliable, and accurate (Figure 7.11). Other technology, such as the use of accelerometers or electronic goniometers, have been explored for kinematic measurements; however, the optical system is the only system widely used in clinical diagnostic laboratories.

Optical Measurement

The modern optical kinematic measurement is based on dividing the body into segments. The most commonly used clinical systems divide the body into 7 or 13 segments (Figure 7.12). Each of the segments is defined by an embedded Cartesian coordinate system related to the specific segment's bony anatomy. The motion of each of these segments relative to its adjacent segment is marked by placing retroreflective markers on specific anatomic landmarks within the segment. Each segment must be defined by a minimum of 3 markers, which means that for a full body assessment 39 markers are required. Then, each of these markers is imaged by a minimum of two cameras simultaneously. With the same marker being imaged from two cameras separated in space, the exact position in three-dimensional space for the marker can be defined. This is the same method our brain uses to give us three-dimensional vision. Because of visual obstruction, most current kinematic

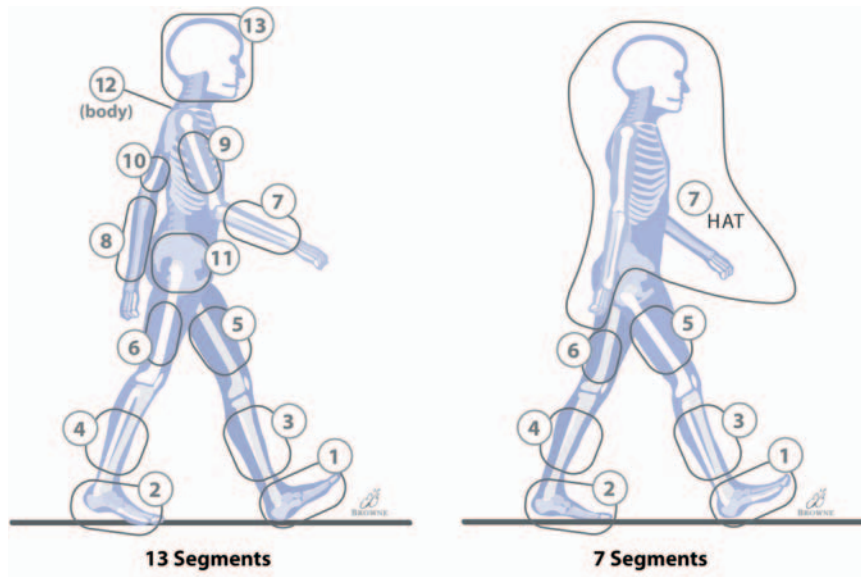


Figure 7.12. To calculate body motion in space or kinematics, mechanical models of the human body have to be developed. In current clinical gait analysis, the 7-segment model of two feet, two shanks, two thighs, and the HAT (head-arms-trunk) segments has been in use the longest. As computer power has increased, there has been a movement to the 13-segment model, which includes two feet, two shanks, two thighs, two forearms, two upper arms, a pelvis, a trunk, and the head.

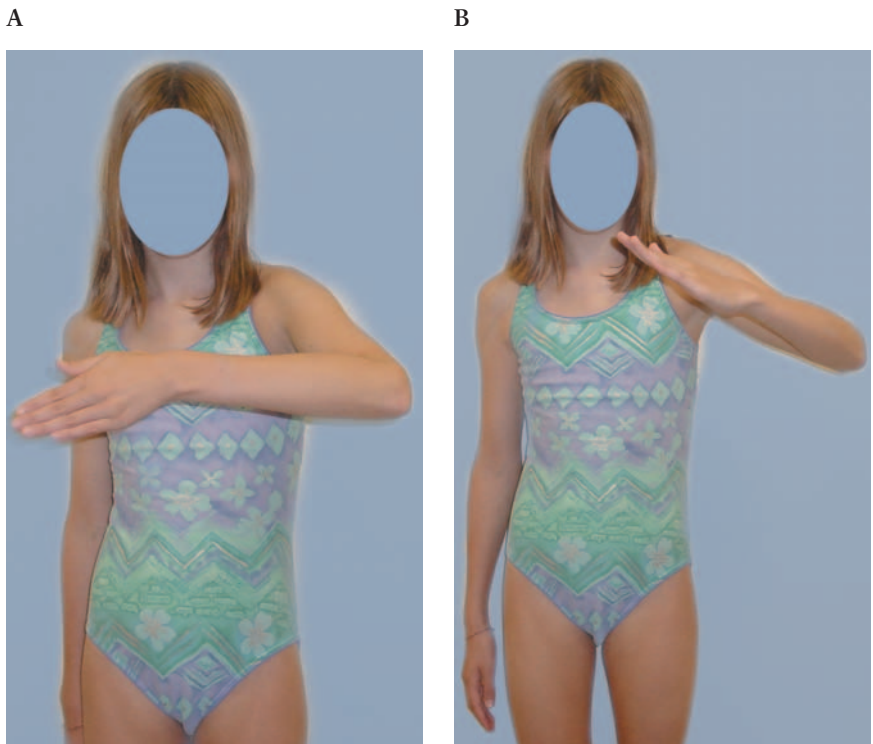
analysis systems use five to eight cameras placed circumferentially around a child. These cameras are focused on a fixed space in the room, which is assigned a room coordinate system. All cameras are synchronized to take images at the same time, for gait usually at a rate of 60 frames per second. With current clinical gait analysis systems, this process of identifying the marker and calculating its precise position in three-dimensional space is all automated; however, some error still occurs requiring each patient to be reviewed by a technical person who has experience with the system, usually an individual trained in biomechanics. Once the marker is identified in space, specialized software defines the specific assigned segment whose motion can then be calculated into clinically defined joint range of motion.

The specific joint motion is calculated from the motion of each segment. A problem that occurs in this reduction process is that the motion of the markers includes soft-tissue motion because the markers are not fixed to bones, but are attached to the skin. To counteract soft-tissue movement, the marker path is smoothed to remove high-frequency motion and the segments are assumed to be attached at points that represent accurate anatomic structure, because joints rarely have any measurable motion in translation or distraction. These two data manipulations help decrease the soft-tissue artifact; however, soft-tissue motion still has to be considered as a possible measurement error in some children if unexplained motion is found. The next major task in the kinematic data reduction is to assign specific clinically recognizable joint positions, such as degrees of flexion or rotation. This task requires choosing a method to reduce the three-dimensional data. Understanding this system is important for clinicians because it may explain the size of some of the numbers that do not correlate with physicians' own assessments.

Data Reduction Algorithms

All commercially available clinical data reduction software algorithms currently in use reduce the data using Euler angles.² In this approach, each coordinate system is rotated to neutral with respect to its adjacent coordinate system in a predetermined order. This process mimics what clinicians routinely do in physical examinations. For example, when a physician measures a specific contracture of the hip, he would say there is so much abduction, so much flexion, and so much rotation present. The mathematical concepts

Figure 7.13. The use of Euler angle calculations is very order dependent; therefore, the order of the calculations has to be understood. For example, the position of the shoulder with a calculation order of 45° internal rotation, 45° abduction, and 45° flexion (A) is very different from the position obtained with 45° flexion, 45° abduction, and 45° internal rotation (B).



of the Euler angles were initially applied to biomechanics because they closely mimic clinical practice.²⁸ The problem with this mathematical system that clinicians must be aware of is that Euler angle reduction is very sensitive to the order of reduction in joints with large, 3° freedom of movement. These joints include the hip, shoulder, and subtalar joints. For example, a shoulder position of 45° flexion, 45° abduction, and 45° internal rotation is very different from 45° internal rotation, 45° abduction, and 45° of flexion (Figure 7.13). All current kinematic systems have adopted the convention of flexion and extension followed by abduction and adduction, then rotation as the order of derotation in the coordinate systems. Based on personal experience, most clinicians seem to rotate out rotation first, or, alternatively, they rotate out the largest plane of motion first. There has been no evaluation of what order clinicians cognitively use for visual or physical examinations; however, the difference is sometimes large enough to make clinicians uncomfortable with the kinematic numbers. There are no right or wrong numbers, as these only reflect the measurement algorithm, and clinicians need to understand that their impression suffers the same faults.

Although the Euler angle transformations are currently in primary clinical use, other coordinate transformation systems are used for research and may gradually find a role in clinical practice. The Grood–Suntay technique²⁹ sets up a global coordinate system in each segment with defined positions of the adjacent coordinate system. The easiest but oversimplified explanation of this system is that it functions similar to the assignment of latitude and longitude in the global surface position assignment systems. The advantage of this system is that it is independent of the order of rotation and may better reflect how clinicians look at children; however, we do not think it reflects how clinicians mentally, or by physical examination, assign degrees of deformity. Another system that is independent of the order of rotation is the finite helical screw approach in which the motion of the mobile coordinate

system is defined as motion along a vector, which has a radius and a length.³⁰ This system may have special appeal for complex motion, such as that of the subtalar joint, and to define motion in space of the pelvis and the trunk. It is important to recognize that the significance of these rotation orders are only important with larger motion changes in three planes; therefore, in relatively normal gait and in most joints they have little relevance.

Measurement Accuracy

The accuracy of the kinematic measures is a separate issue and depends on the specific motion and joint measured. This variation is due to the residual problems of markers attached to soft tissue and the problem of clearly defining bony anatomical landmarks. For example, defining the center of the hip joint is much more difficult and error-prone in large, obese adolescents than in children in middle childhood with a thin body habit. Also, the clinically significant changes are reflected much more reliably for large movements, such as hip and knee flexion, than for rotation or abduction and adduction of the knee joint. These specific joint issues are discussed later.

Kinetics

The measurement of forces at each joint is called a kinetic evaluation. For maximum clinical utility, kinetic measures should give a measure of the muscle force of each muscle; however, this is not clinically possible. Therefore, net joint forces, which are indirectly measured as the opposite of the force required to counteract the momentum and ground reaction force, have to be relied upon. Momentum is measured by assigning each segment a mass and a center of mass, and by the velocity and acceleration of the mass through the use of kinematic measurement. The ground reaction force is measured with sensitive and accurate force plates fixed to the floor, over which children walk (Figure 7.14). The function of these force plates is very similar to bathroom scales; however, in addition to the vertical vector measurement of weight, they can also measure forward and sideways forces on the floor, as well as moments about each of these axes. The residual of the ground reaction force at each joint has a direction and distance from the defined center of the joint. By knowing where the joint's center is in space and the direction of the ground reaction force vector, the moment arm can be calculated. With knowledge of the moment arm and the ground reaction force vector, the

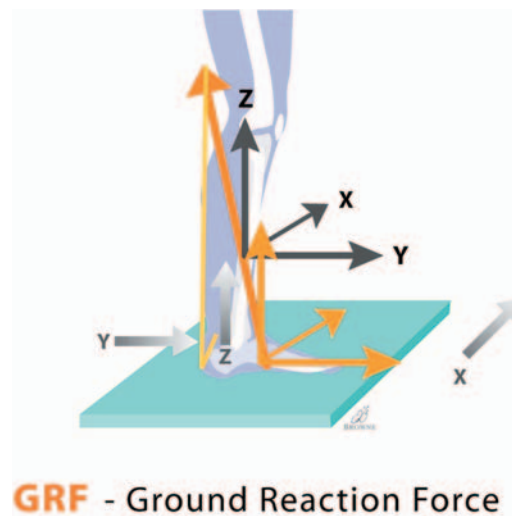
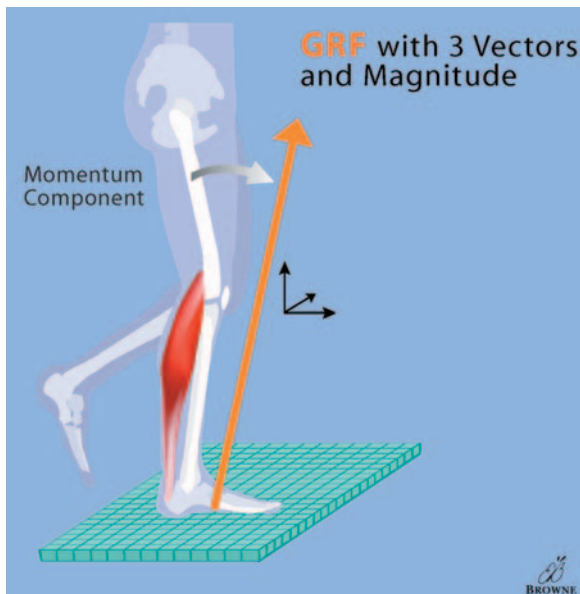


Figure 7.14. The force plate or force platform measures the contact force of the foot to the floor as a single force vector with direction and magnitude. This allows decomposition of the force into orthogonal vectors in the vertical, mediolateral, and anteroposterior planes. Torsional moments can also be measured around each of the principal vectors, but for gait analysis, only the torsional moment around the vertical vector has significance.

Figure 7.15. Calculation of joint moments and powers is called kinetics. The joint moment is calculated by the magnitude and direction of the ground reaction force measured from the force plate combined with the momentum component calculated from the kinematic motions of the joint segments.



moment generated by the ground reaction force vector can be calculated. The moment from the ground reaction force vector is then added to the moment of momentum and the total external joint moment is measured. Therefore, it can be assumed that the muscles, ligaments, and bones must create an equal and opposite internal force because the system is stable in the instance in which the measurement was made. Once the moment has been calculated, joint power is calculated by multiplying moment times velocity (Figure 7.15). The software technique used to reduce the moment and ground reaction force data into joint moment and powers is known as inverse dynamics. Moments are typically measured in units of Newtonian meters (Nm), which are then divided by a child's body weight for a unit of Nm/kg to allow comparison with a normal mean and range. Joint powers have units of watts and again, to compare them with a normal mean, are divided by a child's body weight; therefore, the units typically plotted are the watts per kilogram of body weight.

Measurement Accuracy

The accuracy of kinematic measures is impacted by various measures, with the error of the kinematic system coming along to the kinetic measures. Also, there is error in determining the segment mass and the center of the mass. However, the kinetic measures are far more accurate overall than the kinematic measure. The increased accuracy of kinetics occurs because the contribution from the momentum side of the equation is usually substantially less than the ground reaction force contribution. The ground reaction force measure is extremely accurate and reliable. There are other theories for determining joint forces with forward dynamics being studied extensively, but this presently has no direct clinical application. With forward dynamics, a mathematical model of the musculoskeletal system is developed, then inputs using EMG to define activity times, segment motion from kinematics, and ground reaction force from the force plates are used with the assumption that the body is trying to walk with the least possible energy. This technique can theoretically give, in addition to joint forces, the force of each individual muscle, and by further refinement, where on the length-tension curve the muscle is functioning. The forward dynamic model has many appealing

benefits; however, there are currently so many assumptions required that the model provides no useful individualized information for specific patients. The model has been useful to understand the forces around a specific joint, such as what muscles are important in producing internal rotation about the hip.³¹ There have been attempts to use this model to understand hamstring muscle forces in individual patients.^{32, 33} The problem with this focus on the hamstring muscles and tendon length, as measured by the model's origin to insertion of the muscle-tendon unit, is that there is no consideration for where on the length-tension curve the muscle functions. This crucial information is important for deciding whether or not the muscle should be lengthened. Although these models are being used in a few centers to evaluate muscle origin to insertion length, clinical application of the information is of marginal value in diagnostic decision making.

Electromyography

Electromyography is a summation of all the individual muscle fiber action potentials. This complex waveform varies by the number of action potentials and the distance the recording is from the action potential. If the EMG is recorded from the surface of the skin, the signal is decreased by the subcutaneous fat and skin. Electromyography recorded from the skin has the advantage of recording over a larger area of big muscles, but with small muscles or small children, cross talk from adjacent muscles may occur. Another method for recording EMG is with the use of an indwelling wire electrode that is inserted percutaneously through a needle. The needle is then withdrawn and the wire is left implanted. The location of the wire is confirmed by testing a muscle EMG response to a specific isolated activity of that muscle. The advantage of using the indwelling wire electrode with the EMG is the ability to localize recording from a small or deeply located muscle. The wire electrodes also have less cross talk from neighboring muscles. The main problem with wire electrodes is pain that may make normal walking not as relaxed as normal. Also, children are often scared of needles and will not cooperate after insertion of the wires. The EMG recording contains information on the magnitude of the electrical activity and the timing of the activity in the gait cycle. The magnitude of the EMG relates in complex ways to the force of the muscle contraction.³⁴ However, for children with CP, it is not possible to get reliable maximum voluntary contractions, which are required as part of the calculation to relate muscle force to EMG magnitude. In addition, there is great variation in the resistance of soft tissues and strength of individual motor potentials, all making the relationship of force to EMG magnitude very unreliable. Therefore, the only clinically useful data obtained from EMG are timing data. The EMG has to be closely correlated to the gait cycle either by synchronizing the EMG to the kinematic measurements or by adding foot switches to the feet to assess gait cycles. By using the EMG as timing, a muscle can be determined to have a normal pattern, to be on early or late, to turn off early or late, to be continuously on or never on, or to be completely out of phase (Table 7.8). Using EMG in this fashion was suggested by Perry¹ and is widely used in clinical diagnostic assessment; however, the consistent evaluation of the terminology is less widespread. Usually, EMG assessment is used with kinetics and kinematics for a complete analysis of the gait cycle. Surface EMG is used in most patients for most muscles. Specific muscles, such as the tibialis posterior, soleus, iliacus, and psoas can be reliably measured only with the use of percutaneous wires. These muscles are recorded only in specific indications for children who are able to cooperate.

Table 7.8. Clinical definitions of electromyography activity.

Terminology	Definition
Early onset (premature):	Activity of the muscle begins before the normal onset time.
Prolonged:	Muscle activity continues past the normal cessation time.
Continuous:	The muscle is always on with no turn-off time (constant activity may be hard to distinguish from no activity that generates background noise).
Early off (curtailed):	Early termination of the muscle activity.
Delayed:	Onset of muscle activity is later than normal.
Absent:	No muscle activity, which can be hard to separate from continuous activity.
Out of phase:	The muscle is active primarily during the time it would normally be silent and is silent when it should be active.

Pedobarograph

The force plate measures the force the floor applies to the foot. This force is measured as a summated force vector with a specific point of application. However, the foot does not contact the floor physically as a point, but as a flat surface. The measurement of the pressure distribution on the sole of the foot in contact with the floor is called a pedobarograph. These devices are mats that contain a whole series of pressure sensors (Figure 7.16). Currently, several systems are available, with the major difference being a choice between larger sensing area with less accuracy for the absolute measurement or a smaller sensing area with greater accuracy for the absolute measurement. The use of this system in children with CP is a way of quantifying planovalgus or equinovarus foot deformity as well as heel contact times. There is little need to focus heavily on the absolute pressure measurement for a specific area. If children are developing pressure sores on the feet, such as children with insensate feet from diabetes or spinal cord dysfunction, the more sensitive systems are probably better. Regardless of which system is used, the information on foot position as children walk over the measurement plate without targeting the plate is reliable and the best way currently available to monitor childhood foot deformities. The test is quick and easy to understand, mainly through pattern recognition, and allows quantifying varus, valgus, and heel contact positions. The test can be used as a yearly follow-up tool for children with foot deformities and is especially useful to assess planovalgus feet in young children as radiographic imaging is of little use in this age group. Although the pedobarograph is not available in every laboratory, most pediatric laboratories have it available and use it routinely.

Oxygen Consumption

The most recent addition to the tools of gait analysis is the measurement of whole-body energy consumption. The current mechanism for measuring energy relies on indirect calorimetry, which measures the amount of oxygen used and carbon dioxide produced. Indirect calorimetry works under the assumption that the final pathway, which burns fuel to release energy, comes from a process that consumes ATP and oxygen. For anaerobic metabolism, carbon dioxide production increases; however, there is no increase in oxygen consumption. The instruments currently available for oxygen consumption measurement are small telemetry face masks, which can be worn during normal gait (Figure 7.17). This device gives output of continuous oxygen use,

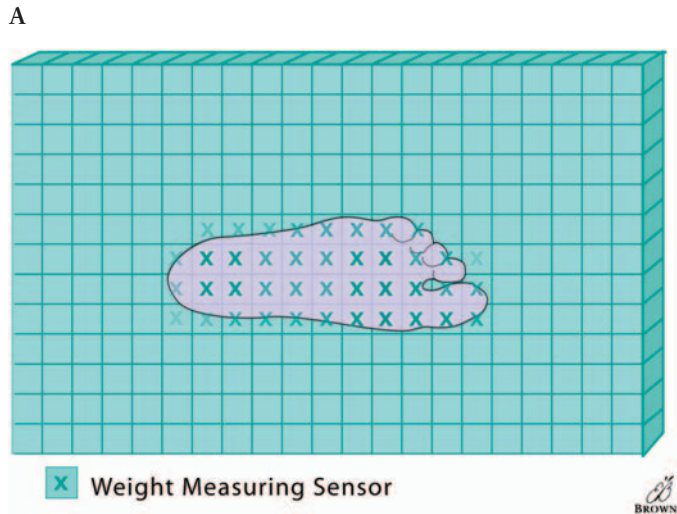
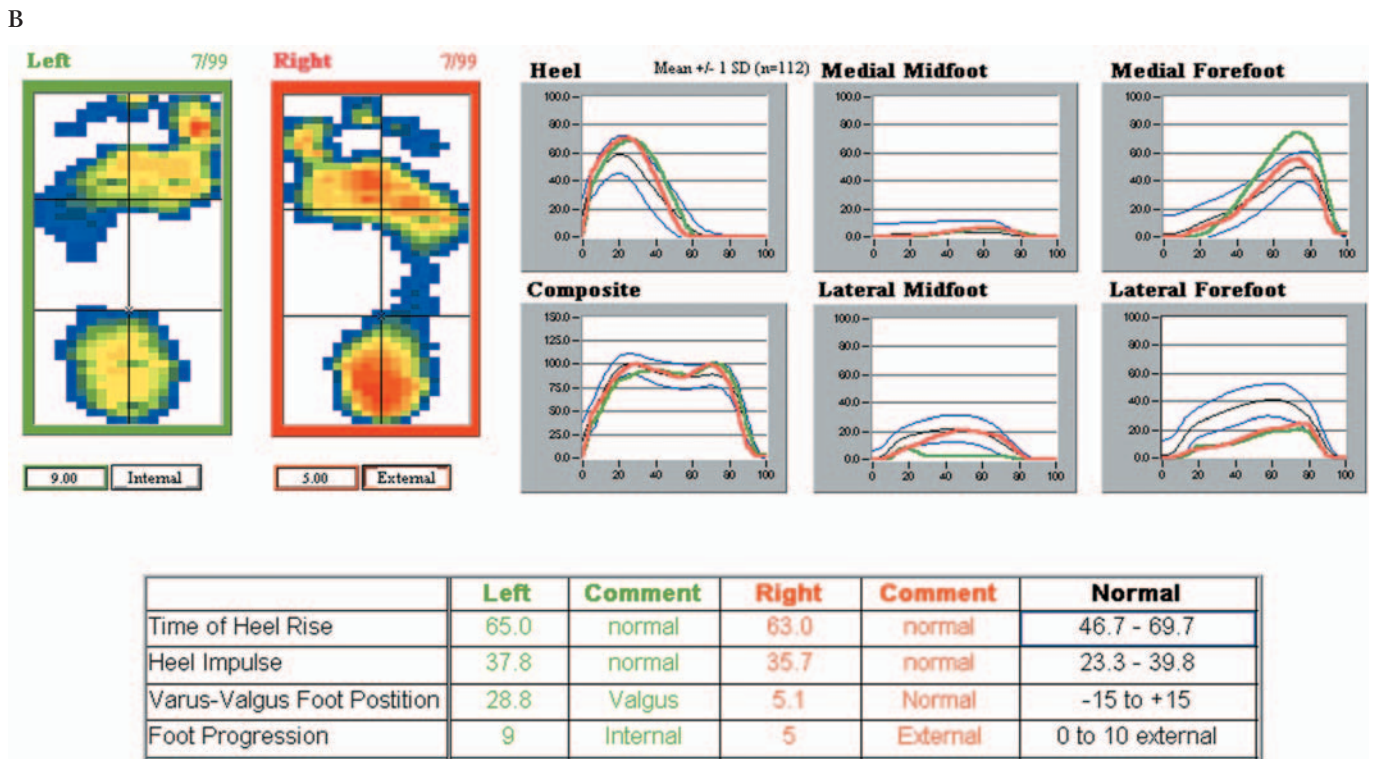



Figure 7.16. Measurement of the distribution of the force on the sole of the foot is done using a pedobarograph. This device has a series of sensing cells that measure vertical load only (A). These areas of pressure measurement can then be plotted together to represent an image of a footprint that shows which area of the foot has the highest force. Segments of the foot can be divided, and the total segments are plotted (B) Other specific data can be calculated, such as the relative distribution of force on the medial side versus the lateral side of the foot; this provides a measure of the varus (increased force over the lateral foot segments) or valgus (increased pressure on the medial side of the foot) foot deformities.

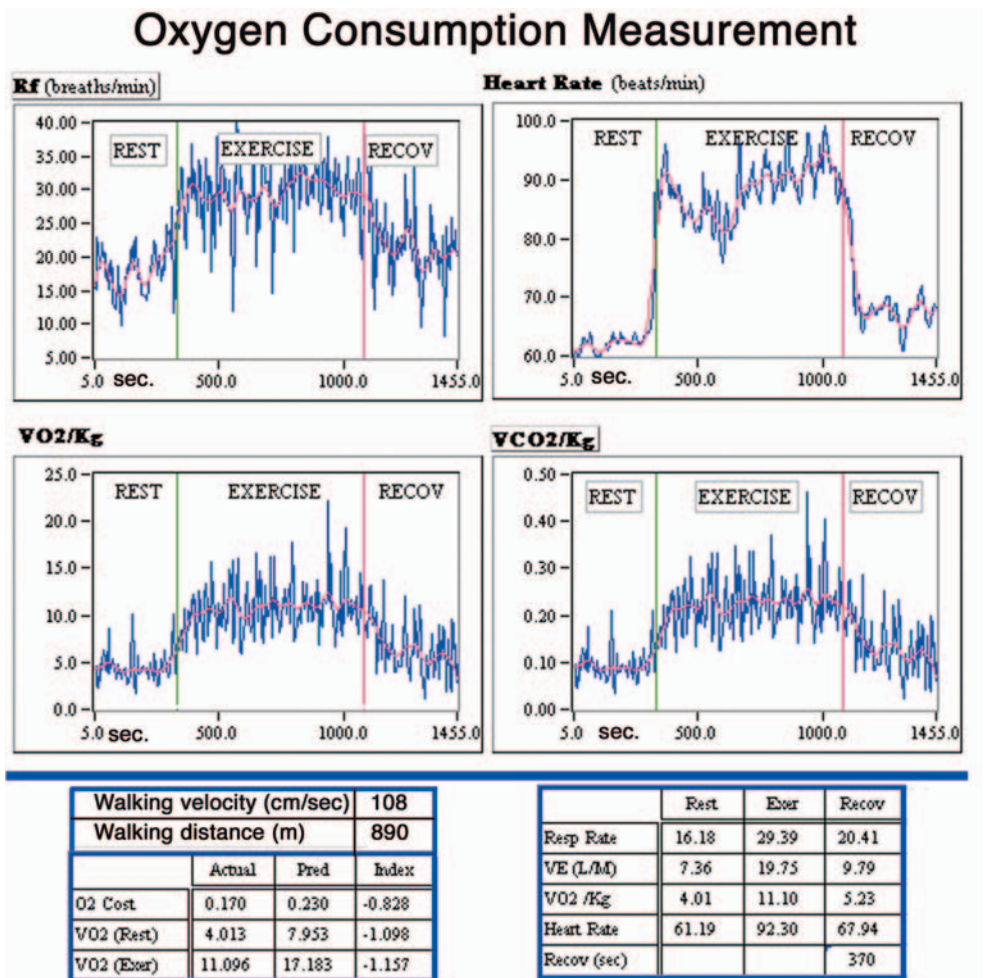


carbon dioxide excretion, respiratory rate, volume of inspired and expired air, and the heart rate. Walking speed is added to these measures. A typical way to measure oxygen consumption is to have children sit comfortably and relax for 3 to 5 minutes, then ask them to get up and walk in a specific pre-determined gait pattern for 5 to 10 minutes. The amount of time they are required to walk on a walkway is recorded, and by knowing the distance they have walked, the velocity can be calculated. Typically, the oxygen consumption has to be normalized for body size. There is a significant reduction in milliliters of oxygen per kilogram of body weight as children get older and heavier. We normalized this measure to the body surface area and used a Z-score or a number of standard deviations from the normal mean to define a child's relative function.³⁵ The heart rate and respiratory rate are evaluated

Figure 7.17. Measuring the energy cost of walking requires measuring the amount of oxygen consumed and the amount of carbon dioxide generated. This measurement is currently performed with a self-contained unit that fits over the child's face and has a data collection system that can telemeter the data to a local computer (A) The system also records breath rate and heart rate. If the velocity of walking is also recorded, oxygen cost in milliliters of oxygen per meter walked per kilogram of body weight can be calculated (B).



B



as well. Oxygen cost is defined as the amount of oxygen burned per kilogram of body weight per meter of movement. Speed is not considered as a variable factor, and for walking in the normal range of 80 to 160 cm per second, there is little impact of velocity.³⁶

Another measure is oxygen consumption, which is defined as the amount of oxygen consumed over time, and is expressed as milliliters of oxygen per kilogram of body weight per second. Oxygen consumption is seldom abnormal in children with CP because they have normal muscles, hearts, and lungs. However, children with muscle disease have oxygen consumption and cost that may be very low.³⁷ The measurement of oxygen cost has been promoted as an excellent outcomes measure in gait treatment in children with CP.³ A definite goal in treatment is to improve the efficiency of gait; however, as demonstrated in comparison with children with muscle diseases, similar functional gait impairments can have even more efficient gaits than normal children as demonstrated by decreased oxygen costs. Oxygen costs should not be used as a lone outcome measure; other functional measures of gait improvement have to be considered as well. Children who seldom walk may have such severe deconditioning that this is the major impediment to their walking. These data are hard to obtain in any way except with oxygen consumption. Oxygen consumption measurement is not available in all laboratories, and because it is the most recent addition, it has the least clear clinical benefits. We routinely measure oxygen consumption with full assessments if children can cooperate and their gait is thought to be substantially abnormal.

There are many older oxygen consumption systems that require using a pushcart to push along as children walk. All these systems give the same information and it is only the issue of convenience and ease that defines the modern devices. Another technique for measuring energy use that has been promoted is the energy cost index, which is a measure in the change in heart rate with increased activity.³⁸ There is a rough correlation of energy consumption with increased heart rate over a resting heart rate. This measure, which is also known as the physiologic index, is almost useless in assessing children with CP over time because of the many variables that impact heart rate. The correlation to the actual measure of oxygen consumption is poor.³⁶ Even if the equipment to measure oxygen consumption is not available, poor reliability of the energy cost index makes it not worth the effort to collect.

Gait Analysis

Diagnosing the Gait Impairment

After the discussion on techniques and methods of assessing gait impairments in children with CP, there is a need to have a focused and goal-oriented methodology to apply these tools in the care of children. The medical treatment of gait follows the same order as followed in other medical care. For example, the evaluation of a child seen by an orthopaedist for a lump on the thigh would start with a history of how and when it was noted, any history of trauma or surgery in the area, and questions as to whether there is pain or are there functional problems. The next step is to do a physical examination, which may be all that is needed if this lump is thought to be a superficial hematoma; otherwise, the next investigation would be a radiograph. The radiograph may show a typical osteochondroma and the treatment can be planned, but if a lesion with periosteal elevation is seen, the next step would be to get a magnetic resonance imaging (MRI) scan of the thigh. Because of

uncertain diagnosis with periosteal elevation, testing would likely include a computed tomography (CT) scan and a bone scan before biopsy. Then, after all the data have been collected, a diagnosis and plan of treatment is offered to families and children.

To follow the same analogy of the thigh lump, when children with gait impairments are initially seen, the history should include questions about the etiology of the CP to confirm to the physician that this is CP and not some other as yet undiagnosed condition. Also, the age of the children, when they started walking, and how specifically the walking has changed in the last 6 to 12 months are important in the evaluation. Questions about orthotic wear, how long the children have had them, do they object to brace wear, and are the braces worn every day are also important. After the history is obtained, the physical examination is performed focusing on joint range of motion, joint contractures, muscle tone, and gross motor function. Following the physical examination, children are observed walking in an area that is big enough to walk a distance. This area should be a hallway at least 10 meters long and wide enough (2 to 3 meters) so that a lateral view of the gait can be observed. It is impossible to see a typical gait pattern in a small examination room, and additionally, children must be undressed to underwear or swimsuits so the legs can be observed in their entirety. The observational assessment of gait should focus on joint position at various parts of the gait cycle, overall motor control and balance, and children's motivation and comfort with ambulation. Barefoot and orthotic shoe combinations used by children should also be assessed. This assessment should include a wheelchair evaluation if one is used. Parents must be instructed to bring all orthotics and walking aids to the appointment because these devices cannot be examined if they are left at home. The first visit with a child is similar to the initial evaluation for the thigh lump. Most of the information has been gained from a history and physical examination, which allows an assessment that further specific treatment is not indicated at this time. Cerebral palsy gait impairment for most children is an evolving condition that is heavily impacted by growth. For these children, there has to be a determination that there should or should not be significant change in treatment; however, children need to be followed to monitor the gait. In this situation, which is similar to that following an asymptomatic osteochondroma, a gait video is ordered.

This video is equivalent to a radiograph for a benign bone lesion. Typically, most children with CP gait impairments should be followed every 6 to 12 months, with the younger and more severe problems monitored every 6 months and the milder, older adolescent patients monitored every 12 months. For each repeat visit, the interim history of change is obtained, the examination is completed again, and gait is observed and compared with the videotape taken previously. The videotape also provides the parents and children the ability to see for themselves what the physicians are seeing. Many parents remember very poorly how their children walked earlier. Home videotapes show these gait patterns poorly because the children are frequently dressed in clothes that mostly obscure the lower extremities and the angles of the views are often very oblique and are not standard frontal or lateral views. Also, most of these home videotapes do not contain activity, such as normal walking, but often involve the children at play, at some other activity, or just standing. If during an examination the determination is made that an additional major change in treatment, such as surgery or major medication or orthotic treatment is indicated, a full gait assessment is ordered. This is the analogy of ordering an MRI scan, a CT scan, and bone scan for the lump on the thigh. The data from the full gait analysis are then used to make a definitive treatment recommendation. The results of the evaluations are

combined with the history and physicians' examinations to make the final treatment plan to present to families. Having videotapes available of similar children and knowledge of how they responded to the treatment are very helpful to the parents and children to understand what to expect.

Is Full Gait Analysis Really Needed to Decide Treatment?

The role of full instrumented gait analysis in the treatment planning of children with CP serves exactly the same function as advanced tests for a mass of uncertain etiology in the femur. In geographic locations where these tools are not available, the treatment of the femoral mass should proceed based on the available data. This means the bone would typically be biopsied and surgery is planned. It has been the experience of the medical community that additional tests help provide more information and therefore treatment can be more specific with possible better outcome. For the treatment of bone tumors, the outcome is easy; either the tumors return and the children die, or they are tumor free on long-term follow-up. Children with a gait impairment from CP will not have such dramatic success or failure. In spastic gait, the good versus bad result is less clear as compared with tumor follow-up. However, as with tumor surgery, there has to be an aggressive follow-up program. Tumor surgeons do not sit back and wait and see if the children will die, but perform periodic tests to find early recurrence by using bone and MRI scans. This same approach is used with gait treatment. A full evaluation should be performed 1 year after surgery, and ongoing clinical follow-up every 6 months is indicated until significant change occurs. The next level of treatment is then initiated. This use of regular periodic physician evaluations and when needed, the use of other available gait measurement tools, gives children the best chance for an optimal outcome.

There are still a few physicians who take the view that no one has shown that gait measures improve the outcome of gait treatment, and from some level of strict scientific perspective, this may be true. It is also true that there is no scientific documentation to prove that the use of radiographs improves the outcome of treating forearm fractures. This scientific documentation for gait analysis could be obtained. We know of one attempt to do a preoperative and postoperative gait analysis but not use the results of the analysis in deciding the surgical treatment. This study could not get Institutional Review Board approval because it was thought that useful information cannot ethically be withheld in the decision-making process. Withholding available information from physicians could potentially harm children. We doubt that ethically this type of study could be performed today. Studies comparing different approaches based on gait analysis measurements are more ethical and more scientific in approach than saying doctors can make better decisions with less information. It is true that more information is not always better, especially if the information is not understood; however, it is also true that in most situations, too little information is worse than too much.

How Should Gait Analysis Be Applied?

The modern scientific medical approach is to evaluate and measure the measurable elements, then try to understand the problem and construct a solution to the problem based on the physical facts. The application of these principles to the treatment of gait impairments demands gait measurement. So, are all the tools of full gait analysis really needed? Yes, in the same way MRI, CT, and bone scan are needed to treat bone tumors. Can physicians treat gait impairments of children with CP without gait analysis? Yes, they should definitely treat the gait impairments to the best of their abilities, just the same

as physicians should treat children with osteosarcoma of the femur if only regular, plain radiographs are available as the only imaging technique.

The application of measurement methods, especially those used in instrumented gait analysis, requires more than just measurement. The data must be combined and clinically analyzed by individuals who understand the data. This understanding of the data is a much greater obstacle for many physicians than getting the measurements done. Understanding the gait data requires a good understanding of normal human gait and the adaptations that the body makes. For those with little background in normal gait, we would recommend the book *Gait Analysis, Normal and Pathological Function* by Jacquelin Perry.¹ Because understanding normal gait as a whole-body function is crucial to understanding and planning treatment for abnormal gait, a review of normal gait is included here.

Normal Gait

Normal human walking is bipedal, which makes the balancing function more crucial than in quadruped ambulation. Bipedal gait is extremely versatile and energy efficient for short-distance mobility. This extremely complex function requires a large dedication from the central nervous system to fulfill the functions of balance, motor control, and cognitive decision making. However, the functions of balance and motor control, which emanate entirely from the brain, can act only through the mechanical components of the musculoskeletal system. When the motor control of gait is abnormal, the mechanical systems still respond directly to the command from the motor control. For example, if the brain can no longer maintain the body in the bipedal stance because of its limited function, it will still try to make the system work, and the muscles will contract normally when a contract command is sent. The attempt to accommodate for limitations due to the brain's decreased ability is not only a one-way street from the brain to the musculoskeletal system, there also seem to be accommodations occurring as the muscles, tendons, and bones make adaptations. In growing children, the musculoskeletal system is responsive over the long term and in trying to accommodate structurally to the brain's impairment. The accommodation by the musculoskeletal system largely follows rules of mechanics and is not always an accommodation that makes a positive impact on the global gait ability. An example of this principle is increased spasticity, or muscle tone, which serves a useful function by stiffening the body and allowing easier control. However, with increased tone, the muscles do not grow as fast, which at a mild level may also help motor control by decreasing joint range of motion over which the muscles can function. Both the increased tone and the decreased range at one level can allow the gait function to improve with a given level of brain functional ability. However, both increased tone and decreased range can get so severe that each becomes part of the impairment in itself. The third element needed for balance is energy output. In normal gait, the brain tries to keep the energy cost of walking low so individuals do not tire out. Understanding the mechanical components of the musculoskeletal system and how this system responds to brain impairments is crucial to clinical decision making, which is directed at producing functional improvement in a specific abnormal gait. In the end, the brain, with its given ability, tries to find a pattern of movement that allows individuals to be stable, mobile, and move with the energy available.

Gait Cycle

Gait is a cyclic event just like the beating heart, and just as understanding the cardiac cycles is important to understanding the heart, all the under-

standing of human gait falls into understanding the cycles of gait and the function of each cycle (Figure 7.18). Clinical descriptions of gait events follow the general pattern and naming convention popularized by Perry.¹ The basic separation of the gait cycle is in the stance and swing phases called periods by Perry.¹ The role of stance phase is to support the body on the floor and the role of swing phase is to allow forward movement of the foot. This two-phase function of gait is analogous to the heart, which fills with blood during its first phase and empties itself of blood during its second phase. The tasks of each phase of gait are simple; however, each of these phases is broken down further. The gait cycle of one limb is called a step and the right and left concurrent steps are known as a stride. The step of a walking cycle has two phases in which both feet are on the ground, a time called double support. The step cycle of running has two periods in which neither foot is in contact with the floor, called float or flight times. Therefore, the difference between running and walking is that walking has double support and running has flight time (Figure 7.19). This also means that walking always has a longer stance phase than swing phase and running always has a longer swing phase than stance phase.

Some basic quantitative definitions of the phases of gait are called the temporal spatial characteristics of gait. The temporal spatial characteristics include the step length, which is the distance the foot moves during a single swing phase measured in centimeters or meters, and the stride length, which is the combination of the right and left step length. Stance phase is measured as support time by the amount of time the foot is in contact with the floor. Swing phase is measured as the swing time, or the amount of time the foot is moving forward, usually equal to the time the foot is not in contact with the floor. The amount of time in seconds or minutes is measured, and both support and swing times are given as a ratio of total step time. For normal walking, the support time is 60% and swing time is 40%. The time when both feet are in contact with the ground is called double support, and each double support is 10% of the cycle. Each step has an initial double support and a second double support. Each stride also has only two double support times because the right initial double support is the same as the left second double support. Also, the time when only one foot is in contact with the ground is called single limb support time, and in normal gait, it is 40% of the step cycle. By knowing the time in seconds of a stride, the number of strides per time unit can be calculated, which is called cadence and is measured as strides per minute. By knowing the stride length and the cadence, the velocity of gait can be calculated, usually expressed as centimeters per second (cm/s) or meters per minute (m/min). There is still large variation between the use of cm/s or m/min; however, for the convenience of staying with a consistent numeric system for the remainder of this text, cm/s is the format used. The final temporal spatial measure is step width, measured from some aspect of the foot as the medial lateral distance between the two feet during the gait cycle.

Stance Phase

The role of stance phase in gait is to provide support on the ground for the body. This support function includes complex and transitional demands. The transition from swing phase to stance phase is called initial contact and is important in defining how the limb will move into weight bearing. The first time component of a step cycle is the loading response, which requires the limb to obtain foot stability on the floor, preserve forward progress of the body, and absorb the shock of the sudden transfer of weight. Loading time is equivalent to initial double support time and ends with the beginning of single limb support. Middle stance is the first half of the single support time

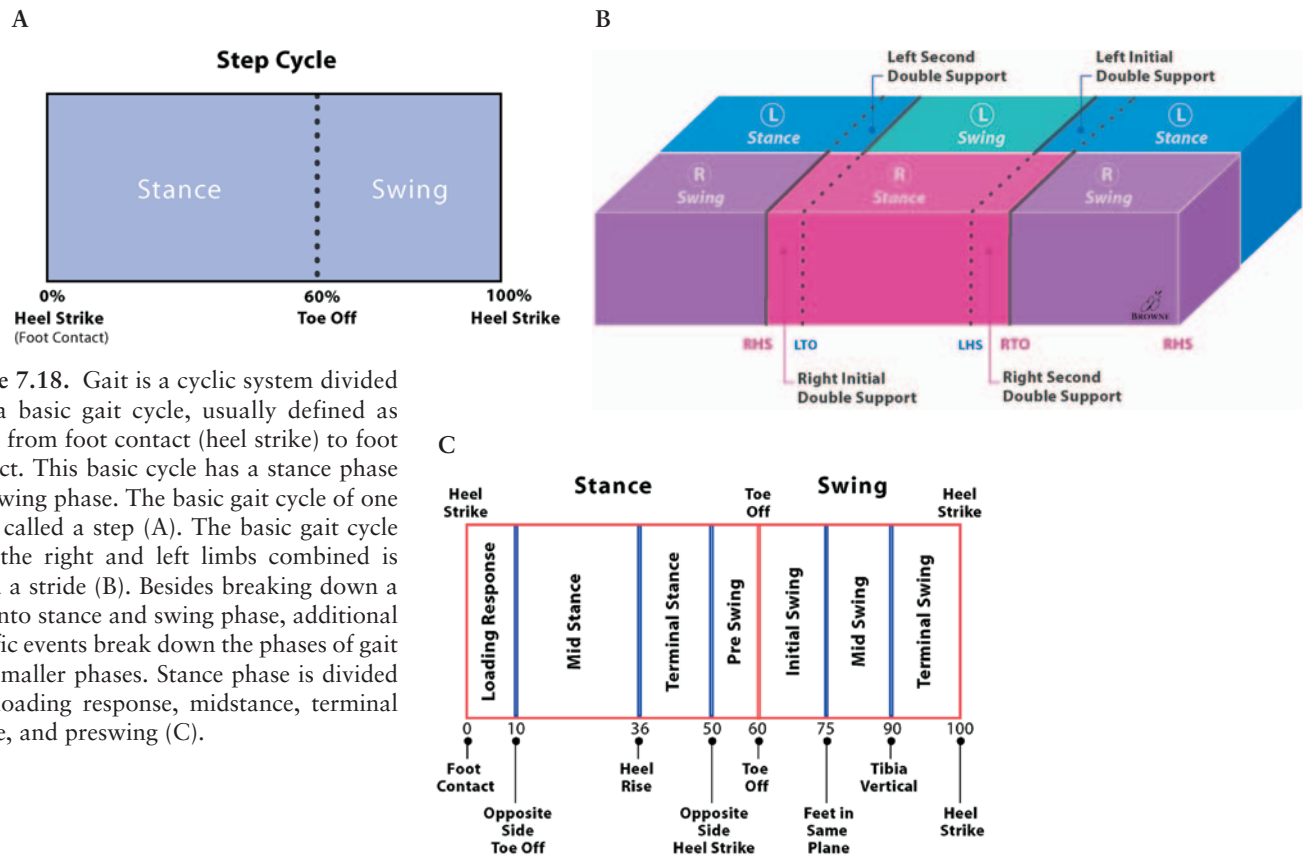


Figure 7.18. Gait is a cyclic system divided into a basic gait cycle, usually defined as going from foot contact (heel strike) to foot contact. This basic cycle has a stance phase and swing phase. The basic gait cycle of one leg is called a step (A). The basic gait cycle with the right and left limbs combined is called a stride (B). Besides breaking down a step into stance and swing phase, additional specific events break down the phases of gait into smaller phases. Stance phase is divided into loading response, midstance, terminal stance, and preswing (C).

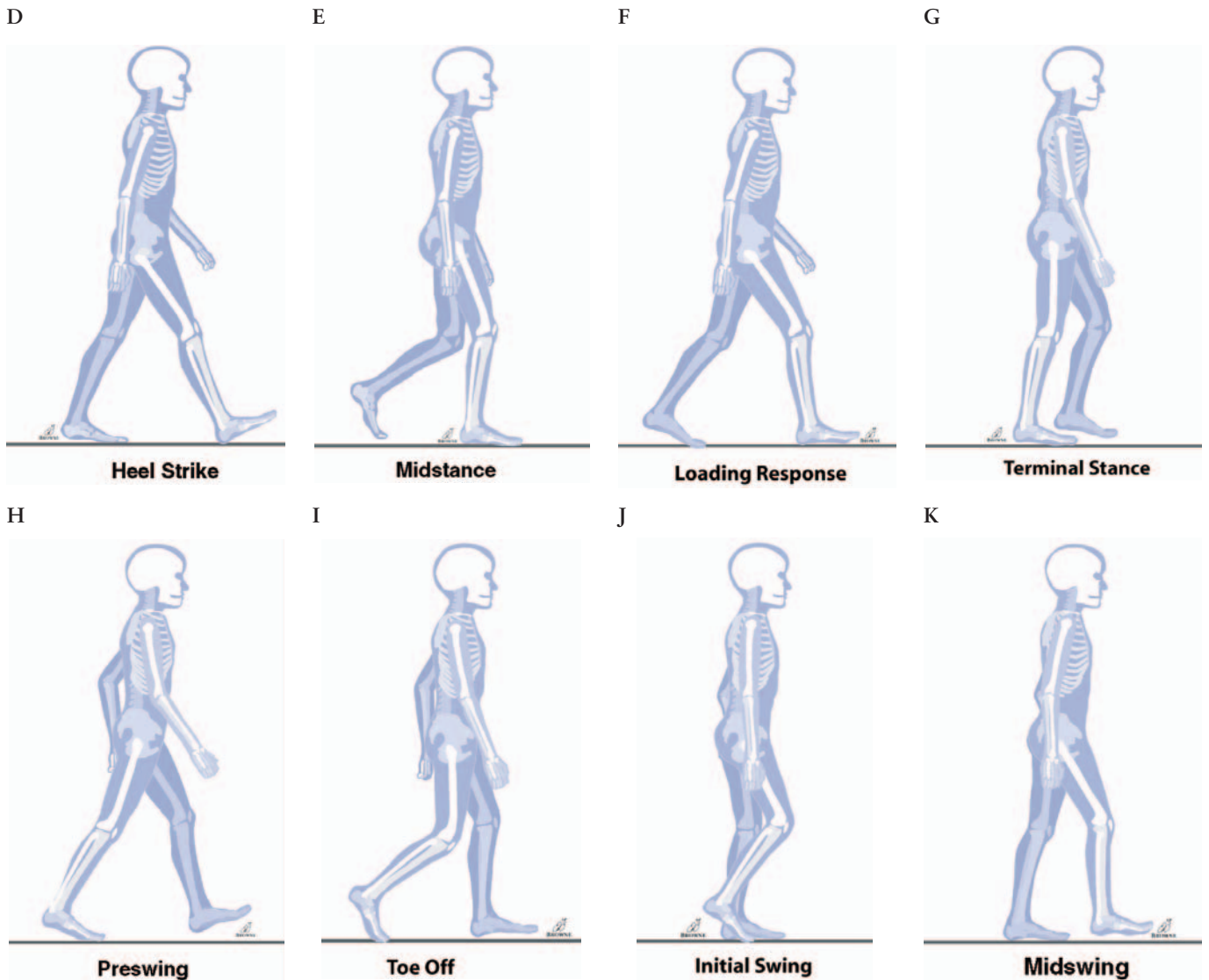
and is the time when the body is progressing over the stable foot fixed on the floor. Late stance, or terminal stance, is the last half of single limb support, and is the time when the body is in front of the planted foot when the foot can put energy into causing forward progression of the body. Preswing is a period corresponding to the second double support time just before swing phase. This is the time when the foot rapidly transfers weight to the other side and prepares for swing phase.

Swing Phase

Swing phase has the requirement of moving the foot forward. The time of initial swing phase takes up approximately the first third of swing phase. This period lasts from toe-off until the foot is opposite the planted foot. The role of the initial swing is to bring the limb from a trailing position to the position of the stance foot, with the swing foot clearing the floor. Midswing begins with the swing foot even with the stance foot, and ends when the tibia is vertical to the floor. At this point, the hip and knee flexion are approximately equal. Midswing takes up approximately 50% of the swing phase. Terminal swing occurs with the knee extending and the limb preparing for foot contact.

Body Segments Important in the Gait Cycle

To understand the gait cycle in more detail, the body has to be considered as segments linked together. The concept popularized by Perry is to consider the passenger, or cargo segment, and the locomotor segments.¹ This is equivalent to thinking of an automobile as having a power train and a body mounted on top of the power train. The passenger, or cargo element, con-

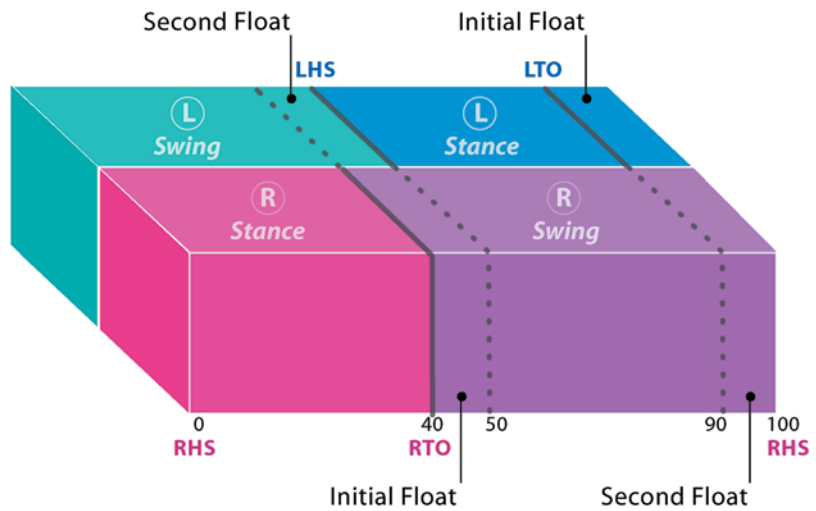


tains the head, arms, and trunk and is abbreviated as the HAT segment (Figure 7.20). The locomotor segments are the foot, shank, thigh, and pelvis, which are articulated by the ankle, knee and hip, and lumbosacral junction. The HAT segment is moved during gait with the goal of its motion being as straight a line as possible in the direction of the intended motion. The HAT segment can be defined by a center of mass that is somewhat higher than the center of gravity of the whole body. The center of mass of the HAT segment is also somewhat dynamic because this segment allows motion of the head and arms independently. The focus on the influence of this changing position of the center of mass of the HAT segment has not been well defined for the application of clinical gait analysis. The concept of the center of mass means that the body mechanically acts as if all its mass were at that point. The center of gravity is approximately the point on the body where the center of mass is located. The center of gravity is also dynamic and can be changed by a change in body shape, but in an upright standing position, the center of gravity is typically just anterior to the first sacral vertebra.¹ During gait, each of the locomotor segments has its own center of mass, which is fixed because each segment is an approximate rigid body that cannot significantly change

Figure 7.18 (continued). The stance phase events that make up these divisions are foot contact (heel strike) (D), opposite limb toe-off (loading response) (E), forward roll of the tibia (midstance) (F), initiation of heel rise (terminal stance) (G), opposite side foot contact (preswing) (H), and toe-off (I). Swing phase is broken down into initial swing, midswing, and terminal swing smaller phases (C). The swing events are toe-off (I), both feet in the same transverse plane (initial swing) (J), shank is vertical to the room (midswing) (K) and terminal swing ending with foot contact (L). Another breakdown can be related to the ankle rockers, in which the events are foot contact (K) to foot flat (E), to define first rocker. Foot flat (E), to heel rise (G) defines second rocker, and heel rise (G) to toe-off (I) defines third rocker.

Figure 7.19. The basic cycles of running are very similar to walking, except there is no double limb support and there is, instead, float time. Running is defined as a gait pattern in which there is a period of time that the body is not in contact with the ground.

Running Gait Phases



A

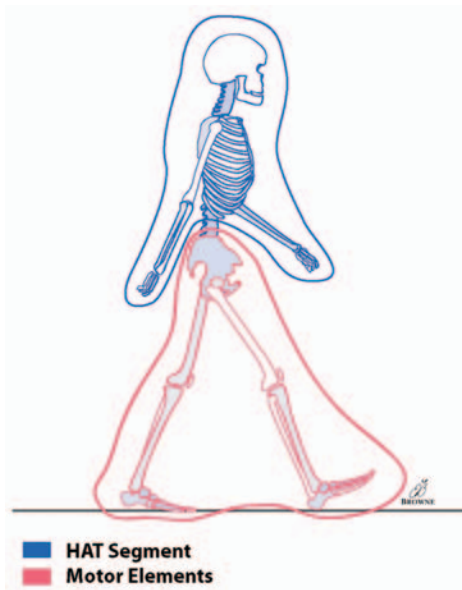
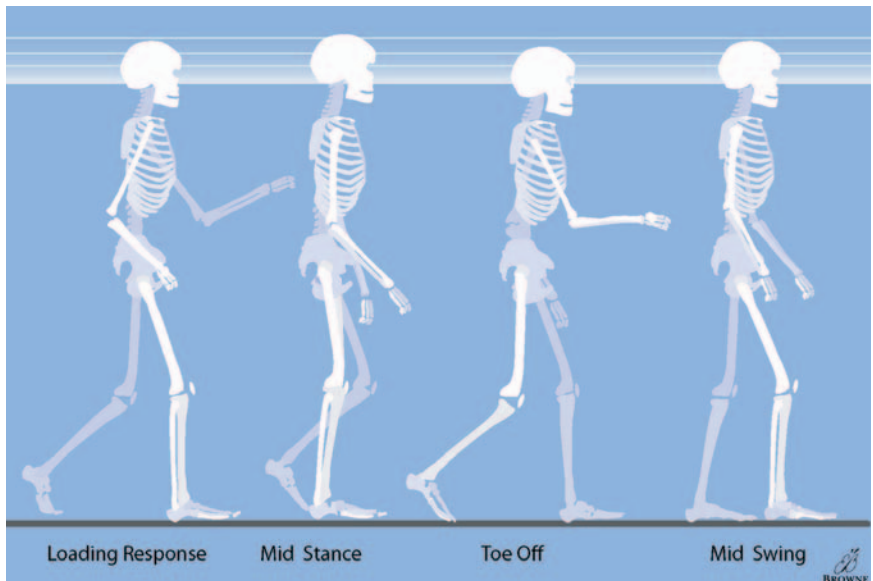


Figure 7.20. As a mechanism for understanding gait, the body can be divided into a motor segment that includes the pelvis and lower limbs, on which rides the cargo segment of the HAT segment (A). The goal of gait should be to move this cargo segment forward with as small a vertical oscillation of the cargo mass as is possible. Lifting this mass vertically and letting it drop with each step is very energy consuming (B).

B



its shape. This concept holds true consistently for the pelvis, thigh, and shank segments, but is much less stable for the foot and HAT segments. The center of mass can be changed significantly by swinging arms, trunk bending, and head movement in the HAT segment. For the foot segment, the change in center of mass is less dramatic than the problem of the foot not being a rigid segment, as assumed in gait modeling. Flexibility of the supposed rigid segment can cause additional problems for gait measurement.

For the gait cycle to have maximum efficiency, the center of mass of the HAT segment should move in a single forward direction of the intended motion only; however, this is not physically possible. Therefore, the goal is to minimize the vertical and side-to-side oscillation of the center of mass of the HAT segment (Figure 7.21). This is accomplished primarily by central

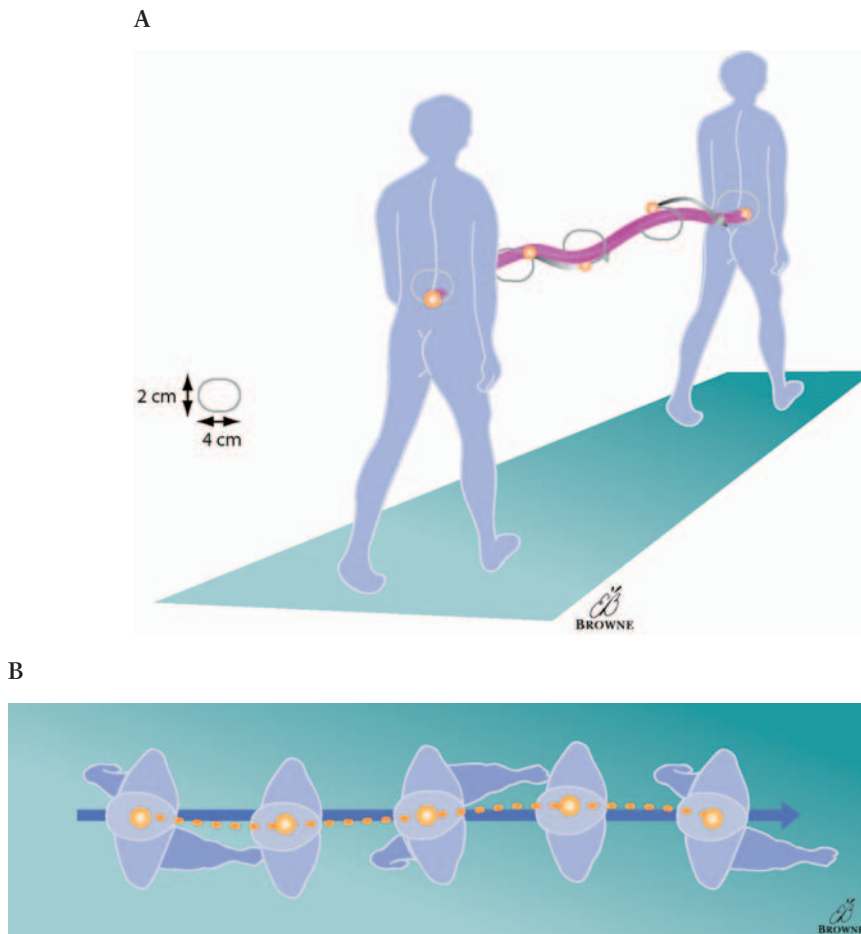


Figure 7.21. The body's center of mass is located just anterior to the sacrum. The most energy-efficient gait requires the least movement of this center of mass out of the plane of forward motion. In actual fact, the motion of the center of mass is really a path that looks like a screw thread in which there is vertical and sideways oscillation (A). There is a significant component of side-to-side movement (B).

motor control adjusting limb lengths through sagittal plane motion of the joints connecting the locomotor segments. Understanding these relationships is easier by looking at the individual joints and at how each joint functions in normal gait throughout the full gait cycle.

Ankle

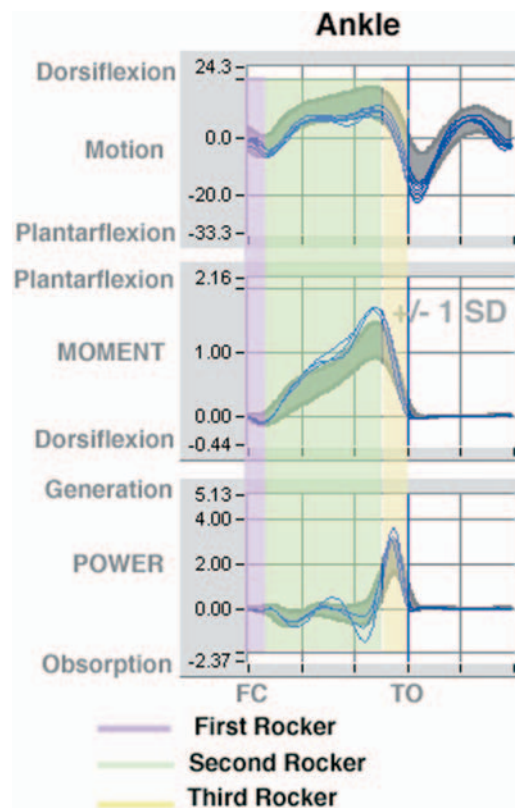
The ankle is mechanically modeled as the joint that connects the foot to the shank. The ankle is modeled as a single axis of motion in flexion extension, with mechanical perspective of the gait measurement. However, this description is a great oversimplification and the measures of rotation around the vertical axis and varus–valgus motion are recorded as well. The ankle joint measurements of rotation and varus–valgus motion are primarily reflections of motions in the foot itself through the subtalar joint; therefore, these measurements are not very useful because of the inaccuracy associated with marker placement and mathematical assumptions of the foot as a single rigid segment. Therefore, it is better to think of the ankle as having only plantar flexion and dorsiflexion ability and then separately consider flexibility and stability issues of the foot as a segment.

Motion of the ankle joint starts at approximately neutral in initial contact with heel strike. At heel strike, the ankle starts plantar flexion controlled by an eccentric contraction of the tibialis anterior. This motion of the ankle from heel strike to foot flat is called first rocker. During first rocker, there is a dorsiflexion moment at the ankle joint. All moments will be defined as

internal moments, or moments that are being produced by the muscles to counteract the external moments produced by the ground reaction force. After the foot is flat on the floor, the tibia rolls anteriorly as the ankle goes into dorsiflexion, a motion controlled by eccentric contraction of the gastrocnemius and soleus. This motion produces a gradually increasing plantar flexion moment, but with only a small power absorption. This period of dorsiflexion, which is controlled by the eccentric plantar flexor contraction, is called second rocker. Then, as the ankle reaches maximum dorsiflexion at approximately 10° to 15° at the end of late stance phase, a rapid plantar flexion motion occurs under the influence of a strong concentric plantar flexor contraction from the gastrocnemius and soleus. This period is called third rocker and is the main power generation for forward progression in normal gait. The important element of this power burst is to have the plantar flexors pretensioned on the slightly elongated segment of the Blix curve. This power burst also requires the foot to be stable, at right angles to the axis of the ankle joint, and aligned with the forward line of progression. The third rocker continues through preswing until toe-off when the dorsiflexors, by concentric contraction, produce dorsiflexion at the ankle to assist with foot clearance (Figure 7.22).

Maximum ankle dorsiflexion occurs in middle swing phase, and only a slight amount of plantar flexion occurs in terminal swing as the foot is prepared for initial contact. The primary dorsiflexor of the ankle is the tibialis anterior and the secondary dorsiflexors of the ankle are the extensor hallucis longus and the extensor digitorum longus. The primary plantar flexors at the ankle are the soleus, which is the largest muscle, and the gastrocnemius, which has approximately two thirds the cross-sectional size of the soleus. The gastrocnemius is primarily a fast-twitch aerobic type 1 muscle, whereas the soleus is predominated with slow-twitch type 2 fibers. The time of

Figure 7.22. The ankle is the primary power output for normal walking. Stance phase of the ankle is best broken into ankle rockers. First rocker is from foot contact to foot flat and is controlled by an eccentric contraction of the tibialis anterior. Second rocker is the time in which the foot is flat on the ground and the tibia is rolling forward on the fixed foot, a motion that is mainly controlled by an eccentric gastrocnemius contraction. Third rocker occurs from heel rise until toe-off and is controlled by a concentric contraction of the gastrocnemius. During this ankle rocker period, the normal period of gait defined in the context of the whole gait cycle also occurs. The ankle motion, ankle moments, and power curves also demonstrate the ankle rocker phases.



contraction in the gait cycle between the gastrocnemius and soleus is very similar,¹ and for practical clinical conditions, especially in children with CP, they can be considered to be contracting at the same time. The secondary plantar flexors are the tibialis posterior, the flexor digitorum longus, the flexor hallucis longus, and the peroneus longus and brevis. All these muscles are predominantly active during terminal stance phase and preswing. The only muscle with consistent activity during weight acceptance is the tibialis posterior. All together, these muscles only generate approximately 10% of the force of the soleus. The main function of these muscles is to stabilize the foot segment.

Foot Segment

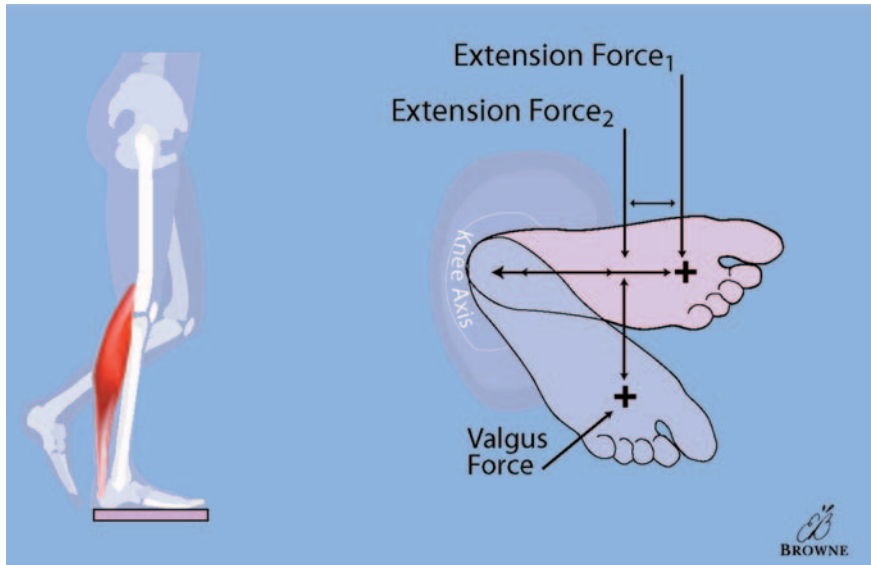
The foot segment is a very complex structure that depends heavily on muscle force to maintain its function as a stable ground contact segment. The function of the subtalar joint is to allow the foot to be stable when the ground surface is uneven. The subtalar joint has very complex motions that are discussed in full in Chapter 11. The motion through the subtalar joint is linked to mid-foot motion, especially the calcaneocuboid joint and the talonavicular joints. The importance of these joints for normal gait is to provide stability to the foot. This stability is controlled by muscles, with the tibialis anterior and the peroneus longus working in opposing directions, and the peroneus brevis and the tibialis posterior working in opposing directions. These muscles are primarily responsible for providing mediolateral stability. The long toe flexors and extensors can significantly increase the length of the foot segment by stiffening the toes so they also become a stable part of the foot segment.

Knee

The knee joint connects the thigh and shank segments, and its primary role is allowing the limb to shorten and lengthen. This function greatly improves the efficiency of gait. If the limb is given no ability to change its length, the vertical movement of the center of gravity would be approximately 9.5 cm compared with 0.5 cm in normal functioning gait. This decreased vertical oscillation represents an energy savings of approximately 50%.¹ The primary knee extensors are the vastus muscles and the rectus femoris. The primary knee flexors are the hamstring group including semimembranosus, semitendinosus, biceps femoris, and gracilis. The secondary knee flexors are the gastrocnemius and the sartorius. The only single joint knee flexor is the short head of the biceps; however, all the vastus muscles are single joint knee extenders.

At initial contact, the knee is slightly flexed approximately 5°. With the knee in almost full extension, the step length is maximized; however, with slight flexion, the knee is ready to absorb the shock of the impending weight transfer. At foot contact, the vastus muscles and the hamstring muscles all tend to be contracting in an isometric contraction to stabilize the knee joint. During weight acceptance, the knee flexes approximately 10° to 15°, allowing the HAT segment to move forward over the supporting foot without having to raise the HAT segment. In middle stance phase, the knee gradually goes into extension again to maintain the height as the mass moves forward on the planted foot. The movement in middle stance phase tends to be largely passive, controlled only by the eccentric gastrocnemius contraction. This phase of knee extension is controlled by the calf muscles throughout the influence of the knee extension–ankle plantar flexion couple (Figure 7.23). The moment and power produced in the knee in stance phase is minimal, with early extension moment and a later stance phase flexion moment predominating (Figure 7.24). In late stance phase, the knee starts rapid knee flexion,

Figure 7.23. Knee control in normal gait is mainly controlled by the gastrocnemius through its control of the plantar flexion–knee extension couple; this means the ground reaction force can be controlled by the degree of ankle dorsiflexion during gait to increase or decrease the knee extension. The efficient function of the plantar flexion–knee extension couple requires that the foot be aligned with the knee axis, and the foot has to be able to generate a stable moment arm. If the foot is externally rotated relative to the knee joint axis, the extension moment arm shortens and the knee valgus moment arm lengthens. Therefore, the gastrocnemius is less effective in controlling the knee joint in flexion–extension, and it places an increased valgus stress on the knee.



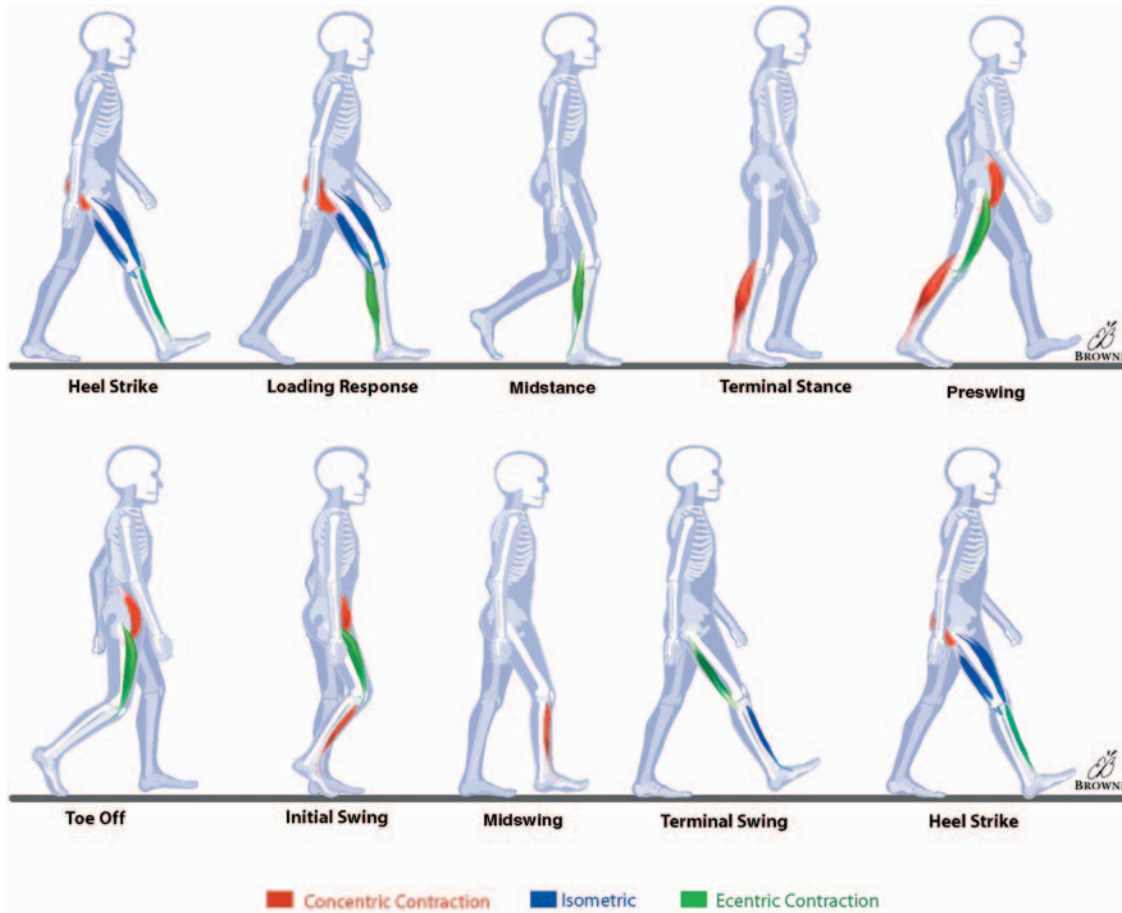
coordinated with the ankle starting plantar flexion and the heel rising off the ground. This knee flexion is passively produced by momentum of the forward movement of the hip joint, the vertical vector of the plantar flexors push-off burst, and the initiation of the hip flexor power burst. All hamstring muscles are quiet during this aspect of toe-off, except for some mild variable contraction of the gracilis and the sartorius, and sometimes with the short head of the biceps. These muscles are the only ones that normally can provide active knee flexion in late stance phase, which is a period of time when the hip is flexing as well. As the knee flexion velocity increases, the rectus femoris starts contracting in preswing phase, with most activity at toe-off and the first 20% of swing phase. The rectus has an eccentric contraction to slow the velocity of knee flexion and transfer this momentum into hip flexion. At the time of peak knee flexion, the rectus muscle turns off and the knee extension begins as a passive motion of gravity working on the elevated foot and shank segment, as well as the momentum of active hip flexion. Enough knee flexion has to occur so the limb is shortened so that the foot will not strike the ground as it swings under the body segment. In terminal swing phase, the passive knee extension is increasing rapidly and the velocity of the knee extension has to be decelerated by an eccentric contraction of the semitendinosus, semimembranosus, and biceps femoris, which also act as hip extensors. These hamstring muscles now transfer force from the forward swinging foot and shank segment into hip extension. The hamstring muscles guide the hip and knee into proper alignment for initial contact. It is at this period of time where control of hip and knee flexion by the hamstring muscles is crucial in the control of step length.

There are some other secondary muscles functioning at the knee, such as the fascia latae and the biceps femoris, which assist with rotational control and valgus stability. The semimembranosus and the semitendinosus with the gracilis may assist in controlling internal rotation of the tibia and varus instability. However, most of these forces are controlled by the ligamentous restraints in the knee joint.

Hip

The hip joint is the only joint with significant motion in all three planes during gait. The hip is also a principal power output joint along with the ankle

A



B

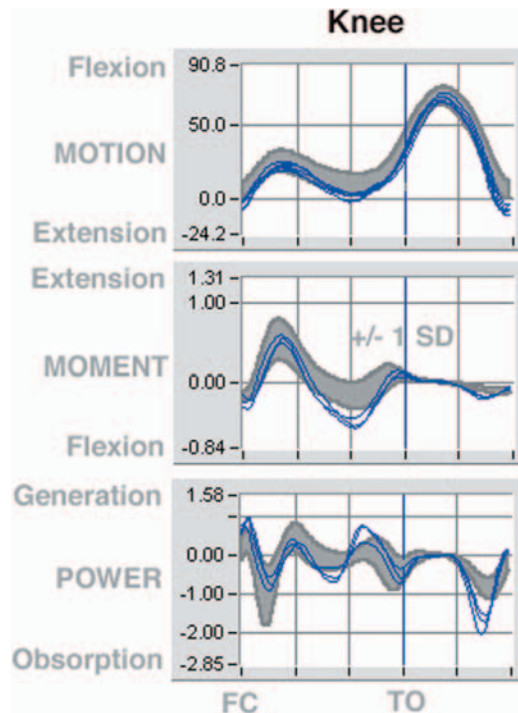


Figure 7.24. Complete control of the knee includes stabilizing function of the hamstrings and quadriceps, especially at foot contact, which is provided by isometric contraction, a hip extensor that uses momentum to extend the hip and knee at the same time. In mid-stance and terminal stance phase, the gastrosoleus is the primary controller of the knee position. In swing phase, the rectus initially controls knee flexion through an eccentric contraction and the hamstrings use an eccentric contraction to decelerate the forward swing of the foot, thereby limiting knee extension (A). These motions are well demonstrated on the knee kinematics along with the normal moments and power absorption at the knee. Significantly more power is absorbed at the knee than is generated, demonstrating the fact that the knee's primary function is to provide stability and change the limb's length between stance and swing phase (B).

in normal walking. The position of hip flexion at initial contact significantly contributes to step length along with knee extension. At initial contact, the hip starts into extension under the influence of strong gluteus maximus contraction. Additionally, all of the hamstring muscles plus the adductors are active at initial contact and remain active during weight acceptance phase. This forceful hip extension provides a large hip extension moment in early stance phase and a power output to lift the forward falling of the body. Also, at initial contact and in weight acceptance, the abductor muscles are active to contract and hold the center of gravity in the midline. There is an initial hip adduction motion in weight acceptance followed in midstance and terminal stance with gradual abduction. In mid- and terminal stance, the hip abductors and extensor muscles are relatively quiet, with the fascia latae being consistently active. Middle stance is a time of low-level muscle activation as momentum provides primary stability with only minimal control by the fascia latae. During terminal stance and preswing, the adductor muscles become active and act as hip flexors and adductors. In terminal stance, the hip flexion is again initiated, which can occur passively as an effect of the momentum of the body moving forward off the planted foot and the forceful contraction of the ankle plantar flexors. This force provides transfer of momentum from knee flexion into hip flexion by the rectus as the rectus activates to decrease the acceleration and control the magnitude of knee flexion (Figure 7.25). The other alternative is a concentric contraction of the primary hip flexors, which include the iliopsoas muscles. Also, the secondary hip flexors, including the gracilis, adductor longus, and brevis, may be active.

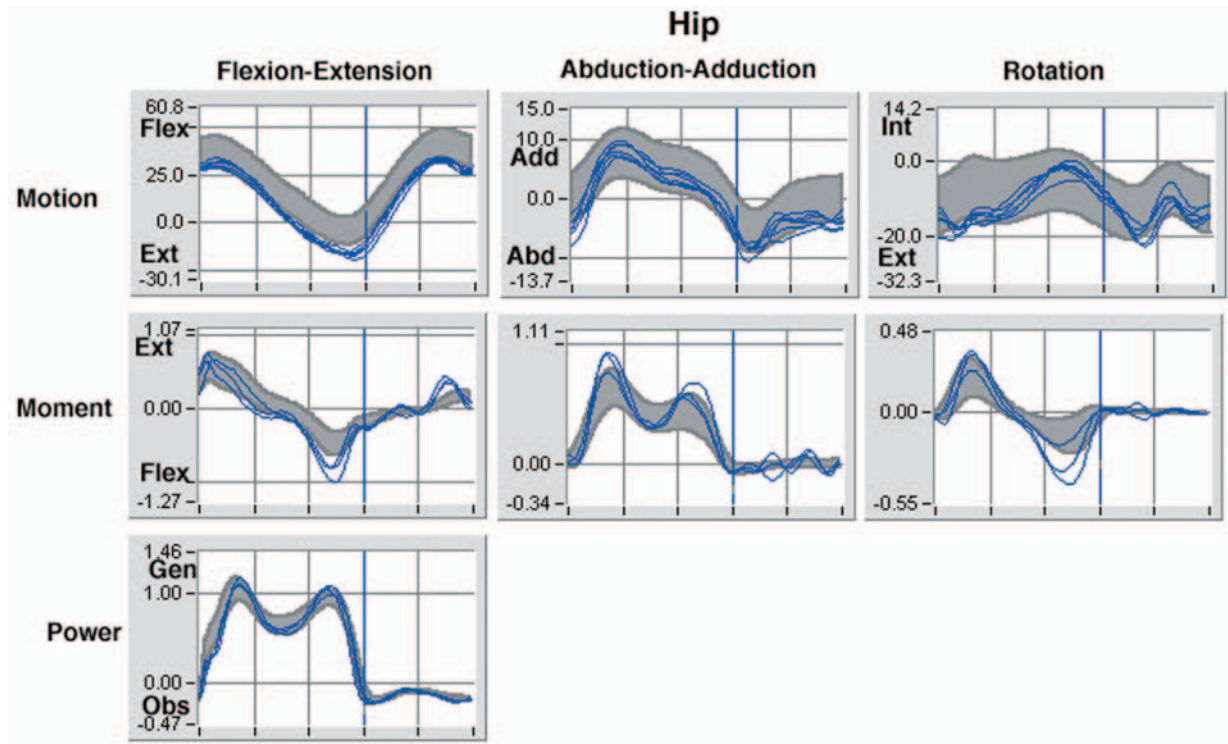
During swing phase, there is gradual hip adduction correlated with hip flexion. In general, the hip flexors adduct and internally rotate and the primary extensor muscles abduct and externally rotate the hip (Figure 7.26). The control of the rotation is not well understood. Early stance phase is a major time of power generation at the hip, second only to the late stance push-off power burst of the gastrocnemius at the ankle to provide the force, which propels the body forward.

This power is primarily generated from the gluteus maximus extending the hip as momentum is driving the forward-falling body. During midstance, there is little power absorption or generation; however, in terminal stance and preswing, the power burst occurs secondary to the active force output to generate forward motion of the leg through hip flexion. In middle swing, there is very little muscle activity; however, by terminal swing, the hip extensors, especially the hamstrings and gluteal muscles, are again becoming active to decelerate the forward swing of the shank and foot, and transfer that force into hip extension.

Pelvis

The pelvis moves through space in a motion akin to swimming, with a combination of pelvic anterior and posterior tilt, pelvic obliquity, and pelvic rotation (Figure 7.27). The pelvis articulates superiorly at the lumbosacral junction in the gait model discussed here. The motion of the pelvis in current clinical calculation algorithms is considered to move relative to the room coordinate system and not relative to the lumbosacral junction. All other motions distal to the pelvis are relative to the immediate proximal segment. The pelvis is a very confusing segment because it is articulated by three other segments, two thighs and the HAT segment. This means that the pelvis has a segment cycle of a stride and not a step, as each of the limbs has. Motion of the pelvis may be presented as a right step and a left step motion cycle; however, this is presenting the same data only in a different order and is quite different than the data presented for instance at the knee joint for right and

A



B

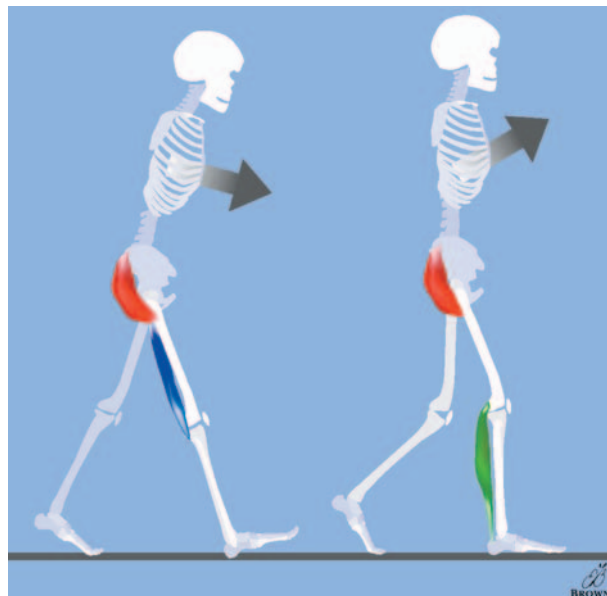


Figure 7.25. Because the hip has free three-dimensional motion, it requires muscle control in each of these dimensions (A). The muscle that controls sagittal plane motion at foot contact and weight acceptance is primarily the gluteus maximus, which provides concentric contraction (B). This muscle activity is the secondary power generator for motion, and when the gastrocnemius becomes inactivated, such as in the use of very high heeled shoes, the gluteus maximus becomes the primary power generator. Hip flexion in terminal stance phase is produced by the gastrocnemius and the hip flexors. Deceleration of hip flexion in terminal swing phase is controlled by the eccentric contraction of the hamstrings.

left steps. Another way to present motion data of the pelvis is to present it as half-cycle data from right heel strike to left heel strike and from left heel strike to right heel strike. This presentation presents two different data sets and allows an assessment of the symmetry of pelvic motion. Again, the difference between these two graphic presentation modes should be understood when looking at the data. This same problem of how to present motion relative to the gait cycle also applies to the trunk segment and the head segment.

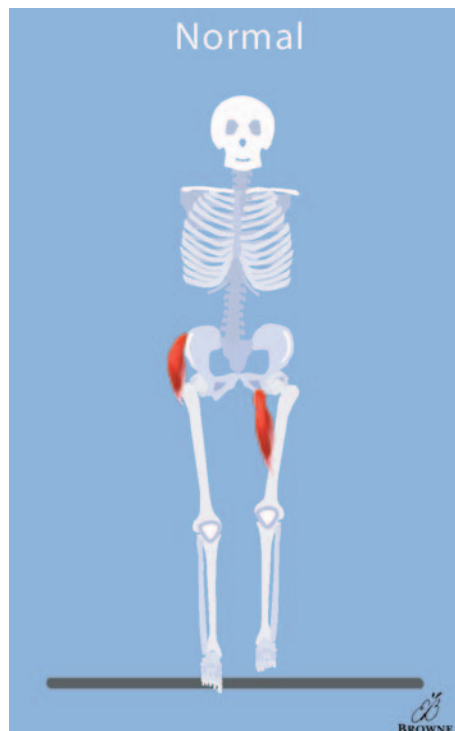


Figure 7.26. Coronal plane motion is controlled by an isometric contraction of the gluteus medius in early stance phase and by adductor contraction in initial swing phase.

Pelvic motion at initial contact on the right is rotated right side forward, then slowly rotates into maximum left side forward at left heel contact, and then back again to full right side forward at right heel contact. Therefore, pelvic motion has one rotation cycle during each stride with the normal total rotation being less than 10° , and this rotation increases with increased walking velocity. Pelvic tilt follows the swing limb, meaning that the posterior pelvic tilt is maximum at foot contact, then as the opposite limb starts hip flexion, the pelvis follows into anterior pelvic tilt, followed by posterior tilt maximum again at toe-off on the opposite side. Pelvic tilt therefore goes through two rotation cycles with each stride concurrent with the swing limb. Normal total range of pelvic tilt is less than 5° , but also increases with increasing speed of walking. Pelvic obliquity is neutral at initial contact. During weight acceptance, the pelvis drops on the opposite side, reaching a maximum pelvic drop in early midstance, then the pelvis starts elevation back toward the neutral position by initial contact on the contralateral side. The pelvic obliquity makes one rotation cycle in each stride with a range of motion of less than 5° (see Figure 7.27).

HAT Segment

The HAT segment is very complicated and the interactions are not well worked out. Motion of the HAT segment tends to be similar to the pelvic segment (Figure 7.28). The trunk muscles serve an important function of maintaining the trunk stable much in the same way the ankle is stabilized by muscles connecting at the foot. These trunk muscles include the abdominal muscles and the paraspinal muscles used for general postural control. The motion of the arms can have a significant impact on the stability and position of the center of gravity in the HAT segment. The arms swing reciprocally with the swinging leg, meaning when the right leg is in forward swing, the left arm is swinging forward (Figure 7.29). If there is a major problem that limits motion in the upper extremity, the contralateral lower extremity will demonstrate the mechanical impact during gait. Also, the head is a separate segment within the HAT segment, which can be positioned so as to impact the center of mass. However, the head postures are more likely to be used for balance and receiving sensory feedback than for altering the center of mass of the HAT segment.

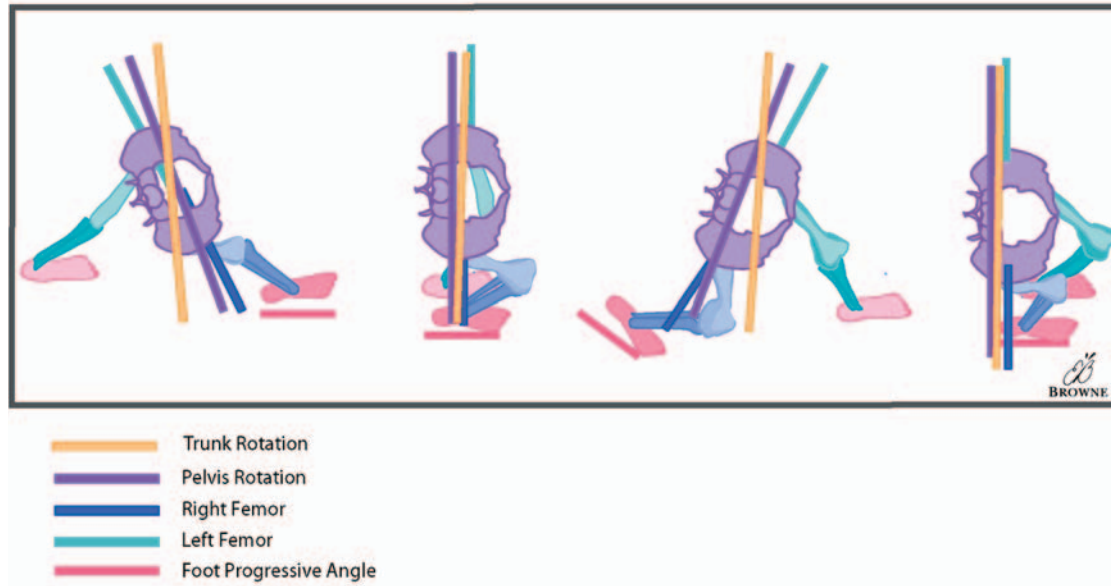
A Simplified Understanding of Normal Gait

The foregoing description of the function of all the segments and joints during gait has been greatly simplified compared with current full understanding. The mechanical understanding of the whole body will simplify this structure even more, but it provides a framework to apply a mechanical clinical understanding to pathologic gait that can be helpful in formulating treatment options.

Simplified Joint Functions

The body is seen as a cargo segment setting on the motor train. The motor train element is made up of linked, rigid segments. The foot is the segment in contact with the ground and its main function is to make a stable, solid connection with the ground and have mechanical lever arm length in the plane of forward motion and at right angles to the ankle and knee joints. The ankle joint is the primary motor output of energy and power for forward motion of gait. Also, the ankle is the primary stabilizer for postural stability. The calf is a straight, rigid segment between the knee and ankle joints. The knee is a hinge joint whose main function is to allow the limb to lengthen and shorten, and the knee needs to be a stable connection between the shank

A



B

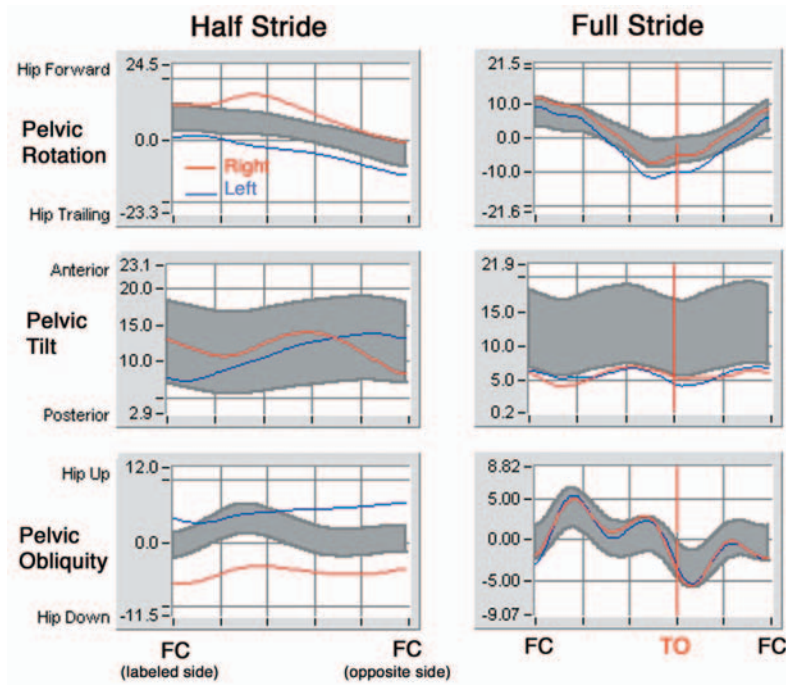


Figure 7.27. The most significant motion of the pelvis is in the transverse plane, although there is motion in both the sagittal and coronal planes as well (A). Transverse plane control of the limb starts with the foot fixed on the floor; however, as toe-off occurs, some internal rotation occurs that has to be accommodated at the pelvis and hip. The cycle of the pelvis does not have a right and left cycle because it is one unit without an articulation in the middle. The cycle is half as long as the stride in the limbs; therefore, we prefer to look at right and left half cycles (B); this allows a comparison of right to left symmetry rather than plotting the same data twice, only out of phase, which is what occurs with full cycle plotting.

and thigh segments. The knee joint axis and ankle joint axis should be parallel and at right angles to the forward line of progression. The thigh is a straight, rigid segment with torsional alignment allowing the knee to have its axis at a right angle to the forward line of progression. The hip allows motion in three dimensions. The hip is the secondary or alternate source of power output for forward mobility. At initial contact, hip flexion combined with knee extension define the step length. The hip also has to keep the pelvis and HAT segment stable with minimal motion. The role of the pelvis is to have enough motion to accommodate the hips so as to decrease the motion of the center of mass of the HAT segment.

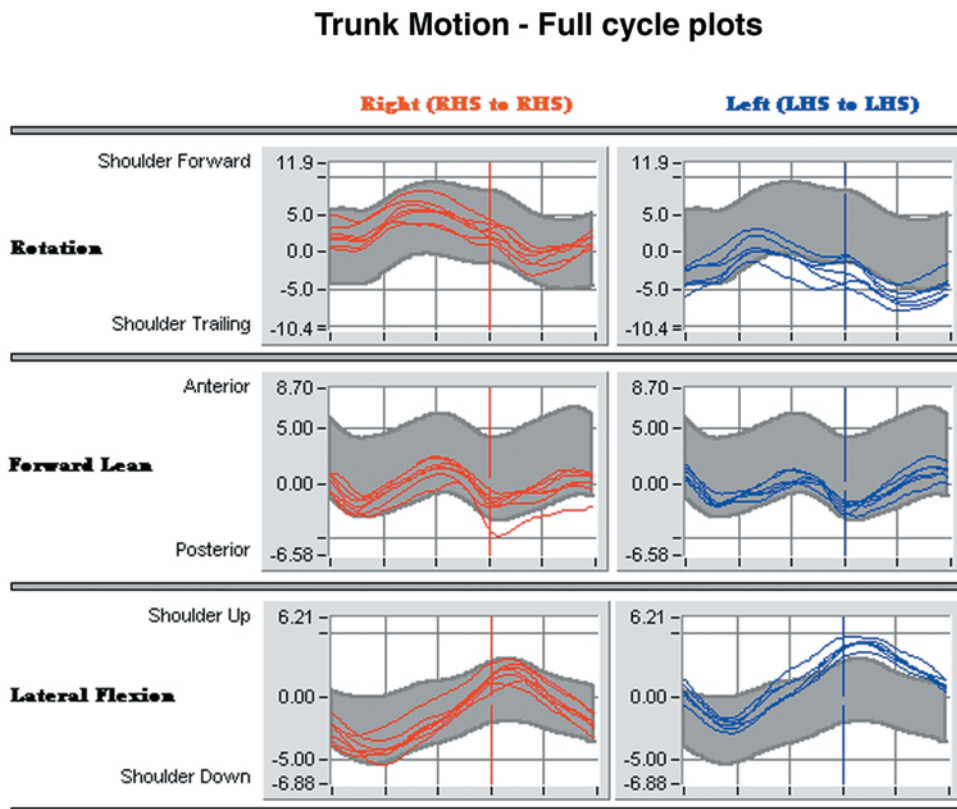


Figure 7.28. Movement of the trunk as defined by the top of the shoulders and chest follows the motion of the upper extremity and is opposite of the pelvis; thus, the trunk rotates forward during ipsilateral stance and contralateral swing phase (Figure 7.27A), just the opposite of the pelvis, that rotates forward with the swing limb. Motions in the other planes are also out of phase with the pelvis. This opposite direction motion of the trunk and pelvis works to decrease the total motion of the center of mass and therefore decreases work required for walking.

Simplified Cycle Functions

Using these very simplified rules of gait, this mechanical understanding can be combined into a full description of the gait cycle. At initial contact, the heel strikes with the knee being almost extended and the hip flexed. The pelvis is rotated forward and tilted posteriorly. During weight acceptance, the foot comes to foot flat with solid contact with the ground. For weight acceptance, the leg initially shortens with knee flexion and ankle dorsiflexion, and hip flexion occurs to slow the forward fall of the HAT segment. This forward fall is primarily controlled by the hip extensors. The knee is stabilized by the hamstrings and the vastus muscles. The shock absorption function also occurs with knee flexion, allowing the leg to shorten, and the energy is absorbed through the eccentric contraction of the gastrosoleus, vasti, and hamstring muscles. In middle stance, only the gastrosoleus has a low level of eccentric contraction with momentum carrying the body forward. In terminal stance, the gastrocnemius and soleus contract with a concentric contraction to produce plantar flexion, causing heel rise and increasing knee flexion, which allows the leg to shorten to accommodate for the rapidly increasing plantar flexion. Hip flexion also starts under the impact of this gastrosoleus push-off contraction. Hip adductors contract to aid hip flexion and adduction in terminal stance. In preswing, the knee is rapidly shortened under the control of the eccentrically contracting rectus muscle. Initial swing phase is marked by the knee shortening to allow the foot to swing through. Also, at preswing and in initial swing, hip flexor power is increased to produce power causing forward swing of the limb at the hip joint. In midswing, there is little muscle activity as most of the motion is produced by momentum. In terminal swing phase, the hamstring muscles start eccentric contraction to decelerate the knee extension and hip flexion to provide stability

of patients and trying to understand the results of the observed changes. It is even more difficult to try to understand the neuroanatomic anatomy and alterations that give rise to specific patterns of gait. Because there currently is not a good neuroanatomic explanation of how the central program generator works, understanding its response to pathologic insults is even more difficult. Therefore, these pathologic changes will be explained on the basis of dynamic motor control theory, which provides understanding of why patterns develop as the system is pulled toward chaotic attractors. For a full description of dynamic motor control, refer to the section on motor control. This method of making predictions based on dynamic motor control theory is similar to techniques used to predict weather patterns. However, in this situation, the impact of growth and development upon a neuromotor system with abnormal control is being predicted. With this theoretical approach, the predictions improve with increased information and the predictions are much better in the short term than long term. Short-term and smaller interventions are easier and more reliable to predict than long-term outcomes and the results of larger interventions. Therefore, the goal is to obtain as much information about each of the neurologic subsystems and the mechanical components as is possible.

Balance

Balance is an absolute requirement for safe ambulation. There are children with relatively good ability to make steps and to hold onto a walker but who have no protective response to falls. These children do not even realize they are falling and fall with a pattern often described as a falling tree. Children with this falling tree pattern, or children who consistently fall over backward, cannot be independent ambulators even with a walking aid unless it is fully supported with a design similar to a gait trainer.

As many young children start walking, problems with balance emerge. Some investigators believe that balance is the primary subsystem that precludes walking in a normal 8-month-old baby. When the baby's balancing system matures, he is ready to become a toddler. This pattern also seems to persist in many young children with diplegia who continue long term with a toddler pattern gait. If the balance system is limited in its ability to keep the body stable in an upright position, the secondary response is to cruise along stable objects or to hold onto objects that can be pushed, such as push toys or walkers. If children are able to walk without holding on, balance feedback is enhanced by keeping the arms in the high guard or medium guard positions. This arm-up position allows using the arm position to alter the center of gravity in the HAT segment and works with the same mechanical principle as the long pole that is used by high-wire walkers at the circus. Another adaptation for poor balance is to use momentum in such a way that children can walk when they are going at a certain minimal speed, but when this velocity decreases or they try to stop, they fall over or have to hold onto a stable object. This adaptive response to poor balance is similar to that which is normally used when riding a bicycle.

Poor balance can be assessed by a decrease in the gross motor function measure and high variability in step length and cadence. Also, there is increased shoulder range of motion and increased elbow flexion reflecting the high guard arm position. Children with severe ataxia often have high variability of hip, knee, and ankle motion patterns on the kinematics. Poor stability, primarily due to foot positioning problems such as toe walking, planovalgus, or equinovarus, also magnifies the central balance problems.

The Impact of Growth and Development

The balance system usually matures rapidly in the first 3 years of life, often making substantial observable gains every 6 months. Significant gains continue in the second 3 years, but usually in a less dramatic fashion. Slow improvements often continue into middle childhood, reaching full balance maturity at 8 to 10 years of age. Usually, during the adolescent growth spurt, balance appears to be deteriorating; however, this is only the appearance of the adolescent clumsy stage that most normal teenagers endure. By several years after the completion of growth, balance will return to a similar level of middle childhood; however, because these children are much heavier and taller, falls are more painful and they may not run along, fall, and then get up again with the same vigor with which they did at age 7 years. Also, for teenagers who are 17 years old, it is not socially acceptable to be repeatedly falling, especially in public.

Interventions

The primary interventions for addressing balance deficiencies are therapy-based techniques that will stimulate children's balance systems. These activities include walking on an edge, walking slowly, and doing activities on one foot, such as hopping. These activities have to be closely matched to the children's immediate abilities. It is important that children be provided with an appropriate aid for walking, usually a walker for young children, and then switched to forearm crutches in middle childhood. Also, crutches or canes used in therapy can stimulate balance, even if these devices are not functional for day-to-day ambulation. It is important to provide as stable a base of support as possible, which is usually accomplished by adding foot orthotics to young children. The orthotic should hold the foot plantigrade and correct planovalgus foot deformities. The first orthotic should be a solid ankle AFO to stabilize the ankle and foot so that children can focus on control of the hips and knees. Stable shoes with good, flat soles should also be used.

Motor Control

Motor control is the primary central program generator function that directs the muscles to contract at the appropriate time. Motor control function is complex and difficult to comprehend, especially considering that only one muscle, the gastrocnemius, has approximately 2000 motor units. Each of these motor units has to be contracted considering the position of the knee and ankle, the velocity of the contraction, the specific fiber type, and the time of the gait cycle. Adding this complexity to the balance system explains why the largest part of the central nervous system is taken up with controlling the peripheral motor system. When this system has a pathologic defect, it tries to maintain control, but generally at a level of less detail. A simple example of this effect occurs in the upper extremity of a hemiplegic hand in which individual fine motor control of finger flexion is lost; however, the child maintains gross grasp finger flexion in which all the fingers and thumb flex at the same time. Sometimes, this even extends to mirror movements on the other side so when the fingers flex on the less-involved side, the fingers also flex on the more-involved hand.

As motor control is decreased, many changes occur. The changes of motor control are definitely drawn to patterns that appear to be attractors for specific limitations. A pattern of simpler movements, often based on mass movement similar to the mirror motion described in the hand, is the most

common alteration. Athetosis, dystonia, chorea, and ballismus are other movement patterns. A full discussion of these patterns occurs in the chapter on motor control (Chapter 4). The tendency toward mass movement initiates significant secondary adaptive changes. This pattern of decreased motor control often has increased muscle tone, which stiffens the system to make control easier. The increased tone also tends to cause muscle fiber shortening, which decreases the joint range of motion, again decreasing variable options available for motor control. Often, the motor control that is available seems to focus on the major joints and gross function at the expense of small joints and small motions. This means the motor control system is able to control motion of the hip, knee, and ankle, but may not be able to control foot position, leading to a higher rate of foot deformities. The system also does better with single-joint muscles than with multiple-joint muscles. Again, there is much less complexity in controlling a muscle that only affects one joint than with a muscle that affects two or three joints simultaneously. An example is the quadriceps muscles, where the rectus often has problems with motor control; the vastus seldom has problems related to motor control. Because many of the multiple-joint muscles work as body stabilizers or provide body stiffening, in the face of decreasing motor control these muscles tend to contract too much and add significant stiffness to the system.

Assessing motor control requires several measures, but a decrease in the fourth dimension in the GMFM is a good indicator of motor control problems. Also, in the physical examination, the individual muscle motor control gives a measure of the function of the central program generator, and the presence of mass movement or the confusion tests indicates increasing motor control problems. The confusion test is positive when children can dorsiflex only in concurrence with hip and knee flexion. The assessment of athetosis usually demonstrates high variability around a single cluster, especially in trunk motion and upper extremity motion. The movement pattern of dystonia often presents with variability around two or three clusters. Often, there is the appearance of motion being drawn to two separate attractors.

The Impact of Growth and Development

Motor control is variable in its development. By the time children are 6 to 7 months old, the central program generator already consistently makes stepping motions if the children are placed on the floor and held so they do not fall. The fine motor control of the feet and the upper extremity come on slowly, following a pattern similar to balance development. The first 3 years have the most rapid development, then very significant development continues over the subsequent three years. By middle childhood, motor development reaches its maturity; however, new motor skills can be learned throughout life.

Athetosis is often present first as poor balance, then the movements start in the second and third years. By age 3 to 5 years, the pattern is well set and seems to change little. Dystonia, when it is mild, may be seen first in the 3- to 5-year-old age range and is often stable during middle childhood. Although there have been no published data, our experience with children has been that the dystonia tends to get worse around adolescence. This increased severity does not seem to recede as the individuals enter young adulthood.

Interventions

Intervention for motor control pathology is similar to balance in that the first intervention should be therapy using a teaching model similar to teaching children to be dancers or ice skaters. This therapy involves cognitive understanding and repetitive performance of a task to be learned. This therapy has

to be within the context of the children's physical abilities, meaning that some children have too much damage to the central program generator to learn to walk and no amount of teaching will get them walking. Also, because of the tendency to focus on major joint control over small joint control, providing stability of the small joints, especially the foot with the use of orthotics, is an important aspect of the first stage. This initial stabilization can be followed later by surgical stabilization of the foot if indicated. Assessing when the adaptive mechanisms have become a pathology in themselves, and addressing these pathologic adaptations, are important parts of the treatment. For example, the stiffness imparted by an overactive rectus femoris may be needed in some children, but in others, it is a definite impairment in its own right. Children who walk very slowly with a walker as household ambulators only, have scores on the fourth dimension of the GMFM of 35%, and have significant toe drag, will likely gain more from the stiffness imparted by the rectus than if this stiffness were removed. Many of these children will recruit the vastus to again provide the knee stiffness because of their need for support in stance. On the other hand, children who are independent ambulators at 8 years of age, but are consistently dragging their feet because the rectus is active too long in swing phase, will respond very well to having the impairment of the knee stiffness removed. When planning treatment, the level of motor control has to be considered in the decision making to determine if the apparent problem is adding to or further impairing children's overall function.

Interventions for athetoid gait patterns are mainly directed at stabilizing joints, such as the feet if the problem is instability. Surgery or other active interventions are seldom of much help in individuals with athetosis unless they have associated spasticity that is causing secondary problems. The spasticity is beneficial in athetosis as a means of placing a shock absorber or brake on the movement disorder. With dystonia, joint stabilization is the only viable option to improve gait. For both athetosis and dystonia, finding the correct walking aid with functioning arm support often requires a great deal of trial and error.

Motor Power

Gait requires energy output that has to be expended by the muscles to create motion. This motion requires the cardiovascular system to bring the energy to the muscles. Weakness can come from problems in any of the energy production pathways. When the problem of decreased energy available is expressed as muscle weakness, an almost normal gait pattern may be preserved through the use of increased motor control to improve efficiency. This is what occurs in children with primary muscle disease, such as muscular dystrophy. These individuals have an extremely energy-efficient gait when oxygen consumption is measured.³⁷ These same children, though, have very limited ability to walk. Children with CP may also have weakness due to small muscle size from spasticity and decreased energy delivery secondary to poor conditioning, but they can seldom make up for these deficiencies with increased motor control. Instead, it is much more common for children with CP to have increased energy cost of walking as a way of compensating for poor motor control and poor balance. Adding stiffness through increasing spasticity and co-contraction of the muscles increases the energy costs of walking; however, these changes provide a functional benefit of lowering the demands on the balance and motor control subsystems. This combination of muscle weakness and cardiovascular conditioning often coalesces to form a milieu in which individual children are drawn to either primary wheelchair

ambulators or community ambulators with assistive devices (Case 7.3). Young adults who primarily ambulate with wheelchairs in the community will lose cardiovascular endurance to the point where community ambulation is no longer possible because of weakness. Therefore, forcing these individuals into wheelchairs further exacerbates the loss of endurance. Individuals who primarily walk will stay well conditioned and usually continue walking. In intermediate ambulators, there also seems to be a psychologic factor that feeds into the process. If individuals have a strong drive to walk, they will continue walking, but if the drive to not walk is stronger, it will soon be reinforced with poor endurance from not walking. Motor power is measured in individual muscles using the motor strength scale from the physical examination. Overall oxygen consumption is measured during walking, and this is combined with the heart rate response as the best measure of children's cardiovascular condition and the energy efficiency of walking.

Impact of Growth and Development

The strength of children's muscles relative to their body weight is greatest in young children, and this strength ratio decreases gradually as they grow into middle childhood. There is rapid decrease in the strength ratio during adolescence. Also, as children with spasticity grow, muscles have less growth than would normally occur, therefore leaving these children even weaker. Cardiovascular endurance does not usually become an issue until the pre-adolescent or adolescent stage. Children in early and middle childhood tend to want to be out of the wheelchair and be as active as their physical ability allows. Then, a combination of factors come together to push these children into either primary wheelchair ambulation or primary ambulation without a wheelchair in the community. The factors that occur just before and during adolescence include the children's weight, physical ability, psychologic drive, family structure, amount of expected community ambulation, and the physical environment of the community.

Interventions

The primary interventions are to maintain cardiovascular conditioning, especially at the adolescent stage, through some activity that the children enjoy. This plan works best if children start at an early age. For example, a child who learns to swim at age 5 or 6 years and continues to swim during middle childhood tends to be more comfortable with this activity and will therefore improve his physical conditioning through swimming. If an attempt is made to teach children to swim at age 15 years for physical conditioning, they will often be very resistant because of the difficulty of becoming comfortable in the water. Also, working on strengthening exercises for children with spasticity does no harm and actually has been documented to provide some benefit.¹⁴

Musculoskeletal Subsystem: Specific Joint Problems

As was noted in the description of normal gait, the musculoskeletal subsystems function as a series of mechanical components linked by joints. Each of these segment components and the connecting joints has a specific role in gait. As problems occur with gait, these mechanical subsystems are the place where the adjustments occur. Again, there can be adaptive adjustments that accommodate for the problem at a different location, or the problem may be primary and the source of the problem requiring the adaptation elsewhere. Sorting out this impact is very important when planning treatment because secondary adaptations need no treatment, as they will resolve when the pri-

mary problem is addressed. However, there are situations where an adaptive secondary change over time can become part of the primary problem. An example of such a problem is the combination of toe walking with hemiplegia in young children. The mechanical system prefers to be symmetric, and in young children who have great strength for their body weight, if forced to toe walk on one side, will usually prefer to toe walk on both sides (Case 7.4). If children have a pure hemiplegic pattern and the unaffected ankle has full range of motion, an orthotic is needed only on the affected side. This orthotic will stop the toe walking on the opposite side as well. If the toe walking has been ignored in older children and they have been walking on their toes for 4 to 6 years, the unaffected side, even if there is no neurologic pathology, will have become contracted; therefore, they cannot walk feet flat comfortably. The adaptive deformity has now become a primary impairment in its own right and if surgical treatment is planned, the unaffected leg must be addressed as well.

Foot and Ankle

The foot has the role of being a stable segment aligned with the forward line of progression and providing a moment arm connected to the floor. The ankle provides the primary energy output for mobility and provides motor output for postural control, as well as being part of the shock absorption function during weight acceptance.

The Foot as a Stable, Stiff Segment

The primary role of the foot segment is to provide a stable, stiff connection to the ground during stance phase. The primary problems occurring at the foot are foot deformities that preclude a stable base of support. These deformities are mainly planovalgus, and less commonly, varus deformity. Another problem is the loss of stiffness of the foot segment, which occurs because of increased range of motion in the midfoot allowing for midfoot dorsiflexion, also called midfoot break. This combination of foot pathology leads to less stability of the foot as a stiff segment and further leads to less stable support with the ground by focusing the pressure into a smaller contact area (Case 7.5). The primary cause of foot deformities is poor motor control, which is added to by the mechanics forcing this deformity into progression. Foot deformities are discussed fully in Chapter 11. The degree of dysfunction caused by the foot deformity is best assessed with a pedobarograph, where only pressure on the medial midfoot would suggest a very severe foot deformity with poor mechanical function. Also, an assessment of the ankle moment often demonstrates low plantar flexion moment in late stance, but a high or normal plantar flexion moment in early stance. A foot that has lost its stiffness also cannot provide support against which the gastrocnemius muscle can work to provide push-off power.

Secondary Adaptations

When a foot is unstable, balancing and motor control subsystems are stressed and one response is to increase the stiffness at the proximal joint through increased tone and increased motor co-contraction, especially at the knee. The vastus muscles, as primary knee extensors, are usually activated to assist with maintaining upright posture with the knee in flexion as part of the crouched gait pattern. These secondary changes, especially in adolescents with greatly increased body mass, add to the pathomechanics causing a foot deformity to become more severe. Most often, the foot is the initial primary cause of the crouched gait pattern (Case 7.5).



Case 7.4 Charvin



Charvin, a 5-year-old girl, presented with the parents' complaint of toe walking. On physical examination she was noted to have Ashworth grade 2 tone in the left gastrocnemius, -5° of ankle dorsiflexion with both knees extended and knee flexion, and 3+ ankle reflex. The right ankle had 10° of dorsiflexion with knee extension, 15° with knee flexion, normal muscle tone, and normal reflexes. Examination of the remaining lower extremities was normal, and the left upper extremity had no increased tone, but seemed clumsier with rapid movements. Observation of her gait demonstrated a child with excellent balance, normal upper extremity arm swing, and bilateral toe strike with persistent bilateral toe walking. A diagnosis of hemiplegia was made and she had a full gait analysis, which demonstrated normal timing of the left tibialis anterior muscle (Figure C7.4.1). A diagnosis of

type 2 left-side hemiplegia was made, although she had significant toe walking on the right as well. This toe walking was felt to be compensatory for the left ankle equinus. An open Z-lengthening of the tendon Achilles was performed, and she walked with a flat foot strike. Over the next 10 years, she continued to have intermittent toe walking related to rapid growth spurts, and persisted with premature heel rise on the left. By the time she reached full maturity at age 15 years, she desired a final correction, and she had a gastrocnemius lengthening that improved her premature heel rise and high early ankle plantar flexion moment on the left side. In addition to having decreased early dorsiflexion peak and premature plantar flexion, which improved bilaterally, she was able to slightly improve her push-off power generation on both sides (Figure C7.4.2).

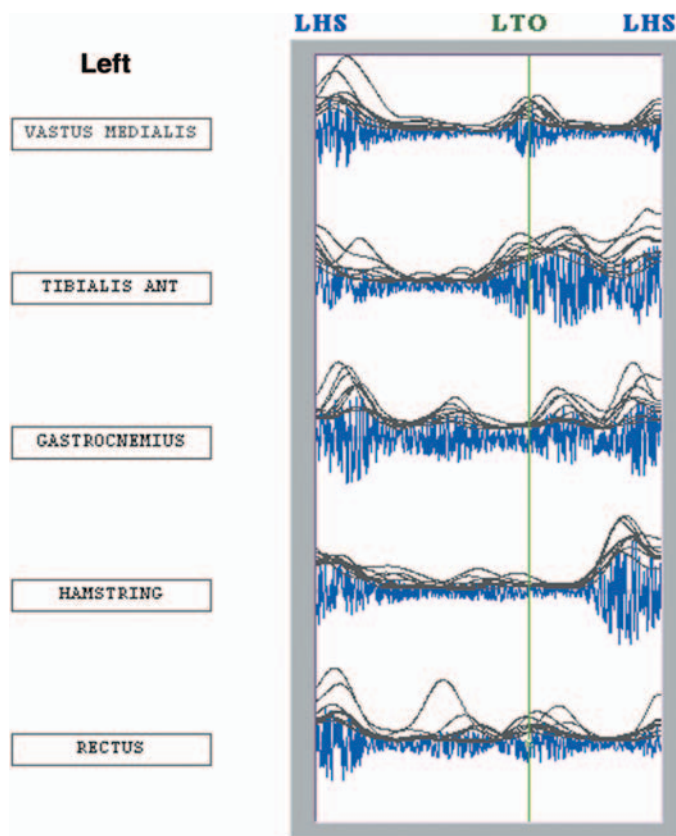


Figure C7.4.1

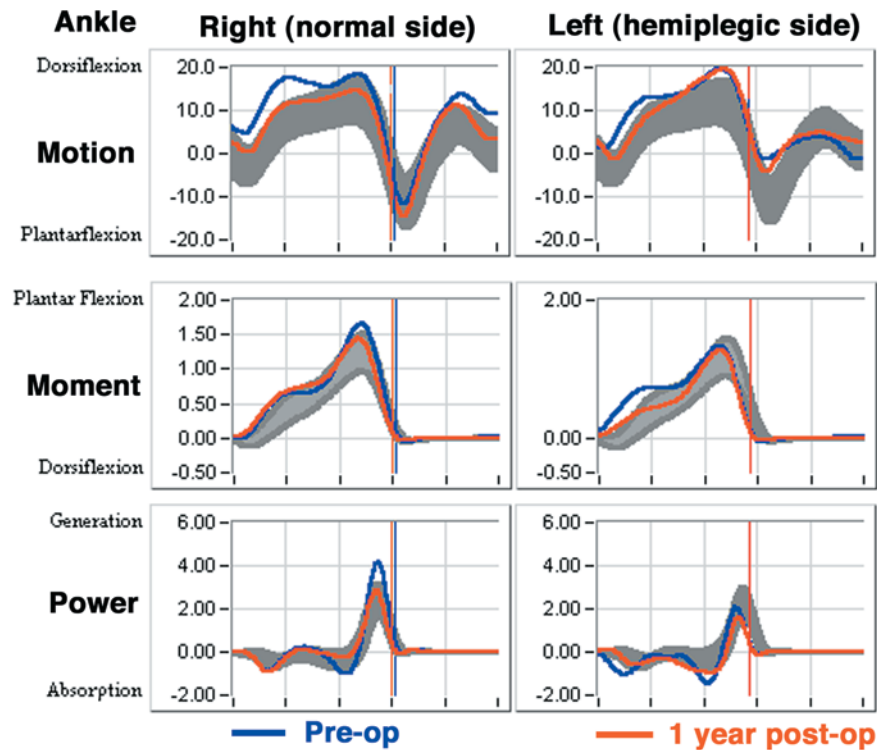


Figure C7.4.2

Treatment

In young children, the primary treatment of the unstable feet is the use of custom-molded foot orthotics, usually starting with solid ankle AFOs; then, if the deformities are not too severe, the AFOs can be articulated. However, if the foot deformity is severe, articulated orthotics do not work well because motion tends to occur in the subtalar joint. At some point, many of these children need surgical stabilization of the foot. There are many surgical options that are discussed fully in the chapter on the foot and ankle.

The Foot as a Functional Moment Arm in Contact with the Ground Reaction Force

The other major function of the foot, in addition to being a stable, stiff segment, is to be a moment arm upon which the ground reaction force can act; this means the foot has to have an alignment that is in line with the forward line of progression and at right angles to the ankle and knee joint axes. Torsional malalignment of the foot does not allow the power output at the ankle to have a moment arm on which to work. This torsional malalignment may have its primary etiology as part of the foot deformity. The planovalgus deformity may cause an external rotation of the foot relative to the ankle joint axis and the equinovarus causes internal rotation of the foot relative to the ankle joint axis. The torsional malalignment may also be due to tibial torsion, femoral anteversion, or pelvic rotation (Case 7.6). The alignment of the foot is best assessed by the foot progression angle on the kinematic evaluation. The source of the rotational malalignment is best determined by tibial torsion and femoral rotation measures on the kinematic evaluation compared with the physical examination. On the physical examination, femoral rotation with hip extension is assessed. Tibial torsion is



Case 7.5 Joshua

Joshua, a boy with asymmetric diplegia, walked with a posterior walker. By age 6 years, he was walking independently, although very asymmetrically, with extreme knee stiffness on the left. At that time he had a rectus transfer on the left, and he continued to do well until age 15 years. As he was going through his adolescent growth, he gradually developed more right foot planovalgus and external rotation, and complained of having increased knee pain with ambulation. He was placed in a ground reaction AFO but, because of poor moment arm due to the external rotation, this was of little help. The knee pain was believed to be due to high joint reaction force external valgus moment at the knee and high shear stress in the knee. The foot pressure demonstrated a moderate right planovalgus foot deformity with an external foot progression angle of 35° , although a weightbearing radiograph of the foot was nearly normal (Figure C7.5.1). He also had 45° of external thigh-foot angle on physical examination. Based on these data, the crouch and knee pain were thought to result from a combination of planoval-

gus and external tibial torsion. Also, a radiograph of his knee demonstrated mild increased knee valgus measuring 12° . The planovalgus was corrected with a lateral column lengthening and the tibial torsion with an osteotomy of the tibia (Figure C7.5.2). It was elected to leave the knee valgus because this was on the border of normal and due to secondary forces from the leg below. One year after the surgery, he was walking without knee pain and no orthotics; however, he still had a mild degree of knee valgus but with improved crouch (Figure C7.5.3). The right foot demonstrates a mild residual valgus deformity; however, the left foot is slightly overcorrected into varus (Figures C7.5.4, C7.3.5). The right gastrocnemius is still somewhat incompetent based on the prolonged heel contact or late heel rise on the right (Figure C7.5.4). To completely correct this deformity, a high tibial varus osteotomy would have been required. This demonstrates the typical occurrence of these deformities as an adolescent goes through the final growth, often with problems occurring at several levels, which combine to cause a severe problem.

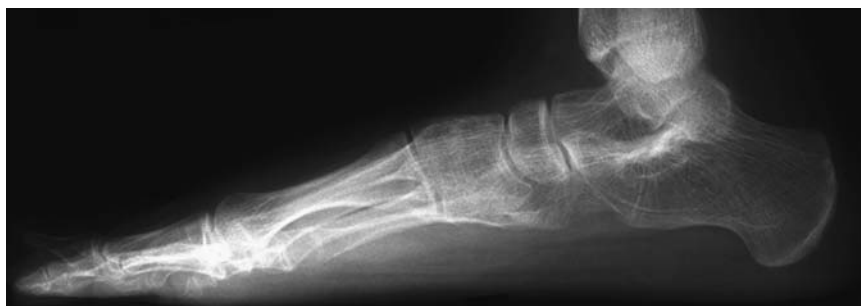

Figure C7.5.1

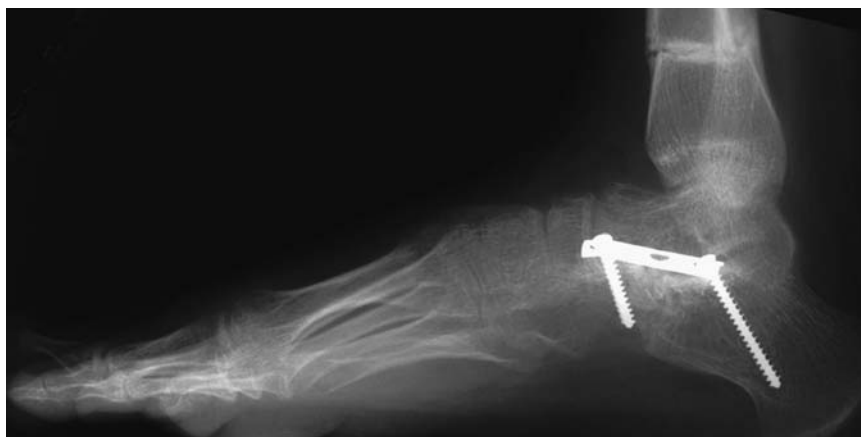

Figure C7.5.2

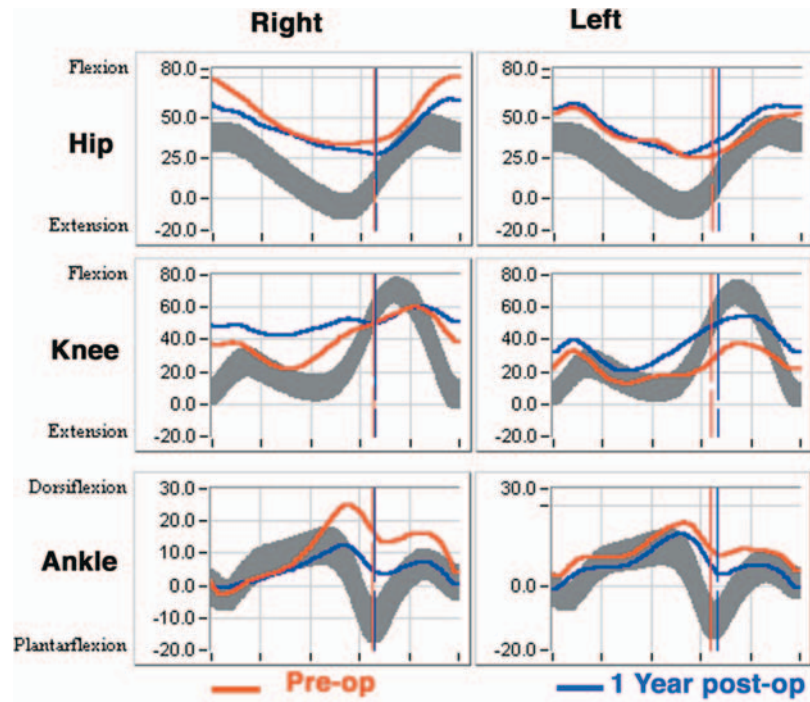


Figure C7.5.3

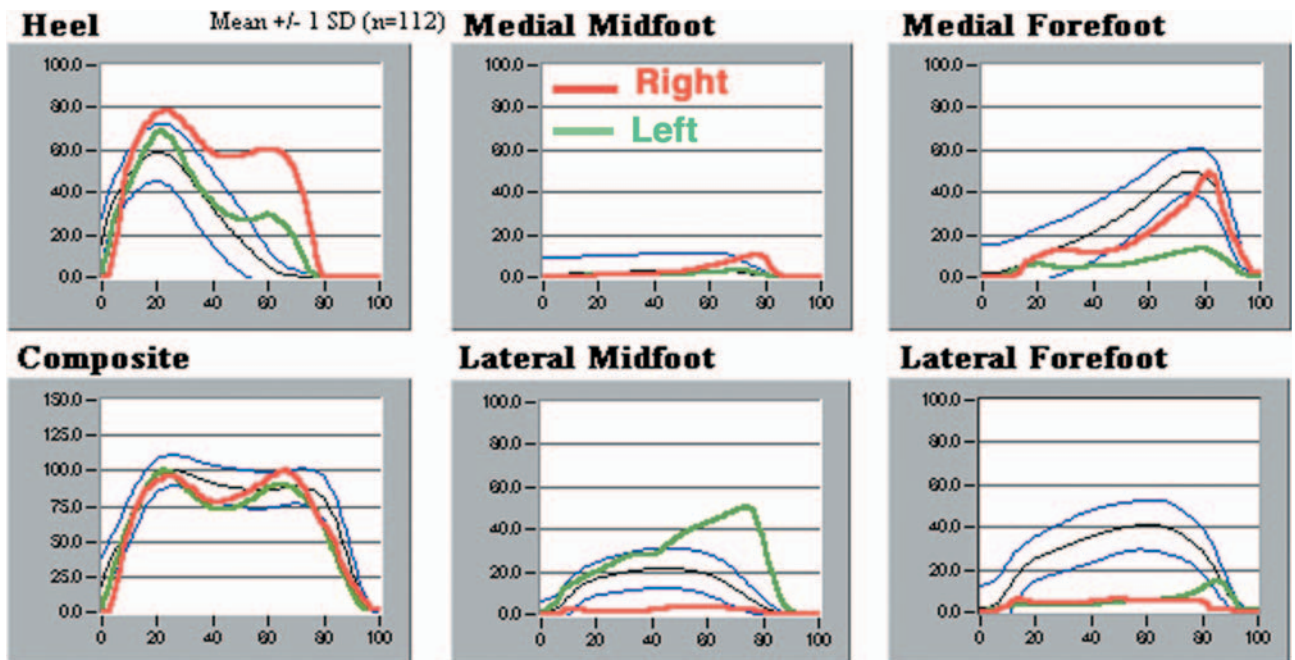


Figure C7.5.4

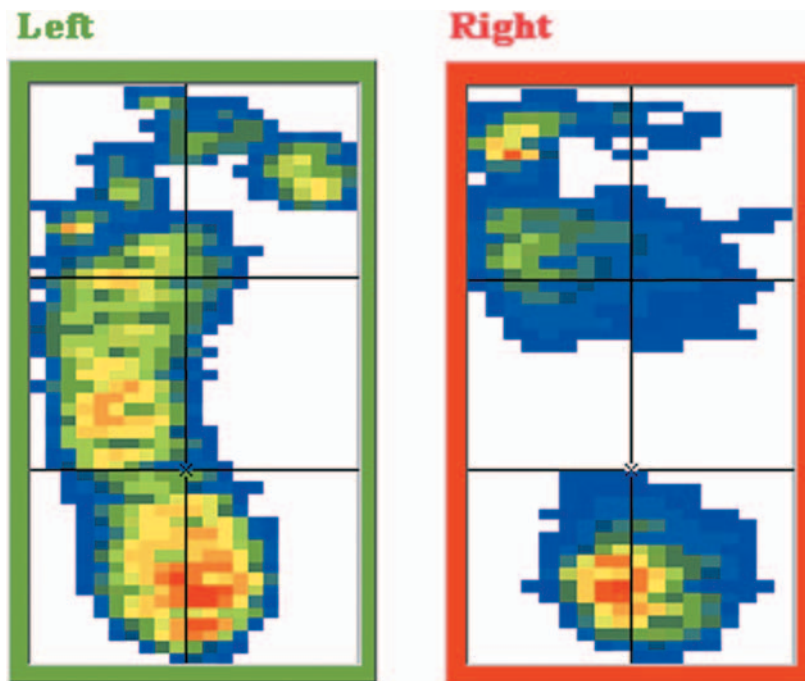


Figure C7.5.5

measured with a transmalleolar axis-to-thigh angle. In general, a normal foot progression angle is 0° to 20° external. Most individuals with CP do well until the angle is more than 10° internal or 30° external. The foot progression angle, which is more than 30° external, will rapidly start to have a negative effect on the moment arm, as an effective length of the moment arm rapidly shortens. This number is due to the length of the moment arm being the length of the foot times the cosine of the rotation angle (Figure 7.30). Therefore, changes of the first 20° to 30° cause minimal change in the affected moment arm.

Secondary Adaptations

As the moment arm becomes less effective, the plantar flexion moment generated by the ankle decreases. As with foot deformities, the same secondary effects of increased stiffness and increased co-contractions occur. There may also be a residual moment, which tends to cause the deformity to get worse. In a foot with severe external rotation, the moment arm in the direction of forward motion has decreased greatly. However, the moment arm generating an external rotation moment has increased and now may be a mechanical factor to increase the deformity, either by increasing the foot deformity, or by causing increased external tibial torsion as children grow. This external rotation moment arm may also cause external rotation subluxation by rotating the tibia through the knee joint. There is an increase in the varus-valgus moment arm as well, but this seldom seems to cause mechanical or growth problems, probably because the force is somewhat reduced with the increased co-contraction required for walking, which is common in this combination of deformities. Many children have a combination of external rotation and planovalgus foot deformity, which makes a double-dose insult to the moment arm function of the foot. This insult is a principal cause of severe crouched gait and has been termed lever arm disease by Gage³ (see



Case 7.6 Lakesia



Lakesia, a 15-year-old girl with a diagnosis of spastic diplegia, was in a regular high school and was a varsity swimmer on the high school swim team. She had also been playing lacrosse as a recreational sport. Over the

past 2 years, she had grown rapidly and gained weight. During that time she gradually started to develop more knee pain, worse on the left than the right, to the point that she had trouble walking around her school and she

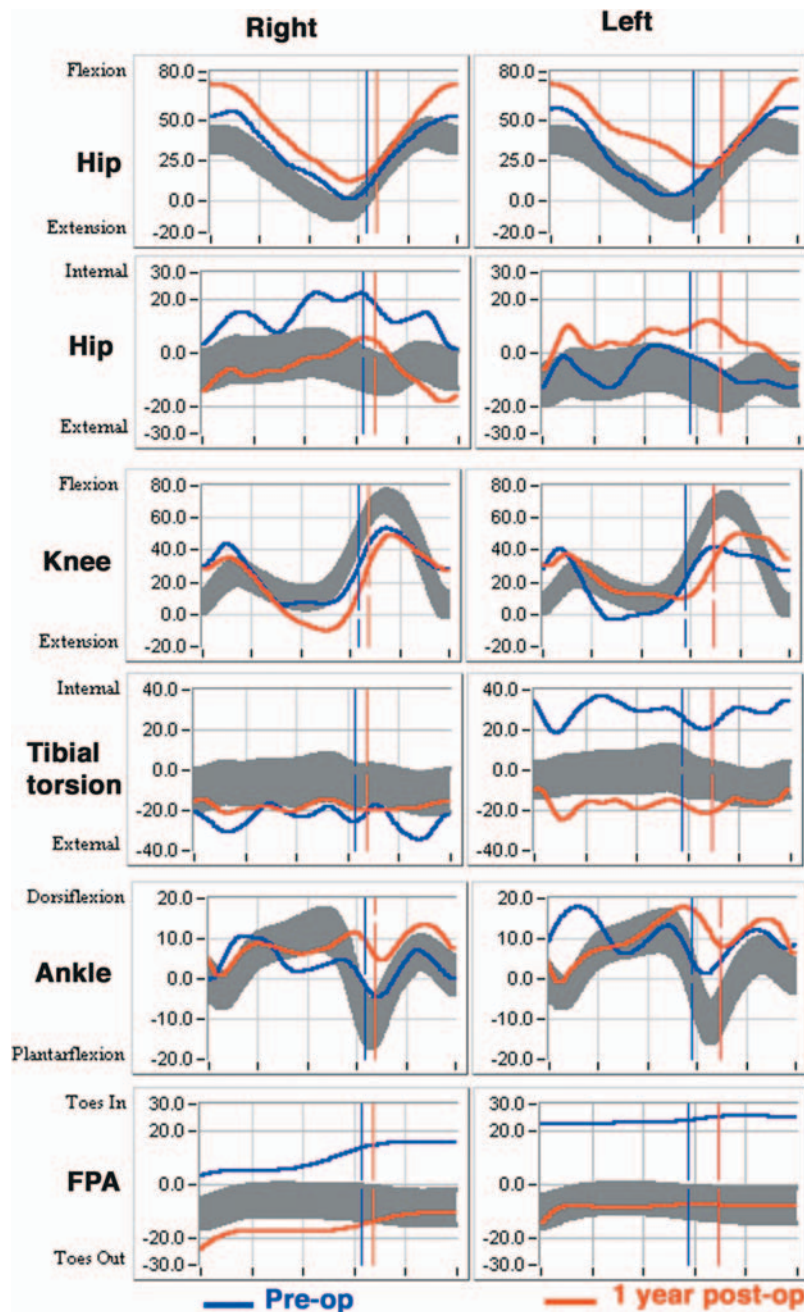


Figure C7.6.1

could not run to play lacrosse. Her family doctor told her to buy and use a wheelchair. Her gait involved a significant amount of trunk lurching with mild crouching, stiff knee gait, and internal rotation of the knees. On physical examination, both knees had mild diffuse tenderness, with no effusion, mechanical instability, click, or joint line tenderness. Hip motion demonstrated 80° of internal rotation, 10° of external rotation, full knee flexion and extension with popliteal angles of 70°, and transmalleolar-to-thigh axis of 30° external on the left and 20° on the right. Both feet demonstrated a planovalgus deformity and both feet had significant bunions. Radiographs of the knees were normal. She was initially evaluated in the sports clinic where a diagnosis of intraarticular pathology was made, and she was scheduled for knee arthroscopy, where an inflamed plica was found and excised. Following a 6-month rehabilitation program, she still continued with the same pain, and she was now using the wheelchair

for all ambulation except for household ambulation. An evaluation in the gait laboratory found significant internal rotation of the hips, external tibial torsion on the right, and internal tibial torsion on the left with the planovalgus feet, increased knee flexion at foot contact, and decreased knee flexion in swing phase (Figures C7.6.1, C7.6.2). Because there was minimal EMG activity in the rectus in swing phase (Figure C7.6.3), a trial of Botox to the left rectus also demonstrated no change in the motion of the left knee in swing phase. It was thought that the decreased knee flexion in swing was due to the poor push-off and poor mechanical advantage on the hip flexors at push-off. She was immediately referred to physical therapy and taught crutch walking to try to get her out of the wheelchair. She was then reconstructed with bilateral femoral derotation osteotomies, left tibial rotation, bilateral lateral column lengthenings, bunion corrections, and hamstring lengthenings. One year following surgery, she

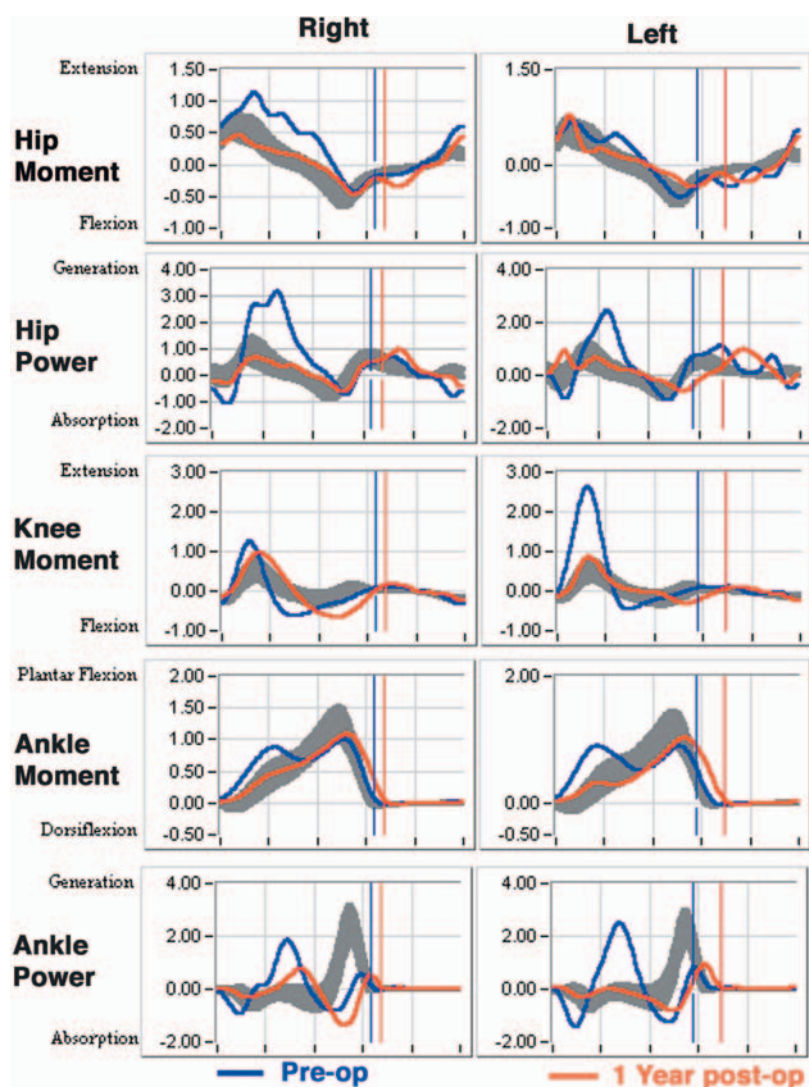


Figure C7.6.2

was pain free, was again swimming on the varsity swim team, and was no longer using the wheelchair for any community mobility, except for very long walks such as

at airports or amusement parks. In all community ambulation, she used the Lofstrand crutches, which she preferred over the wheelchair.

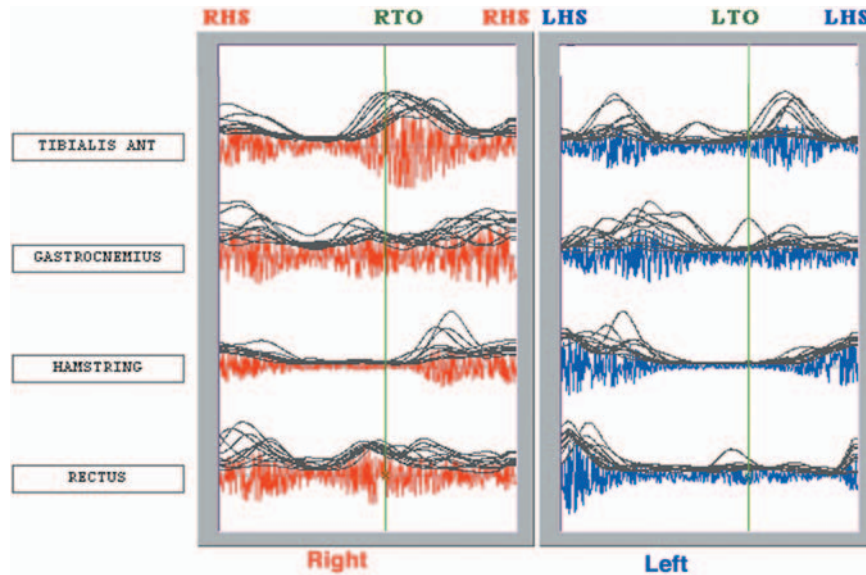


Figure C7.6.3

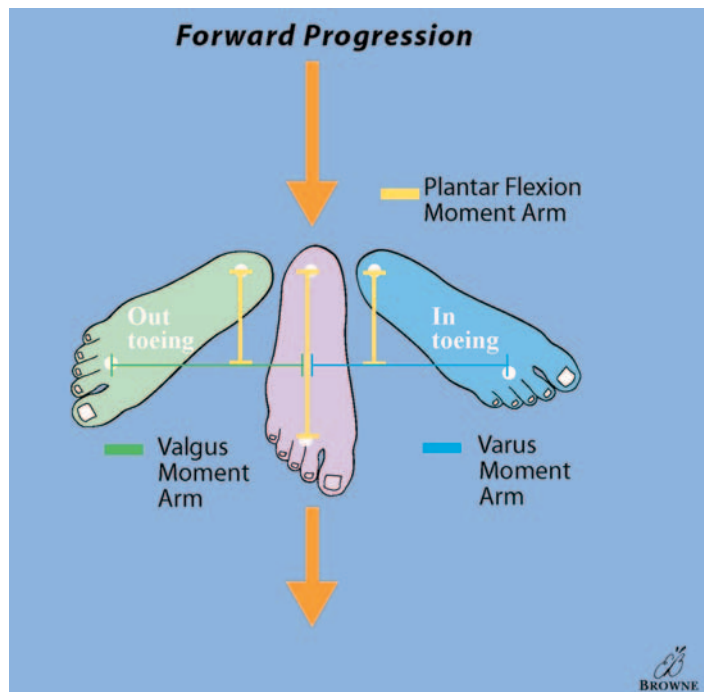


Figure 7.30. The torsional alignment of the foot, knee, and the forward line of progression of the body is very important. If the foot is not stable or lined up with the knee axis, the plantar flexion–knee extension couple cannot function, and the child drops into a crouched gait pattern. As the foot rotates relative to the knee axis, the moment arm of the foot decreases. The length of the moment arm is determined by the cosine of the angle of rotation. This means that there is very little effect on the first 20° to 30° of external or internal rotation; however, over 30°, the moment arms rapidly lose length, and the moment arm falls very fast when there is more than 45° of external rotation.

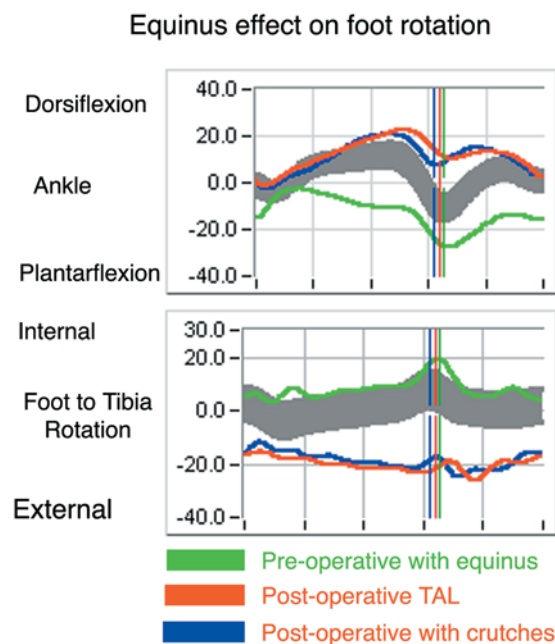
Figure 7.30). The lever arm is another name for a moment arm, and the importance of this concept to the etiology of crouched gait is often missed. Failing to understand the importance of the moment arm in the crouched gait pattern is like spending time sewing a skin wound on the leg of a child with an injury while failing to see the underlying fracture. All orthopaedists

know that the open fracture is really much more significant than the skin wound, and likewise, the lever arm dysfunction at the foot is much more significant as a contribution to crouched gait in most children than the knee flexion, which is readily apparent (Case 7.5).

Treatment

Malrotation of a foot progression angle can be treated with a foot orthotic if a major portion of the malrotation comes from the foot deformity. If the malrotation is secondary to torsional deformity more proximally, the only treatment option is surgical correction of the malrotation. In some children, the rotation is present in two or three locations and a decision has to be made if all or several need to be corrected. A relatively common example is severe planovalgus feet with external tibial torsion and increased femoral anteversion. In this situation, based on the physical examination and kinematic measurements, a judgment of how many of the deformities need to be corrected has to be made. These data have to be combined with an intra-operative assessment. For example, after the planovalgus foot deformity has been surgically corrected, the foot-to-thigh angle should be checked. If the foot-to-thigh angle is more than 25° to 30° externally, tibial osteotomy is definitely needed, but if the foot-to-thigh angle is between 10° internal and 10° external, no tibial osteotomy is needed. The midpoint ranges have to include consideration of children's level of function with more accurate correction attempted in children with better functional ability. In situations in which there is internal tibial torsion and femoral anteversion, the decision about doing one or both levels may be especially difficult. Correcting significant equinus also causes the foot to go from internal rotation to external rotation. Therefore, when making the decision on the need for rotational correction, the final determination should be made after surgical correction of the equinus (Figure 7.31). One rule that should almost always be applied is do not create compensatory deformities, or in other words, do NOT externally rotate the tibia past neutral to compensate for femoral anteversion. This compensation often leads to progressive deformity of external tibial torsion.

Figure 7.31. As the foot develops more equinus, it also tends to go into internal rotation of the foot relative to the tibia. When the severe equinus is corrected, as the foot goes into dorsiflexion it also goes into external rotation relative to the tibia. When correcting severe equinus, this secondary rotational change always has to be considered, so one should not be surprised that the individual now has severe external tibial torsion after tendon Achilles lengthening.



The Ankle as a Power Output Joint

The ankle is the principal power output joint and is an important part of being a shock absorber along with the knee. Ankle position at initial contact is very important in the shock absorption function. If initial foot contact is with toe strike, the foot and gastrocnemius may absorb some energy; however, if the position is foot flat, there is often a very hard strike, with the floor having to absorb the energy of initial contact. Children walking with this pattern can often be heard walking down hallways because of the loud sound and vibrations set up in the floor. The lack of shock absorption is measured on the vertical ground reaction vector of the ground reaction force. The loading response may show a magnitude of 1.5 to 2 times body weight when normal children's loading force should be between 1.1 to 1.2 times body weight (Figure 7.32). The loss of shock absorption also occurs in children in whom there is an incompetent gastrosoleus, a situation where they strike only on the heel but have little ability to absorb the load except through the heel pad. This situation is primarily seen in children whose Achilles tendon has been transected by tenotomy. During weight acceptance, the position of the ankle joint is determined by the gastrosoleus muscle. If the muscle is contracted and unable to allow 15° to 20° of dorsiflexion by eccentric contraction, a premature heel rise will occur. If the eccentric contraction initiates a concentric contraction, a premature plantar flexion will occur in midstance phase, causing a midstance phase rise in the center of gravity, called a vault. A major burst of power generation will be associated with the vault (see Figure 7.32). The premature gastrocnemius and soleus contraction may also cause the heel to rise, but with increased knee flexion. The center of gravity does not rise; however, the child's crouch increases. The second possible response to increased plantar flexion in midstance is knee extension, producing back-kneeing. The reasons for these three attractors for knee response to overactivity of the gastrocnemius in midstance is discussed in the knee section.

The primary reason for the gastrocnemius and soleus having a premature contraction in midstance phase may be a contracture of the gastrocnemius, which most commonly does not allow the muscle sufficient excursion for the required 20° of dorsiflexion. The treatment of this contracture is lengthening of the muscle-tendon unit, usually by gastrocnemius lengthening only. Appropriate gastrocnemius lengthening can restore some push-off power and normalize the ankle moment.^{39, 40} Another primary cause of premature gastrocnemius contraction may be related to decreased motor control, making independent control of eccentric contractions difficult. These difficulties may be correlated with increased tone and increased sensitivity in the tendon stretch reflex, which together initiate a concentric contraction at the foot contact. This concentric contraction continues through weight acceptance and midstance and is best treated with an AFO that blocks plantar flexion but allows dorsiflexion.

As the gait cycle moves to late stance, the time for the power burst of the gastrocnemius occurs. If the transition from midstance to terminal stance has the ankle in plantar flexion, the mechanical advantage of the moment arm of the foot will be compromised. If the ankle is in 0° to 10° of plantar flexion, this may not be a significant compromise; however, if the ankle is in 45° of plantar flexion as terminal stance is entered, there is very little ability to generate a push-off power burst. The amount of the power burst also depends on the amount of stretch and muscle fiber length relative to the rest length or, in other words, it depends upon the muscle's position on the length-tension curve. If the muscle is already almost completely shortened

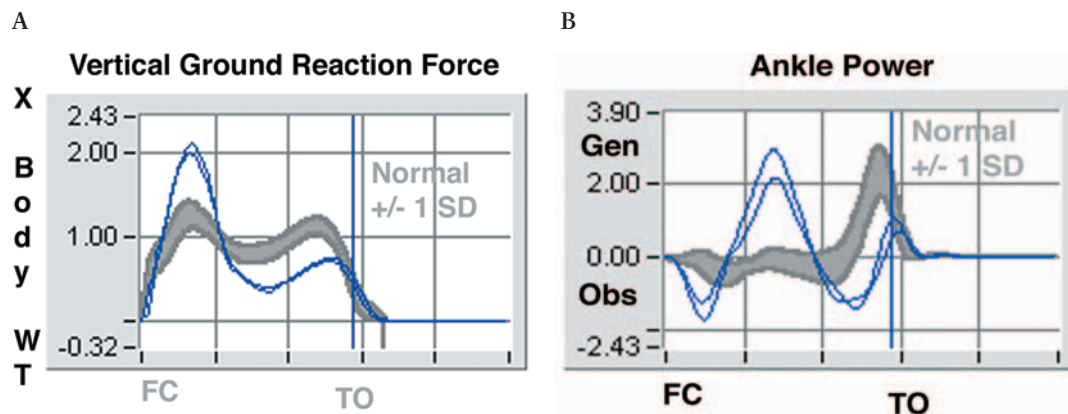
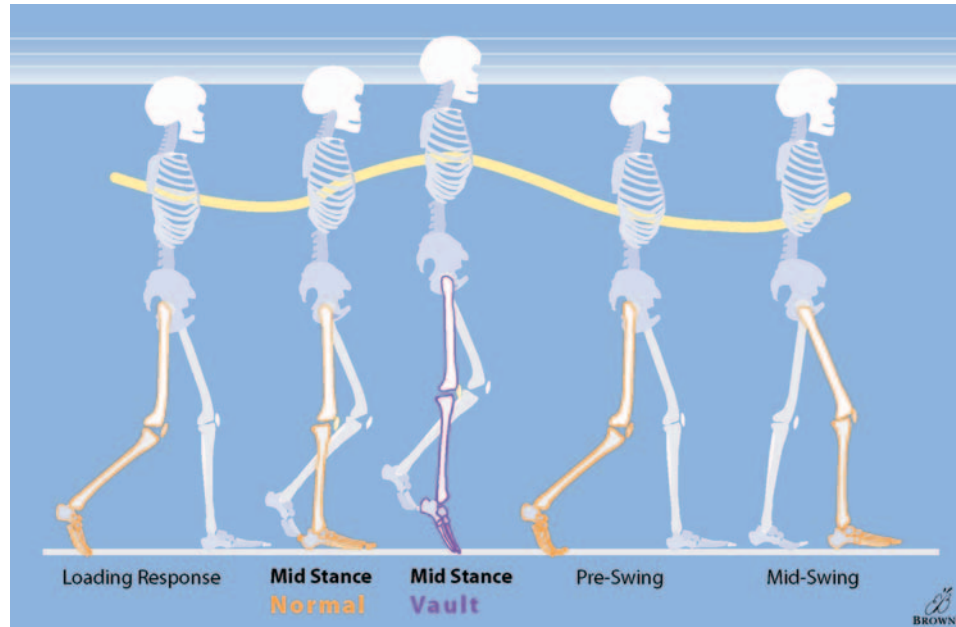


Figure 7.32. At initial contact and loading phase, the stance limb functions as a shock absorber. When the limb is not shortening through the knee, there is a very high impact force as the weight is shifted on the loading limb; this is seen best on the vertical vector of the ground reaction force (A). If the ankle then also develops a premature plantar flexion in midstance called a vault, power that lifts the center of mass vertically is generated (B).

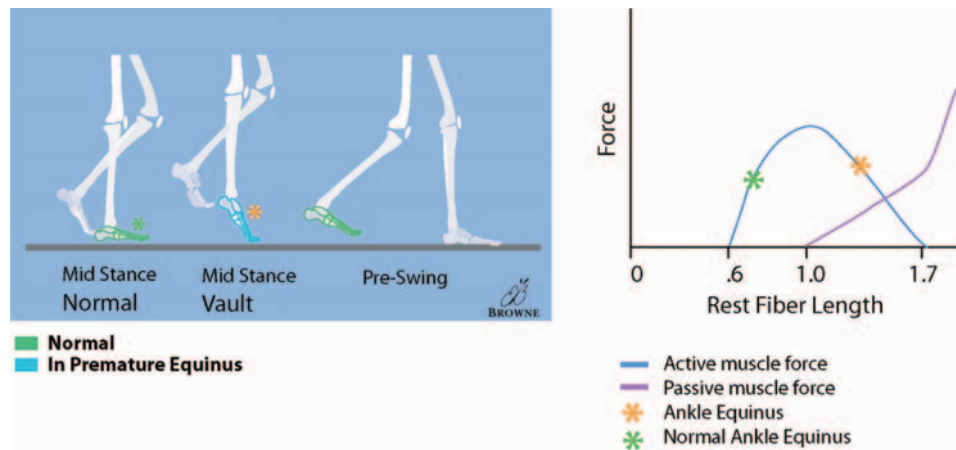
through a contraction, little additional power can be generated. Power output that is required for the push-off power burst can be generated only with a concentric contraction, in which the muscle actually shortens. The poor prepositioning of the ankle joint in terminal stance often precludes significant push-off power generation (see Figure 7.32). The secondary adaptations for the decreased ankle push-off power generation require that the hip extensors become the primary power generators for forward motion of gait. This proximal migration of power generation is often combined with increased pelvic rotation. This change increases the total energy of walking, but is a good trade-off when motor control is not sufficient to manage the more distal ankle power generation. This same process is invoked in the role of fashion by the use of high-heeled shoes. The high-heeled shoes prevent the prepositioning of the ankle in slight dorsiflexion during terminal stance, therefore precluding the push-off power from the gastrocnemius. This forces power generation to the hip extensors, which also increases the amount of pelvic rotation.

Treatment of the plantar flexion prepositioning of the ankle at the start of terminal stance can include the use of orthotics. Although the orthotic can block the midstance problems of vault, back-kneeing, or increased crouch, it will not preposition the foot to allow push-off power burst because it prevents active plantar flexion. An articulated AFO may preserve some push off power; however, it is greatly reduced from normal. The use of a leaf-spring orthosis is another option; however, the stiffness required to prevent the midstance phase plantar flexion almost always prevents the terminal stance phase plantar flexion burst as well. In many patients, the gastrocnemius is much more of a problem than the soleus. The gastrocnemius covers three joints and tends to develop a more severe contracture more quickly. Based on the physical examination, the degree of contracture between the gastrocnemius and the soleus can be separated based on the degree of dorsiflexion of the ankle with the knee flexed versus extended. This examination records the excursion of the soleus compared with dorsiflexion of the ankle with the knee extended, which reflects the excursion of the gastrocnemius. Usually, lengthening only the gastrocnemius will greatly improve the premature contraction problem in middle stance, and in some situations, allows improved push-off power development by improved prepositioning of the ankle. It is very important to avoid overlengthening because the ankle generally functions better in mild equinus than hyperdorsiflexion, a position where it can generate no plantar flexion. Many children who had their Achilles tendons transected require lifelong use of AFOs to stabilize their ankle joints.

C



D



Ankle Dorsiflexion in Swing Phase

Dorsiflexion in swing phase has two roles. First, in early swing phase, dorsiflexion helps to shorten the limb and allows swing through. Second, in terminal swing phase, dorsiflexion is part of prepositioning the limb for initial contact. Most children with CP have active dorsiflexor power produced by the tibialis anterior. If the EMG of the tibialis anterior is phasic in its activity, but very little dorsiflexion is produced, the cause is usually co-contraction with the gastrocnemius and soleus, or the tibialis anterior is attempting to contract against a contracted gastrocnemius muscle. In the presence of a phasic contracting tibialis anterior muscle, the ability for it to produce dorsiflexion will be enhanced with gastrocnemius lengthening. If the plantar flexion contracture was severe, the tibialis anterior may be overstretched and will require using an orthotic for some time to contract and function in its proper length (Figure 7.33). Some children with incompetent Achilles tendons

Figure 7.32 (continued). From the peak of the vault, the body falls forward into terminal stance (C); however, the ankle is usually still in equinus, thereby decreasing the ability for the ankle to generate power from additional push-off. This occurs because the muscle tends to be positioned on the wrong side of the length–tension curve to have maximum ability to generate power, and the remaining range of motion is limited (D).

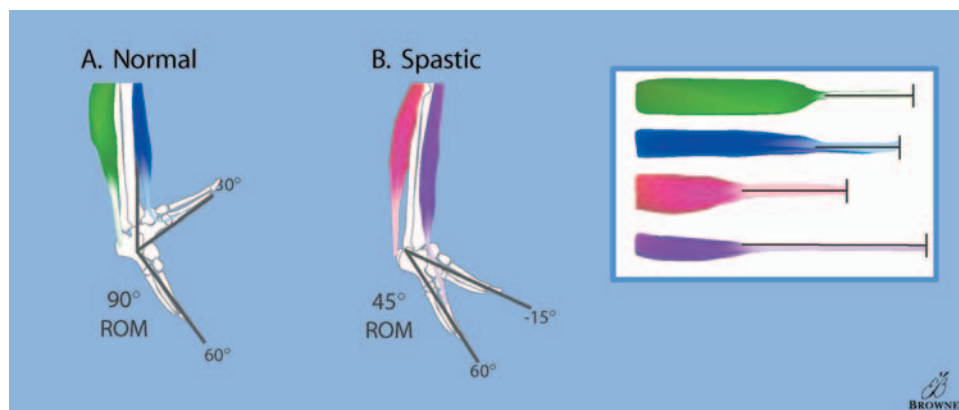


Figure 7.33. A problem of equinus contracture that gets most of the attention is the shortened gastrocnemius which limits the active range of motion. This active range of motion can be changed by lengthening the tendon Achilles; however, the second problem is that the tibialis anterior has developed an overlengthened tendon and it too is functioning in the equinus position. After lengthening the tendon Achilles, the tibialis anterior is now much too long; therefore, it is not functioning as an antagonist muscle in the same range in which the gastrocnemius is working. Time is required for the tibialis anterior to shorten.

develop dorsiflexion contractures because there is no gastrocnemius strength to overcome the tibialis anterior power. Some children with inadequate dorsiflexion combined with a stiff knee have severe toe drag in early swing phase. The dorsiflexion is a secondary cause of toe drag with the stiff knee being the primary cause. Often, this order is confused and the equinus gets the primary blame. For example, an individual with complete paralysis of the tibialis anterior and a drop foot but otherwise a normal functioning extremity, will never drag his toes. He will instead develop hyperflexion of the hip and knee to allow clearing of the foot. The only time an equinus foot position will cause toe drag is when it is associated with a knee that has decreased knee flexion in early swing phase. Many children with toe drag have dorsiflexion of the ankle and still drag their toes. This dorsiflexion also explains why children wearing orthotics that prevent plantar flexion still have toe drag. This again shows that the toe drag actually was due to the knee and not the plantar flexion. The treatment of decreased dorsiflexion power preventing active dorsiflexion is a very light, flexible leaf-spring AFO. These AFOs will control dorsiflexion and still allow some plantar flexion to occur. These AFOs are useful only when the gastrocnemius and the soleus have relatively normal tone and muscle length.

Knee

The primary function of the knee is to allow limb length adjustment and to provide stability in stance phase. At initial contact, the knee should have slight flexion so it can participate with the ankle in absorbing the shock of weight transfer. If the knee is completely extended, it does not easily have smooth flexion and therefore will not provide good shock absorption. The degree of knee flexion is modulated mainly by the hamstrings, and in children with CP, full knee extension at initial contact usually is the result of overlengthening of the hamstrings. Full knee extension at initial contact is also seen in children with hypotonia and ataxia.

Increased knee flexion at foot contact is much more common. This increased flexion helps shock absorption; however, this is often associated with plantar flexion and toe strike, which places an immediate strong external extension moment on the knee that the hamstrings have to resist. During weight acceptance, there tend to be two patterns of knee motion; one is immediate extension from initial contact position and the other is increased knee flexion, which may occur because of eccentric gastrocnemius contraction, weak gastrocnemius, or a poor moment arm of the foot. The amount of knee flexion during weight acceptance should be 10° to 20° if it is normally controlled by the gastrocnemius and soleus eccentric contraction. If the degree of knee flex-

ion is more than 20° , it is likely due to weakness of the gastrosoleus or an insufficient moment arm at the foot.

As the gait cycle proceeds to midstance, if there was knee flexion during weight acceptance, knee extension should now begin. If the knee flexion continues into midstance, then a crouched gait pattern is present (Case 7.7). The primary causes of increased knee flexion in midstance are knee flexion contractures, hamstring contractures, a deficient foot moment arm, and gastrosoleus weakness (Figure 7.34). A secondary etiology may be significant hip flexion contracture, which can limit knee extension in midstance. Often, there are several causes of increased knee flexion in midstance and all primary and secondary causes should be identified. This identification involves considering the actual magnitude of the flexion by evaluating the knee extension in midstance on the kinematic evaluation, the ankle moment in midstance, and the knee moment in midstance. If the ankle moment is normal or below normal, and the knee flexion is not increased, then the ankle weakness and foot moment arm are the most likely causes. If the kinematics show the knee extending to the limits of the fixed knee flexion contracture measured on physical examination, then the knee joint contracture is a likely cause. If the ankle has a high plantar flexion moment and the knee has a high flexion moment, it is likely a combination of contracture of the gastrocnemius and the hamstrings. If the hip extension peak occurs early, is decreased, and the physical examination shows a significant hip flexion contracture, then hip flexion contracture may also be contributing to the midstance phase knee flexion deformity. If children use ambulatory aids such as crutches and the hamstring muscles are not really contracted, there is a tendency for them to fall into back-kneeing, both when the gastrosoleus is overactive, and when it is too weak. If children are independent ambulators or have overactive hamstrings, they will be strongly drawn to a crouched gait pattern. If children are very strong and have high tone, they will be drawn to keep the knees stiff and vault in midstance phase. This vault action raises the body and increases the energy cost of walking; however, it has the benefit of allowing the contralateral leg to clear the floor during swing. Also, by raising the body in midstance, the body can then fall forward in terminal stance so forward momentum can be used at initial contact and the contralateral limb can use the gluteus to lift the body back up again (Figure 7.35).

The back-kneeing position in midstance phase is an especially difficult problem to address. This position has been shown to follow three patterns, with one pattern having predominantly overactive gastrosoleus muscles, the second having the HAT segment center of gravity move anterior to the knee often in the face of a weak gastrocnemius, and the third having the HAT center of gravity moving posterior to the hip but anterior to the knee.⁴¹ Treatment for all back-kneeing is to make sure the gastrocnemius has enough length to allow dorsiflexion with knee extension. If dorsiflexion with knee extension is possible, children should be placed in an orthosis that allows 3° to 5° of dorsiflexion while limiting plantar flexion to minus 5° . This orthosis can usually be an articulated AFO. If there is a pattern in which the ground reaction force is moving either significantly in front or behind the knee in the face of a weak gastrosoleus, a solid ankle AFO should be used to assist the gastrosoleus in ankle control. Back-kneeing that is especially difficult to control is that which is present in children who use walkers or crutches, because the center of mass of the HAT segment can be so far forward that when they are placed in AFOs, the toes of the shoes and AFOs will just rise with all the weight being borne on the heel. This persistent back-kneeing in spite of appropriate orthotics in children with assistive devices may cause progressive back-kneeing because of increasing knee hyperextension and the development



Case 7.7 Michael



Michael, a 5-year-old boy, was evaluated 1 year after he walked independently without the use of his walker. His parents complained that he fell a lot and had trouble stopping without falling at the end of a walk. Michael appeared to be age-appropriate cognitively and had significant spasticity in the lower extremities. He also had some increased tone in the upper extremities and poor hand coordination. His gait demonstrated toe walking with mild knee flexion in stance phase and significant internal rotation of the hips. After a full evaluation, he underwent a reconstruction with bilateral femoral derotation osteotomies, distal hamstring lengthening, and gastrocnemius lengthening. In his rehabilitation, gait training focused on ambulation with crutches, which he learned to manage well. By age 10 years, he was in a regular school and walked with Lofstrand crutches (Figure C7.7.1). He then fell and sustained a femur fracture, which was treated in his community hospital by placing him in a hip spica cast for 3 months. Following this, he could barely walk short, in-home distances with a walker (Figure 7.7.1). Shortly before the fracture accident, his parents went through an acrimonious divorce. Following removal from the cast, he was placed in a wheelchair and there was

little or no effort to try to rehabilitate him. Over the next 3 years, his father, who was very enthused about the boy's ambulatory ability, successfully petitioned the court to get custody from the mother, who felt ambulation was hopeless. This change in homes greatly lifted the boy's spirits, and in spite of not being able to stand to transfer himself by age 14 years, he was enthused about trying to get back to walking. By this time he had severe crouch stance posture, severe planovalgus feet, knee flexion contractures, and hamstring contractures (Figures C7.7.2, C7.7.3). At this time, Michael was doing well academically in a regular school. He underwent bilateral planovalgus correction with triple arthrodesis (Figure C7.7.4), gastrocnemius lengthening, posterior knee capsulotomies, and hamstring lengthening. By 6 months postoperatively, he could again walk in the house for short distances using a walker and ground reaction AFOs. By 9 months postoperatively, he made further progress with increased walking endurance, and by 2 years after surgery, he was again doing community ambulation and had worked back toward crutch use. The problems that caused Michael to stop walking were all reversible, including social home environment, his depression and lack of motivation, and the physical deformities. The key to having clinical confidence in getting him out of the wheelchair was having documentation in the videos or other gait analysis of his

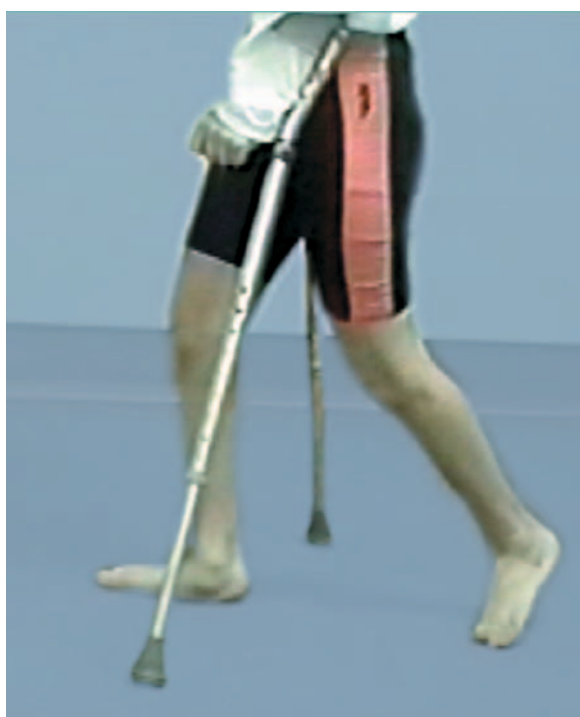

Figure C7.7.1



Figure C7.7.2

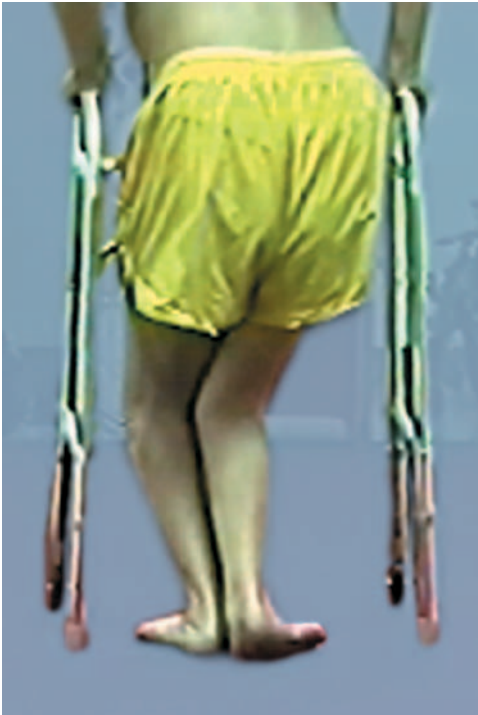

Figure C7.7.3

prior walking ability, and then making sure that all the factors were addressed before the physical deformities were corrected. The success of getting Michael walking again was probably as much a result of the change in home environment as it was the medical care.

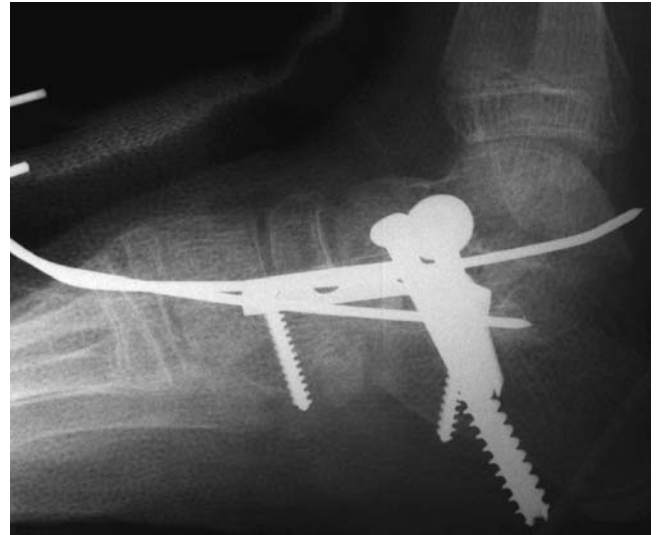
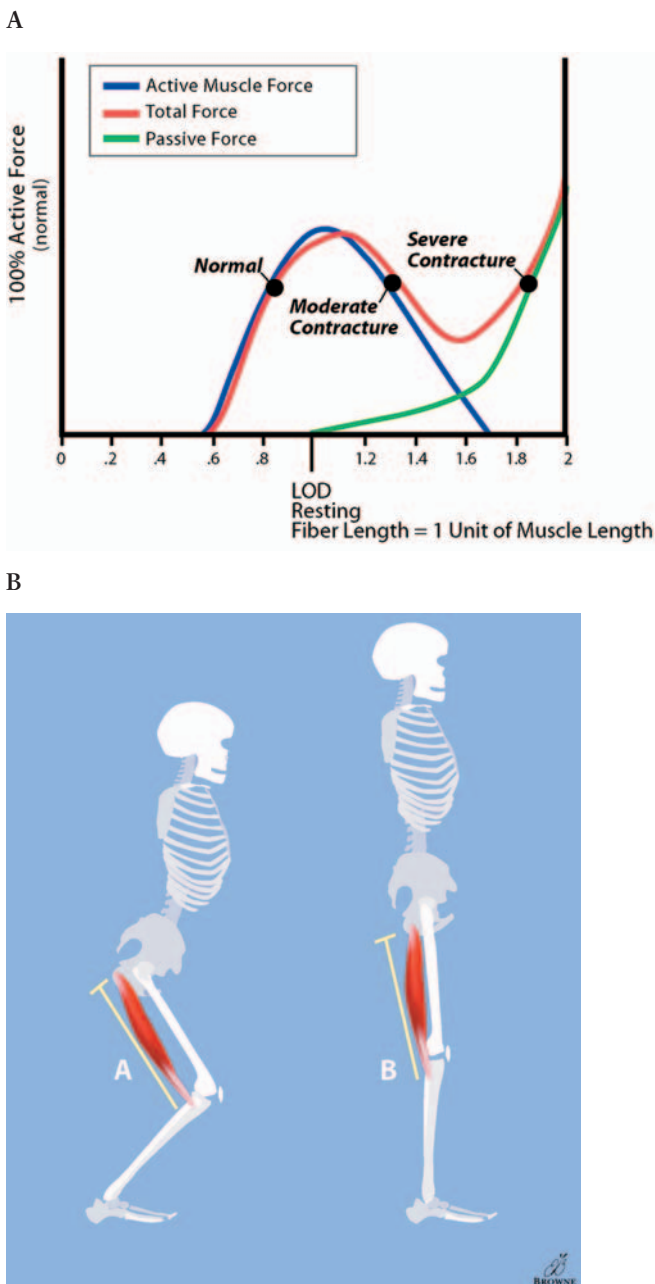


Figure C7.7.4

of pain. The only treatment for this kind of progressive back-kneeing is through the use of a knee-ankle-foot-orthosis (KAFO) with extension blocking hinges at the knee.

As the gait cycle progresses to terminal stance, the knee should start to flex as part of the process to accommodate the plantar flexion from the ankle joint and to start the process of shortening the limb for swing through. If flexion is delayed or decreased, it may be due to a lack of push-off power burst from the ankle, a lack of hip flexor power, too much contraction of the rectus, or co-contraction between the hamstrings and the vastus muscles. As the joint moves to early swing phase, the peak of flexion should be occurring in initial swing in the first 20% to 30% of swing phase. The stiff knee gait syndrome may be present if there is a decreased magnitude of knee flexion, meaning less than 55° to 65° of peak flexion, or the flexion occurs in midswing phase. This syndrome is the principal cause of toe drag. The primary cause of this stiff knee gait syndrome in children with CP is a rectus muscle that is contracting out of phase or with too much force. Secondary causes of decreased knee flexion in swing phase are the low push-off power bursts from the gastrosoleus, decreased hip flexor power, and a knee joint axis that is severely out of line with the forward line of progression. To diagnose the overactive rectus as the primary cause requires an EMG of the rectus, which is active for a prolonged period in swing phase, the time of maximum swing phase knee flexion is late, and the magnitude of maximum swing phase knee flexion is decreased. Additional data to reinforce the rectus muscle as the cause of the stiff knee are provided by the physical examination showing a contracted rectus muscle with a very positive Ely test and a rectus that is spastic. A poor push-off power burst at the ankle and little or no hip flexion power generation at toe-off suggests that some of the problem is coming from these sources.

Figure 7.34. The hamstrings effect on knee flexion in stance or crouched gait results from the hamstrings muscle ability to generate the same magnitude of force at three different points on the length–tension curve based on the level of contracture. At normal fiber length, the muscle still has the ability to generate more force with increased contraction. With a moderate contracture, there is decreased force generation as the muscle further lengthens and, with a severe contracture, there is rapid increase in force due to passive increase in tension from the connective tissue (A). In addition to the impact of the contracture on the hamstrings force-generating ability, the ability to generate joint moment depends on the position of the hip and knee joint. The hamstrings may be at the same length and generate the same force; however, if the hip and knee are flexed, as in a crouched gait, there is a large moment arm at the knee generating much more knee flexion force than when the knee is near full extension (B). Therefore, the end-to-end length of the muscle in crouch may be the same as in upright stance, but this does not mean the hamstring contracture is not a problem. One must consider the contracture effect on the length–tension relationship, and as this drives the knee into flexion, the crouch is a self-propagating position because more knee flexion increases the hamstrings mechanical advantage through an increasing knee moment arm.



When the stiff knee syndrome is due to an overactive rectus, the required treatment is to remove the rectus from its insertion on the patella (Case 7.8). This removal requires transferring the rectus to some other muscle, with the sartorius and the gracilis being the most common sites. The specific site of the transfer does not matter⁴²; however, it has to be transferred and not only released from the quadriceps tendon.^{43, 44} If the tendon is released only, it will probably reattach to the underlying tendon and go back to doing its old job again. The primary goal of this transfer is to remove the action of the rectus from knee extension but preserve its function as a hip flexor. Usually, the contraction pattern is appropriate for hip flexion, and if it is to have an effect on the knee, it should work as a knee flexor. Good results with increased knee flexion in swing phase and an earlier peak knee flexion have

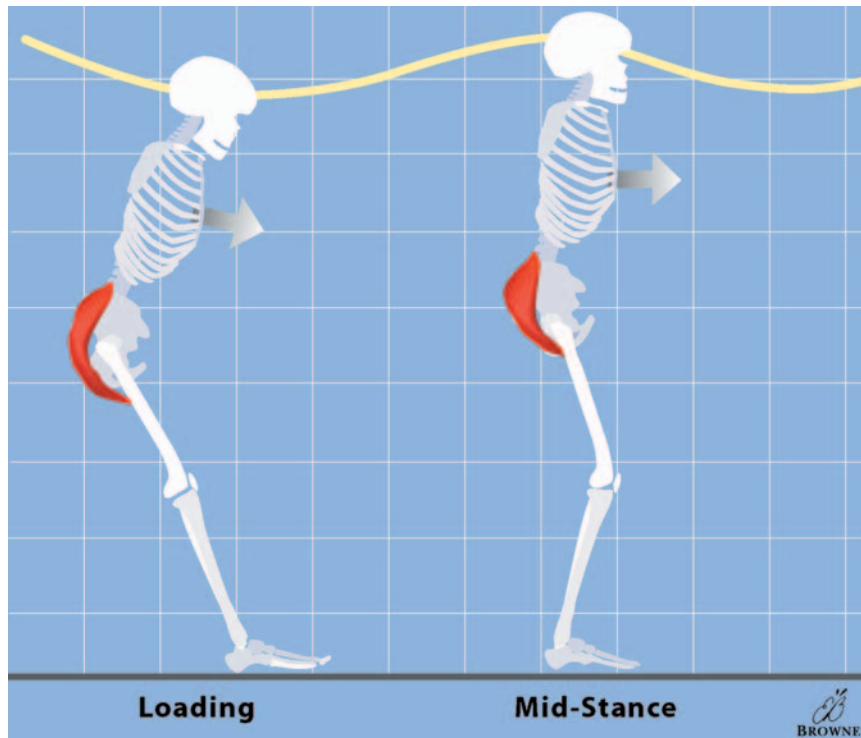


Figure 7.35. The gluteus maximus, primarily and along with the other hip extensors, are the secondary muscles generating forward motion. This function is accomplished by the muscle having a strong contraction at foot contact and early stance, in which the forward falling HAT segment and center of mass are decelerated and lifted. The strong contraction between momentum of the forward falling body and the fixed foot uses the lifting of the body by a concentric contraction. When the gastrosoleus is inactivated by an equinus contracture or by the use of very high heeled shoes, the hip extensors become the primary power output muscles generating power for walking.

been well documented by several studies.^{42–44} The distal transfer is better than the proximal release⁴⁵ and works best when there is good walking velocity and swing phase EMG activity of the rectus but not constantly on rectus EMG activity.⁴⁶

During terminal swing phase, the knee should be extending in preparation for initial contact. This extension is controlled by eccentric contraction of the hamstring muscles. The impact of the hamstring insufficiency to allow the knee to fully extend has already been noted. A much more common problem is overactivity of the hamstrings with early initiation on the EMG. Often, the primary problem is a contracture of the hamstrings and overactivity of the hamstrings muscle; however, the secondary cause is decreased momentum from slow hip flexion. This increased knee flexion at the end of swing phase causes short step lengths (Figure 7.36).

Treatment of diminished knee extension in terminal swing phase is primarily directed at the hamstrings, where surgical lengthening is the main treatment option. The function of the hamstrings is extremely complex, and the benefit of hamstring lengthening to improving knee extension at initial contact is less consistent.⁴⁷ Most reports showing positive results of hamstring lengthening come from the pre-gait analysis literature and have no dynamic data; however, they suggest that the popliteal angle remains improved after 2 to 4 years.^{48, 49} There are reports showing improvement in stance knee extension, loss of knee flexion in swing phase, and mild increased lumbar lordosis after hamstring lengthening.^{50, 51} There have been many modeling studies showing that the hamstring length is often not significantly shortened when measured from origin to insertion in the crouched gait midstance posture.^{32, 33} These findings fail to consider that these patients also have greatly decreased muscle fiber length as demonstrated by high popliteal angles. These modeling origin to insertion measurements miss the significant impact of the change of muscle power based on the position the muscle falls on the



Case 7.8 Josie



Josie, a 16-year-old girl, presented with the complaint of frequent tripping and wearing out the front of her shoes very quickly. She has never had surgery, attends high school where she is an average student, and desires treatment for her complaints. On physical examination she had good hip motion, and full knee range of motion with popliteal angles of 45° bilaterally. An Ely test was positive at 60°, the rectus had 1+ spasticity on the Ashworth scale. Ankle dorsiflexion with the knee extended was 5°. Kinematics showed knee extension in stance to the normal range but only 35° peak flexion in swing phase. The ankle kinematic showed early ankle plantar flexion. The ankle moment had a significant early plantar flexion moment. The ankle power showed a midstance genera-

tion burst indicating a significant vault. An EMG of the rectus showed constant swing phase rectus activity, but no significant stance activity. Bilateral rectus transfers were performed, and she had significant increase in swing phase knee flexion immediately after surgery (Figure C7.8.1). This improvement was maintained 3 years later, along with excellent improvement in symptoms. She now reports much less tripping and never wears out the toes of her shoes. Although patients with isolated stiff knee gait are rare, this demonstrates the excellent benefit of rectus transfer when the indications are correct. Often, the cause of swing phase knee stiffness is not so isolated but also includes poor hip flexor power and poor ankle push-off.

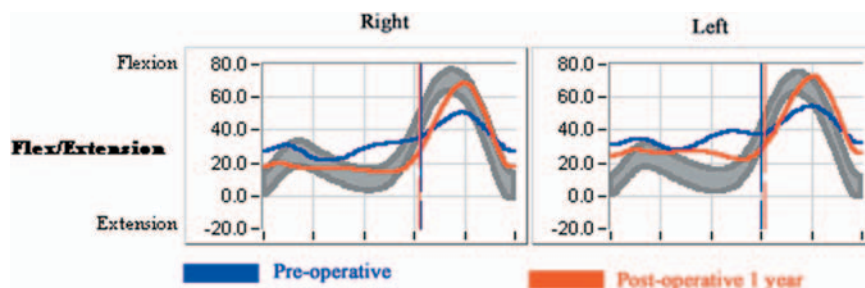


Figure C7.8.1

length–tension curve and the impact of the change of the moment arm based on joint position (see Figure 7.34). With the knee flexed 60°, the moment arm for knee flexion by the hamstrings is much greater than when the knee is extended. This same change in moment arm also occurs at the hip; however, the length the moment arm changes is less significant at the hip. There are also three separate muscles, the semimembranosus, semitendinosus, and long head of the biceps, which make up the primary hamstrings, and each of these muscles has a different fiber length but very similar origin and insertion sites. As all the variables involved with hamstring contraction are added to the force generated, which depends on the velocity of the contraction, the complexity of the control of the force impact on the hip and knee from the hamstrings is demonstrated. These variables include three muscles, each with different fiber lengths, approximately 1500 motor units in each muscle, and variable moment arms at two points for each muscle. With this great level of complexity, it is easy to see why these muscles are not commonly well controlled in children with motor control problems. This complexity can also explain why the outcome of lengthening is not very predictable. However, based on clinical experience, severely short hamstrings do not work well even if the simplistic modeling suggests that the origin-to-insertion length of the hamstrings in the midstance part of the gait cycle is long enough.

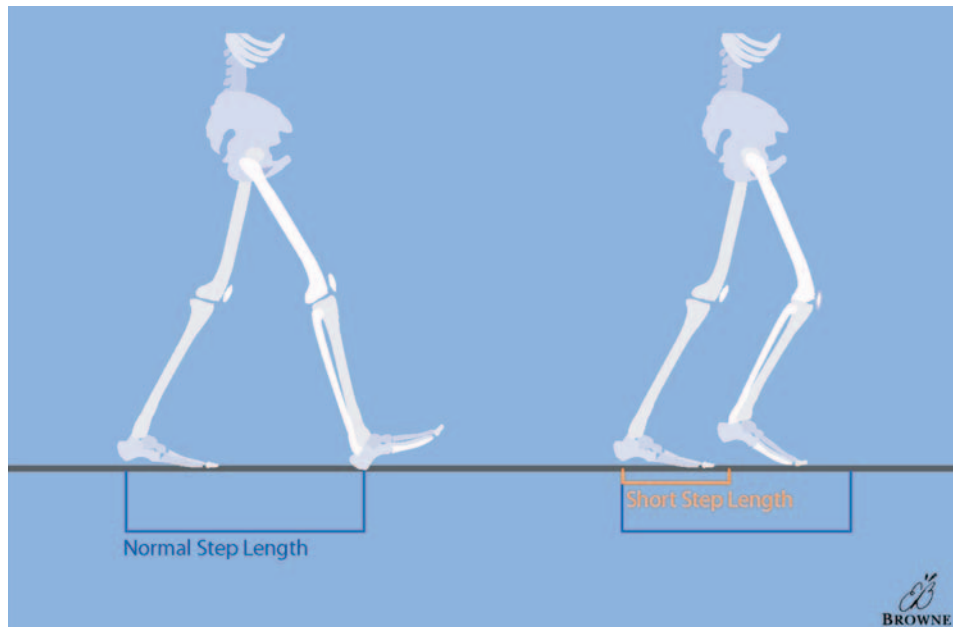


Figure 7.36. An important function of the knee is to develop extension at foot contact. Lack of knee extension at foot contact can be a significant cause of short step lengths.

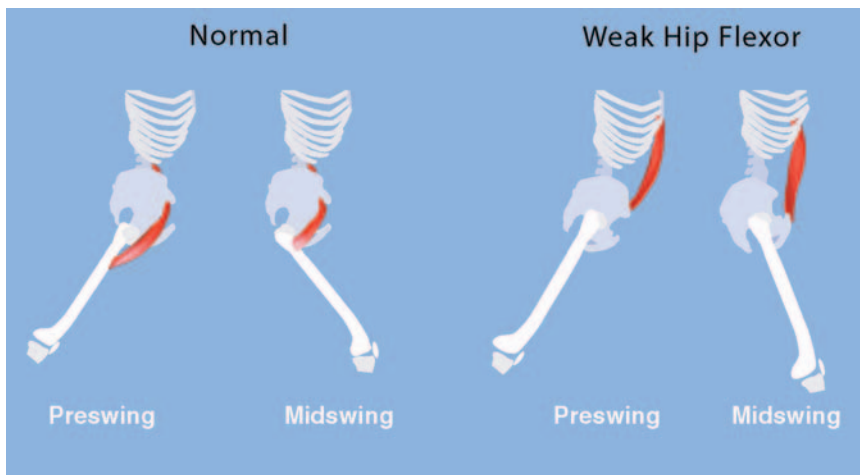
Hip

Sagittal Plane

The major role of the hip joint is to allow progression of the limb under the body and provide three degrees of motion between the limb and the body. The hip joint is also the secondary power output source. In the sagittal plane, the hip is typically flexed at initial contact, which is seldom a problem even if the flexion is slightly exaggerated. At weight acceptance the hip is starting to extend as the body is moving forward over the fixed limb. The ankle and knee should be acting as shock absorbers. If the ankle and knee are held stiff, the hip extension may be slowed. The hip extensors are very active in weight acceptance as the body falls forward and is dropping with momentum. The main hip extensors are the gluteus maximus and the gluteus medius along with the hamstrings, which forcefully contract and output power, effectively lifting the body up again. If the hip extensors are weak, some compensation may occur by shifting even more proximally and using the spine extensors or the paraspinal muscles to create increased lumbar lordosis. Weak hip extensors are assessed by physical examination and by the weight acceptance hip extension moment and power generation in early stance phase. Another sign of hip extensor weakness is an early crossover of the hip moment from extension in early stance to flexion in terminal stance. This crossover should occur between mid- and late stance and not during weight acceptance. Treatment of weak hip extensors should include a strengthening program. For severe weakness, an ambulatory aid, either a crutch or a walker that allows the arms to assist the hip extensors in lifting the forward fall of the body during weight acceptance, should be prescribed.

In midstance phase, the hip continues to extend as the weightbearing limb moves behind the body. Hip flexion contractures are contractures of the hip flexors, primarily the psoas, which cause the extension to be limited. This limitation requires secondary adaptation of increasing anterior pelvic tilt and preventing full knee extension (Figure 7.37). Hip flexion contraction may be measured by several different physical examination methods, but it is most important to have a sense of what the normal range is for the method used.

Figure 7.37. The primary hip flexors assist with increasing hip flexion acceleration in preswing and into early swing phase. If these muscles are not functioning because of weakness or contracture, the abdominal muscles can provide an adaptive mechanism by increasing pelvic tilt motion to augment inadequate hip flexion.



Hip extension in the kinematic measurement in midstance should come nearly to neutral; however, the normal range for the specific marker placement should be considered. Treatment of hip extension deficiency includes stretching exercises of the hip flexors or lengthening the psoas through a myofascial lengthening of the common iliopsoas tendon. Lengthening of the psoas has not been shown to consistently decrease anterior pelvic tilt⁵²; however, one report found that it did better in younger children.⁵³ Modeling studies suggest that the iliopsoas may be shortened more relative to normal in crouched gait than the hamstrings.³² Occasionally, a contracture of the rectus femoris or the fascia latae can contribute to the hip flexion contracture. Contractures of the rectus femoris and the fascia latae should be evident on physical examination.

In terminal stance phase, the hip again starts to flex, and much of the power for this hip flexion in normal gait comes from the gastrosoleus push-off burst. However, in most children with CP, this gastrosoleus burst is deficient and the direct hip flexors are the primary power output source to move the limb forward. This burst is also the main source of power that causes knee flexion. The primary hip flexor muscles are first the iliopsoas, followed slightly later in the cycle by the adductors, primarily the adductor brevis and the gracilis. Inactivity or weakness of the hip flexors is demonstrated by delayed hip flexion on the kinematic measurement and by absent hip flexion moment or late crossover from the extension to flexion moment in late stance phase. The compensations for a weak hip flexor are increased pelvic movement, usually a posterior pelvic tilt in terminal stance and a slow velocity of walking, especially caused by decreased cadence. Treatment of hip flexor weakness is first to avoid excessive surgical lengthening of the psoas and adductors. Strengthening exercises are the only option for adding strength to these muscles if weakness is the major problem. The use of assistive devices, such as walkers or crutches, will not help with the problem of hip flexor weakness and often makes it worse. The weakness of the hip flexors in terminal stance is magnified by crutch use because crutch users generally lean forward, increasing their hip flexion and causing the need for even more hip flexion in swing phase. The forward lean also tends to put less prestretch on the hip flexors, making them even less effective as power generators. Having the muscle at the optimum position on the length-tension curve is an important way to increase the muscle's functional

strength, but crutch use tends to do the opposite with hip flexors. Another common disability from weak hip flexors is the inability to step up on a curb or a stair step. Problems stepping into vehicles or bathtubs are also common complaints.

In initial swing, the hip flexor continues to be active as the force for initiating the forward swing of the swing phase limb. The hip flexor is also the force that produces the knee flexion. Problems of terminal stance are continued with the same implications in initial swing. In midswing, there is seldom much direct impact, except for the common problem in CP of premature initiation of hamstring contractions, which tends to limit hip flexion and knee extension at a time when momentum is needed going into terminal swing. In terminal swing, the excessive activity of the hamstrings is again the most common problem. The effects of this activity are most dramatic at the knee, but the hamstrings contraction, if it is very excessive, may also limit hip flexion in terminal swing. Compensation occurs at the pelvis, where a posterior pelvic tilt may occur as a compensation for excessive hamstrings force in terminal swing. If the hamstrings or vastus muscles are very weak, the gluteus maximus and medius may substitute by a forceful contraction in terminal swing, which causes the knee to fully extend. This contraction places the knee in a fully extended preposition for initial contact (Figure 7.38). This is a position of maximum inherent stability for initial contact and weight acceptance, but it allows poor shock absorption at the knee.

Coronal Plane Hip Pathology

The coronal plane motion of the hip is used to keep the center of mass of the body in midline and allow the feet to be under the body close to the midline. At initial contact, the hip is abducted slightly, which decreases in midstance and then increases again at toe-off. During swing, the process is repeated. If there is a contraction of the adductor at initial contact, there will be less hip flexion and the foot will be positioned across the midline, where it tends to impede the forward line of progress during swing phase of the contralateral limb. This pattern, in which the foot is positioned across the midline, causes the scissoring gait pattern. In the scissoring gait pattern, the swing phase foot gets trapped behind a foot that has been placed too medially. If the adductor contraction or overactivity is unilateral, the uncontracted hip can abduct, compensating along with pelvic obliquity. This pelvic obliquity will then cause a limb length discrepancy, which has to be compensated for. The primary assessment of coronal plane hip pathology is based on physical examination measurement of hip abduction with the hip extended and the measurement of hip abduction on the kinematic evaluation. The hip should abduct slightly at initial contact. Then, there may be several degrees of abduction in midstance phase and swing phase. The main treatment for overactive or contracted adductors usually requires surgical lengthening. A contracted adductor is not a common problem in children who are functional ambulators. Some children who are marginal ambulators and often require gait trainers consistently have increased adduction such that the feet are always crossed and they cannot step. Some of these children have adduction because of poor motor control, in which a total flexor response to initiate stepping is used (Case 7.9). This flexor response includes hip flexion, adduction, knee flexion, and ankle plantar flexion. Even if the adductor is lengthened, for some of these children the motion continues unless all the adductors are removed, which will only cause a new problem. Unilateral increased hip adduction can also be a secondary response to limb length

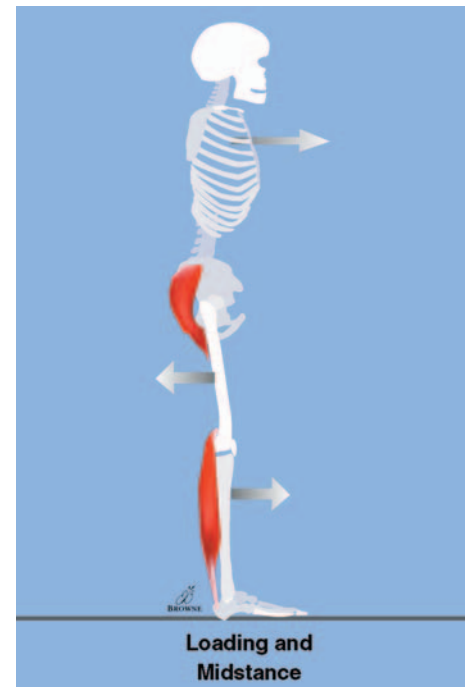


Figure 7.38. The hip extensors also provide important function in controlling knee position. During stance, this is provided in coordination with the gastrocnemius in which knee extension is produced as a result of hip extension. Momentum is moving the body forward over the fixed stance phase foot, allowing the hip and gastrocnemius to control knee stability. In swing phase, the deceleration of the hip flexion by the hip extensors can allow the knee to swing into full extension if the hamstrings are not activated.



Case 7.9 Jacob



Jacob, a 10-year-old boy, was brought in by his father with the main complaint that he could not walk because his feet crossed over each other when he stood and tried to walk. His father was most concerned about the boy's spasticity, which he felt was limiting his ability to walk and was making bathing, dressing, and transferring more difficult. On physical examination, Jacob was not able to sit unsupported. He could self-feed with a spoon (if the food was sticky like mashed potatoes), had no speech, and was in a special education classroom for children with severe cognitive limitations. The physical examination demonstrated Ashworth grade 1 and 2 spasticity throughout most muscles in the lower extremity and the upper extremity. He had no ability to do individually isolated joint movement in the lower extremity. The hip demonstrated a symmetric 30° of abduction, popliteal angles were 40° , hip internal rotation was 50° , and ex-

ternal rotation was 30° . Jacob was cooperative in trying to stand and take steps when being held from the back. He had a gait trainer, which he enjoyed. Based on this assessment, Jacob was believed to have significant spasticity; however, this was not felt to be the main cause of the scissoring. The scissoring was due to poor motor control and poor motor planning. It was not thought that he would benefit from further surgical lengthening of the adductor because these were not contracted, and part of the cause of the scissoring was his poor coordination in the use of hip flexors to advance the limb. A baclofen trial was given, but he could not stand with the decreased spasticity after the baclofen injection, and his parents felt the benefit of the decreased spasticity during custodial care would not make up for his functional loss of not being able to stand.

inequality. In children with CP, this inequality can be a physically short limb, but is more commonly a functional limb shortening due to asymmetric hip, knee, or ankle flexion. Treatment of the limb length inequality will treat the hip adduction. Asymmetric adduction on one hip and abduction on the opposite hip may also be caused by fixed pelvic obliquity emanating from spinal deformities.

Increased hip abduction leads to a wide-based gait, which is cosmetically unappealing and is very functionally disabling if the children are functional ambulators. The wide-base position forces excessive side-to-side movement of the body to keep the center of mass over the weightbearing limb. If children have increased abduction with a wide-based gait but have no abduction contracture on physical examination, the cause of the wide-based gait is weakness of the adductor muscles. Usually, the cause is incompetent adductors secondary to excessive adductor lengthening, or the addition of an obturator neurectomy to an adductor lengthening (Case 7.10). The best treatment of this problem is to prevent it from happening by not doing this type of surgery on a functional ambulator. However, if presented with the problem, working on strengthening the remaining adductor strength and allowing the children to grow often slowly corrects the problems. There are no other treatments available. The wide-based gait may also be due to an abduction contracture, usually of the gluteus medius or fascia latae. The etiology of wide-based gait due to a contracture requires identifying the source of the contracture, and the kinematic measure should show increased abduction, especially in midstance phase. Once the specific source of the abduction contracture is identified, the treatment is surgical lengthening of the contracted muscle. Fixed contractures of the hip joint may also cause the same effect as muscle contractures. Sometimes, this contracture requires a



Case 7.10 Sean



Sean, a 5-year-old boy with quadriplegia, had an adductor lengthening and distal hamstring lengthening to treat spastic hip disease at age 3 years. By age 5 years, he walked efficiently with a walker; however, his parents were concerned about his wide-based gait and foot drag. On physical examination, he was not able to get into the walker without assistance, but had functional gait once he was in the walker. His hip abduction was 50° on each side, full hip flexion and extension was present, the popliteal angle was 40° , and he had grade 2 spasticity in the rectus, with a positive Ely test at 40° . Kinematic evaluation showed increased hip abduction and decreased knee flex-

ion in swing phase with EMGs of the rectus, which were very active in swing phase. His hip radiographs were completely normal. His gait was characterized by a wide-based gait with foot drag and knee stiffness in swing phase. Based on these data, Sean had bilateral rectus transfers because the knee stiffness was believed to be adding to the tendency to have a wide-based gait. He was initiating a circumduction maneuver because of adductor weakness to assist with foot clearance. After the rectus transfers, his base of support narrowed and knee flexion increased nicely. His foot drag also decreased.

radiographic evaluation of the joint to determine if the source is the muscle only or a combination of the muscle and the joint.

Transverse Plane Deformity

Transverse plane deformity in children is common and is often confused with coronal plane deformity. The difference between scissoring, which is excessive hip adduction, and hip internal rotation gait is often missed. Scissoring is a completely different motion requiring a different treatment (Figure 7.39). Hip rotation is defined as a rotation of the knee joint axis relative to the center of hip motion in the pelvis. In normal gait, this rotation around the mechanical axis of the femur allows the feet to stay in the midline and allows the pelvis to turn on top of the femur, which are both motions that work to decrease movement of the HAT segment and therefore conserve energy. At initial contact, the normal hip has slight external rotation of approximately 10° , then it slowly internally rotates, reaching a maximum at terminal stance or initial swing phase. If the hip is positioned in internal rotation at initial contact, then during stance phase as the knee flexes, there is an obligatory hip adduction and the knee may impact the opposite limb (Case 7.9). If the internal rotation is present during midstance, such as in a crouched gait pattern, the knees often rub during swing phase of the contralateral limb. Internal rotation positioning in terminal swing also causes the knee to cross the midline, a problem that continues into initial swing. Another primary effect of this internal rotation is placing the knee axis out of line with the forward line of motion. This position causes significant alteration in mechanical efficiency of the push-off power that the ankles generate. Secondary adaptation to the internal rotation of the hip includes decreased knee flexion in weight acceptance in swing phase, decreased ankle push-off power burst, and requires the use of more hip power. If the internal rotation is unilateral, the pelvis may rotate posteriorly on the side of the internal hip rotation, then the contralateral hip compensates with external rotation. The amount of internal rotation is assessed by physical examination with children prone and the hips extended (Case 7.11).

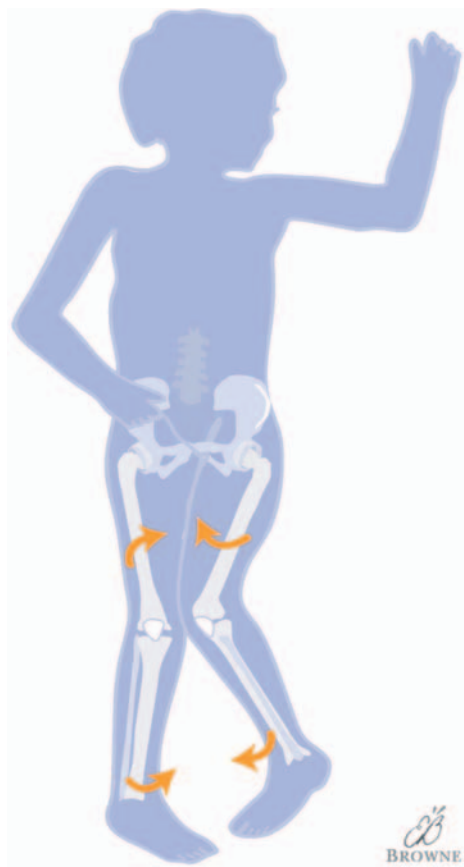


Figure 7.39. Crossing over of the knees is often called scissoring gait. However, it is better to use the term scissoring gait only when it is caused by true hip hyperadduction. Most of the time, crossing over of the knees is due to internal rotation of the hips, often secondary to increased femoral anteversion and not caused by primary increased hip adduction.

The kinematic measure should show external rotation through almost all of the gait cycle. There are two problems with the kinematic measure of which clinicians must always be aware. First, the measure is very dependent on defining the axis of the knee joint by the person placing the marker. An error of 5° to 10° in defining the knee joint axis is to be expected. The second major issue is all clinical gait software programs currently use rotation as the last Euler angle to derotate. This means that often the measured degree of rotation is less than clinicians perceive, probably because they are mentally derotating the hip first. This is not an error in the kinematics or the clinicians' assessments but is related only to the method of expressing the position. Clinically, the hip rotation may be more significant than the kinematic measure suggests.

The principal cause of the increased internal rotation is increased femoral anteversion. A secondary cause may be a contracture of the internal rotators. A third cause may be motor control problems as mentioned with increased scissoring, which are often seen in marginal ambulators. For children who previously had surgery on the hip and in whom there is a question as to the specific cause of the internal rotation, measurement of the femoral anteversion with ultrasound or CT scan should be considered. Children in middle childhood or older who are functional ambulators tend to do poorly with internal rotation that is greater than 10° during terminal stance phase. From middle childhood on, there is little apparent spontaneous correction of the internal rotation. Children who are very functional ambulators and have any internal rotation during stance phase are easily cosmetically observed as having internal rotation. Some children with 0° to 15° of internal rotation of the hip in stance phase seem to have very few measurable mechanical problems; however, parents often notice that they trip more frequently, which may be due to decreased knee flexion to avoid knees crossing over the midline. These increased problems that require sophisticated motor control probably cause children with CP to be more clumsy. Also, during running when there is increased knee flexion, a heel whip will appear if children have persistent internal rotation. This heel whip clearly adds to children's poor coordination during running. Treatment of increased internal rotation is a derotation femoral osteotomy, which will improve the foot progression angle.⁵⁴ If the source of the internal rotation is felt to be a contracture of the internal rotators of the hip, the most usual cause is the anterior fibers of the gluteus medius and the gluteus minimus.⁵⁵

Excessive external rotation of the hip during gait is rarely a primary problem of gait in children with CP. Usually, this external rotation is associated with hypotonia and may be part of a progressive anterior hip subluxation syndrome (Case 7.12). Typically, these children start losing functional ambulatory ability as the hip increases its external rotation at the same time the anterior subluxation is increasing. The treatment is to correct the hip joint pathology. The second situation where external rotation may be seen is secondary to excessive external rotation of the femur for treatment of femoral anteversion. The rule of thumb should be that a little external rotation is better than a little internal rotation, with the goal being 0° to 20° of external rotation. However, too much external rotation, meaning greater than 20° , is worse than a little internal rotation of 0° to 10° . The goal should be to have 0° to 10° of femoral anteversion, and the kinematic measure should show 5° to 20° of external rotation of the femur during stance. Femurs with excessive external rotation may need to be turned back into internal rotation again. Imaging studies should be obtained to fully assess the deformity before undertaking repeat surgery because external rotation contractures



Case 7.11 Tonya



Tonya, an 11-year-old girl with a diagnosis of spastic diplegia, complained of increased difficulty in walking due to clumsiness and pain from her knees knocking together. This problem had become much more symptomatic over the past year. Tonya had normal cognitive function, and no other medical problems. On physical examination, she had 70° of hip internal rotation and -10° external hip rotation. Hip abduction was 20° , popliteal angles were 60° , and the feet were normal. Her gait demonstrated a foot flat gait pattern with mild knee flexion in stance, decreased knee flexion in swing, severe in-

ternally rotated knees with heel whip, and mild increased lumbar lordosis. Kinematics showed hip internal rotation of 20° in stance phase. The EMG of the rectus showed mild increased activity in swing phase and that hamstring activity was normal (Figure C7.11.1). Based on the EMG activity, the main problem was believed to result from femoral anteversion, and she had femoral derotation osteotomies bilaterally. This procedure resolved all her complaints and substantially improved her knee motion and hip extension.

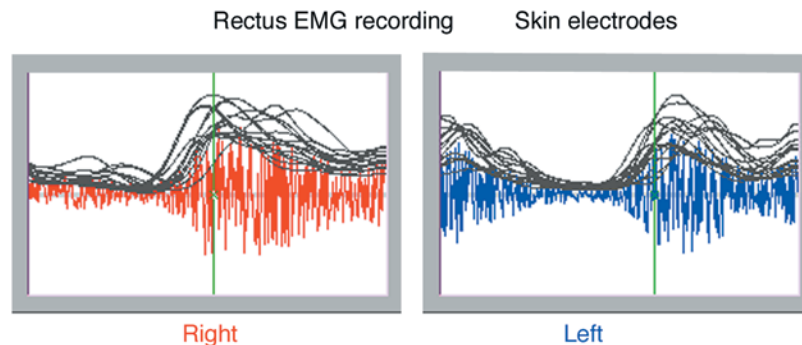


Figure C7.11.1

can occasionally occur. These external rotation contractures usually involve the posterior half of the gluteus medius and the short external rotators of the hip joint.

Pelvis

Pelvic motion is viewed as motion of the pelvis in the space of the room coordinate system. Observational gait analysis of pelvic motion is difficult because this body segment does not have clear borders and it is socially difficult to have children undressed at the pelvic level. Therefore, trying to see the pelvis move is somewhat like watching the neighbor's television through a window covered with a curtain. Pathologic motion of the pelvis occurs either with excessive motion or asymmetric motion. Excessive pelvic motion is defined as more than 10° on the kinematic measure in any of the three directions and is usually due to increased tone, which has stiffened the hip joint and limits hip motion (Table 7.9). Often, treatment is not needed as this is a functional way of increasing mobility that has only a slightly increased energy cost. This increased pelvic rotation may cause heel whip during running, therefore making running more difficult. The only available treatment is to decrease muscle tone by rhizotomy or intrathecal baclofen, both of which cause or bring out muscle weakness. Often, the weakness is more impairing to the gait function than the stiffness.



Case 7.12 Hameen



Hameen, a 10-year-old boy with hypotonia and mental retardation, had increased difficulty in ambulation. He used to walk everywhere using a posterior walker, but now his mother stated that he refused to walk except for very short distances. She did not perceive that he had any pain. Nine months before this presentation, he had a femoral osteotomy for a subluxating hip at another hospital. Following this osteotomy, his gait had not improved, although he was walking almost as well as he was before that surgery. His health had otherwise not changed, except his mother felt his external rotation of the feet, especially on the left side, was getting worse. On physical examination he was noted to have generalized hypotonia, hip abduction was 60° , full flexion and extension, hip external rotation to more than 90° , and an internal rotation to 60° . The left hip had a click with rotation. Anterior palpation suggested that the femoral

head was subluxating anteriorly. A radiograph was obtained that showed a mild lateral displacement of the femoral head with a healed femoral osteotomy (Figure C7.12.1), and the CT scan showed that it was slightly anterior (Figure C7.12.2). He was observed walking with a posterior walker and severe external rotation of the left hip. The cause of his decreased walking tolerance was thought to be the anterior hip subluxation, and he had a Pemberton pelvic osteotomy without a varus femoral osteotomy because the soft tissue was believed to have enough laxity (Figure C7.12.3). By 1 year after the surgery, he had returned to his usual walking tolerance, and by 6 years after surgery, he was a fully independent community ambulator with a stable hip (Figure C7.12.4). Although he continued to have external foot progression on the left and bilateral back-knee, he was without symptoms (Figure C7.12.5).

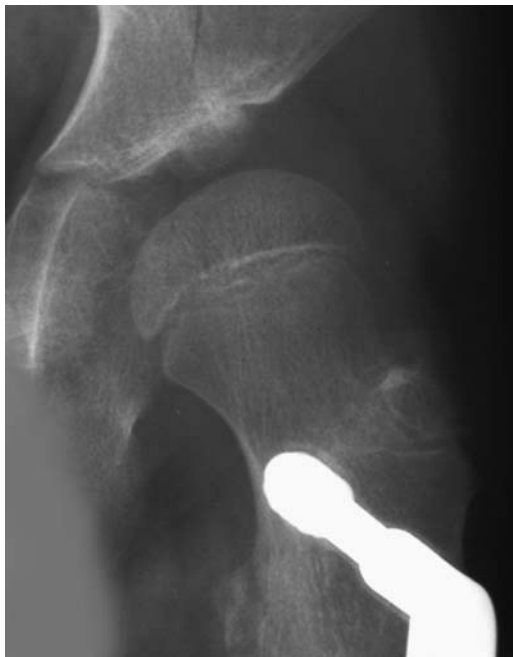

Figure C7.12.1

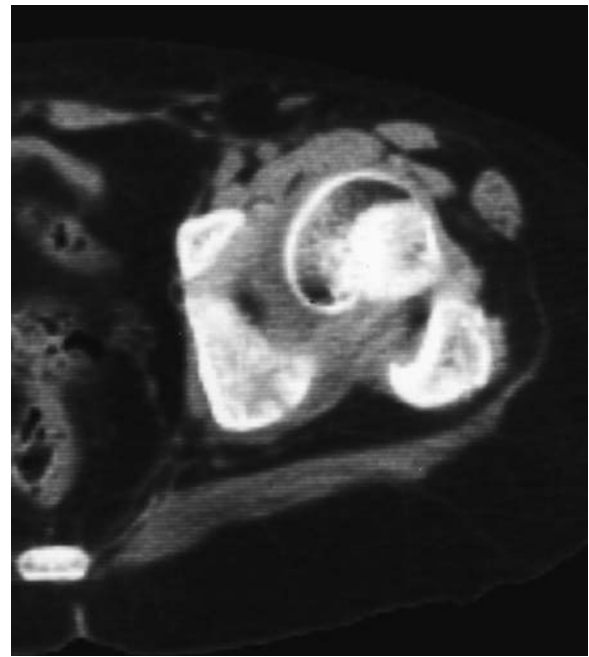


Figure C7.12.2

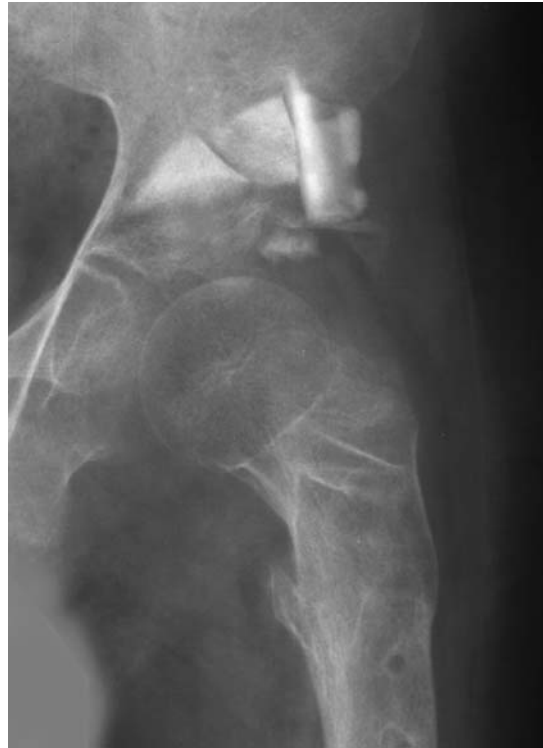

Figure C7.12.3

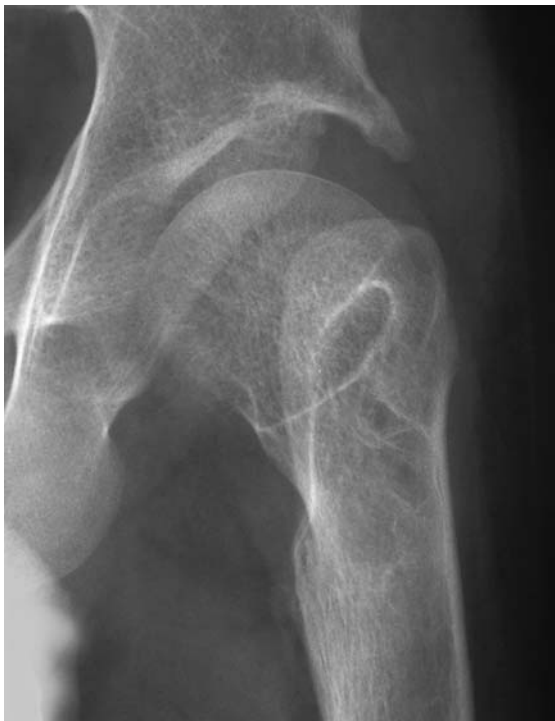

Figure C7.12.4

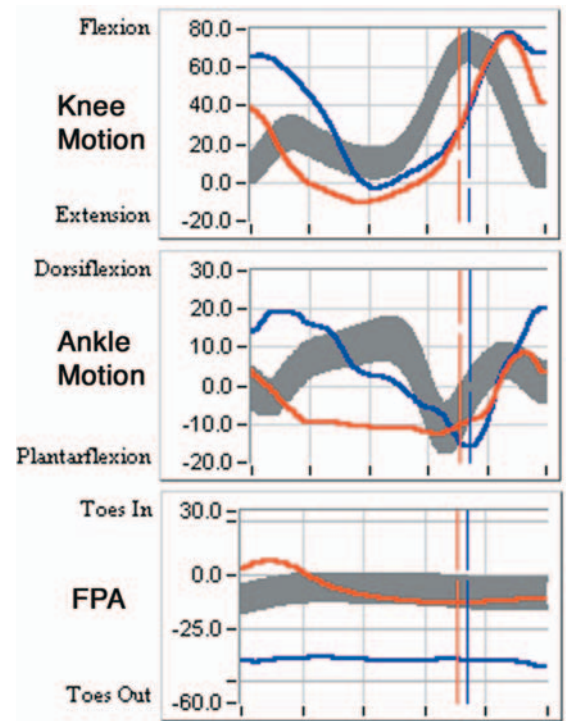


Figure C7.12.5

Table 7.9. Segment and joint compensations.

Problem	As the primary etiology	Compensatory effect for
Pelvis		
Increased anterior tilt	As part of lumbar lordosis that is compensated by increased hip flexion	Compensating for a hip flexion contracture or hip extensor weakness
Increased tilt motion		Hip stiffness or hip weakness
Asymmetric pelvic rotation	Hemiplegia type motor control	Asymmetric femoral rotation with the pelvis posterior on the internally rotated side
Increased rotation		Decreased push-off from gastrocnemius, hip stiffness, hip flexor weakness
Asymmetric pelvic obliquity	Lumbar scoliosis	Hip abduction or adduction contracture, limb length discrepancy, ankle plantar flexion contracture
Increased drop on swing side		Abductor muscle weakness
Hip		
Decreased flexion in swing	Hip joint stiffness or extension muscle contractures (hamstrings or gluteus)	Weak push-off power burst from the ankle plantar flexors
Decreased flexion	Hip flexor weakness	
Decreased extension stance	Hip flexor contracture, joint stiffness	Lack of knee extension
Increased abduction	Weak adductor muscle, joint or abductor contractures	Adduction contracture of the opposite hip, ataxia
Increased adduction (scissoring)	Adductor contracture	Poor motor control
Increased internal rotation	Increased femoral anteversion, contracture of internal rotators	Asymmetric pelvic rotation, external tibial torsion
Increased external rotation	External rotation contracture, retroversion of femur	Asymmetric pelvic rotation often due to opposite hip internal rotation, internal tibial torsion
Knee		
Increased flexion at foot contact	Knee flexion contracture, premature hamstring activity, hamstring contracture, toe strike due to ankle equinus, weak push-off, or hip flexor	
Decreased knee flexion at foot contact	Weak hamstrings	Quadriceps weakness, hypotonia
Lack of weight acceptance knee flexion	Knee stiffness	Ankle plantar flexor contractures
Decreased midstance flexion (back-knee)	Contracture or overactivity of gastrocnemius, or weak gastrocnemius	Poor motor control, hamstrings that are too weak compared with the gastrocnemius
Increased midstance flexion (crouch)	Knee joint contracture, hamstring contracture, lever arm disease (planovalgus feet)	Lack of plantar flexion, balance problems, severe abnormal foot progression angle, hip flexion contracture, ankle equinus
Lack knee flexion swing (stiff knee gait)	Overactivity of the rectus muscle, knee stiffness, quadriceps contracture	Poor push-off power from the gastrocnemius, poor hip flexor power
Foot		
Equinus at foot contact	Gastrocnemius and/or soleus contracture, weak dorsiflexors	Severe knee flexion contracture
Lack of first rocker	Gastrocnemius and/or soleus contracture or muscle overactivity, ankle stiffness, weakness of dorsiflexors	
Premature second rocker	Lack of first rocker, spastic or contracted gastrocnemius or soleus	Lack of knee extension in midstance
High early plantar flexion moment	Spastic or contracted gastrocnemius or soleus	
Decreased late stance plantar flexion moment	Contracture of gastrocnemius, or weak gastrocnemius	
Decreased push-off power	Lack of plantar flexion in third rocker	Lever arm disease, planovalgus, severe torsional malalignment
Internal or external foot progression	Tibial or femoral torsion, planovalgus, or varus feet	Severe muscle weakness or poor balance, and is used to stabilize posture



Case 7.13 Christopher



Christopher, a 6-year-old boy, presented with a diagnosis of CP and a peculiar gait pattern. His parents were concerned that he tripped a lot and they wanted to improve the appearance of his walking. He had normal speech and was cognitively age appropriate. He had no other medical problems, and his parents felt that he had had very little change in his gait in the past year. On physical examination he had significant spasticity in his left upper extremity, with internal rotation at the shoulder, elbow flexion, and wrist flexion. He could use gross grasp of the fingers. He was using the hand as a helper hand without prompting. He had full hip flexion and extension, and abduction was 15° on the left and 28° on the right. Internal rotation of the hip was 80° on the left and 50° on the right. External rotation was 5° on the left and 30° on the right. Knee popliteal angles were 55° on the left and 40° on the right. Ankle dorsiflexion with extended knee was -7° on the left and 0° on the right. Dorsiflexion with the knee flexed was 0° on the left and 8° on the right. His gait demonstrated severe pelvic rotation with the left side being posterior 45° to 65° throughout the whole cycle. The left knee appeared to be internally rotated rel-

ative to the pelvis. The right foot was internally rotated and the left foot was neutral. Both knees were in hyperextension in midstance, with increased knee flexion at foot contact. The upper extremity was held in elbow flexion and internal rotation of the shoulder. Christopher's pelvic rotation seemed mostly caused by asymmetric hip rotation with the left hip being internally rotated; therefore, a left femoral derotation osteotomy was performed to correct this. The deformity was probably being exaggerated because of his hemiplegic motor control problems. Lengthening of the adductor on the left also helped to allow the limb to externally rotate and abduct. Lengthening the tendon Achilles on the left and the gastrocnemius on the right helped the knee extension in midstance. Following these procedures, the pelvic rotation improved significantly; however, he developed a planovalgus foot, partly due to a split transfer of the tibialis posterior tendon, which should not have been done. Several other operative procedures for other problems were required during his growth period; however, the pelvic rotation remained corrected until he reached full maturity.

Pelvic Rotation

Asymmetric pelvic rotation may be primarily caused by motor control, or as a secondary adaptation for asymmetric hip rotation. Children with very asymmetric neurologic involvement, especially severe hemiplegic patterns, often lead with the most functional side of the body. Leading with the functional side of the body seems to be a motor control attractor, probably because it is easier to control the impaired limb in the trailing position. If the asymmetry is only 10° to 20° , trailing of the involved side is not very cosmetically apparent and usually needs no treatment. Most rotations greater than 20° are cosmetically apparent and cause functional problems, such as increased tripping and poor coordination, especially in highly functional ambulators. If the rotation is severe, sometimes reaching 45° to 60° , children are walking sideways, which is ineffective and very cosmetically noticeable (Case 7.13). Severe rotation is often a combination of asymmetric hip motion and motor control, which should be addressed by making all efforts to correct hip asymmetries and even slightly overcorrecting these asymmetries. Many children have pelvic rotation asymmetry due to asymmetric hip rotation or adduction. Physical examination should focus on hip rotation with hips extended and with hip abduction. The hip on the side of the pelvis that is rotated posteriorly should have more internal rotation or have less passive external rotation. Typically, this hip has increased adduction and often flexion contracture as well. The treatment is to do a unilateral hip derotation

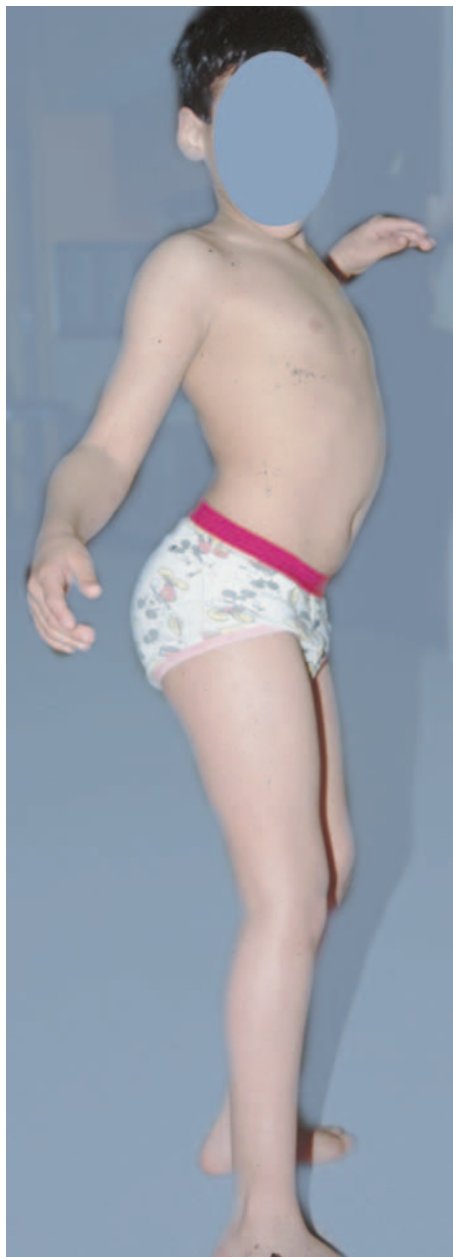


Figure 7.40. Some children who are independent ambulators have significant hamstring contractures requiring lengthening of the hamstrings. They should be carefully examined to be sure that there are not significant hip flexor contractures. This boy, 1 year after hamstring lengthening, has developed severe hyperlordosis primarily because the hip flexors were not lengthened. There are children, however, who naturally take on this posture and, when they are examined, do not have a hip flexion contracture.

and adductor lengthening if the adductor is contracted, meaning there is less than 20° of hip abduction with the knee extended. Excessive adductor lengthening should not be done; a percutaneous adductor longus tenotomy only is often sufficient.

Pelvic Tilt

Anterior pelvic tilt may have increased magnitude, be asymmetric, or be increased in either direction. Increased magnitude of pelvic motion is very common and is related to increased tone in the lower extremities. Also, the increased magnitude serves as another proximal power input joint as a way of propelling the swing limb forward. This increased stiffness and use of pelvic tilt is also present with hip flexion contractures, specifically the iliopsoas, and has been called the double bump pelvic motion. This term is somewhat misleading because it suggests a new pathologic movement pattern of the pelvis, which is not true. This pelvic motion is only a magnification of the normal movement. Again, in many patients, this pelvic motion serves a useful secondary adaptation to help with swing phase in a limb with increased stiffness or decreased power output. If children are very functional with good ankle push-off power generation, it is possible to decrease this pelvic motion through lengthening the hamstrings and the psoas, which increases the hip joint range of motion. If the hip is the main source of power output, these lengthenings run the risk of shifting the length–tension curve such that the weakness of the hip muscles will be magnified and the pelvic tilt range may increase even more to compensate.

Increase in anterior pelvic tilt primarily occurs due to increased hip flexion contractures, or secondarily occurs due to increased lumbar lordosis. The normal upper range for anterior pelvic tilt is 15° to 20° , although this varies somewhat with different marker placement algorithms. An increase to 25° is common in children with CP. Weakness of the hip extensors and increased force in the hip flexors are the primary causes of increased anterior pelvic tilt. Primary lumbar lordosis is another cause, and it may be difficult to separate primary lumbar lordosis from lumbar lordosis as a secondary response to increased anterior pelvic tilt due to increased hip flexion forces. Increased pelvic tilt and lumbar lordosis are strong attractors in motor control, possibly because they increase stability and lock the lumbar spine, thereby producing more mechanical stiffening. Iliopsoas lengthening should be performed if lumbar lordosis is flexible, hip flexor contracture is present, hamstring lengthening is needed to improve knee kinematics, and these individuals are independent ambulators. If a child does not meet all these criteria, iliopsoas lengthening may have more side effects than benefits. If the lordosis is stiff, muscle surgery will not affect anterior pelvic tilt. If the iliopsoas is not contracted, psoas lengthening will only weaken effective hip flexion. However, if hamstring lengthening is performed and the contracted hip flexor is not lengthened, the anterior pelvic tilt will almost definitely get worse. These individuals often develop the jump position with forward lean of the trunk on the anterior tilted pelvis. Over time, the compensation is obtained by having increased lordosis (Figure 7.40). For individuals who use walkers or crutches, hip flexor lengthening will increase apparent weakness due to increased anterior pelvic tilt from always leaning forward.

Increased posterior tilt is usually defined as abnormal if there is any posterior tilt past neutral. The principle cause of posterior pelvic tilt is a contracture of the hamstrings. The posterior pelvic tilt has to be correlated by physical examination. The posterior tilt may be due to gluteus contractures; however, we have never seen this in children with CP. Treatment is lengthening of the hamstrings if they are contracted. A secondary cause of posterior

pelvic tilt is lumbar kyphosis or, more commonly, total spinal kyphosis. Correction of the kyphosis will correct the posterior pelvic tilt.

Pelvic Obliquity

Most causes of abnormal pelvic obliquity are due to asymmetric contractures of the hip adductors or abductors or weakness of one of the muscle groups. This pelvic obliquity may be secondary to apparent or real limb length discrepancy, or it may be secondary to fixed scoliosis. Pelvic obliquity may be asymmetric when one side has strong muscles and hip hiking on the swing side is used to help with clearance.

The Trendelenburg gait, often discussed by writers concerned with hip pathology, is really only a magnification of normal movement pattern, much like the double bump anterior pelvic motion. This gait is a response to mild weakness in the abductors as the hip on the swing side drops more to pre-tension the abductor muscle until it finds the strength to resist. Increased movement of the center of mass of the HAT segment over the weightbearing limb is usually combined with this, thereby decreasing the force needed to resist the drop of the pelvis. This pattern may also suggest mechanical instability of the hip joint, such as hip subluxation,⁵⁶ and hip radiographs should be obtained. With severe weakness of the abductor muscles, the center of mass of the HAT segment will move completely over the weightbearing limb, usually with elevation of the pelvis on the swing side. This movement is called a hip lurch, in which the trunk muscles can also be used to control the drop of the pelvis on the swing limb side (Figure 7.41). Treatment of Trendelenburg gait is by strengthening of the abductor muscles when possible. Treatment of the lurch gait pattern is by strongly encouraging patients to use forearm crutches, which will decrease both the energy of walking and the force on the joints in the lower extremities, especially the knee joint. Some of these movement patterns may also occur secondary to pain in the hip joint. Therefore, a good history should be available with the gait analysis.

Figure 7.41. Obliquity of the pelvis can change in different ways to accommodate muscle weakness, hip pain, or motor coordination problems. In normal gait, the abductors are used to maintain the pelvis with only minimal motion. As the muscles develop mild weakness, the pelvis may drop on the swing limb side in a motion commonly called Trendelenburg gait. There is little movement of the center of mass in this gait pattern. As the weakness or pain becomes more severe, the pelvis raises on the swing limb side as the center of mass moves laterally over the stance phase limb, causing a gait pattern commonly called a lurch. As the muscle weakness becomes more severe, the pelvis may drop on the swing limb side as the center of mass moves laterally over the stance limb.

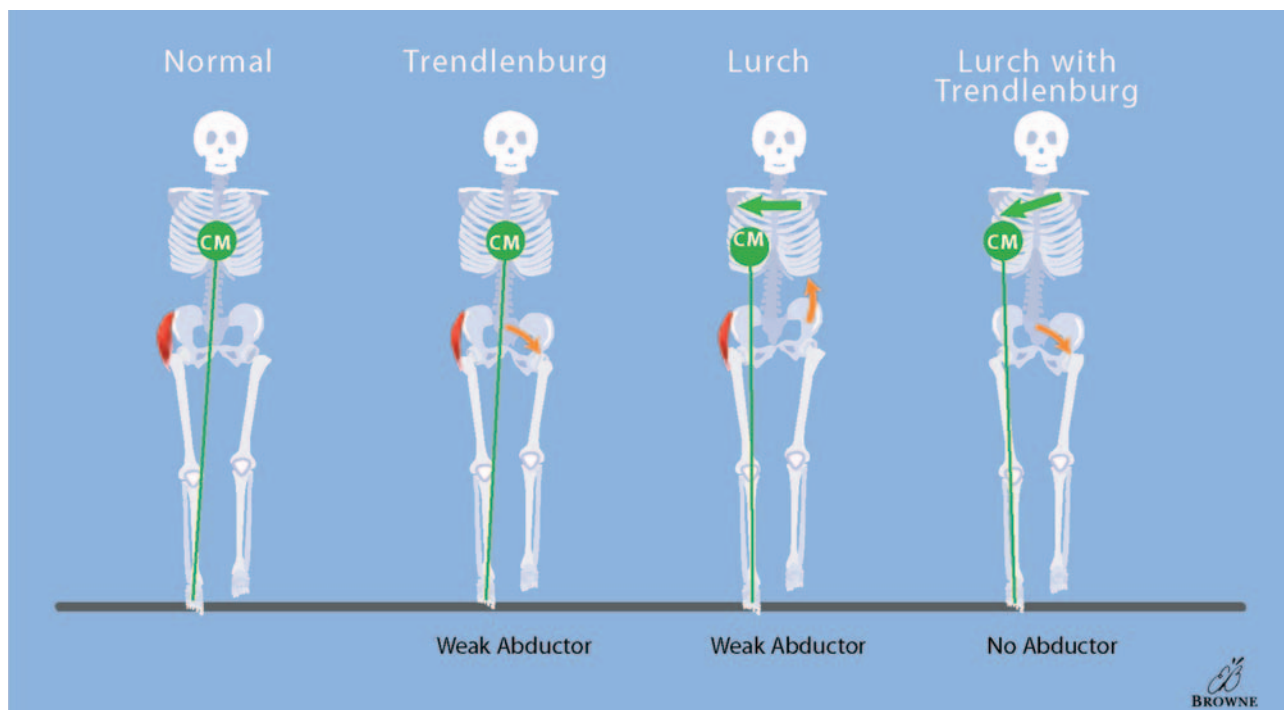
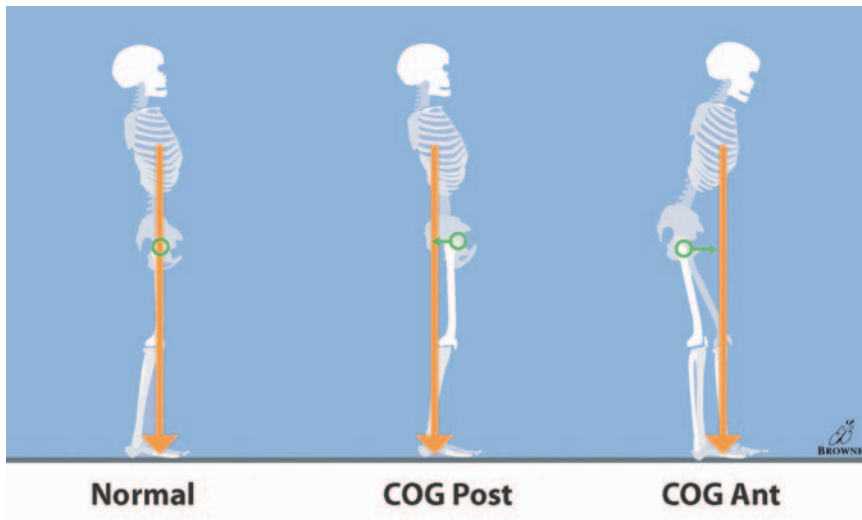


Figure 7.42. The motor control system can adjust the trunk alignment and the position of the center of mass or center of gravity (COG) so either the ground reaction force goes directly through the hip joint, therefore requiring little hip muscle power posterior to the hip in which the hip flexors are the main active muscles, or anterior to the hip joint, requiring mainly hip extensor use. It is often hard to understand why the motor control system chooses one pattern over the other in children with CP.



HAT Segment

The real function of gait is to move the HAT segment in space. This segment, however, is not only passive cargo. By the use of trunk muscles, neck muscles, and arm movements, the HAT segment can position its center of mass to assist in gait. In normal gait, the HAT segment primarily involves passive motion, which will cause the center of mass to have the least movement away from the line of progression. Through the motor control system, the center of mass can be positioned in front of the hip joint to allow the hip extensors to be more effective as power generators, or it can be positioned behind the hip joint so the weak hip extensors are not stressed and the anterior hip capsule or hip flexors are the primary supports of the mass (Figure 7.42). As was discussed with lurching, the trunk muscles can output force and provide power for movement in children (see Figure 7.41). The contribution of active power generation of the HAT segment is not well understood. Typically, the trunk is rotated posteriorly on the involved side of individuals with hemiplegia. Often, the arms are in the high to medium guard positions with elbow and shoulder flexion in individuals with poor balance. Treatment specific for asymmetries of trunk motion or increased magnitude is primarily directed at determining the need for assistive devices. Individuals with 20° to 30° of trunk motion side to side usually do better with walking aids such as crutches, especially for long-distance walking.

Cerebral Palsy Gait Patterns, Treatments, and Outcomes

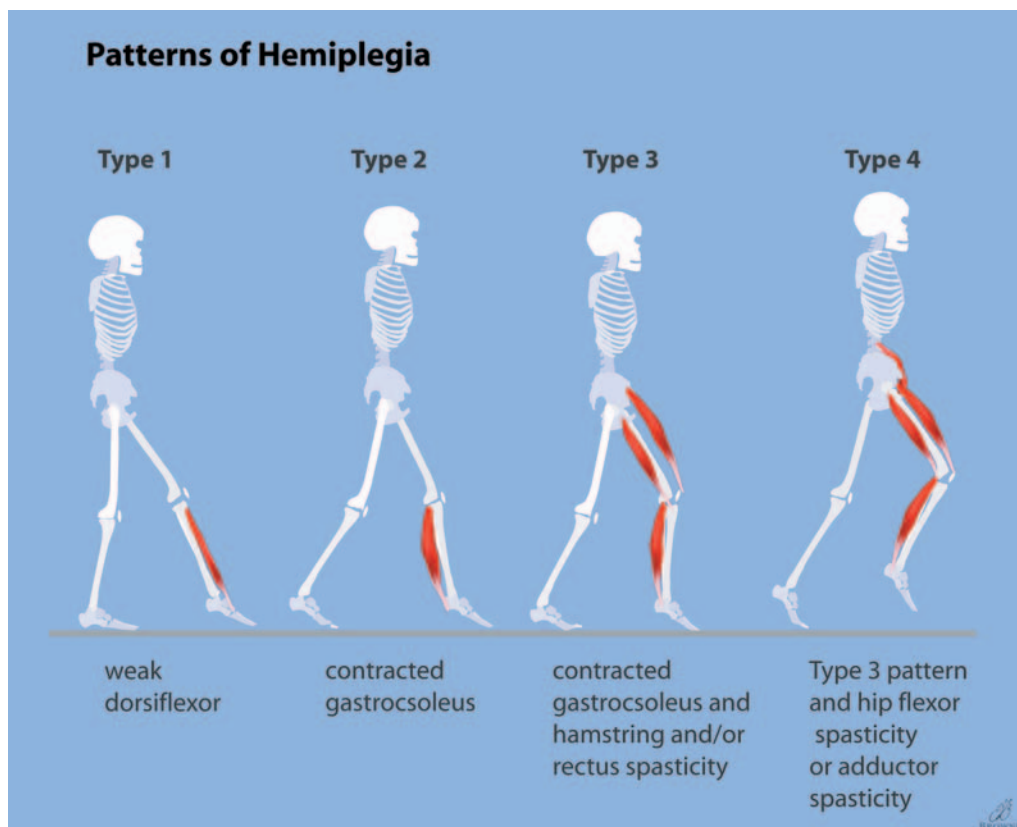
Ambulatory children with CP require treatment of the whole motor system, not consideration of a problem in only one segment or subsystem of the gait's pattern. The goal is to understand all the primary and secondary problems as much as possible, then address all these problems in one operative event. Dr. Mercer Rang popularized the concept of avoiding the birthday syndrome for surgery. The birthday syndrome was a common approach in the 1960s and 1970s. In this treatment approach, children would typically have an Achilles tendon lengthening one year, hamstring lengthening the next year, adductor and iliopsoas lengthening the year after, then they would need another Achilles tendon lengthening. This process would go on with yearly surgery


throughout children's growth years. With tools for gait evaluation, few children should need to have more than two surgical experiences during their childhood years to treat problems related to gait. The surgery can be arranged for children and families so it occurs when the families can best manage the time commitment and children are least impacted with respect to school. As the pathologies for each joint, movement segment, and motor subsystem are combined into the whole functioning musculoskeletal system, patterns of involvement have to be defined. Children's anatomically involved pattern of CP needs to be determined first, meaning separating out hemiplegia from diplegia from quadriplegia. In this overall pattern, children whose primary problems are ataxia or movement disorders also have to be considered. These problems do not fit neatly into the hemiplegia and diplegia pattern of involvement. Within each of these patterns, there has to be a further sub-categorization to reach an understanding of the most common patterns.

Hemiplegia

Almost all children with hemiplegic pattern CP walk. Typically, these children are very functional ambulators, and their major orthopaedic problems are related to improving gait pattern and upper extremity position. A few children, usually with severe mental retardation, do not become functional ambulators. Often, nonambulation is related to poor function in the upper extremity, which makes the use of an assistive device difficult. There have been several attempts to classify patterns of hemiplegic gait,^{57, 58} but the classification of Winters et al.⁵⁸ is easy to remember and has the most direct implications for treatment (Figure 7.43). This classification divides hemiplegic

Figure 7.43. The best classification of hemiplegia is that of Winters et al.,⁵⁸ in which type 1 is due to a weak or paralyzed ankle dorsiflexor causing a drop foot. Type 2 has equinus foot position due to a contracture of the gastrocnemius or gastrosoleus preventing dorsiflexion. Type 3 has spastic or contracted hamstrings or quadriceps muscles in addition to type 2 ankle. Type 4 has spastic or weak hip muscles in addition to type 3 deformity. Almost all patients are relatively easy to classify into one or the other type, which is then helpful for planning treatment. Transverse rotational plane malalignments do not fit into this classification and should be seen as an additional problem.





Case 7.14 Tania

Tania, an 18-year-old girl, had hemiplegia as result of a traumatic brain injury sustained at age 8 years. Her main complaint was that she could not lift her foot. Physical examination of her right ankle demonstrated an active toe extensor, and some apparent activity of the tibialis anterior on withdrawal stimulus of a pin stick on the sole. Ankle dorsiflexion was 10° with knee flexion and 20° with knee extension. Ankle kinematics showed no active dorsiflexion in swing phase and no EMG activity of the tibialis anterior (Figure C7.14.1). Observation of her gait demonstrated an extended hallux in swing phase, but no apparent dorsiflexion was in swing phase. Knee and hip motion appeared to be normal. She was ordered a leaf-spring AFO that worked well when it was worn.

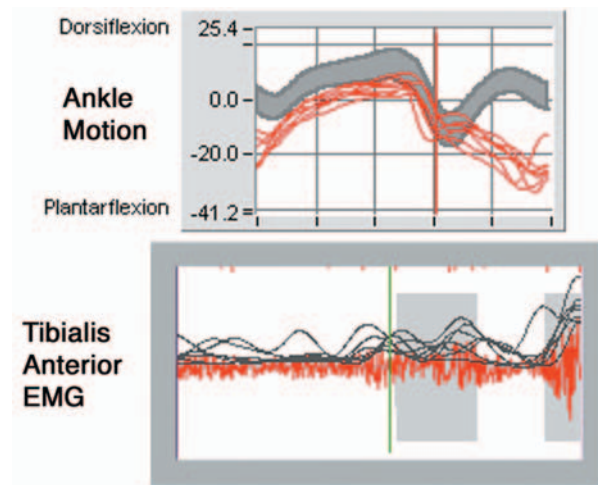


Figure C7.14.1

gait into four patterns. Type 1 has ankle plantar flexion in swing phase with an inactive or very weak tibialis anterior, which is the cause of the plantar flexion. Type 2 has an equinus gait pattern but with spastic or contracted plantar flexors, which overpower an active dorsiflexor. Type 3 includes the ankle position of type 2, further adding abnormal function of the knee joint. Type 4 includes all problems of type 3 with the addition of abnormal function of the hip joint muscles. The separation of these types is usually easy through a combination of physical examination, EMG, kinematic evaluation, and kinetic data. As with all biological groups, however, there are intermediate patients. This system does not consider transverse plane deformities; however, most children with significant residual internal femoral torsion are types 3 or 4, and tibial torsion occurs with types 2, 3, or 4.

Type 1

In children with hemiplegic pattern CP, type 1 is the least common pattern of involvement. Type 1 occurs more with adult stroke or with a peripheral nerve injury. If this type is identified in a child with CP, the physical examination will demonstrate full passive dorsiflexion; however, no active dorsiflexion can be demonstrated. The kinematic examination will show plantar flexion at initial contact and no dorsiflexion in swing phase. The EMG will demonstrate a tibialis anterior that is silent or nearly silent. The primary treatment for type 1 hemiplegia is a relatively flexible leaf-spring AFO (Case 7.14). In very rare situations where the tibialis posterior has normal tone and normal phasic firing, the tibialis posterior can be transferred through the interosseous membrane to the dorsum of the foot. However, this transfer is mainly used with peripheral nerve palsy. With central lesions, relearning is difficult as this is an out-of-phase transfer, and transfer of the spastic tibialis posterior leads to very severe foot deformities.

Type 2

The most common subtype of hemiplegia is type 2, making up approximately 75% of all children with hemiplegia. Typically, children learn to walk independently between 15 and 20 months of age, either with toe walking or foot flat with a planovalgus. The early treatment is to provide the children support through the use of an orthotic, usually starting with a solid ankle AFO, then following with an articulated AFO for the second orthotic. If a child has a very spastic gastrocnemius, botulinum toxin injection for two or three cycles can help parents apply the AFO and make AFO wear more comfortable for the child. Usually, by 4 to 7 years of age, the gastrocnemius contracture has become so severe that brace wear is no longer possible. On physical examination, children often demonstrate a contracture of both the gastrocnemius and soleus. The kinematic examination will show equinus throughout the gait cycle, and knee flexion at foot contact may be increased as children preposition the knee to avoid high external extension moments from the ground reaction force during weight acceptance. Often, these children will be toe walking on the unaffected side as well, and a careful assessment is required to make sure that this is compensatory toe walking and not mild spastic response in a limb that was erroneously thought to be normal. The physical examination and kinematic evaluation are most useful for this assessment. The unaffected ankle should have adequate dorsiflexion measuring 5° to 10° with knee extension. The ankle moment should show normal late stance phase plantar flexion moment or a variable moment, one or two of which may look almost normal. The affected ankle will also be more consistently abnormal with high early plantar flexion moments. If children have been allowed to walk on the toes until late middle childhood, their unaffected ankles will often develop plantar flexion contractures from persistent toe walking. The physical examination will show a reduced ankle range of motion, and the ankle moment will still show the same variability with much better power generation than the affected ankle. The step length of the affected side is usually longer and the stance phase time of the normal limb is longer. These changes occur because the affected leg has a normal swing phase but is more unstable in stance phase. If the normal ankle is contracted it will need a gastrocnemius lengthening or the normal ankle will become a driving force toward toe walking after correction of the contracture on the primarily involved side (Case 7.15).

Outcome of Tendon Lengthening

The need for postoperative orthotic use varies, but braces are not routinely needed. If children do not gain foot flat at initial contact by 3 to 6 months after surgery, an AFO should be used, usually an AFO that allows dorsiflexion to encourage the tibialis anterior to gain function. This AFO can be either an articulated AFO or a half-height wrap-around AFO with an anterior ankle strap. With appropriate early treatment, most children with type 2 hemiplegic pattern CP can be free of an orthosis by early grade school. Some children will develop an equinus contracture again in late childhood or adolescence. If an adolescent is willing to tolerate the orthosis, another round of Botox injections and orthotic wear can delay surgery until he is near the completion of growth. Approximately 25% of type 2 hemiplegics will need a second gastrocnemius or tendon Achilles lengthening in adolescence. Adolescents or young adults with type 2 hemiplegia should seldom need to wear an orthosis after this last lengthening. Long toe flexor spasticity may also be present, but this seldom needs surgical treatment.

In early childhood, the feet are often in a planovalgus position; however, as children gain increased tone, gastrocnemius and soleus equinus develops.



Case 7.15 Christian



Christian, a boy with hemiplegia, started walking at 17 months of age. He used a solid ankle AFO until he was 2.5 years old. He then used articulating AFOs until he was 4 years old, when he complained that the orthotics caused him pain. After multiple attempts to make the orthotics comfortable, he was allowed to walk without orthotics for 1 year until age 5 years, when he had a full analysis. The physical examination demonstrated that he had popliteal angles of 35° bilaterally, and ankle dorsiflexion on the right was only -25° with both knee flexion and extension. On the left, he had ankle dorsiflexion to 20° with knee flexion, but only 5° with knee extension. The observation of his gait showed that he was toe walking bilaterally, although higher on the right than the left. It was recommended that he have an open Z-lengthening of the tendon Achilles. Postoperatively, he used an articulated AFO for 1 year, and following this, he developed good active dorsiflexion with a plantigrade foot position (Figure C7.15.1).

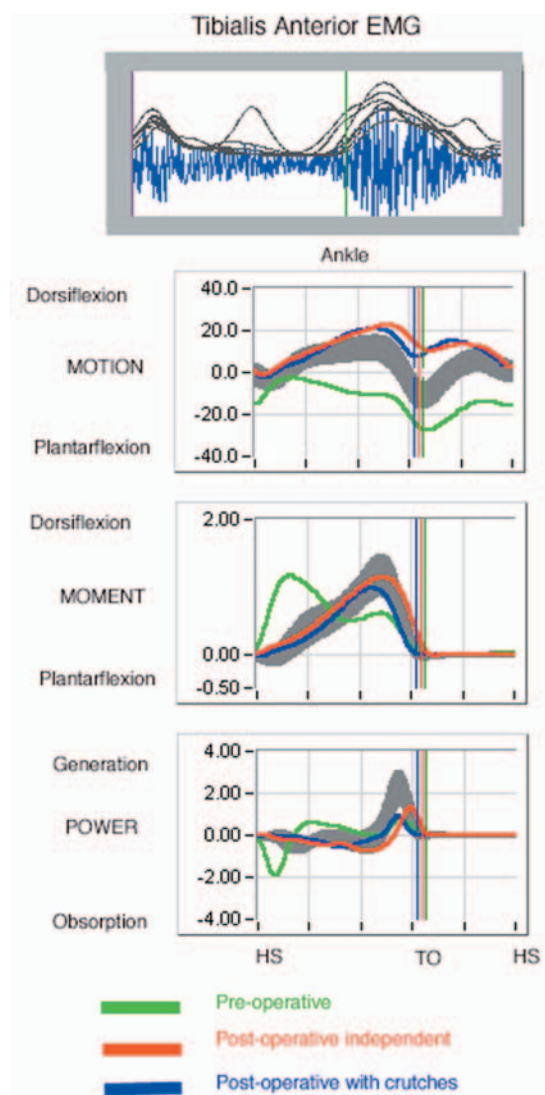


Figure C7.15.1

Almost always, this equinus causes the planovalgus to correct and sometimes even overcorrect. Children with type 2 hemiplegia develop planovalgus that needs treatment only on rare occasions. Surgical treatment should not be considered until 8 to 10 years of age because this planovalgus frequently resolves spontaneously. The predominant problem for children with type 2 hemiplegia is equinovarus, usually due to a spastic or overactive tibialis posterior. In occasional children, equinovarus is due to a spastic tibialis anterior. The diagnosis as to the cause of the varus between these two tendons requires a com-

bination of physical examination and EMG data. The physical examination will often demonstrate increased tone in the muscle most responsible. The EMG should show a tibialis anterior that is active during preswing and initial swing phase, and again in terminal swing at initial contact. Significant activity during midstance is abnormal. The tibialis posterior may be active throughout stance phase, more so in terminal stance, and should be silent in swing phase.⁵⁹ Most commonly, the tibialis posterior is constantly active on EMG and spastic on physical examination, although there are cases where it is only active in swing phase. If the subtalar motion is supple, allowing full correction of the varus, a split transfer of the tibialis posterior to the peroneus brevis on the lateral side is performed. If the tibialis anterior is most affected, it is split transferred to the cuboid or to a slip of the peroneus longus. If both tendons are abnormal, both can have a split transfer performed at the same time. If the subtalar joint is not allowing overcorrection into some valgus, a calcaneal osteotomy may be required, although this is rare in type 2 hemiplegia.

Rotational Deformities

Transverse plane torsional deformities are not common in type 2 hemiplegia and are usually mild, similar to torsional deformities in normal children. Because the torsional deformities are mild, surgical treatment should not be considered until late middle childhood or adolescence. Limb length discrepancy is usually approximately 1 cm shorter on the involved side, which is anatomically perfect. Shoe lifts should not be given, as they will only require children to make an adaptation, which increases the difficulty of swinging the leg through. This degree of shortness causes no short-term or long-term problems.

Treatment of the spasticity, which is limited to the plantar flexors in type 2 hemiplegia, is only by local measures such as tendon lengthening, Botox, and/or bracing. There is no role for dorsal rhizotomy or intrathecal baclofen because the local treatments are effective and much simpler. Because both the gastrocnemius and soleus seem to contract together in many of these children, it is reasonable to consider nighttime orthotic wear to try to stretch the soleus and perhaps the gastrocnemius. A nighttime orthosis is usually attempted when contractures are present; however, most children object to this orthosis because they are unable to fall asleep and therefore, in practice, this seldom works.

Type 3

Children with type 3 involvement have all the concerns and problems of the children with type 2 involvement. Children with type 3 hemiplegia tend to start walking slightly later than with type 2, usually at 18 to 24 months of age. They almost all start walking on the toes of both feet but usually will not need assistive devices to start walking. The diagnosis of type 3 hemiplegia requires establishing evidence that the knee is involved in the pathology as well. On physical examination, there may be increased tone in the hamstrings or rectus muscles and increased hamstring contracture, usually at least 20° and often 30° to 40° more than the unaffected side. Knee flexion at initial contact will be high, more than 25°. In midstance, the knee flexion continues to be increased. All type 3 patterns have abnormal hamstring activity. On the EMG, this activity is usually premature onset in swing phase and prolonged activity in stance phase. The presence of a fixed knee flexion contracture of more than 5° is also evidence of hamstring involvement. The step length is usually shorter than the normal side and the stance time is variable, sometimes longer and sometimes shorter depending on the stability of stance phase (Case 7.16). Treatment of the hamstring contractures and overactivity may



Case 7.16 Kwame



Kwame, an 18-month-old boy, was initially seen with a complaint that he was late in learning to walk. He was reported to have been premature by 8 weeks, but had been healthy since discharge from the hospital. On physical examination he had increased tone through the lower and upper extremities, but it seemed worse on the left side. He was placed in an AFO and, over the next 6 months, he started walking. By age 5 years, he was developing significant internal rotation of the femur and having a stiff knee gait as well as significant toe walking bilaterally. At this time, the physical examination showed that he had hip abduction of 25° on the left and 45° on the right, and internal rotation on the left of 75° and on the right of 60° . The popliteal angle on the left was 68° compared with 50° on the right. The left ankle dorsiflexion with the knee extended was -20° , while on the right it was 4° . The knee flexed ankle dorsiflexion on the left was -8° , while on the right it was 11° . The kinematics demonstrated low nor-

mal knee flexion in swing phase, increased knee flexion at foot contact, bilateral early ankle dorsiflexion in stance phase, with less total dorsiflexion on the left side. Internal rotation of the left femur was also noted (Figure C7.16.1). The EMG showed much less clear activity patterns on the left with the rectus having high variability and the hamstring having very early initiation on the left. The right side looked normal (Figure C7.16.2). Except for the internal rotation of the hip, the primary pathology seemed to be in the left knee and ankle; therefore, this is a type 3 hemiplegia. Based on this, the femur was derotated, hamstring lengthened, distal rectus transferred to the sartorius, and a tendon Achilles lengthening was performed (Figure C7.16.3). He did well for 4 years, but then he again developed a significant ankle equinus requiring a second tendon Achilles and distal hamstring lengthening. As he entered puberty, he was doing well with a nearly symmetric gait pattern.

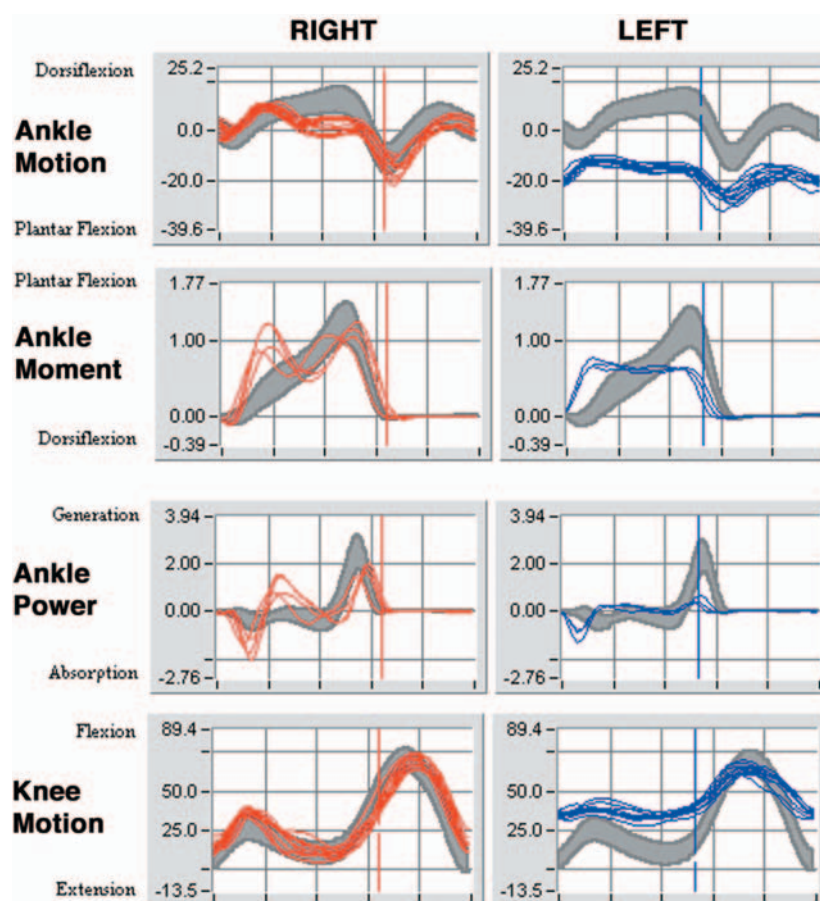


Figure C7.16.1

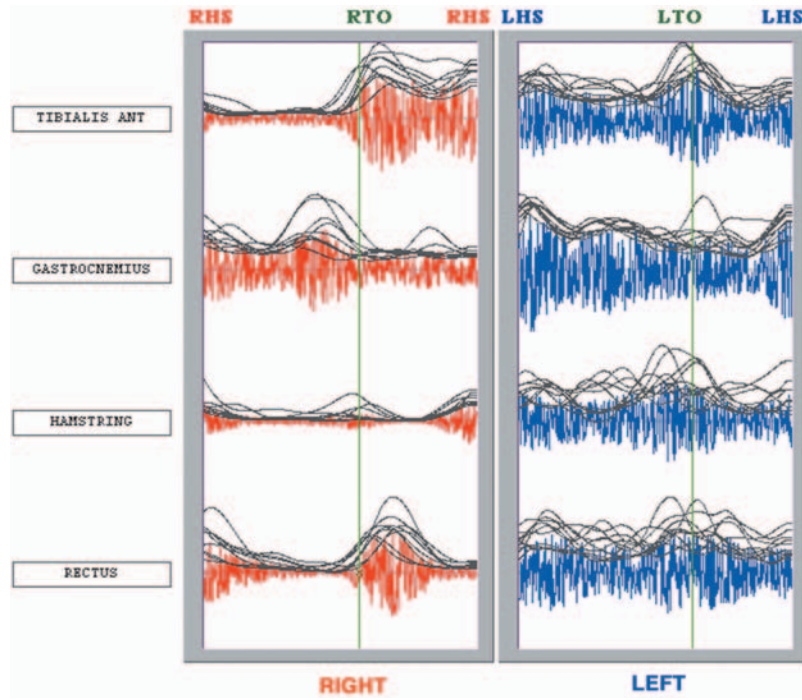


Figure C7.16.2

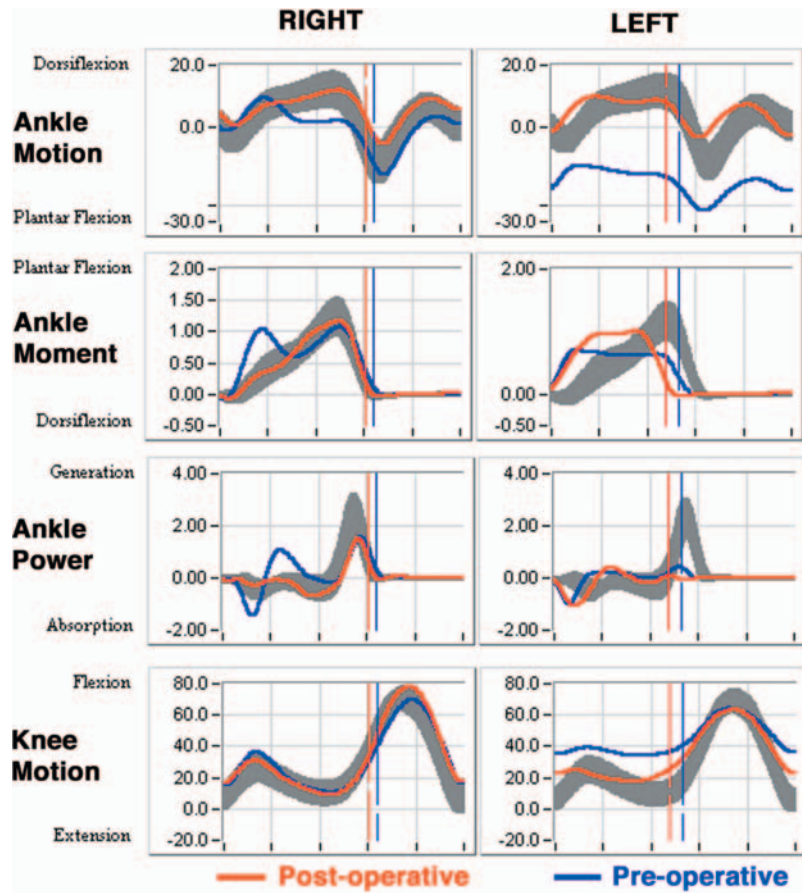


Figure C7.16.3

be with botulinum toxin injections for several cycles in young children, along with gastrocnemius injections. When the hamstring contracture is causing progressive knee flexion contracture, surgical lengthening should be performed. If the gastrosoleus contractures need to be addressed, the hamstrings should also be lengthened at the same time, or knee flexion in midstance will draw these children to either toe walk again or stand with a crouched gait on the affected side, which also draws the unaffected side into a crouched gait pattern with increased knee flexion in stance.

Stiff Knee Gait

Some children with type 3 hemiplegia have involvement of the rectus. This involvement will be noted by the parents as a complaint of toe dragging, frequent tripping, and rapid shoe wear, especially on the anterior aspect of the shoes. The physical examination may or may not demonstrate increased rectus tone and a positive Ely test. The kinematic evaluation will show swing phase peak knee flexion to be less than the normal, usually less than 50°, and the peak is often late, close to midswing. For children with late or low knee flexion in swing, when the EMG activity of the rectus muscle in swing phase is increased and evidence of complaints of toe dragging is present, then a distal transfer of the rectus is indicated. This transfer is almost always performed with hamstring lengthening and gastrocnemius or tendon Achilles lengthening. Similar to type 2 hemiplegia, approximately 25% of the children will need two tendon lengthenings, one at age 4 to 7 years, and a second at adolescence. A few children will need three lengthenings. These tend to be children who needed the first lengthening very early, sometimes as early as the third year of life. The goal of delaying the first tendon lengthening is to try to avoid the second or third tendon lengthening, although there is no physical documentation that this strategy is effective.

Rotational Deformities

Transverse plane deformities are more common with type 3 hemiplegic involvement. If tibial torsion or femoral anteversion are causing increased tripping or are very cosmetically objectionable by 5 to 7 years of age, surgical correction can be considered. If children have a very asymmetric pelvic rotation as an adaptation for unilateral femoral anteversion, correction should be considered as early as age 5 to 7 years. Because the functional impairment is greater, the limb length discrepancy tends to be slightly greater than for type 2 hemiplegia, often between 1 and 2 cm at maturity. For most children, this limb length discrepancy works perfectly well to help with foot clearance during swing phase in a limb that does not have as good ability to shorten during preswing and initial swing phase. A shoe lift should not be used, and radiographic monitoring of limb length is needed only with a discrepancy of over 1.5 cm. If the knee flexion contracture is more than 10°, additional shortening will occur. To prevent further leg shortening, knee flexion contracture prevention is important. Like type 2 hemiplegia, there is no role for the global treatment of spasticity in type 3 hemiplegia.

Type 4

Type 4 hemiplegia is the third most common pattern; however, it is relatively rare, probably making up less than 5% of all children with hemiplegia. It is relatively common to find type 4 hemiplegia that overlaps with asymmetric diplegia or mild quadriplegia, and it is uncommon to find a child with type 4 hemiplegia who is completely normal on the contralateral side. Children with type 4 involvement usually walk later, between the ages of 2 and 3 years. Many children will use a walker during the learning period of walking. The

walker usually needs to be fitted with an arm platform on the involved side. The diagnosis of type 4 hemiplegia is made by the presence of increased tone in the adductor or hip flexor muscles and by evidence on the kinematic examination of decreased hip extension in midstance. Both the stance time and the step length will be shortened as the limb neither can swing normally nor is very stable in stance phase. All the problems and considerations of type 2 and type 3 have to now be added into the treatment of type 4. In addition, concern for overactivity and contracture of the adductors and hip flexors has to be considered as well. It is important to recognize that children with type 4 hemiplegia can develop spastic hip disease, so they have to be monitored by physical examination and radiographs for hip dysplasia.

From the perspective of children's gait, the decisions about surgery are usually based mostly on the function at the level of the ankle and knee. Based on the evaluation of these joints, surgery of the hip has to be considered as an additional procedure. Adductor lengthening is only needed occasionally. If the abduction is greater than 20° on physical examination and abduction is present at foot contact, surgery is seldom indicated. Iliopsoas lengthening is indicated if hamstring lengthening is to be done, a hip flexion contracture of more than 20° is present, anterior pelvic tilt is more than 25° , and there is less than 10° of hip flexion at maximum extension in mid- or terminal stance. Usually, these lengthenings are needed only once; however, additional lengthenings, especially hamstring and gastrocnemius lengthenings, are very commonly needed. Probably 75% to 90% of children with type 4 hemiplegia need at least two lengthening procedures and approximately 25% may need a third lengthening procedure. Treatment of the distal problems follows the pattern of type 2 and type 3; however, the muscle tone and contractures tend to be worse.

Rotation Deformities

Transverse plane deformities, especially increased femoral anteversion, are common in type 4 hemiplegia. Usually, this is added to the neurologic tendency for pelvic rotation with the affected side rotated posteriorly. In occasional children, this pelvic rotation may be so severe that they present with almost sideways walking. This sideways walking pattern can also be described as crab walking. This gait pattern is very ineffective and should be addressed at the young age of 5 to 7 years. Femoral derotation, which will then allow the pelvis to rotate anteriorly on the affected side, is required, and children will have a more symmetric gait pattern. Femoral derotation should be considered if the pelvic rotation is more than 15° to 20° on the involved side and the physical examination shows an asymmetric femoral rotation with more internal rotation on the affected side. Femoral derotation can be combined with all the other soft-tissue lengthenings that may be needed. Children with type 4 hemiplegia may develop foot deformities similar to diplegia in which the planovalgus improves into middle childhood, but then gets worse again in adolescence.

Limb Length Discrepancy

Limb length discrepancy should be an active concern because many of these children have 2 to 2.5 cm of shortness on the affected side. The functional impact of the limb shortness is increased with the tendency for knee and hip flexion deformities to add more functional shortening to the real shortening. Also, this leg length discrepancy may be further complicated by adductor contractures that may limit hip abduction allowing the pelvis to drop on the affected side, which further magnifies the limb length inequality. If the limb length cannot be functionally accommodated, the use of a shoe lift

is recommended for type 4 hemiplegia. This group also merits close radiographic monitoring of limb length with the goal in some children of doing a distal femoral epiphyseodesis to arrest growth on the non-involved side. The goal in type 4 hemiplegia is to have the affected limb length equal to 1 cm longer than the non-involved side because of the functional impact of the inability to accommodate for joint positions during stance phase, which take precedence over swing phase dysfunction (Case 7.17). There is benefit to having a longer affected limb only in definite type 4 hemiplegia. In all other types, which make up more than 95% of hemiplegia, the affected limb should be approximately 1 cm shorter for maximum function (Figure 7.44).

In some children with type 4 hemiplegia, the use of intrathecal baclofen can be considered for treating severe spasticity even though it is unilateral. We have not used intrathecal baclofen in this population and there are no reports specifically addressing its use. However, the local treatment of the degree of spasticity present in many children with type 4 hemiplegia is not very effective.

In severe type 4 hemiplegia, an assistive device is needed long term for ambulation. These children usually require a platform walker unless they can walk with one crutch or cane. The most functional device is found by trial and error in physical therapy. In the children who have many ambulatory problems, wheelchairs are needed. Because of the presence of one normal arm, a double-rim one-arm-drive chair should be considered.

Diplegia

Diplegic pattern involvement has a wide spectrum, blending with the quadriplegic pattern at the more neurologically severe end of bilateral involvement and blending with the hemiplegic pattern on the more severely asymmetric end of the spectrum. Attempts to classify diplegic gait patterns usually end with parameters directly related to age, such as limb length,⁶⁰ or indirectly related to age, such as jump position versus crouch⁶¹ (Figure 7.45). There is no easy and relatively separable severity grouping such as is defined for hemiplegia. There are definitely children with mild diplegia and children with severe diplegia, but these groups seem to be opposite ends of a standard distribution curve with a mean being moderate involvement. Severity of involvement tends to increase from distal to proximal similar to hemiplegia; however, there are few children with diplegia with only ankle involvement. Most children with diplegia have some hip, knee, and ankle involvement. The method for planning treatment that is easy to remember and relates directly to the treatment plan is based on the age of children rather than on the individual severity. Therefore, young children, middle childhood aged children, and adolescents to young adults will be the age groups, and within each age group, mild, moderate, and severe involvement is considered.

Diplegia in Young Children (the Prancing Toe Walker)

Mild Involvement

Children with mild diplegia may start walking between 18 and 24 months of age. Usually, these children initiate independent ambulation by toe walking with extended hips and knees. Typically, the spasticity in the gastrocnemius and hamstrings is mild, and there may even be a question of these children being idiopathic toe walkers or mild diplegic pattern CP. The toe walking is easy to control with an AFO, and as children gain motor control and balance, some will start to walk foot flat without an AFO. However, other children will become more spastic, occasionally with severe spasticity requiring Botox injections just to tolerate brace wear. If these children are



Case 7.17 Jeremy

When Jeremy was 9 years old, his parents complained that he tripped over his right leg and could not run. Jeremy had moderate mental retardation and no other history of medical problems. The left side was normal on physical examination, but on the right side he had weakness, especially at the hip abductors and extensors. He had no spasticity of the gastrocnemius, but increased tone in the hamstrings with a popliteal angle of 50° on the right and 30° on the left. Ankle dorsiflexion on the right was 15° with knee flexion and 5° with knee extension. Hip abduction was limited to 10° on the right, full flexion was present, and a 2.5-cm shortness was noted on the right side (Figure C7.17.1). Jeremy was put in an AFO and given a 1.5-cm shoe lift, which improved the tripping symptoms. An adductor and hamstring lengthening was performed, and the leg length was monitored with annual scanograms. Because this was believed to represent a type

4 hemiplegia without much compensation attempted by toe walking, a femoral epiphyseodesis was planned when his remaining growth would leave the right leg approximately equal to 1 cm long. At age 12.5 years, the epiphyseodesis was performed (Figure C7.17.2) and by age 16 years, he was left with several millimeters of increased lengthening on the right side (Figure C7.17.3). He was weaned off of the shoe lift and out of the AFO. At the completion of growth, he walked without assistance. This is the typical limb length problem of type 4 hemiplegia, which should be managed to gain equal limb lengthening to slightly overlengthening on the involved side. With the other types of hemiplegia, the goal is to leave the child with a 1- to 2-cm shortness on the involved side, which will help with limb clearance and accommodate for the tendency for premature heel rise from gastrocnemius spasticity or contracture.

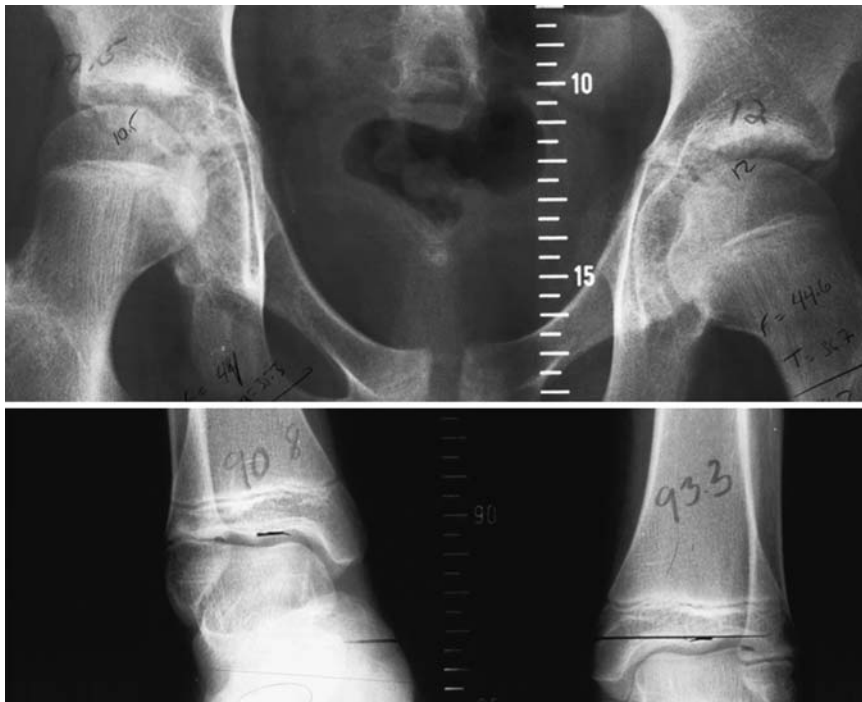

Figure C7.17.1

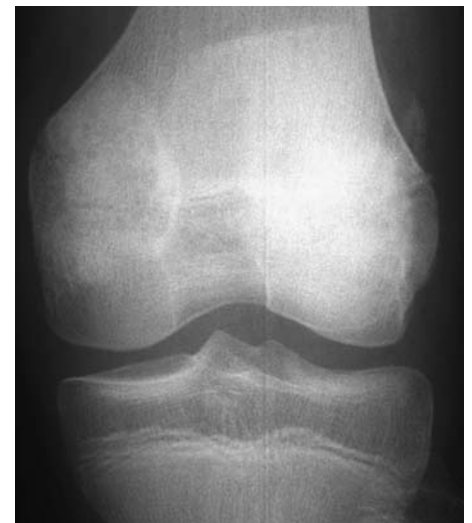

Figure C7.17.2

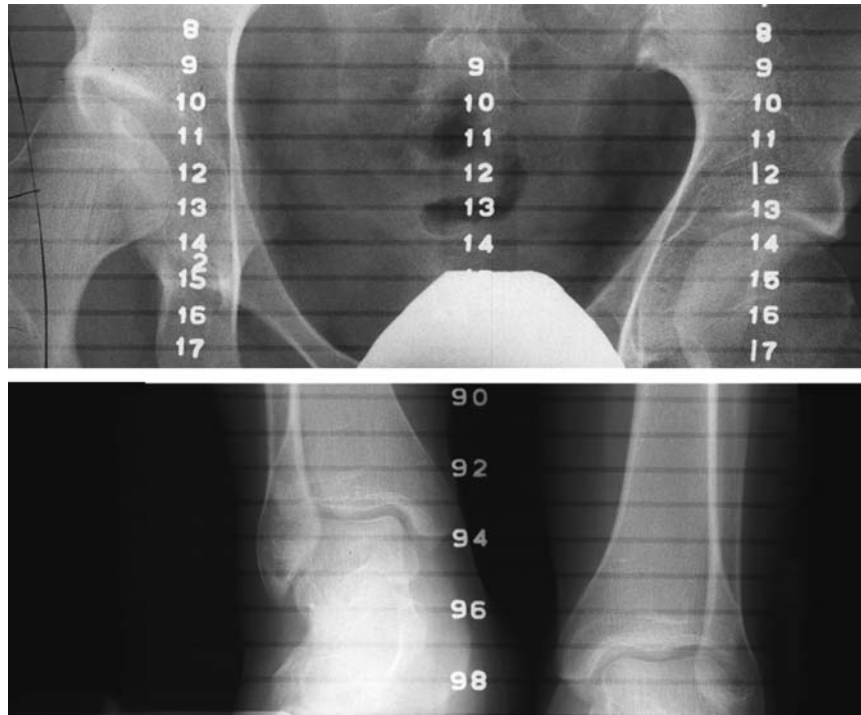
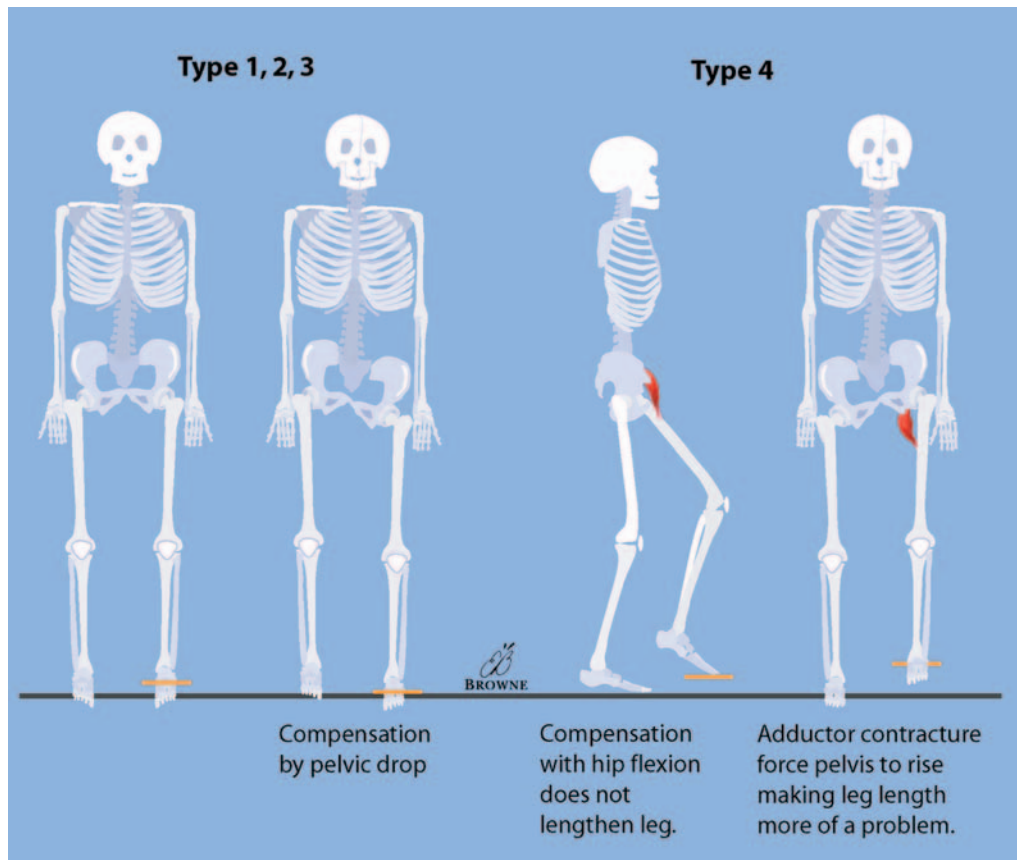


Figure C7.17.3

still toe walking without an AFO by 5 to 7 years of age, surgical tendon lengthening should be considered. If the ankle dorsiflexion with knee extension is less than 5° , and the maximum dorsiflexion in stance phase is occurring during weight acceptance instead of terminal stance, gastrocnemius lengthening is indicated. If there is a high early plantar flexion moment with a big power absorption and poor push-off power generation, gastrocnemius lengthening is also indicated. If the initial contact knee flexion is increased above 20° and the popliteal angle is increased, then hamstring lengthening should also be considered. It is expected that children with mild diplegia will need only one surgical procedure to maximize gait. Most children with mild diplegia do not have transverse plane deformities; however, if they do, the correction can be made at the same time, between the ages of 5 and 7 years (Case 7.18).

Moderate Degree of Involvement

Most children with diplegia would be defined as moderate. If balance is adequate, most moderate children walk independently between the ages of 24 and 36 months. If balance is a problem, walker use will continue to be required, starting with crutch training around 4 to 5 years of age. Functional community ambulation with crutches should not be expected until age 5 years and sometimes will not occur until children are 8 to 10 years old. In the first year of independent ambulation, these children will walk with the arms in the high guard position, walk fast up on the toes, and when they want to stop, they will run to find fixed objects like a wall or fall to the floor. Most children walk with knee stiffness, extended hips and knees, and with increased rotation of the pelvis. Some children have transverse plane deformities with increased femoral anteversion being most common, but they also may have tibial torsion. Many children at this age with moderate diplegia



walk with ankle equinus and varus. Surgical treatment is planned for between 5 and 7 years of age after children have had 6 to 12 months of no improvement in ambulatory speed, walking endurance, or improvement in balance. The primary treatment at this age is aggressive physical therapy using the teaching modalities and repetitive practice to improve balance and motor control. Passive stretching may be taught to caretakers as well as performed by therapists. Localized treatment with Botox may be beneficial if there are specific focal problems such as gastrocnemius, spasticity, or hamstring spasticity that are causing impediments to progress in gait learning (Case 7.19).

Severe Involvement

The most severe end of the diplegic pattern are children who have very significant asymmetry, who start walking with a walker at 2 to 3 years of age and, if they come to independent ambulation, do so only after 4 or 5 years of age, usually following surgery. These children are high, early toe walkers in their bare feet. They may be able to get feet flat, often with significant planovalgus. Many of the toe walkers have varus foot position associated with equinus. Transverse plane deformities are common, with both tibial torsion and femoral anteversion. Spasticity tends to include the hip, knee, and ankle almost equally. These children have to be closely monitored for spastic hip disease, which will occur in a significant number and requires early adductor lengthening. Often, these children are best treated with solid AFOs until they are 4 or 5 years of age. Physical therapy is the mainstay of treatment, with the focus being the same as with children with moderate involvement.

Figure 7.44. In hemiplegic types 1 to 3, it is better to have a mild shortness of the affected limb. Naturally, this ends up being between 1 and 2 cm, which helps limb clearance in swing. However, in type 4, there is a tendency to have increased hip adduction and flexion contractures that greatly magnify any other leg shortness. Also, hip extension and abduction are major mechanisms for accommodating leg length shortness, and when this is deficient in type 4 hemiplegia, the limb shortness becomes an impairment in its own right. Therefore, careful attention should be paid to limb length in type 4 with a goal usually of having symmetric limb lengths. An occasional patient may even function better with a longer limb on the affected side.

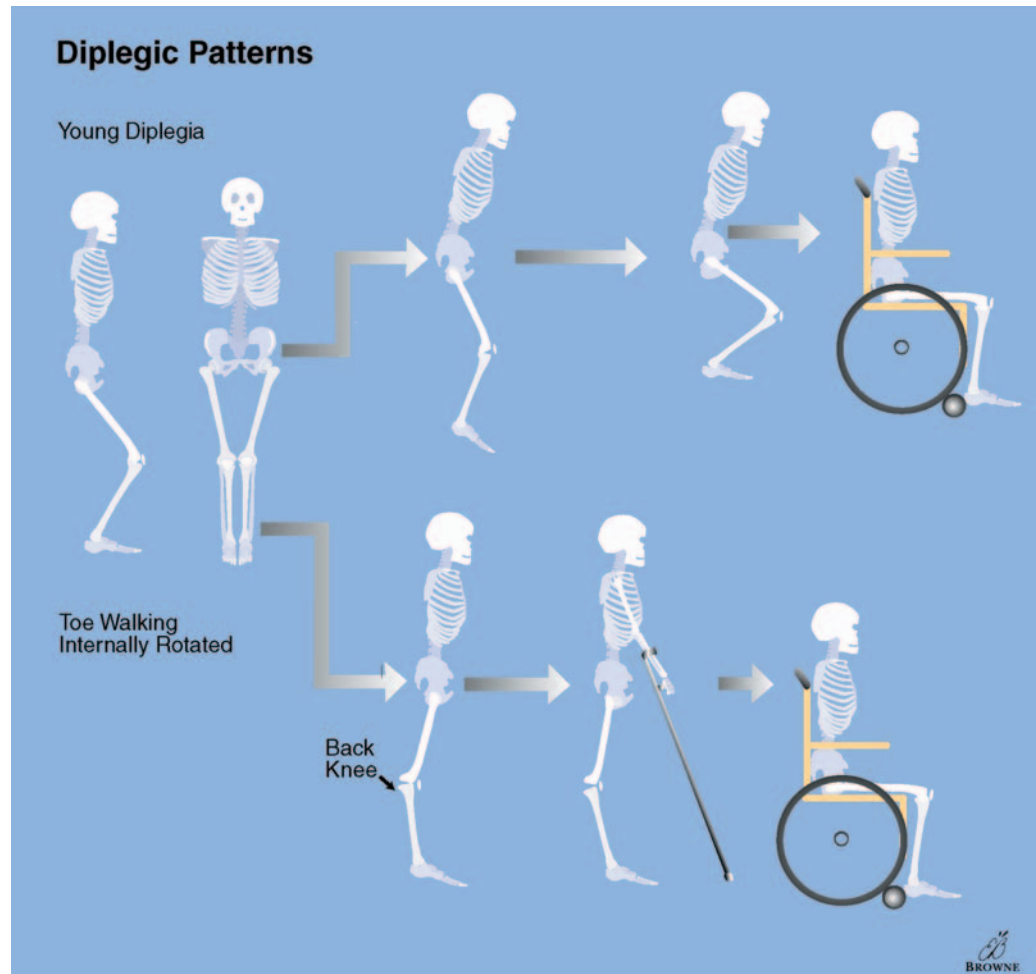


Figure 7.45. The patterns of diplegia are more difficult to define than those of hemiplegia. It is better to divide the stages or ages rather than pattern of involvement. Children younger than 5 years old tend to toe walk with equinus knee stiffness and often internal rotation of the hips. By middle childhood, they often develop a crouched gait pattern which, if left untreated, gets rapidly worse during the adolescent growth period. This problem may drive a child into a wheelchair if it is untreated and severe. Some children in middle childhood start to back-knee, and this may become worse in adolescence to the point where it causes severe knee pain if it is not addressed again, causing the child to end up in a wheelchair.

These children seldom have significant benefit from Botox because of the diffuse widespread involvement of the increased spasticity.

Surgical Treatment of the Prancing Toe Walker

Surgical treatment planning is usually focused at the interface between early childhood and middle childhood. By 4 or 5 years of age, children are reaching a plateau in neurologic development and the rate of learning motor and balance skills is plateauing as well. Socially, children are preparing to enter kindergarten or first grade if they have adequate cognitive skills. For cognitively high functioning children, the goal should be to have the gait impairment surgically corrected and rehabilitation completed before entering first grade. Entering first grade is a significant transition point for many children as they change from primary gross motor skills orientation to primary fine motor skills and cognitive skills learning. This transition period should include decreasing physical therapy and transitioning to normal age-appropriate athletic activities that individual children's functional levels and community ambulatory abilities allow. For example, having a child play soccer 2 days a week with a team would be better than spending that time in physical therapy doing medically oriented therapy, especially for a child who is an independent ambulator.

As children reach a gait functional plateau, usually between 5 to 7 years of age but sometimes as early as 4 years of age, a full analysis and evaluation



Case 7.18 Cherisse



Cherisse, an 18-month-old girl with increased stiffness in the legs, was seen for slow walking development. Although there was no history of birth problems, she had a workup with a brain MRI that was normal, and a diagnosis of diplegic CP was made. She was placed in an AFO and her mother was encouraged to have her move using heavy push toys. By age 2 years, she was walking independently and by age 3 years, she was walking on her toes, going faster but falling a lot. She was wearing an articulated AFO and was in physical therapy where she had good continued improvement up to age 4 years. Therefore, she was continued for another year in the same program. By age 5 years, both her mother and therapist who were working with her felt that there had been little additional progress in the past 6 months. At this time, her physical examination demonstrated a popliteal angle of 50° , knee extended ankle dorsiflexion of 5° , and bilateral and knee flexed ankle dorsiflexion of 15° . Internal rotation of the hips was 70° with external rotation of 20° . Other ranges of motion were normal. Kinematics demonstrated increased knee flexion at foot contact, premature ankle dorsiflexion, and internal rotation of the hips (Figure C7.18.1). The gastrocnemius had 2+ spasticity and the hamstrings and hip adductors had 1+ spasticity. Her mother was given the option to have either a dorsal rhizotomy or orthopaedic surgery, and she chose to do the orthopaedic procedures. Cherisse had bilateral hamstring lengthening, gastrocnemius lengthening, and femoral derotation osteotomy. One year after surgery, her gait had improved with better knee motion and correction of the internal rotation. This improvement was maintained 4 years later. It is expected that this girl will likely not need more surgery and that she will be an excellent ambulator as an adult.

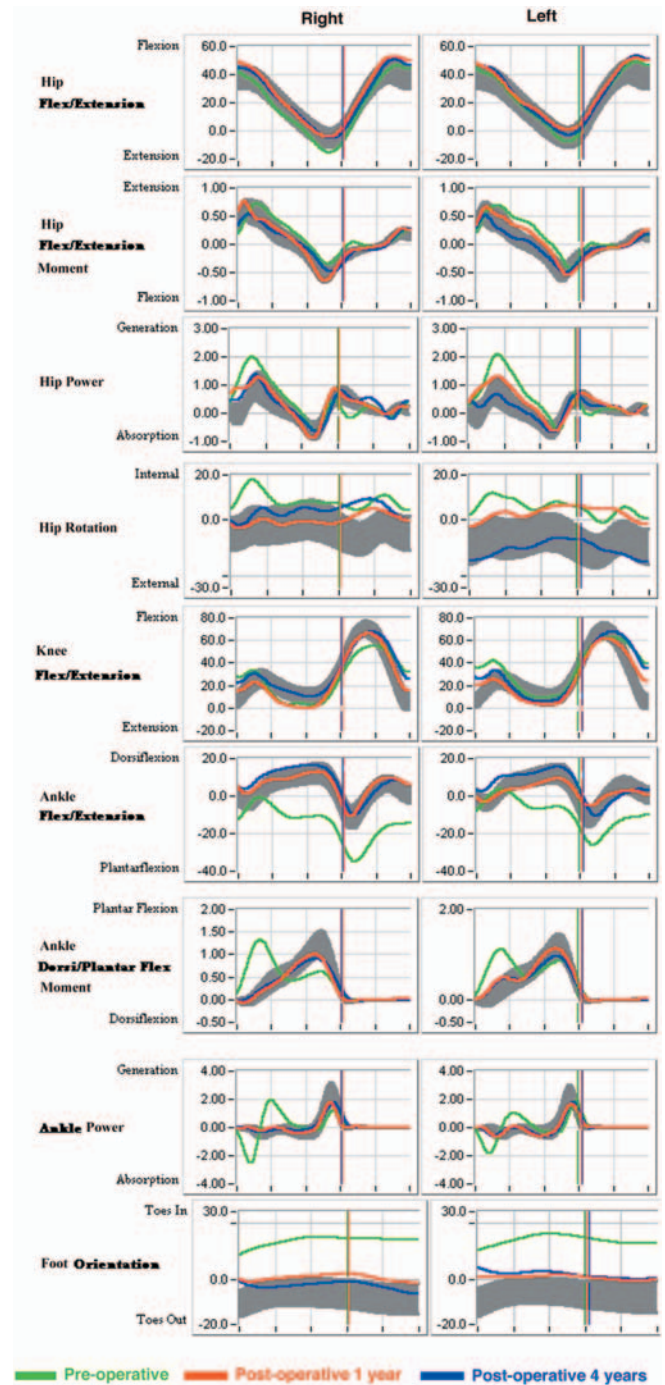


Figure C7.18.1



Case 7.19 Daymond



Daymond, a 2-year-old boy, presented with a history of prematurity and slow motor development. At that time, he was just starting to hold on to and push some toys. He was placed in solid ankle AFOs and, after 1 year of physical therapy, he was able to walk slowly in the posterior walker, but could not get into the walker by himself. By age 4 years, through continued therapy, he learned to get up into a standing position and increased his walking speed. He was also switched to articulating AFOs. By age 5 years, he was walking well with the walker, and in therapy, he was working on balance development with the use of quad canes, which were nonfunctional for ambulation outside the therapy environment. By age 6 years, he was practicing with Lofstrand crutches and by age 8 years, he was starting to practice walking independently. He was finding more stability and walking more with back-kneeing and ankle dorsiflexion even though he did not have equinus contractures (Figure C7.19.1). It was clear at this time, however, that he would be a permanent crutch user as age 8 years is a common plateau point, and he had been receiving intensive therapy, which means significant additional improvement cannot be expected. He had no significant structural limitations that could be corrected, and most of his ambulation problems were related to poor balance with the arms in the high guard position. Over the next 4 years, he continued to work on his balance, but as he entered puberty, it was clear that he would never be able to walk independent of the crutches except for very short times in home areas.

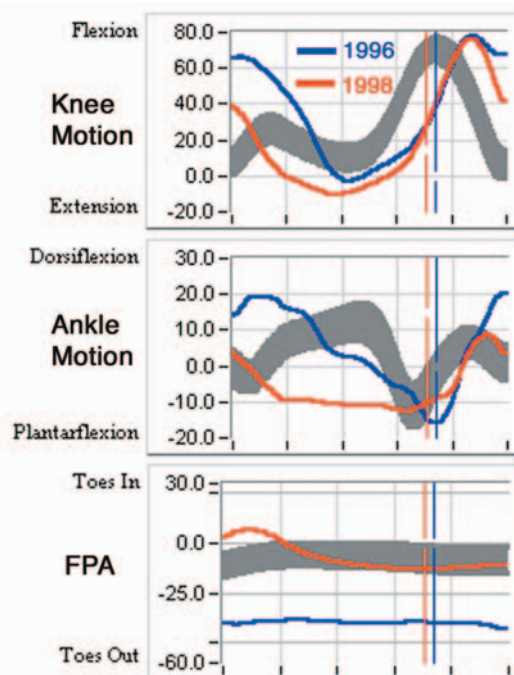


Figure C7.19.1

of their gait function is performed. A surgical plan is made and the actual surgery planned to least disturb families' normal activities. First, a decision has to be made if a tone reduction procedure is indicated or if the treatment is to be all musculoskeletal based. If children are independent ambulators and the physical examination demonstrates increased tone throughout the lower extremities and minimal fixed muscle contractures, the kinematics demonstrate decreased range of motion at the hip, knee, and ankle, and there are no transverse plane deformities, these children are considered excellent candidates for a tone reduction procedure. Children who meet all these criteria are very rarely seen, so there are almost always relative contraindications. At this time, the reported data from rhizotomy in this age group suggests that ambulatory ability is not improved much over physical therapy alone.⁶² Dorsal rhizotomy decreases spasticity and the joint range of motion increases, especially at the hip and knee.⁶³⁻⁶⁵ Muscle contractures do not resolve, and there is no impact on transverse plane deformities.⁶⁶ There are very few data comparing direct musculoskeletal surgery with

dorsal rhizotomy, with the only report suggesting a better chance of independent ambulation following muscle surgery than dorsal rhizotomy.⁶⁷ Based on these reports and our own experience, we no longer recommend dorsal rhizotomy to any child; however, it is still used in some centers. The use of intrathecal baclofen for this population has not been reported. The large size of the pump and the need for frequent refills has made families hesitant to have these pumps implanted. We know of no center using the pump for this indication, although theoretically it would be an ideal indication. The pump would allow controlling the spasticity and allow children to be as functional as possible. Part of the problem with dorsal rhizotomy is that too much tone is removed and children are left weak. With the pump, this could be modulated.

Clearly, the mainstay of surgical treatment of children with diplegia is direct correction of the deformities that are causing the functional impairment to gait. The goal should be to correct all the impairments that can be corrected with one surgery. The analysis starts distally and works proximally. If there is a varus foot deformity with equinus that seems to be causing toe walking, there is a temptation to suggest that this should be corrected. In early and middle childhood diplegia, unless the varus foot deformity is fixed, no surgery should be done on the tibialis anterior or tibialis posterior. Almost all these children will convert to planovalgus later, and any surgery on the foot at this age will only speed up that process. If children have a planovalgus deformity that is supple and are tolerating an orthotic, continuation of the orthotic is in order. If the deformity is severe, causing problems with orthotic wear, correction of the planovalgus is indicated, usually with a lateral column lengthening at this age. For severe fixed deformities, subtalar fusion is indicated.

Ankle dorsiflexion on physical examination will almost always demonstrate a discrepancy between gastrocnemius and soleus muscle contractures. Usually, the ankle is in plantar flexion at initial contact and comes to early dorsiflexion, but still lacks normal dorsiflexion. The ankle moment shows increased plantar flexion moment early in stance with a high power absorption in middle stance and low push-off power generation. These parameters indicate the need for gastrocnemius lengthening. The whole Achilles tendon should never be cut with a percutaneous tenotomy in children with diplegia. Although one study reportedly found no difference between open Z-lengthening of the Achilles tendon and doing a gastrocnemius-only lengthening,⁶⁸ there is no known or theoretical benefit to lengthening the soleus tendon if the muscle is not contracted.

Almost all children with diplegia have increased popliteal angles on physical examination and increased knee flexion at initial contact and during weight acceptance. Most will continue with increased knee flexion in midstance as well, which indicates hamstring lengthening is needed. If the knee goes into extension in midstance phase but has a very high popliteal angle of greater than 60° and knee flexion at initial contact of more than 40°, hamstring lengthening is still indicated, but usually only medial semitendinosus and semimembranosus lengthenings. However, if children have external tibial torsion, a biceps lengthening should also be added. If children's popliteal angles and knee flexion are intermediate between the two and they have full knee extension in midstance phase, only the semitendinosus should be lengthened. As the knee motion proceeds into swing phase, rectus dysfunction is diagnosed by prolonged swing phase rectus activity on EMG, low peak knee flexion, and late peak knee flexion in swing phase. If the walking velocity is greater than 80 cm/s and families complain of toe drag, a rectus transfer is indicated.

At the hip, a flexion contracture of more than 20° with anterior pelvic tilt of greater than 20° and decreased hip extension in early stance phase are indications for iliopsoas lengthening. If the indication is borderline, the procedure should be done if children are independent ambulators, but not if they are using walking aids or walk slower than 80 cm/s. Transverse plane deformities need to be assessed and should be addressed if the foot progression angle is more than 10° internal or 30° external. At this age, children almost never have an external progression foot angle; however, internal foot progression angle, which may be due to the internal tibial torsion or femoral anteversion or a combination of both, is common. On physical examination, significantly greater internal hip rotation compared with external rotation suggests increased femoral anteversion, and if this is combined with 20° or more of internal rotation of the hip on the kinematic evaluation, and especially if this occurs in early stance phase, it should be corrected with a proximal femoral derotation osteotomy. If the transmalleolar axis-to-thigh angle is internal, or the internal torsion measures more than 20° internal on the kinematic evaluation, a tibial derotation osteotomy is indicated. In some children, both will be present and both should be corrected. Do not overcorrect at one level to compensate for the other level. This compensatory overcorrection will lead to the knee joint axis being out of line with the forward line of progression and will likely deteriorate or increase as children grow, requiring later correction.

After a full gait assessment, children can have the specific surgical plan made. Each limb should be assessed separately, as many children with diplegia have some asymmetry and require different surgical procedures on each limb. In general, most children with diplegia need gastrocnemius lengthening with some hamstring lengthening. Very rarely is only a gastrocnemius lengthening indicated. The surgical procedure should be done so that children can be rapidly mobilized and returned to physical therapy for rehabilitation. Postoperatively, most children will continue to need some level of foot support, often with an AFO, to assist with dorsiflexion until the tibialis anterior develops muscle tone and correct length.

Middle Childhood, Early Crouch, and Recurvatum of the Knee

After the surgical correction and postoperative rehabilitation, which should be expected to last 1 year as an outpatient with gradually decreasing physical therapy, children with diplegia should be in a stable motor pattern for middle childhood. Often, these children will be more stable; however, they will also walk slower because they are now standing foot flat and do not have the falling gait that was present with the high prancing toe walking posture. Parents may see this slower gait as regression, but they have to be informed to expect this change, which will now allow the children to focus on developing a more stable gait. Children with diplegia in middle childhood tend to be drawn to several postural attractors. This is the age when prominent back-kneeing or crouched gait pattern will start to be seen consistently. This is the time when there may be sudden shifts in ankle position as the posture is being drawn to back-kneeing or crouch positions (Figure 7.46). With the correct soft-tissue balance, almost all children who are independent ambulators will tend to fall into a mild crouched position, which is the goal of treatment. This position is most functional when the crouch is mild, meaning midstance phase knee flexion is less than 20° to 25° and the children have an ankle dorsiflexion maximum of less than 20°. In middle childhood, this tends to be stable with children gaining confidence in walking ability with

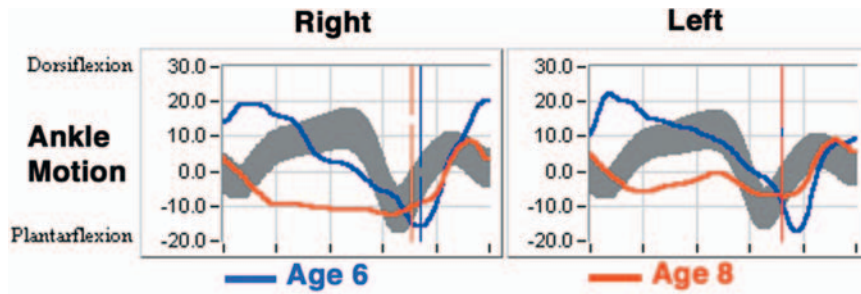


Figure 7.46. As growth occurs and muscle length changes along with changes in the muscle strength to body mass ratio changes, children often make sudden significant shifts in posture; this shows the concept of a shift from one strong attractor to another strong attractor. In this example, a child changed from a flat foot premature heel rise gait pattern to toe walking with ankle equinus. These relatively quick shifts are difficult to predict.

less falling and having longer community ambulator endurance. If the ankle dorsiflexion is increasing above 20° , a dorsiflexion resisting AFO or ground reaction AFO should be applied. If the midstance knee flexion goes above 30° and children develop increasing knee flexion contracture and progressive hamstring contracture, repeat muscle lengthening has to be considered. These contractures seldom become a problem until approximately 5 to 7 years after the initial surgery, when the children are in early adolescence. During middle childhood, there is little need for routine physical therapy for children who are independent ambulators. These children should be encouraged to get involved in sports activities, such as martial arts or swimming. For children who are dependent on walking aids, therapy directed at learning to use forearm crutches before the age of 10 years and weaning off the walker are recommended. Learning to use crutches may require a period of teaching by physical therapy during the summer, or during a time when it does not interfere with school work. Passive range of motion should not be routinely done by physical therapists, and children should be encouraged to do it themselves under the direction of the parents or caretakers.

Knee Recurvatum

Some children who fall into the back-knee attractor have a gastrocnemius that is a little too tight for the hamstrings, which can be easily controlled with an AFO that limits plantar flexion. These children need full calf-length articulated AFOs that block plantar flexion at 5° of dorsiflexion. Often, with full-time brace wear, the hamstrings will gain strength over time and the back-kneeing will slowly resolve as children grow. The second pattern of back-kneeing is children who go into the jump position, where the body is anterior to the hip and the knee joint axis. This pattern may be due to a missed iliopsoas contracture that was not lengthened or may result from a weak gastrosoleus. The use of a solid AFO in 5° of dorsiflexion should provide a trial. Also, if there is decreased lordosis and more than 30° of hip flexion contracture, the hip flexor should be suspected as the primary cause. If the problem is a contracted hip flexor that was missed in the original operation, this may need to be lengthened to get children to stand upright. The third posture creating back-kneeing is taken by independent ambulators who back-knee in stance with hyperlordosis. In this posture, the HAT center of mass is behind the hip joint but in front of the knee joint. A trial with a solid AFO is the best treatment of this pattern. Most children who are independent ambulators in middle childhood respond well to AFO treatment for back-kneeing.

Back-kneeing in children who use walking aids, such as walkers or forearm crutches, is a major problem (Case 7.20). This back-kneeing may be due to a motor control problem in which individuals lean forward on the crutches, usually with hyperlordosis. With the center of mass of the HAT segment far forward of the hip and knee joint, there is a large knee external



Case 7.20 Frederico



Frederico, a 7-year-old boy, presented with his mother who complained that he had severe back-kneeing when he walked with his walker or used his crutches. He had AFOs, which he complained did not help him and he did not want to wear them. On physical examination he had normal hip motion and knee popliteal angles of 40° bilaterally. Knee extended ankle dorsiflexion was -10° and knee flexed ankle dorsiflexion was $+15^\circ$. Frederico had poor balance and could not stand without holding on. Kinematic evaluation showed increased knee flexion at

foot contact, knee hyperextension with almost every step in midstance, early and decreased ankle dorsiflexion with significant early plantar flexion, and very little additional plantar flexion at toe-off. He had gastrocnemius lengthenings, which were the main cause of the back-kneeing; this was also the reason he could not tolerate the AFOs. He was then gradually weaned out of the AFOs, and gained knee control, although he still had a tendency to be either in crouch or convert into knee hyperextension in midstance.

extension moment on the knee. If individuals have any shortness of the gastrocnemius, the knee will hyperextend and go into back-kneeing. Also, if individuals have weakness in the gastrocnemius, they will back-knee. The primary treatment is to use AFOs that prevent plantar flexion; however, with the use of walking aids, AFOs often do not work well as individuals will simply allow the forefoot to rise from the floor. If the knee flexion moment is very high in midstance and individuals complain of knee pain or passive range of knee hyperextension demonstrates an increase of more than 10° to 15° , the only option is the use of a KAFO with an extension stop knee hinge. It is important to make sure that there is no contracture of the gastrocnemius. Ankle dorsiflexion has to be 5° to 10° in knee extension or the gastrocnemius should be lengthened. Many individuals will continue to have back-kneeing but will remain stable and pain free over many years. Often, the back-kneeing will include a valgus extension thrust in midstance; however, the knee flexion moment is not too large, probably because weight bearing on the upper extremity through the walking aid helps to reduce the magnitude of the ground reaction force. Another way of understanding this is that as individuals move the center of mass of the HAT segment further forward, more weight is shifted to the arms. Although the extension moment at the knee is getting longer, there is a decreased amount of weight from the HAT segment carried by the feet, which decreases the magnitude of the extension moment.

There may be a role for dorsal rhizotomy in the middle childhood period; however, the rehabilitation of older children is even slower. Dorsal rhizotomy is even less indicated because more localized methods are available. Also, the use of intrathecal baclofen has had little or no exposure in this population age.

Adolescent, Young Adult Crouched Gait

During adolescence with the rapid onset of weight and height growth, the classic crouch gait develops, gets worse, and may prevent some children from functional ambulation if it is not treated appropriately. The crouch pattern may be seen in all levels of severity; however, it is primarily encountered in moderate and severe diplegia. The definition of a crouched gait is increased knee flexion in midstance with increased ankle dorsiflexion, and usually

increased hip flexion. The toe walking knee flexion pattern is not seen in full adolescence or nearly adult-sized individuals. The muscles and joints are not strong enough to support the body weight for chronic ambulation with the typical early childhood toe walking pattern. If young children are left untreated, the natural history during late middle childhood, when knee flexion in stance increases and the foot starts to dorsiflex, causes collapsing through the midfoot and hindfoot as severe planovalgus foot deformities develop. During the time when children are growing rapidly and increasing weight quickly, midstance phase knee flexion will increase, and ankle dorsiflexion and hip flexion will also increase by a compensatory amount. Individuals who use walking aids tend to increase weight bearing on the walking aids during this time by increasing anterior lean (Case 7.21).

Many adolescents with mild crouch gait, defined as knee flexion in midstance between 10° and 25° , will not need any treatment or will need only single joint level treatment, such as correction of planovalgus feet. Almost all surgery should be done on individuals with moderate crouch, meaning midstance phase knee flexion of 25° to 45° . Only rarely, and usually only in medically neglected patients, is surgery done in severe crouched gait with knee flexion in midstance greater than 45° . As with many other conditions, allowing the crouch to become severe means the treatment is less effective (see Case 7.7). The symptoms of increasing crouch include the complaint of knee pain as the stress rises on the knee extensor muscles to support weight bearing. Distal pole of the patella and tibial tubercle apophysitis may occur, especially during rapid growth. Walking endurance will decrease and the feet will start causing more pain with long-distance walking as the planovalgus develops larger pressure areas. The orthotics are no longer able to support the collapsing feet. All these progressive additive impairments combine to frustrate adolescents, and parents typically complain that the individual is losing motivation to walk.

Treatment

Appropriate treatment for crouched gait should focus on early detection and intervention before the problem becomes severe. Early detection means children should be followed closely, every 6 months during middle childhood. A full gait study should be available as a baseline and is usually obtained 1 year after the first surgery, which occurred between the ages of 5 and 7 years. Children's weight should be monitored on every clinic visit, and as they start gaining weight fast and complaining of high stress pain at the knees or the feet, another gait study is indicated. Also, the physical examination should be monitored, especially the passive knee extension and popliteal angle, to monitor progressive hamstring contractures or fixed knee flexion contractures. If there is a significant increase in either of these, a gait study should be made as well. Any significant change in community ambulatory endurance should prompt a full evaluation. Ambulatory children should not be allowed to become dependent on wheelchairs for community ambulation (Case 7.7). This level of deterioration makes the recovery and rehabilitation exceedingly more difficult.

The full evaluation of children with a significant increase in crouch or symptomatic loss of function from crouch should be carefully assessed to make sure all components of the crouched gait are found. All elements that are identified and are correctable should be corrected at the same time. The foot must be a stiff segment and be aligned within 20° of the forward line of movement and within 20° of right angle to the knee joint axis. This means if the foot has a significant planovalgus or a midfoot break, it must be corrected. A stable and correctly aligned foot is mandatory in the correction of



Case 7.21 Elizabeth



Elizabeth, a 14-year-old girl, presented with the concern that her walking had become so difficult that she could no longer walk around her junior high school. According to her parents, she did not even own a wheelchair when she was in grade school, as she was able to walk everywhere using a walker. They were concerned that she would completely lose her ability to walk. She had no previous surgeries and currently received no physical therapy. She had grown rapidly in the past 2 years, and in the past year, as she had spent more time in the wheelchair, she had gained a lot of weight. A physical examination demonstrated hip abduction to 20° , almost symmetric hip rotation with 40° internal and 30° external rotation; popliteal angles were 70° , the knees had 10° fixed knee flexion contractures, and the feet had severely fixed planovalgus deformities. The kinematics showed high knee flexion at foot contact and decreased knee flexion in swing phase, with a severely reduced knee range of motion (Figure C7.21.1). The pedobarograph showed severe planovalgus with external foot progression of 34° on the right and 19° on the left (Figure C7.21.2). Most weight bearing was in the medial midfoot (Figure C7.21.3). The main cause of the loss of ambulation appeared to be the crouch gait caused primarily by severe and progressive planovalgus foot de-

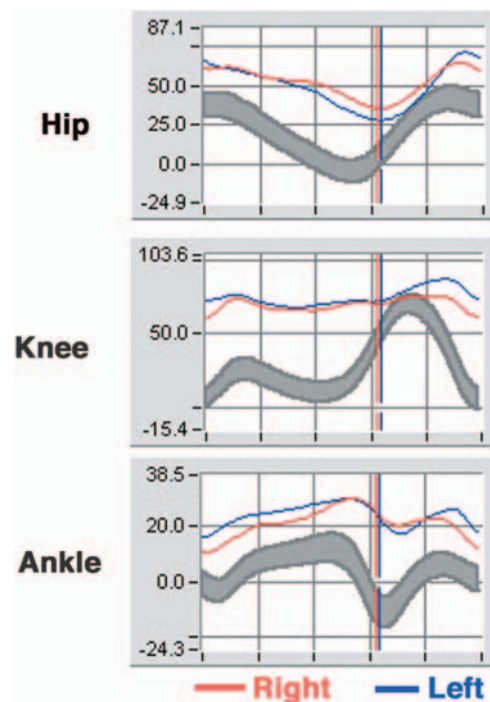


Figure C7.21.1

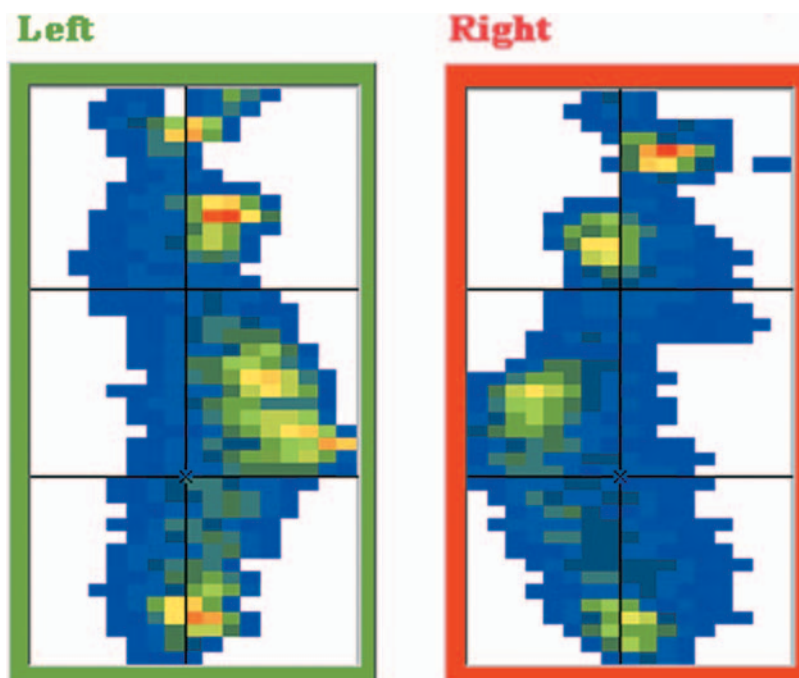


Figure C7.21.2

formities, which prevented the foot from functioning as a rigid moment arm, with the majority of the weight bearing on the medial midfoot (Figure C7.21.3). This lever arm disease needed to be corrected by stabilizing the foot so it was a stiff and stable structure, and it had to be aligned with the axis of the knee joint. Correction of the plano-

valgus with a triple arthrodesis both stabilized the foot and corrected the malalignment. Hamstrings were lengthened, and after a 1-year rehabilitation period, she was again doing most of her ambulation as a community ambulator using crutches. The foot pressure showed a dramatic improvement although there was still more weight

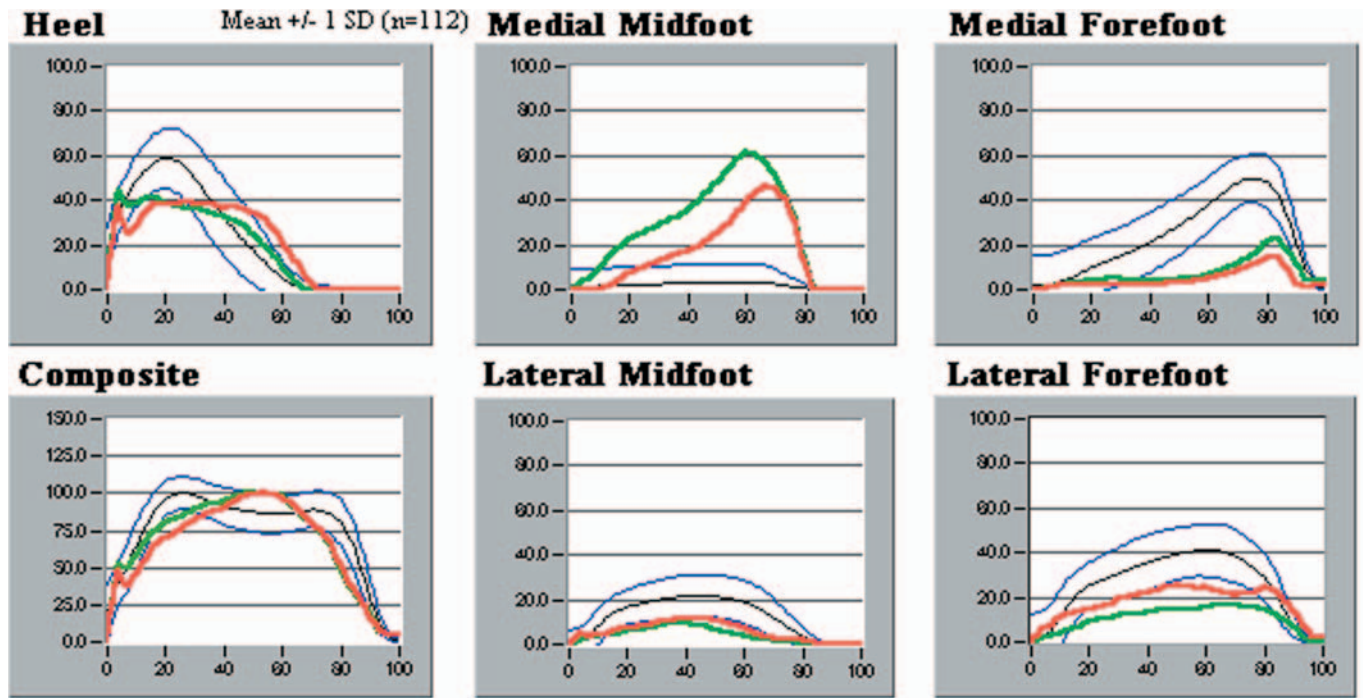


Figure C7.21.3

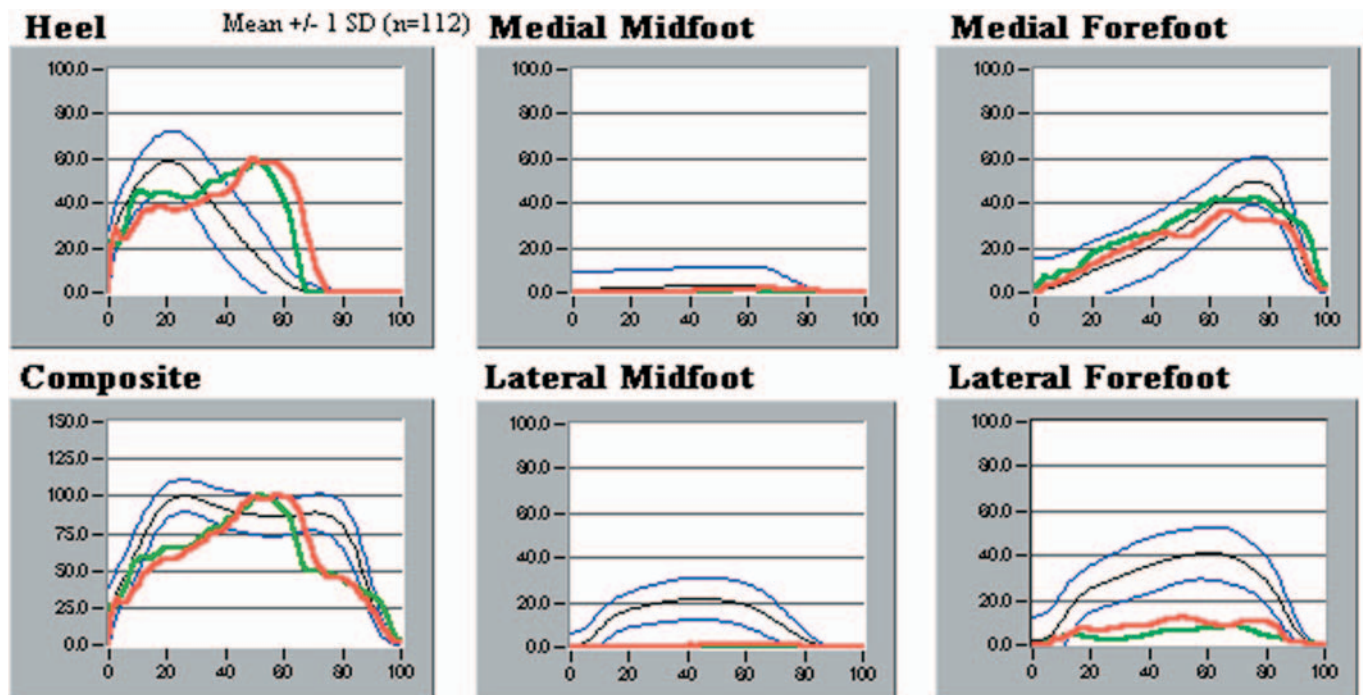


Figure C7.21.4

bearing on the medial forefoot than the lateral forefoot, indicating some mild residual valgus (Figure C7.21.4). There is also increased weight bearing on the heel, indicating continued weakness in the gastrocsoleus (Figures

C7.21.4, C7.21.5). The kinematics demonstrate a good improvement in knee extension and ankle plantar flexion (Figure C7.21.6). Elizabeth would have become a permanent wheelchair user if her feet had not been corrected.

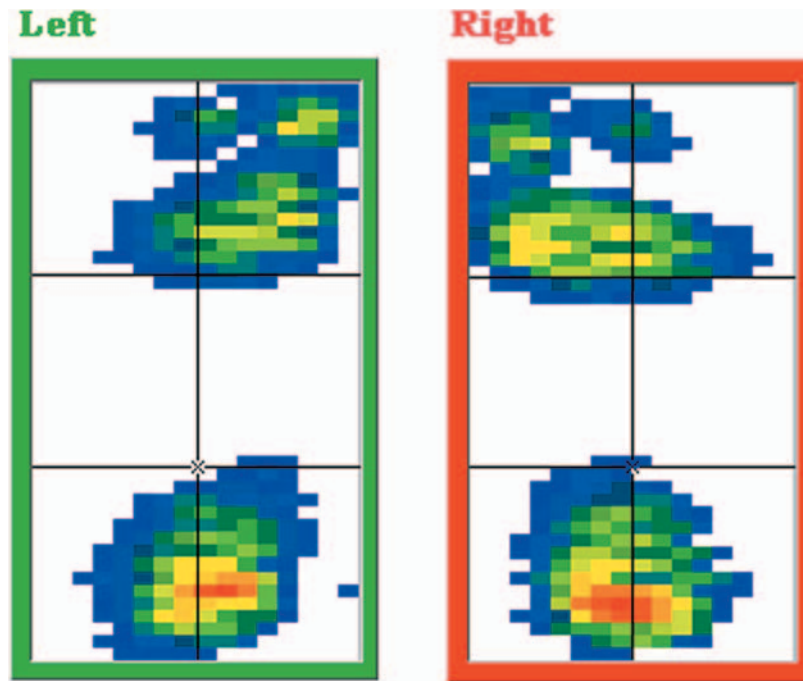


Figure C7.21.5

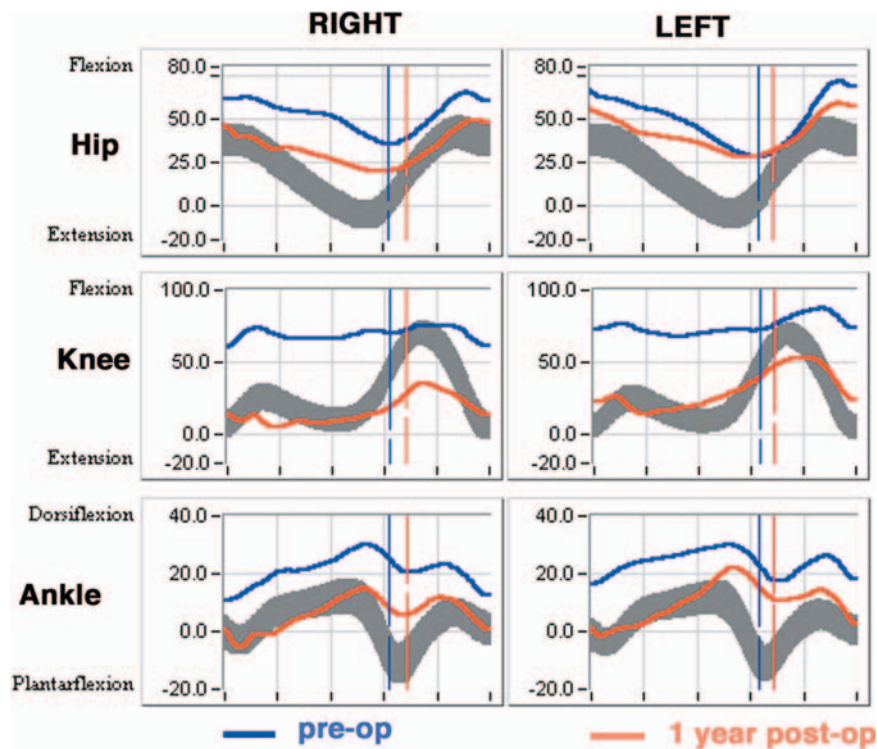


Figure C7.21.6

crouch because the ground reaction force has to be controlled through the foot as a functional moment arm.

Poor moment arm function of the foot causing the ground reaction force to be ineffective in producing knee extension is often one of the primary pathologies of a crouched gait pattern. The foot has to come to within neutral dorsiflexion in midstance so it can be placed in an orthosis, or the gastrosoleus must provide the force needed to control the ground reaction force. If the gastrocnemius or soleus is contracted, it must be lengthened, but only to neutral dorsiflexion at the end range.

Never do uncontrolled, percutaneous tendon Achilles lengthenings in adolescent crouching individuals. These individuals will likely never be able to stand again without using a fixed AFO. Tibial torsion must be assessed next, and if it is contributing to the malalignment of the foot causing the foot to be out of line with the knee joint axis, a tibial derotation is required.

Physical examination of passive range of motion of the knee should allow extension to within 10° of full extension. If the fixed knee flexion contracture is between 10° and 30° , a posterior knee capsulotomy is required. If the fixed knee flexion contracture is greater than 30° , a distal femoral extension osteotomy is required. Distal hamstring lengthening is always indicated with crouched gait unless the procedure has been done in the preceding year. The indication to do a hamstring lengthening is a popliteal angle of more than 50° with an initial contact knee flexion of more than 25° , and knee flexion in midstance phase of more than 25° . If individuals have decreased knee flexion in swing phase or late knee flexion in swing phase with toe drag, a rectus transfer should be performed. Many clinicians are hesitant about doing rectus transfers in individuals with crouched posture; however, they must remember that the rectus is only 15% of the strength of the quadriceps and the muscle is not even active, except in pathologic cases in midstance phase. If children are very slow walkers in the quadriplegic category, rectus transfer has less benefit. This discussion presumes independent ambulators or ambulators who use walking aids but do not use wheelchairs for community ambulation. This type of ambulator will gain much more from the rectus transfer than the risk of weakness.⁶⁹ If children require a distal femoral osteotomy to correct fixed knee flexion contracture, a shortening of the patellar ligament is usually required as well (Case 7.22). Individuals with moderate crouch, defined as midstance phase knee flexion of 25° to 45° , will not need any shortening of the patellar ligament because the quadriceps will have enough excursion and will readjust when the pathomechanics are corrected. The next concern is the axis of the knee joint, which should be between 0° internal and 20° external at initial contact.

If there is significant internal rotation, meaning more than 5° to 10° of internal rotation at initial contact, and the physical examination shows significantly more internal than external rotation of the hip, the femoral internal rotation should be corrected. Usually, this correction is made by doing a femoral derotational osteotomy, but if there is a question of the source of the internal rotation, a CT scan of the femur should be obtained to evaluate the source of the internal rotation. Last, the hip flexor will need lengthening if the hip flexion contracture is more than 20° and midstance phase hip extension is less than -30° . If there is more than 30° of anterior pelvic tilt but less hip flexion, hip flexor lengthening is also indicated, usually doing an intramuscular lengthening of the iliopsoas. While assessing the crouched pattern, it is important to assess each lower extremity independently, as the surgery will often need to be asymmetric. Correction of the torsional malalignments is extremely important for the correct mechanical function of the lower extremity, especially when there is decreased motor control.



Case 7.22 Brandon



Brandon, a 3-year-old boy, started to walk using a walker while in physical therapy. He did well walking in his school environment; however, his mother reported that he refused to use the walker at home. During the next several years his grandmother cared for him; then, at age 7 years, he again returned to his mother and his initial school. He had developed significant knee flexion deformities that made walking difficult; however, he moved freely on the floor in reciprocating quadruped crawl. A popliteal angle of 90° and 30° knee flexion contractures were found on physical examination. He had knee capsulotomies and hamstring lengthening bilaterally; however, the stress of the surgery and a breakdown in the social service system led to very little physical therapy. By the time he returned to school 4 months later, and the school got him back to the clinic, his knee flexion contractures were slightly worse than preoperatively. Over the next several years, he was in school but received only sporadic therapy. At age 10 years, his mother was very concerned because he crawled everywhere, but he was getting bigger and he refused to stand on his feet. In the classroom and at home he did a lot of knee walking and had several episodes of severe knee bursitis, which required his mother to try to keep him off his knees. His mother's main concern was that soon she could not care for him if she had to carry him everywhere. At this time, he was in a self-contained special needs classroom with a teacher's aide. He had moderate mental retardation, functioning at the 3-year-old level. On physical examination he had a popliteal angle of 100° and fixed knee flexion contractures of 60° bilaterally (Figure C7.22.1) but excellent knee flexion (Figure C7.22.2). He had a large callus on the anterior knee, demonstrating that he did a lot of knee walking (Figure C7.22.3). His hip motion and hip radiographs were normal, and his feet were in planti-

grade and without deformity. Knee radiographs showed no abnormalities (Figure C7.22.4). Observation of his movement on the floor showed that he was very proficient as a reciprocal quadruped crawler and a very functional independent knee walker. Based on the assessment that he had excellent balance with good motor control and motor planning skills, he had hamstring lengthening, distal femoral extension osteotomy, patellar tendon plication, and transfer of the rectus to the sartorius (Figures C7.22.5, C7.22.6). After the osteotomy healed (Figure C7.22.7) and after a 1-year rehabilitation period, he was able to walk in the school and home using a posterior walker with full knee extension. Limited knee flexion prevented proficient crawling or knee walking, which drove him toward walking with the walker. In the second year after this procedure, Brandon developed scoliosis, which required a spinal fusion, and that required another year of rehabilitation. It is expected that he will continue to make more gains in his walking ability over the next several years as his motivation to walk improves. The mental retardation is a significant factor in the speed of the rehabilitation but probably not in the final outcome.

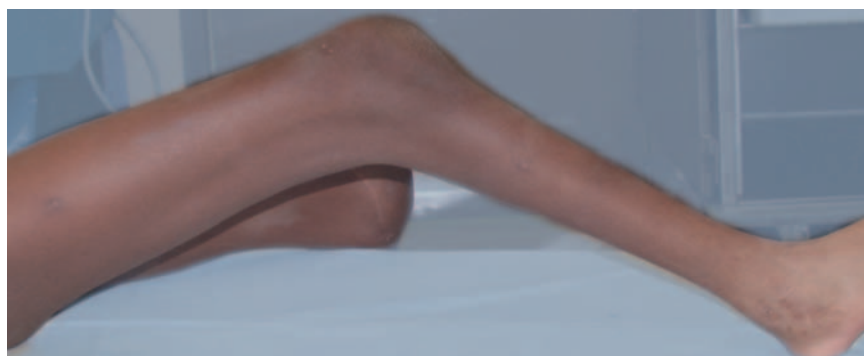

Figure C7.22.1

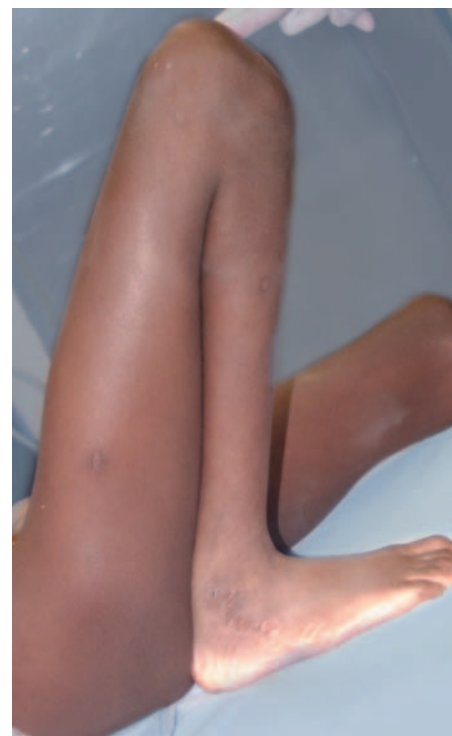

Figure C7.22.2

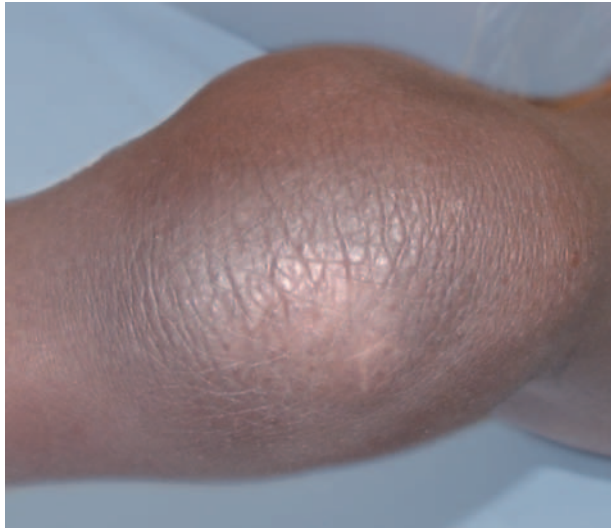


Figure C7.22.3

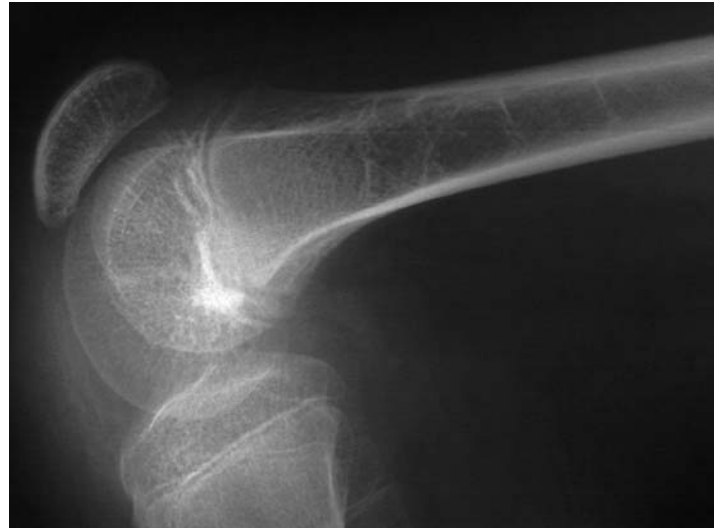

Figure C7.22.4

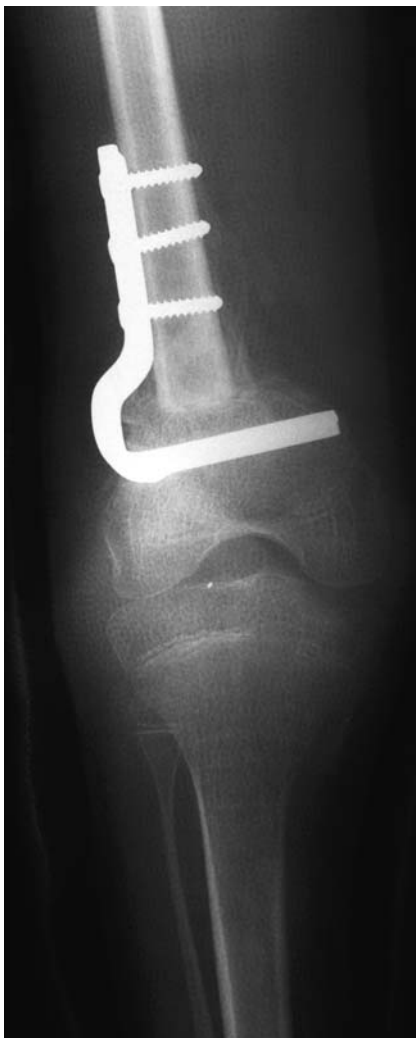

Figure C7.22.5

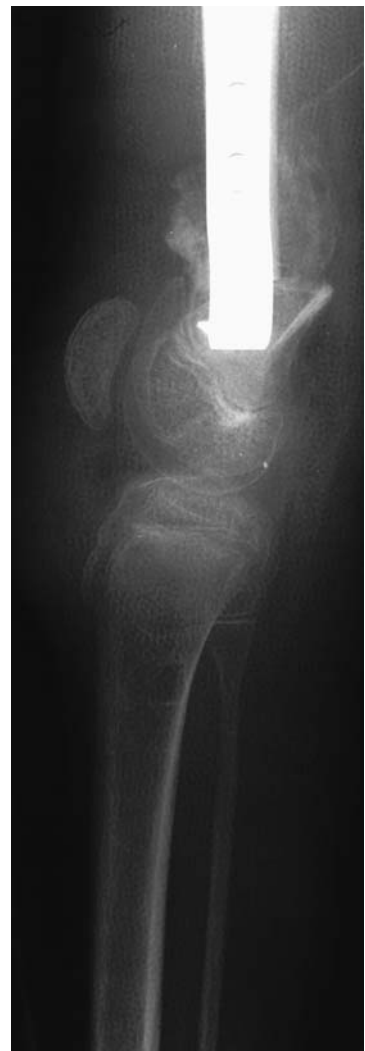

Figure C7.22.6

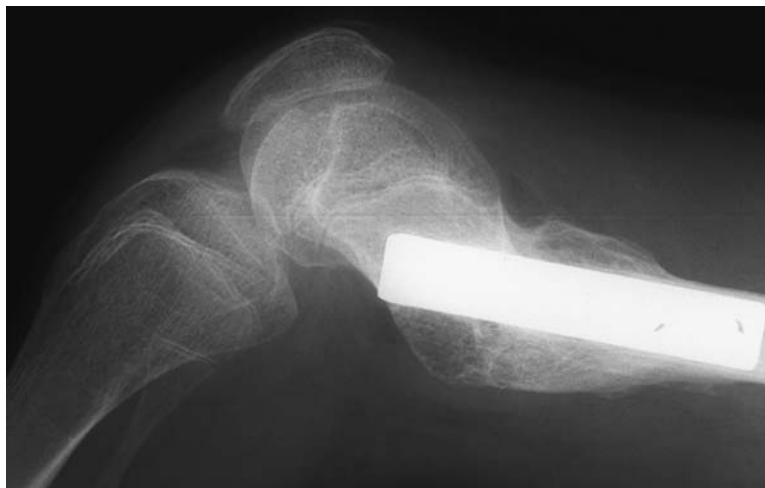


Figure C7.22.7

Performing the Crouched Gait Surgery

The surgery for crouched gait often involves many procedures at different joints. The preferred order is to start at the hip and correct the hip rotation, with iliopsoas lengthening if needed. Then the knee is addressed by hamstring lengthening followed by knee capsulotomy or femoral extension if indicated. The foot deformity is corrected next, then an intraoperative assessment of the torsional alignment is used to make the final determination of the need for a tibial osteotomy. After the tibial osteotomy, another intraoperative assessment should be made to show that the hip fully extends and the knee can be fully extended and lies in approximately 10° of external rotation. The foot-to-thigh alignment should be 20° external to neutral with neutral dorsiflexion. Postoperative rehabilitation should start in the hospital with the goal of having children at least standing before discharge and plan for immediate home rehabilitation. Parents need to expect that the acute rehabilitation will take 3 months until these individuals are close to their preoperative function, and then it will take at least 1 year of rehabilitation to reach maximum function. If there is weakness or a tendency for the gastrocnemius not to have good strength, a ground reaction AFO has to be used postoperatively. This is the ideal time to use the articulated ground reaction AFO, which will allow the gastrocnemius to gain strength, and over 1 to 2 years, the orthotic can be weaned away and the correction will be maintained.

The outcome of surgery for crouched gait is excellent if there is a complete diagnosis, correction of all deformities, and follow-through with good rehabilitation. If the surgery is done at adolescence near the end of growth or when individuals are well into adolescence, the correction will be permanent and no additional procedures will be needed.

Back-Kneeing as Adolescents or Young Adults

Back kneeling continues to be a problem in adult-sized individuals, primarily in those using walking aids. The same treatment is used as noted in the section on middle childhood. A few individuals who walk independently will back-knee, and they are usually the individuals with severe weakness of the gastrocnemius, and have often had tendon Achilles transections.

Spasticity Reduction in Adolescents and Young Adults

Some adolescents have very limited motion because of severe spasticity but are nevertheless good ambulators. The use of intrathecal baclofen is a reasonable option; however, it often unmasks weakness when the spasticity is reduced. There have been no objective reports on the effects of intrathecal baclofen on gait in this age. In our personal limited experience, individuals will have a mild increased crouch and may slow their gait slightly. The patients, however, report feeling more comfortable and find dressing and other activities of daily living easier. Dorsal rhizotomy is not indicated in this group, as the risks far outweigh any benefits that could be expected.

Quadriplegic Gait

By definition, most children with quadriplegia do not ambulate. However, there are many children who have some ambulatory ability. These children are often called severe diplegia or mild quadriplegia, and for the purpose of this discussion, we will consider these individuals to have quadriplegic pattern involvement. By definition, these are individuals who use walking aids and are usually limited to household ambulation. Other ways to define this population are patients with a standing (dimension D) on the GMFM of less than 25%, a walking speed less than 50 cm/s, or an oxygen cost that is greater than 0.8 ml of oxygen per kilogram per meter walked. Many of these are children or adolescents who used a gait trainer in early childhood and are transitioned to a walker adapted with forearm supports in middle childhood. At adolescence, these individuals are usually transfer ambulators, able to move in their home environment and do weightbearing transfers. Many of these individuals have high tone from spasticity and many in the late 1980s and early 1990s had dorsal rhizotomies. The typical experience of this group with rhizotomy, in which spasticity was removed, is that these children can no longer stand or walk, except with the assistance of a gait trainer. If the rhizotomy is less aggressive, leaving some spasticity, most of the spasticity will return over a few years and these children will be back where they started. Rhizotomy is not indicated for this population. The use of the intrathecal baclofen pump, especially for middle childhood and adolescence, is an excellent option. Correctly adjusting the pump so there is enough spasticity to stand but not cause problems requires trial and error.

Early Childhood

In early childhood the children should be placed in standers, and as they develop coordination, start in gait trainers. Many of these children are at high risk for developing spastic hip disease and need to be monitored for the prevention of spastic hip disease. Encouraging ambulation in a gait trainer may not allow individuals to move to walking with an unsupported walker; however, it still gives them a sense of movement and weight bearing. Usually, these children are provided distal support with a solid ankle AFO so they can focus on proximal motor control at the hip and knee. There is really nothing to be gained by using articulated AFOs for these children. Often, these children will have significant scissoring with adduction in initial swing phase. If the adductors are very spastic and contracted, these children may benefit from adductor lengthening; however, this is often not due to spasticity but is a motor control problem. The best way to address this motor control problem is to use lateral ankle restraints, which are available on many commercial gait trainers. If severe equinus limits orthotic tolerance, the use

of Botox may help, or surgical lengthening is required. Aggressive attempts to lengthen muscles, correct foot deformities, and correct torsional malalignments in young children less than 6 or 7 years of age often leads to disappointment unless an evaluation has clearly demonstrated that the musculoskeletal impairment is the direct cause of the limited function. Often, parents will identify some problem, such as scissoring, and focus on the assumption that if this problem were removed, the children could walk. If adductor lengthening is performed in these children but they still can adduct, the scissoring is seldom improved. These children's central motor control generators are using a flexor posture that causes the legs to scissor but is not directly responsible for simple, single-muscle overactivity. The scissoring is part of the primitive stepping mass reflex that children are using to advance the limbs. Often, as these children mature, they learn to overcome scissoring and subsequently will slowly do less scissoring. If the musculoskeletal impairment is blocking progress, it is reasonable to correct the deformity, usually around 5 to 7 years of age at the youngest. If there is a question of the significance of the musculoskeletal impairment, it may be beneficial to wait until 8 to 10 years of age when a better assessment can be made, with more time to evaluate how these children are changing.

Middle Childhood Quadriplegic Ambulators

In middle childhood, most children will reach a plateau with motor function. An evaluation of the benefits of correction of musculoskeletal deformities should be performed. If there are limitations that are significantly impairing the children, correction should be made. Correcting the contractures that are causing impairments is often beneficial, and these contractures may include equinus contractures, hamstring contractures, knee flexion contractures, hip flexion contractures, and adductor contractures. Sometimes the parents report that these releases help the caretakers provide personal hygiene more easily, such as easier bathing or dressing. Severe planovalgus foot deformities merit correction when they limit orthotic wear. During this time, if children have good cognitive function, a decision should be made to focus less on walking and more on cognitive learning and fine motor skills. If children have moderate or severe mental retardation, continuing to focus on ambulation is a reasonable option. Some of the children with severe mental retardation will make significant progress in ambulatory skills in middle childhood, even up to age 12 or 13 years. As children approach adolescence, the gait trainer is less useful because the device has to be so large that it does not fit through doors and cannot be functionally used in most homes. Caretakers and parents are encouraged to continue to walk holding the hands of the patients, so as not to lose the ability to do weightbearing transfers. Correction of foot deformities and knee contractures should also be directed at the goal of maintaining these individuals' ability to do standing weightbearing transfers.

Adolescent Quadriplegic Ambulation

Adolescence is when individuals will continue to do household ambulation if they can walk with a standard walker, but usually stop walking if it requires the use of a gait trainer. Most individuals will be able to maintain weight bearing as a transfer ability. If the limitation is due to a musculoskeletal deformity, correction should be considered. Typical problems that occur at this age are severe planovalgus feet, which limit the ability of individuals to stand or wear AFOs. This correction is easy to maintain and will not be lost at this age. The second most common major problem is hamstring contractures and fixed knee flexion contractures. If children are growing rap-

idly, the hamstrings will often rapidly recontract after lengthening. If there is a severe knee flexion contracture of more than 30°, this too gets worse. As the knee flexion contracture goes over 30° to 40°, standing rapidly becomes more difficult. Correcting the knee flexion contracture is a difficult decision because the contracture may make standing more difficult, but if individuals can only stand and spend most of their time sitting in their wheelchairs, correction of knee flexion contracture is not likely to be successful, as the knee will just recontract. Therefore, correction of significant knee flexion contractures should be reserved for individuals who do some community ambulation, or who surgeons believe have the ability to do some community ambulation. Correction of torsional malalignment, such as tibial torsion or femoral anteversion, is indicated if the correction will improve an individual's ability to sit. Often, the benefit from treatment for sitting takes precedence over problems of ambulation unless it is a very severe torsional malalignment. The problems of stiff leg gait with rectus spasticity are often much less of a problem in this group of individuals than individuals who are full community ambulators with faster walking speed. Also, the quadriplegic pattern involved individuals have a high tendency for recurrence of knee stiffness in swing phase, sometimes even recruiting the vastus muscles to keep the knees stiff during swing phase if the rectus is removed. It seems these individuals with limited ambulatory ability need the knee stiffness to be able to provide stability and control of their standing.

One of the problems that occurs with these quadriplegic patterns is caretakers who insist the children used to walk everywhere but now they can no longer walk, except in the house. Parents and caretakers tend to forget how these children walked 3 years prior, and most often, the video record will show that there is little difference. If there is a real difference and it is due to progressive musculoskeletal problems, these deformities must be corrected. If the deterioration cannot be explained by musculoskeletal changes, a full neurologic workup is indicated to determine if there is any pathology not previously diagnosed. Forgetting how these children walked is a very important reason for having video records of ambulation, even in children with limited walking ability. Video records are an important and relatively cheap tool to assess change in ambulatory ability for children with some ambulatory ability during development.

The outcome of treating gait problems in children with limited ambulatory ability is the same as it is for children with more function. These children should not lose substantial ambulatory ability that they gained. If they do lose ambulatory ability, the cause should be found.

Movement Disordered Gait

Athetosis

Gait problems in individuals with movement disorders can be especially difficult to address. Individuals with athetosis often have spasticity associated with the athetosis, which works as a shock absorber on the pathologic movement. Individuals with athetosis may develop significant deformities that make ambulation more difficult, and there is merit in addressing these problems. Therapy to improve athetoid gait is limited but sometimes adding resistance through the use of ankle weights or a weighted vest can be helpful. Procedures that will provide stability have the most reliable outcome. For example, correction of planovalgus feet with a fusion is a reliable procedure. There is no benefit of trying muscle balancing or joint preservation treatment in the face of athetosis.

Knee flexion contracture is the most common problem at the knee level, and may lead to significant fixed knee flexion contracture. Although the post-operative course may be difficult, the outcome of the surgical treatment of fixed knee flexion contractures is usually good. Often, these patients have very high cognitive function and are very hesitant to undertake the correction, even if severe deforming musculoskeletal problems are clearly limiting their activities. Both a full analysis and an experienced surgeon will usually be able to convince them of the benefit if the problem is clear and straightforward. These patients also need an explanation of the corrections planned, which are limited to bony correction, joint fusion, or muscle lengthening. There is no role for tendon transfer in individuals with significant athetosis. Most of the surgery should be planned in late middle childhood or adolescence, as these individuals seldom have fixed deformities that cause problems earlier.

Dystonia

The first and most important thing to address in individuals with dystonia is to diagnose the dystonia and make sure it is not misinterpreted as spasticity. Diagnosing dystonia was addressed fully in the motor control chapter. Often, a foot will look like it has severe varus deformity, then on another day, the foot will be in valgus. If surgeons do not have a video record and are not very attentive, a presumption of a spastic equinovarus foot deformity may easily be made. These feet may look like ideal feet for tendon transfers because they are supple; however, tendon transfers tend to cause severe over-reaction in the opposite direction. There is no role for tendon transfer in dystonia. We had one patient in whom we did a rectus transfer, not recognizing that it was dystonia and not spasticity. This individual spent 9 months with a flexed knee every time she tried to walk. With persistent therapy and bracing, and under the threat of reversing the transfer, the muscle suddenly went silent and knee flexion in stance stopped. Botulinum toxin is an extremely effective agent to block the muscle effects of dystonia, with its major side effect being that it only works for three to four injection cycles, then the body becomes immune. If the individual has a foot deformity that is symptomatic, the correct treatment is fusion, usually a triple arthrodesis with transection of the offending muscles. Very little other surgery except for fusion is of benefit in ambulatory individuals with dystonia.

Ambulatory problems related to chorea and ballismus are rare, and we have never had occasion in which surgery was required. Again, if there is foot instability, a fusion would be a reasonable option.

Complications of Gait Treatment

There are many real and potential complications in the treatment of gait problems in children with CP. Often, there is the presumption that nonoperative treatment has no complications; however, this is false. The most severe complication of nonoperative treatment is to continue to treat a deformity that is clearly getting worse but the progression is ignored (Case 7.7). A typical example is a child who is increasing in crouch with increasing knee flexion contracture, but there is no decision to address the problem. When the knee flexion contracture finally gets to the point that the child can no longer walk, a decision has to be made to put him in a wheelchair or try surgery. This poor judgment will be the direct cause of the child being in a wheelchair for the remainder of his life, or it may be the direct cause of the complications, which are incurred much more commonly in correcting severe knee flexion contractures than in correcting milder deformities. Individuals who are good community ambulators at age 7 or 8 years of age do

not go into wheelchairs at age 15 years unless there is some complication or supervening medical problem unrelated to CP. Also, the use of inappropriate orthotics can lead to severe skin breakdown or permanent scars on the calf from breakdown of the subcutaneous fat layer. Another complication of nonoperative management is to have children in walking aids that are inappropriate. This means that children should have the correct training before being allowed to use crutches or walkers. Parents have to be informed of the risks of walking aids, such as being aware of wet floors with the use of crutches or open stair doors for individuals with poor judgment.

Complications of Gait Analysis

Complications that arise in the analysis of gait for preoperative planning are usually recognized by the analysis team. Parents or caretakers should be asked if the current gait is representative of the child's home and community ambulation. Children spend enough time during the analysis that experienced therapists will also see how constant and representative their gait is during the whole evaluation. Children may be able to walk for doctors or therapists in a 10-minute clinic examination, but this walk can almost be impossible for them to maintain for a 2-hour laboratory evaluation. Also, the current standard is to evaluate multiple gait cycles, with 10 to 15 cycles usually being evaluated. Evaluating multiple gait cycles also removes the concern about a representative specific cycle. Some children, especially those with behavior problems, have trouble with the level of cooperation that is required to get a full gait analysis. Also, it is difficult to get a full evaluation in children before age 3 years because of the cooperation required. Another complication to watch out for in evaluating gait data is to recognize the sensitivity of the rotational measures to proper marker placement on the extremities. Therefore, hip rotation and tibial torsion have to always be compared with the physical examination and with the knee varus-valgus measures on the kinematics as an assurance of accuracy. If the knee joint axis is incorrect, the knee will demonstrate increased varus-valgus movement as the knee flexes. There also needs to always be a careful evaluation of EMG patterns with the thought that leads may have gotten switched. If the pattern is really confusing, consider lead mix-up as a possibility and have the EMG repeated.

Complications of Surgery Planning

Complications of surgery planning are mostly related to not identifying all the problems or misinterpreting a compensatory problem for a primary problem. A common example of missing problems is not identifying the spastic rectus in the crouched gait pattern, missing internally rotated hips in children with an ipsilateral posterior rotation of the pelvis, and missing internal tibial torsion when there is severe planovalgus deformity that needs to be corrected (Case 7.23). Some common misinterpreted secondary problems are the mid-stance phase equinus on the normal side of a child with hemiplegia, hip flexor weakness in children with increased hip flexion and anterior pelvic tilt but high lordosis as they rest on the anterior hip capsule, weakness of the quadriceps as a cause of crouch, and intraarticular knee pathology as a cause of knee pain in adolescents with crouched gait. Many decisions on specific data are somewhat arbitrary, but having the data is an excellent way to develop an understanding of what the data mean. As a clinical decision is made, the result is then evaluated after the rehabilitation period, and understanding of the significance of the data is developed. Also, some of the errors in interpretation are related to not taking natural history into account. An example is the response of the common equinovarus foot position seen in early childhood. If these children are diplegic, the natural history is for this deformity



Case 7.23 Nikkole



Nikkole, a 4-year-old girl, was evaluated with the concern that she was having trouble controlling her feet. According to her mother she had made good progress in her walking ability in the past 3 months. Her hip radiographs were normal. She was continued in her physical therapy program to work on balance and motor control issues. Her mother was taught how to use walking sticks to help Nikkole with motor control and balance development. She continued to make good progress until age 6 years, when she plateaued in her motor skills development. At that time she had a full evaluation. On physical examination she was noted to have hip abduction of 25° , and hip internal rotation of 70° on the right and 78° on the left. Hip external rotation was 5° on the right and 12° on the left. Popliteal angles were 65° on the right and 73° on the left. An Ely test was positive at 60° . Extended knee ankle dorsiflexion was -8° on the right and -10° on the left. Flexed knee ankle dorsiflexion was 5° on the right and 3° on the left. Observation of her gait demonstrated that she was efficient in ambulating with a posterior walker. However, she had severe internal rotation of the hips, with knee flexion at foot contact and in midstance, and a toe strike without getting flat foot at any time. The kinematics confirmed the same and the EMG showed significant activity in swing phase of the rectus muscles. There was minimal motion at the knee with ankle equinus and lack of hip extension and internal rotation of the hip (Figure C7.23.1). She had femoral derotation osteotomies, distal hamstring lengthenings, and gastrocnemius lengthenings. A rectus transfer was also recommended, but because of the fear of causing further crouch, she did

not receive this procedure. Following the rehabilitation, she was taught to use Lofstrand crutches, with which she became proficient. Her main problem after the rehabilitation was a severe stiff knee gait, but because of the trauma of the surgery, neither she nor her mother was willing to have another operative procedure unless it was absolutely needed; they felt she was doing much better and they were happy. This case is also a good example of a family that is happy because of the excellent gains, even though the surgeon would grade this outcome as disappointing because of the severe stiff knee gait, which should have been treated at the initial procedure.

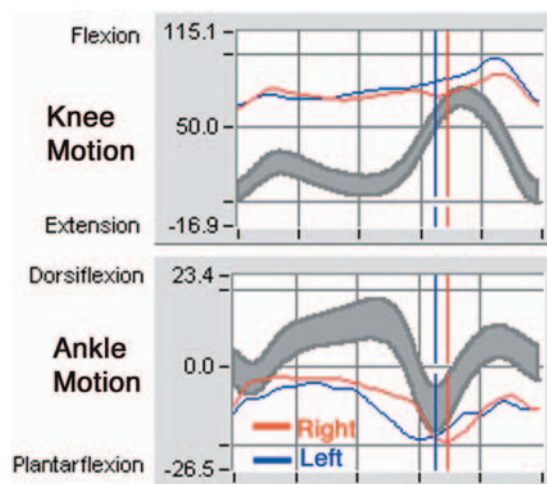


Figure C7.23.1

to completely reverse and become a planovalgus foot, so aggressive treatment should seldom be considered for the early childhood equinovarus posture. Another error is in not considering the energy cost of walking. Children who use 2 ml oxygen per kilogram per meter walking are not going to be community ambulators, and judgment has to be directed as to their real function, which will primarily be sitting in a wheelchair. Also, children's general condition should be considered as the complaints related to walking may be in part result from very poor conditioning and not specific deformities.

Interrelated Effect of Multiple Procedures

When interpreting gait data, there should be an awareness of the impact of adding procedures together. Most procedures are relatively independent of each other; however, there are some interactions. Understanding the impact of multiple concurrent procedures is somewhat like understanding drug inter-

actions. Some specific combinations to watch out for include tibial derotation for internal tibial torsion in the ipsilateral side of a foot that is having posterior tibial tendon surgery for equinovarus. In a small series of 10 limbs, 8 failed and required repeat surgery, all with overcorrection.⁷⁰ Based on this, we recommend choosing the deformity that seems to be the worst, or primary, deformity. Another procedure interaction is planovalgus foot correction so that the heel is in neutral through the use of a subtalar fusion, then doing a supramalleolar osteotomy to correct ankle valgus. This combination of procedures will leave the heel with a residual varus deformity, which is highly undesirable. Another interaction of procedures is that patients who have external tibial torsion that is not being corrected should not have only medial hamstring lengthening, as this will further imbalance the external rotation torque by allowing the biceps femoris muscle to create additional external torque through the knee joint.

Complications of Surgical Execution

The most common complication of surgical execution is overcorrection of a deformity, especially in correction of femoral anteversion. Undercorrection may also occur in femoral rotation. The reason undercorrection occurs is that the femur is somewhat square, and often the plate used for fixation wants to set on the corner, but as the screws are tightened, it may rotate 10° or 15° in one direction or the other. Careful intraoperative evaluation after the fixation is important, and if the rotation is not corrected, it can be corrected immediately. Other intraoperative problems are specific to the procedure, such as recognizing that the foot will never look better than it does immediately after the surgery has been performed in the operating room; therefore, if the foot is still in valgus, it will be so when the cast is removed. Three months and 12 months after surgery, this valgus will only get worse, not better. Correcting residual problems in the operating room is much easier than deciding to come back and correct them with a separate surgical procedure or a revision procedure.

Complications of Rehabilitation

The major problem with rehabilitation is the lack of follow-through by families, or failure of families to be able to pay or get their insurance companies to pay for the therapy that is required. Most children can be rehabilitated as outpatients; however, there are a few especially complicated cases that really benefit from inpatient rehabilitation. The need for postoperative rehabilitation should be discussed with families, and an understanding of how and who will provide this is important even before undertaking the surgery. It is important to have therapists who clearly understand the goals for these children's function, as it is of little benefit to have therapists spend a great deal of time working on sitting transfers when the goal of the surgery was to get the children walking. Postoperatively, the physical therapy has to be directed at the goal that was preoperatively defined through communication with the surgeon, who should be able to clearly articulate what the goals of the surgery were. Other issues in the postoperative period that may cause problems are postoperative pain and subsequent depression. Postoperative pain and depression need to be treated aggressively if they are interfering with the ability of patients to cooperate with the rehabilitation program. Often, using the correct pain medication and adding an antidepressant can be very helpful.

Monitoring the Outcome of Gait Development and Treatment

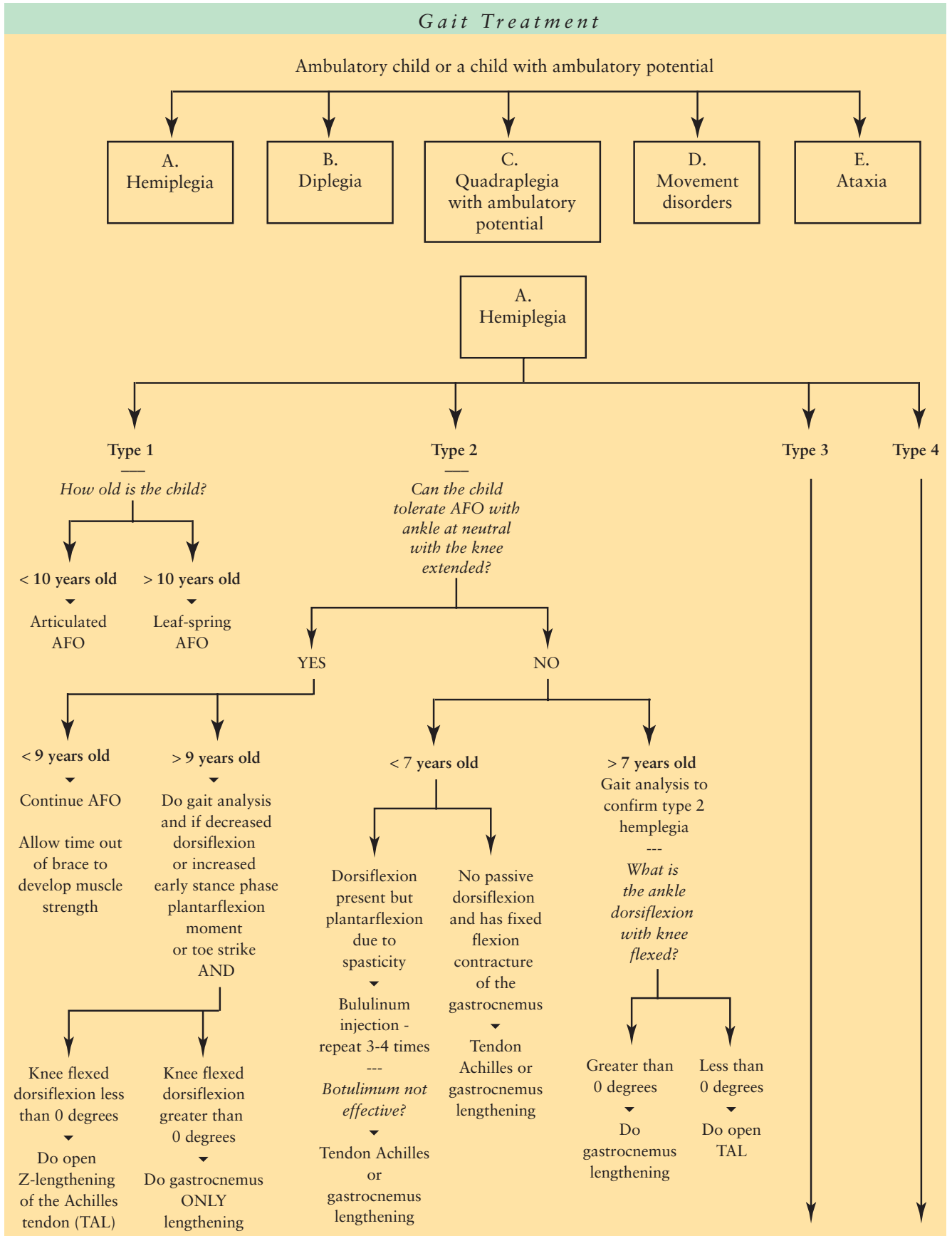
Monitoring the outcome of gait treatment is an area where a clear consensus of a goal has not developed. In general, the goal is to make the different patterns of gait impairments move toward the normal means. Therefore, children

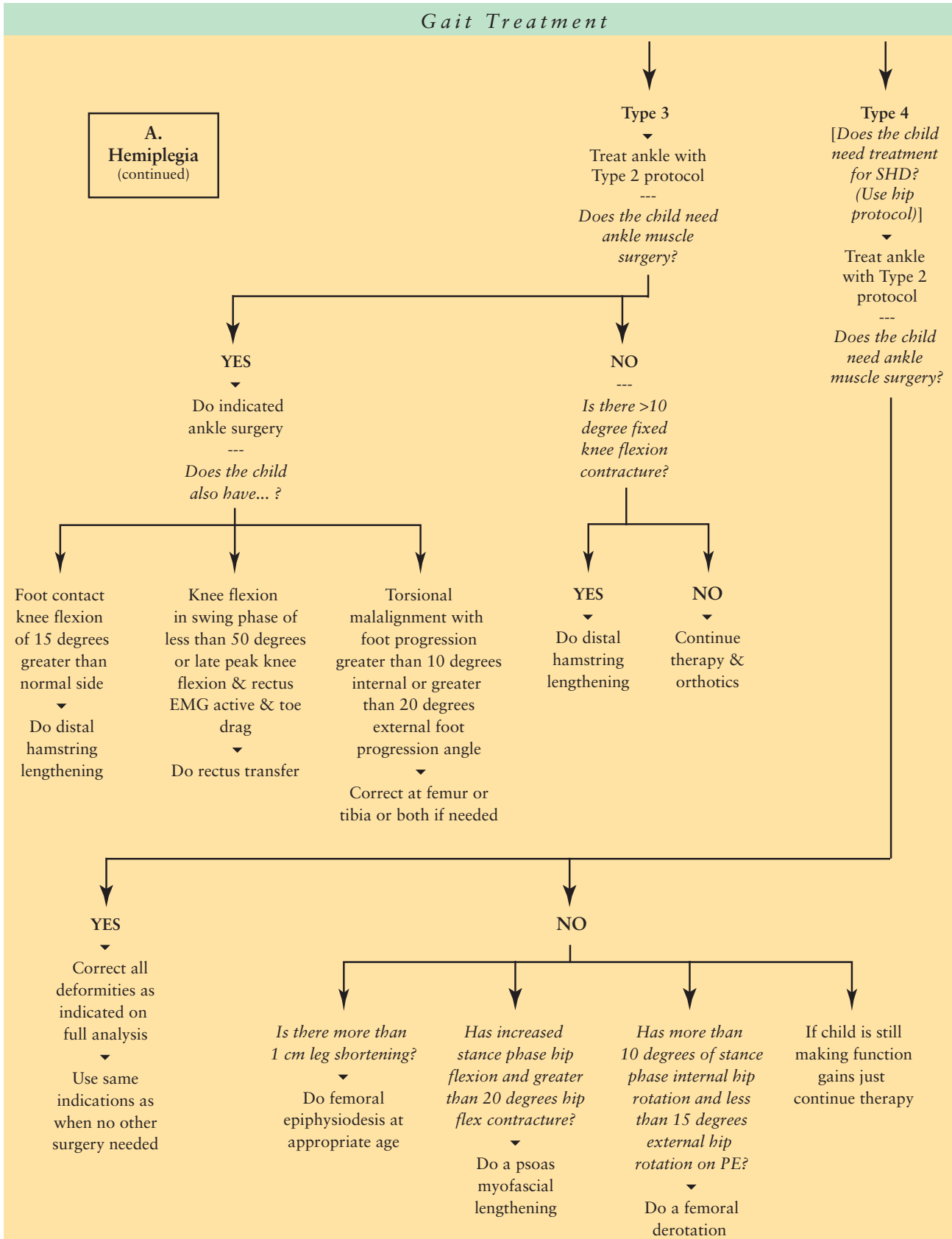
who walk at 60 cm/s are considered improved if, following the treatment, they walk 90 cm/s. Likewise, children who go from 90 cm/s to 60 cm/s would be considered worse. This goal can be applied to joint motions, such as midstance phase knee flexion, maximum knee flexion in swing, or terminal stance power generation at the ankle. However, there are situations where this might not be exactly true, as in the example of a 5-year-old with a high toe walking prancing gait pattern who can only move fast or fall over. He may have a walking speed of 90 cm/s; however, after soft-tissue lengthening, the foot is flat and he can stand in one place and start and stop without falling, although the velocity has dropped to 60 cm/s. This child has clearly improved in the sense of stability, and even though the change in speed seems to be demonstrating the opposite, it is not a reflection of the goal of the initial treatment. The change in perspective of a specific child, the child's age, the functional ability, and the goal of the surgery have to be considered. It is not very effective to measure the volume of a fluid with a thermometer, and in this same way, the measurement tool must reflect the treatment goal. Often, parents complain that the children do not walk better after an adductor lengthening performed as part of the preventive treatment of spastic hip disease. The parents need to be initially told that the goal was to prevent hip subluxation and not make their child walk better. At the same time, children are not expected to walk worse after the adductor lengthening, but the surgery was not directed at improving gait and therefore gait improvement should not be expected.

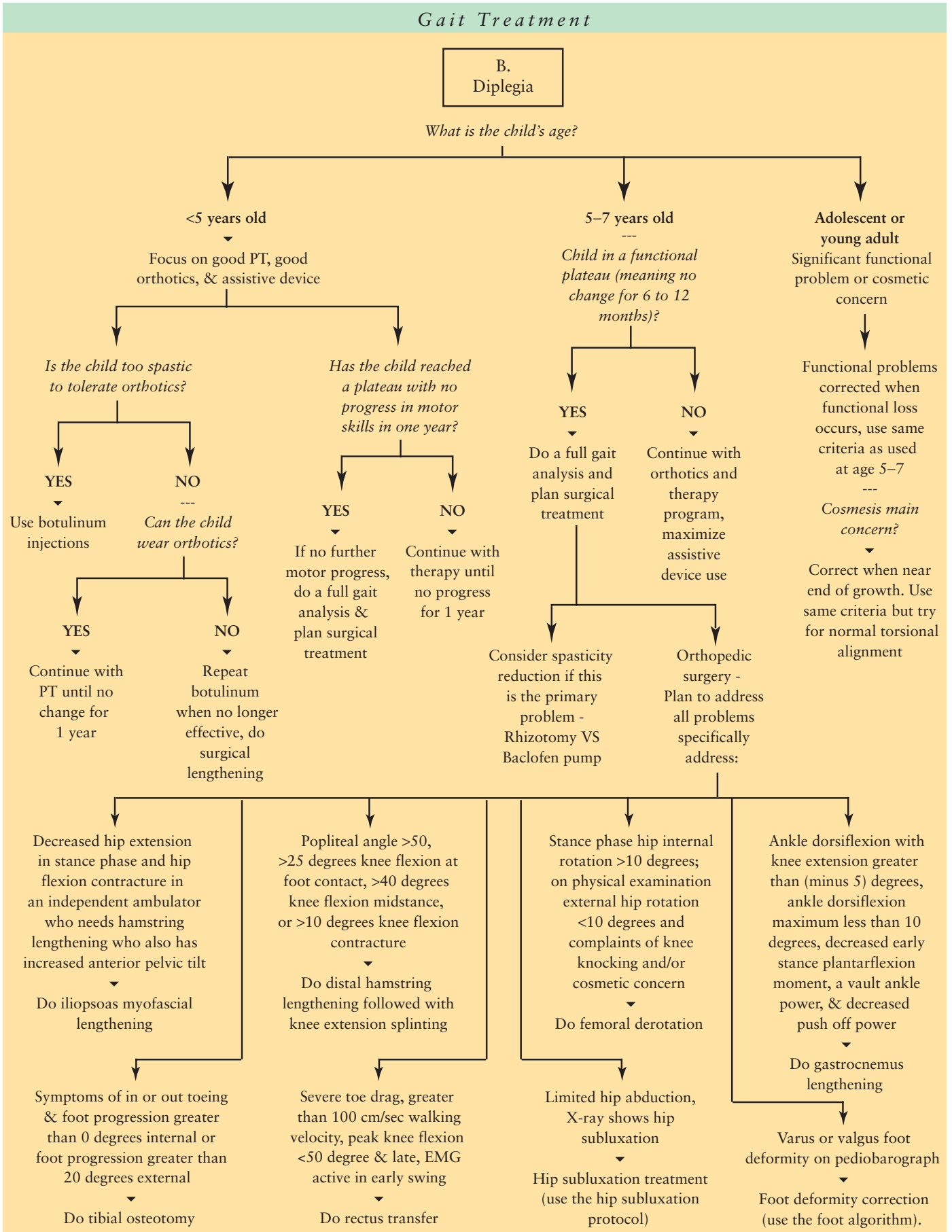
Energy Use Measurement

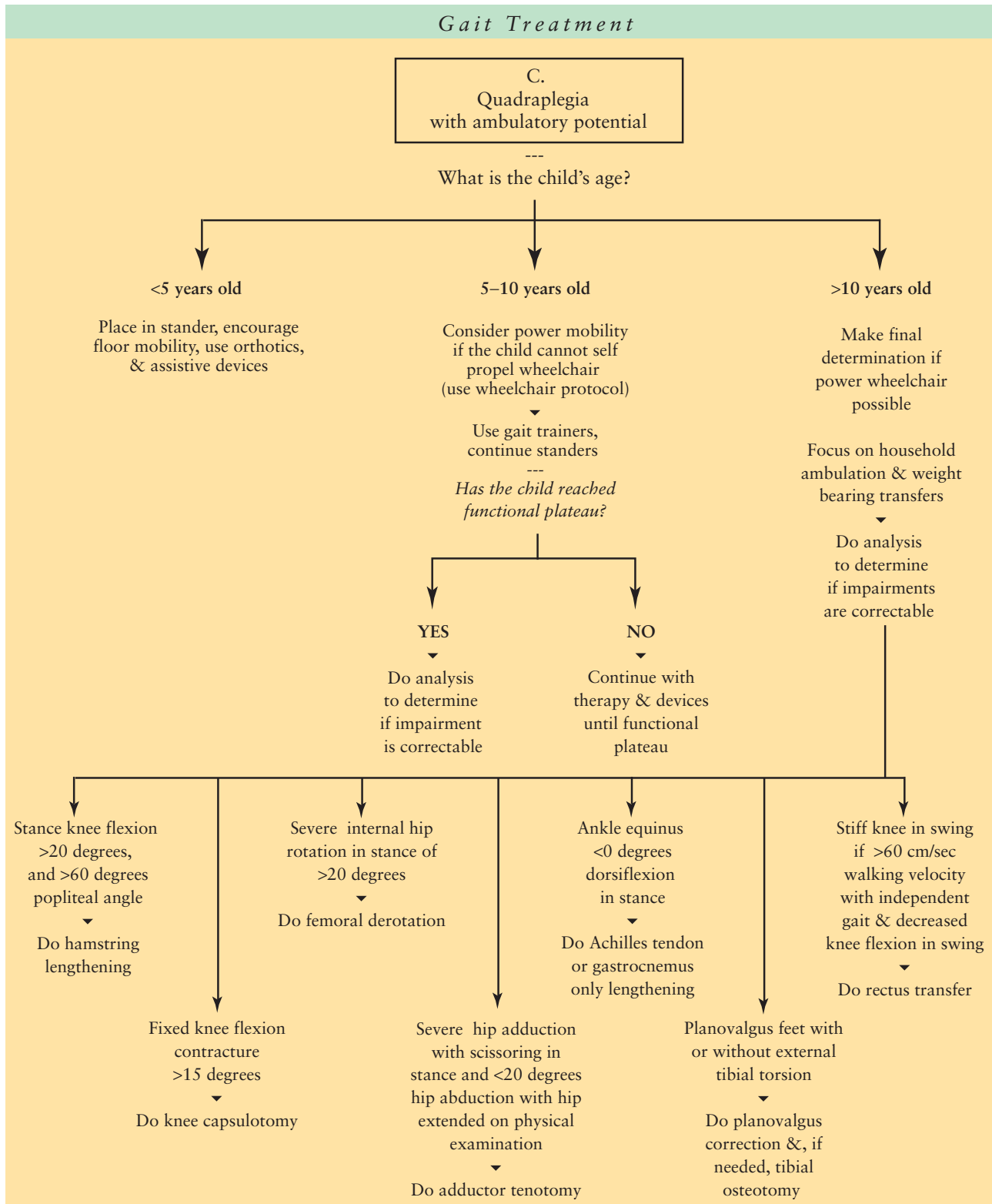
Another measure that has been advocated for assessing outcome of gait treatment is the energy efficiency measured by oxygen consumption. There have been suggestions of using physiologic cost index to measure energy efficiency in children with CP^{71, 72}; however, this has so much variability that it is of no use in these children.^{36, 73} If children have a high oxygen cost of walking, then an improvement is desired; however, this is also a relative measure because a very energy efficient gait can at the same time be completely nonfunctional. This nonfunctional but energy-efficient gait is commonly seen in children with primary muscle disease.³⁷ There have been oral reports that rhizotomy is effective in decreasing the energy cost; however, it makes children act like muscle disease patients rather than spastic patients. The improvement in oxygen cost of walking has to be confirmed with an increased physical functionality, meaning children can do more in their environment. There has been increased interest in developing tools to assess children's function as related to their environment. The pediatric MODEMS questionnaire has been developed for use with children with physical disabilities. There has not been much reported use of this instrument in children with CP. Another scale, developed at the Gillette Hospital, the Gillette Functional Assessment Questionnaire, asks parents to grade children's ambulatory ability on a 10 functional level scale.⁷⁴ This same group has developed a scale of normality in the gait motion data, using principal component analysis of 16 gait variables.⁷⁵ The GMFM and the Pediatric Evaluation of Disability Inventory (PEDI) are two other measures that can be used to give some measure of functional ability.

At this time, a parent-reporting questionnaire with technical data from the gait analysis has to be combined as a measure of outcome. The outcome should also be considered over the child's whole growth and development, not only for a 1-year follow-up period. This measure of outcome has to include obtaining as much information as possible about the natural history of the condition. Measuring outcome is an area that will require much work in the future but it is crucial if the treatment algorithm for the gait impairment secondary to CP is to improve in a way that is documented.









References

1. Perry J. *Gait Analysis: Normal and Pathologic Function*. Thorofare, NJ: Slack, 1992.
2. Harris G, Smith PA. *Human Motion Analysis; Current Applications and Future Directions*. New York: The Institute of Electrical and Electronic Engineers, 1996.
3. Gage J. *Gait analysis in Cerebral Palsy*. London: Mac Keith Press, 1991.
4. Burke RE, Levine DN, Tsairis P, Zajac FE III. Physiological types and histochemical profiles in motor units of the cat gastrocnemius. *J Physiol (Lond)* 1973;234:723–48.
5. Gordon DA, Enoka RM, Stuart DG. Motor-unit force potentiation in adult cats during a standard fatigue test. *J Physiol (Lond)* 1990;421:569–82.
6. Chamberlain S, Lewis DM. Contractile characteristics and innervation ratio of rat soleus motor units. *J Physiol (Lond)* 1989;412:1–21.
7. Cavagna GA, Dusman B, Margaria R. Positive work done by a previously stretched muscle. *J Appl Physiol* 1968;24:21–32.
8. Miller F, Moseley CF, Koreska J. Spinal fusion in Duchenne muscular dystrophy. *Dev Med Child Neurol* 1992;34:775–86.
9. Jozsa L, Kannus P, Jarvinen TA, Balint J, Jarvinen M. Number and morphology of mechanoreceptors in the myotendinous junction of paralysed human muscle. *J Pathol* 1996;178:195–200.
10. Castle ME, Reyman TA, Schneider M. Pathology of spastic muscle in cerebral palsy. *Clin Orthop* 1979;223–32.
11. Ito J, Araki A, Tanaka H, Tasaki T, Cho K, Yamazaki R. Muscle histopathology in spastic cerebral palsy. *Brain Dev* 1996;18:299–303.
12. Wiley ME, Damiano DL. Lower-extremity strength profiles in spastic cerebral palsy. *Dev Med Child Neurol* 1998;40:100–7.
13. Damiano DL, Abel MF. Functional outcomes of strength training in spastic cerebral palsy. *Arch Phys Med Rehabil* 1998;79:119–25.
14. Damiano DL, Kelly LE, Vaughn CL. Effects of quadriceps femoris muscle strengthening on crouch gait in children with spastic diplegia. *Phys Ther* 1995;75:658–67; discussion 668–71.
15. Pearson AM. Muscle growth and exercise. *Crit Rev Food Sci Nutr* 1990;29:167–96.
16. Ziv I, Blackburn N, Rang M, Koreska J. Muscle growth in normal and spastic mice. *Dev Med Child Neurol* 1984;26:94–9.
17. Thompson NS, Baker RJ, Cosgrove AP, Corry IS, Graham HK. Musculoskeletal modelling in determining the effect of botulinum toxin on the hamstrings of patients with crouch gait. *Dev Med Child Neurol* 1998;40:622–5.
18. Gros C, Frerebeau P, Perez-Dominguez E, Bazin M, Privat JM. Long term results of stereotaxic surgery for infantile dystonia and dyskinesia. *Neurochirurgia (Stuttg)* 1976;19:171–8.
19. Koman LA, Mooney JF III, Smith BP. Neuromuscular blockade in the management of cerebral palsy. *J Child Neurol* 1996;11(Suppl 1):S23–8.
20. Videman T. An experimental study of the effects of growth on the relationship of tendons and ligaments to bone at the site of diaphyseal insertion. *Acta Orthop Scand Suppl* 1970:1–22.
21. Roll JP, Vedel JP, Ribot E. Alteration of proprioceptive messages induced by tendon vibration in man: a microneurographic study. *Exp Brain Res* 1989;76:213–22.
22. Booth CM, Cortina-Borja MJ, Theologis TN. Collagen accumulation in muscles of children with cerebral palsy and correlation with severity of spasticity. *Dev Med Child Neurol* 2001;43:314–20.
23. Fettweis E. Spasm of the adductor muscles, pre-dislocations and dislocations of the hip joints in children and adolescents with cerebral palsy. Clinical observations on aetiology, pathogenesis, therapy and rehabilitation. Part II. The importance of the iliopsoas tendon, its tenotomy, of the coxa valga antetorta, and correction through osteotomy turning the hip into varus (author's transl). *Z Orthop Ihre Grenzgeb* 1979;117:50–9.

24. Kolban M. Variability of the femoral head and neck antetorsion angle in ultrasonographic measurements of healthy children and in selected diseases with hip disorders treated surgically. *Ann Acad Med Stetin* 1999;Suppl:1-99.
25. Catanese AA, Coleman GJ, King JA, Reddihough DS. Evaluation of an early childhood programme based on principles of conductive education: the Yooralla project. *J Paediatr Child Health* 1995;31:418-22.
26. Burtner PA, Woollacott MH, Qualls C. Stance balance control with orthoses in a group of children with spastic cerebral palsy. *Dev Med Child Neurol* 1999; 41:748-57.
27. Brogren E, Hadders-Algra M, Forssberg H. Postural control in children with spastic diplegia: muscle activity during perturbations in sitting. *Dev Med Child Neurol* 1996;38:379-88.
28. Chao EY. Justification of triaxial goniometer for the measurement of joint rotation. *J Biomech* 1980;13:989-1006.
29. Grood ES, Suntay WJ. A joint coordinate system for the clinical description of three-dimensional motions: application to the knee. *J Biomech Eng* 1983;105: 136-44.
30. Spoor CW, Veldpaus FE. Rigid body motion calculated from spatial co-ordinates of markers. *J Biomech* 1980;13:391-3.
31. Delp SL, Hess WE, Hungerford DS, Jones LC. Variation of rotation moment arms with hip flexion. *J Biomech* 1999;32:493-501.
32. Delp SL, Arnold AS, Speers RA, Moore CA. Hamstrings and psoas lengths during normal and crouch gait: implications for muscle-tendon surgery. *J Orthop Res* 1996;14:144-51.
33. Hoffinger SA, Rab GT, Abou-Ghaida H. Hamstrings in cerebral palsy crouch gait. *J Pediatr Orthop* 1993;13:722-6.
34. Enoka RM, Rankin LL, Stuart DG, Volz KA. Fatigability of rat hindlimb muscle: associations between electromyogram and force during a fatigue test. *J Physiol (Lond)* 1989;408:251-70.
35. Bowen TR, Cooley SR, Castagno PW, Miller F, Richards J. A method for normalization of oxygen cost and consumption in normal children while walking. *J Pediatr Orthop* 1998;18:589-93.
36. Bowen TR, Lennon N, Castagno P, Miller F, Richards J. Variability of energy-consumption measures in children with cerebral palsy. *J Pediatr Orthop* 1998; 18:738-42.
37. Bowen TR, Miller F, Mackenzie W. Comparison of oxygen consumption measurements in children with cerebral palsy to children with muscular dystrophy. *J Pediatr Orthop* 1999;19:133-6.
38. Rose J, Medeiros JM, Parker R. Energy cost index as an estimate of energy expenditure of cerebral-palsied children during assisted ambulation. *Dev Med Child Neurol* 1985;27:485-90.
39. Rose SA, DeLuca PA, Davis RB III, Ounpuu S, Gage JR. Kinematic and kinetic evaluation of the ankle after lengthening of the gastrocnemius fascia in children with cerebral palsy. *J Pediatr Orthop* 1993;13:727-32.
40. Saraph V, Zwick EB, Uitz C, Linhart W, Steinwender G. The Baumann procedure for fixed contracture of the gastrosoleus in cerebral palsy. Evaluation of function of the ankle after multilevel surgery. *J Bone Joint Surg Br* 2000;82: 535-40.
41. Simon SR, Deutsch SD, Nuzzo RM, et al. Genu recurvatum in spastic cerebral palsy. Report on findings by gait analysis. *J Bone Joint Surg [Am]* 1978;60: 882-94.
42. Ounpuu S, Muik E, Davis RB III, Gage JR, DeLuca PA. Rectus femoris surgery in children with cerebral palsy. Part I: The effect of rectus femoris transfer location on knee motion. *J Pediatr Orthop* 1993;13:325-30.
43. Chambers H, Lauer A, Kaufman K, Cardelia JM, Sutherland D. Prediction of outcome after rectus femoris surgery in cerebral palsy: the role of cocontraction of the rectus femoris and vastus lateralis. *J Pediatr Orthop* 1998;18:703-11.
44. Ounpuu S, Muik E, Davis RB III, Gage JR, DeLuca PA. Rectus femoris surgery in children with cerebral palsy. Part II: A comparison between the effect of trans-

- fer and release of the distal rectus femoris on knee motion. *J Pediatr Orthop* 1993;13:331–5.
45. McCarthy RE, Simon S, Douglas B, Zawacki R, Reese N. Proximal femoral resection to allow adults who have severe cerebral palsy to sit. *J Bone Joint Surg [Am]* 1988;70:1011–6.
 46. Miller F, Cardoso Dias R, Lipton GE, Albarracin JP, Dabney KW, Castagno P. The effect of rectus EMG patterns on the outcome of rectus femoris transfers. *J Pediatr Orthop* 1997;17:603–7.
 47. Thometz J, Simon S, Rosenthal R. The effect on gait of lengthening of the medial hamstrings in cerebral palsy. *J Bone Joint Surg [Am]* 1989;71:345–53.
 48. Atar D, Zilberberg L, Votemberg M, Norsy M, Galil A. Effect of distal hamstring release on cerebral palsy patients. *Bull Hosp Jt Dis* 1993;53:34–6.
 49. Damron T, Breed AL, Roecker E. Hamstring tenotomies in cerebral palsy: long-term retrospective analysis. *J Pediatr Orthop* 1991;11:514–9.
 50. Hsu LC, Li HS. Distal hamstring elongation in the management of spastic cerebral palsy. *J Pediatr Orthop* 1990;10:378–81.
 51. McHale KA, Bagg M, Nason SS. Treatment of the chronically dislocated hip in adolescents with cerebral palsy with femoral head resection and subtrochanteric valgus osteotomy. *J Pediatr Orthop* 1990;10:504–9.
 52. DeLuca PA, Ounpuu S, Davis RB, Walsh JH. Effect of hamstring and psoas lengthening on pelvic tilt in patients with spastic diplegic cerebral palsy. *J Pediatr Orthop* 1998;18:712–8.
 53. Sutherland DH, Zilberfarb JL, Kaufman KR, Wyatt MP, Chambers HG. Psoas release at the pelvic brim in ambulatory patients with cerebral palsy: operative technique and functional outcome [see comments]. *J Pediatr Orthop* 1997;17:563–70.
 54. Tylkowski CM, Rosenthal RK, Simon SR. Proximal femoral osteotomy in cerebral palsy. *Clin Orthop* 1980;183–92.
 55. Joseph B. Treatment of internal rotation gait due to gluteus medius and minimus overactivity in cerebral palsy: anatomical rationale of a new surgical procedure and preliminary results in twelve hips. *Clin Anat* 1998;11:22–8.
 56. Metaxiotis D, Accles W, Siebel A, Doederlein L. Hip deformities in walking patients with cerebral palsy. *Gait Posture* 2000;11:86–91.
 57. Hullin MG, Robb JE, Loudon IR. Gait patterns in children with hemiplegic spastic cerebral palsy [see comments]. *J Pediatr Orthop B* 1996;5:247–51.
 58. Winters TF Jr, Gage JR, Hicks R. Gait patterns in spastic hemiplegia in children and young adults. *J Bone Joint Surg [Am]* 1987;69:437–41.
 59. Renders A, Detrembleur C, Rossillon R, Lejeune T, Rombouts JJ. Contribution of electromyographic analysis of the walking habits of children with spastic foot in cerebral palsy: a preliminary study. *Rev Chir Orthop Reparatrice Appar Mot* 1997;83:259–64.
 60. O'Malley MJ, Abel MF, Damiano DL, Vaughan CL. Fuzzy clustering of children with cerebral palsy based on temporal-distance gait parameters. *IEEE Trans Rehabil Eng* 1997;5:300–9.
 61. Lin CJ, Guo LY, Su FC, Chou YL, Cherng RJ. Common abnormal kinetic patterns of the knee in gait in spastic diplegia of cerebral palsy. *Gait Posture* 2000;11:224–32.
 62. McLaughlin JF, Bjornson KF, Astley SJ, et al. Selective dorsal rhizotomy: efficacy and safety in an investigator-masked randomized clinical trial [see comments]. *Dev Med Child Neurol* 1998;40:220–32.
 63. Boscarino LF, Ounpuu S, Davis RB III, Gage JR, DeLuca PA. Effects of selective dorsal rhizotomy on gait in children with cerebral palsy. *J Pediatr Orthop* 1993;13:174–9.
 64. Peacock WJ, Staudt LA. Functional outcomes following selective posterior rhizotomy in children with cerebral palsy. *J Neurosurg* 1991;74:380–5.
 65. Vaughan CL, Berman B, Peacock WJ. Cerebral palsy and rhizotomy. A 3-year follow-up evaluation with gait analysis. *J Neurosurg* 1991;74:178–84.
 66. Thomas SS, Aiona MD, Buckon CE, Piatt JH Jr. Does gait continue to improve 2 years after selective dorsal rhizotomy? *J Pediatr Orthop* 1997;17:387–91.

67. Marty GR, Dias LS, Gaebler-Spira D. Selective posterior rhizotomy and soft-tissue procedures for the treatment of cerebral diplegia. *J Bone Joint Surg Am* 1995;77:713–8.
68. Yngve DA, Chambers C. Vulpius and Z-lengthening. *J Pediatr Orthop* 1996; 16:759–64.
69. Gage JR. Surgical treatment of knee dysfunction in cerebral palsy. *Clin Orthop* 1990;45–54.
70. Liggio F, Kruse R. Split tibialis posterior tendon transfer with concomitant distal tibial derotation osteotomy in children with cerebral palsy. *J Pediatr Orthop* 2001;21:95–101.
71. Carmick J. Clinical use of neuromuscular electrical stimulation for children with cerebral palsy. Part 1: Lower extremity [see comments] [published erratum appears in *Phys Ther* 1993;73(11):809]. *Phys Ther* 1993;73:505–13; discussion 523–7.
72. Nene AV, Evans GA, Patrick JH. Simultaneous multiple operations for spastic diplegia. Outcome and functional assessment of walking in 18 patients. *J Bone Joint Surg [Br]* 1993;75:488–94.
73. Boyd R, Fatone S, Rodda J, et al. High- or low-technology measurements of energy expenditure in clinical gait analysis? *Dev Med Child Neurol* 1999;41:676–82.
74. Novacheck TF, Stout JL, Tervo R. Reliability and validity of the Gillette Functional Assessment Questionnaire as an outcome measure in children with walking disabilities. *J Pediatr Orthop* 2000;20:75–81.
75. Schutte LM, Narayanan U, Stout JL, Selber P, Gage JR, Schwartz MH. An index for quantifying deviations from normal gait. *Gait Posture* 2000;11:25–31.

Upper Extremity

The upper extremity is frequently affected in children with cerebral palsy (CP). Many children have only mild fine motor difficulties (diplegia) whereas others are more severely affected (hemiplegia and quadriplegia). The classic child with a spastic upper extremity, in whom surgical treatment is considered, has spastic hemiplegia causing posturing of the involved upper extremity with the elbow flexed, forearm pronated, the wrist and fingers flexed, and the thumb adducted and flexed in the palm. Children with movement disorders (athetosis or dystonia) may present with upper extremity involvement however, surgical correction is rarely indicated. The greatest task is to clearly define the functional difficulties (if any), determine optimum goals for a specific child's developmental stages, and bring together realistic long-term goals between patients and orthopaedic surgeons. This task requires that surgeons understand the concerns of families and children about the cosmesis of the extremity and the specific functional concerns. Often, the concerns of patients, especially adolescents, are different from the concerns of parents. Also, orthopaedists have to understand each component of the global extremity's impairment and how these impairments evolve with developmental maturation.

Normal Development of Function of Children's Upper Extremities

Upper extremity spastic deformities start out as a clinched fist position with the thumb in the palm under the flexed fingers. As children grow, the fingers open first, and as more maturity and development occur, the thumb relaxes out of the palm. Often, in children with hemiplegia, the fingers are out of the flexed position by 2 to 3 years of age, and over the next several years the thumb slowly frees up. By 6 to 9 years of age, the thumb may be at the level of maximum abduction, and wrist flexion is becoming the predominant position. There is also significant elbow flexion with forearm pronation from early childhood. As children move through middle childhood and into adolescence, the elbow flexion and pronation often slowly decrease but almost never resolve or become insignificant. By late childhood and early adolescence, the upper extremity deformity has developed the position it will maintain throughout the remainder of individuals' lives, except some of the contractures such as the contracted finger and wrist flexors may slowly become more fixed and more severe. These progressive contractures seem to be more common in quadriplegia than hemiplegia. Throughout childhood, the evaluation of individual children has to focus on their current function, physical deformity in the context of their age, and cognitive abilities.

Table 8.1. Upper extremity function.

Functional Type:	
A	Extremity is not functional
B	Can use hand as a paperweight, pressure assist, or posting device; is able to swipe a toy and turn a switch on and off
C	Hand has mass grasp but poor active control
D	Hand has active grasp and release and can place an object with some degree of accuracy
E	Hand has fine pinch useful for holding a pen or pencil, has key pinch with the thumb
F	Normal function, can be used for buttoning and shoestrapping, thumb has fine tripod opposition
Within each type, also assess level of contractures:	
I.	No contractures
II.	Dynamic contractures
III.	Fixed contractures

Evaluation of Patients

Perhaps one of the most difficult tasks is to accurately determine children's maximum functional abilities to perform tasks of daily living that are age appropriate. This can be done by taking a careful history from the parents, and if possible, questioning the children's occupational therapists to determine tasks that they are working on and tasks that they have recently achieved. For example, in toddlers, the parents should be asked if these children are able to hold a cup or bottle, pick up finger foods, pass a toy from one hand to the other, or hold a piece of paper or crayon. Another question to ask is if the children tend to ignore one of their extremities or do they voluntarily use the extremity? In older children, assessing their ability to dress and toilet themselves, comb their hair, button clothing, tie shoes, etc. becomes more important. Older children may be too embarrassed to admit to some functional limitations and questions may best be asked of parents and patients separately. Also ask about the children's cognitive ability: are they grade appropriate for age, what kind of grades are they making? We have found a parent/patient questionnaire helpful in asking some of these questions (Table 8.1).

Physical Examination

A careful physical examination is done of passive and active range of motion of all joints from the shoulder distally. Evaluation of fixed muscle contractures versus dynamic muscle contractures, as well as recognition of joint contractures and/or joint subluxations and dislocations, are all very important. Even though the Ashworth scale is subjective, it is a good estimate of the tone of the extremity being tested. Particular attention is paid to children's abilities to abduct and flex the shoulder, fully extend the elbow, supinate the forearm, and extend the wrist. The ability of children to do active finger extension with the wrist held in passive extension provides a means of separating out lack of wrist extensor power from contracture of the finger flexors. If children can do active finger extension with the wrist extended 20° to 30°, finger motor function is good (Figure 8.1). If the fingers cannot be actively extended but can be passively extended, lack of extensor motor power is the problem. If the fingers cannot be passively extended, the primary problem is lack of contracture of the finger flexors. The thumb is examined for active

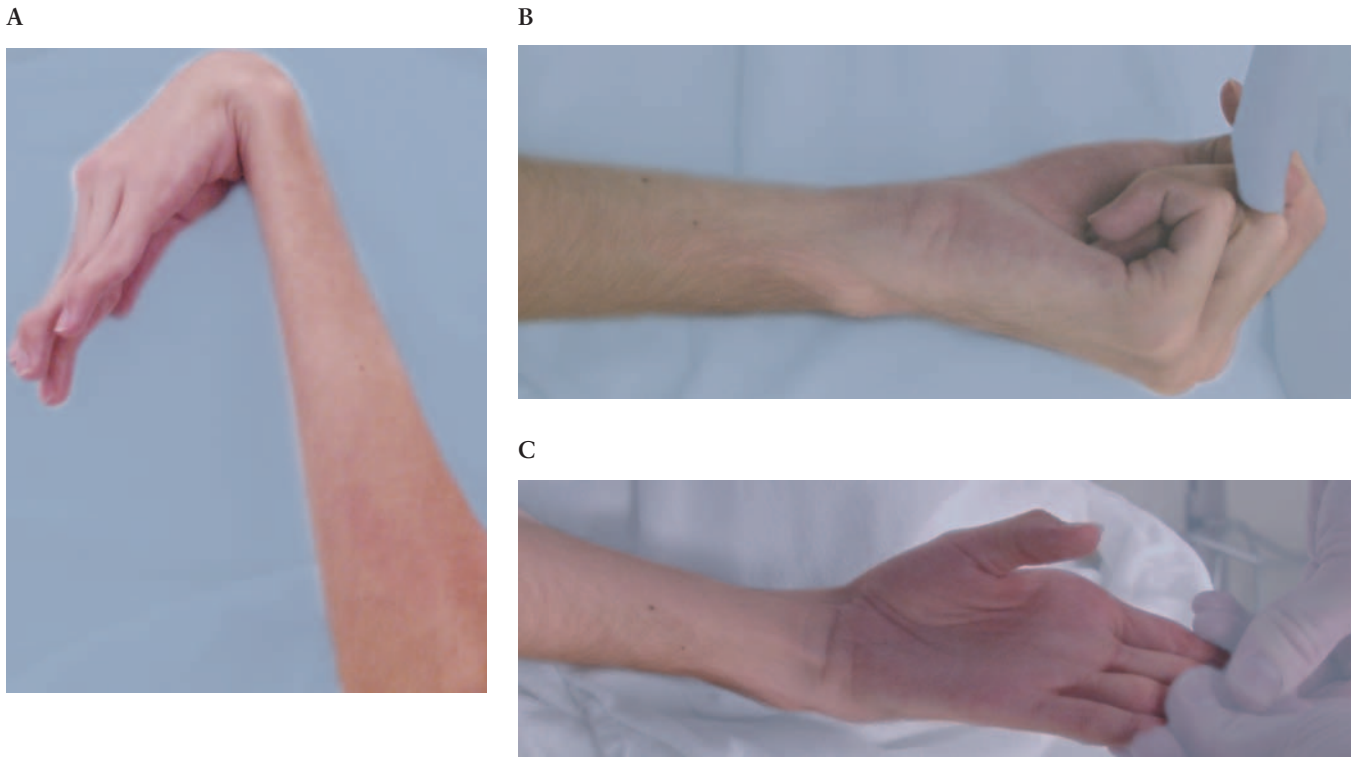


Figure 8.1. Upper extremity involvement covers a wide spectrum of muscle contractures and postures. The typical arm has elbow flexion, wrist flexion, and forearm pronation (A). It is important to assess the degree of wrist and finger flexion contracture. For example, this wrist has minimal wrist flexor or joint contracture, as demonstrated by the ease of wrist extension with the fingers flexed (B). However, there are significant finger contractures as demonstrated by the difficulty in extending the fingers with the wrist extended (C). In addition to assessing the contracture, the ability for active motion in each position also needs to be evaluated.

abduction and extension. Particular attention is paid to whether the deformity is a result of a muscle group being spastic with a fixed contracture and/or an opposing muscle group that has excessive weakness. Similar to the finger examination, the thumb should be examined with the wrist in 20° to 30° of dorsiflexion. The inability to passively abduct the thumb means there is a contracture of the thumb adductors. Passive abduction, which cannot even be done in part actively, demonstrates a lack of thumb abduction motor power. The typical thumb-in-palm deformity results from tight adductors of the thumb, tight flexors of the thumb, or weakness of the thumb extensors and/or thumb abductors. Most often a combination of causes of the muscle imbalance exists.

Sensibility must also be carefully evaluated. Two-point discrimination (>15–20 mm) is the ideal to test but it is difficult to accurately ascertain in children under 10 years of age. In younger children, tactile sensitivity, graphesthesia, stereognosis, and proprioception are easier and more accurate to test. The sensation is a good measure of the overall functional ability of the extremity.

Classification of Upper Extremity Involvement

Classification of patients' overall function is helpful to not only assess functional limitations, but also to determine realistic long-term goals and possible benefits from surgery. Most classifications that have been devised to describe the cerebral palsied upper extremity focus on a specific deformity or function (e.g., grasp and release at the wrist or thumb function). Few classifications describe overall function, are practical in the busy clinical setting, and have been correlated with parents' impression of patients' function. Some, such as Jebson, have shown strong clinical correlation with function, but children with CP cannot perform many of the timed tests to accurately

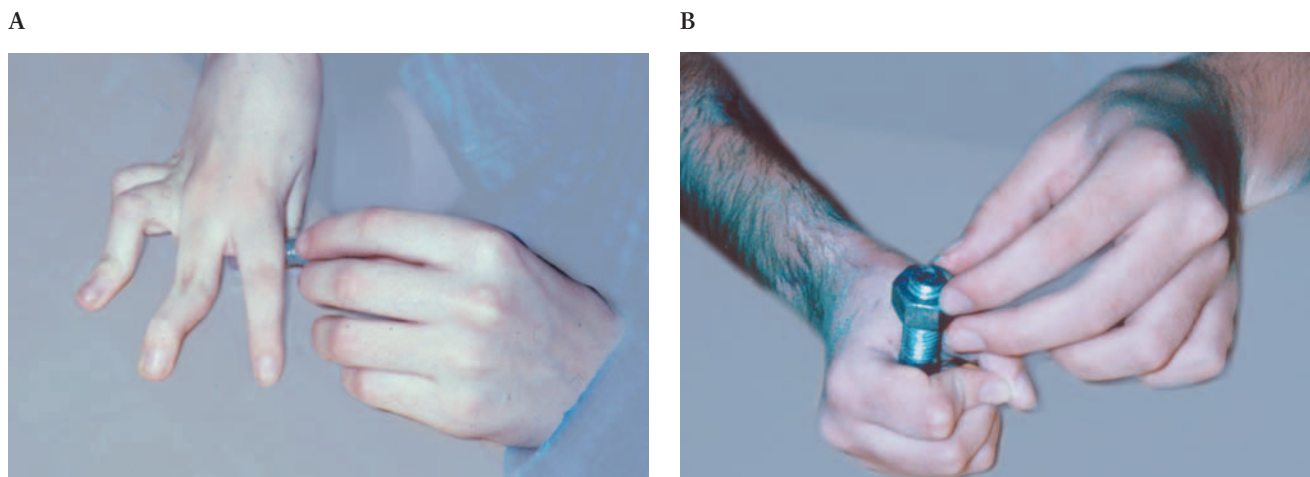


Figure 8.2. Only measuring individual joint functions can miss the functional use of the limb. The way a helper hand is used also needs to be evaluated with more complex functional measures, such as asking the child to screw a nut onto a bolt. The preoperative pattern shows swan neck deformities with wrist flexion (A); however, after reconstruction of the forearm with a pronator release, thumb adductor release, and transfer of the flexor carpi ulnaris to the extensor carpi radialis brevis, the pattern of use of this helping hand has changed completely. The same task can still be performed but the new pattern of use allows a firmer grip in a position in which the screw is more visible (B).

Table 8.2. Upper extremity functional patterns.

Type 0	No active function in the entire upper extremity
Type 1	Proximal function, none to minimal distal function (uses hand as a paperweight/posting device)
Type 2	Mass grasp, poor active control and strength, poor fine motor control
Type 3	Fair active grasp/release (able to place object with fair accuracy), poor thumb opposition
Type 4	Good active grasp/release, fair thumb opposition (key pinch only)
Type 5	Normal to near-normal function, good thumb opposition, able to perform sophisticated fine motor tasks (e.g., buttoning clothes)
Each type is further subdivided into A, no contractures; B, dynamic contractures only; and C, fixed contractures only.	

score the test. The use of the tasks of the Jebson test are helpful; however, the timed nature of the scoring often does not reflect the significant pattern changes that a surgical procedure produces (Figure 8.2). A functional classification system based on six categories was developed for use in the clinic (Table 8.2).

Using this classification, we classified 54 pediatric patients with spastic CP into one of the six types. The classification type strongly correlated with the parents/patients questionnaire described earlier. All 14 patients who were surgically treated improved by one type or more indicating that the classification is sensitive enough to show change with surgery. This classification is also easy to perform in a busy clinical setting.

Guidelines for Setting Goals

Parents are concerned about upper extremity function usually after the concern about children's walking has been addressed. Upper extremity function becomes a major issue as fine motor skills are being considered between 3 and 5 years of age, and become more sharply focused as these children enter school. Goal setting for the treatment and expectations of upper extremity function has to consider the children's age, cognitive function, physical function, and cosmetic concerns. In general, the guidelines based on young

childhood, middle childhood, and adolescent age groups can be used for setting goals.

Early Childhood: Ages 0 to 6 Years

Children may have considerable spasticity early in their development that usually increases between 9 months and 2 years of age. Relaxation or decrease in the spasticity occurs in early childhood as neurological maturation occurs. In early childhood, gross motor coordination is developing. During this time the focus should be on occupational therapy to help develop these skills. Encouraging children to use two-handed toys so that they can develop the use of their more involved hand, especially as an assist hand, is important in this age group. Splinting at this age should be minimized to night usage if there are contractures. Some functional daytime splints, such as soft opponens-type thumb splints to keep the thumb out of the palm, may also be helpful. Bulky splints that discourage the use of the involved extremity should be avoided at all costs. Also, splints that cover a significant surface of the palm and palmar surface of the fingers should be avoided because this removes sensory and tactile feedback ability from the hand and will encourage ignoring the hand, not spontaneous hand use.

Middle Childhood: Ages 6 to 12 Years

Children in this age group generally have maximized gross motor function but are continuing to develop fine motor skills. Also, helping these children to develop skills in activities of daily living, such as getting dressed, self-toileting, and feeding, is extremely important at this age. As these children are going through a rapid growth spurt, muscle contractures are beginning to occur. Dynamic contractures can be treated with botulinum toxin injections into the affected muscles. Surgery should be considered for fixed contractures in patients who meet the proper surgical prerequisites. Cosmetic concerns about the appearance of the extremity arise in these children during middle childhood.

Adolescence: Ages 12 Years and Older

Individual functional development will focus on activities of daily living and skills, such as recreational activities in younger adolescents and vocational and educational activities in older teenagers. This development will help individuals become independent in school. For some children with more severe involvement, the use of an aide to assist with handwriting and also learning to operate a laptop computer is very helpful. Focusing on what works best for an individual child is most important. Trying to force children into a traditional predetermined mold of the way these children should use the involved extremity can be damaging to their self-esteem. For example, trying to force a child into doing a timed handwritten essay test or penalizing them for poor handwriting is humiliating and fruitless to their overall development, particularly with the technology that is available as an assistive writing device. Surgery can still be performed at this age. It is important to communicate to families and children the realistic functional gains that can be expected with any surgery. On the other hand, the benefits of a cosmetic improvement in the appearance of an involved extremity should not be underestimated. Of course, overall goals must be individualized after a careful history, physical examination, assessment by therapists and surgeons, and realistic expectations of parents and patients.

Treatment

Preoperative Evaluation

In addition to a careful history and physical examination by an orthopaedic surgeon, more detailed evaluation by an occupational therapist is extremely helpful. This evaluation generally takes approximately 1 hour and details range of motion, manual muscle testing, assessment of gross and fine motor skills, and assessment of tone and sensation. Occupational therapists will often note details that the surgeon did not for reasons of time limitations. A clear definition of the expected goals of the prescribed treatment is important to help physicians be realistic and for families to hear what they can expect. For example, an arm is never normal after any treatment, which is clear to physicians but must be stated especially clearly to adolescents. An adolescent may say “Oh yes, I know that” but usually continues to harbor unrealistic expectations. This conversation causes her to verbally acknowledge these expectations. Other diagnostic testing, such as dynamic electromyography (EMG), has been advocated by some clinicians as helpful in the planning of muscle transfers. Muscles found to be in phase with the recipient muscle have been found by some investigators to perform better than those that are non-phasic.¹ Hoffer et al. state that flexor carpi ulnaris transfer to the wrist extensors causes excessive wrist extension if it is done out of phase.² We have not used dynamic EMGs in our preoperative planning regimen; however, based on the published reports, it would seem to improve diagnostic workup.

Control of Spasticity

Neuromuscular blocks using botulinum-A toxin can be injected directly into the desired muscle belly to be weakened. This injection can be helpful in predicting the effects of muscle lengthening, although it may be ineffective in the presence of a fixed tendon contracture. The injections can also be used therapeutically; however, they must be repeated every 3 to 4 months because the effects are overcome with neurologic recovery. In the past, ethanol and phenol injections were also used; however, these drugs are very painful to inject and generally require sedation. Botulinum-A toxin, on the other hand, can be injected in the clinic setting without sedation. Also, ethanol and phenol cause pain from sensory neuropathy and muscle fibrosis so they are seldom used today.³ Botulinum-A is particularly helpful in younger patients with dynamic spasticity that is interfering with function. In a double-blinded trial, Corry and colleagues found botulinum-A toxin to be effective in improving range of motion and gross motor function in the short term.⁴ Long-term benefits are unknown. Aggressive therapy after injection helps strengthen antagonist muscles. Dosages of 20 to 50 units per muscle belly are utilized, limiting the total dosage to 10 to 15 units per kilogram.

During the period of enthusiasm for dorsal rhizotomy, there were many papers extolling the benefits of lumbar rhizotomy on the tone reduction and functional gain in the upper extremities.^{5, 6} However, by using age-matched controls, it was apparent that the effect being recorded was improvement related to maturation and was not related to the rhizotomy.⁷ Dorsal lumbar rhizotomy currently has no substantial benefit on upper extremity function. Likewise with the introduction of intrathecal baclofen, there have been many reports suggesting a reduction of upper extremity tone.⁸⁻¹¹ In our experience, this reduction of tone is related to the local placement of the intrathecal catheter. If the catheter tip is placed between C6 and T3, good reduction of upper extremity tone occurs. As the catheter is progressively placed lower,

there is less upper extremity effect. Intrathecal baclofen to control upper extremity spasticity can be helpful if the catheter is threaded up into the high thoracic or low cervical region. Careful postoperative monitoring is important to look for any signs of respiratory depression.

Orthopaedic Surgery

Several prerequisites have been identified as reliable indicators for functional improvement after upper extremity surgery in children with CP. These include voluntary control of grasp and release, sensibility, intelligence, age of the patient, and type of neurologic involvement. As in the lower extremity, it is best to identify and treat all deformities at one time to prevent secondary deformity and to decrease multiple surgical events. It is very appropriate to consider the cosmetic concerns of families and patients, because the upper extremity, especially the forearm and hand, is the second most publicly visible fully exposed segment of the human body after the face. Improving the appearance of the upper extremity can make a large difference in the self-image of developing adolescents.

Voluntary Control

Voluntary control of grasp and release is the most important criteria to assess children with CP with upper extremity involvement, and it provides the most reliable indicator for functional gains after surgery despite poor indicators in some of the other categories. Zancolli and Zancolli have defined grasp and release patterns according to three patterns.¹² In pattern 1, active finger extension is possible with the wrist in less than 20° of flexion. These patients have difficulty with prehension due to contraction of the wrist flexors during active grasp. In pattern 2, active finger extension is not possible unless the wrist is allowed to flex more than 20°. Subgroup A of pattern 2 has wrist extension with full finger flexion, whereas subgroup B has no wrist extension. In pattern 3, active finger extension is not possible even with maximum wrist flexion. Severe deformity of the fingers and wrist exists. Patterns 1 and 2 have the most functional benefits after surgery. Pattern 3 cannot be improved functionally but can have improvement in cosmesis and hygiene. All these patterns are usually associated with some adduction or flexion deformity of the thumb, pronation deformity of the forearm, and flexion contracture of the elbow (Figure 8.3). All patterns must be assessed for the presence or absence of voluntary control.

Sensibility

Sensory deficits are present in most patients with CP with upper extremity involvement. Sensory testing in these patients has been previously described. Although important, sensibility should not in itself be a contraindication to surgery. Increased severity of sensory deficit is a reflection of an increasing severity of the neurologic impairment. Many children effectively use hand-eye coordination to compensate for defects in stereognosis and proprioception, particularly if they have good voluntary control. Also, the spastic limb can learn by experience, as shown by tests of fingertip force application based on the material presented.^{13, 14} Even though the uninvolved side of children with hemiplegia is believed to be normal, fine motor testing usually shows deficits in tactile processing.¹³

Intelligence

The ideal patient to consider for surgical reconstruction has an intelligence quotient of greater than 70, adequate behavior, cooperation, and motivation

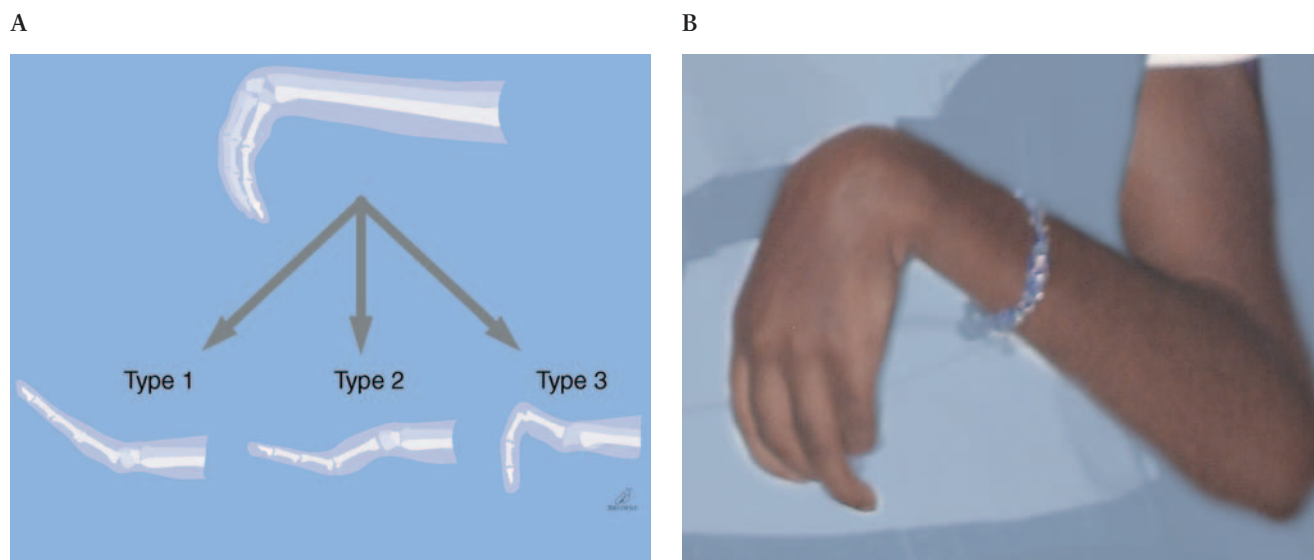


Figure 8.3. Specific patterns of spastic hand deformity, based primarily on the grasp pattern, have been described by Zancolli and Zancolli.¹² Type 1 deformity has full active finger extension with the wrist at 20° of flexion or less. The wrist is in neutral or slight flexion with grasp. In type 2, there is full active finger extension but the wrist requires more than 20° of flexion for this to be possible. Finger grasp occurs with significant wrist flexion only (A). Type 3 pattern has little active finger extension or grasp function (B).

before undertaking upper extremity surgery. Postoperative cooperation in therapy is also important. Once again, minor abnormalities in mental status should not contraindicate surgery if children have good voluntary control. These criteria are most important if the goal is to make functional gains; however, they are of little importance if the treatment is done to improve cosmesis or improve custodial care problems.

Patient Age

Most orthopaedic surgeons have advocated delaying surgery until age 4 years when adequate maturation of the nervous system has developed and when some degree of patient cooperation can be expected. Traditional teaching is that the ideal age to consider surgery is between 4 and 9 years. We have found children between the ages of 7 and 12 years to be ideal candidates for surgery. This age range gives children enough maturity to cooperate with occupational therapy and enough skeletal growth where recurrence due to increasing muscle tightness secondary to growth is at less risk. These patients are also not too old for retraining of transferred muscles, and they have reached a plateau in their neurologic development.

Neurologic Type

Patients with spasticity benefit most from surgery. It is extremely important to distinguish dystonia from spasticity, which can look very similar. Dystonic patients do poorly with muscle transfers and lengthening as do most patients with movement disorders (including athetosis). In general, tendon surgery should be avoided in patients with movement disorders. Some individuals, especially those with athetosis, may benefit from restraining the nondominant extremity during fine motor skill tasks.¹⁵

Shoulder

Shoulder Contractures

Individuals with quadriplegic pattern involvement often develop shoulder contractures. Typically, these contractures start to become noticeable in

middle childhood and become more noticeable in adolescence. The most common deformity is protraction and elevation of the shoulder through the scapulothoracic joint, with the clavicle becoming more vertical and anteriorly directed. As severely involved patients become adults, this shoulder position becomes fixed but seldom causes any pain or discomfort. In spastic patients, internal rotation contracture of the shoulder develops as a result of spasticity of the pectoralis major and subscapularis muscle. On rare occasions, extension and external rotation abduction contractures develop, often caused predominantly by the long head of the triceps and teres muscles.

Natural History

The natural history of shoulder contractures is for increasing severity during late childhood and adolescence with minimal change after hormonal and skeletal maturity. Also in middle childhood, primarily in children with quadriplegia, shoulder adduction, internal rotation, and flexion contractures develop. As these contractures become more severe, especially at puberty with the hormonal changes and the growth of axillary hair, the contractures become so severe that proper cleaning and drying of the axilla becomes very difficult. Also, dressing these children, especially placing arms in sleeves, becomes very difficult. For other functional positions, such as seating and different reclining positions, this upper extremity position is good.

During adolescence, there are a small group of children who develop an external rotational abduction contracture of the shoulder. This becomes a functional problem, especially when seated in a wheelchair, as the arms tend to strike walls as these children are being transported. This shoulder position also limits side lying.

For ambulatory children, the most common hemiplegic posturing is with shoulder elevation and protraction combined with adduction, flexion, and internal rotation. This becomes severe enough to cause functional problems only in rare ambulatory children with hemiplegia. There are also a few children who develop shoulder extension and external rotation combined with elbow extension. In ambulatory children this is usually a sign of dystonia, although this may be encountered in individuals with spasticity and contracture (Figure 8.4).

Figure 8.4. Shoulder and elbow extension can be disabling because it causes the arm to be behind and lateral to the individual. This may lead to the arm getting bumped or striking furniture, and it is a significant cosmetic problem (A). After proximal release of the lateral and long head of the triceps, the elbow and shoulder flexion are greatly improved (B). This also allows the arm to hang at the side during ambulation (B). (Case Material contributed by Federico Fernandez-Palazzi and Joaquin Xicoy-Forgas, Caracas, Venezuela.)

A



B



Treatment

In childhood, the primary treatment of shoulder contractures is by passive range-of-motion exercises. Splinting is of no use, especially the attempt to use figure-of-eight straps on the shoulders to counteract the shoulder protraction and elevation. These straps have too little mechanical advantage to make an impact without causing children discomfort.

As children with quadriplegia enter puberty and approach maturity, problems related to dressing and hygiene develop. When the parents or caretakers report problems, treatment is indicated. By this time the contractures are fixed and only surgical lengthening will make a difference. The goal of surgery is to lengthen the shoulder internal rotator and adductors enough so children's arms can easily be placed in sleeves and the axilla can be cleaned. Obtaining 90° of shoulder abduction in the operating room is very adequate to accomplish these goals. Usually, this abduction is accomplished with complete release of the pectoral muscles (Case 8.1).



Case 8.1 Jessica

Jessica, a 16-year-old girl who was completely dependent in all activities of daily living, was brought by her caregivers from a facility where she lived. Her mother cared for her at home one weekend a month and was also present. They agreed that the major problem was difficulty in dressing her left upper extremity because her arms were very stiff. The caregivers also complained that it was very difficult to clean her axilla and they could not control her strong body odor because of difficulty with bathing, especially in her axilla and wrist flexion crease. She had had multiple previous surgeries including spinal fusion for scoliosis and hip osteotomies for spastic hip disease. She had severe mental retardation and seizures. On physical examination, the shoulder demonstrated severe fixed contracture allowing less than 20° of abduction, fixed internal rotation, elbow flexion contractures of 90°, and a fixed wrist flexion contracture with no functional use in the extremity (Table 8.1). She previously had a surgical correction of the right upper extremity. With the goal of improving custodial care, she had release of her pectoralis muscles and subscapularis. In the operating room she could be abducted to 90° at the shoulder and externally rotated almost to neutral. The elbow had a complete release of the biceps, brachialis, and brachioradialis muscles allowing extension to -60°. The wrist had a proximal row carpectomy flexor tendon lengthening and plication of the finger extensors. Postoperatively, she developed a position similar to the right upper extremity with improved ability for bathing and dressing (Figure C8.1.1).

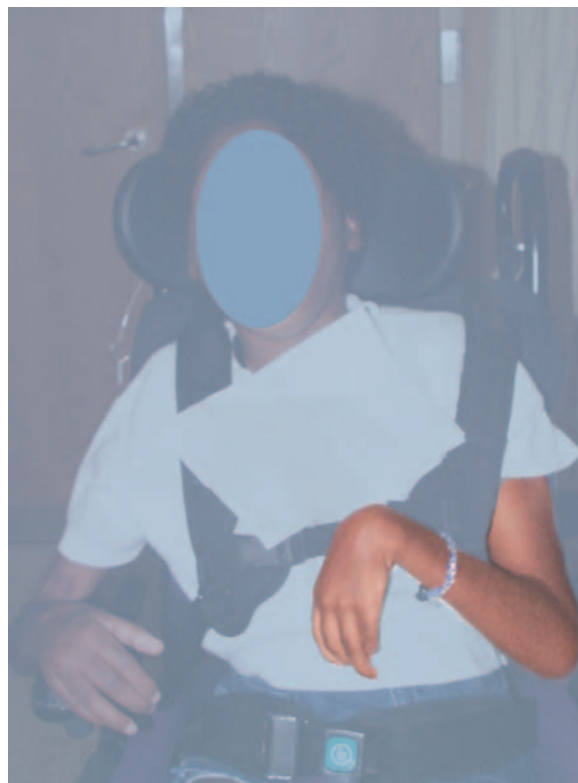

Figure C8.1.1

For children who have extension and external rotation contractures, usually with a major dynamic component, the triceps can be injected with botulinum toxin. Temporary relief will usually be noted and the definitive treatment is to release the long head of the triceps at the shoulder. This release will allow the limb to hang at the side or stay in the flexed position. If this procedure is done in individuals with dystonia, a severe flexion, adduction, and internal rotation deformity usually develops.

For adolescents with severe contracted abduction and external rotation shoulder contractures, usually bilateral in individuals who use wheelchair mobility, the most reliable procedure is humeral osteotomy. This osteotomy is rarely needed but does address the problem in a definitive and more reliable way than trying to relax all the contracted muscles. Humeral osteotomy is also the best procedure for individuals with predominantly internal rotation contractures who want the arms to be in a more normal position (Case 8.2).

Outcome of Treatment

There are no published reports of the outcome of shoulder adductor lengthenings; however, in our experience, the goals that can be reliably obtained are usually limited to improved ability to dress children and provide better personal hygiene. If the procedure is done during puberty there does not seem to be much recurrence of the contracture. Recurrence is the main problem if shoulder adductor lengthenings are done on younger children.

Other Treatment

When these fixed contractures develop, there are no significant options other than surgery. When the problem is noted, there is often an increase in therapy as an attempt to stretch out the contractures. This therapy occasionally seems to help a little, but the passive range of motion is a common cause of proximal metaphyseal humeral fractures as these children are very osteopenic from minimal upper extremity use. Therefore, if passive stretching is instituted, it should be done by an experienced therapist.

Complications of Treatment

Surgical lengthening of the shoulder adductor, triceps release, or humeral osteotomy have minimal complications.

Shoulder Instability

Shoulder joint instability is relatively common in individuals with quadriplegic involvement and children in middle childhood with athetosis. The most common pattern is anterior subluxation as the shoulder becomes protracted and elevated. The humeral head becomes subluxated anteriorly toward the coracoid process. These subluxations cause children no pain but are often accompanied by decreased range of motion, especially external rotation and abduction. The increasing contracture may cause problems with dressing or cleaning the axilla.

Complete acute dislocation of the shoulder, either in the anteroinferior direction or the posterosuperior direction, also occurs. For many children in middle childhood or adolescence, this event causes pain but the shoulder is easy to reduce. In a few children the shoulder becomes dislocated and is not painful. The fixed dislocations occur in individuals with severe involvement and they do not become painful over time.



Case 8.2 Timothy

Timothy, a 17-year-old boy, complained that his arm always hung in front of him and bothered him, especially when he wanted to walk fast. Also, he was concerned about the appearance of the limb. He was in 11th grade of a regular high school and did age-appropriate academic work. He used the extremity as a helper hand but he was not concerned about improving the function of the extremity. On physical examination he demonstrated the ability to raise the arm to 90° of forward flexion, maximum external rotation to only -45° , and the elbow could be flexed fully and extended actively to -30° . On physical examination the shoulder could be externally rotated to almost neutral passively (Figure C8.2.1). Forward flexion and abduction appeared to be full. The elbow extended to a minimum of 15° with full flexion on passive motion. He stood and walked with the elbow flexed and the shoulder

internally rotated. Because this was thought to be a shoulder with useful function, we did not want to do extensive muscle lengthening; therefore, he had a derotation osteotomy of the humerus and a myofascial lengthening of the biceps and brachialis (Figure C8.2.2). Postoperatively, he had 30° of external rotation of the shoulder, and the elbow came to -20° of extension. He was happy with the result, and although the limb still tended toward internal rotation, it was better than fixed internal rotation.

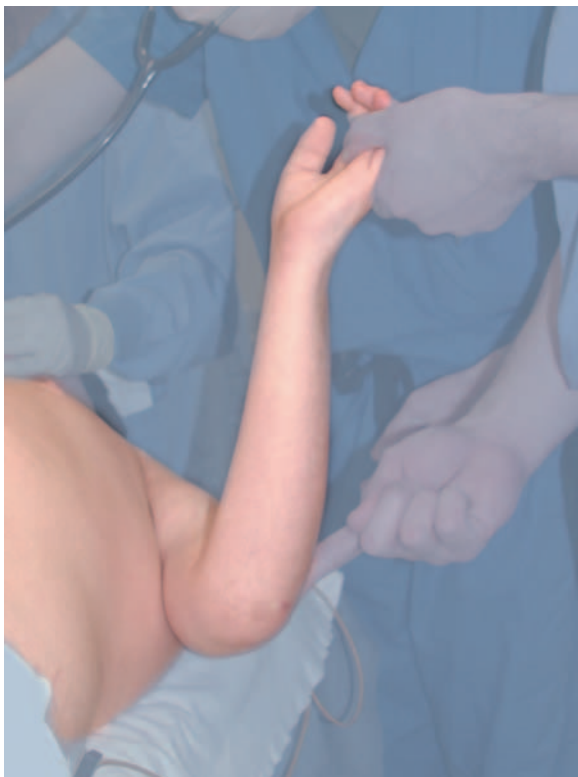

Figure C8.2.1

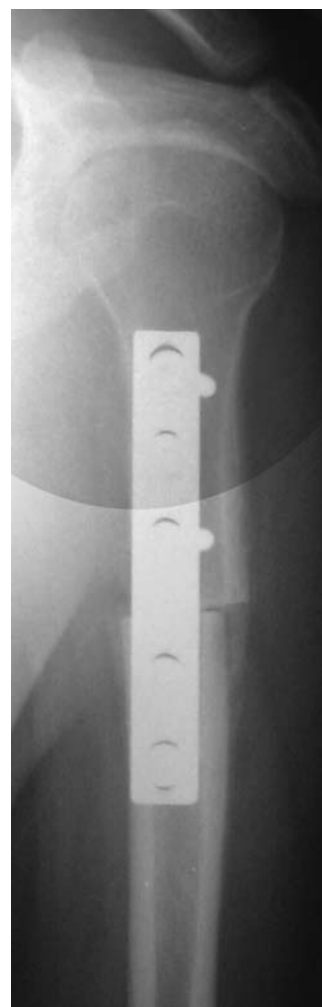


Figure C8.2.2

Natural History

Very few fixed shoulder dislocations become painful. The painful acute dislocations may slowly resolve over time as the shoulder is protected. A small group of individuals, usually late adolescents or young adults, develop severe instability with multiple recurrent dislocations. These dislocations may become progressively more painful as joint degeneration occurs.

Treatment

Fixed anterior subluxations and fixed dislocations of the shoulder with no pain seldom need any treatment. Acute dislocations should be reduced and the position causing the dislocation avoided, which may require the use of a sling but needs to be individualized to each child. Parents and therapists need to be advised to avoid moving the arm into the position where the instability occurs. Caretakers need to be advised to avoid lifting the children by holding the arms and definitely never lift them by pulling the arms into the extended and flexed overhead position. If recurrent dislocations get worse and do not slowly resolve, which almost always happens in childhood and adolescence, surgical reconstruction should be considered using standard shoulder stabilization procedures. If reconstruction fails or if the joint has severe degenerative arthritis, fusion of the shoulder joint is a good option.

Occasionally, athetoid or dystonic patients will have an unstable shoulder. An unstable shoulder is an extremely difficult problem to treat because standard soft-tissue repairs tend to stretch out when patients continue to posture the shoulder in an unstable position. Careful positioning of the shoulder, trying to avoid surgical treatment, is first attempted. Shoulder fusion may be required in resistant cases. We have had one dystonic patient whose shoulder became increasingly unstable as her scoliosis progressed. After correction of her spinal curvature with a spine fusion, her shoulder reduced and became stable.

Elbow and Forearm

Elbow Flexion Contracture

The elbow flexors have a significant mechanical advantage over the elbow extensors; therefore, when severe spasticity occurs, the flexors tend to shorten, which causes an elbow flexion contracture. The biceps is a two-joint muscle and is the primary cause of the contracture. The brachialis and brachioradialis are one-joint muscles that also develop contractures, especially with severe and long-standing contractures.

Natural History

Fixed contractures tend to develop in late childhood and adolescence. For individuals with severe quadriplegia, the flexion contracture may become so severe that bathing and keeping the elbow flexion crease clean becomes difficult. In individuals with hemiplegia, the position of the flexed elbow causes a significant cosmetic concern. Usually, by young adulthood, the contracture is fixed and not progressive.

Treatment

In young childhood and middle childhood the use of extension splinting may be helpful, although there is no good documentation. Injection of the elbow flexors with botulinum toxin has been reported, but none of these reports

suggest that any significant lasting benefits occurred.^{4, 16, 17} Botulinum toxin may be useful for a few individuals in whom short-term goals are defined. As the contracture becomes very severe and causes problems with hygiene, a surgical release of the elbow flexors is indicated. In individuals with severe quadriplegia and severe contractures, the release should include a complete transection of the distal biceps, brachialis, and brachioradialis. Extension splinting then follows this transection. This level of release usually allows elbow extension to be between approximately 60° and 90° of flexion, which is enough to allow for bathing and keeping the elbow clean.

In individuals with hemiplegia, the release of the flexion contracture is indicated because of a cosmetic concern of the elbow always being in a flexed position. If individuals are very functional with their arms and the contractures are mainly dynamic, a Z-lengthening of the biceps tendon is indicated. If the arms are less functional or a fixed contracture of 10° to 20° is present, a complete release of the biceps tendon is indicated. For children with more severe positioning, especially if their arms are held to almost 90° during ambulation, a myofascial lengthening of the brachialis is added. Elbow flexor lengthening during late childhood and adolescence does seem to provide a permanent improvement in elbow extension.¹⁸

Severe fixed flexion contracture of the elbow is encountered mainly in quadriplegia where there is little indication to treat the contracture beyond a muscle lengthening. In rare occasions, a severe contracture may present in hemiplegia, where there is an indication to gain extension for a specific functional gain or cosmetic concern. Treatment with an extension osteotomy of the distal humerus is a safer and simpler approach than trying to do a complete capsulotomy. Elbow joint resection with a flexor release has been reported as a treatment of severe elbow flexion contractures,¹⁹ but we have no experience with this procedure.

Complications of Treatment

Complications of elbow flexor release are rare. The most serious complication is injury to the brachial artery or the medial nerve during flexor lengthening. This complication is best avoided by doing the lengthenings through an open incision and under tourniquet control for optimal visualization of the operative field. Loss of elbow flexor power is only of concern in a few individuals with very heavy use of the extremity. Lack of active flexion has never been encountered and complaints of elbow weakness are almost never reported. Most individuals are happy with the degree of improvement.

Radial Head Dislocation

Radial head dislocation is a relatively common problem in severe quadriplegia with elbow flexion contracture and pronation contracture. Radial head dislocation reportedly occurs in 2% of all children with CP involving the upper extremity when elbow radiographs are carefully evaluated.^{20, 21} In those with severe elbow flexion and forearm pronation contractures, 27% have radial head dislocation.¹⁸ This association seems to suggest that the flexion contracture combined with the pronation contracture causes the dislocation. Most of these dislocations are posterior, which is also the position into which the radial head would move with elbow flexion.

Natural History

In middle childhood, the radial head starts to migrate posteriorly and laterally as the pronation and flexion contracture increase. There is a time when

the elbow may develop pain as the radial head dislocates and then reduces again. Most children develop a fixed dislocation rather quickly and no more pain is noted. For a few children, this pain is increasing and parents may want to have the problem treated. As the radial head becomes dislocated, both the contracture and the radial head dislocation usually limit elbow extension and forearm supination. As children continue to grow, the radial head may become very prominent on the posterolateral aspect of the elbow. During late adolescence or young adulthood, the prominence of the radial head may lead to skin breakdown from rubbing on wheelchair trays. Also, in individuals who have functional use of the elbow, pain from degenerative arthritis may develop.

Treatment

Most children with radial head dislocations do not need active treatment. Early recognition and preventive treatment directed at splinting and early contracture release has been recommended as a way to prevent radial head dislocations.²² However, we have not found this to be a useful approach and there are presently no objective data to support early intervention. Although radial head dislocation is a common problem in children with CP, there are only a few reports that mostly focus on reporting that the deformity exists.^{20–22} This is reflected in practice because few caretakers or children complain of pain or disability from this problem. If children do have pain that is persistent and parents wish to pursue intervention, surgical stabilization is the only option. The surgical procedure requires release of the elbow flexors and pronation contracture, followed by stabilizing the radial humeral joint by reconstruction of the annular ligament, usually using the transected biceps tendon. The indication for this procedure in children with passively reducible radial head dislocations is not clear (Case 8.3). The outcome of this procedure is usually a fixed dislocated radial head that is pain free. Fixed dislocations in childhood CP are best left untreated, as they are seldom painful. Pain, if it develops, occurs in adolescents or young adults. At this time, the best option is radial head excision. Excision may also be occasionally indicated for adolescents with very prominent radial heads that cause skin breakdown (Case 8.4).

Complications of Treatment

Surgical reconstruction in children with severe spasticity has led to a 66% (four of six) rate of repeat dislocations. These dislocations did not cause pain; therefore, if the surgery was done for pain relief, it would be successful but maintaining a reduced radial head was not successful. Radial head excisions have been successful in decreasing pain and removing the lateral mass. Radial head excision is not recommended before completion of growth because of fear of radial overgrowth proximally and of proximal migration of the radius causing increased problems at the radioulnar joint at the wrist.

Forearm Pronation

Pronation contracture is a very common deformity in both quadriplegia and hemiplegia (Figure 8.5). The primary deforming muscle is the two-joint pronator teres. At the later stage, the one-joint muscle, pronator quadratus, may become contracted. The pronation contracture is almost always combined with a significant flexion contracture caused by the biceps, which is the strongest supinator. Therefore, the typical release or lengthening of the biceps to treat the flexion contracture also weakens the forearm supination.



Case 8.3 Shakoor

The mother of Shakoor, a 6-year-old boy with severe quadriplegia, complained that he cried when she put his arm in a shirt sleeve. She also reported feeling a click when she moved his arm. Shakoor was a dependent sitter with no functional use of the upper extremity. On physical examination the right radial head could be palpated in an anterolateral dislocated position. With forearm supination and flexion, the radial head reduced easily but seemed to cause him discomfort. When the arm was pronated and extended, the radial head again dislocated, which again caused the child some discomfort. Radiographs confirmed the physical examination (Figure C8.3.1). An operative reconstruction was performed, which transected the biceps tendon at the musculotendinous junction and used this tendon as the material to form an annulus ligament. The elbow was immobilized for 4 weeks, and 3 months later the radial head was dislocated in a fixed position but without pain. The mother was happy with the result (Figure C8.3.2). Another similar case had a reconstruction with an ulnar osteotomy, be-

cause there was always some bowing deformity in the ulna as part of the deformity (Figure C8.3.3). This, too, went to a fixed dislocation within 3 months postoperatively but again was pain free (Figure C8.3.4). Another example (Figure C8.3.5) was a case in which the radial capitellar joint was fixed with a pin for 6 weeks (Figure C8.3.6); however, this led to a dislocation of the ulna trochlea joint and severe elbow stiffness (Figure C8.3.7).

As demonstrated in these cases, we do not have a good operative solution for the spastic radial head dislocation, which is the reason we favor decreasing activity and allowing the dislocation to become fixed, then the pain will resolve. Such an example is a 6-year-old boy who presented with almost the same history as above, whose mother was instructed to avoid activities that caused pain and was not to try to splint or otherwise position the arm in a position to prevent the radial head dislocation (Figure C8.3.8). After a 4-year follow-up, the radial head was in a fixed dislocation with substantial radial head remodeling, and the elbow was pain free (Figures C8.3.9, C8.3.10).

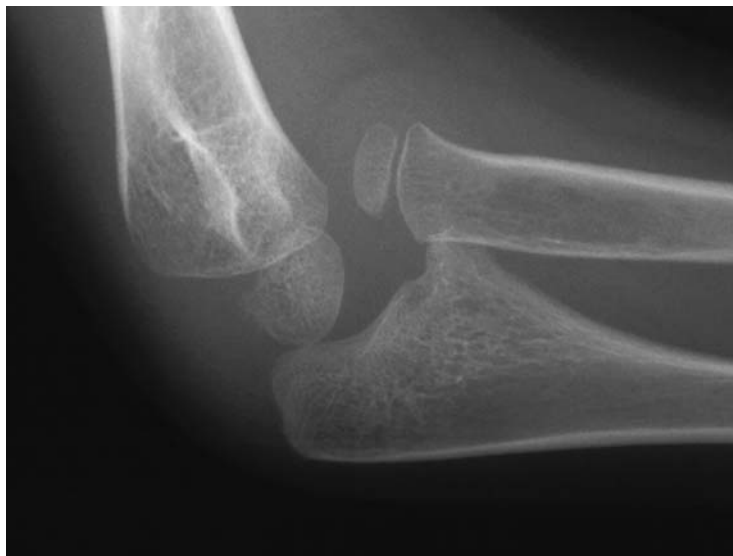

Figure C8.3.1

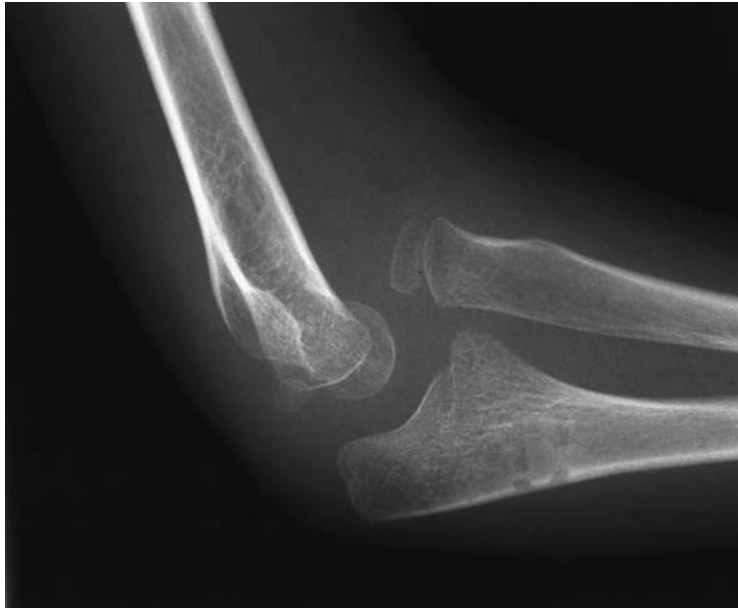

Figure C8.3.2

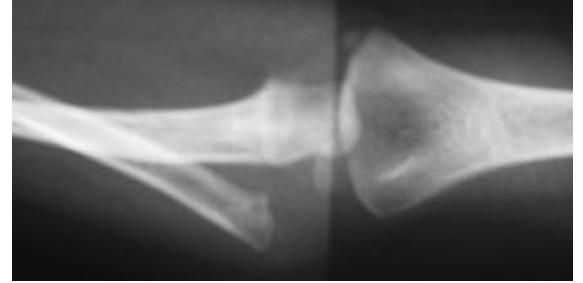


Figure C8.3.3

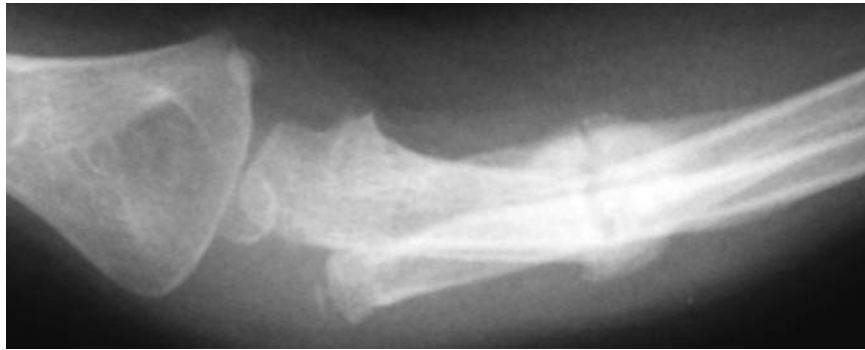

Figure C8.3.4

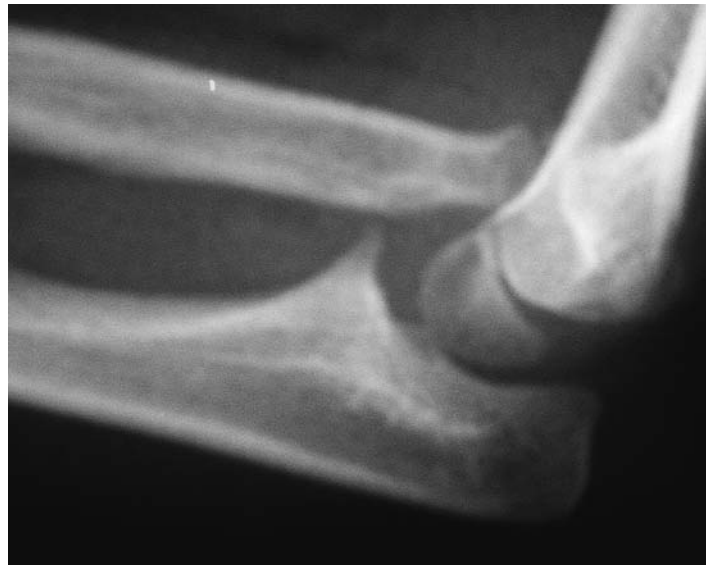

Figure C8.3.5

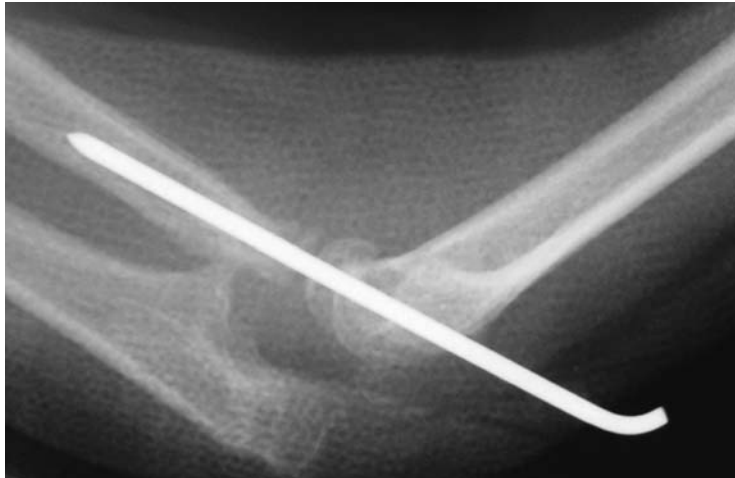


Figure C8.3.6

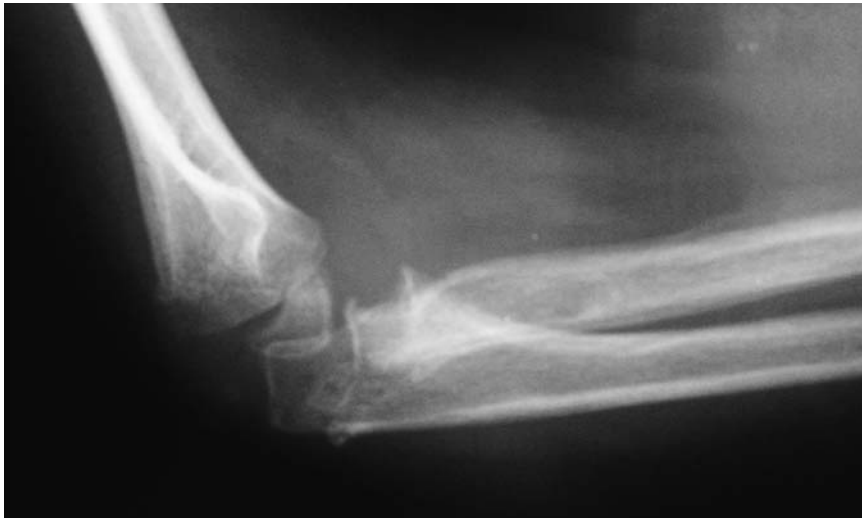

Figure C8.3.7

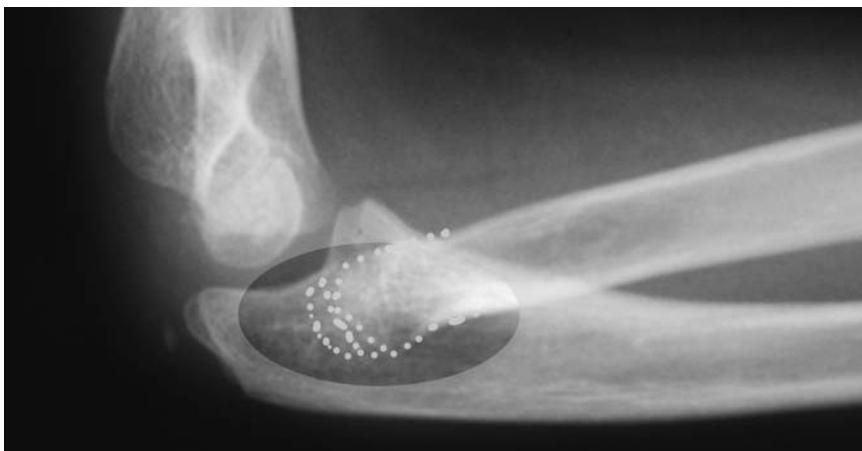

Figure C8.3.8

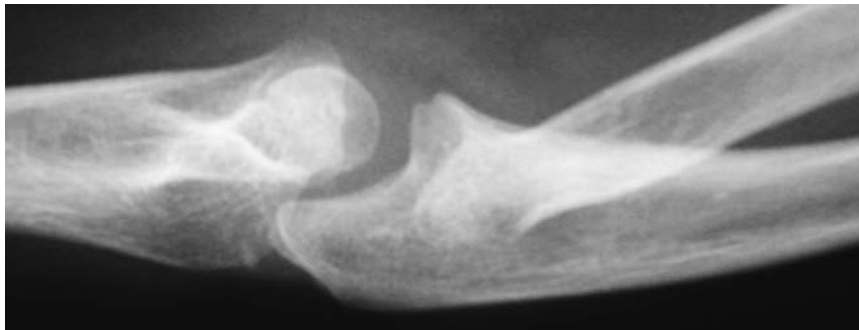


Figure C8.3.9



Figure C8.3.10



Case 8.4 Corey

The mother of Corey, a 17-year-old boy with quadriplegia who had some limited use of his upper extremities, complained that he seemed uncomfortable with the extension of the elbows. His mother was especially concerned because he was hitting his elbow against the back of the wheelchair or walls, and getting skin breakdown over the lateral elbow, where he had a prominence from his dislocated radial head (Figure C8.4.1). Physical examination demonstrated mild tenderness with passive elbow extension, which was limited by a 35° fixed flexion contracture. Radiographs of the elbow demonstrated the dislocated radial heads (Figures C8.4.2, C8.4.3). After radial head excision, his elbow flexion contracture was unchanged, but he no longer had pain and the skin breakdown stopped. Radial head excision gives excellent symptomatic relief, although no change in function should be expected.

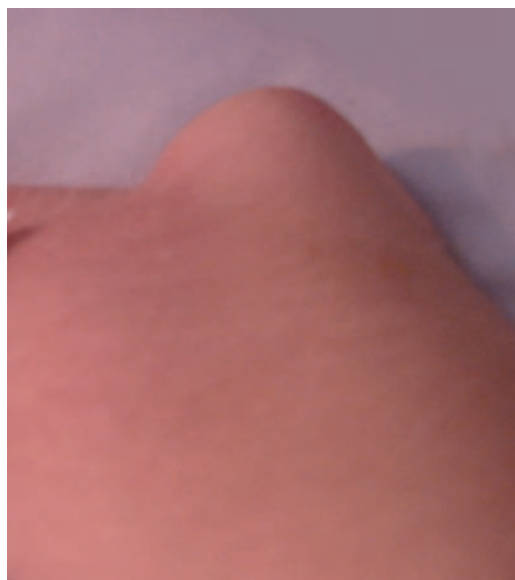

Figure C8.4.1

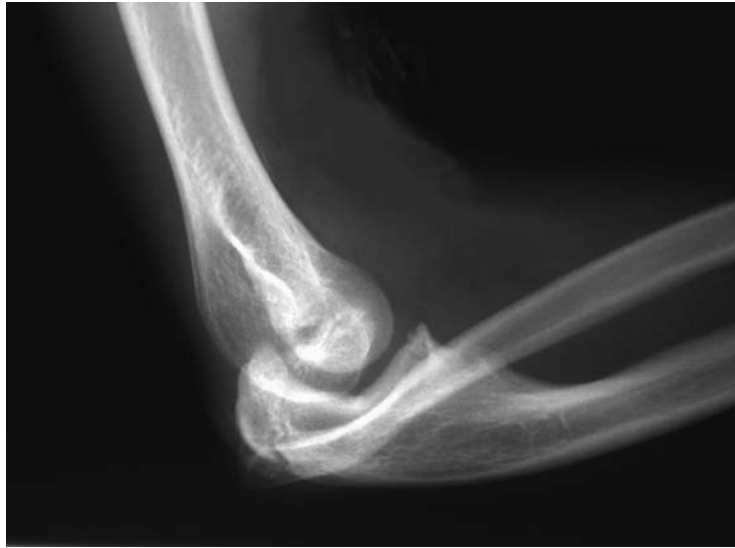

Figure C8.4.2

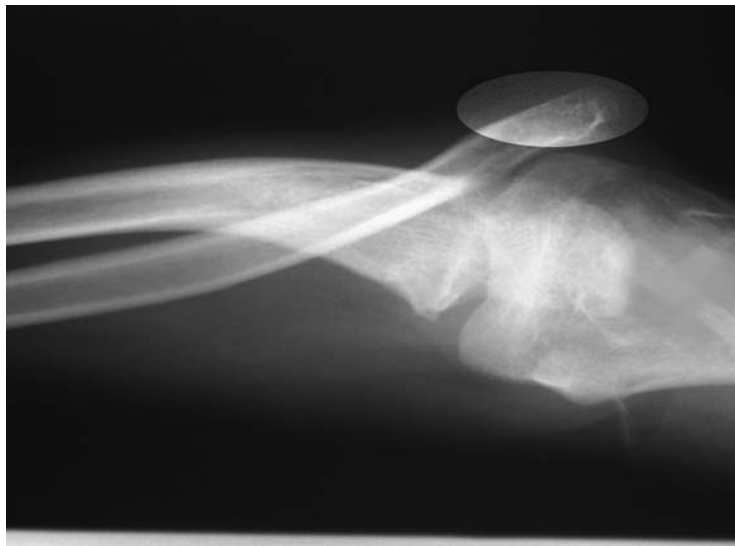

Figure C8.4.3

Natural History

The natural history is for the pronation contracture to get worse during growth. For most individuals with hemiplegia, the pronation is a cosmetic deformity that causes functional disability by placing the palm out of sight. Some degree of pronation contracture is almost always present in children with spasticity of the upper extremity. The deformity aggravates the wrist flexion deformity and when it is severe, patients have a reverse grasp posture. The deformity can also cause difficulty grasping on to handholds of walkers in patients who require assistive devices for walking. Because most hemiplegic limbs have reduced sensation, the use of the hand as a helper requires visual feedback for individuals to know what is in the hand. By decreasing the pronation and allowing the palm to be seen, the hand can be used to hold objects in a more functional manner.



Figure 8.5. The most typical posture of the hemiplegic upper extremity is elbow flexion, forearm pronation, wrist flexion, thumb adduction, and finger extension. Finger flexion contractures usually underlie the extended finger when the wrist is brought to the neutral position. All these individual deformities need to be closely evaluated and each needs to be corrected if the deformity is present when doing a reconstruction of a spastic upper extremity.

Treatment

Pronation deformity of the forearm is almost impossible to effectively splint unless a full upper extremity orthosis with the elbow flexed to 90° is used. This type of orthotic is so large that it has severe functional implications; therefore, pronation orthotics are seldom used. Usually, the pronation contracture is treated only in the context of an upper extremity reconstruction in which the pronation contracture is recognized as one of many problems. Correction of the pronation contracture should be performed in combination with procedures to correct the wrist and finger deformities to optimize placement of the hand. The goal of treatment is to reduce the pronation deformity; however, this should not lead to a fixed supination position. A position between neutral and 30° of pronation is best with active supination to 45° . Surgical treatment is indicated when individuals lack the ability to actively supinate at least 20° to 30° .

Many surgical options have been described, and the data on each procedure do not give each a clear advantage. Release of the pronator tendon from the insertion on the radius removes the primary deforming force. This procedure works well over a wide group of individuals, is the simplest procedure, and has the least complications. Transfer of the distal insertion of the pronator from the dorsal insertion on the radius to wrapping the tendon around the volar aspect of the radius and making it a supinator has been reported to increase the amount of active supination compared with a release only.^{23, 24} Another option is to transfer the distal end of the pronator into the extensor carpi radialis to provide wrist extension and decrease pronation.²⁵⁻²⁷ This procedure probably provides the least pronator weakening and has the advantage of assisting wrist extension. This is a reasonable option if there is a mild supination or pronation deformity with tendency for dynamic wrist flexion; however, there are few children who fit this mild level of involvement and still need surgery. Another option is the proximal pronator flexor slide at the muscle origin. We have found very little indication to do proximal pronator flexor slides in children with good function. We have rarely utilized a proximal pronator flexor slide; it has been used in a child with residual head injury and in a child with severe quadriplegia.

For severe deformities with fixed pronation contractures, a myotomy of the pronator quadratus may need to be added. These children often have a contracture of the interosseous ligament as well, which may need to be stretched out by casting or even cross-fixed with a K-wire.

Outcome of Treatment

Sakellarides and associates found 82% of their patients had good to excellent results with an average of 46° of active supination.²³ They did have radius fractures as a complication. Strecker et al. modified this technique by only utilizing a larger unicortical hole with a smaller drillhole to pass suture through and around the radius.²⁴ When comparing pronator release with rerouting, they found the latter group to have improved supination.

Complications of Treatment

The worst complication of pronation contracture treatment is overcorrection and development of significant supination deformity. The supination is much more cosmetically objectionable and more functionally debilitating than an equal pronation deformity. If overcorrection occurs and a pronator transfer has been performed, the transferred tendon has to be released. If a transfer of the flexor carpi ulnaris was performed around the lateral ulna and this muscle is tight, causing the supination, the muscle should be released. If the biceps muscle is spastic or contracted and it was not released at the first procedure, it may also be the cause of the overcorrection.

One technique for transferring the tendon around the opposite side of the radius requires drilling a bicortical hole in the distal radius to place a suture to attach the tendon. This drillhole may become the stress riser for a fracture. If a fracture develops, it has to be treated in the standard method, usually with internal fixation using a plate. This complication can be avoided or reduced by using only a small unicortical hole into which a stay suture device is placed, or the tendon can be sutured to the periosteum instead of the bone.

Wrist

Wrist Flexion Deformity

Wrist flexion is a very common deformity in older individuals with spasticity of the upper extremity. In most individuals, the wrist is in flexion and ulnar deviation is caused by overpull and contracture of the wrist flexors. In most wrists, the flexor carpi ulnaris is the primary and most contracted muscle, followed by the flexor carpi radialis, and then the finger flexors. Because the forearm is usually in pronation, gravity also helps to cause the wrist to drop. As the wrist flexes, the extensor tendons of the fingers are put under tension and the finger flexors are relaxed; therefore, the fingers are usually in some extension, although this is variable. The strength and power of grasp in wrist flexion is very weak, so whatever limited hand motor function was present in children tends to be made worse with the poor hand position.

As the wrist flexion deformity increases, the wrist joint tends to collapse and cause subluxation of the intercarpal joints. In some individuals with severe spasticity, the wrist comes to rest against the volar aspect of the forearm and the wrist flexion crease is very hard to keep clean, causing a foul odor to develop.

Natural History

In young children under 3 years of age, the wrist is most commonly in the fisted position with the thumb in the palm under the flexed fingers. As neurologic development occurs, the wrist drops into flexion, allowing the fingers to open and become more functional. For children who are crawling on the floor, weight bearing on the upper extremity may start with dorsal weight bearing, then for some as the finger flexors relax, palmar weight bearing starts. As children enter middle childhood, the predominant flexed wrist position is established but is usually without fixed flexion contractures. In children with hemiplegia, the wrist flexion remains supple and functional gains may continue to be made into part of middle childhood. As children with hemiplegia enter adolescence, the contractures tend to become more fixed, although many will continue to have a primarily dynamic deformity. In middle childhood and into adolescence, the functional gains can continue in individuals with quadriplegic involvement. Also, as the severity of the spasticity increases, the rate of fixed contracture development increases.

Diagnostic Evaluations

Hoffer et al. recommend the use of careful physical examination and dynamic EMGs to distinguish two patterns: primary difficulty with grasp and primary difficulty with release.¹ Tendon transfer of the wrist flexors is favored over lengthening alone, and these patterns tend to exist. We have relied on the physical examination to separate out the patterns of wrist deformity (see Figure 8.2). These patterns generally follow a pattern of severity of neurologic involvement in the children.

Mild Wrist Flexion Deformity

In a few individuals with hemiplegia, there is a very mild dynamic wrist flexion and forearm pronation present with no fixed contractures. When children are not aware of the extremity position, the wrist tends to be in flexion and when they use the hand, it tends to be predominantly in flexion and pronation. These children have full independent active control of the hand and wrist function. This extremity is classified as a type 5 extremity.

Moderate Wrist Flexion Deformity

The next level of involvement is those individuals with some fixed flexion contracture of the wrist but good active finger extension with the wrist held passively extended. These extremities fall into type 4 on the classification scale.

Severe Wrist Flexion Deformity

At the next level, types 2 and 3 are those individuals who cannot actively extend their fingers with the wrist passively extended to neutral to 20° of extension. This group has two subgroups. The first subgroup includes those with contracted finger flexors such that the fingers cannot be passively extended with the wrist passively extended. The second subgroup has the ability to get passive finger extension with the wrist held passively in extension. This subgroup has finger extensor deficiency without finger flexor contracture.

Very Severe Wrist Flexion Deformity

The last group is predominantly types 0 and 1, and they have severe fixed wrist flexion contractures getting a maximum of -20° of wrist extension. These individuals have minimal function in the hand.

Wrist Extension Contracture

Although rare, wrist extension contractures may be seen in children with CP. These contractures are usually in individuals with very limited function of the hand. Often, the wrist extension contracture is a sign that this is a concomitant spinal cord injury and CP. On rare occasions, children may not have CP but only a spinal cord injury that has been misdiagnosed. Spinal cord injuries occurring during the birthing process are usually diffuse stretching injuries with high-level involvement and may be difficult to separate from cerebral origin encephalopathy.


Treatment

The use of splints, passive range of motion, and botulinum toxin have all been reported and are widely used, especially for young children with dynamic deformities.²⁸ There is no documentation of any long-term benefit from these treatments, especially with botulinum where marginal short-term gain has been reported.^{4, 16, 17}

Indications for surgical treatment of mild flexion deformities are often based on cosmetic concerns and the goal of improving grasp. A simple and easy treatment of a mild deformity is the transfer of the pronator teres to the extensor carpi radialis brevis if the wrist has no tendency for ulnar deviation. If there is a tendency for ulnar deviation, transfer can be to the extensor carpi radialis longus. Pronation should not be a major part of the deformity.

Extremities with moderate involvement are ideal candidates for transfer of the flexor carpi ulnaris to the extensor carpi radialis brevis, which is also called the Green transfer. This transfer decreases the wrist flexor power, and augments wrist extensor power and forearm supination. This forearm transfer is usually combined with release or transfer of the pronator teres. The flexor carpi ulnaris is attached to tension the wrist at 10° to 30° of extension as a passive wrist position on the operating room table (Case 8.5). Extreme dorsiflexion should be avoided because it may cause the opposite deformity and difficulty with releasing objects as many of these patients use tenodesis of the wrist in flexion to aid in finger extension for release of objects (Case 8.6). The wrist is casted at 20° extension for 4 to 6 weeks. After cast removal, nighttime splinting is continued for 6 months. The addition of a daytime function splint to allow for grasp and release is added if wrist extensors are believed to be too weak. Aggressive therapy is begun to retrain gross motor function and regain strength.

Wrists with severe deformities require the Green transfer but with additional lengthening of the finger flexors if finger flexor contractures are present. After the release of the flexor carpi ulnaris, the finger flexors are lengthened using group Z-lengthening or myofascial lengthening. If the wrist still



Case 8.5 Cambria

Cambria, a 9-year-old girl with right hemiplegia, presented with a concern about the appearance of her arm. She felt other children noticed the arm and some children had called her crippled. The mother was concerned

because Cambria used the arm very little and only for activities where she definitely had to use two hands. Cambria was in a regular fourth grade class and was completely age-appropriately independent in all activities,

except she could not tie her own shoes. On physical examination, her elbow flexion lacked 10° to full extension, supination lacked 20° to full supination, wrist flexion and extension was full, and thumb abduction was full. On attempted active finger extension, her wrist flexed to 30° . With the wrist held passively at 30° of dorsiflexion, she could extend her fingers fully at the proximal interphalangeal and distal interphalangeal joints, but lacked 40° of extension at the metacarpal phalangeal joints. When she was observed standing, her elbow was flexed 60° , the forearm was pronated, the wrist flexed, the thumb was adducted, and the fingers were midpoint between flexion and extension. She had a myofascial lengthening of the biceps at the elbow, distal release of the pronator teres, and a transfer around the ulnar border of the flexor carpi ulnaris to the extensor carpi radialis brevis. A midsubstance myotomy of the adductor pollicis was performed in the palm. Thumb abduction was augmented with a transfer of the palmaris longus. At the conclusion of the procedure the hand remains in the ideal position with 20° of wrist dorsiflexion (Figure C8.5.1). The fingers are in a position of comfort and the thumb rests in mild abduction (Figure C8.5.2). She was placed in a long arm cast in 80°

of elbow flexion, full supination, 30° of wrist dorsiflexion, thumb in full abduction at the metacarpal carpal joint, and mild flexion at the metacarpal and interphalangeal joints. The fingers were in 30° of flexion at the metacarpal and interphalangeal joints. After 4 weeks, she was removed from the cast and therapy was started three times a week to focus on joint range of motion, with the only limitation being that there was no passive wrist flexion stretching. She was to wear a wrist extension splint that held her wrist in 20° to 30° of extension full time, except during bathing, for 6 more weeks to protect the transferred tendon. After 6 weeks, the splint was removed except for nighttime wear, which was to be used for 6 months. Functional activities in therapy focused on activities of daily living, and teaching her how to tie her shoes using a one-handed technique. After 1 year, Cambria and her mother were again evaluated and she was very happy with the outcome because she felt her arm now looked nearly normal. Her mother, however, was unhappy because she said Cambria, in spite of the surgery and extensive therapy, still did not use her hand any more than before. She notes that although she had learned to tie her shoes, she only used one hand.

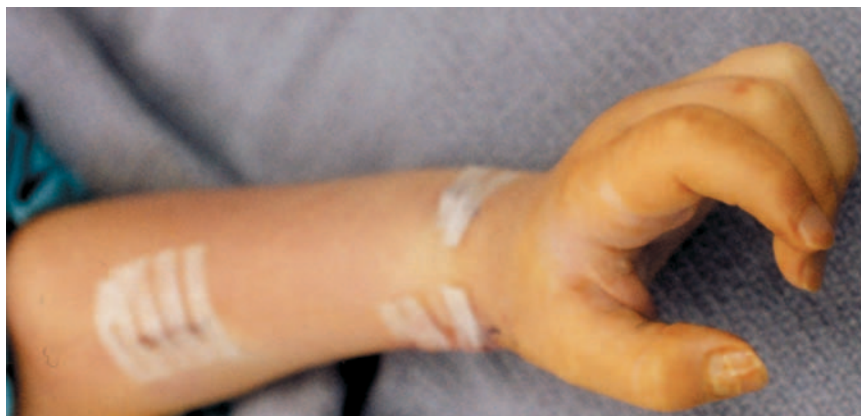

Figure C8.5.1

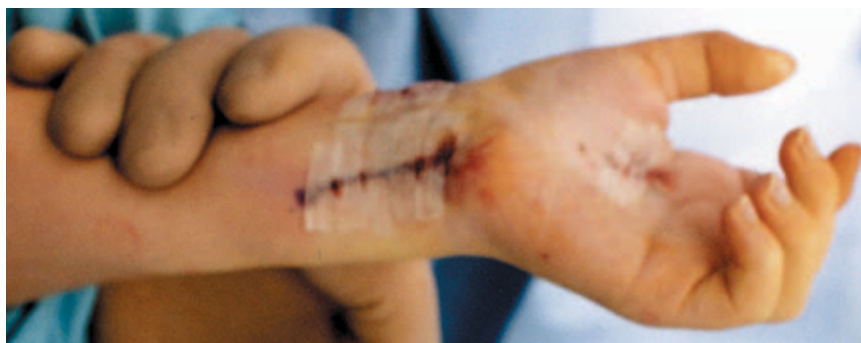

Figure C8.5.2



Case 8.6 Stacy

Stacy, an 18-year-girl with hemiplegia, complained of wrist extension that was bothering her because of the cosmetic concern. She was also having some difficulty getting her arm into shirt sleeves, especially if the sleeves were a little tight. The transferred tendon had become prominent (Figure C8.6.1). She had graduated from high school and wanted to have something done before she started college in 2 months. On physical examination she had 50° of dorsiflexion at rest and with maximum active wrist flexion, could only get to -30° of wrist flexion. On passive stretching, she could get to almost 0° wrist flexion. She

was otherwise happy with her extremity surgery, which had been done 6 years prior. A complete release of the transferred flexor carpi ulnaris was performed on the dorsolateral side of the wrist. She was started on active wrist flexion stretching exercises immediately, and by the time she went to college, the rest wrist position was at 30° to 40° extension, and maximum passive wrist flexion was to 10° wrist flexion. On follow-up 1 year later, there was no significant change from the 3-month postoperative visit and she was happy with the result.

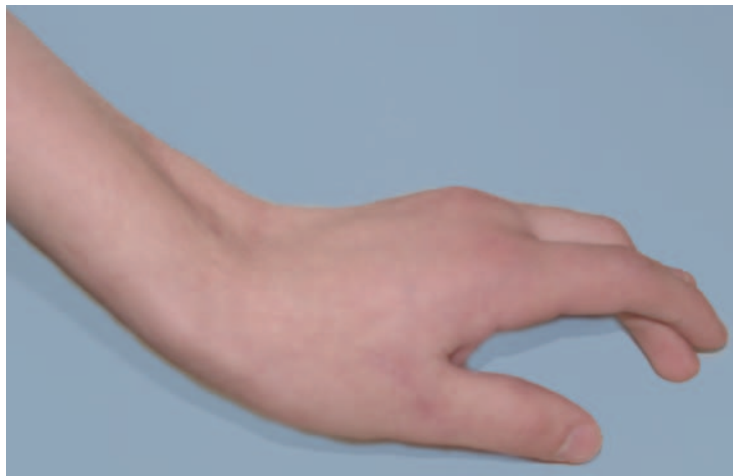

Figure C8.6.1

does not extend passively to 20° or 30°, a Z-lengthening of the flexor carpi radialis is performed. If finger flexors or flexor carpi radialis are lengthened, the flexor carpi ulnaris is transferred into the extensor carpi radialis brevis if there is minimal residual ulnar deviation. Transfer of the flexor carpi ulnaris to the extensor carpi radialis longus allows for wrist extension in a more radial direction. If there is a significant ulnar deviation deformity, lengthening of the extensor carpi ulnaris should also be performed.

For severe wrist deformity with minimal finger flexor contractures but no active finger extension, transfer of the flexor carpi ulnaris should be into the extensor digitorum communis. Wrist flexion is then augmented by plication of the radial wrist extensors or by adding a transfer of the pronator teres to the extensor carpi radialis brevis. This procedure is only indicated for individuals with active finger flexion when the wrist and fingers are passively held in an extended position. The same postoperative routine is used as for the flexor carpi ulnaris transfer alone. Fingers are always included in the cast with 30° to 40° of flexion of the interphalangeal and metacarpal phalangeal joints.

For individuals with very severe wrist deformities, the indications for treatment are usually due to problems with custodial care, such as having problems getting arms in shirt sleeves and problems keeping the wrist flexion crease clean. The primary treatment for these deformities is wrist fusion by shortening the wrist. The shortening is provided by excision of the carpal bones, usually the proximal row, but in some severe cases all the carpal bones are removed, and the distal metacarpals are fused to the radius. Internal fixation of the wrist is provided with crossed K-wires or a dorsal plate (Case 8.7). The use of a small external fixator has been reported,²⁹ but this seems to be overly invasive for severely neurologically involved individuals



Case 8.7 Julian

Julian, a 15-year-old boy with severe quadriplegia, presented with the mother's complaint that she had difficulty in keeping the wrist and hand clean, especially in the summer when the hand would sweat and develop a very foul odor (Figure C8.7.1). Neither of the upper extremities had any useful function. On physical examination the elbow had 70° flexion contracture, the forearm could not be rotated to neutral, the wrist lacked 40° in coming to neutral extension, and in this position, the fingers were flexed and could not be extended. The thumb was extended but adducted with a narrow web space. A tenotomy of the

biceps and brachialis was performed at the elbow. The pronator tendon was released by distal tenotomy. Proximal row carpectomy and wrist joint resection allowed correction of the wrist deformity, which was then fused using a plate for stabilization (Figures C8.7.2, C8.7.3). The finger flexors had myofascial lengthening in the forearm and the finger extensor tendons were plicated. A myotomy of the adductor pollicis and the first dorsal interosseous muscles was performed. After healing, the position of the limb looked good.

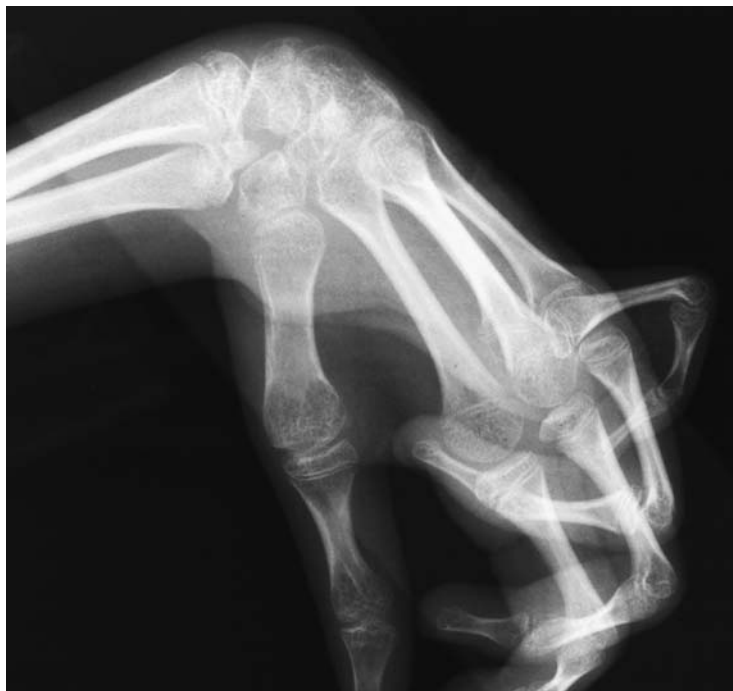

Figure C8.7.1

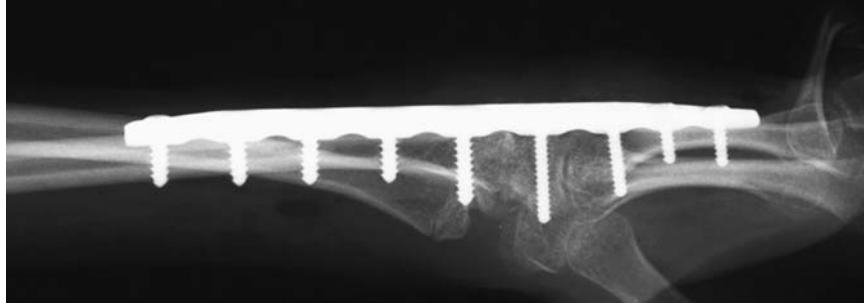


Figure C8.7.2

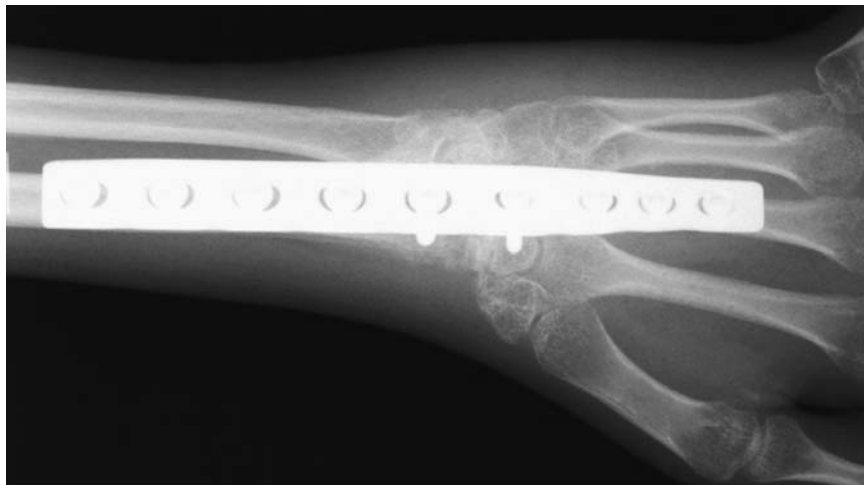

Figure C8.7.3

who are candidates for wrist fusion. In our experience, bony fusion seems less important than adequate decompression and lengthening of the spastic finger flexors to prevent later finger clawing. Immobilization is in a cast for 8 to 10 weeks. Postoperative therapy is less important than with tendon transfer cases.

Wrist extension contractures seldom become severe enough to need treatment unless they are the result of the overcorrection of a wrist flexion treatment. If there is a significant wrist extension with poor wrist flexor strength, this extension is much more likely to come from the residual imbalance of an incomplete spinal cord injury.

Outcome of Treatment

The outcome of pronator transfer has been reported as good.^{26, 27} We have very little experience with this procedure as it is seldom indicated based on our criteria. Most individuals receive the reliable Green type transfer. In general, excellent improvement in cosmesis in 88% to 100% of functional children with hemiplegia is reported.^{30, 31} The arc of wrist motion does not improve according to most reviews,^{30, 31} although one report suggests otherwise.³² However, wrist extension does improve 9° on average.³¹ Functional gains occur in approximately 75% of patients.^{30–33} These reports are very similar to our results in which the improvement in cosmesis is good, especially from the perspective of the children. There is often less functional gain than was desired, especially from the parents' perspective; however, the re-

sults are related to the severity of the deformity. As more finger flexor lengthenings and flexor carpi radialis lengthenings are required, the procedure is less reliable. Also, athetosis has been shown to lead to unpredictable outcomes with a high rate of severe overcorrection.³⁴

The outcome of wrist fusion has been reported to be improved appearance, ease of dressing, and personal hygiene. Even improved function was reported in eight of nine fusions.³⁵ Another recent report showed that 83% of children had some functional gain from fusion and almost all caretakers were happy with the cosmetic result and the improvement in hygiene.³⁶ The outcome of wrist fusion is good when it is used in severe deformities; however, this should not imply that this is a useful procedure for moderately involved hemiplegic extremities. Fusions in these limbs in our experience cause significant limitations because wrist motion can now no longer be used to augment finger flexion and extension. Although the wrist cosmetically looks good, many of these patients lose functional abilities.

Other Treatment

Because wrist flexion is a very visible and common deformity in CP, many different treatment options have been advocated in addition to the treatment protocol recommended above. Proximal carpectomy without an attempt at fusion has been recommended combined with muscle transfers and lengthenings.³⁷ This is a reasonable option and can be used instead of a fusion; however, there is a slightly higher rate of loss of position if the muscle balance is not good (Case 8.8). Transfer of the brachioradialis has been suggested as an augmentation to flexor carpi ulnaris transfer in some children.³⁸ We have no experience with this procedure; however, the brachioradialis has poor excursion, which makes this a poor muscle for transfer where excursion is needed. Neurectomy of the motor nerves to the forearm is possible³⁹; however, this essentially leaves no function or the spasticity will return if only a minimal neurectomy was performed. In some ways, neurectomy is close to the proximal flexor muscle insertion slide, which is an old operation most recently reviewed in 1972.⁴⁰ Although this procedure does reduce flexor strength, often little function remains. The procedure is seldomly used today except in extremities with minimal function, and even then, selective distal tendon lengthening is easier. Correction of severe wrist flexion with an external fixator can be done⁴¹; however, this seems to be a very difficult approach to a problem that can be much more simply addressed with bone resection and wrist fusion.

Complications of Treatment

There are primarily two complications in wrist flexion surgery: one is overcorrection and the other is undercorrection. Overcorrection occurs from inserting the transfer tendon, usually the flexor carpi ulnaris, with too much tension or there is too much lengthening and weakening of the finger flexors and flexor carpi radialis. Usually, the overcorrection is not apparent immediately but occurs over the next several years following the procedure. This procedure is in a way like treating crouched gait, in which there are strong attractors to cause a wrist flexion deformity; however, if there is some overcorrection, the extension contracture attractor is also strong. There are some individuals in whom this balance is very difficult to obtain. The ideal goal is 20° to 30° of wrist extension with the hand relaxed at the child's side. Slight undercorrection with flexion from 10° wrist flexion to 20° extension is the preferred direction of error. Mild overcorrection up to 45° extension is the next level of deformity. In most children, if the wrist falls past 20° of flexion, it will again continue into severe flexion. This is less cosmetically



Case 8.8 Taylor

Taylor, a 16-year-old girl with severe quadriplegia, presented from a residential facility with her caretakers, who complained that it was very difficult to keep the hand clean and it was very hard to place the arm in shirt sleeves. Taylor was completely dependent in all activities of daily living. On physical examination the wrist was flexed at 100° and maximum extension was -60° . The fingers were in the open position (Figures C8.8.1, C8.8.2). A proximal row carpectomy with fixation using crossed Kirshner wires was performed (Figure C8.8.3). The finger flexor had myofascial lengthening and the finger extensors were plicated. The result at the 1-year follow-up time was a wrist with only slight motion resting in 20° of flexion (Figures C8.8.4, C8.8.5, C8.8.6). The caretakers felt the problems that they were concerned about were corrected and they were happy with the outcome.

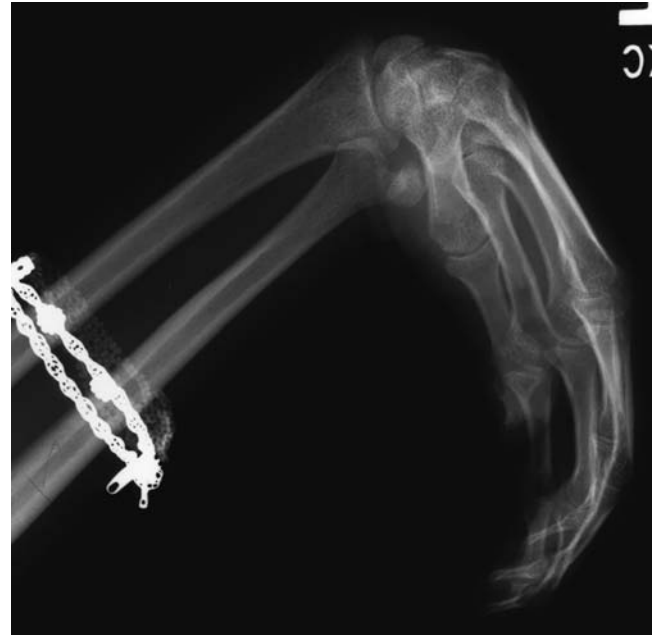

Figure C8.8.2



Figure C8.8.1

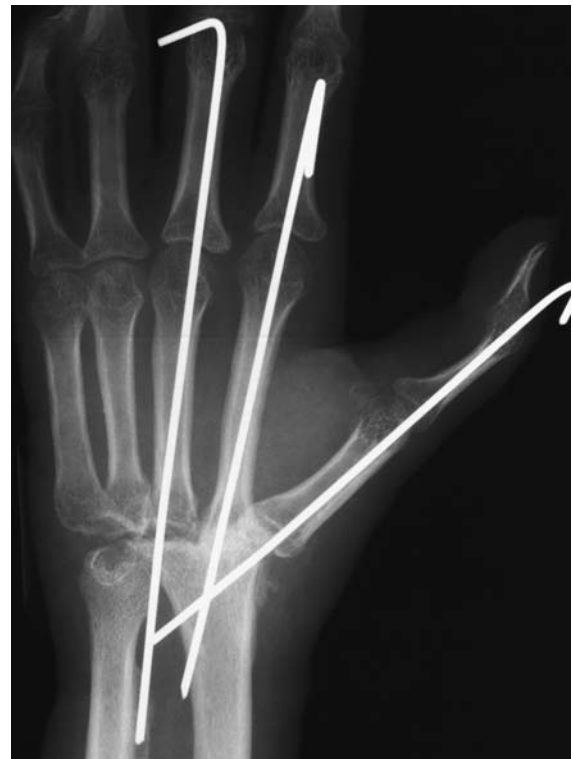

Figure C8.8.3

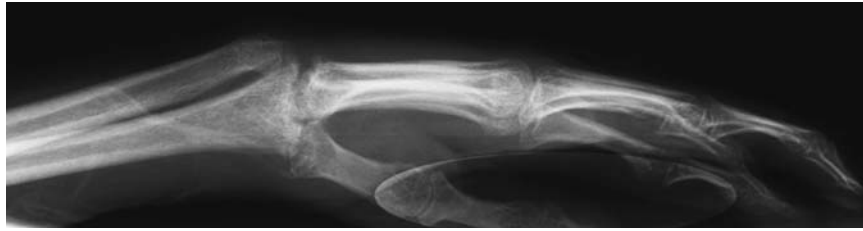

Figure C8.8.4

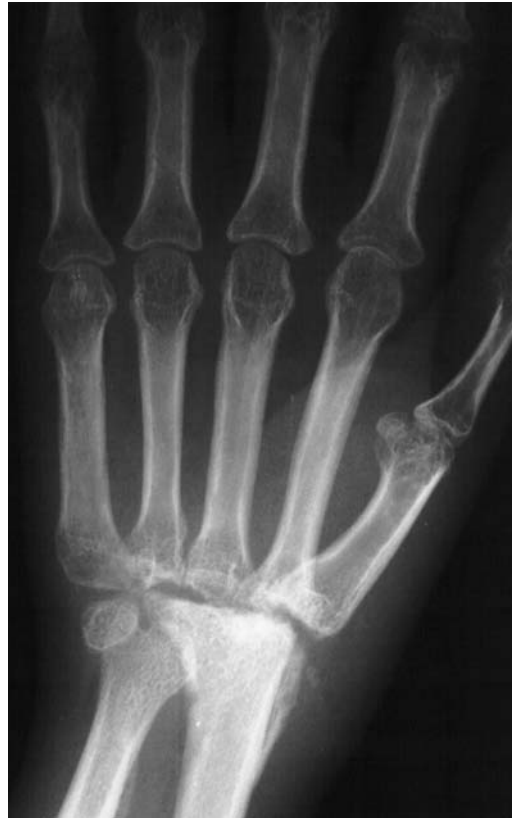

Figure C8.8.5

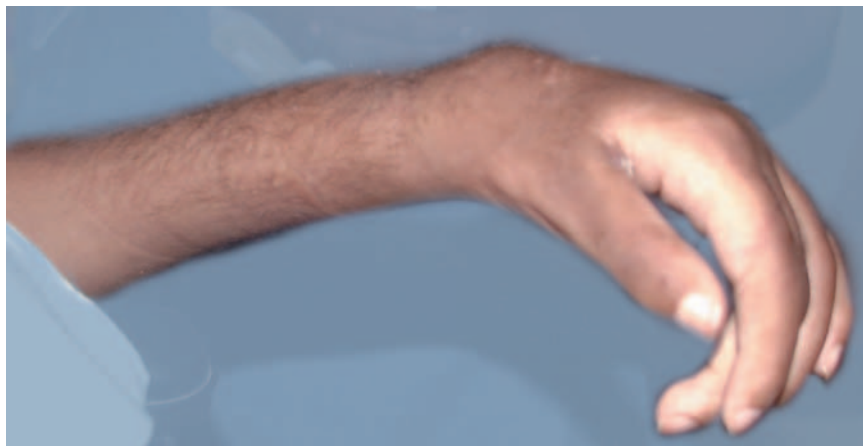

Figure C8.8.6

noticeable and functionally better than severe extension of more than 60°. If wrist extension starts to go over 45°, it tends to get worse, and if individuals are bothered by this, release of the transferred tendon should be performed before the extension gets worse (Case 8.6). This release usually stops the increasing extension and improves the wrist position without a complete reversal into flexion. If increased flexion deformity gets severe enough so that further correction is indicated and the initial surgery included flexor carpi ulnaris transfer, usually the best salvage is to do a wrist fusion. In our experience, recurrent severe flexion occurs mainly in individuals who already had severe wrist contractures.

Thumb

The thumb-in-palm deformity is the most common thumb deformity seen in children with CP. This deformity is perhaps the most functionally hindering in a patient with CP because the thumb accounts for approximately 50% of hand function. The deformity consists of the thumb being adducted or flexed and adducted. The etiology is spasticity of the adductor pollicis, the flexor pollicis brevis, and the first dorsal interosseous muscle, which overpower the abductor pollicis longus and the extensor pollicis longus and brevis. Occasionally, the flexor pollicis longus is also spastic. Functionally, the hand is impaired due to the thumb obstructing the other fingers from an effective grasp and preventing objects from entering the palm during digital extension. In addition to the thumb-in-palm deformity, thumb adduction with metacarpal phalangeal joint extension is also common. This condition is a collapse of the thumb with interphalangeal joint flexion, metacarpal phalangeal joint extension, and carpal metacarpal flexion and adduction. The etiology of this collapse is overpull of the extensor pollicis brevis with a strong extensor pollicis longus contracting against a strong spastic flexor pollicis longus. Secondary changes at the metacarpal phalangeal joint occur with stretching of the volar plate, allowing progressive hyperextension. Over time, severe degenerative changes occur in the metacarpal phalangeal joint, causing pain.

Natural History

Thumb-in-palm deformity tends to be most severe early in life, usually in the second year. Most children with hemiplegia and moderate quadriplegia will slowly be able to get active control of some aspect of the thumb, allowing some abduction. By 5 years of age, most children will be able to get the thumb out of the palm so it is not always impeding grasp. In early childhood, there is seldom any significant fixed contracture present. In children with severe quadriplegia, the thumb remains in the palm and starts developing fixed contractures in early childhood, often becoming severe and fixed by adolescence. The hemiplegic thumb also develops fixed contractures in middle childhood, especially at adolescence.

Diagnostic Evaluations

Physical examination and history are the primary diagnostic evaluations we use. The use of EMG to define selective control of the adductor has been advocated by Hoffer et al.⁴²; however, it is not widely used and we have no experience with this technique.

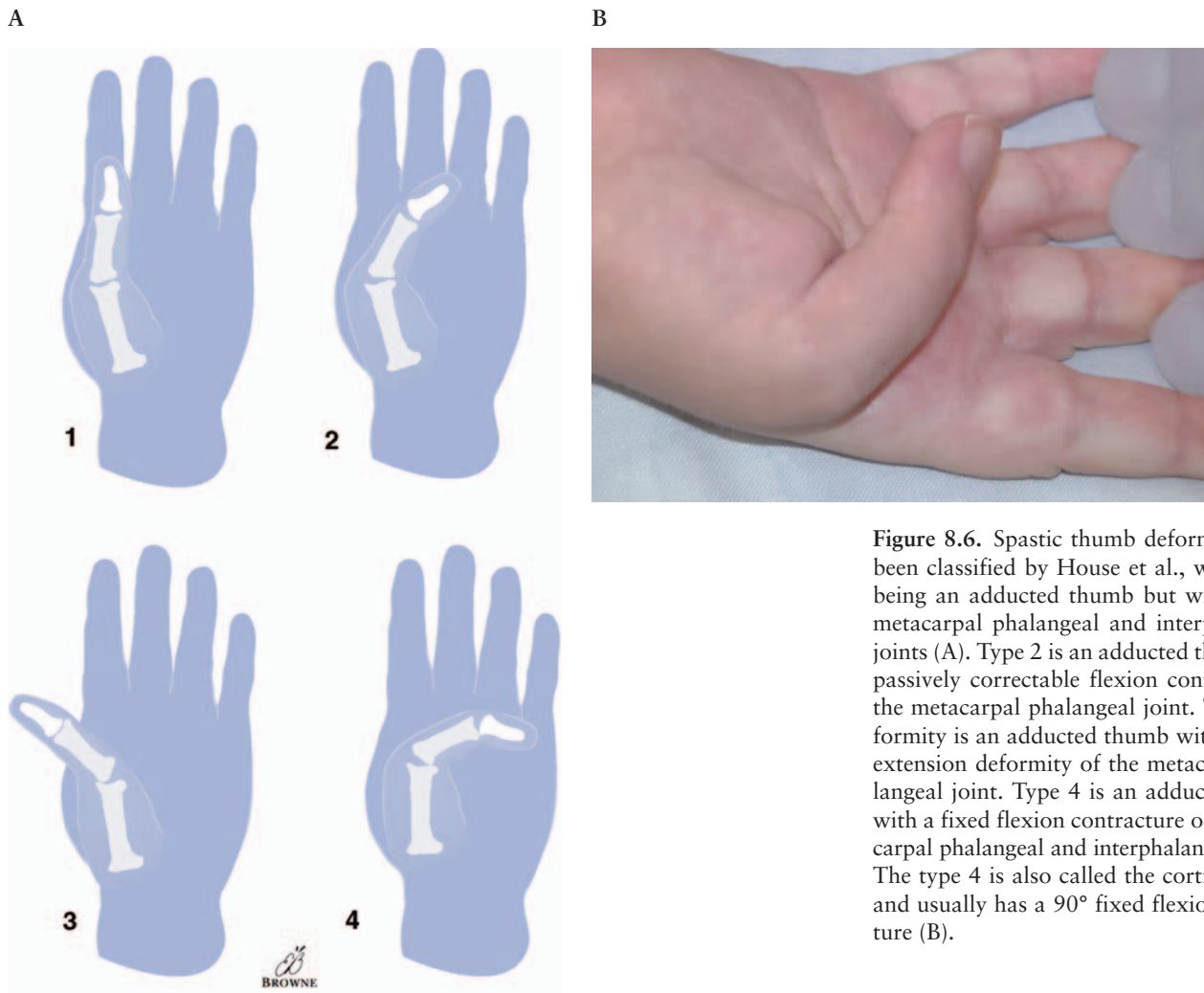


Figure 8.6. Spastic thumb deformities have been classified by House et al., with type 1 being an adducted thumb but with neutral metacarpal phalangeal and interphalangeal joints (A). Type 2 is an adducted thumb with passively correctable flexion contracture at the metacarpal phalangeal joint. Type 3 deformity is an adducted thumb with a hyperextension deformity of the metacarpal phalangeal joint. Type 4 is an adducted thumb with a fixed flexion contracture of the metacarpal phalangeal and interphalangeal joints. The type 4 is also called the cortical thumb and usually has a 90° fixed flexion contracture (B).

Treatment

Several classifications exist to describe different types of thumb deformities.^{43, 44} We have found the House and associates classification inclusive and helpful with treatment,⁴³ and it forms the basis of our approach (Figure 8.6). Although classifications are helpful to determine treatment, a good rule of thumb is that tight muscles should be lengthened, weak muscles should be augmented, and unstable joints should be stabilized.

House Classification

Type 1

In type 1, patients have spasticity of the adductor pollicis and first dorsal interosseous causing adduction of the metacarpal. The thumb extensor and abductor have adequate power and a simple release of the thumb adductor with or without the first dorsal interosseous is sufficient. A technique with partial myotomy^{42, 45} of the transverse fibers preserving the oblique fibers of the adductor pollicis is adequate in patients with active adduction. This technique preserves “key pinch,” which many patients rely on for opposition. A discussion with patients is important because all operations on the thumb are like every other muscle lengthening, meaning the active range of the muscle does not change, but the position where it functions can change.

Complete release of the adductor pollicis may result in loss of key pinch but give the ability to grasp a walker handle better. If individuals want to use their hands to hold a glass, then web space deepening by Z-plasty is required (Case 8.9). For most hands, a simple two-flap Z-plasty provides adequate release, but if more width and depth is desired, a four-flap Z-plasty provides increased room. A simple two-flap Z-plasty increases web space 1 cm, and a four-flap Z-plasty will increase the web space by 50% more.⁴⁶ In patients without active adduction, a traditional complete release of the adductor from the third metacarpal and the first dorsal interosseous from the first metacarpal provides easier positioning of the thumb.

Type 2

In type 2, the metacarpal is adducted as in type 1 patients and the metacarpophalangeal joint is flexed. There is full passive range of motion of the thumb joints except for the adduction contracture. These patients have weakness of the thumb extensor or abductor, so in addition to release of the thumb adductor, the thumb extensor or abductor should be augmented with a transfer. The extensor indicis or palmaris longus is preferred. For those hands with some active abduction and good thumb extension, the extensor pollicis longus can be rerouted palmar to Lister's tubercle to allow its pull to become more of an abductor.^{13, 47} Other muscles that are also available include the brachioradialis, flexor carpi radialis, and ring flexor digitorum superficialis. The brachioradialis is especially good if a strong tenodesis effect is desired in a hand with poor active control. Removal of the flexor carpi radialis may leave the wrist without an active wrist flexor if the flexor carpi ulnaris is being transferred; if the flexor carpi ulnaris is intact, there usually is an imbalance into ulnar deviation. Therefore, the risks of harvesting the flexor carpi radialis are usually too large. The ring flexor digitorum superficialis is a reasonable muscle to transfer to augment thumb abduction; however, it is a more complex procedure than the more superficial or locally available muscle options.

Type 3

In type 3, the metacarpal is adducted and the metacarpophalangeal joint is hyperextended. These patients require treatment of the thumb adduction contracture as in type 1 plus stabilization of the thumb metacarpophalangeal joint. It is important to recognize this metacarpal joint laxity preoperatively, because failure to recognize this may result in a marked hyperextension deformity particularly if the extensor pollicis longus has been indirectly augmented by the flexor pollicis longus lengthening. Metacarpophalangeal joint stabilization is best done by doing a metacarpophalangeal joint fusion. This provides a stable permanent solution with excellent functional gain (Case 8.10).⁴⁸ Other options include volar plate advancement^{49, 50}; however, the risk of failure of this operation is too high with minimal to no functional benefit over arthrodesis. Sesamoid fusion has also been reported.⁵¹ We have no experience with this procedure, but again, it seems overly complex for no apparent functional gain.

Type 4

In type 4, patients have adduction of the thumb plus contracture of the flexor pollicis longus and usually a fixed flexion contracture of the metacarpophalangeal joint, often more than 90°. This is also called the cortical thumb position. Patients with this type of deformity tend to be severely involved with quadriplegia. As these individuals have minimal function, the treatment usually is directed at improving hygiene. Many of these children have thumbs that are held tightly in the palm, making cleaning difficult and often creating a foul odor in the hand, sometimes with skin breakdown in



Case 8.9 Dylan

Dylan, a 15-year-old boy with hemiplegia, had an upper extremity reconstruction in which he had an adductor pollicis myotomy. He was still not happy because he used the extremity as a helper hand, especially for holding larger objects such as bottles, which he could not do because of limited thumb adduction. On physical examination he had neutral alignment of the thumb with 45° of flexion to zero extension of the metacarpal joint. Thumb abduction was limited so he could only get the thumb a maximum of 2 cm from the radial border of the index finger. Strong key pinch was present but he was not able

to oppose the thumb and index or long fingertips. After some discussion, he was willing to give up key pinch for a larger grip area of his thumb through better thumb abduction. A web space deepening was performed with release of the first dorsal interosseous muscle from the index metacarpal. He also had augmentation of thumb abduction by radial rerouting of the extensor pollicis longus. He was happy that he could then hold a Coke bottle (Figure C8.9.1); however, he could no longer hold a piece of paper with key pinch (Figure C8.9.2).

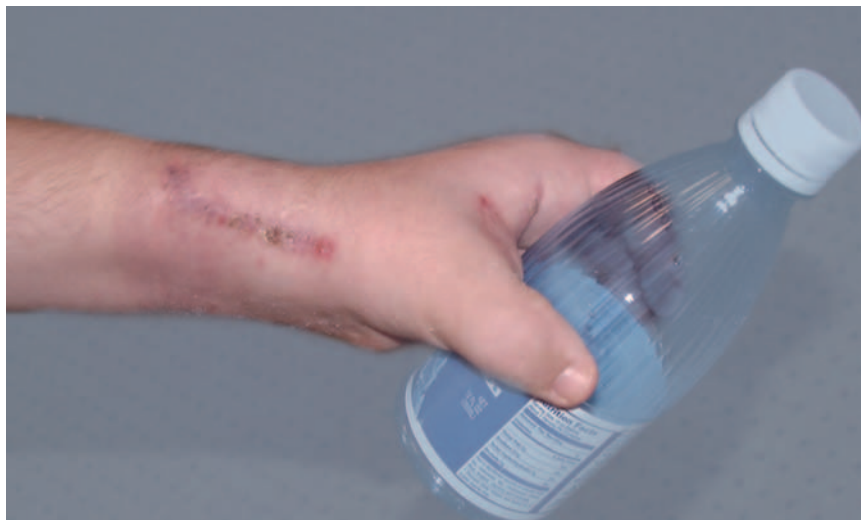

Figure C8.9.1

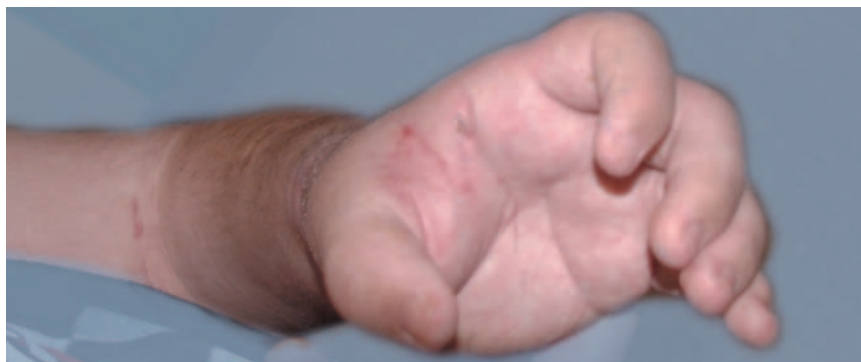

Figure C8.9.2



Case 8.10 Julian

Julian, a 16-year-old boy with hemiplegia, had an upper extremity reconstruction 12 months prior, which involved a myotomy of the adductor pollicis, plication of the extensor digitorum communis, advancement of the volar plate on the thumb metacarpal joint, transfer of the flexor carpi ulnaris to the extensor carpi radialis brevis, and pronator teres rerouting. He was happy with the extremity except for the thumb, which continued to go into hyperextension, making it difficult to hold onto handles. He was an enthusiastic hockey player and he could not hold on to a hockey stick. The involvement in the lower extremity was very mild, allowing him to be competitive in hockey. On physical examination the thumb metacarpal was noted to rest in 30° of extension and any attempt at thumb flexion only caused more metacarpal hyperextension (Figure C8.10.1). Passive range of motion of the thumb metacarpal joint was normal. There was mild lim-

itation on the abduction; however, he could actively open his web space so there was at least 4 cm of distance between the thumb and index finger. Because the only physical problem he complained about was the metacarpal hyperextension, a metacarpal joint fusion was performed. Six months after the surgery, he was playing hockey without discomfort or problems from the extremity (Figure C8.10.2).

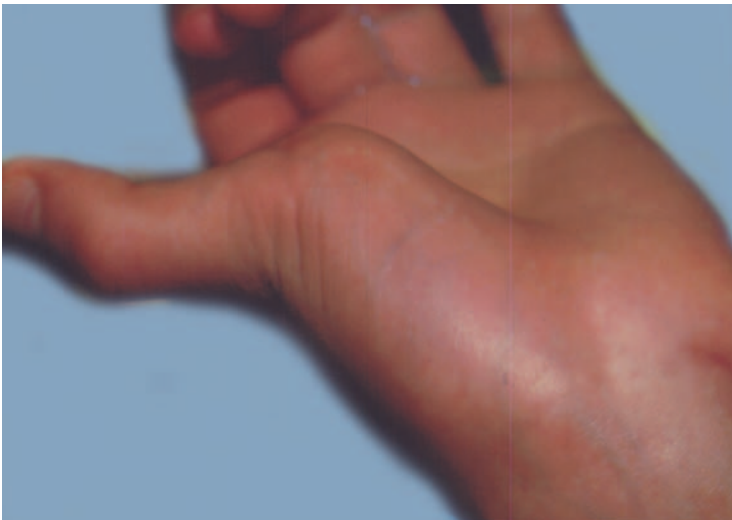

Figure C8.10.1

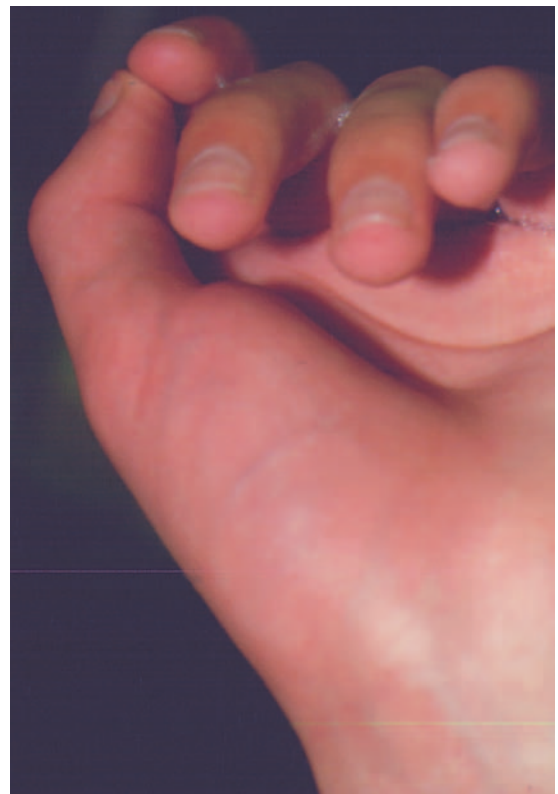


Figure C8.10.2

the thumb flexion crease. The treatment requires release of the adductor brevis, tenotomy of the flexor pollicis longus, and fusion of the metacarpophalangeal joint in full extension (Case 8.11). In a few individuals with severe adduction, a Z-plasty of the web space may be required.

Outcome of Treatment

The outcome of thumb procedures depends on the associated upper extremity procedures, which are usually performed concurrently with the thumb



Case 8.11 Justin

Justin, a 7-year-old boy with severe quadriplegia, presented with his mother who complained that she was not able to keep the boy's hand clean, and the hand developed a very foul odor especially in the summer. Physical examination demonstrated a hand in which the thumb was held against the palm and the fingers were flexed on top of the thumb (Figures C8.11.1, C8.11.2). During passive motion, the fingers could be opened and the thumb ex-

tended, but only to -30° metacarpal extension. As soon as the thumb was released, it went into the palm again. A fusion of the thumb metacarpal joint with preservation of the growth plate in the proximal phalanges was performed with the joint in full extension (Figure C8.11.3). Following the healing period, his mother reported complete resolution of the problems she had in keeping the hand clean. The thumb stayed at the side of the fingers.

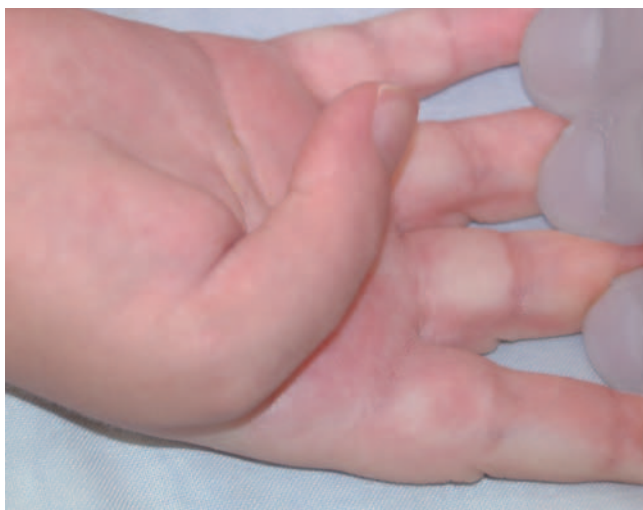

Figure C8.11.1

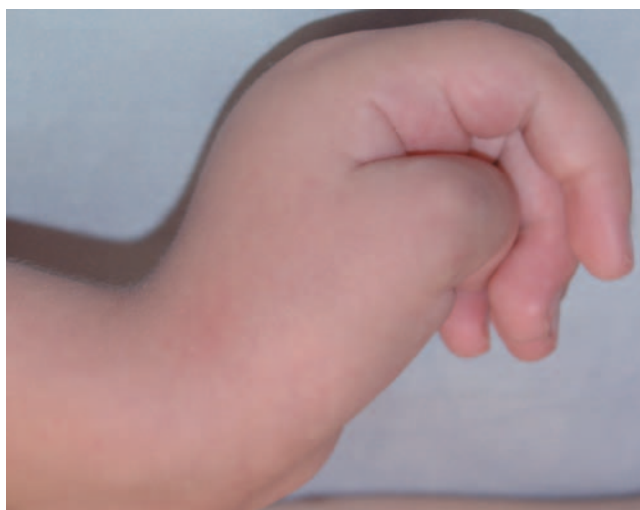

Figure C8.11.2

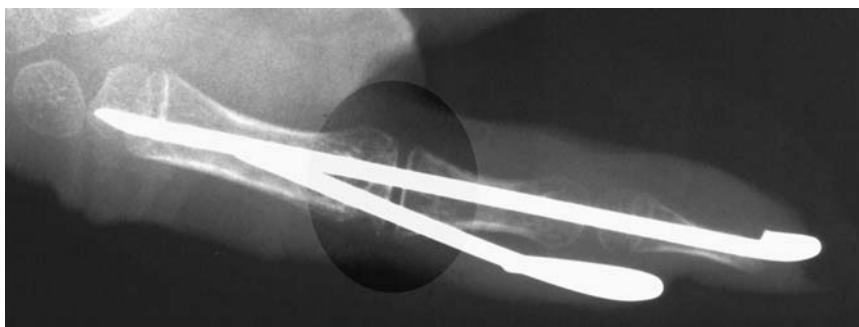


Figure C8.11.3

surgery.⁵² Dahlin et al. reported an improvement in grasp and stereognosis in most children after thumb surgery.⁵³ It is difficult to explain why stereognosis should increase. In this series, 31 of 39 hemiplegic thumbs maintained the corrected abduction, but there was only a 15-month follow-up.⁵³ Matev reported 82% of hands maintained some correction of the abduction

after a 5-year follow-up time.⁴⁵ Manske reported 90% of patients were able to get enough thumb abduction to allow good grasp function.⁵⁴ Smith reported on seven hands with good function and found improved grasp in all, but no improvement in pinch or fine motor function. He reported one patient lost fine motor function due to excessive adductor lengthening causing loss of pinch.⁵⁵ Arthrodesis of the metacarpophalangeal joint can be performed in children as young as 4 years of age if care is taken to avoid damage to the distal epiphysis of the proximal phalanges.⁴⁸

Other Treatment

There are other approaches to addressing the thumb-in-palm deformity, including radial and dorsal transfer of the flexor pollicis longus combined with fusion of the interphalangeal joint.⁵⁵ This would usually have to be combined with adductor pollicis lengthening, and the transfer would take the place of augmentations. We have no experience with this procedure. Correcting thumb adduction by osteotomy of the first metacarpal or resection of the greater multangular is another option to correct the adduction deformity.¹⁹ These options may be useful in severe isolated thumb deformities; however, we usually also address the wrist flexion deformity with a carpal resection and fusion. By resecting the whole scaphoid, the thumb is decompressed and increased abduction is obtained. Another option that comes from the poliomyelitis period is a bone block fusion between the thumb and index metacarpal to fix abduction. This operation is no longer indicated with the improvements in understanding of obtaining thumb balance with maintenance of mobility.⁴⁵

Complications of Treatment

The primary complications are recurrent deformity, and based on current reports, it is difficult to come up with expected recurrence rates. Usually, 10% to 20% of patients reportedly have not achieved the abduction goals desired.^{45, 53, 54} In our experience, few children have no improvement but approximately one in five probably still complain of not enough abduction. When the treatment routine changes to be more aggressive with treating the adduction deformity, an increased number of patients complain of overcorrection with loss of pinch and fine motor skills.⁵³ Overcorrection can be more functionally disabling because of loss of fine motor skills, and an abducted thumb gets in the way of dressing. In general, we think it is better having 20% of individuals slightly undercorrected than having 10% undercorrected and 10% overcorrected. Also, secondary correction of residual adduction is easy by simply adding more release and augmenting abduction power. Treatment of overcorrection requires a muscle transfer to increase strength of the deficient adductor.

Failure to recognize hyperextension mobility of the metacarpophalangeal joint leads to rapid progressive additional metacarpophalangeal joint hyperextension. This hyperextension is easily salvaged with a fusion of the metacarpophalangeal joint.

Fingers

Finger Flexion

Finger flexion deformity is often coexistent with wrist flexion deformity and interferes with releasing objects. The primary muscle that is contracted is the flexor digitorum sublimus, and secondarily, the flexor digitorum profundus.

The intrinsic muscles are almost never a significant aspect of the pathologic deformity in the spastic hand.

Treatment

Indications for treating finger flexor contractures have to be considered with the wrist flexion deformity. Adequate finger extension is defined as a good release of grasp position, meaning extension of the metacarpophalangeal and interphalangeal joints to -30° . If this level of extension cannot be passively obtained with the wrist in 0° to 20° of extension, lengthening of the finger flexors is indicated. Lengthening of flexor digitorum superficialis is usually sufficient in a functional hand. Simultaneous lengthening of the flexor digitorum profundus is best avoided in a potentially functional hand because it may cause an excessively weak grasp. However, if the flexor digitorum profundus is excessively tight, it too may require lengthening. When finger flexor contractures are severe, proper hygiene and cleaning of the hand is difficult. In these severe contractures, both the flexor digitorum superficialis and flexor digitorum profundus have to be lengthened.

Fractional lengthening at the musculotendinous junction of the flexor digitorum superficialis in mild to moderate deformity is preferred as it does not disrupt the continuity of the muscle and is less likely to result in overlengthening. Overlengthening may result in weakness of grasp. Care has to be taken that not too much lengthening occurs or the muscle tendon junction will become completely disrupted. In more severe cases, we prefer to do Z-lengthening, usually lengthening the index and middle finger as a group and also the ring and little finger as a group.

Outcome of Treatment

There are very few studies that report the outcome of finger flexor lengthening. Hoffer et al. have reported that augmenting the finger extensors by transferring the flexor carpi ulnaris to the finger extensors rather than the wrist extensors substantially improves release of finger grasp.² They also report that this procedure works best in hands that start with the best function.² Tonkin et al. reported improvement in 30 of 34 hands treated for finger flexor contractures.⁵⁶ Our experience has been that as the severity of the contracture gets worse, requiring more lengthening, there is an increased amount of weakness in finger flexion. These results are more specifically a demonstration that the muscles have severe decreased excursion and unless the active range is perfectly placed, they are likely to be perceived as weakness. Over time, there is a tendency for the finger flexion contracture to recur, but seldom to the level it was before surgery. Good outcome studies are not available.

Other Treatment

Several other methods of lengthening are possible including flexor pronator slide (proximal lengthening), Z-lengthening of individual flexor tendons, selective peripheral motor neurectomy,³⁹ and sublimus to profundus transfer. The flexor pronator slide provides little control and excessive weakness for children with any function; for those who are severely involved, the Z-lengthening is an easier and simpler operation. Another option similar to the slide is excision of the proximal muscle fascia with detaching the muscle from the bone.⁵⁷ We have no experience with this procedure. With the limited control present in spastic hands, individual tendon Z-lengthening is more complicated and provides little gain. Transfers of flexor digitorum superficialis to flexor digitorum profundus to create a single motor unit for the fingers seem to also provide little benefit over simpler lengthening procedures.

Neurectomies provide excessive weakness and do not address the contractures. Another option reported by Matsuo et al. is to release the long finger flexors and long finger extensors thus freeing the intrinsics to control the fingers.⁵⁸ We have no experience with this procedure, but we would be very worried about the extreme weakness this would cause. Most of the function of a hemiplegic hand is for gross finger grasp and thumb key pinch, both activities requiring power more than fine control.

Complications of Treatment

The major complication is overlengthening, leaving the fingers with no power in the range where individuals need power for function. This loss of function usually recovers over several years, but only partially. We have not had any individuals with such severe weakness that they desired an operative attempt to correct the overlengthening. Some individuals want additional lengthening if there is still too much flexion. Those who want additional lengthening are mainly individuals in whom a decision was initially made that the finger flexors need lengthening but no or very minimal lengthening was performed.

The other complication is leaving an imbalance with an excessively strong flexor digitorum profundus and extensor digitorum longus causing the swan neck deformity to develop. This deformity can be extremely disabling because it locks the fingers so that they cannot be used. Treatment indicated is described in the next section.

Finger Swan Neck

Tightening of the finger flexors secondary to the wrist flexion deformity plus spasticity of the intrinsic muscles and the extensor digitorum longus results in hyperextension of the proximal interphalangeal joint and flexion of the distal interphalangeal joint, which causes the swan neck deformity. The volar capsule of the proximal interphalangeal joint becomes stretched out secondarily. When the deformity is severe, the fingers may become locked into extension and cannot actively flex (Figure 8.7). This deformity can be the result of overlengthening the flexor digitorum superficialis in the face of a spastic and cocontracting flexor digitorum profundus and extensor digitorum longus.

Treatment

The initial treatment should include the use of the figure-of-eight finger orthotic, which prevents extension of the proximal interphalangeal joint (Figure 8.8). This splint can be made from plastic and, if tolerated by the patients, cosmetically appealing metal splints, which look like finger rings, can be ordered. If the hyperextension is forceful, many individuals find the rings uncomfortable because of the small area of skin contact, which causes high local skin pressure. Surgical treatment is the next option.

For supple and moderate deformities that can easily be passively corrected, correction of the swan neck deformity as well as the wrist flexion deformity should be done at the same time. Two procedures, a volar capsulodesis and a flexor superficialis tenodesis, have been described to correct the deformity. The two procedures can be combined if necessary. Midlateral or Z-plasty incisions can be performed to expose the flexor surface of the proximal interphalangeal joint. The volar capsule is detached and advanced proximally on the distal end of the proximal phalanx. One half of the flexor digitorum superficialis is detached proximally and sutured to the tendon sheath proximally. The joint is immobilized with a single transarticular K-wire in 30° to 40° of flexion.

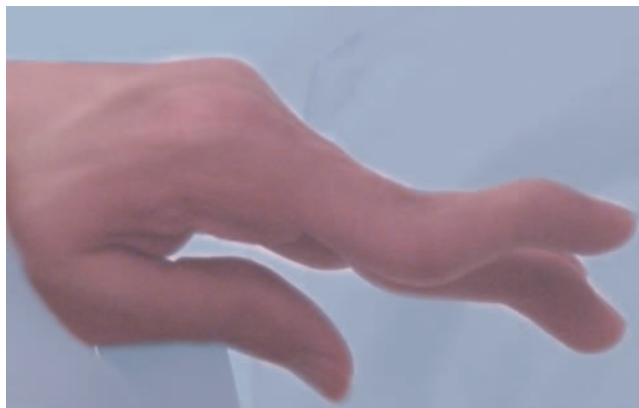

Figure 8.7. Swan neck deformities of the fingers are common and are caused by contractures of the central extensor slips with stretching out of the volar capsule on the proximal interphalangeal joint. Reconstruction is required if it is a symptomatic deformity for the patient.

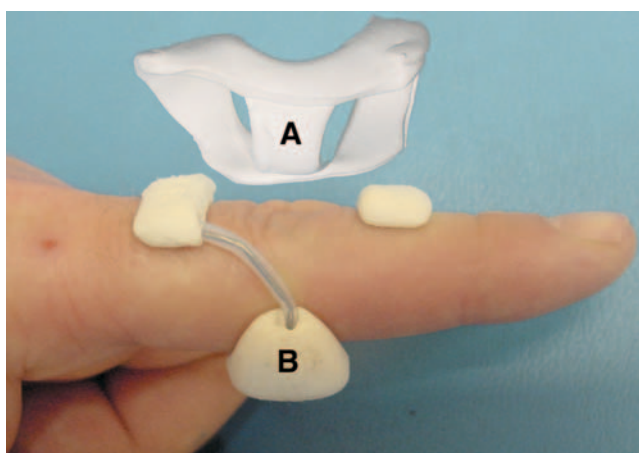
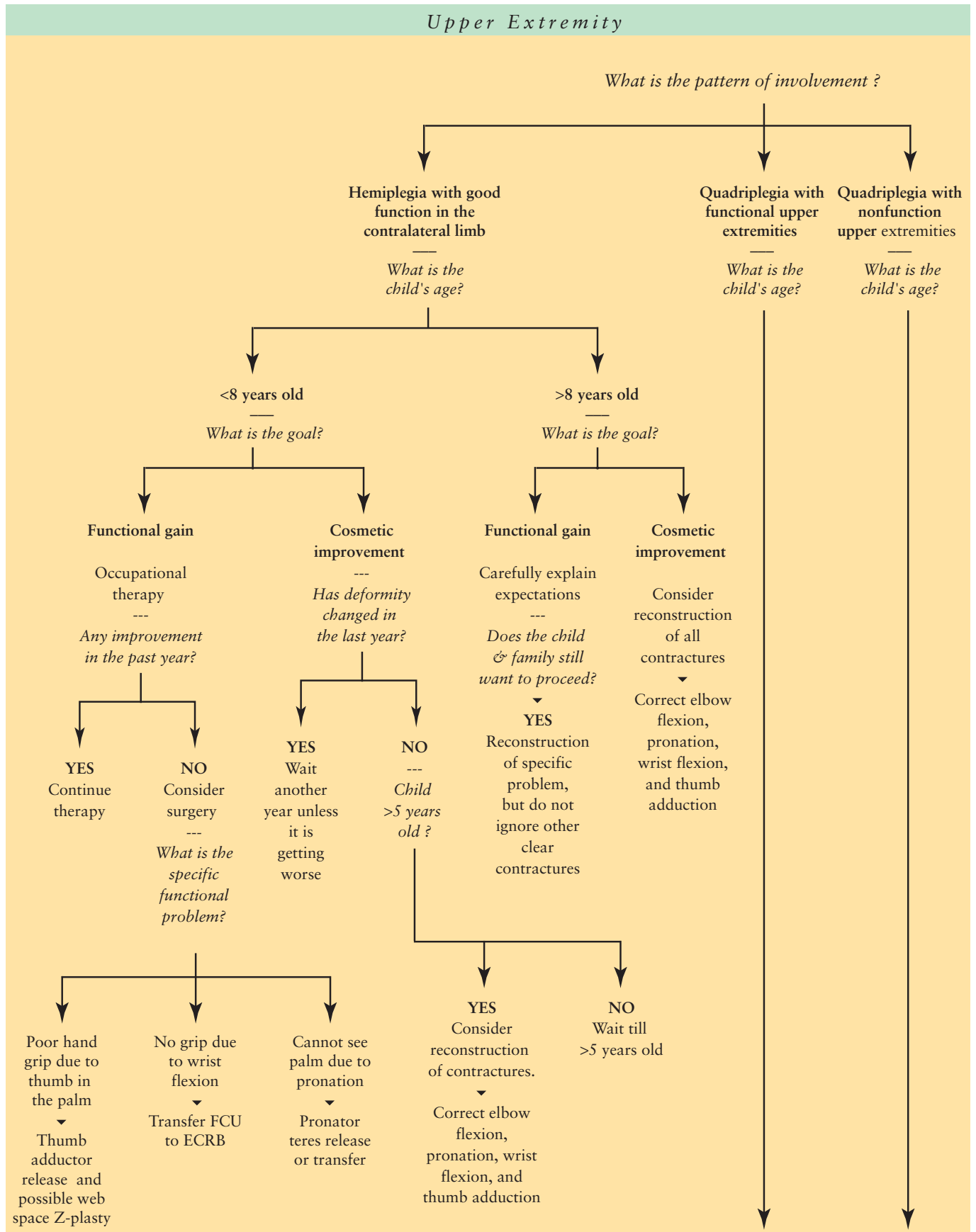


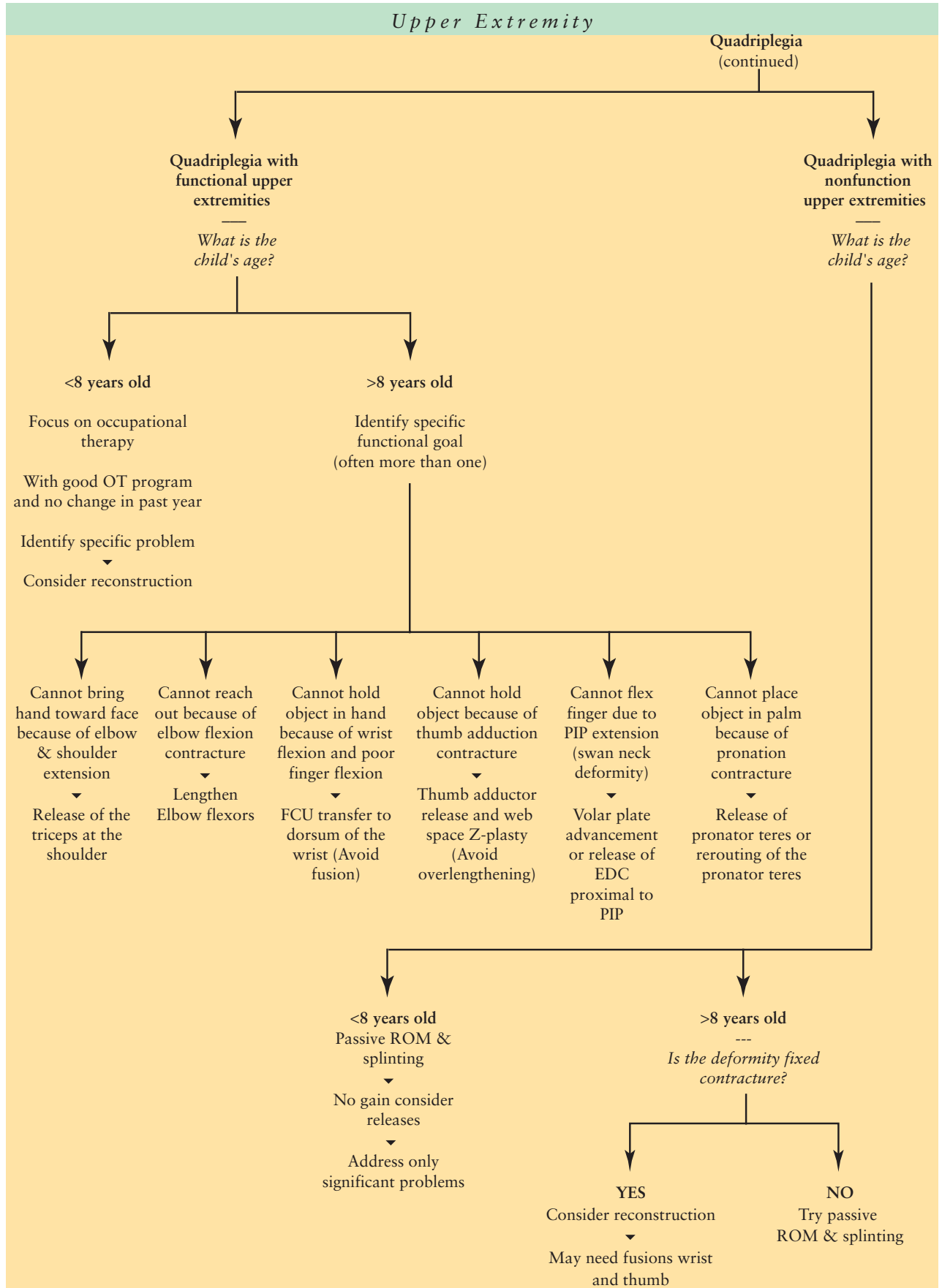
Figure 8.8. Splints are commercially available to prevent swan neck deformity; however, custom-molded splints can also be fabricated from thermoplastics. These splints prevent proximal interphalangeal joint extension but allow free flexion.

For severe swan neck deformities in limbs with minimal function or those in which the proximal interphalangeal joint hyperextension is fixed, the best treatment is proximal interphalangeal joint fusion in 30° to 40° of flexion. Another treatment that has been discussed at meetings is lengthening or incising the central slip of the extensor digitorum longus proximal to the proximal interphalangeal joint. This does seem to be a reasonable and simple approach, but it is also one that has had no published outcomes and one with which we have no experience.

Outcome of Treatment

The only report of the outcome of swan neck treatment, which includes only a few individuals with CP, was by Swanson in 1966.⁵⁹ He found good outcome if both volar plate advancement and sublimus tendon slip were used in the tenodesis. Immobilization with a transarticular pin was also believed to be important in the outcome. Our experience has been that surgery is not often required compared with all the hand surgery that is done. The most common complication is recurrent deformity for the soft-tissue procedures, especially if the proximal interphalangeal joint was not immobilized with a transarticular pin; however, we do not have enough patients to make an objective assessment. It seems that swan neck deformity is less common than it was earlier, which may be the result of better earlier treatment of the wrist and finger flexion deformities and doing fewer wrist fusions in functional limbs.





References

1. Hoffer MM, Perry J, Melkonian GJ. Dynamic electromyography and decision-making for surgery in the upper extremity of patients with cerebral palsy. *J Hand Surg [Am]* 1979;4:424–31.
2. Hoffer MM, Lehman M, Mitani M. Long-term follow-up on tendon transfers to the extensors of the wrist and fingers in patients with cerebral palsy. *J Hand Surg [Am]* 1986;11:836–40.
3. Gracies JM, Elovic E, McGuire J, Simpson DM. Traditional pharmacological treatments for spasticity. Part I: Local treatments. *Muscle Nerve Suppl* 1997;6:S61–91.
4. Corry IS, Cosgrove AP, Walsh EG, McClean D, Graham HK. Botulinum toxin A in the hemiplegic upper limb: a double-blind trial [see comments]. *Dev Med Child Neurol* 1997;39:185–93.
5. Beck AJ, Gaskill SJ, Marlin AE. Improvement in upper extremity function and trunk control after selective posterior rhizotomy. *Am J Occup Ther* 1993;47:704–7.
6. Loewen P, Steinbok P, Holsti L, MacKay M. Upper extremity performance and self-care skill changes in children with spastic cerebral palsy following selective posterior rhizotomy. *Pediatr Neurosurg* 1998;29:191–8.
7. Buckon CE, Sienko Thomas S, Aiona MD, Piatt JH. Assessment of upper-extremity function in children with spastic diplegia before and after selective dorsal rhizotomy. *Dev Med Child Neurol* 1996;38:967–75.
8. Albright AL. Baclofen in the treatment of cerebral palsy. *J Child Neurol* 1996;11:77–83.
9. Albright AL. Intrathecal baclofen in cerebral palsy movement disorders. *J Child Neurol* 1996;11 Suppl 1:S29–35.
10. Albright AL, Cervi A, Singletary J. Intrathecal baclofen for spasticity in cerebral palsy [see comments]. *JAMA* 1991;265:1418–22.
11. Gilmartin R, Bruce D, Storrs BB, et al. Intrathecal baclofen for management of spastic cerebral palsy: multicenter trial. *J Child Neurol* 2000;15:71–7.
12. Zancolli EA, Zancolli ER Jr. Surgical management of the hemiplegic spastic hand in cerebral palsy. *Surg Clin North Am* 1981;61:395–406.
13. Gordon AM, Charles J, Duff SV. Fingertip forces during object manipulation in children with hemiplegic cerebral palsy. II: bilateral coordination. *Dev Med Child Neurol* 1999;41:176–85.
14. Gordon AM, Duff SV. Fingertip forces during object manipulation in children with hemiplegic cerebral palsy. I: Anticipatory scaling. *Dev Med Child Neurol* 1999;41:166–75.
15. Nwaobi OM. Nondominant arm restraint and dominant arm function in a child with athetoid cerebral palsy: electromyographic and functional evaluation. *Arch Phys Med Rehabil* 1987;68:837–9.
16. Friedman A, Diamond M, Johnston MV, Daffner C. Effects of botulinum toxin A on upper limb spasticity in children with cerebral palsy. *Am J Phys Med Rehabil* 2000;79:53–9;quiz 75–6.
17. Hurvitz EA, Conti GE, Flansburg EL, Brown SH. Motor control testing of upper limb function after botulinum toxin injection: a case study. *Arch Phys Med Rehabil* 2000;81:1408–15.
18. Mital MA. Lengthening of the elbow flexors in cerebral palsy. *J Bone Joint Surg [Am]* 1979;61:515–22.
19. Sherk HH. Treatment of severe rigid contractures of cerebral palsied upper limbs. *Clin Orthop* 1977:151–5.
20. Nishioka E, Yoshida K, Yamanaka K, Inoue A. Radiographic studies of the wrist and elbow in cerebral palsy. *J Orthop Sci* 2000;5:268–74.
21. Pletcher DF, Hoffer MM, Koffman DM. Non-traumatic dislocation of the radial head in cerebral palsy. *J Bone Joint Surg [Am]* 1976;58:104–5.
22. Subbarao JV, Kumar VN. Spontaneous dislocation of the radial head in cerebral palsy. *Orthop Rev* 1987;16:457–61.
23. Sakellarides HT, Mital MA, Lenzi WD. Treatment of pronation contractures of the forearm in cerebral palsy by changing the insertion of the pronator radii teres. *J Bone Joint Surg [Am]* 1981;63:645–52.

24. Strecker WB, Emanuel JP, Dailey L, Manske PR. Comparison of pronator tenotomy and pronator rerouting in children with spastic cerebral palsy. *J Hand Surg [Am]* 1988;13:540–3.
25. Colton CL, Ransford AO, Lloyd-Roberts GC. Transposition of the tendon of pronator teres in cerebral palsy. *J Bone Joint Surg [Br]* 1976;58:220–3.
26. de Paula A, Cardenas E, Leivas TP, dos Santos CA, Carazzato JG. Transfer of the pronator teres tendon to the extensor carpi radialis tendon in wrist flexion deformity in cerebral palsy. *Rev Hosp Clin Fac Med Sao Paulo* 1994;49:120–3.
27. Patella V, Martucci G. Transposition of the pronator radial teres muscle to the radial extensors of the wrist, in infantile cerebral paralysis. An improved operative technique. *Ital J Orthop Traumatol* 1980;6:61–6.
28. Law M, Cadman D, Rosenbaum P, Walter S, Russell D, DeMatteo C. Neurodevelopmental therapy and upper-extremity inhibitive casting for children with cerebral palsy [see comments]. *Dev Med Child Neurol* 1991;33:379–87.
29. Patella V, Franchin F, Moretti B, Mori F. Arthrodesis of the wrist with mini-fixators in infantile cerebral palsy. *Ital J Orthop Traumatol* 1984;10:75–9.
30. Beach WR, Strecker WB, Coe J, Manske PR, Schoenecker PL, Dailey L. Use of the Green transfer in treatment of patients with spastic cerebral palsy: 17-year experience. *J Pediatr Orthop* 1991;11:731–6.
31. Wolf TM, Clinkscales CM, Hamlin C. Flexor carpi ulnaris tendon transfers in cerebral palsy. *J Hand Surg [Br]* 1998;23:340–3.
32. Wenner SM, Johnson KA. Transfer of the flexor carpi ulnaris to the radial wrist extensors in cerebral palsy. *J Hand Surg [Am]* 1988;13:231–3.
33. Thometz JG, Tachdjian M. Long-term follow-up of the flexor carpi ulnaris transfer in spastic hemiplegic children. *J Pediatr Orthop* 1988;8:407–12.
34. Thom H, Manolikakis G. Results of hand surgery operations in spastic-athetotic paresis. *Z Orthop Ihre Grenzgeb* 1988;126:274–81.
35. Rayan GM, Young BT. Arthrodesis of the spastic wrist. *J Hand Surg [Am]* 1999;24:944–52.
36. Alexander RD, Davids JR, Peace LC, Gidewall MA. Wrist arthrodesis in children with cerebral palsy. *J Pediatr Orthop* 2000;20:490–5.
37. Omer GE, Capen DA. Proximal row carpectomy with muscle transfers for spastic paralysis. *J Hand Surg [Am]* 1976;1:197–204.
38. House JH, Gwathmey FW. Flexor carpi ulnaris and the brachioradialis as a wrist extension transfer in cerebral palsy. *Minn Med* 1978;61:481–4.
39. Msaddi AK, Mazroue AR, Shahwan S, et al. Microsurgical selective peripheral neurotomy in the treatment of spasticity in cerebral-palsy children. *Stereotact Funct Neurosurg* 1997;69:251–8.
40. White WF. Flexor muscle slide in the spastic hand: the Max Page operation. *J Bone Joint Surg [Br]* 1972;54:453–9.
41. Atar D, Grant AD, Lehman WB. New approach to limb deformities in neuromuscular patients. *Bull Hosp Jt Dis Orthop Inst* 1990;50:99–106.
42. Hoffer MM, Perry J, Garcia M, Bullock D. Adduction contracture of the thumb in cerebral palsy. A preoperative electromyographic study. *J Bone Joint Surg [Am]* 1983;65:755–9.
43. House JH, Gwathmey FW, Fidler MO. A dynamic approach to the thumb-in-palm deformity in cerebral palsy. *J Bone Joint Surg [Am]* 1981;63:216–25.
44. Sakellarides HT, Mital MA, Matza RA, Dimakopoulos P. Classification and surgical treatment of the thumb-in-palm deformity in cerebral palsy and spastic paralysis. *J Hand Surg [Am]* 1995;20:428–31.
45. Matev I. Surgery of the spastic thumb-in-palm deformity [see comments]. *J Hand Surg [Br]* 1991;16:127–32.
46. Meyer RD, Gould JS, Nicholson B. Revision of the first web space: techniques and results. *South Med J* 1981;74:1204–8.
47. Rayan GM, Saccone PG. Treatment of spastic thumb-in-palm deformity: a modified extensor pollicis longus tendon rerouting. *J Hand Surg [Am]* 1996;21:834–9.
48. Goldner JL, Koman LA, Gelberman R, Levin S, Goldner RD. Arthrodesis of the metacarpophalangeal joint of the thumb in children and adults. Adjunctive treatment of thumb-in-palm deformity in cerebral palsy. *Clin Orthop* 1990:75–89.

49. Filler BC, Stark HH, Boyes JH. Capsulodesis of the metacarpophalangeal joint of the thumb in children with cerebral palsy. *J Bone Joint Surg [Am]* 1976;58:667-70.
50. Schuurman AH, Bos KE. Treatment of volar instability of the metacarpophalangeal joint of the thumb by volar capsulodesis. *J Hand Surg [Br]* 1993;18:346-9.
51. Tonkin MA, Beard AJ, Kemp SJ, Eakins DF. Sesamoid arthrodesis for hyperextension of the thumb metacarpophalangeal joint. *J Hand Surg [Am]* 1995;20:334-8.
52. Silver CM, Litchman HM, Simon SD, Motamed M. Surgical correction of spastic thumb-in-palm deformity. *Dev Med Child Neurol* 1976;18:632-9.
53. Dahlin LB, Komoto-Tufvesson Y, Salgeback S. Surgery of the spastic hand in cerebral palsy. Improvement in stereognosis and hand function after surgery. *J Hand Surg [Br]* 1998;23:334-9.
54. Manske PR. Redirection of extensor pollicis longus in the treatment of spastic thumb-in-palm deformity. *J Hand Surg [Am]* 1985;10:553-60.
55. Smith RJ. Flexor pollicis longus abductor-plasty for spastic thumb-in-palm deformity. *J Hand Surg [Am]* 1982;7:327-34.
56. Tonkin M, Gschwind C. Surgery for cerebral palsy: Part 2. Flexion deformity of the wrist and fingers. *J Hand Surg [Br]* 1992;17:396-400.
57. Rath S. Flexor aponeurotic release for resistant adaptive shortening of long flexors in claw hands in leprosy. *Indian J Lepr* 1997;69:101-7.
58. Matsuo T, Lai T, Tayama N. Combined flexor and extensor release for activation of voluntary movement of the fingers in patients with cerebral palsy. *Clin Orthop* 1990:185-93.
59. Swanson AB. Treatment of the swan-neck deformity in the cerebral palsied hand. *Clin Orthop* 1966;48:167-71.

Spine

Most spinal deformities involve scoliosis and primarily affect those individuals who are most severely involved, causing a clear-cut, definite disability. There are other less common deformities of the pelvic spinal segment that all children with cerebral palsy (CP) are at some risk of developing. The diagnosis and treatment of most spinal deformities is very clear, because if the deformity cannot be controlled with relatively simple seating adjustments, then surgery is the only treatment available. Surgical procedures for the spine are well defined. From the perspective of families, the functional results of these procedures provide the best outcome of any operation that can be done in children with severe quadriplegic involvement.

Scoliosis

Children with CP may develop an idiopathic pattern of scoliosis; however, this is quite uncommon. These children much more typically develop a neuromuscular pattern of scoliosis that includes a hyperkyphosis or hyperlordosis. Initially, these children develop a very flexible postural curve and then a structural component follows. After this structural component becomes present, a follow-up radiographic examination is indicated every 6 months. Most children who develop spinal deformities are dependent sitters and cannot stand; therefore, radiographs are obtained in the sitting position. Because many of these children are dependent sitters, having a consistent positioning chair is important. A positioning chair can be constructed quite simply using typical materials found in a seating clinic (Figure 9.1). This chair should allow the trunk to be consistently held in an upright posture and the pelvis consistently positioned. The chair should allow children to be seated so that an anteroposterior and a lateral radiograph can be obtained without changing their position. Also, there should be no need for family members or technicians to hold the children in position while radiographs are made. Because many of these children have components of kyphosis or hyperlordosis, anteroposterior and lateral radiographs are routinely recommended at each evaluation.

Etiology

The cause of CP scoliosis is directly related to the severity of the neurologic deficit. For young adults with quadriplegic involvement, 74% have significant scoliosis.¹ In another study of institutionalized patients, 64% had scoliosis and most of these were nonambulatory dependent sitters.² The overall

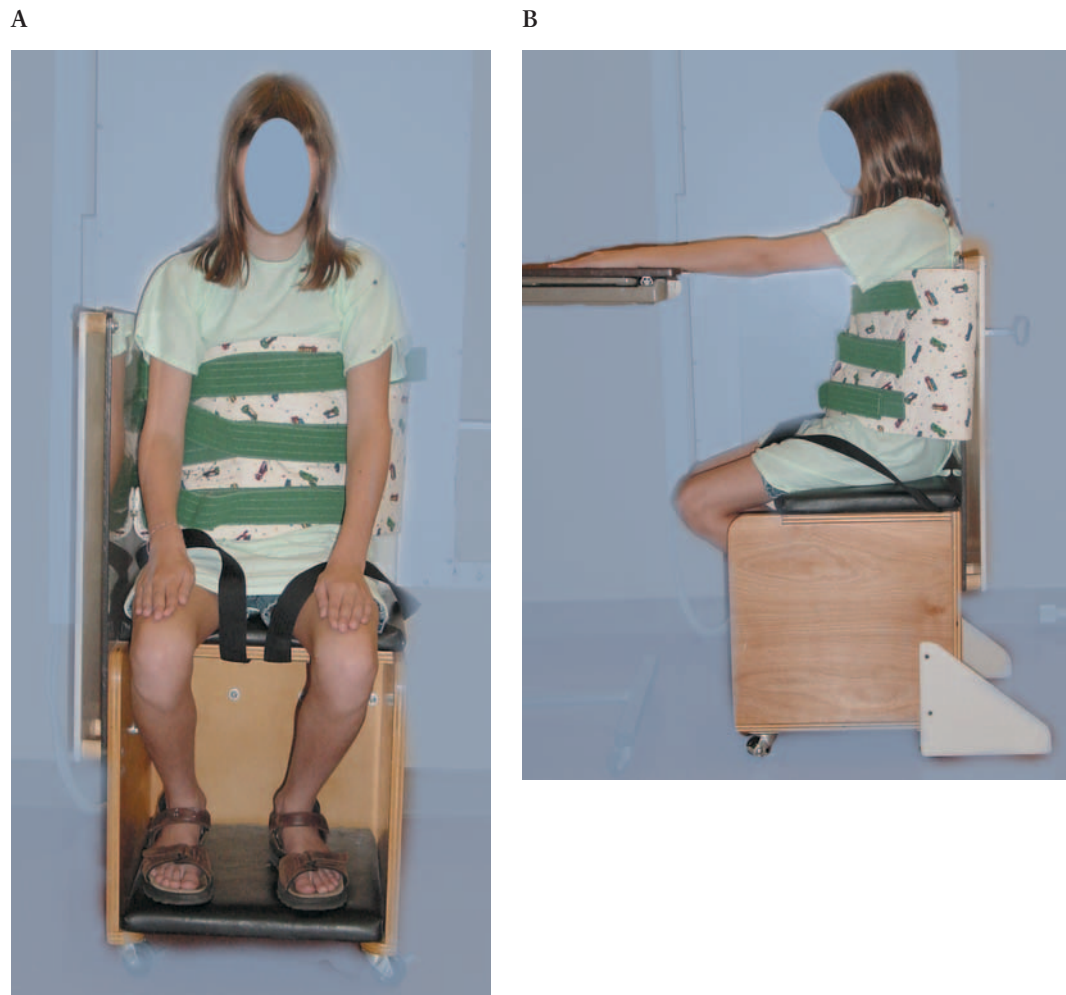


Figure 9.1. Scoliosis should be monitored with upright sitting radiographs, as these are often difficult to obtain on children who cannot sit independently. The best mechanism is to use a positioning chair that allows a child to sit with as much trunk support as in a wheelchair (A). This seating frame should be on castors so it can be turned into the lateral position with changing the child's seating posture as a way to obtain accurate and reproducible radiographs in two planes (B).

severity of the neurologic deficit is related to the frequency and severity of the scoliosis curve; however, it is not clear exactly which component of neurologic control is most directly responsible. General poor muscle control in the growing spine is the primary etiology; however, poor balance, spasticity, and muscle weakness may contribute as well.

Natural History

Scoliosis is rarely present in early childhood in individuals with CP, and when it is present, it is usually very flexible and without significant structural components. In the occasional rare case, a structural curve may develop as early as age 2 or 3 years; however, this is almost always limited to children who appear to have some type of congenital syndrome, even when no syndrome can be specifically diagnosed. These curves may progress very rapidly in both stiffness and magnitude at this very early age.

Most typically in children who are dependent sitters with quadriplegic pattern involvement, there tends to be a postural scoliosis and kyphosis in early and middle childhood, which is easily controlled with seating adaptations. In early and middle childhood, the structural component and the flexibility of the scoliosis often change very little. As these children enter adolescence, especially as they start with a rise in pubertal hormones and the adolescent growth spurt, the magnitude of the scoliosis increases dramati-

cally, often at a rate of 2° to 4° per month.^{3, 4} Almost uniformly, the magnitude of the scoliosis increases to about the 60° to 90° range, then the stiffness of the structural curve follows approximately 6 to 12 months later. During this rapid increase in curve magnitude, there is often a sudden realization by families and caretakers of increased problems with sitting, head control, and arm use. There is usually approximately a 2- to 3-year period when families and caretakers start noticing problems caused by the scoliosis until the spinal deformity becomes fixed with minimal flexibility (Case 9.1). In individuals with less neurologic deficit, this progression may be delayed into adulthood. There are individuals with severe quadriplegic pattern involvement who never develop scoliosis. If individuals do enter adulthood with mild scoliosis, the risk of continued progression is very high. In one report, if the curve was more than 40° , it progressed at a rate of 4° per year.⁵ In another report, all adults with curves over 40° progressed to a mean of 80° .⁴ Other data suggest that curves as low as 20° at the end of growth may continue to progress at a rate of approximately 0.8° per year.³

The natural history of problems associated with scoliosis is not well defined. In individuals with CP, as the scoliosis gets more severe, there is some respiratory restriction; however, because of the difficulty of doing pulmonary function testing in this patient population, there are no quantitative data to define this problem. A small group of children, especially those with a history of tracheal malacia, may develop a redundant and collapsing trachea with compression of the trachea especially at the sternal clavicular junction. Also, in some children with gastroesophageal reflux, swallowing and aspiration get worse⁶; however, there is no quantitative evidence to specifically define this problem. Discomfort in sitting from the ribs impinging on the pelvis occurs and limits sitting tolerance, especially if there is a progressive increase in pelvic obliquity with the scoliosis. Most patients continue to have progression of this spinal deformity to such a magnitude that they can no longer sit.

Treatment

As previously noted, the problems caused by the progressive severe deformity of scoliosis are directly due to the severe distortion of the trunk. This severe distortion makes sitting difficult, causes pain as the pelvis impinges against the ribs, makes breathing difficult as the chest cavity is distorted, and causes anatomical changes in the abdominal organs as the abdominal cavity is distorted. The primary goal of treatment is to correct this distortion, which requires correction of most of the spinal deformity. Therefore, a primary outcome factor in any treatment evaluation needs to be how good the alignment of the child's trunk is at the completion of treatment. The specific alignment goals are to have the shoulders parallel to the pelvis, the chest centered over the pelvis, and relatively normal sagittal plane alignment with thoracic kyphosis so the cervical spine is straight and the head can be easily held upright. A definite lumbar lordosis should be present so body weight is moved forward onto the proximal thigh during sitting, instead of being posterior on the ischial tuberosities (Figure 9.2). When this technical alignment is accomplished, a positive subjective evaluation of the patients and their caretakers is additional evidence of the success of the treatment (Case 9.2).

Conservative Treatment

Although families are greatly interested in the nonoperative treatment of scoliosis, there are no nonoperative treatments that have had any documented impact on the progression or eventual outcome of the spinal deformity.

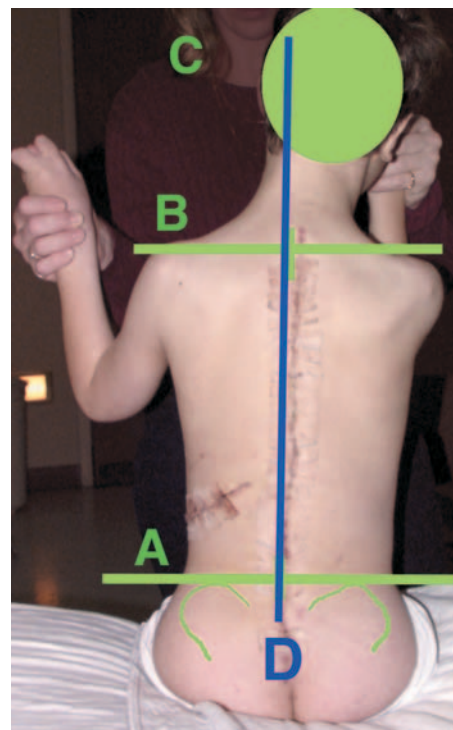


Figure 9.2. The goal of the surgical treatment of scoliosis in children with CP is to maximize their sitting posture. This means the goals required are (a) a pelvis that is level with the seat, (b) shoulders that are parallel to the pelvis, (c) head balanced over the shoulders, and (d) the midline of the shoulders should be aligned to the midline of the pelvis. The degree of residual scoliosis on the radiograph is less important but usually is less than 30° . Normal kyphosis and lordosis should also be produced.



Case 9.1 Melissa

Melissa, a 5-year-old girl with severe quadriplegia and mental retardation, had an initial radiograph at age 5 years when caretakers complained of painful hips and difficulty sitting. An examination of her spine demonstrated no scoliosis, and plans were made to address her hip pathology (Figure C9.1.1). Seven years following her hip surgery, she was again having more problems with seating,

and a radiograph showed a lumbar curve (Figure C9.1.2). Melissa was comfortable with appropriate seating adjustments until 18 months later when a rapid increase in the scoliosis made sitting more difficult (Figure C9.1.3). The scoliosis was then addressed with surgical correction using Unit rod instrumentation and was well maintained 5 years postoperatively (Figure C9.1.4).

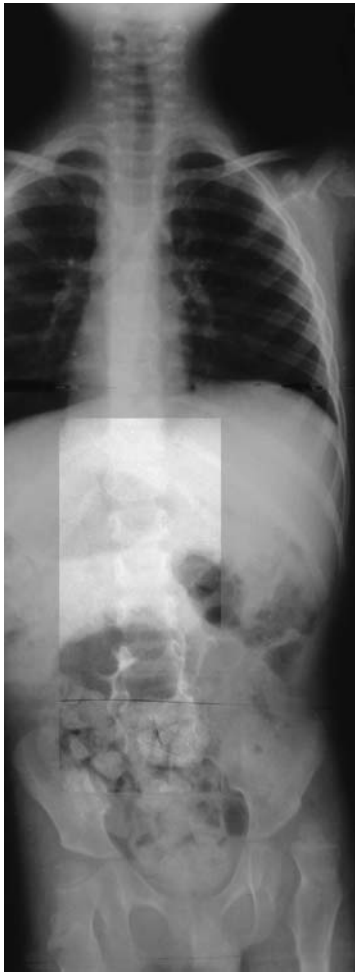

Figure C9.1.1

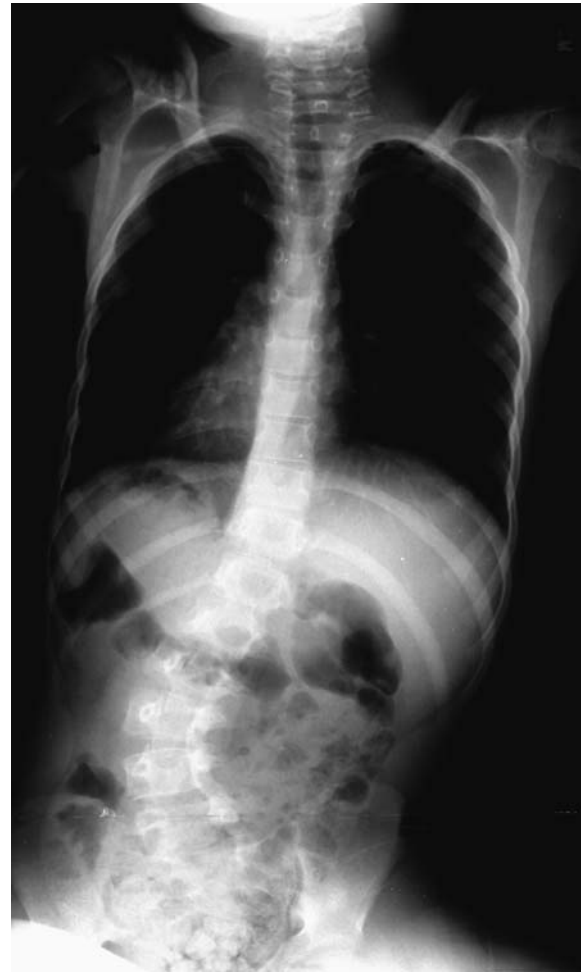

Figure C9.1.2

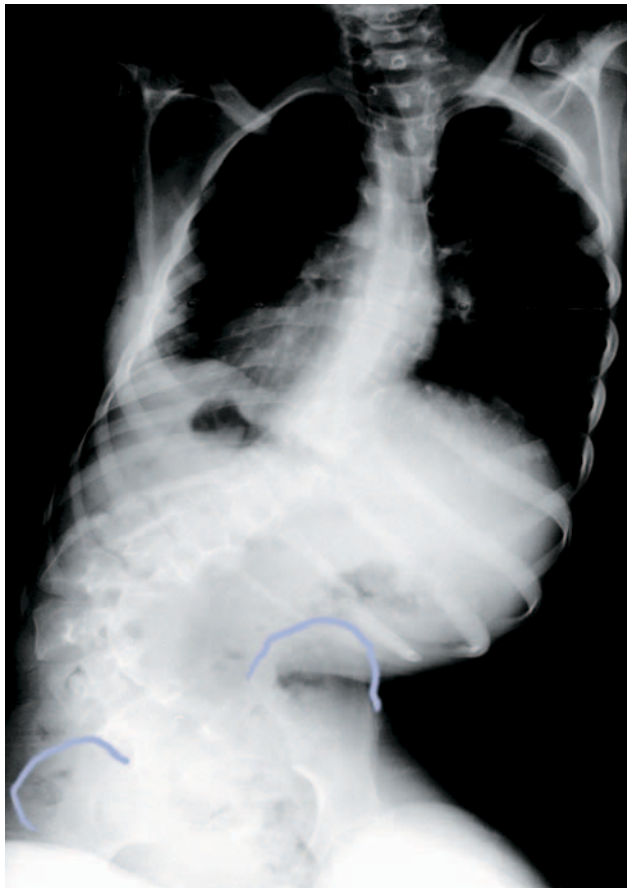


Figure C9.1.3

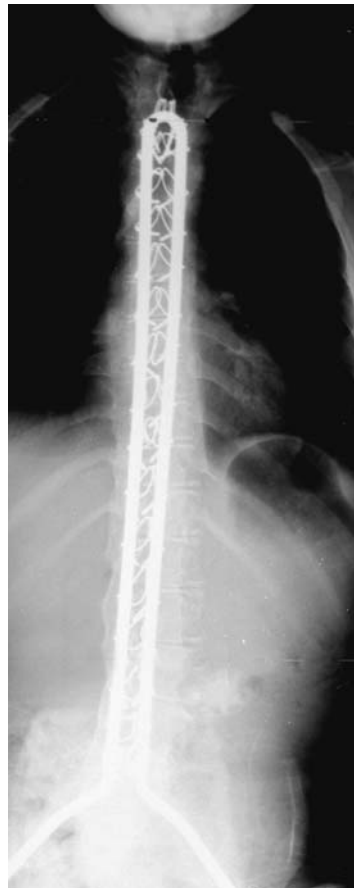

Figure C9.1.4

However, because of the prevalence of interest and the frequent enthusiasm from different segments of the treatment team, it is important to address each of the conservative modalities advocated for treating this problem.

Orthotics

Idiopathic adolescent scoliosis has shown beneficial response to bracing, and this concept was translated to children with CP in the early days of development of spinal orthotics. In the 1970s and early 1980s, there was great enthusiasm with reports of positive effects in children with CP⁷; however, review of these same patients compared with a control group who were not braced, has shown that there is no change in the rate of progression of the scoliosis or of the final outcome of the magnitude or stiffness of the scoliosis.³ Some of these children have been braced as long as 14 years in institutions where there is excellent documentation that they were kept in brace wear 23 hours a day and still developed typical scoliosis of the same magnitude and stiffness (Case 9.3). A more recent report suggested the possibility of benefit in some children⁸; however, most individuals in this group still developed scoliosis. Bracing in these children was started as young as age 4 years when there is rarely any real scoliosis present. This study also had no control group and has exactly the same outcome as the earlier report that simply reported the natural history of scoliosis in this group of patients.⁷



Case 9.2 Bryan

Bryan, a 16-year-old boy with moderate spastic quadriplegia and moderate mental retardation, was seen with progressive scoliosis. His mother cared for him at home by herself. During the past year he had grown rapidly and gained 25 kg. His mother used to do standing transfers but he had gotten so heavy that she could no longer do this safely. Bryan is a self-feeder and in good nutritional condition. On physical examination he could sit independently if supported by his arms (Figure C9.2.1). A radiograph demonstrated lumbar scoliosis of 80° with

flexibility (Figure C9.2.2). Unit rod instrumentation and fusion were performed without difficulty (Figure C9.2.3), and by the seventh day postoperatively, he could sit independent of arm support (Figures C9.2.4, C9.2.5). By the 1-month postoperative visit, his mother reported that she could again do standing transfers with him (Figure C9.2.6). Not many children make this kind of dramatic functional gain after spine surgery, but this does demonstrate the possibilities of gain and the rate of typical recovery.

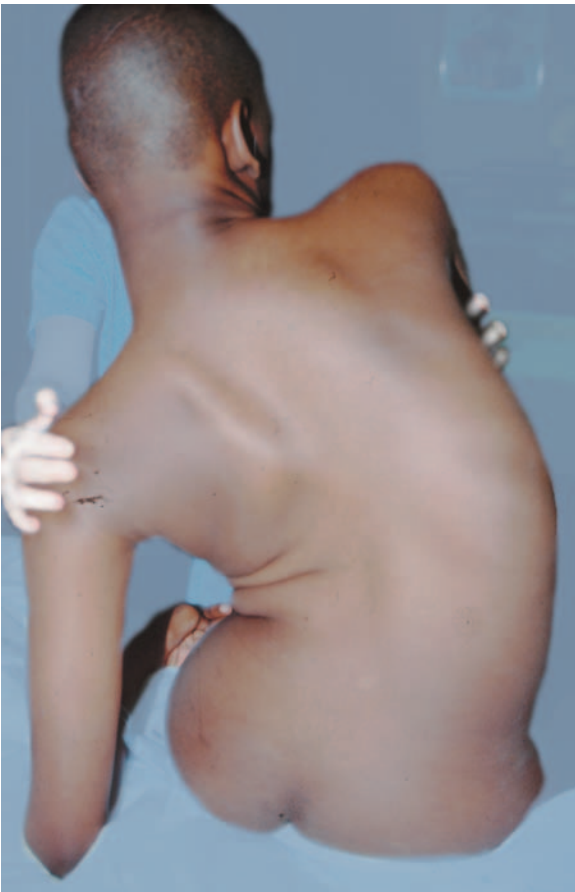

Figure C9.2.1

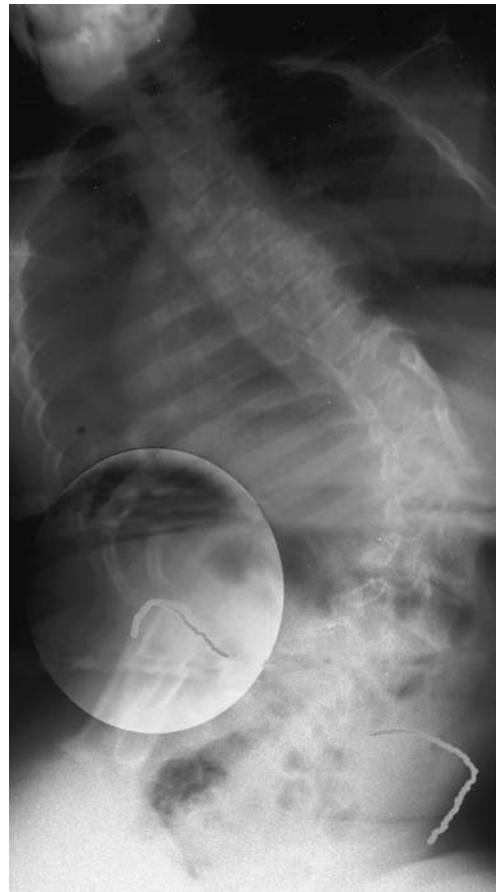

Figure C9.2.2

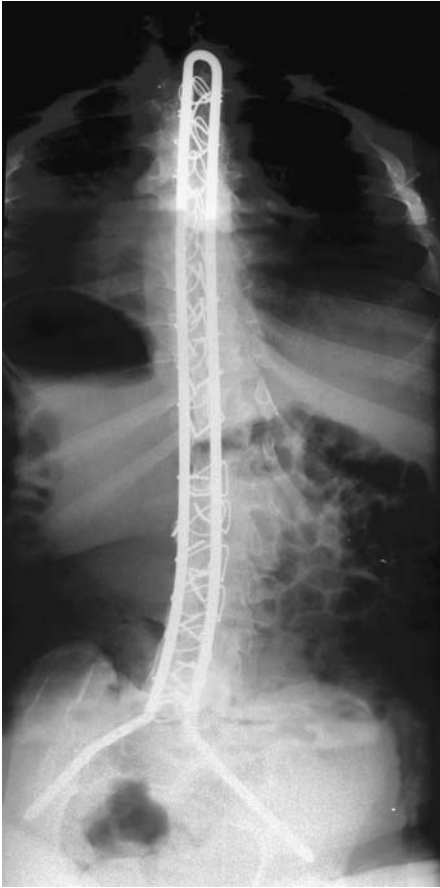

Figure C9.2.3

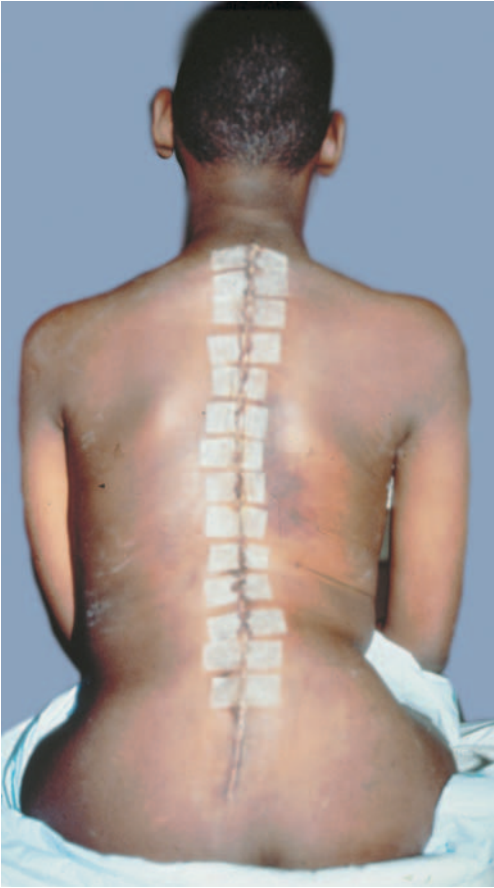

Figure C9.2.4

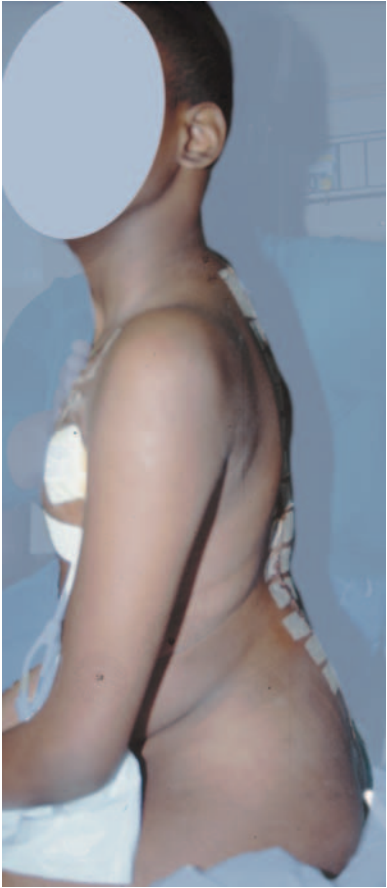

Figure C9.2.5

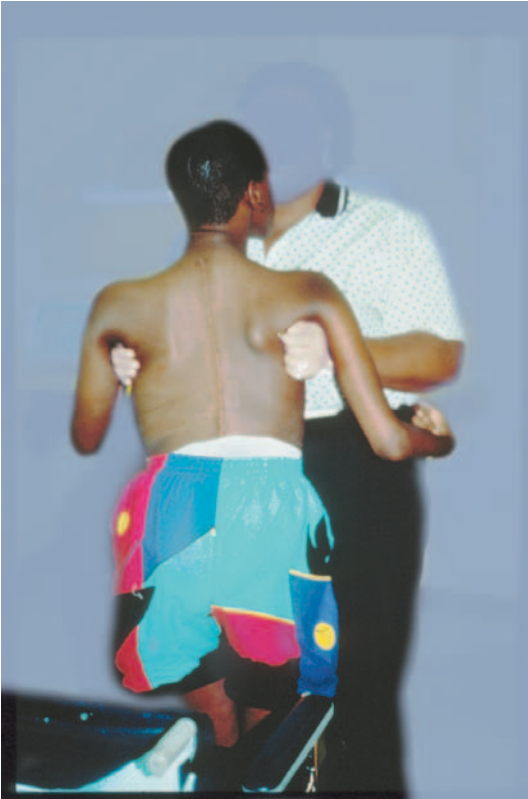

Figure C9.2.6



Case 9.3 Danjay

Danjay, a boy with severe quadriplegia, started a full-time bracing program in a custom-molded TLSO (Figures C9.3.1, C9.3.2), which he wore for 23 hours a day starting at age 3 years. Because he was cared for by a profes-

sional nursing service, excellent compliance records were available. After 14 years of brace wear, he still developed scoliosis that made bracing uncomfortable (Figure C9.3.3) and required surgical correction (Figure C9.3.4).

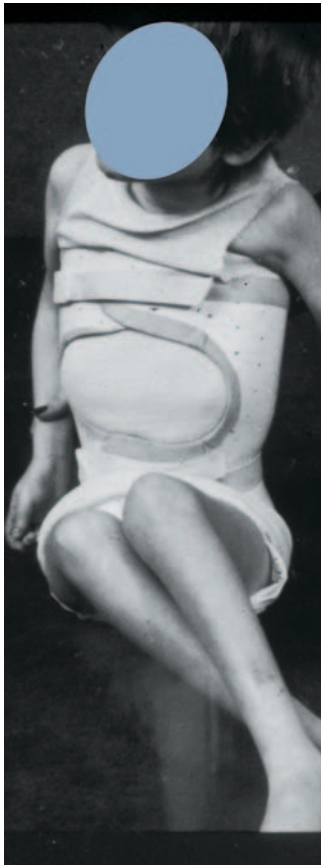

Figure C9.3.1

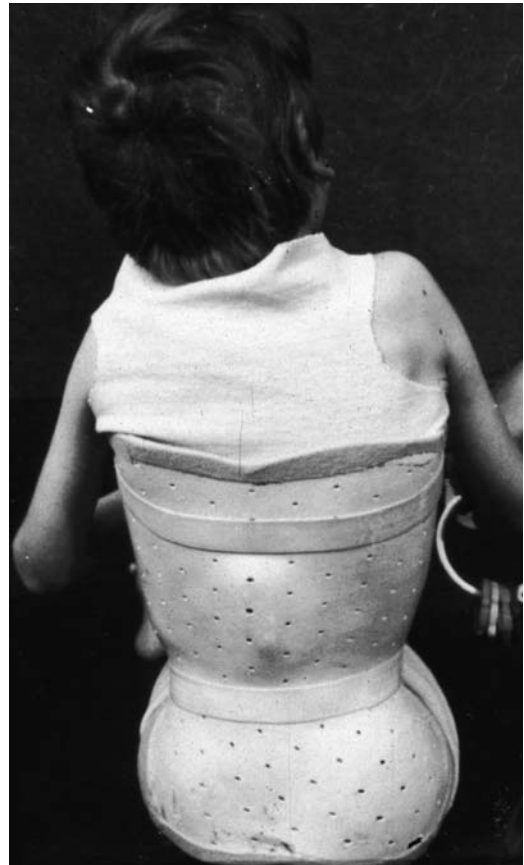

Figure C9.3.2

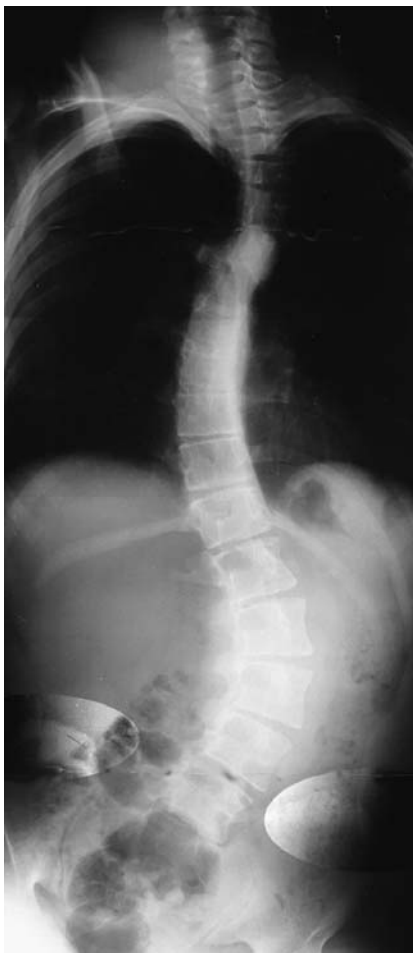

Figure C9.3.3

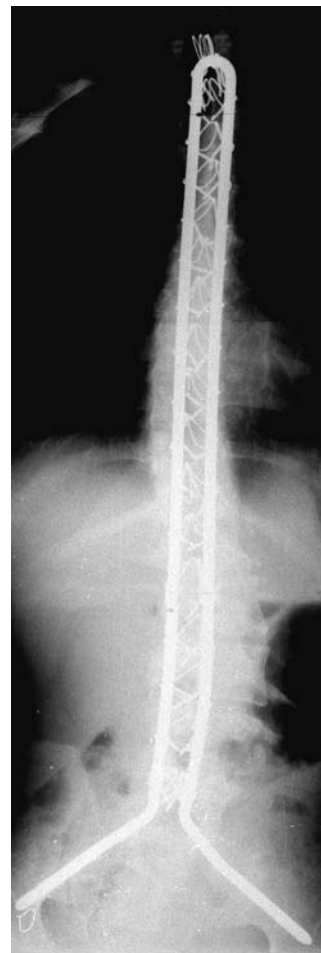


Figure C9.3.4

There is a role for the use of orthotics, specifically, the use of a soft corset-type thoracolumbosacral orthosis (TLSO) jacket that opens in the front so that it can be applied and removed easily. This corset jacket can be applied over clothes and is used only for sitting to improve children's sitting posture (Figure 9.3).

This orthosis is never used at night and is simply another alternative to appropriate wheelchair-seating adaptations that allow improved sitting in areas other than the adapted wheelchair. Parents must be instructed that no benefit on the structural scoliosis curve by the use of this orthosis is expected, so the orthosis should be used only at times when it is providing children direct functional benefit. This lack of structural benefit use has to be clarified because parents frequently develop false hopes that the orthotics will prevent scoliosis and are then disappointed as the scoliosis continues to increase in spite of orthotic use.

Problems with the use of these soft TLSO jackets are that they tend to cause children to become hot in warm weather and may be restrictive enough to impact on their breathing ability. Although one report stressed that the benefit of sitting upright was equal to the restrictive effect of the orthotic, in the balance, children did as well with the brace as without the brace.⁹ We have seen some children who could not tolerate the orthotic because of the

Figure 9.3. To assist with prop sitting, a soft TLSO may be used. This assists the prop sitting but has no impact on the development or progression of the scoliosis.



respiratory restriction it caused, and the orthotic had to be loosened significantly or discontinued. The most common restrictive problems with the orthosis occur with feeding, especially in children who are tube-fed and have gastroesophageal reflux. The brace sometimes has to be removed or significantly loosened for feeding. Another problem that may occur is fitting these children in wheelchairs with the brace in place. If the wheelchair is adapted to be used with the brace, it often does not fit when the children are seated without the brace. Therefore, parents or caretakers need to decide if they want the children to wear the brace almost entirely when seated, or whether they want to use it only for specific seating when children are not in the wheelchair.

Seating

The primary method for dealing with scoliosis before surgical intervention is to adapt the wheelchair with offset chest laterals. These adjustments have to be made continuously because children are often growing rapidly at this time and the three-point pressure configuration of the offset chest laterals only functions when they are fitting correctly. The wheelchair should be used as the primary sitting device, including its use as the feeding chair, especially during this period of children's lives. If a different feeding chair is used, it too should be adapted with the three-point pressure system to help children sit upright. (See chapter 6 for details on wheelchair adaptations.)

Therapy

There are no data to suggest that any stretching or range-of-motion therapy is of any benefit in reducing or delaying the progression of the scoliosis. Children are encouraged to be out of the wheelchair for periods of time during the day, especially in the prone and side lying positions. However, there is no evidence that these alternate positions affect the course of the scoliosis.

Electrical Stimulation

Although spinal electrical stimulation was briefly very popular in the late 1980s for adolescent idiopathic scoliosis, it subsequently has been determined not to be of benefit in the idiopathic scoliosis patient population. There have been no published studies evaluating its use in children with CP and there is no rational reason why it should have any benefit. Any attempts at treating scoliosis with electrical stimulation should be discouraged.

Botulinum Toxin

Botulinum toxin is currently an extremely popular drug used by some physicians in almost every circumstance of perceived spasticity. There is no rational reason why this drug would be of any benefit in altering the course of scoliosis in childhood CP, primarily because it is extremely short acting. A significant component of the progression of the scoliosis curve is due to mechanical collapse because of rapid growth that botulinum would not affect.

Surgery

The only treatment for CP scoliosis that has a positive effect is spinal instrumentation and fusion. As posterior spinal fusion came to be the accepted treatment for idiopathic adolescent scoliosis, these same techniques were applied to selected children with CP. In the 1970s, Harrington rods and anterior Dwyer cable instrumentation were mainly used, with some reports of positive outcome.¹⁰ A major breakthrough occurred when Dr. Eduardo Luque introduced the concept of sublaminar wire fixation and the use of smooth stainless steel rods. This breakthrough led to an explosion of different facilities doing spinal fusions in children and young adults with CP. However, the early enthusiasm¹¹ was soon dampened by reports of high rates of post-operative curve progression in up to 30% of individuals,^{12, 13} high rates of instrumentation complications ranging up to 21% of individuals,¹⁴ and high rates of pseudarthrosis up to 10%.¹⁴ One problem with the Luque construct that was identified early on was related to driving the rod through the lateral wall of the ilium, providing no control of anteroposterior pelvic tilt. This method of driving the rod often caused pain at the ilium and large bone erosions. This problem was resolved very ingeniously by Ferguson and Allen¹⁵ with the Galveston technique of intermedullary placement of the rod into the ilium. Independent movement of the unconnected smooth rods was soon recognized as another major problem in the Luque construct for failing to provide stable fixation (Case 9.4). One method for stabilizing the construct was an attempt to use postoperative immobilization; however, this was found to make no difference.¹⁶

The next solution was to rigidly connect the rods, with The Texas Scottish Rite Hospital Group developing mechanical rod connecting plates. At the same time, the Hospital for Sick Children in Toronto worked on developing a unified connected rod called a Unit rod. For the past 15 years, the concept of requiring very rigidly connected rods has been widely accepted and is now the basis for almost all instrumentations in CP scoliosis. Because of the simplicity of the hardware, the Unit rod is the predominant instrumentation choice of surgeons who do high volumes of CP surgery.

Great difficulty exists in evaluating the published literature of spinal instrumentation because many articles mix together very different pathologies such as CP and myelodysplasia deformity correction. The mixed diagnoses make it almost impossible to separate out the problems related to CP scoliosis from the very different problems related to myelomeningocele scoliosis, muscular dystrophy, or spinal muscular atrophy. All these conditions have somewhat different indications for surgery and tend to have different complications. The following discussion attempts to separate out the specific diagnoses and focus only on the problems of correcting scoliosis in CP.

Unit Rod

The primary instrumentation for children with CP is the Unit rod (Figure 9.4). The Unit rod has the advantage of being cheaper, is completely prebent, has no risk of failure at connecting sites, and generally is very easy to use. The use of two smooth rods that are rigidly connected after implantation



Case 9.4 Leatrice

Leatrice, a 14-year-old girl with moderate spastic quadriplegia who had good speech and mild mental retardation, developed scoliosis requiring instrumentation using the Luque technique with unconnected rods (Figure C9.4.1). Initially, some correction was obtained; however, the intended lordosis all spun into the scoliosis (Figure C9.4.2). Over 3 years of follow-up with progressive growth, the rods shifted and rotated. After the fracture of one rod, 90° of rotation occurred with a rapid increase in symptoms

of respiratory restriction (Figures C9.4.3, C9.4.4). She was returned to the operating room where an anterior release was performed, followed by removal of posterior instrumentation, multiple level osteotomies, and repeat instrumentation using a Unit rod (Figures C9.4.5, C9.4.6). This procedure provided excellent trunk alignment and correction of the trunk malrotation, and completely relieved the restrictive respiratory symptoms.

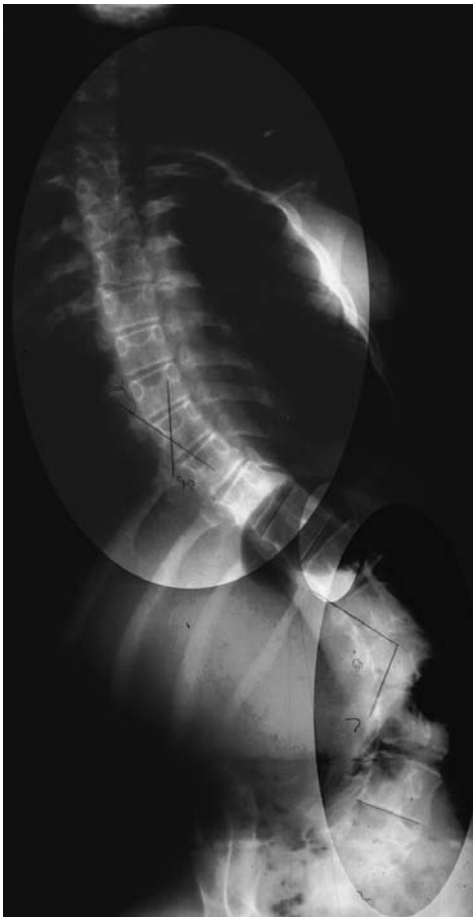

Figure C9.4.1

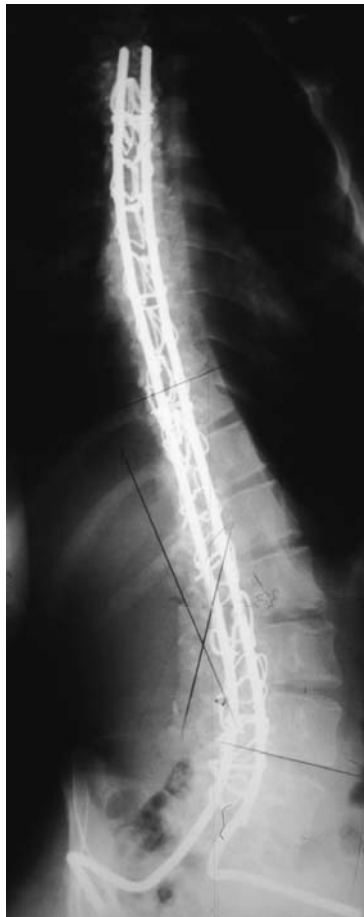

Figure C9.4.2



Figure C9.4.3

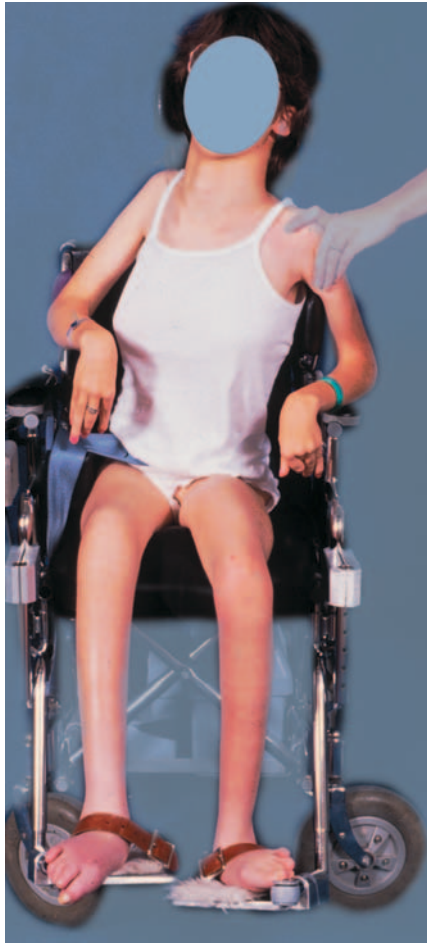

Figure C9.4.4

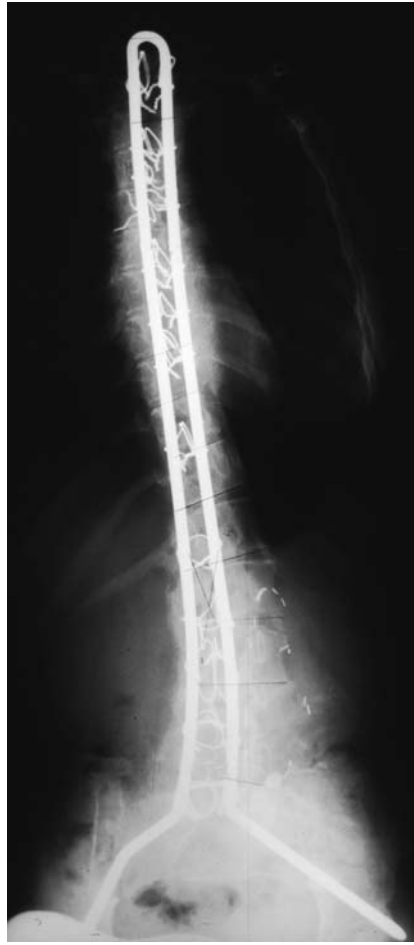

Figure C9.4.5

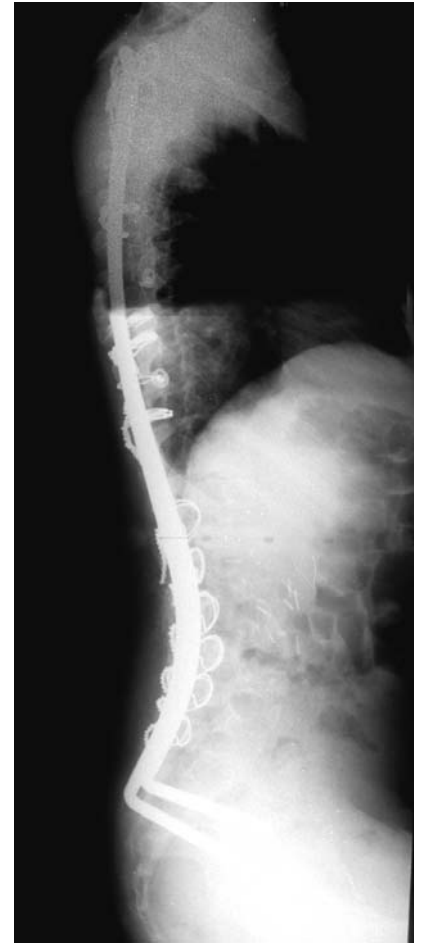


Figure C9.4.6

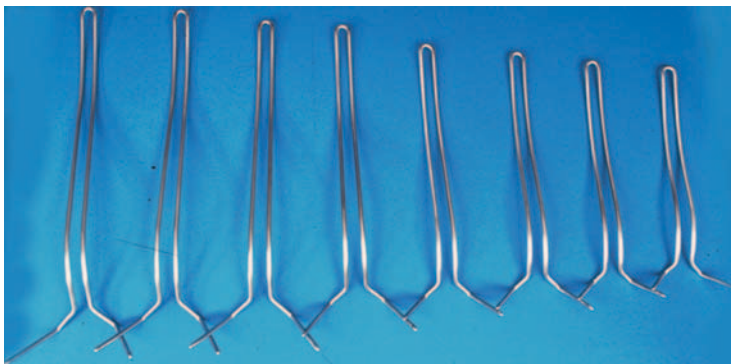

Figure 9.4. The Unit rod is available commercially from several vendors and comes in a range of sizes in 2-cm length increments. It is designed for fusion from the T1 to the sacrum so the pelvic limbs, lumbar lordosis, and thoracic kyphosis are all sized to the changing length of the rod.

into the pelvis provides the same mechanical benefits as the Unit rod with the exception that connectors may fail and the connection must be made with a correctly aligned rod before curve correction and rod wiring. The use of two rigidly connected rods is the second preferred technique if a Unit rod is unavailable or if a surgeon is unfamiliar with its use. Other hook and rod systems may also be used, but these are at much greater cost, greater complexity, and with less reported correction.

Indications

The indications for spinal fusion must consider children's age, medical condition, scoliosis magnitude, scoliosis flexibility, and the desires of families and caretakers. Scoliosis curve magnitude and age should be considered together because they are very closely related. For young children, less than 8 years of age, the scoliosis is usually very flexible and surgery can be delayed with seating adjustments. There are very rare, severe early curves that are discussed later in a special section. As children get to be 8 or 9 years of age, a standard instrumentation and fusion should be considered. For these young children, it is appropriate to allow the curve to go to a magnitude of 90° to 100° if it remains flexible. As individuals get older, 14 to 16 years of age, curves of over 60° should be considered for fusion because there is generally less remaining growth and minimal benefit in waiting. After the individual has completed growth and the curve is 30° to 40° or greater, spinal fusion is generally recommended because of the well-recognized risk of increased curve progression in adulthood.

In addition to age and curve magnitude, it is important to monitor the flexibility of the curve using the physical examination side bending test (Figure 9.5). With this test, the curve is considered flexible if it can be completely reversed on side bending as demonstrated by palpating the spinous process, and considered to be moderately stiff if it can be bent just to midline. If the curve definitely cannot be bent to midline, then it is considered very stiff and correction with posterior spinal fusion alone is not likely to be successful. For young children, 8 to 14 years of age, the curve can generally be monitored until it is in the moderately stiff category and still be corrected with only a posterior spinal fusion. In an occasional very small or exceptionally young child, allowing the curve to progress to severe stiffness to allow for spinal growth may be worthwhile. However, families must be aware that waiting means an anterior release will be required with a posterior correction. An anterior release is needed at all ages for very stiff curves and is never needed for flexible curves regardless of curve magnitude. Occasionally, older individuals who are past skeletal maturity and have curve magnitudes approaching or greater than 90° with moderate curve stiffness may benefit from an anterior release. In general, however, most children who are in the moderately stiff category do not need anterior releases.

Another indication when considering whether or not children should be having spinal fusions is their general health. General health is very subjective; however, children who have had poor medical care, have an extremely large and stiff curve greater than 120°, frequent respiratory infections, and extremely poor nutrition are considered at very high risk and are recommended against having spinal surgery (Case 9.5). These children also have a limited life expectancy. Another large factor in this decision-making process is the surgeons' and medical team's experience and comfort in dealing with severely involved individuals as to their sense of what is medically safe. There are no specific criteria that can be definitively made precluding an indication for spinal surgery. However, children's general medical condition and physicians' perceived risk should be brought together with families' desires. There are families who want all possible medical care for their children, and in the United States, it is families who legally make the final decision. If physicians are not comfortable with the specific procedure or the families' desires, they should suggest a second opinion from another physician with the required expertise. If two or three different medical opinions agree, families will usually come to understand the reality of the situation. However, physicians' opinions are often based more on philosophical opinions that these children

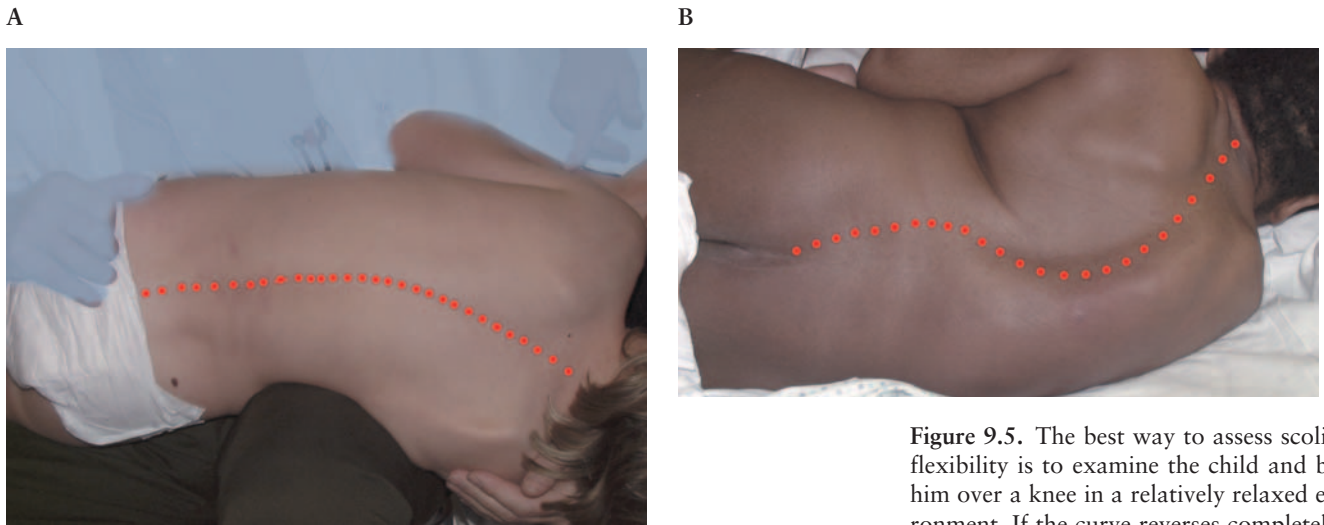


Figure 9.5. The best way to assess scoliosis flexibility is to examine the child and bend him over a knee in a relatively relaxed environment. If the curve reverses completely, it is flexible (A). If the curve does not decrease so the spinous processes come close to the midline with side bending (B), an anterior release is required to correct the deformity.

should not have surgery than on experienced medical facts as to the safety of having the surgery. It is not the place of physicians to make these philosophical decisions.

Families Choosing to Limit Treatment

Likewise, there are families who do not want to have surgery and it is very important that they be shown pictures and have a clear understanding of what not having surgery means for their children. Specifically, they must be told that the children will most likely stop being able to sit and will have to spend most of their time in a supine position. This supine position makes it almost impossible for the families to continue taking these children out into the community. Families should be pushed to decide for or against spinal surgery, because they are often unwilling to decide and will procrastinate until the children get so severe that the risk of surgery is significantly increased by both their general health and the need for an anterior release in addition to the posterior spinal fusion. Once families decide that they do not want to have surgery for their children's progressive scoliosis, it is important for the medical care system to support the families by continuing to provide supportive comfort care for the children.

There are families who want their children to be as comfortable as possible but do not want to prolong their lives. They may request the spine fusion, but with specific limitations on the medical care that will be provided. They often specifically request a "no resuscitation order," which must be carefully explained to them. These families must be told that this means the children will have to be on a ventilator as part of the recovery, but a no resuscitation order, meaning no mechanical or cardiac compression for resuscitation if that were required, would be honored. All other interventions would be discussed with families before proceeding, and they would have the choice of either agreeing to or rejecting the recommended intervention. Some physicians are not ethically comfortable with this kind of arrangement and should tell families and offer to refer their children to another physician. This order can lead to some very difficult decisions (Case 9.6). We had one child in whom the mother refused surgery to stop postoperative bleeding, and in another, the mother rejected a second resuscitation effort after the first succeeded.



Case 9.5 Chad

Chad, a 17-year-old boy with severe quadriplegia and mental retardation, was brought to the CP clinic on referral from an outside hospital where he had just been treated for pneumonia. He was fed by mouth, was cared for by his mother, and had never been in school. Recently, his mother was concerned that she was having trouble carrying him because he was getting taller. She could no longer sit him in a soft chair in which she typically kept him during the day. His current pneumonia was his first ever. On physical examination he was extremely malnourished with severe scoliosis, dislocated hips, and contracted knees and feet (Figure C9.5.1). When he was examined, his skin was so friable that it spontaneously opened with attempts at doing the side bending test for spine flexibility. A radiograph was obtained; however, because of severe osteoporosis, the degree of scoliosis could not be measured, although it was greater than 180° . Because his mother's main goal was to have a place to put him during the day, he was fitted with a foam-padded mobile stretcher and a deflatable Styrofoam bean bag (Figure C9.5.2). A very short life expectancy prognosis was also explained to his mother, and 9 months later, he again developed pneumonia and died.

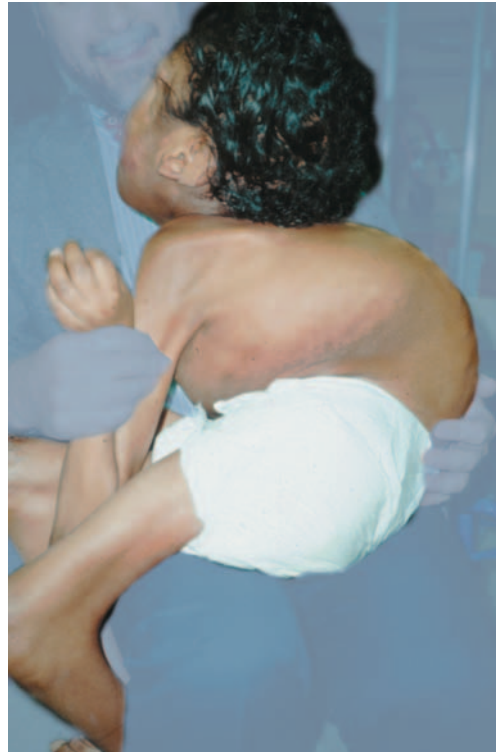

Figure C9.5.1

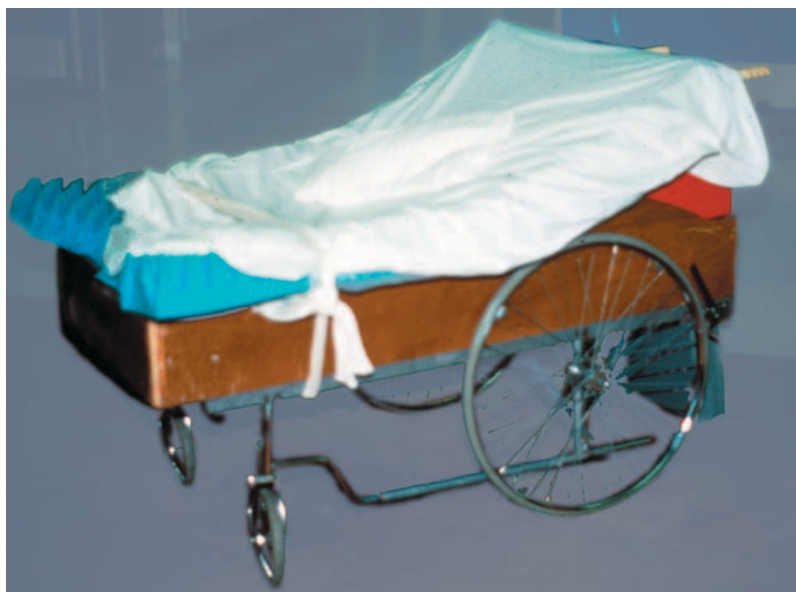

Figure C9.5.2



Case 9.6 Craig

Craig, a 19-year-old boy with severe spastic quadriplegia and severe mental retardation, was cared for in a group home sponsored by his parents. The parents continued to be very involved in Craig's care. He developed severe scoliosis and a spinal fusion was performed under a no resuscitation order, which was agreed to by the operative team. The surgical event and recovery were uneventful; however, 4 weeks after discharge he was brought back to the hospital with a temperature of 40.2°C, vomiting, and not tolerating any food. An examination determined that the source was likely an acute abdominal process, and

surgical exploration was recommended. The family refused because they felt this would be a life-saving procedure, not a life quality enhancement procedure. Within 12 hours of the family making this decision, he died of sepsis. An autopsy demonstrated a ruptured Meckel's diverticulum. There was significant frustration among the surgeons and nurses, and difficulty understanding how the family could agree to a very large operative procedure, such as the spine fusion, but refuse a simpler life-saving laparotomy.

Preoperative Workup

After families have decided to have the surgery, the preoperative workup should ensure that all medical conditions are under maximum medical management. Specifically, intraventricular shunts should be checked with radiographs and computed tomography (CT) scan to make sure that they are not broken and are functioning if the shunt is still needed (Figure 9.6). Seizures should be under maximum control, gastroesophageal reflux should be under the best possible medical management, pulmonary status should be maximized, and the children's nutrition should be as good as these families are willing to provide. There are no specific nutritional criteria that would preclude surgery, but children with no subcutaneous fat, poor food intake, and poor body weight for height should try to have nutrition improved by feeding supplementation, including consideration of nasogastric tube feeding if families agree. Some families, however, will refuse and actually suspect that the doctors are suggesting that they are not caring for or feeding their children adequately. There are also families who are very concerned that their children not become too large because they are dealing with the difficulty of having to physically lift these growing children. There is no good evidence that any specific nutritional level matters preoperatively if aggressive postoperative nutrition is carried out.^{17, 18} Clearly, however, children in severe stages of starvation should not have surgery and, in general, children with better nutrition probably have fewer complications and heal better.

Preoperative Preparation

Children with significant respiratory problems, temperature instability, and poor feeding should be admitted the day before the surgery with overnight preoperative hydration. It is also important that their body temperature is maintained above 35.5°C and their pulmonary status is documented to be stable. If children are brought to the operating room cold and dehydrated, it is often much harder to start intravenous lines, including increased difficulty in starting central lines and arterial line placement. Also, the sudden large-volume hydration and warming may make the physiology somewhat unstable even before the surgery starts. Many of these children are chronically dehydrated, especially poor feeders, and often have blood pressure drops

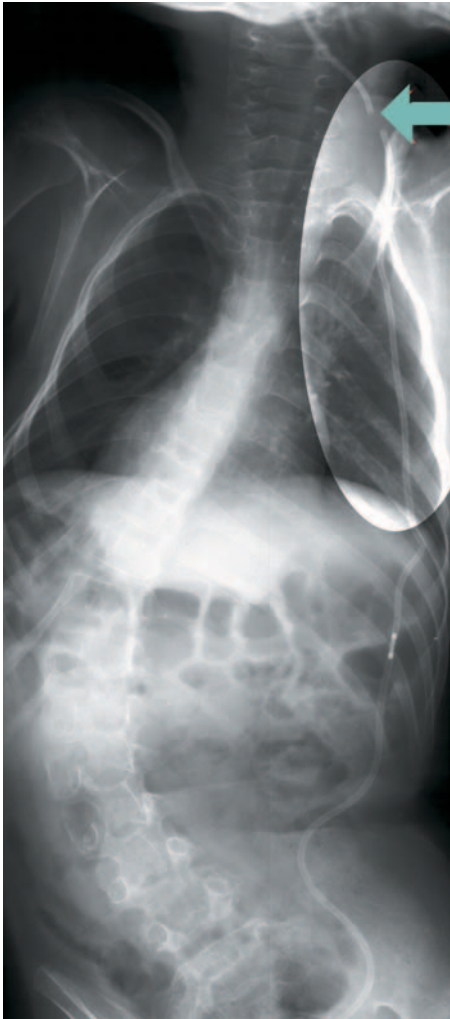

Figure 9.6. If the child has a functioning ventriculoperitoneal shunt before scoliosis correction, it should be checked. If there is a fracture in the shunt tubing, it does not mean that the shunt is not functioning. This patient had the fracture identified before surgery on the scoliosis radiographs; however, the shunt was not believed to be needed any longer. After scoliosis correction, the apparent open tract occluded and she developed acute hydrocephalus requiring shunt revision.

with the induction of anesthesia. Before children are taken to the operating room, there must be documentation of at least one blood volume of blood typed and cross-matched. This requirement usually means having six units of packed cells available with at least that much available in the blood bank for cross-matching if it should be needed later. The blood bank should also be ready to emergently prepare platelets and fresh-frozen plasma.

Anesthesia and Intraoperative Preparation

After children are anesthetized, the endotracheal tube must be well secured so that it will not dislodge. If children have a standard tracheostomy, an oral endotracheal tube is usually used to allow better securing of the tube. If children have a tracheal diversion, an endotracheal tube is inserted and secured with sutures at the level of the tracheal stoma. It is difficult to secure this type of tube with tape because the posterior aspect of the neck has to be prepped for the surgical field. Two large 18-gauge peripheral intravenous catheters need to be inserted if possible, and we always insert a double-lumen large-bore central venous catheter. The double-lumen central venous catheter is placed through a long tunnel in the subcutaneous tissue to decrease the risk of infection, and in this way, it can also become the access port for providing nutrition via central venous hyperalimentation. All children should have direct intraarterial monitoring of blood pressure, which also provides a port for obtaining blood samples to continue to monitor clotting factors, hemoglobin levels, and blood chemistry. If a percutaneous arterial catheter cannot be placed, a surgical cutdown of an artery should be performed to insert a catheter. A urinary catheter is required to measure urine output, and a nasogastric tube should be inserted to decompress the stomach. This stomach decompression may help with bleeding by decreasing the intraabdominal pressure. Many children with CP have had multiple medical problems with frequent hospital stays, often with multiple intravenous and arterial lines. In a few children these prior multiple lines may make insertion of intravenous access and arterial lines difficult. It is important for the surgical team to have patience at this stage of the procedure because short cuts may lead to disasters later. Very occasionally, preparation times of 1 to 2 hours should be expected.

After children are anesthetized and fully prepared, they are turned into the prone position on an operating table onto a frame that allows the abdomen to be suspended and the knees to be flexed to 90°. Following the usual prepping and draping, the surgical procedure is performed as detailed in the surgical procedures section. It is important to do a good fusion with decortication and facet resection with the use of copious amounts of bone allograft. In earlier versions of the procedure, only local bone graft was used and there were two rod fractures and pseudarthroses noted in large mobile adolescents.¹⁹ Also, there has been a report that children with CP have better correction and maintenance of the correction, less blood loss, and less anesthesia time when allograft is used as compared with autograft.²⁰

Postoperative Management

Postoperatively, children should be kept intubated, although this probably is not necessary in those who had a good surgical course, no preoperative oral pharyngeal dysfunction, and are in otherwise good medical health. Careful immediate postoperative monitoring of the blood pressure, temperature, hemoglobin, blood chemistry, and coagulation factors are important (Table 9.1). Postoperative management also requires that children be started on feeding on the second or third postoperative day. All children except those in excellent health and with relatively good motor function are started on

Table 9.1. Factors to monitor immediately postoperatively in the intensive care unit.

Parameter	Method	Interventions levels
Blood pressure	Direct arterial line	Systolic >90 mmHg
Central venous pressure	Central line	Approximately 5–15 mmHg
Urine output	Foley catheter	>0.5 ml/kg/h
Hemoglobin	Hemoglobin level	>10.0 in first 24 hours, >9.0 after 24 hours
Platelets		>75,000
Protome, prothrombin time		<1.5 times normal
Sodium		Normal range
Potassium		Normal range
Calcium		Normal range
Magnesium		Normal range

central venous hyperalimentation on postoperative day 1 or 2. They are then progressed to the preoperative feeding level as soon as possible. When gastrointestinal feeding has been reestablished, the central venous hyperalimentation is discontinued. As soon as children are extubated, they are gotten up in a chair, usually starting with a reclining wheelchair. These children should not be placed in their own wheelchairs until a physical therapist has evaluated and adjusted the chairs to make certain there are no pressure points. The dramatic change in these children's body shape usually makes the preoperative chair fit very poorly. By forcing children into these chairs, they run the risk of developing pressure points and skin breakdown. The children are discharged when they are eating approximately 1.2 to 1.5 times the recommended daily caloric requirement, are comfortable sitting in the wheelchair, the wound is dry, and they are afebrile. The children may return to school as soon as they can sit long enough, which usually is after 2 to 4 weeks at home. Families and caretakers are told that there are no restrictions on discharge and that the children may bathe, go swimming, and start all preoperative activities in which they are comfortable. For children who have an uneventful surgery and recovery, we try to have them home by postoperative day 7 and back to school by 3 weeks after surgery. When we first see them in the outpatient clinic 5 weeks after surgery, they are expected to be back to most activities but are still continuing to have some discomfort and decreased endurance. By 6 months of postoperative follow-up, we expect the children to have recovered fully and be back to all activities in which they were engaged in preoperatively.

Anterior Surgery

Anterior release is done to improve the flexibility of the spinal deformity, not for the goal of providing a fusion. The indication for anterior release is severe stiffness in any child and a large curve of more than 90° and moderate stiffness in an older child. In the past, we did the anterior surgery staged, with 1 week between the anterior and posterior procedures; however, in the past 8 years we performed the anterior surgery on the same day as the posterior surgery. In healthy children, having both procedures on the same day may enable them to recover more quickly and go home faster. However, for children with severe curves and multiple medical problems, the posterior surgery should be delayed for 1 to 2 weeks. We have found increased complication rates in same-day surgery when compared to staged anterior spinal release. Because anterior surgery is done to gain flexibility, no anterior instrumentation should be inserted and the disk spaces should not be packed

solid with bone graft. Only loose pieces of bone graft from the resected ribs should be inserted and most of that kept at the edge of the disk space.

Crankshaft

Crankshaft has been identified as a common cause of progression of scoliosis after instrumentation and fusion in immature children. Crankshaft was especially a problem in the original Luque system.^{12, 13, 21} With the use of the Unit rod, this concern has completely disappeared. We have found no progression in 29 immature children fused with the Unit rod before closure of their triradiate pelvic cartilages and followed to the completion of growth.²²

Other Instrumentation

There are sporadic reports of other systems, mainly hook and rod combinations, which report good results. However, all these reports have mixed populations of CP, myelomeningocele, and muscle patients that make any realistic assessment of their specific results in children with CP difficult.²³ These papers generally report more mechanical problems and more pseudarthroses, but approximately the same degree of correction as the Unit rod technique, in which the rod is fixed to the pelvis and the deformity is sequentially corrected proximally. Complexity of the instrumentation, cost, and length of operative time are all significantly greater than the Unit rod.

Outcome

The outcome of the technical improvement in the children's trunk alignment is excellent with the Unit rod. Correction of the scoliosis of 70% to 80% of the preoperative curve and correction of the pelvic obliquity of 80% to 90% of the preoperative curve with normalization of kyphosis and lordosis is expected.^{19, 24-27} With this kind of correction, caretakers and families express a very high rate of happiness with the procedure.²⁷ However, the subjective assessments of caretakers may be difficult to quantify based on specific functional gains or decreases in care requirements.²⁸

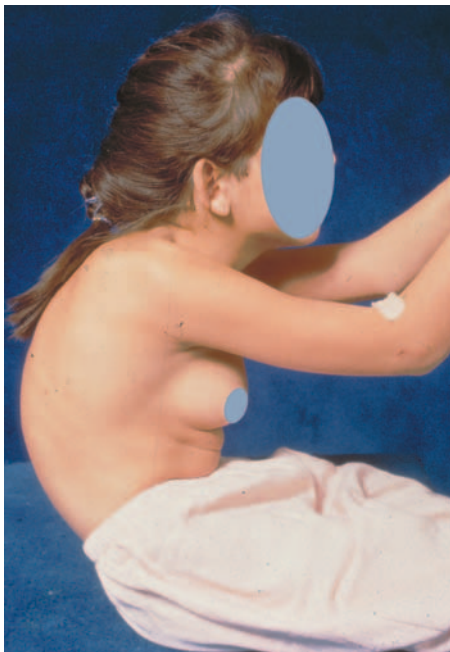

Figure 9.7. The etiology of kyphosis may be hamstring contracture. This is a typical posture with complete loss of lumbar lordosis and thoracic kyphosis caused by hamstring contracture.

Kyphosis

Kyphosis is common and is usually associated with scoliosis, although it does occur as an isolated deformity. There is, however, almost no reported literature on isolated kyphosis in CP.

Etiology

Tight hamstrings have frequently been recognized as a cause of decreased lordosis, which is then compensated for with increased thoracic kyphosis. The worst end of this spectrum is the type 1 anterior hip dislocation with the extended hip and knee. These children frequently end up with a fixed thoracolumbar kyphosis. A much more common cause of kyphosis is hamstring contracture or spasticity in 4- to 10-year-old children who sit with severe posterior pelvic tilt and compensatory thoracic kyphosis (Figure 9.7). When the knees are flexed, the kyphosis disappears. This is not a cause of permanent kyphosis; however, this natural history is not well defined. Another common cause of kyphosis is severe truncal hypotonia. The trunk collapses forward in these children and as they grow larger, it is more difficult to control this deformity with shoulder harnesses. Some children even seem to pull against the shoulder harness, trying to create kyphosis. Most children, as they

become adolescents, gain enough trunk tone that this collapsing kyphosis does not become a fixed deformity and they can be managed properly with wheelchair adjustments and shoulder harnesses. However, some children do develop fixed kyphotic deformities and continue to have substantial problems with seating, especially with holding up their heads to look forward and to eat. These fixed kyphotic deformities tend to occur near or at adolescence. Another etiology for thoracolumbar kyphosis, which has appeared in the last 10 years, is following the Fazano-type laminectomy for dorsal rhizotomy (Figure 9.8). This technique involves a limited rhizotomy at T12–L1, and we have seen three adolescents who developed a sharp kyphosis at the level of this laminectomy.

Natural History

For children in whom the cause of their flexible kyphosis is spasticity or contracture of the hamstrings, significant improvement occurs following hamstring lengthening. There is no direct relationship with these hamstring contractures and the later adolescent development of a fixed, kyphotic deformity. However, most adolescents have hamstring contractures, so this relationship continues to not be defined clearly. In general, however, the lengthening of hamstrings in adolescence when fixed kyphotic deformities are beginning does not provide much benefit. For children who develop severe fixed kyphotic deformities, seating and supine and prone lying become more and more difficult. If children have the ability to hold up their heads, a cervical extension or cervical lordotic contracture may develop. We have not seen significant complaints of pain as a consequence of kyphosis. However, if the kyphosis occurs following the thoracolumbar laminectomy, there is a tendency for it to get worse during the middle teenage years, and most of these individuals do complain of pain at the level of the kyphotic apex. The major problem with progressive increased kyphosis is the difficulty with functional sitting, especially with holding the head in an upright position (Case 9.7).

Treatment

The treatment of kyphosis in CP has not been previously reported; however, we have reviewed our experience, and most of the information is based on our experience of 30 children who have been treated surgically with spinal fusion.

Conservative

Most children with flexible kyphosis, especially those who have not reached adolescence, can be treated with appropriate seating adaptations or orthotics.

Seating

The primary treatment for kyphotic deformities in childhood is appropriate seating. For children with tight hamstrings, it is very important to keep the knees flexed at 90° to 100°. Some physical therapists tend to want to stretch the hamstrings in the wheelchair so they do not become more contracted; however, all this does is tilt the pelvis posteriorly and make children have more difficulty seating because of the compensatory kyphosis. It is important to have a properly adjusted shoulder harness with the superior attachment of the harness being higher than the shoulders when children are sitting in the maximum upright position. A very common problem with poor wheelchair fitting is that the shoulder harness has a posterior attachment significantly below the level of the shoulders, which depresses the shoulders and

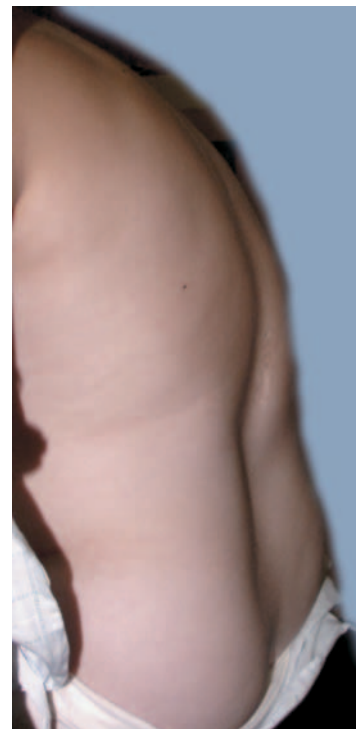

Figure 9.8. Kyphosis that is present in the thoracolumbar junction with normal hip movement has only been seen as a residual deformity from dorsal rhizotomy in the technique of a localized exposure of only the thoracolumbar junction. Normal lumbar lordosis is present below the kyphosis.



Case 9.7 Yeiska

Yeiska, a 15-year-old girl with moderate quadriplegia and truncal hypotonia, had a kyphosis that became more fixed and made it difficult to hold up her head (Figure C9.7.1). The kyphosis was located in the midthoracic spine on radiograph examination (Figure C9.7.2). The harness in the wheelchair could no longer keep her erect so she was tilted back in the chair. Surgical correction was recommended to include an anterior release because of severe

stiffness present in the kyphotic area of the thoracic spine. Postoperatively, she had better head control even before she was discharged home from the hospital (Figure C9.7.3). The instrumentation extended to T1 and provided excellent correction of the kyphosis (Figure C9.7.4). Her head control remained permanently improved, as did her seating posture.

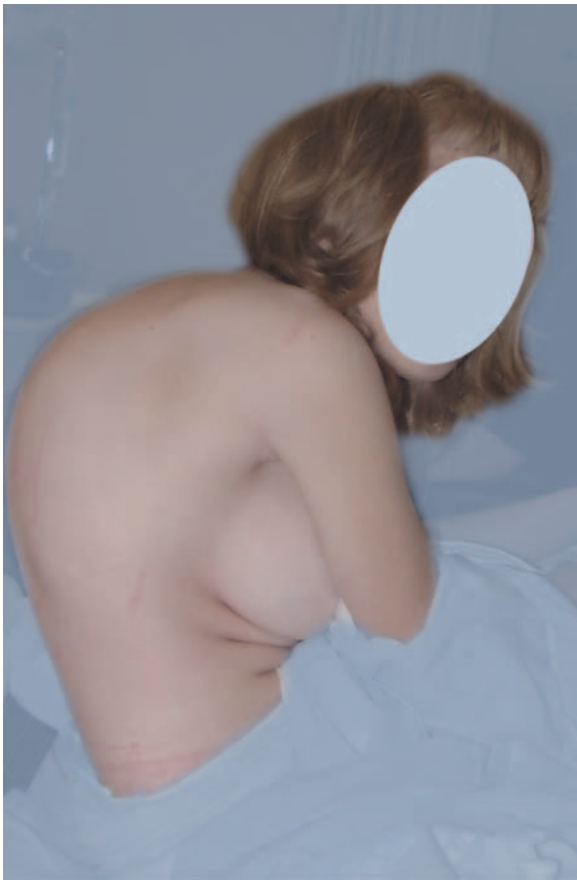

Figure C9.7.1

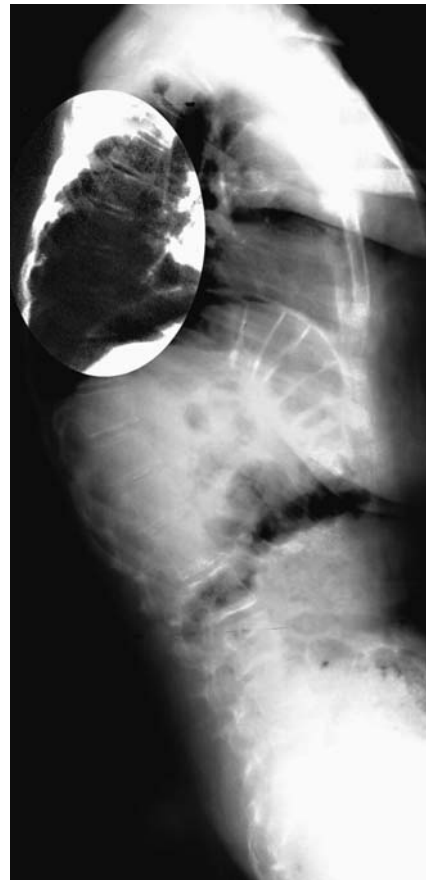

Figure C9.7.2

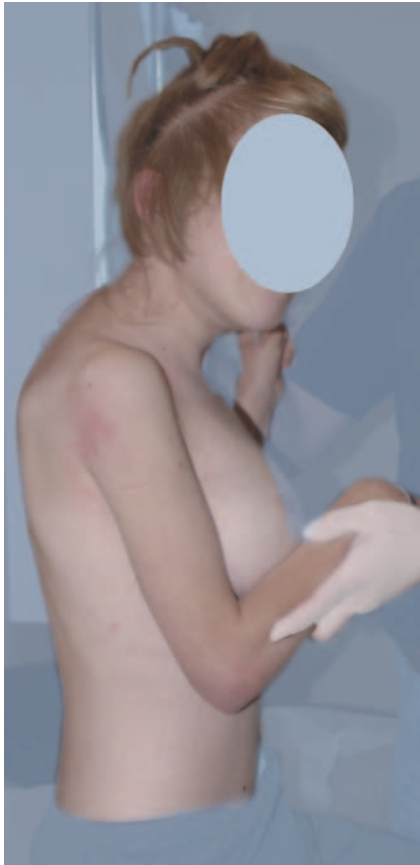

Figure C9.7.3

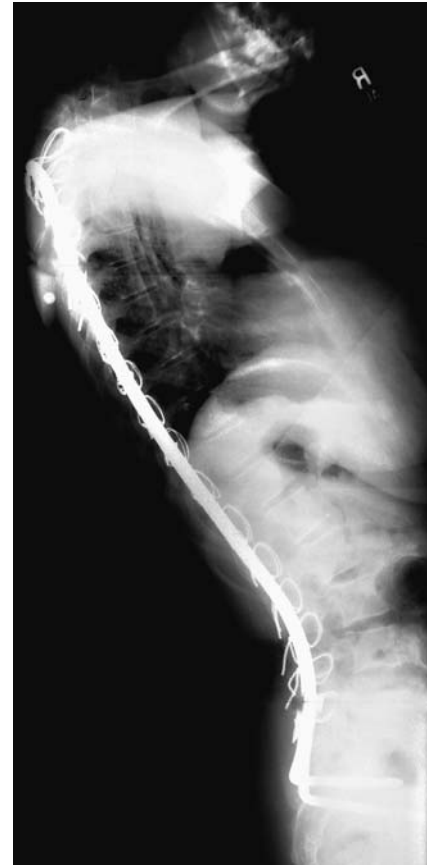

Figure C9.7.4

feeds into the kyphosis. This poor fitting may occur because of poor understanding by the technician who adjusted the chair at the original fitting; however, it often occurs because children are growing rapidly and no one is keeping the chair adjusted for this growth. Therefore, it is very important for physicians to check the appropriate fitting of the wheelchair during routine outpatient visits. As the kyphotic deformity starts to become fixed, the back of the wheelchair may need to be contoured to accommodate the deformity. Trying to force this fixed deformity into a corrected position does not work, as it will only cause poor wheelchair fitting and difficulty with sitting.

Another very important aspect of seating adjustment in the treatment of kyphosis is to keep the lap tray of the wheelchair high. If the arms are allowed to drop onto children's laps, they tend to accentuate the kyphosis. If the arms are elevated on a tray on the wheelchair to a level close to children's nipple line, they will be forced to sit more upright. In this way, children can also use the arms to help push themselves upright. If children do not use a wheelchair tray, desks or other work surface areas they use should be at this appropriate elevated height to discourage collapsing forward into kyphosis (Figure 9.9).

Orthotics

For children who cannot be comfortably fitted in a wheelchair and for those few ambulatory children who develop symptomatic kyphosis, the use of a trunk orthosis can be functionally beneficial. Because the tendency to fall forward places considerable pressure on the anterior aspect of the orthotic,

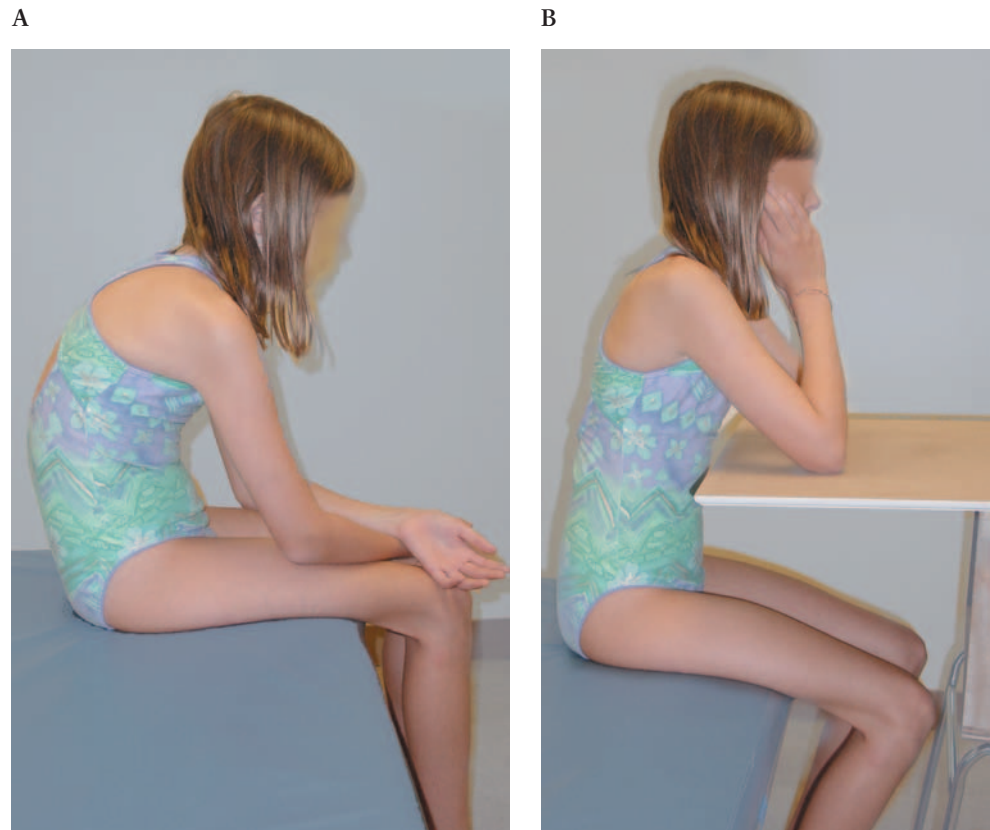


Figure 9.9. It is very important to have appropriate seating for children with poor trunk control. The work surface for upper extremities or the lap tray needs to be placed between the lower aspect of the rib cage and the nipple line. Asking the child to sit in a regular chair or wheelchair without arm support invites collapsing into kyphosis (A). By providing the elevated rest area for the arms, the trunk extends (B).

it is necessary to use a custom-molded solid plastic bivalve TLSO, which can be kept quite low posteriorly. However, the anterior shell has to come to the sternal clavicular notch and must be maintained low to the level of the anterosuperior iliac spine. A stomach hole may be cut out if needed for comfort or feeding purposes. The goal of this orthosis is to provide functional improvement and not to prevent development of a rigid deformity. There is no evidence of the impact of this orthotic on the development of a fixed deformity; however, based on data from scoliosis bracing in children with CP, we do not believe that it has any beneficial long-term effect. The orthosis is to be used only during the day, in a pattern that children and caretakers find to be most useful functionally.

Surgery

For adolescents with fixed deformities and those individuals with large flexible curves who are having significant functional problems with sitting and lying, the only definitive treatment is spinal instrumentation and fusion. The goal of this surgery is first and most importantly to correct the deformity and then to fuse the spine so it stays corrected. By lying children supine and trying to hyperextend the back, a good sense of how stiff the deformity is can be obtained. If children cannot lie supine comfortably, an anterior release over five or six levels at the thoracic apex of the curve is usually needed. If children can lie comfortably on a hard examination table in the prone position, then the deformity can usually be corrected with a posterior procedure only.

Unit Rod

Most children who need spinal instrumentation are dependent sitters and their main functional problems are related to poor sitting posture. This pos-

ture often involves a thoracic kyphosis that extends into the lumbar spine with some hypolordosis of the lumbar spine. To treat all components of the deformity, it is necessary to instrument the spine from the pelvis to control the posterior pelvic tilt as well as increase the lumbar lordosis and decrease the thoracic kyphosis. The instrumentation is performed with a procedure similar to the scoliosis procedure. It is extremely important to have the instrumentation far enough proximal because the apex of the kyphosis is often quite high, sometimes to T4. This high apex may be an indication to instrument to C7; therefore, it is important that the rod size is long enough, but not so long that it will become prominent. If the rod is a little too long, rod benders should be used to curve it anteriorly so it will be less prominent superiorly. As the superior aspect of the stiff kyphosis is wired, it is important that hard pressure be held against the cranial end of the rod, pushing it to the spine until all wires are tightened so that wires will not pull through the lamina. Postoperative care is the same as for scoliosis treatment.

When to Fuse Short

Occasionally, in adolescents who are ambulatory and have thoracic kyphosis, it is not necessary to fuse to the pelvis. Several individuals whom we have fused have been large adults, and correcting the kyphosis puts a large force on the caudal end of the fixation. Various instrumentations with either a hook or a wire construct cranially may be used; however, the caudal end should be fixed with two sets of pedicle screws. Wire breakage and hook pullout have been encountered at the caudal end of the kyphotic instrumentation. There is one case report where only one set of pedicle screws were used and a chance fracture developed through the body of the vertebra as the screws pulled out.²⁹ Also, the instrumentation should start with cranial fixation first and then move caudally. This method gives a much longer lever arm on the rod and makes it easier to manage correcting the kyphosis.

Lordosis

Lordosis is commonly associated with scoliosis and it tends to make correction of the scoliosis significantly more difficult. Moderate lordosis is also a common deformity in ambulatory diplegia.³⁰ Most of these children have lordosis of 50° to 60° and have occasional complaints of back pain. This increased lordosis is probably also associated with a higher rate of lumbar spondylolisthesis and, therefore, if the back pain is felt to be significant and long lasting, a workup for an acute spondylolysis should be performed. We have also seen several children who have had workups for abdominal tumors because of an abdominal mass that the pediatrician palpated. This abdominal mass is the spine, which is often visibly protruding in the anterior aspect of the abdomen when severe lumbar lordosis is present. Many pediatricians are not aware that the spine may present as an abdominal mass, especially that the spine may be eccentric if there is some scoliosis present.

Etiology

There are primary and secondary causes of lumbar hyperlordosis. The most common primary cause of isolated severe lumbar lordosis in children with CP is the sequelae of multiple level lumbar laminectomy performed during dorsal rhizotomy. These sequelae are most common in nonambulatory individuals and accounts for 60% of primary lumbar lordosis that requires surgery in our facility (Case 9.8). For children who develop primary fixed



Case 9.8 Kevin

Kevin, a 14-year-old boy, was nonambulatory due to spastic quadriplegia. Upper extremities were functional so that he could feed himself, and he communicated well, although he had moderate mental retardation. Five years before this visit, he had a lumbar rhizotomy in which the laminae were replaced at the end of the procedure. Initially after the dorsal rhizotomy, he had a great decrease in his spasticity; however, over the past several years the spasticity returned, which has made dressing of the lower extremities difficult. Although he had always had a mild increase in lumbar lordosis, as the spasticity increased and he started into his adolescent growth, his mother felt it got worse, and he complained of back pain when he sat the whole day. The wheelchair was modified by raising the

front of the seat to close the seat back angle to 80° , and his mother was encouraged to have him spend time out of the wheelchair at least once in the middle of the day. On the next clinic visit, 6 months later, his mother stated that the back pain had increased so much that his sitting tolerance was less than 2 hours. On physical examination, he had a significant increase in lumbar lordosis and was expressing definite low back pain from sitting only a short time (Figures C9.8.1, C9.8.2). Following an excision of the lumbar disks from L4 to T12, he had a posterior spinal fusion with Unit rod instrumentation on the same day (Figure C9.8.3). This procedure immediately improved his sitting ability and tolerance (Figure C9.8.4).

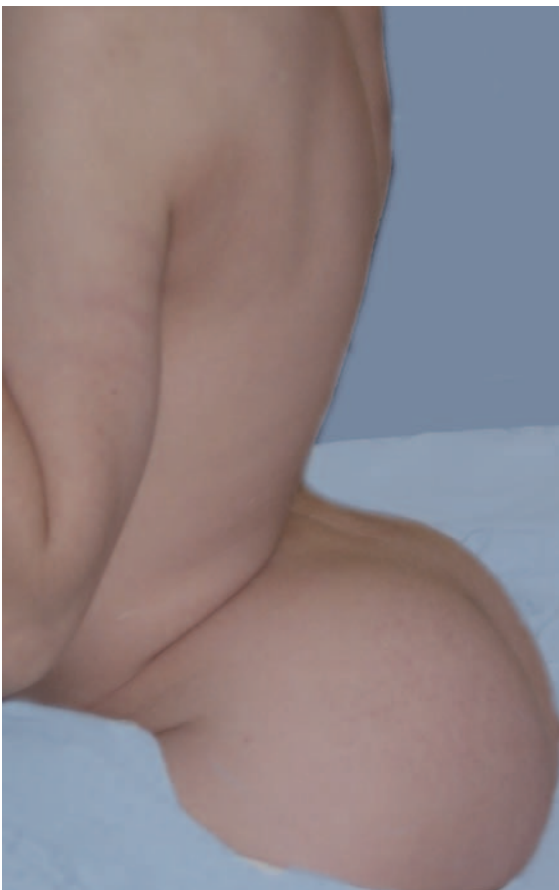

Figure C9.8.1.

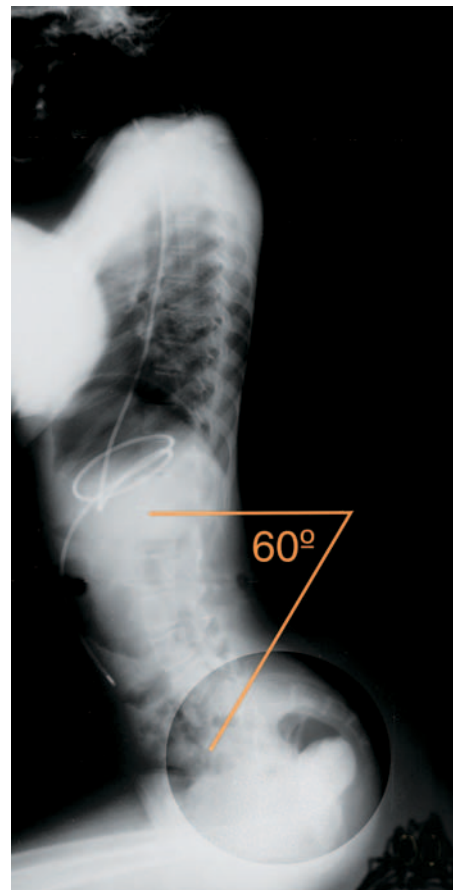


Figure C9.8.2

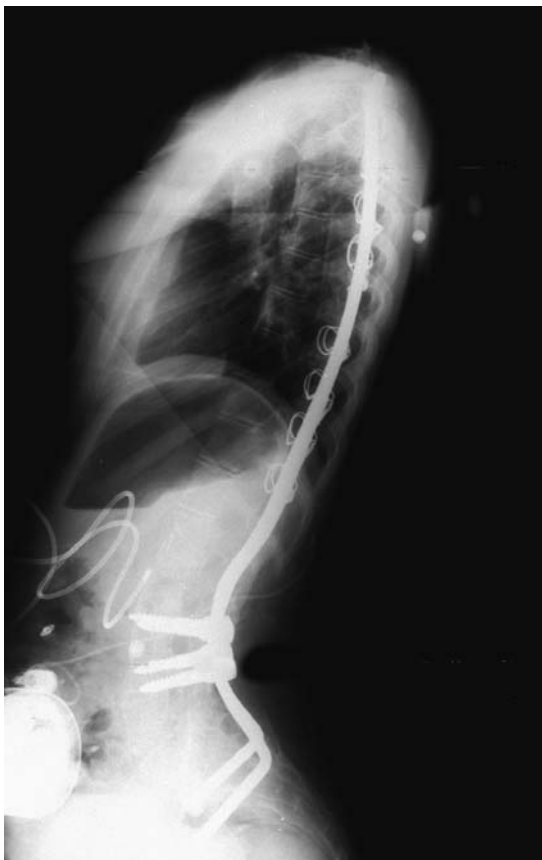

Figure C9.8.3

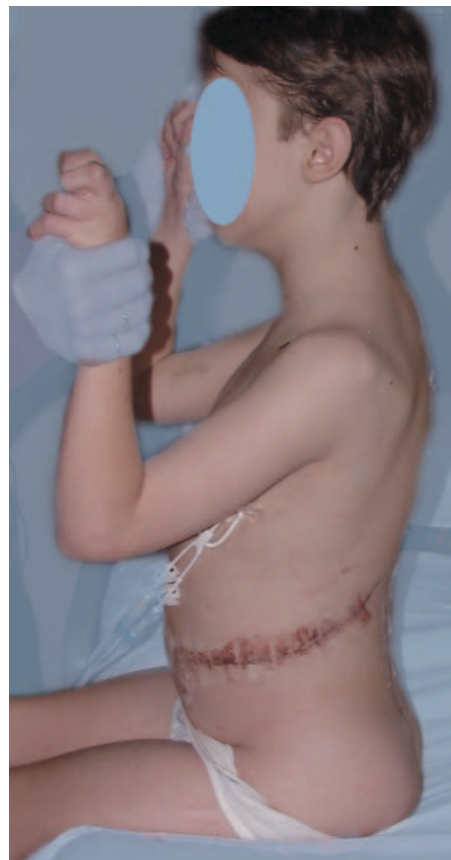

Figure C9.8.4

lumbar lordosis without evidence of a secondary cause, a magnetic resonance imaging (MRI) scan of the spine is indicated to rule out a tethered spinal cord. There are rare children who develop a severe primary lordosis that becomes fixed and has no secondary recognizable etiology.

Severe lumbar lordosis most commonly occurs as a secondary compensating deformity due to anterior pelvic tilt. The primary cause of this anterior pelvic tilt is further discussed later, but it may be due to hip flexion contracture and spastic contracted hip flexors that are not balanced against adequate hip extension.

Natural History

In the most common, moderate degree of lumbar lordosis seen in ambulatory diplegia, there is seldom a need to provide any treatment intervention beyond an occasional antiinflammatory for mild back pain. These adolescents are encouraged to stay flexible by doing daily stretching, which seems to help keep them more comfortable. It is not clear if there is a relationship between this early increased anterior pelvic tilt and the rare development of severe fixed lumbar lordosis in some adolescents. For adolescents who develop severe lumbar lordosis, usually in the range of 80° to 140° , most eventually develop increasing pain. Children who have had a dorsal rhizotomy tend to have a rather sudden increase in the magnitude of the lordosis during rapid growth, often followed by significant back pain and discomfort in

sitting. Often, by the time they start developing significant functional problems with sitting, the lordosis will be 120° to 140° during sitting, making it very difficult for these children to sit straight upright without falling forward.

Treatment

For children in whom the lordosis is secondary to the anterior tilt of the pelvis usually due to hip flexion contracture, the treatment is directed at the primary etiology. However, if the lumbar lordosis has become painful and fixed, even if it was initially caused by an infrapelvic anterior pelvic tilt, it still requires direct surgical treatment.

Conservative Treatment

There is very little role for nonoperative treatment in significant lumbar lordosis. Encouraging children to stay flexible when the curve is mild to moderate is recommended.

Orthotics

There are no orthotics that are useful in the management of severe lumbar lordosis. The pressure that would have to be placed against the anterior abdomen cannot be tolerated.

Seating

The only reasonable seating adaptations that can accommodate severe lumbar lordosis are keeping the seat back angle to approximately 80° and elevating the anterior aspect of the seat by approximately 10° to 15° to try to tilt the pelvis posteriorly.

Surgery

The only treatment that has any significant impact on severe lumbar lordosis is surgical correction and fusion. The indications for correction and fusion first require correcting the deformity followed by instrumentation and fusion to maintain correction. If the deformity is not corrected, children's sitting postures will not improve. Correcting severe lumbar lordosis almost always requires an anterior release, which should include a large anterior wedge-shaped resection of the disks, especially at the apex of the lordosis. Inexperienced surgeons tend to think that the anterior release will be easy to perform by doing a direct anterior approach. However, this deformity should be approached by the standard lateral retroperineal approach because the direct anterior approach will encounter many structures tightly draped over the midline with the aorta displaced over the left side of the spine and the vena cava displaced over the right side of the spine. All major vessels, such as the renal artery and vein, will be tightly draped over this apex of spine, making the approach extremely difficult. Also, it is a very difficult approach from the lateral side if the curve is large and stiff; however, with patient dissection, the kidney and spleen can be mobilized and brought anterior so the apex of the lordosis can be approached safely through the retroperineal space. Large anterior-based wedge resections are required of each disk.

Unit Rod

The posterior instrumentation for lordosis is very technically demanding. For children who have had a laminectomy for dorsal rhizotomy, pedicle screw fixation in the area of the laminectomy is required. Placing these screws is very demanding, as often the posterior anatomy is extremely difficult to define. Usually, the facets are intact and become the most reliable

landmark. If the laminae have been replaced after laminectomy, there are often partial vertebral fusions at different levels that need to be taken down. After the facets are identified, it is usually possible to palpate the pedicle on the inside of the spinal canal with a blunt instrument. By using the facets and the palpated pedicle, the pedicle finding awl can be used to make a tunnel for the screws. We have not found fluoroscopy to be very helpful in the placement of these pedicle screws. Because of the lordotic deformity, it may be difficult to place screws on both sides at every vertebra, as the screws tend to interfere with each other through the apex of the lordosis.

If pedicle screws are used, it is easiest to place a short rod on one side and then distract the pedicle screws to correct the apical lordosis. The Unit rod can then be inserted into the pelvis in the standard fashion and often set into the screws on the opposite side. The short rod can be connected with rod connectors to the Unit rod (Case 9.9).

Because most children who develop severe lumbar lordosis are primarily sitters, we routinely instrument into the cranial aspect of the thoracic spine to T2 or T3. This instrumentation assures a well-balanced spine for sitting and adds little or no morbidity. For this reason, we prefer to use the Unit rod. However, when lordosis is severe, the Unit rod is technically very difficult to insert into the pelvis. One option is to cut the Unit rod on one side at the thoracolumbar junction and insert each part of the rod separately, bringing the pieces together in situ and reconnecting them with rod connectors (Case 9.10). Another option is to bend the rod into hyperlordosis, insert it into the pelvis, and then bend the hyperlordosis back out after the rod has been inserted. This technique may be more difficult because bending the lordosis and then bending out the lordosis without affecting the torsional alignment of the Unit rod is difficult.

If the posterior laminae have not had previous surgical violation, then the routine use of sublaminar wires through the lumbar spine is adequate and much simpler. When the rod is inserted into the pelvis in this situation, reducing the lumbar lordosis before rod insertion as much as possible is important. This reduction can be assisted by placing a rigid block anterior to the abdomen so the anterior aspect of the protruding spine rests on a solid block. Pressure can then be placed on the pelvis and at the thoracic spine to create maximal manual correction. This pressure against the anterior aspect



Case 9.9 Lemika

Lemika, a 14-year-old girl, presented 6 years after having had a dorsal rhizotomy. Her main complaint was difficulty sitting (Figure C9.9.1). She had moderate spastic quadriplegia, self-fed, and had mild mental retardation. On physical examination the spinal deformity appeared to be relatively fixed, especially the lordotic component (Figure C9.9.2). She was otherwise in good health and took no medications. She was taken to the operating room where the anterior release was performed first, followed by the posterior instrumentation using a Unit rod with

pedicle screws. A short rod was used on the convex side of the scoliosis and attached to the Unit rod with rod connectors. The pedicle screws on the concave side were set into the Unit rod directly. She had an uneventful recovery, and by the fifth postoperative day was sitting with excellent balance (Figures C9.9.3, C9.9.4). Radiographs also showed good correction of the deformity (Figures C9.9.5, C9.9.6). There has been no change in this spinal alignment over a 5-year follow-up.

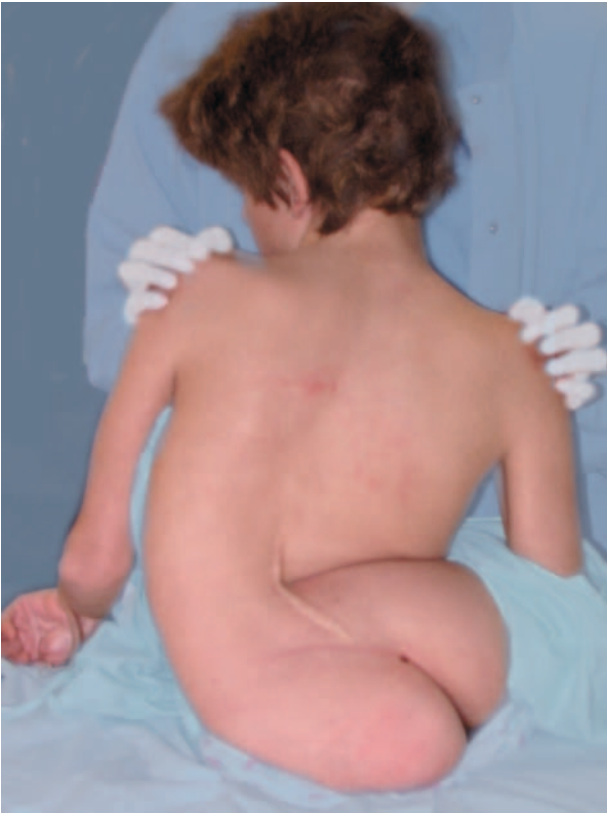

Figure C9.9.1

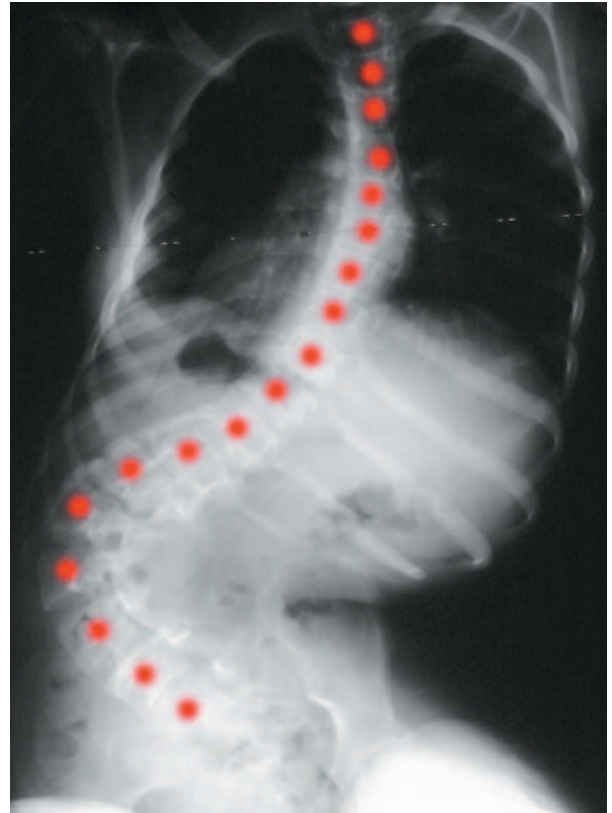


Figure C9.9.2

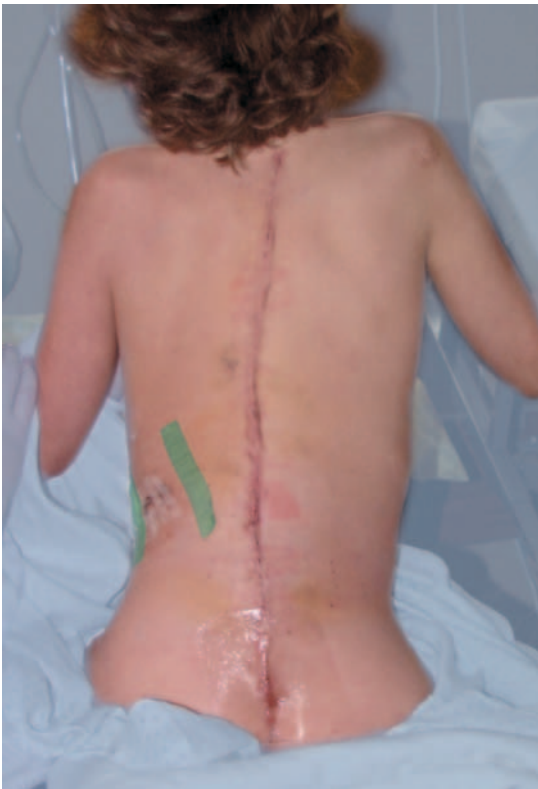

Figure C9.9.3

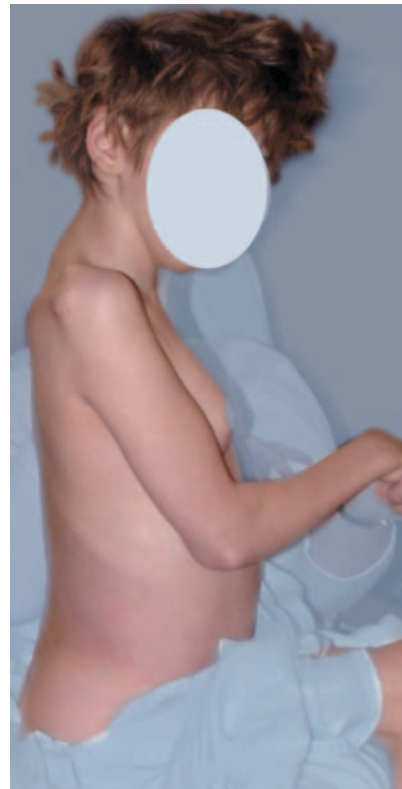

Figure C9.9.4

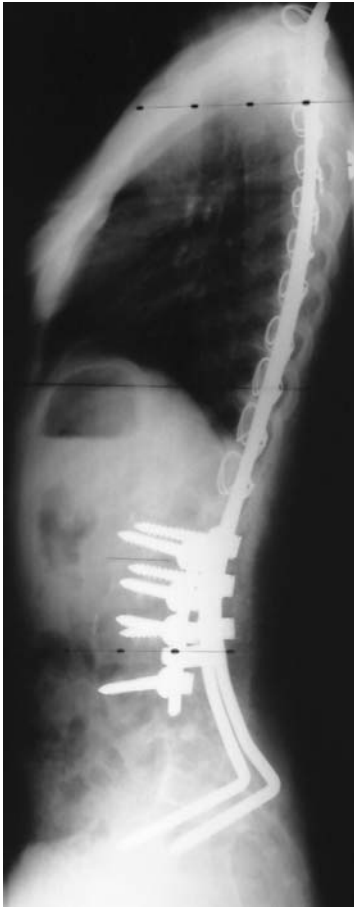

Figure C9.9.5

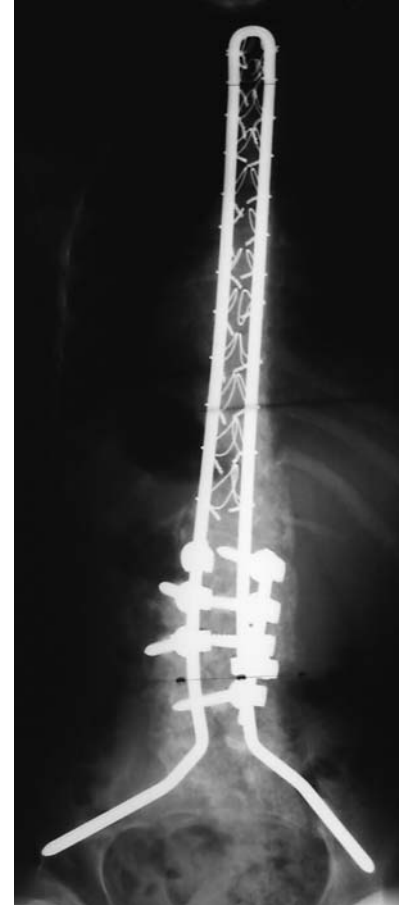


Figure C9.9.6

of the abdomen may temporarily increase bleeding; however, it is left in place only until the rod is inserted and the lumbar wires have been tightened (Figure 9.10).

Postoperative management of children with severe lumbar lordosis is the same as instrumentation for scoliosis with two exceptions. These children are at special risk for developing duodenal obstruction or cast syndrome as

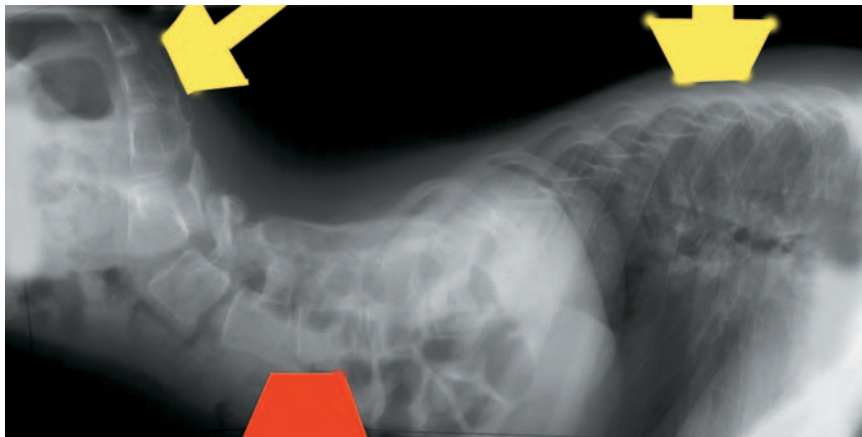


Figure 9.10. Intraoperative correction of lumbar lordosis requires the ability to use three-point bending. This may require a block on the anterior aspect of the lumbar spine with assistants pushing down on the sacrum and chest. This technique is helpful in inserting the Unit rod into individuals with significant lordosis. In cases with severe lordosis, the rod needs to be cut and then reconnected after it is inserted.



Case 9.10 Emily

Emily, a 10-year-old girl, presented with severe lordosis, which significantly limited her sitting tolerance (Figure 9.10.1). She was 2 years following dorsal rhizotomy and still had fair lumbar flexibility; therefore, she was scheduled for only posterior spinal instrumentation. To insert the Unit rod into the pelvis, one side was cut at the thoracolumbar junction, and each side was then inserted

separately, and the rod was reconnected. Postoperative oblique pelvic radiographs confirmed that the rod was in the pelvis (Figure 9.10.2). Only one rod connector was used; however, we now believe this was not sufficient because we have had many failures of these connectors. Another cross-connection should be inserted distal to the first connection.

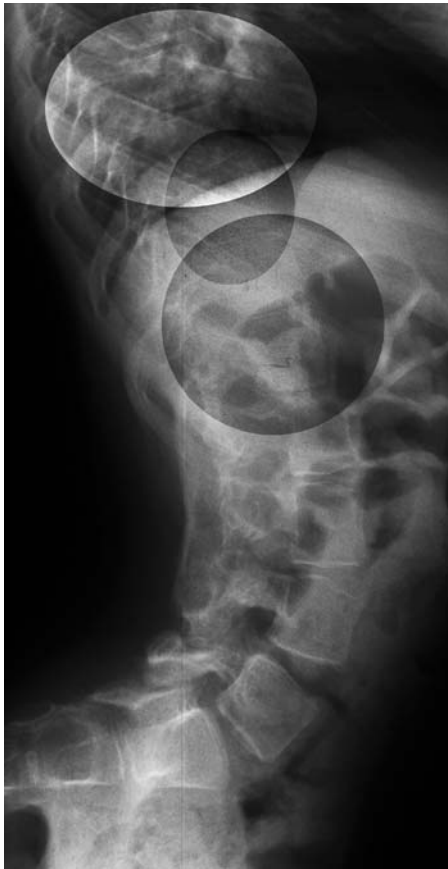

Figure C9.10.1

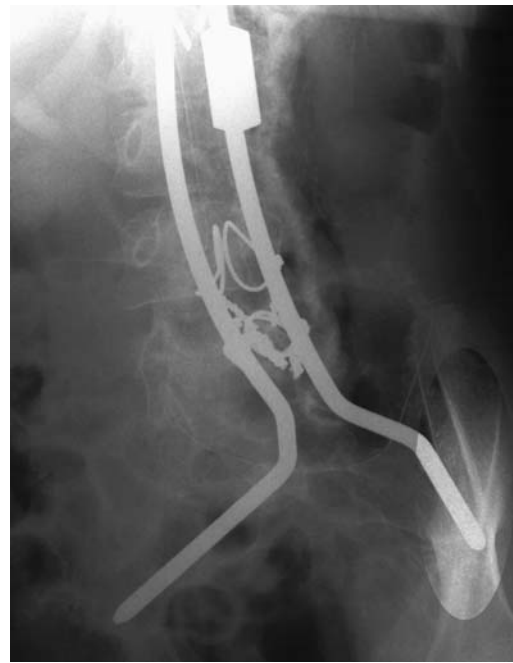


Figure C9.10.2

they start feeding. Also, as these children are mobilized, they may complain of a period of neuritic pain in the lower extremity, and several children have complained of areas of numbness. This neuritic pain is probably caused by the extensive nerve stretch that occurs when lumbar lordosis is corrected as the posterior neuronal structures undergo some lengthening. All patients have overcome this neuritic pain syndrome and the numbness has resolved; however, it occasionally requires up to 1 year.

Complications of Spine Surgery

Complications of posterior spinal fusion in children with CP are common. Most of these complications are relatively self-limiting and resolve with appropriate management. From an extensive review of 107 spinal fusions in children with CP, the best predictor for risk of complication is severity of the neurologic disability. The level of the neurologic involvement is defined based on a score that combines the ability to speak, walk, eat, presence of seizures, and intelligence. Based on assessing these five areas, there was such a strong correlation to neurologic disability that the presence of additional risk factors such as tracheostomy, tracheal diversion, gastrostomy tubes, seizure drugs, or malnutrition were not correlated with additional risk.¹⁸ One other report suggested that poor nutritional indicators, as defined by low absolute lymphocyte count and low albumin, increase the risk of complications, which are defined as urinary tract infection, length of intubation, and length of hospital stay.¹⁷ This relationship was not present in our patients and we suspect this is partly because the more neurologically involved children had a more prolonged course of postoperative lack of nutrition. At this time, we believe the overriding risk factor for complications following spine surgery is the severity of the children's neurologic disability. It is difficult to know how to use this information to counsel families, but physicians have to be honest with this risk. For families who want to aggressively pursue medical care, this risk is usually not a significant concern because the alternative of the child becoming bedfast is difficult for them to manage as well.

Children or adolescents who have a spinal fusion for severe scoliosis usually also have many other multiple system problems. These problems, combined with the large magnitude of the surgical procedure, mean that these children are at risk for almost any medical problem that can be imagined. This discussion of complications will focus only on serious complications that have been encountered or that are encountered frequently. In reality, this covers almost every complication encountered in the 340 children with CP in whom we have done a spine fusion. Several notable areas are missing from this complication list, mainly thromboembolic disease. We have never seen pulmonary embolus or deep venous thrombosis in children or adolescents undergoing surgery. If thromboembolic disease was considered because of asymmetric swelling in the lower extremity, it has always been heterotopic ossification (discussed in Chapter 10) or a fracture. Therefore, the concern about thromboembolic disease rarely needs to be raised, and then only after every other alternative has been ruled out.

Death: Mortality

The most significant complication of spinal surgery is death. This is the only surgery in CP where there is a definite risk of mortality, although all surgery carries this risk at some level. There are no literature reviews that specifically evaluate the mortality rate, although series reporting mortality range from 31%³¹ to reports that include one death.^{16, 32, 33} Also, there are many series of small numbers of patients that report no deaths. In the last 12 years, we have performed 340 spinal fusions in children with CP and have had three deaths in the acute postoperative period. This result translates into a rate of slightly less than 1% mortality; however, these three deaths occurred in the most involved half of our children. Therefore, a more accurate risk is three deaths in 170 children for a rate of approximately 1.7%. This is a reasonable rate based on conversations with other centers for this group of children who have the most severe neurologic involvement with no speech, no

self-feeding, requiring gastroesophageal tube feeding, and who are fully dependent sitters. To maintain a low morbidity rate in these severely disabled children, high-volume experience and good protocols with multidisciplinary care are required. It is as important when comparing mortality rates as it is when comparing general complication rates to consider the severity of the children's neurologic deficit. It is also important to do a careful case evaluation of all deaths, as often the death may have been due to a preventable cause and lessons can be learned.

Specific causes of intraoperative death are usually bleeding that was not appropriately managed. With proper preparation and anesthesia, as well as surgical management, this should almost never happen, and every death due to excessive blood loss needs very careful attention to identify the causes of treatment failure. Another reported intraoperative cause of death is air embolism,³² and we are aware of two other cases that have not been reported. The usual scenario of an air embolus is a child whose blood pressure is dropping from hypovolemia, in which the anesthesia team responds by decreasing the anesthesia level. At a time when many epidural spaces and epidural veins are open, this child under light anesthesia starts breathing on their own, drawing air in through the open venous sinuses. Air embolism is totally preventable in that children should always be under full neuromotor paralysis during this procedure to avoid inadvertent negative pressure in the chest cavity. Other causes of intraoperative death, such as dislodgment of the endotracheal tube and loss of vascular and arterial access, are all preventable by appropriate preoperative preparation.

Transition Time

Another high-risk time is in the transition from the end of the operative procedure until children are completely set up in the intensive care unit. For two deaths, the initiating event began in this time frame. One child had a difficult anteroposterior surgery followed by a required revision at the distal end of the Unit rod because of pelvic perforation. This child had initially been moved from the operating table to the hospital bed and a radiograph was obtained. Multiple radiographs were obtained because of concern of the rod placement. Over a period of approximately 30 minutes, it was decided that the rod needed to be revised and preparations were made to move the child back onto the operating table. During this time, the child's blood pressure dropped somewhat and fluid resuscitation was initiated. The child was placed back on the operating table and a short 30-minute procedure was performed to revise the rod. At the end of this short revision, the patient had a sudden drop of blood pressure and there was also extensive bleeding from the surgical site. It was concluded at this time that the child was in a coagulopathy, and aggressive resuscitation with blood products was begun. During the time, the child was moved back over to the hospital bed, the arterial line became dislodged, and it was some time before it was possible to get further blood pressure readings. During this time the child had a severe hypotensive event and continued with bleeding. The child was resuscitated and taken to the intensive care unit but continued to bleed into the chest; however, the mother requested that no further resuscitation be performed. In another case, the child had a very uneventful anterior and posterior procedure with exceptionally low blood loss. Again, the child was transferred to the hospital bed. Some time was consumed in obtaining appropriate radiographs, and over a 30- to 45-minute period, the child was transferred to the intensive care unit. As the child was being moved into the intensive care unit, the portable monitor showed that the blood pressure had dropped and there was a concern that there might have been a monitor malfunction; however,

with a short review, it was determined that the child had a cardiac arrest. The child was then returned to the operating room, aggressively resuscitated, and returned to the intensive care unit. No source of bleeding was found and the cardiac arrest was due to a combination of hypovolemia and anemia. Again, the mother requested that no further resuscitation efforts be made, and 8 hours later, the child had another drop in blood pressure and a cardiac arrest and no resuscitation was performed. These two cases demonstrate the extreme importance of maintaining a high state of vigilance in this period from the end of the operative procedure until children are safely in the intensive care unit with full monitoring.

Immediate Postoperative Period

Immediate postoperative deaths may occur if there is not an aggressive intensive care unit management of electrolyte balance, coagulopathy, hypovolemia, and respiratory support. We had one death in the first 24 hours after surgery in which the girl developed a rapid coagulopathy followed by a cardiac arrest from which she could not be resuscitated. The postmortem examination showed severe hemorrhagic pancreatitis for which there was no explanation for the cause. Risks of death after the acute postoperative period are mainly due to respiratory compromise. After discharge from the hospital, the risk may be higher in the first 6 months, but not substantially. Again, this risk involves those children with the most severe neurologic disability. We also had three deaths of children who were scheduled for surgery but died before the spine surgery could be performed. All of these were severely involved children in whom the caretakers noted increasing problems from the scoliosis and desired aggressive comfort management. The treating physician did not perceive that these children were having any more medical problems than many similar children who do well and make significant improvements following surgery. We also had three children die in the first 3 months after surgery after discharge from the hospital. One of these children was admitted to the hospital with what was initially thought to be severe constipation; however, she quickly became septic and was believed to have an acute surgical abdomen. The family refused surgical treatment of the acute abdomen because the spinal fusion had been performed under a no resuscitation order. The family desired only comfort care. When the child died, the postmortem examination showed a ruptured Meckel's diverticulum that was completely unrelated to the spinal fusion. Another child developed pneumonia 6 weeks after discharge and was admitted to another hospital, where again the family refused to have the child intubated, and she died. The spinal fusion may have been related in the development of her pneumonia; however, one of the goals of the spine surgery was to try to improve her respiratory function, which had been getting progressively worse. A third child was found dead in bed in the morning by the caretaker 4 weeks after discharge. No postmortem examination was done; however, this is how death most commonly occurs in this group of severely involved children.

Preoperative Problems

If families have decided to move ahead with the posterior spinal fusion, it is important that their children's whole medical treatment be under maximal therapy.

Poor Nutrition

As previously noted, the importance of good nutrition is well understood, but how good is required is totally unknown at this time. The goal is to have

children in as good nutrition as their families will allow; however, we would almost never refuse surgery because of malnutrition unless the children are in the severe stages of starvation and malnutrition. A full diet history should be done and evaluated by a dietitian. Using this data and a history of the family dynamics, the dietitian can usually recommend appropriate feeding supplements and better nutrition. Nighttime feeding with a nasogastric tube is also recommended occasionally. The primary focus on nutrition, however, is in the postoperative period.

Gastroesophageal reflux, gastritis, and stomach and duodenal ulcers are quite common in this population. Children should be under maximum medical management of these conditions; however, if the gastroesophageal reflux is of such severity that it requires surgical repair, we prefer to do the spine fusion first. The effect of the spine fusion on the gastroesophageal reflux is very unpredictable, ranging from very significant improvement, to no effect, to significant deterioration (Case 9.11). This unpredictability appears to be due to the poorly understood anatomical changes that the spinal deformity causes to the diaphragm and gastroesophageal junction. The assessment of our surgical colleagues is that it is also easier to address the gastroesophageal reflux when the spine is straight and there is not a severe distortion of the anatomy.

Seizure drug levels should be checked preoperatively, and a consultation with a neurologist is encouraged if the seizures are not well controlled. If the child has a ventricular peritoneal shunt, it should be checked because significant changes in body shape may affect its function. However, there is little concern about managing seizures postoperatively because they are seldom a problem. If a grand mal seizure occurs in the postoperative phase, the Unit rod is strong enough to resist failure and we have never seen any related problems.

Intraoperative Complications

Respiratory Problems

Many children with severe neurologic involvement have some level of aspiration, which may lead to reactive airway disease. As children are anesthetized, asthma may become more noticeable. Appropriate treatment with inhalers and steroids should be started, and if the patients respond quickly, the surgery can proceed. If there are prolonged periods of hypoxia or difficulty with ventilation, the surgery should be canceled if it has not been started, and if this occurs during the operative procedure, very rarely surgery may need to be abandoned.

Dislodgment of the endotracheal tube is a serious respiratory emergency and the whole team must understand the protocol in the event this occurs. Children need to be turned emergently into a supine position on a stretcher that should always remain immediately accessible to the operating room. The endotracheal tube may also occasionally move distally into the right mainstem bronchus and cause hypoventilation on the left side. If there is hypoxia and decreased breath sounds on one side during surgery, the movement of the endotracheal tube should be the first thing to check. If the tube is fine, then an acute pneumothorax on the side with decreased breath sounds should be considered. It is very difficult to get a good chest radiograph in the prone position on a spine frame, so if the problem persists, it is better to prophylactically place a chest tube on the side with decreased breath sounds. This placement is relatively easy to perform. By only minimal movement of the surgical drapes, the midthoracic level of the posterior axillary line is accessible and a tube can be easily inserted from the surgical field. If no pneumothorax is present, no damage is done; however, this can potentially avoid



Case 9.11 Eric

Eric, a 14-year-old boy with severe quadriplegia and severe mental retardation, was evaluated because of his increasing scoliosis, which had reached 95° (Figure C9.11.1) and made sitting very difficult (Figure C9.11.2). He was only comfortable lying in one position. He was also in treatment for severe gastroesophageal reflux, and was taking tegretol to treat seizures. He was very thin and weighed 23 kg. After the reflux was under maximum medical management, he had spinal surgery with a Unit rod instrumentation to correct the scoliosis. During surgery, he had a high blood loss, totaling four blood volumes, due to a coagulopathy that was not treated aggressively enough early in the case. As a result of the coagulopathy, and the surgical technique at that time in which the pelvic holes were drilled just before to rod insertion, pelvic fixation was abandoned and he was only instrumented to L5 (Figure C9.11.3). Postoperative radiographs showed good but not complete correction of the pelvic obliquity. His postoperative recovery was uneventful with greatly diminished gastroesophageal reflux. Immediately after surgery, sitting was much improved. He again presented 9 months following surgery with increased sitting difficulty and increased gastroesophageal reflux. He had increased

pelvic obliquity and lumbar scoliosis (Figure C9.11.4). He was then taken back to surgery for an anterior release, followed by posterior osteotomies, and connection to the proximal end of the rod with rod connectors (Figure C9.11.5). For the first 3 months after surgery, he was again much better with decreased gastroesophageal reflux but then had a sudden onset of reflux and the parents felt his body shape changed. Repeat examination demonstrated that the rod connectors had failed, which required a third procedure with rod replacement (Figure C9.11.6). Following the third operation, his reflux was again under easy control (Figure C9.11.7). This case demonstrates how responsive reflux is to spine deformity correction in a few children. Some get worse and many are unchanged. This case also demonstrates two major errors. One is that the procedure needs to be planned for progressive increase in blood loss, which the team must be prepared to address; that means the pelvic holes should be drilled early in the case when there is little blood loss. The second error is that end-to-end rod connectors located at the same level have a high failure rate and this should be avoided. We had three such failures until we learned this lesson.

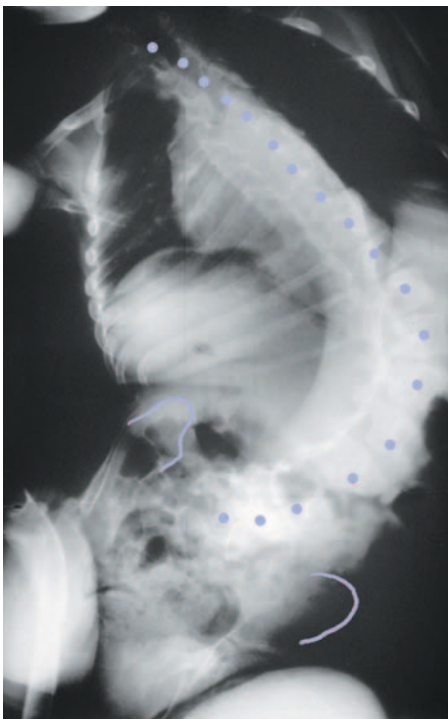


Figure C9.11.1

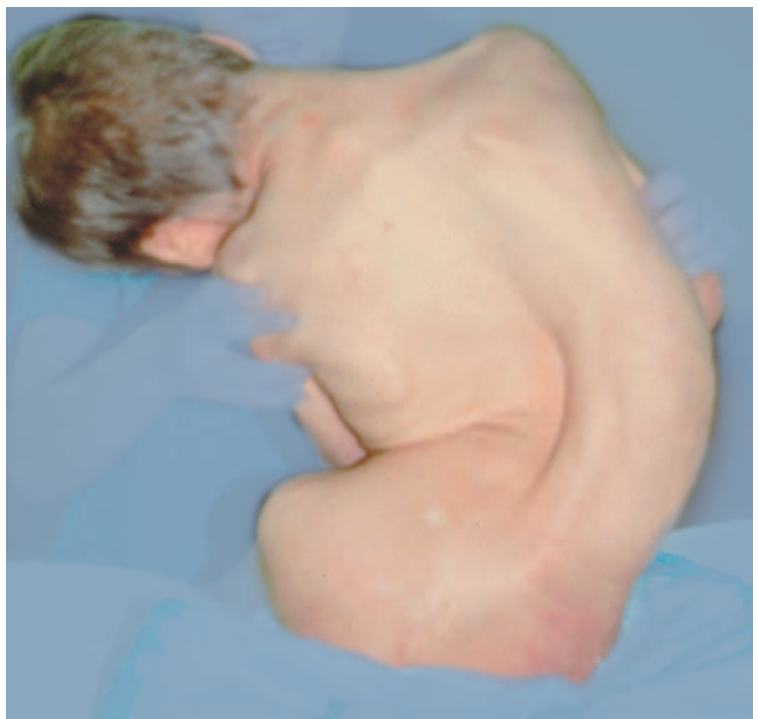

Figure C9.11.2

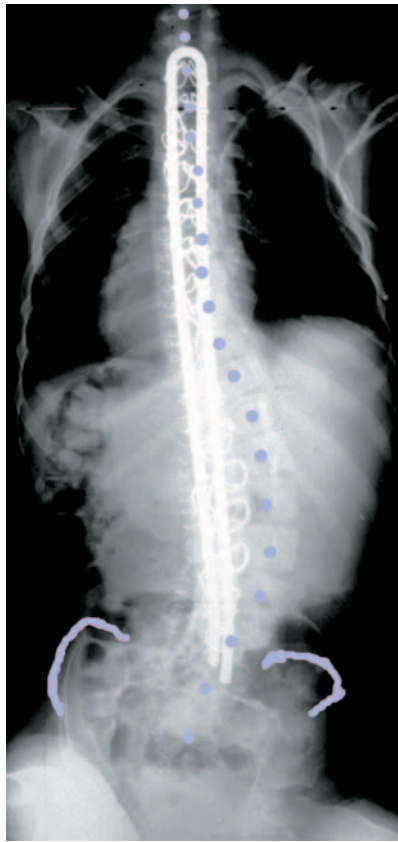

Figure C9.11.3

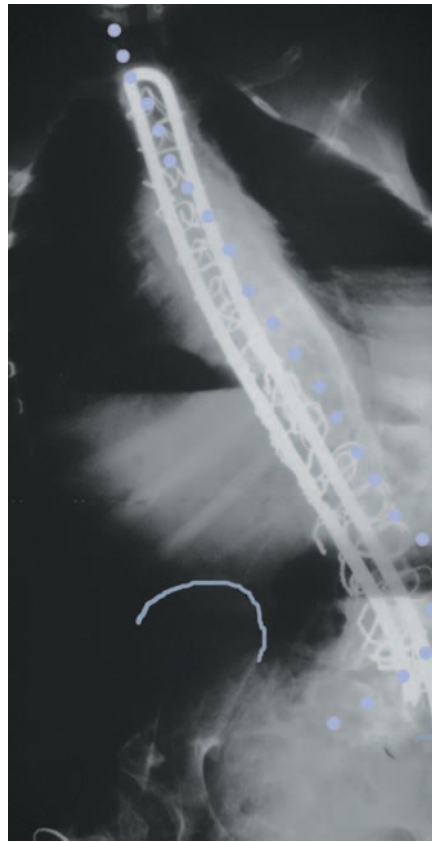


Figure C9.11.4

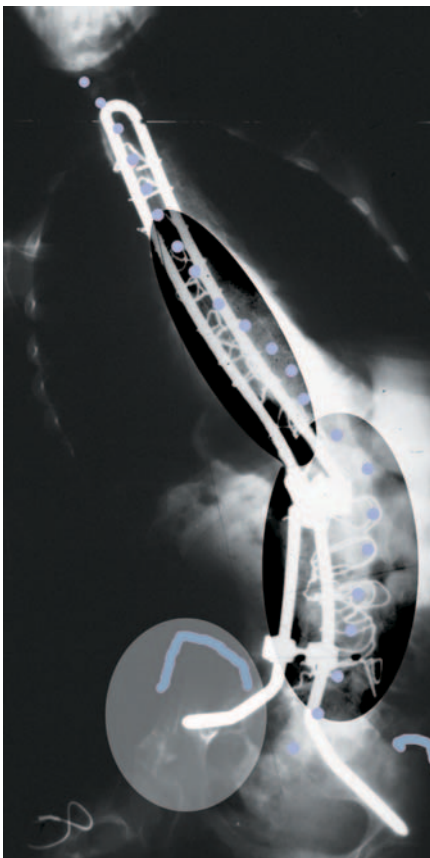


Figure C9.11.5

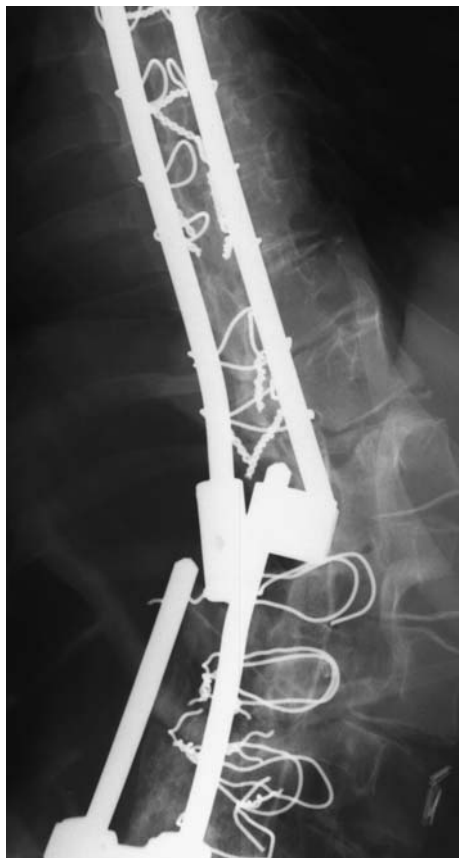


Figure C9.11.6

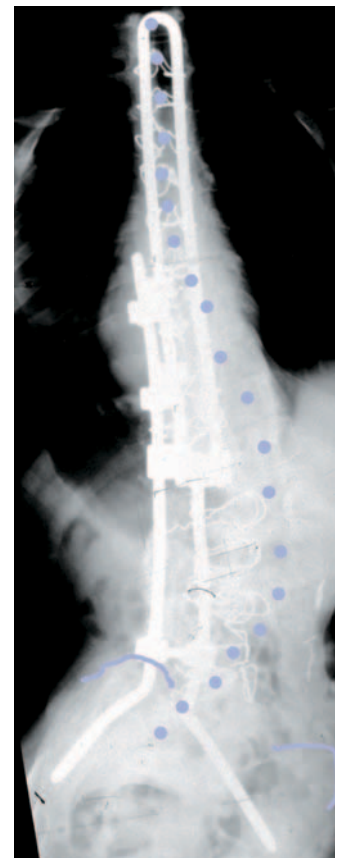


Figure C9.11.7

a very serious complication. The tube can be left open to the air until the end of the case when it is placed under water seal.

Bleeding Problems

Intraoperative bleeding is a well-recognized problem in children with CP. This bleeding is worse than for other neuromuscular conditions and may be made even worse if children are on valproate sodium for seizure control. Another factor may involve chronic dehydration and contraction of the intravascular fluid volume, which many children have. This intravascular fluid space, if rapidly expanded under the stress of surgery, may cause acute dilution of the coagulation factors. However, this increased risk for bleeding is multifactorial, as there has been little effect with attempts to raise specific coagulation factors with desmopressin acetate.³⁴ The key is not to allow a coagulopathy to develop. Often, there are situations where children appear to be doing very well and then have a sudden decrease in the ability of clot formation and increased bleeding begins. Ideally, the coagulopathy can be treated before it becomes this obvious by the early administration of fresh-frozen plasma when approximately one half of the blood volume has been lost. In children on valproate sodium, phenobarbital, or other drugs known to cause increased bleeding, as well as children with severe neurologic involvement, earlier transfusion of fresh-frozen plasma may be considered. Periodic blood samples should be obtained, especially as one blood volume of loss is approached, to monitor platelet count. Hemoglobin levels also need to be monitored. If the platelet count falls below 100,000 during surgery, platelet transfusion should be given. Hemoglobin should be maintained above 8 grams during the surgical procedure, and the goal is to maintain blood pressure at a mean of between 60 and 80 mmHg. More aggressive hypotensive anesthesia is not beneficial because most of the bleeding is venous in origin. Maintaining a low venous pressure is beneficial in decreasing blood loss, but this can be very dangerous. Children may go from maintaining a blood pressure of 60 mmHg, and if the intravascular volume is being maintained low to help with bleeding, they may suddenly drop to a systolic pressure of less than 30 mmHg. It is better to have a little more margin of safety even if there may be a little more bleeding.

Surgeons must be prepared to handle high blood loss (Case 9.11). The value of blood salvage in this group of children is uncertain because most of the blood loss tends to come at the end of the procedure, especially with bone decortication and facetectomy. To most adequately use blood salvage, the blood needs to be obtained through suction and there should be no wound coagulant, such as thrombin and Gelfoam, used in the wound. In our facility, there is not much difference in the amount of blood lost and the amount of donor transfusion, whether blood salvage is used or not. Also, there is debate about how much electrocautery should be used, with some surgeons doing much of the dissection with electrocautery and others using it only to control points of bleeding. Again, there is not much difference in blood loss. Surgeons must be aware that some children with CP have high blood loss with surgery and some have very minimal blood loss. Except for children with the most severe neurologic deficit and possibly those on seizure medications, it is impossible to predict exactly which children will have high blood loss.

Epidural Bleeding

Opening of the epidural space may cause the most blood loss. In most children, this part of the procedure involves very little or no bleeding. Sometimes one level will have a slight amount of venous bleeding, which is easily controlled. However, in a few rare children, approximately 1 in 75, there will

be exuberant bleeding from almost every epidural space at every level. This bleeding can make wire passing stressful; however, with proper preparation, it can always be performed. The technique for managing this exuberant bleeding is to open the epidural space, then pack it with Gelfoam and neural strip sponges, putting gentle pressure on the interspace. Almost all this bleeding is venous, and no attempt should be made to find the vein as these epidural veins are very circuitous and hard to control directly. After all the interspaces have been opened and packed, start passing wires at each interspace, removing only the pack at that interspace. If substantial bleeding occurs during passing of wires, the interspaces are immediately packed again with Gelfoam, neural strips, and a sponge, sometimes requiring someone to hold pressure over the area. When this type of bleeding is encountered in the surgical field, it is mandatory to communicate with the anesthesia team to ensure that enough blood has been typed and cross-matched and that coagulation factors are being transfused. Our worst experience with this type of bleeding occurred in a girl with relatively good motor function who was cognitively normal but had many previous abdominal procedures and severe hyperlordosis. It is our impression that this combination of abdominal procedures and hyperlordosis increased the risk of this venous bleeding. It is likely that the vena cava had a partial obstruction and that the blood flow from the lower extremities was coming, in part, through the epidural veins, which had become dilated. In some of these children, each interspace seems like passing a wire through the vena cava itself. In our most severe case, 10 liters of blood was lost during the procedure, most in passing wires and controlling the epidural bleeding. However, this case is an ideal example that the volume of bleeding has little to do with postoperative recovery, as this girl had an excellent postoperative recovery and has had no perceptible effects of this blood loss.

Bone Bleeding

The second major source of bleeding is from bone veins during decortication and facetectomies. We prefer to control this bleeding with packing with bone graft that has been embedded with thrombin immediately after decorticating and doing facetectomies. Also, packing the wound with sponges helps to control this venous bleeding if there is not a concomitant coagulopathy. We also prefer to do the decortication and facetectomies after the wires have been passed but before the rod is inserted. This approach allows for the best decortication and removal of the facets; however, there is then a longer period of time of bone bleeding until the wound is closed. The problem with doing decortication after the rod is inserted is that it is very difficult to do any substantial decortication and facet removal. However, in rare patients in whom there are severe problems with bleeding early in the case, we prefer to do the decortication after the rod has been inserted.

If significant bleeding occurs, it is important for surgeons and anesthesiologists to keep communicating. In general, the protocol we use is to try to maintain a mean blood pressure of 60 to 80 mmHg. If the mean pressure drops below 60 mmHg, volume is replaced with crystalloid and donor packed cells because few of these children are able to donate blood. If the mean pressure drops below 40 mmHg and is not quickly responding to volume replacement, the surgical wound should be packed and held under pressure to stop all wound bleeding temporarily. If part of the problem is coagulopathy, clotting factors and platelet replacement should be given as soon as they can be obtained from the blood bank. It is also important for anesthesiologists and surgeons to always be aware of how much blood is available for immediate transfusion. During the operative procedure, the amount of blood available for immediate transfusion should never drop below two units. By

the time the fifth unit of transfusion is needed, the blood bank should be in the process of cross-matching more blood. It must be recognized that children with CP have a tendency for sudden drops in blood pressure, especially if the intravascular volume is too low and they become suddenly coagulopathic. This tendency for sudden drops in blood pressure may occur because these children have very poor general conditioning, as they never get any exercise. Also, if there is a substantial drop of the blood pressure below a systolic of 30 or 40 mmHg, preparation should be made to emergently turn patients into a supine position in the event a cardiac arrest should occur. However, cardiac arrest with a substantial blood pressure drop is rare, and aggressive fluid replacement will almost always reverse the situation.

The most important aspect in managing intraoperative blood loss is for the operative team to be prepared and expect the worst. If blood loss is managed properly and the operation is completed properly, the amount of blood loss has very little impact on children's recovery or outcome.¹⁸ Surgery done poorly because of blood loss usually means another return to the operating room with the same bleeding problems encountered again, which can be well demonstrated by an individual case (Case 9.11).

Dural Leak

While opening the epidural space, or during passing of sublaminar wires, a dural tear may occasionally be created, although this is very rare in individuals who have not had previous spine surgery. In these situations, the tear is usually small, and with slightly more opening at the interspace, it is possible to repair the dura directly with a small 6-0 nylon suture. Gelfoam can then be placed on top of the repair, and the dural leak is adequately controlled. However, it is much more common to get dural openings when there has been previous surgery, such as following a dorsal rhizotomy. Again, most of these dural tears tend to be small and are fairly easy to repair with direct suture. If the dura is extremely friable and cannot be directly repaired, it can be left open if this open area is large enough that a one-way valve is not created. Usually, this means that the open area should be approximately 0.5 cm², which is left covered with Gelfoam, and then the spinal procedure is continued. At the end of the procedure, the fascia is closed very tightly in the usual fashion, being especially careful that the area over the dural tear is closed with good substantial soft tissue. Occasionally, it may be appropriate to place some crushed cortical bone directly over the tear so long as there is no pressure pressing this bone into the spinal canal. The most common circumstance where substantial tears of the dura are encountered is during spinal osteotomy, when there has been substantial previous spinal surgery. Another option for repairing these dural tears is to obtain a small bit of lumbar fascia and then suture it over the dural defect. All these children are kept supine for 2 to 3 days because of the large magnitude of the surgical procedure; therefore, this area usually seals or becomes part of the surgical wound. We have never had any problems with persistent dural leaks or problems with spinal headaches in children in whom we have left large defects in the dura open.

Perforation of the Pelvis with Unit Rod

One of the potential complications of Unit rod instrumentation is perforation of the pelvic wall with the pelvic limb of the rod. This complication occurs primarily in individuals whose deformity has a major component of lumbar hyperlordosis and is especially common in children who are very short in stature and have thin osteoporotic pelvic bone. These specific criteria are not contraindications to using the Unit rod, but should raise the concern about possible perforation. Decreasing the lordosis by maximum hip flexion and

using an anterior abdominal block can all help to prevent this problem. Also, getting a good visual perception of the angle of the hole in the pelvis and making sure that the pelvic rod stays in line with this hole during insertion is important. If there is any concern after the pelvic limbs are inserted, a physical examination by direct palpation of the abdomen between the iliac crests is recommended, followed by movement of the legs to make sure the rod has not perforated the hip joint.

Medial Pelvic Perforation

Three types of perforation of the pelvis may occur. Perforation of the medial wall of the pelvis has the highest risk of causing significant problems. We had one patient in whom the rod perforated the pelvis and subsequently caused a colon perforation. This perforation occurred at a time early in our experience when we did not think there would be much risk from colon injury because we thought the rod would lie on the medial side of the ilium and the colon would simply move away. We are aware of one other case of colon perforation in which the rod was allowed to lie on the inside of the pelvis. We now believe that this is not an appropriate position to leave the rod long term and recommend revision when it lies substantially medially to the pelvis. Both these colon perforations occurred late, 7 weeks after surgery in our case. This colon perforation responded well to draining and closure of the colon perforation initially, then, after 5 days, the posterior spine was opened at the distal end and the rod on the side of the perforating leg was cut and removed. The hole in the pelvis where the rod was supposed to go was identified, and the rod was cleaned and reinserted. The wound was well irrigated, and the child was maintained on antibiotics for 4 weeks and had an uneventful recovery with no recurrent infection in the spine after more than 5 years of follow-up.

If the intraoperative examination of a child seems normal, our recommendation is to proceed and complete the operative procedure. When the child is turned in the supine position, obtain an anteroposterior pelvis radiograph and right and left oblique radiographs of the pelvis if there is any doubt that the rod might have perforated the medial wall of the pelvis. These children are also easier to examine in the supine position, and careful examination should be performed because the tip of the rod can always be palpated when it has perforated medially in our experience. If the child is stable, the best time to do the repair, if there is a medial perforation, is before leaving the operating room. The child should again be placed in the prone position, the distal end of the wound opened, the rod cut on the side of the perforating leg at approximately the L3–L4 level, and the rod removed. The proper hole in the pelvis can almost always be identified; the rod leg can be inserted, and then reconnected with one end-to-end connector and one cross-link connector (Case 9.12). If it is difficult to reconnect this rod leg, getting another Unit rod of the same length is advised. The rod should be cut so it can be overlapped and side-to-side rod connectors on the side where the rod has been cut should be used.

Lateral Pelvic Perforation

The Unit rod may perforate the pelvis laterally as well, and this almost never causes a problem and generally can be ignored. We had one such perforation that was close to the sciatic nerve and caused neuritic pain, requiring eventual resection of the rod leg on that side. In another child, just the tip of the rod perforated laterally and developed heterotopic ossification over the tip of this rod, which formed a painful bursa and required removal of the heterotopic bone and tip of the rod (Figure 9.11). Theoretically, it is possible for the Unit rod to perforate the normal acetabulum. However, if the



Case 9.12 Hyon

Hyon, a 12-year-old girl with severe spastic quadriplegia, developed a lordoscoliosis that required instrumentation and correction. The pelvis was noted to be very osteoporotic and thin. With care, the rod was inserted and the abdominal examination was thought to be normal. There was significant bleeding present during the case and, after she was turned into the supine position, the abdominal examination suggested a possible protrusion on the right side, although it was not definitive. An oblique radiograph of the pelvis demonstrated the rod outside the confines of the pelvis (Figure C9.12.1). After some dis-

cussion, it was decided to leave the rod in this position. She did well postoperatively and was discharged from the intensive care unit on the fourth postoperative day. On the fifth postoperative day, she was returned to the operating room where the rod was cut off on the right side, the correct hole identified, and the rod inserted and connected with an end-to-end rod connector (Figure C9.12.2). This case demonstrates an acceptable approach, although a second crosslink would be preferred (Figure C9.12.3). Also, we prefer to do the revision before leaving the operating room whenever possible.

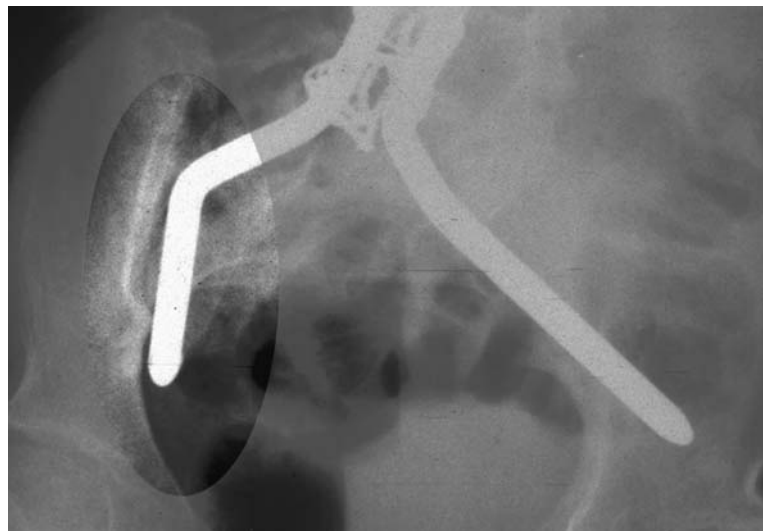


Figure C9.12.1

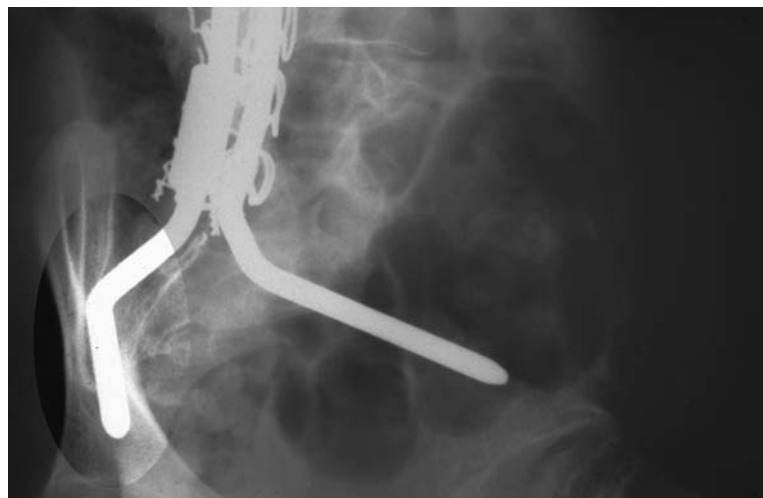


Figure C9.12.2

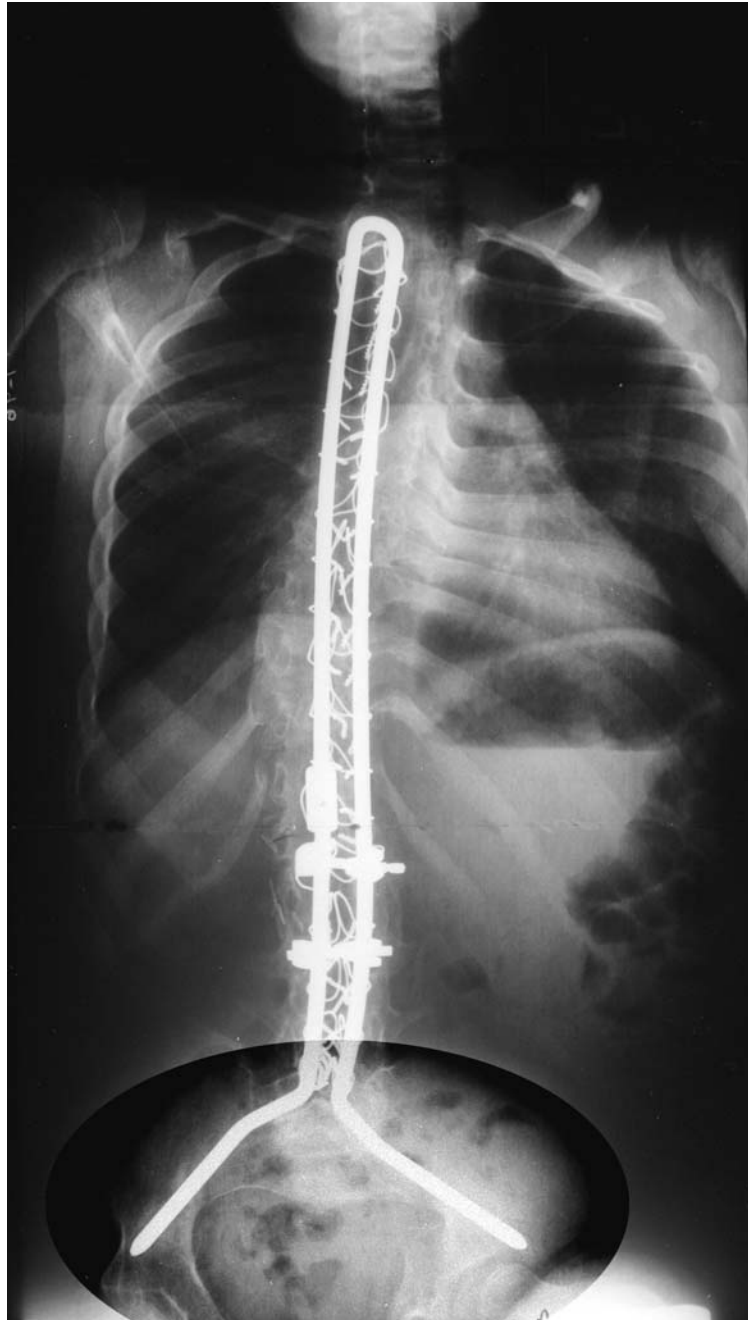


Figure C9.12.3

entrance of the drillhole is started in the inferior aspect of the posterosuperior iliac spine and the drill guide ensures that the hole is drilled just above the sciatic notch, this almost never occurs.

Acetabular Perforation

The rods are also sized so that the pelvic legs of the Unit rod are not long enough to reach into the acetabulum. However, if children have a severely dysplastic acetabulum, which is migrated posterosuperiorly, it is possible for the leg of the rod to reach and enter this false acetabulum. This rod perfor-

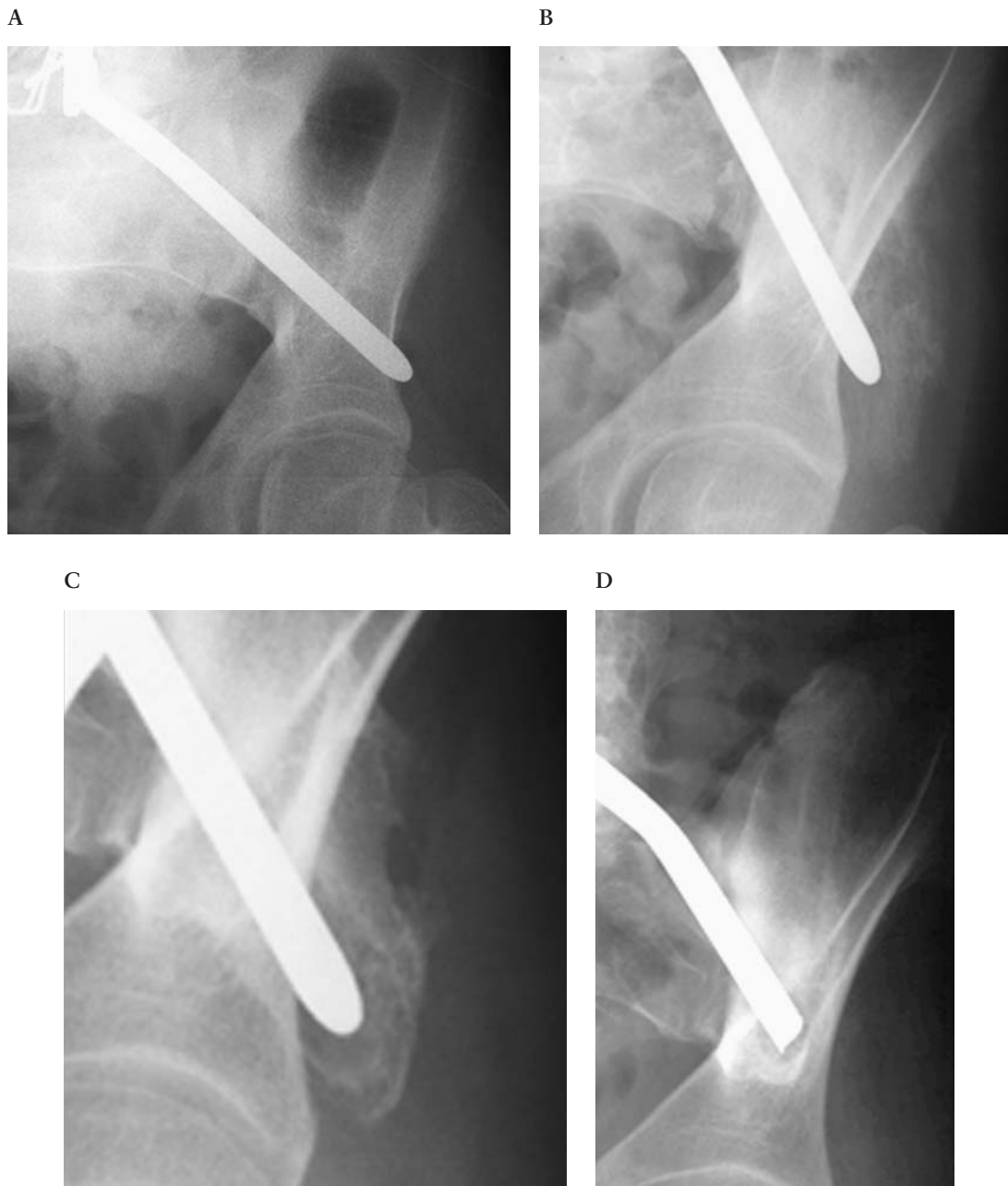


Figure 9.11. Protrusion of the pelvic leg of the Unit rod may occur on the lateral side (A). This usually does not cause any problem; however, it may cause ossification of the muscle (B). Over 6 to 12 months, this usually matures and becomes asymptomatic; however, in a few cases, persistent bursitis remains after complete maturity (C). Excision of the ossification and rod are then required, and this would usually be treated with one dose of radiation to prevent recurrence (D). Inferior protrusion into the sciatic notch may cause sciatic nerve irritation, requiring revision of the pelvic limb of the rod. Medial protrusion into the abdomen should be avoided because colon perforation may occur.

ration has occurred in one of our children. We removed the tip of the rod by opening the ilium just anterior and superior to the acetabulum and cut off the tip of the rod, drawing it out of the acetabulum but leaving the remainder of the leg with good fixation in the ilium.³⁵

Because radiographs of the pelvis with children on the spine frame are very difficult to interpret, we believe they are a waste of time and generally

do not obtain them. However, it is important to obtain at least an antero-posterior pelvis radiograph to confirm appropriate position of the rod. If an unexpected medial perforation is seen or palpated, and there is some physiologic instability because of high blood loss or other medical problems, it is appropriate to leave the rod in this position temporarily. Recognizing the problem but then choosing not to address it until later when children are more medically stable is acceptable. It is theoretically possible to get an acute perforation of a pelvic organ; however, this has never been reported. In this circumstance where there is medical reason, it is very appropriate to delay this aspect of the surgery. This revision is a relatively minor procedure and, if done a week later, should not significantly impact children's recovery times.

Wires Pulling Through Laminae

In many children with CP, the bones of the laminae are not of normal strength. Occasionally, a lamina fractures during wire tightening. With one or two laminae fractured, they can be bypassed and there is no problem. The most common lamina to fracture is L5, which is often quite thin and weak. L5 is probably the least important lamina, although it is at a transitional level. The most important laminae that should not fracture are the top two or three levels. The laminae of T1, T2, and C7 are very strong and will almost always be the ending fixation, especially when significant osteoporosis or osteopenia has been encountered. In spite of even severe osteoporosis, almost all lamina fractures are caused by technical error by surgeons. These errors can be avoided first by absolutely never using the wire to pull the rod to the spine. The rod must always be pushed against the spine, and then the wire is tightened until it just contacts with the rod. There must be a very gentle touch to using the wire twister in children who have osteoporosis and osteopenia, being specifically careful to avoid jerking movements and stopping as soon as the wire twist is in contact with the rod.

Also, as the major deformity is corrected, it is important to not decrease pressure on the rod pusher or the zipper effect may be encountered. The zipper effect happens when the end lamina has too high a pressure and starts to fail with all laminae pulling out to the apex of the curve. It is important to maintain pressure on the rod holder until all the wires are twisted; in this way the force is distributed over many laminae and this kind of failure will not occur. If a zipper effect does occur, it is important to have at least three good stable laminae above this area. The rod can be pushed to these laminae, and then all three should be tightened down with pressure on the rod, which should be released slowly. The zipper effect happens very rarely; and if the laminae at T1, T2, and C7 are utilized, good proximal strength can usually still be obtained.

Rod Either Too Long or Too Short

One of the most difficult technical challenges in using the Unit rod is choosing the correct length of the rod (Figure 9.12). Even after doing more than 200 cases, this still continues to be a difficult judgment at times. Surgeons must predict how much length will be gained as the deformity is corrected. This prediction is complicated by correction of scoliosis and lordosis, which add length to the spine in the instrumented area and correction of kyphosis, which shortens the instrumented section. In general, it is not a major problem if the rod is one level too short because the wires from T1 still will provide a significant corrective force. We have never had a rod that was too short. Even if the rod ended between the T2 and T3 interspace, the wires still provided significant corrective force and could be brought to the end of the rod without difficulty. If the rod is too long, bending the tip of the rod forward

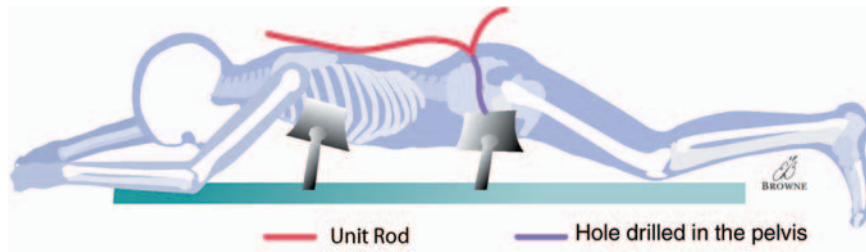


Figure 9.12. The correct length of the Unit rod is the most difficult decision during the surgical procedure. The best method is to set the chosen rod upside down on the spine with the distal corners right over the pelvic drillholes. The proximal end should come to the T1 level. If the child has severe scoliosis, the spine may lengthen and a rod one size longer can be chosen. If the child has severe kyphosis as the primary curve, there will be significant spinal shortening and a shorter rod should be chosen. It is important to not try to determine if the rod is the correct length after it has been inserted into the pelvis by pushing it down onto the spine. This action risks causing a pelvic fracture.

so that it is not too prominent posteriorly is helpful. With the rod slightly bent forward, it may be left at a level as high as C5 or C6 without causing any problems. If the rod is too long, another option is to cut off the top of the rod; however, before the rod is cut, it is very important that the two rods be cross connected with two strong cross-connecting elements. If the rods are not cross connected first, they will shift when they are cut and some correction will be lost, as the rods tend to twist into the deformity. If the rod is prominent after surgery and causes pain from the development of a bursa, it can be cut off as an outpatient procedure at the level of T2 or T3. However, it is recommended that this should not be done until a fusion has occurred, and we try to encourage individuals to wait at least 1 year postoperatively before the rod is cut off superiorly (Case 9.13).

Somatosensory Evoked Potentials

Somatosensory evoked potentials (SSEP) and motor evoked potentials (MEP) have become common intraoperative mechanisms for monitoring spinal cord function during spinal surgery in idiopathic adolescent scoliosis. Their use in children with CP has not been as well defined, with early reports suggesting that they are not reliable.³⁶ However, other reports suggest that about 50% of children can be monitored with SSEP.³⁷ Another report suggests the use of epidural monitoring has even better results.³⁸ In a consecutive trial of 30 children with CP who had both motor and sensory monitoring, we found that 30% to 40% of the children could not be monitored. As with every test obtained in the treatment of individuals, the fact that a test can be done does not mean that it should be done. Specifically, even though children with CP technically can have spinal cord monitoring, we have to ask what we hope to gain from these data. If children are ambulatory, an aggressive approach similar to that in idiopathic adolescent scoliosis would indicate that all corrective force from instrumentation should be removed if spinal cord monitoring detects spinal cord dysfunction. For the Unit rod, this would involve bending the rod to allow some deformity as a way of decreasing its corrective force or, alternatively, considering removal of the rod. If a hook and rod system is used, it should usually be removed because the rods provide some longitudinal force and the hooks may cause direct compression of the spinal cord. If sublaminar wires are in place, they should not be removed, as their removal is more dangerous and likely to cause more injury than just tightening the wires in place. Clearly, the 1-mm or even 2-mm thickness of sublaminar wires would never cause a significant compression of the spinal cord; therefore, there is no rational reason indicating that the risk of removing the wires would be of any benefit. There could potentially have been damage from inserting the wires, but their removal would only increase the risk of more damage. If hooks were used, they should be removed because the volume of the hook is such that it definitely can place potential pressure on the spinal cord. These children should also be given an immediate bolus of corticosteroids to prevent further secondary damage from spinal cord swelling.



Case 9.13 Tiffany

Tiffany was a 16-year-old girl with a thoracolumbar kyphosis due to a rhizotomy (Figure C9.13.1). The kyphosis was instrumented to T1 (Figure C9.13.2). The rod was left in the normal position but the end was slightly prominent, as the kyphosis extended into the cervical spine (Figure C9.13.3). The rod formed a bursa over the end and, by 1 year after surgery, she complained of pain at the end of the rod (Figure C9.13.4). Approximately

4 cm of the proximal end of the rod was cut off and her pain was resolved (Figure C9.13.5). This problem could have been avoided by bending the rod anteriorly at the tip or by wiring it to C6 and C7. Another option would have been to cut the rod at the end of the original procedure and connect the individual rods with the two rod connectors. This is the least preferred approach because loss of fixation may occur.

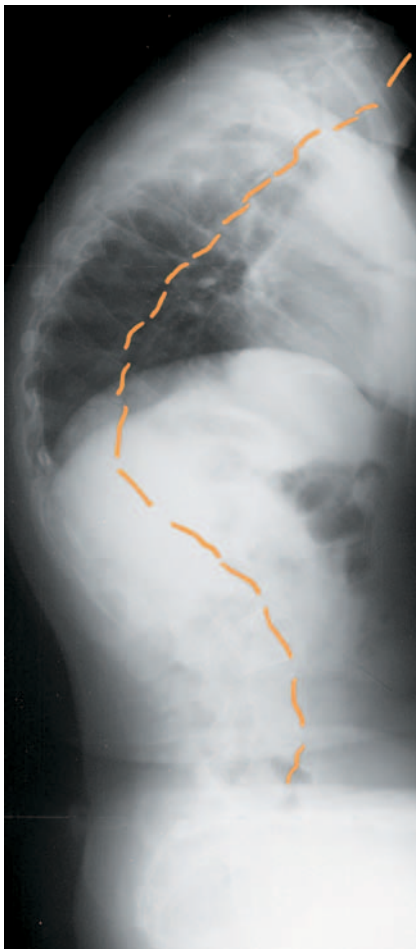

Figure C9.13.1

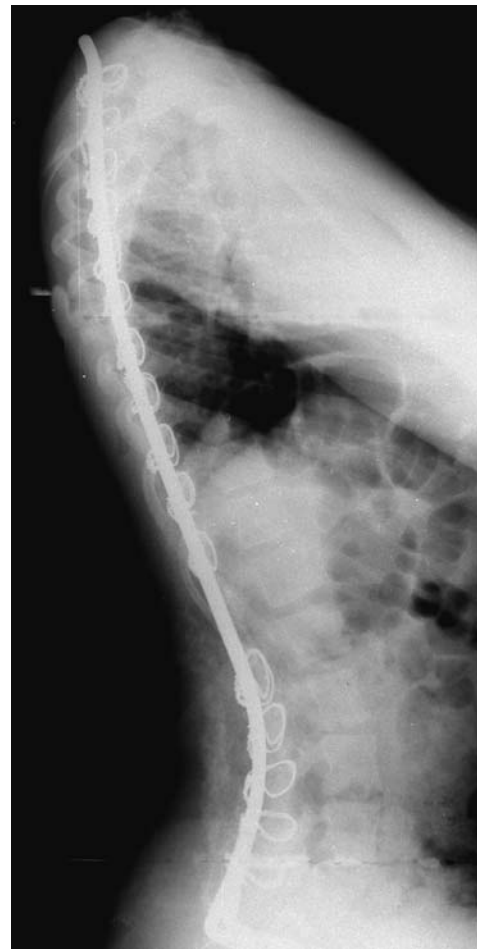

Figure C9.13.2

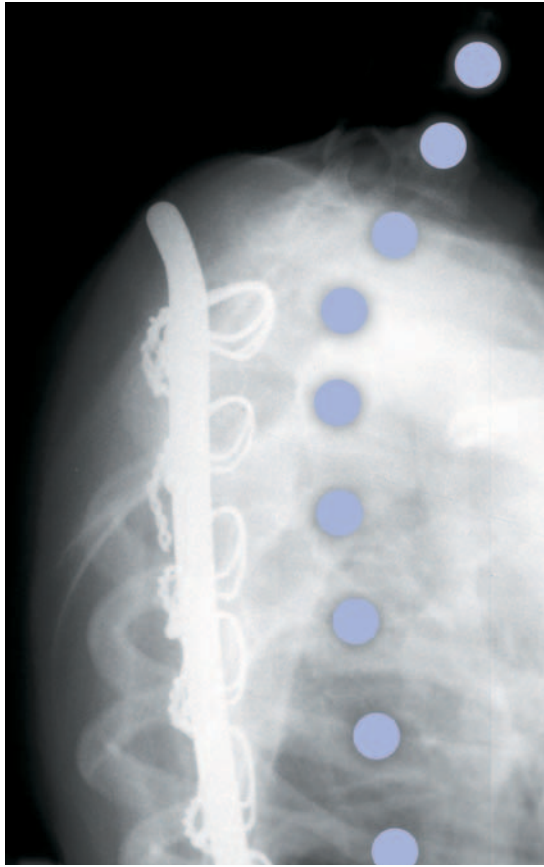


Figure C9.13.3

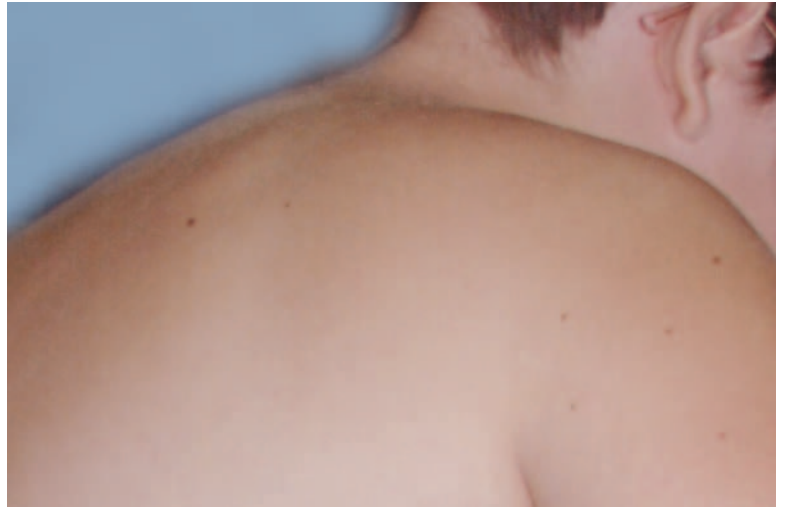

Figure C9.13.4

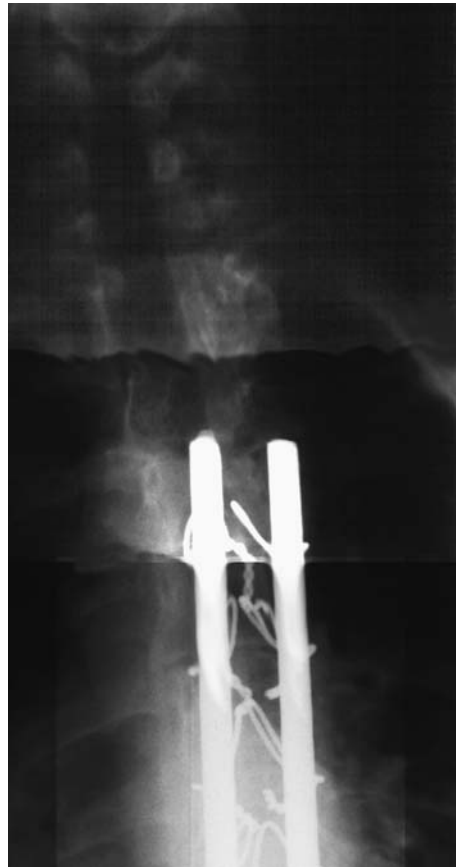


Figure C9.13.5

Using this planned protocol for response to abnormalities determined with spinal cord monitoring, it is clear that spinal cord monitoring is indicated for children with CP who have significant ambulatory ability.

The goal of surgery for children with total body involvement is to correct the spinal deformity so they can sit well. The risk of poor sitting and decubitus formation is such that, in the worst cases where children are completely paralyzed, they will still be better off with a corrected body posture. The use of spinal cord monitoring has much less benefit in severely involved children. The treatment we would consider is to increase the blood pressure if it is low and perhaps give corticosteroids; however, the risk–benefit ratio of this would have to be seriously considered. We always raise the blood pressure if it goes below a mean of 60 mmHg, and spinal cord monitoring would not provide additional information, as this is part of our required protocol without the spinal cord monitoring. In 30 patients, 20 of whom were monitored, 3 false positives of the spinal cord monitoring occurred. None of these children had any noticeable neurologic change, and except for giving corticosteroids to 2 of these children, no change in the treatment was made. Also, in 340 children with CP who had spinal fusions, only 2 neurologic deficits occurred, and both were associated with infections in the postoperative recovery period. Intraoperative spinal cord monitoring would not have helped to detect either of these deficits. Based on this experience, we believe intraoperative monitoring of the spinal cord in nonambulatory children with CP adds no beneficial gain to the care of these children and, as a consequence, is not indicated.

Postoperative Complications

Many reports in the literature evaluate the outcome of spinal fusions in children with CP. Many of these authors report major and minor complications. It is impossible to determine any reasonable rate of complication from these reports because there is no clear definition of what constitutes a major or a minor complication. In general, most surgeons would consider a deep wound infection a major complication because it significantly delays children's recovery and requires much effort from surgeons. Conversely, it is unlikely that surgeons would consider children who required endotracheal intubation and positive pressure ventilation for 2 days postoperatively to have had a complication. However, if children need ventilation for 7 days, is it then a complication? If children need ventilation for 4 weeks and then are converted to a tracheostomy, it would probably be considered a complication. However, if children were considered for possible tracheostomy before spinal surgery, and the hope was that the spinal surgery would make the tracheostomy unnecessary, then it may not have been a complication of surgery, just a failure of the surgery to accomplish the desired goals. Because these children often have multiple system pathologies, there are many outcomes that may or may not be considered a complication. Because of this complexity, there will be no attempt to summarize any complications from the literature. A definite correlation of severity of children's neurologic disability with the incidence of complication exists, and because no reports are clear about the neurologic level of the patients, discussion of the incidence of complications is meaningless.

Hypotension

In the acute postoperative period in the intensive care unit, fluid status has to be monitored very carefully with the goal of maintaining urinary output at a minimum of 0.5 ml per kilogram per hour. The arterial blood pressure should be maintained at or above a mean of 60 mmHg and the hemoglobin

should not drop below 9 g in the first 48 hours postoperatively. Often, the hemoglobin will drop steadily for the first 12 to 24 hours for a total drop of as much as 3 to 5 g from the immediate postoperative hemoglobin level. Significant additional fluid is almost always required because of third spacing with the accumulation of a significant amount of edema. This edema generally starts to resolve as children start to diurese on the second and third postoperative day. This accumulation of fluid is believed to be due to the syndrome of inappropriate antidiuretic hormone (SIADH). Also during this period careful monitoring of the electrolytes, magnesium, and calcium is required. In occasional patients, the blood pressure and lack of diuresis may need to be treated with low levels of dopamine. A well-defined intensive care unit protocol to monitor laboratory values and treat critical levels should be part of the postoperative management protocol. With proper intensive care unit management, these acute postoperative problems rarely have any long-term consequences, although these problems can raise families' anxieties. Families need to be reassured constantly that these are temporary problems that should resolve without any long-term consequences.

Coagulopathy

Just as careful intraoperative monitoring of the clotting cascade was important in the immediate postoperative period, especially for the first 12 hours, this careful monitoring must be continued with an attempt to normalize all clotting parameters. If the clotting cascade is not managed aggressively as children continue to have a decrease in hemoglobin level requiring large volumes of crystalloid, a severe coagulopathy can develop quickly in the intensive care unit. Protime and prothrombin time should be brought to the normal range with fresh-frozen plasma, and the platelet count should be kept above 75,000 during this period. With appropriate aggressive postoperative care, no children have developed a coagulopathy in the postoperative period except for one child who died of hemorrhagic pancreatitis 12 hours after surgery. This girl's coagulation studies were never fully corrected in the postoperative period, although she received a substantial amount of blood factors.

Respiratory Failure

As noted earlier, most children are kept intubated and ventilated for the first 12 to 24 hours postoperatively. This protocol allows an assessment of children's strength, allows adequate pain control, and allows for extubation in a very slow, controlled environment of the intensive care unit. Clearly, however, many high functioning children with good oral motor control can be extubated safely in the operating room. There are also those children with poor oral motor control who will need to be intubated for 5 to 7 days until the fluid shifts have all stabilized, until they have little need for pain medication, and they are close to their preoperative motor function. It is very important that this preoperative oral motor function information be communicated to the physicians managing these children in the intensive care unit. These physicians will often not have seen the children before their arrival in the intensive care unit. There are some children who have such marginal control of their oral pharynx that tracheostomy may be considered. If these children have severe scoliosis, it is our practice to do the spinal fusion first, then if they cannot be extubated at 3 to 4 weeks after surgery, a tracheostomy is done. The response to the spine fusion is often such that children are slightly better and can avoid having the tracheostomy.

As previously noted, allowing children to gain strength and maximize motor control in the postoperative period before extubation is better. Also, following extubation, a period of positive pressure nasal ventilation is often

needed to help the children gain good independent respiratory function. Parents must be kept informed of the progress in the intensive care unit because they often start measuring success by how many tubes their children continue to have, and when the endotracheal tube remains in place, they often have trouble seeing that the children are still making progress.

In the immediate first 5 days of the postoperative period, fevers often occur and are almost always of pulmonary origin. Full fever workup is indicated if the fever spikes to 40°C or greater, or if the temperature remains over 39°C after good pulmonary suction and therapy. If the fever remains at 39°C for 8 hours, a respiratory cause is presumed. Full culture of these children is indicated and, while the culture results are pending, they should be started on a broad-spectrum antibiotic against respiratory organisms. Also, if chest radiographs suggest an infiltrate, antibiotic treatment should be started. If the children respond to the antibiotics by becoming afebrile, the antibiotic treatment is generally continued for 7 days as empiric treatment unless other specific culture results are obtained.

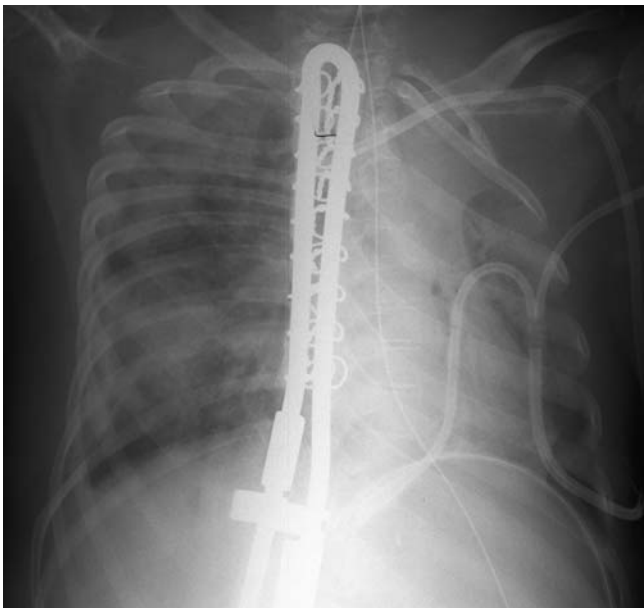
Pneumo- or Hemothorax and Pleural Effusion

Another occasional problem in the postoperative period is the occurrence of fluid or air in the chest cavity, most commonly a pleural effusion. This effusion usually becomes apparent on an upright chest radiograph 5 to 7 days after surgery. It most likely occurs slowly in the postoperative period, during rapid fluid shifts and periods of generalized edema (Figure 9.13). During these times, there are seldom good upright chest radiographs so the fluid may be present but not seen if the amount is small. Only rarely does the effusion get large enough to impair breathing, which is the only indication to treat by tube drainage. Most of the time when drainage is required, it is a pink-tinged to serous fluid. Rarely, the drainage will contain a significant amount of blood, which presumably drained into the chest from the posterior surgical wound. This effusion usually resolves quickly with drainage over several days.

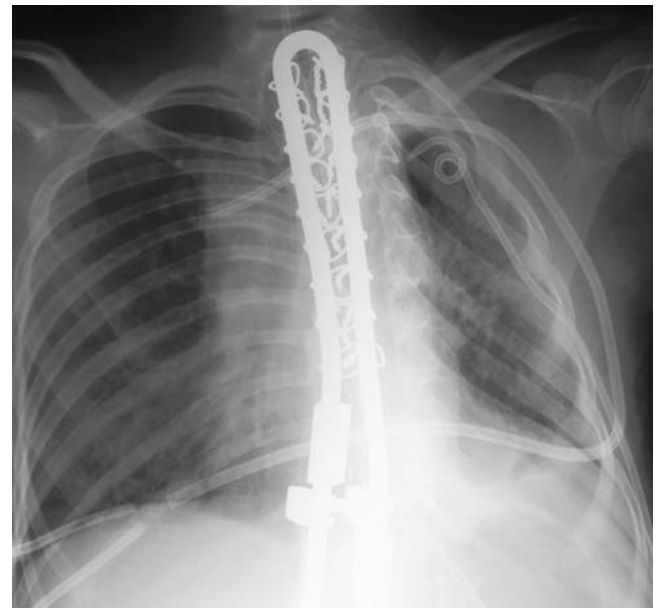
Pneumothorax may also be noted, sometimes occurring as late as 10 days postoperatively. If children are having respiratory problems or difficulty with hypoxemia, an upright chest radiograph should be obtained any time during

Figure 9.13. Pleural effusions are relatively common after Unit rod instrumentation. If the effusion becomes very large and impacts the ability to ventilate the child (A), a chest tube may need to be inserted (B). Usually, there is serous or serosanguineous drainage for 3 or 4 days until the child is diuresing well. On rare occasions, a hemothorax may be seen, and it is then presumed that the posterior wound is draining into the chest. Chest tube drainage and correction of coagulopathies will always stop this bleeding.

A



B



the hospital stay. If the pneumothorax is relatively small and minimally symptomatic, it may be carefully monitored. However, if children are having significant respiratory problems or the pneumothorax involves more than 30% of the volume of the chest, it should be drained with a tube. The origin of these pneumothoraces may come from positive pressure ventilation, incidental opening of the chest during posterior spinal surgery, or from the insertion of the central line. However, these pneumothoraces are usually relatively minor and insignificant in the overall recovery of children.

Reflux and Aspiration

Many children with CP have gastroesophageal reflux and chronic aspiration. The presence of scoliosis has also been associated with an increased incidence of these problems.³⁹ Our protocol is to do the spinal fusion before any surgical correction of the gastroesophageal reflux or aspiration. Some children will have a dramatic postoperative improvement in the reflux; however, some will have no change and some will become significantly worse. These outcomes are in approximately equal proportions, although we do not have good objective data to make this evaluation. Clearly these children can be managed safely through the spinal fusion, and then the response can be assessed and appropriate treatment instituted following recovery from the spine surgery. These children need to be monitored very carefully, especially in the intensive care unit immediately after extubation and then again when feeding is begun. Feeding should be with the children in an upright position with careful monitoring to make sure there is no reflux and aspiration. If there is any evidence of reflux, feeding should be stopped immediately and the respiratory status should be monitored carefully. If there is any suggestion of aspiration of the stomach contents, children should be treated for aspiration pneumonia. Most children with severe quadriplegic pattern CP have some posterior aspiration and run a risk of aspiration during the initiation of feeding. This aspiration can lead to very severe and rapid respiratory compromise.

Some children with tracheal malacia develop a redundant and collapsing trachea as the scoliosis increases, sometimes with collapse and compression between the sternum and spine. In two of our patients, the response to correcting the spinal deformity was complete resolution of the symptoms of tracheal collapse and compression. There was concern that these children might have been made worse.

Pancreatitis

Chemical pancreatitis, as expressed by a rise in the serum amylase, is relatively common and is present in approximately 50% of children in the postoperative period. A much smaller number, approximately 15% to 20%, has some symptomatic pancreatitis that may rarely become very severe. One of the deaths in our patients was from acute hemorrhagic pancreatitis. The cause of pancreatitis is unknown; however, it has been recognized as a risk of most spine surgery even in otherwise healthy adolescents who have idiopathic adolescent scoliosis.^{40, 41} When children are symptomatic from pancreatitis, medical management includes maintaining adequate liquids and nutrition with central venous hyperalimentation and resting of the gastrointestinal system.

Colicystitis

Most of our children are managed with aggressive postoperative nutrition with central venous hyperalimentation on day 2 or 3, and by day 5 or 7, when they have bowel sounds but are not tolerating feeding, the workup should

include an ultrasound of the gallbladder. Often, some sludge is noted in the gallbladder, occasionally with some inflammation of the wall of the gallbladder. Sometimes stones are found as well, leading to this inflammation. Children with severe disabilities are at increased risk of developing cholecystitis and cholangitis. When cholecystitis is diagnosed in the postoperative period, medical management includes gastrointestinal rest and antibiotics. Following full recovery, children may be scheduled for cholecystectomy.

Duodenal Obstruction

Obstruction at the second part of the duodenum where it is trapped between the superior mesenteric artery and the spine may occur in malnourished children with CP, even without any surgical insult.⁴² After correction of major scoliosis curves, especially those that involve significant lordotic deformity, duodenal obstruction is even more common. These children present with good bowel sounds; however, their stomachs become very distended when fed. Severe stomach distension leading to death can occur.⁴² The treatment is to drain the stomach, rest the bowel, and provide nutrition. This obstruction is definitively diagnosed by a swallow study with dilute barium. If the first part of the duodenum fills but the barium does not continue to pass, there is a duodenal obstruction. Some children will have a partial obstruction, which can be managed by giving small amounts of fluid, and a jejunal tube can be passed through the area of the obstruction in some children. The final treatment of this problem is getting the child to gain weight, which may require prolonged central venous hyperalimentation. One of our children required hyperalimentation for more than 2 months. Parents must be informed that some of these children are at risk for the obstruction returning if they do not eat adequately and start to lose weight in the months following surgery. In rare chronic cases, jejunal tube feeding may be needed for prolonged periods to prevent recurrence of the obstruction.

Constipation

Constipation is a persistent and chronic problem for many children. This constipation is not affected much either positively or negatively by the spine fusion; however, families should be instructed on methods to avoid prolonged impactions postoperatively, which tend to decrease the children's interest in eating.

Poor Feeding

As mentioned before, good postoperative nutrition is important. Good nutrition is especially important for children who have little reserve to heal the very large wound created by doing a posterior spinal fusion, which involves all of the spine and posterior pelvis. The goal is for children to take in 1.2 to 1.5 times the daily caloric requirement in the first postoperative month. This intake may be accomplished with oral nutritional supplements and occasionally with short-term nasogastric tube feeding in children who are not eating enough and who do not have a gastric tube. Our experience is that many parents who refuse to use a nasogastric tube preoperatively can be convinced to use it for a short time in the postoperative period when the tube may be seen as part of the surgical treatment.

Hair Loss

Most children have increased hair loss from the stress of a large operation such as a posterior spinal fusion. Some children will develop spots of alopecia, usually 2 to 3 cm in diameter. Usually the parents can be assured that the hair will grow back in 6 to 12 months (Figure 9.14).

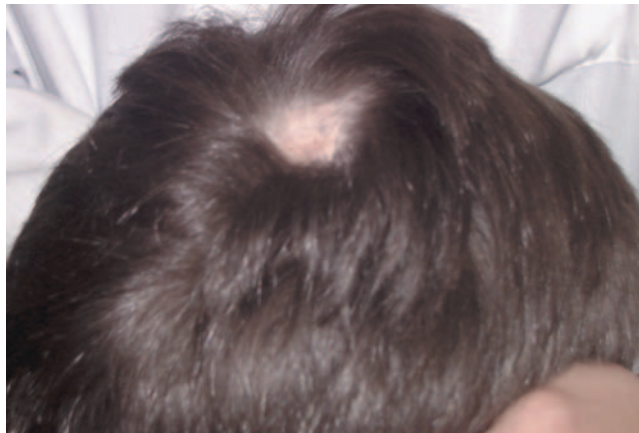

Figure 9.14. Following posterior spinal fusion, many children are reported by parents to lose hair. Some children develop a completely bald spot, sometimes in an area of inflammatory response. In almost all children, the hair regrows completely over the next 6 to 12 months. The cause of the hair loss is not known but is probably a stress response to the surgery.

Mechanical Problems

The mechanical problems occurring with spinal fusions in children with CP are specific to the instrumentation system used. The current state of the art is the use of the Unit rod or similar devices; therefore, the multitude of mechanical problems that are specific to other individual systems is not addressed.

Pain in the Spine

Complaints of pain in the back after the acute postoperative period occur mainly from either the distal or proximal end. At the proximal end, there is often a 3-month period of some discomfort at the cervicothoracic junction. This discomfort has never become a chronic problem in any of our patients. If the rod is too long, or prominent, a bursa can form over the end of the rod and cause chronic discomfort. If this discomfort persists for more than 1 year, the top of the rod can be excised at approximately the T3 level and the discomfort will disappear (Case 9.13).

At the distal end, children may occasionally develop very severe halos around the pelvic leg of the rod, which most typically occur 1 to 3 years after surgery (Figure 9.15). If these individuals are having pain, especially if the pain is increasing, there may be a low-grade infection in this area. Of four children in whom we have removed the pelvic legs, infections were present in two. This infection can be treated by excising the pelvic end of the rod followed with antibiotics. In both these children, the rest of the rod did not develop any signs of infection, and the rod was solidly encased in fusion mass at the time of removal of the distal end. Many children get some halo effect around the rod but it is not painful and probably represents movement of the sacroiliac joint. The halo effect should be of concern only if there is significant pain. Then, if the surgery was more than 1 year ago, the ends can simply be removed; however, it is always important to take a culture from the area of the pelvis where the rod end was removed.

One of our children had persistent sciatica from a rod that perforated the pelvis laterally. This perforation responded to removal of the end of the rod. Also, when correcting severe lordosis, several of our children complained of neuritic symptoms in the legs, which resolved over the first postoperative year.

Proximal End Prominence or Wire Prominence

As previously mentioned, if the rod is left too long, it will often appear prominent and may develop a symptomatic chronic bursitis. This bursitis can be easily treated by cutting the rod at the T3 level and removing the proximal

Figure 9.15. Large halos occasionally develop around the pelvic legs of the Unit rod. These halos are due to motion in the sacroiliac joint, as can be seen in this example of a child with a solid fusion at the lumbosacral level. If the halos do not form, the rod will sometimes fracture as it enters the ilium.

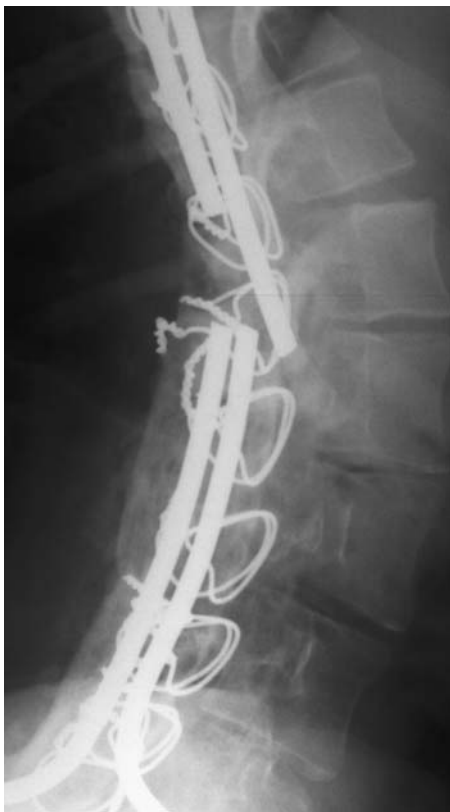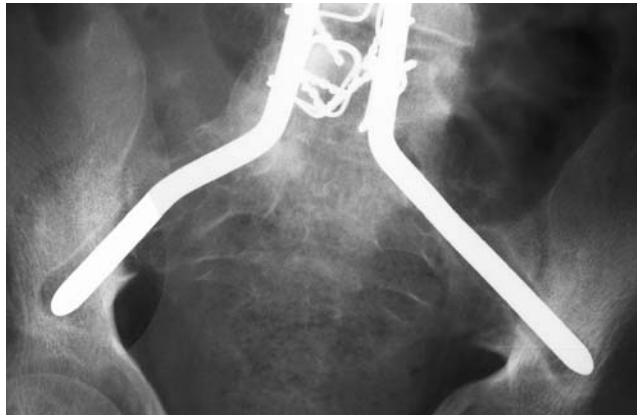


Figure 9.16. A common cause of nonunion is the use of 3/16-inch rods that are not rigidly connected. This 17-year-old ambulatory girl was seen in consultation 2 years after being instrumented with 3/16-inch rods and clear pseudarthrosis with rod fracture. She presented with severe back pain. Treatment of this pseudarthrosis requires compression instrumentation and repeat bone grafting.

end. Treating the chronic bursitis should be done after the spine has fused; therefore, we like to wait at least until children are 1 year postoperative. If there is an acute need for treatment, the rod should be exposed more distally and two rigid connecting devices used to connect the two individual rods to prevent rod motion. We had two children who have presented with open decubitus ulcers over the prominent proximal end of the rod. The decubitus ulcer was excised and the proximal end of the rod was excised with good healing of the wounds with no persistent infection occurring. We also had one child in whom a wire that was not bent down toward the rod perforated through the skin. Under small local anesthetic, an additional small incision was made and the wire was cut off at the level of the fascia. The skin was allowed to heal over without any development of infection or problems on follow-up of more than 5 years.

Nonunion–Pelvic Leg Halos–Rod Fracture

Nonunion, which was a significant problem in the early days of spinal fusion in children with CP, has disappeared. In an earlier report of the outcome of the Unit rod instrumentation,¹⁹ there were two rod fractures, both occurring at the thoracolumbar junction with nonunions (Figure 9.16). In the time period reflected in this report,¹⁹ the instrumentation was performed without the use of allograft, using only the bone harvested from the spinous process resections (Figure 9.17). There have been no reports of nonunions in children with CP with Unit rod instrumentation when copious amounts of allograft were used. In 340 posterior spinal fusions with the Unit rod using copious amounts of allograft, decorticating, and doing facetectomies, there were no recognized nonunions. There may have been some nonunions that were not recognized; however, there were only two rod fractures, both at the lumbopelvic junction in very large individuals. These individuals did not develop any halo effect in the pelvis and we believe that the rigidly fixed leg of the pelvic end of the rod fractured because of micromovement of the sacroiliac joint (Figure 9.18). These individuals remain asymptomatic.

Crankshaft

Late progression of scoliosis, especially in young children, was a common cause for the need for revision surgery in the early era of spinal fusion in children with CP. As many as 20% of children with the first versions of the Luque system had substantial late progression of their scoliosis.^{12, 14} This progression has been attributed to continued anterior growth along the anterior aspect of the spine, even after a solid posterior fusion, and it is called

the crankshaft effect. Twenty-nine children, who were fused posteriorly only using the Unit rod before closure of the triradiate cartilage, were reviewed. At skeletal maturity, none of these children had any measurable loss of correction compared with their immediate postoperative position. Crankshaft does not occur when Unit rod instrumentation is used; therefore, there usually is no concern for prevention.²² This instrumentation is so strong that it prevents this anterior growth from distorting the spine.

Seating Adjustments

One positive or negative effect of major deformity correction in teenagers with severe spinal curves is a dramatic change in their sitting height. Although this is very dependent on the specific deformity, sitting height gains of 10 to 15 cm are common. These major changes in the children's body shapes also require that their wheelchairs have major adjustments before they are allowed to sit in them for a significant amount of time. Also, parents should be warned about this significant gain in height, especially if they are transporting these children in vans with wheelchair lifts, as frequently these vans were adapted when the children were smaller or during a time when significant scoliosis was already present. Parents may need to make plans for modification of their vans or for a different wheelchair. This planning should occur before attempting to place children in the van after discharge following spinal fusion so that the parents will not suddenly realize that they can no longer transport the child in their van.

Neck Stiffness

Almost all children who can communicate will complain of neck stiffness after spinal surgery. Stiffness is due to soreness and decreased range of motion from the surgery at the thoracocervical junction. Often, these children's necks feel stiff because their heads are in a very different and much more stable position. With the spine fully corrected, the head sits naturally at a correct angle on top of the shoulders without much force. Some children perceive this change as being unnatural because they were so used to the force required to hold their head upright. This complaint almost always resolves after 3 to 4 months postoperatively as these children get used to the new sense of their head position, and the soreness from surgery usually subsides.

Decreased Floor or Bed Mobility

There is a risk of substantial functional loss in children who cannot sit independently but can move on the floor by rolling, often using considerable trunk action. These children can often roll in bed as well to change their position by using this combination of trunk extension and trunk torsion. The

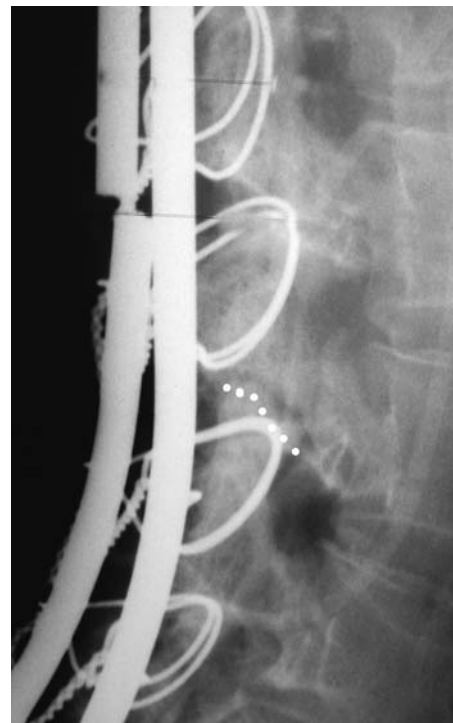
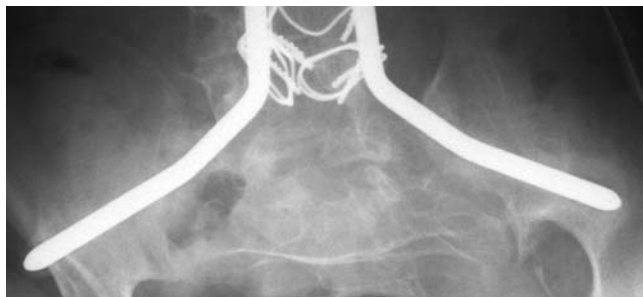

Figure 9.17. Nonunion and Unit rod fractures are very uncommon if there is complete facetectomy, transverse process decortication, and application of a large amount of bank bone. This boy is a large ambulatory boy with diplegia who suddenly developed pain 3 years after surgery. He has minimal fusion mass at the thoracolumbar junction with probable pseudarthrosis. We have not had a documented pseudarthrosis in over 300 cases, although there are likely pseudarthroses that have not become symptomatic. This case shows that it takes a lot of force for 3 years to cause rod failure.

A



B

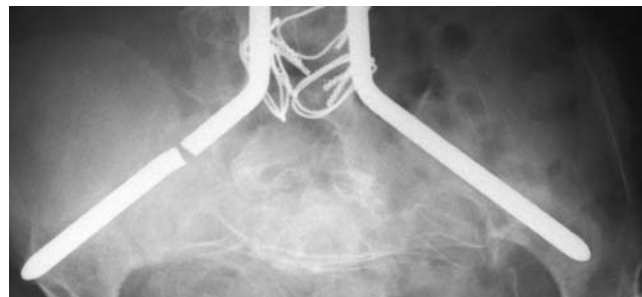


Figure 9.18. Rod fracture can occur at the distal bend on the Unit rod when there is solid fixation of the pelvic limb in the pelvis (A). The spine radiograph demonstrates excellent fusion mass along the whole spine, and the rod fracture was found inadvertently on a 2-year surgical follow-up radiograph (B). This girl is asymptomatic.

most common complaint of loss of function from parents and caretakers is that these children can no longer turn in bed and no longer have floor mobility. Most of these individuals are at a stage when they are becoming young adults, and the difficulty of getting them up off the floor, in addition to the socially unacceptable posture of rolling around on the floor at home, makes this loss of floor mobility a relatively minor problem. However, the loss of ability to turn in bed is a major problem because caretakers now must attend to these individuals every time they need to change their position. Some children will slowly regain this ability over 1 to 2 years after surgery; however, other individuals can never regain the ability to change their position in bed. A good effort should be made, with intensive physical therapy to try to teach these individuals to turn themselves as well as provide them with adaptive equipment such as rails or overhead bars if these devices can be demonstrated to be useful. These individuals usually make other gains, such as dramatic improvement in sitting ability, which allow the caretakers to see this loss of function as a negative part in an overall greater improvement. If caretakers express overall dissatisfaction with posterior spinal fusion, this loss of function is the most common reason for the dissatisfaction. This small group of children can be preoperatively identified, and parents and caretakers should be warned of this possible loss of function.

Postoperative Infections

Major postoperative infections are among the most serious complications that occur following surgery. Infections have been the cause of the only neurologic deficits we have had after spinal fusion, and they are the most severe insults that delay recovery and have the potential for causing death, paralysis, or loss of hardware.

The initial increase in fevers, which typically occurs in the first 5 days after surgery, are almost always respiratory based. As such, these fevers should be treated with broad-spectrum antibiotics if these children remain febrile, even if there are no positive cultures. From 3 days postoperatively until discharge, urinary tract infections should always be considered as a possible source of febrile events or sepsis. As long as children have intravenous lines, these lines need to be cultured and observed as possible sources of sepsis. All intravenous lines and arterial catheters should be removed as soon as they are no longer being used. The central venous line can also be a source of sepsis; however, it is crucial to providing nutrition and should not be removed unless there is cultured evidence that it is infected and a likely source of the ongoing infection. If these central lines are routinely removed as soon as there is a fever, these children will hardly ever get adequate intravenous feeding and a new problem will result. The goal of this aggressive management of postoperative sepsis is to avoid septicemia, which might seed the large operative wound and hematoma.

Persistent Fevers

Persistently high fevers, usually starting between days 7 and 14 postoperatively, sometimes with elevation of the white blood cell count to 20,000, are occasionally encountered. These high temperatures will rise to over 40°C and an aggressive search for a source of infection should include chest radiographs, sputum cultures, urine cultures, and blood cultures. The wound should be aspirated with a long 18-gauge needle and the hematoma fluid sent for culture. This aspiration is performed by going through healthy paraspinous muscle and not through the operative wound. Aspirating through the operative wound may leave a draining injection site that can itself become the

source of an infection. Abdominal ultrasound and blood tests should be performed to rule out pancreatitis and colicystitis. Broad-spectrum antibiotics should be started. If the fever rises above 40° to 40.5°C and does not decrease with antipyretics, body cooling should be instituted using cooling blankets or ice packing. A small group of children are never positive on any culture but continue to have very high fevers. If these high fevers continue for 5 to 7 days, all antibiotics should be discontinued and temperature control maintained as needed with antipyretics and external cooling, but also with a persistent awareness of the possibility of a missed infectious source. The longest time we have seen for this persistent febrile course was 4 weeks; the fever then resolved without any residual effects. More commonly, the high temperatures persist for 3 to 5 days and then slowly decrease with a pattern of afternoon spikes. The source of these idiopathic fevers is unknown, but it may be a rejection phenomenon from the large volume of bone graft that is used or may be related to poor central neurologic temperature control, which many children with severe quadriplegic pattern CP also have.

Superficial Wound Infections

Superficial wound infections occurring at some level, by which we mean that a small area of the wound opens and a subcuticular suture becomes exposed, are quite common. There are occasionally larger areas of erythema in which the superficial area opens more. These superficial wound problems can be treated easily with local wound care and with oral antibiotics if there is erythema. These superficial wounds do not have much drainage. They can be covered with dry gauze, and in 12 to 24 hours, they should not soak a thin gauze sponge but should leave a circular area of drainage somewhat larger than the wound that it was covering. These children do not have significant systemic signs of infection, such as fever and leukocytosis. If the drainage is larger or the children have systemic problems, it is important to make sure that a deep wound infection, meaning an infection beneath the muscle fascia, is not present. It is very important to do a watertight careful wound closure of the deep fascia because if any open areas in the fascia are left, almost every minor superficial wound problem will become a deep wound infection. This careful closure is undoubtedly the most important technical thing that surgeons can do to avoid deep wound infections in spine surgery, especially in children with CP.

Acute Deep Wound Infection

Acute deep wound infection is the most common serious complication occurring in spinal surgery in children with CP. The incidences from the literature vary because many reports of spinal surgery, even those directed at studying wound infection rates, combine all neuromuscular patients, including spina bifida patients. This is not appropriate because children with spina bifida are insensate and have poor skin and will always have a higher infection rate than children with CP. Children with CP probably have the next highest infection rate, although this is difficult to determine definitely.⁸ Again, the severity of children's neurologic involvement is probably the highest risk factor for the development of a deep wound infection. However, we have had deep wound infections in ambulators as well as in children with the most neurologic involvement. In our latest review,⁴³ we reported 6 deep wound infections in 172 cases for an incidence of 3.7%. The incidence is similar to other reports when an attempt is made to separate out the various specific diagnoses that have been mixed together. Sometimes, making the diagnosis is very easy because the wound is grossly open and infected and the children appear generally septic, being febrile with leukocytosis. However, more

commonly, children have a small superficial wound that is draining more than expected and they are not really septic. Gentle probing of this superficial wound should give a definite resistance at the level of the deep fascia. If during this probing the deep fascia is easily breached and the probe reaches to the fusion site, a deep wound infection is present by definition. Sometimes, the fascial defect is proximal to the more superficial wound and will be missed in this initial probing. An aspiration of the deep wound using a long 18-gauge needle should also be performed if there is still concern. If no hematoma is aspirated, it may mean that the hematoma has decompressed itself and a deep wound infection is present. The aspiration is only definitive if good hematoma is aspirated and is found to be sterile. If it is unclear whether children have deep wound infections, it is generally best to just observe the children over several days and allow the wound to declare itself. A superficial wound infection or wound opening will gradually have decreasing drainage; however, a deep wound infection will continue with copious amounts of drainage with fluid being expressed proximal or distal to the superficial wound. These deep wound infections become clarified with time through this careful observation. All scans, such as bone scans and white blood cell-labeled scans, are of no use in this acute phase after spinal fusion. Obtaining scans to determine the presence of a deep wound infection is a waste of time. By careful observation over time, the deep wound infection will become defined clearly (Case 9.14).

Approximately one third of acute deep wound infections are due to an infection from outside in through an open superficial wound. These infections usually occur at the far distal end where a small wound opens and then becomes soiled during a bowel movement. This area is often difficult to get a firm, tight fascial closure with good subcutaneous and skin closure. If small wound drainage starts, and the wound is contaminated with feces, a multiple bacterial species infection with fecal bacteria will result. These have been the worst infections, with one child becoming severely septic. In addition to careful wound closure, as the initial dressing is removed from the caudal end of the wound, it is important to keep an occlusive dressing on the distal third of the wound to prevent this type of contamination from minor wound leakage. We had two cases where the clear cause of the deep wound infection was dehiscence of the deep fascial closure, which then allowed communication with a minor superficial skin opening. This is a clear and completely avoidable complication. Another third of our deep infections were linked to sepsis at other sites, such as urinary or respiratory infections causing septicemia. These infections are usually single organism, either gram positive or gram negative. The last third of our infections, most of which are gram positive and probably occur as contamination of the wound intraoperatively, occur without a clear source.

Treatment

Acute deep infections. Treatment of deep wound infections should be standardized because there is a tendency for surgeons to want to deny the severity of the infection and not approach it with the level of care the wound needs. All deep wound infections should be taken to the operating room and aggressively debrided, irrigated, and packed open with a betadine-soaked sponge. The whole spine wound usually does not need to be opened; however, the area of the abscess does need to be opened to the full extent of the abscess. All reports of other treatments have reported significant rates of failure, meaning that the hardware needs to be removed up to 50% of the time.⁴⁴ The packing then should be changed twice daily starting the day after surgery. This can almost always be done on the ward; however, if the



Case 9.14 Jordan

Jordan, a 14-year-old boy with severe spastic quadriplegia, had an uneventful spinal fusion and was discharged home to his mother's care on the tenth postoperative day. Two weeks after he was discharged, his mother felt that he was warm, and she was concerned that his wound seemed to be a little warmer. She took him to see the pediatrician who thought he might have some viral syndrome and started him on oral antibiotics. Jordan returned to school, and over the next week started to have some drainage from the back wound. (Figure C9.14.1) His mother returned to see the pediatrician, where his

antibiotic dose was increased. He continued to have fever spikes to 40.5°C and seemed ill to the school personnel. The school nurse referred him back to the CP clinic where an evaluation showed that he had a temperature of 39.4°C and a white blood cell count of 14,300. The erythrocyte sedimentation rate (ESR) was 127. The back wound had a small area of approximately 5 mm in length that was draining a purulent material (Figure C9.14.2). When pressure was placed on the wound 10 cm distal to the draining, a significant increase of the drainage occurred. Blood cultures were sent and he was taken to the operating

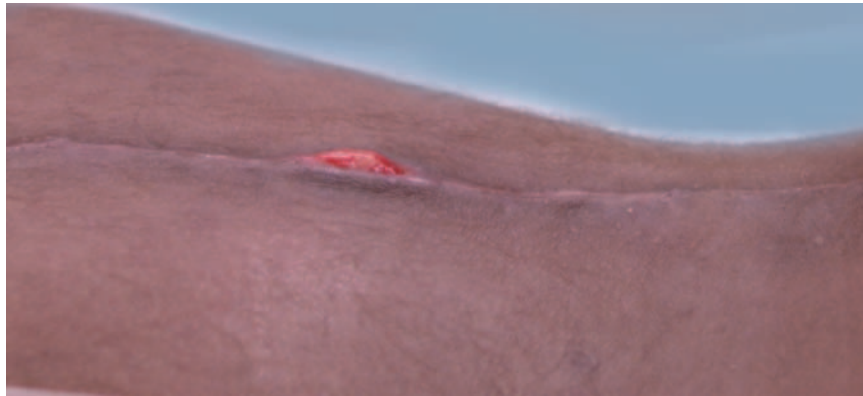


Figure C9.14.1

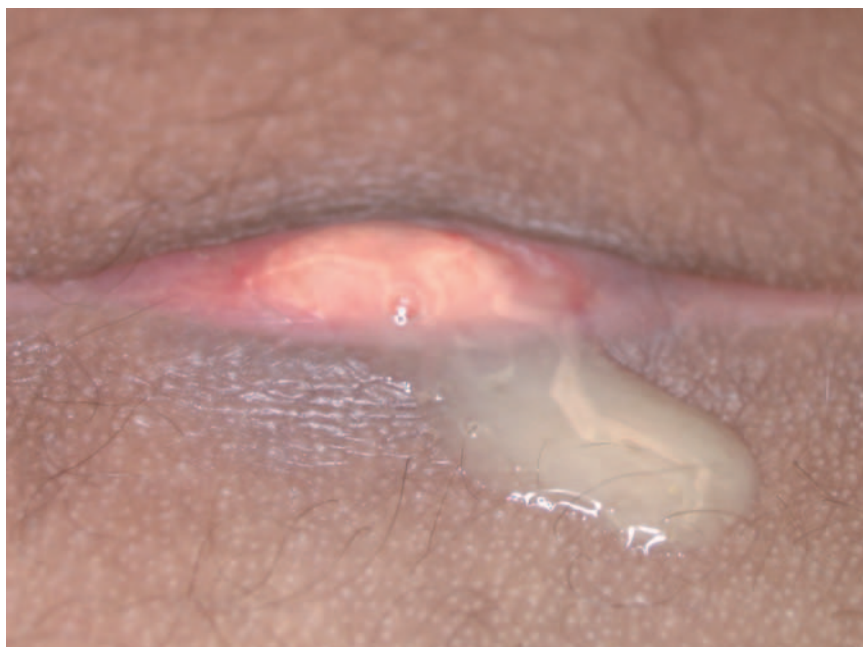

Figure C9.14.2

room. When the distal 25% of the wound was opened, it was filled with purulent material surrounding the rod and bone graft. No purulent material could be expressed from the proximal end of the wound. Tissue biopsy was sent for culture and sensitivity, and the wound was copiously irrigated and packed with betadine-soaked sponges. A central line was inserted in expectation of needing long-term antibiotic and he was started on cephazolin. The following day the dressing was changed on the ward under sedation, and dressing changes were started three times a day. The culture grew *Staphylococcus aureus*, and he was continued on high-dose nafcillin. After 10 days, the wound had less purulent material and was getting drier, so the dressings were changed to saline-soaked packing. After 2 more weeks, then 3.5 weeks after drainage, the wound was developing excellent granulation tissue and the packing was discontinued in favor of a loose wet-to-dry cover dressing. After 3 to 4 weeks healthy granulation tissue

covers most of the hardware (Figure C9.14.3), however some gray necrotic fascia may need to be debrided (Figure C9.14.4). He did not have a fever for 3 weeks and the ESR was 82. At 4.5 weeks after the drainage, the hardware was covered, and he was discharged home to receive the remaining 10 days of intravenous antibiotic and to continue the wet-to-dry cover dressing. Jordan returned 6 weeks after drainage, and the central line was removed and he was switched to oral trimethoprim sulfamethoxazole twice a day. The ESR had decreased to 53. The wound was still open, 15 cm in length and 4 cm wide. Three weeks after this, he was seen in the outpatient clinic with the wound completely healed. The antibiotic was decreased to once a day, and his mother was informed that she was to continue with this for 6 months. Radiographs showed good healing and formation of fusion mass 4 months after the original fusion.

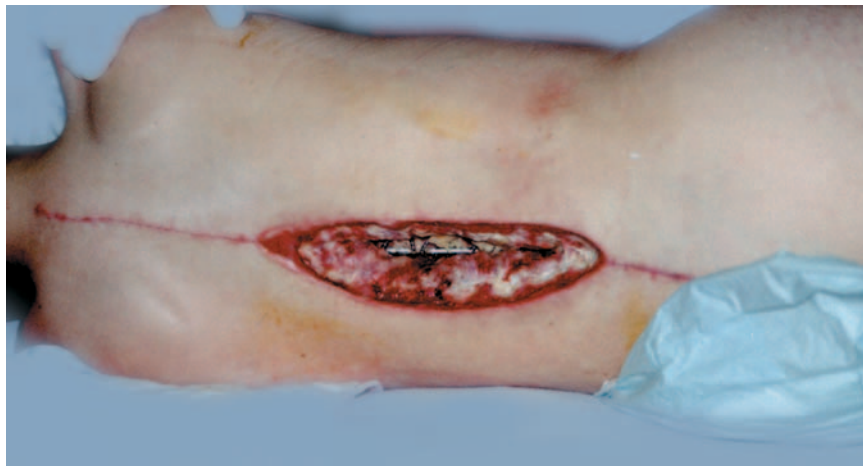

Figure C9.14.3

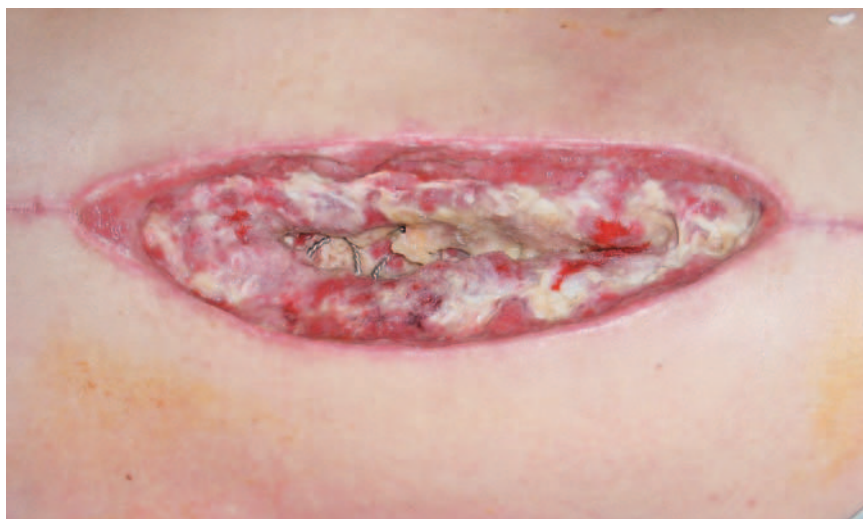

Figure C9.14.4

wound is very large, another return to the operating room for dressing change and debridement under general anesthesia may be required. The debridement may continue on the ward as the necrotic tissue separates and is then removed. After all the necrotic tissue has been removed, the wound is allowed to close by secondary intention from the bottom up. The packing should be very loose with a saline-soaked sponge; however, it should be clear that the granulation tissue closes over the rod and that it does not close leaving a fluid-filled cavity as the skin closes over the top. Managing this closure requires that physicians continue to check the wound every day or two. This need for frequent wound checks and intravenous antibiotics means that these patients are kept in the hospital for 4 to 5 weeks of treatment until granulation tissue has covered the rod, which is the criteria for discharge to outpatient and home nursing care. Typically, intravenous antibiotics specific to the results of the culture are continued at full doses for 6 weeks. After 6 weeks, children are kept on antibiotic suppression therapy with one antibiotic orally if a simple antibiotic is available against the specific organism. This suppression therapy is continued for 6 to 12 months.

Except for one patient with a very severe infection of the whole spine combined with meningitis, all our other deep wound infections have cleared and the hardware has remained covered and in place without evidence of any late infections.

Late deep wound infections. We have had two late deep wound infections occurring 2 and 5 years after the original surgery. One of these was directly related to a concurrent urinary tract infection; however, the other was a staphylococcus infection that was not directly related to any known concurrent problem. Both these infections involved the whole spinal rod and required removal of the rod and all wires. Solid fusions were present in both cases. Both wounds healed, and one child has done well for 6 years except the fusion mass has bent, so he now has an additional 20° of scoliosis (Case 9.15). The other boy healed his wound well and had almost closed the deep wound when he had a sudden period of shortness of breath followed by a cardiac arrest at home. No autopsy was done. We have never seen a case of late sterile drainage requiring removal of the hardware, which has been reported with other systems.²³

Special Problems with Spinal Surgery

Doing Revision Spinal Surgery in Children with Cerebral Palsy

Doing revision surgery in children with CP is often a difficult task; however, this depends on the specific problems that are to be addressed. Usually, there should be a very specific goal to be accomplished, such as getting children into better sitting positions, treating painful nonunions, or improving respiratory function. Based on a well-defined problem, a careful plan to achieve these specific goals should be outlined.⁴⁵

Fall-Off from a Short Fusion

If the identified problem is that the previous fusion was performed too short, leaving severe pelvic obliquity and an increased residual curve, it is often possible to remove the distal part of the implant and use the proximal end as fixation for the new instrumentation (Case 9.16). Using this proximal end avoids having to remove all the old instrumentation and provides a source for rigid proximal fixation. The apex of the curve must be identified, and



Case 9.15 Charles

Charles, an 18-year-old male with severe spastic quadriplegic CP was 5 years after a successful posterior spinal fusion with Unit rod instrumentation when he presented with sepsis (Figure C9.15.1). He was noted to have mild erythema along his spine, which was aspirated and grew *Proteus*. The same bacteria also cultured out from his urine, so this was believed to be a hematogenous infection from his urinary tract. The spine was explored and the whole rod was found to be involved. All hardware was

removed (Figure C9.15.2). With dressing changes and antibiotic, the infection cleared. No pseudarthrosis was present when the hardware was removed. However, by 18 months after rod removal, the scoliosis curve had increased 20° and he had a noticeable increase in his physical position (Figure C9.15.3). This increased scoliosis was thought to be caused by bending of the fusion mass. This problem should not progress further; however, he has been lost to further follow-up.

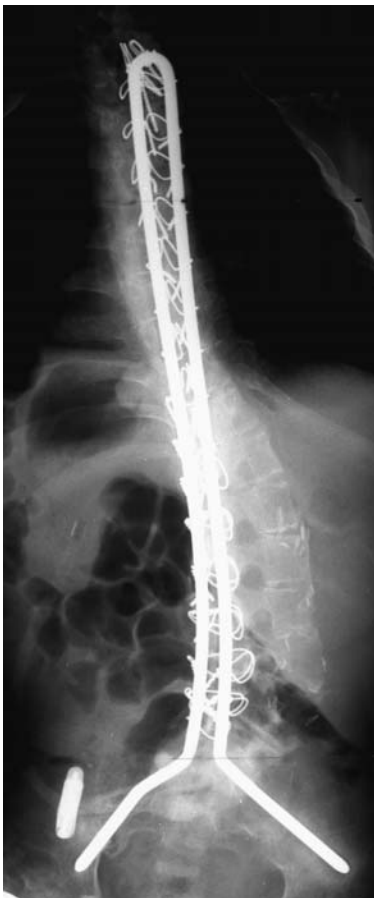

Figure C9.15.1

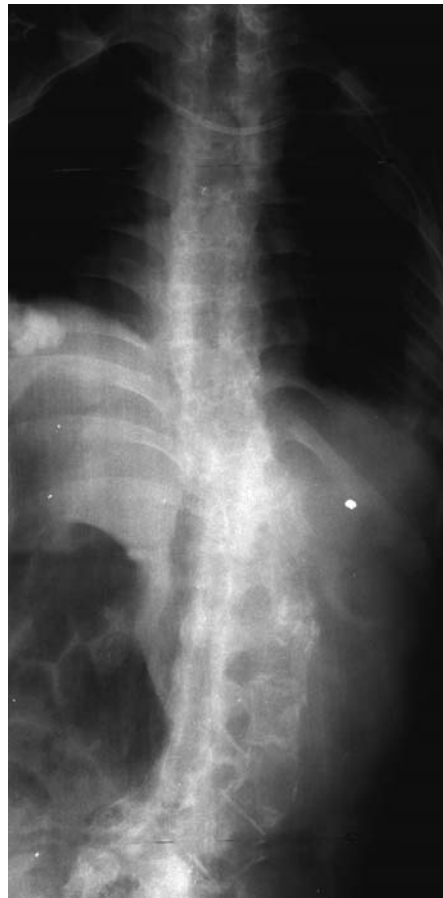

Figure C9.15.2

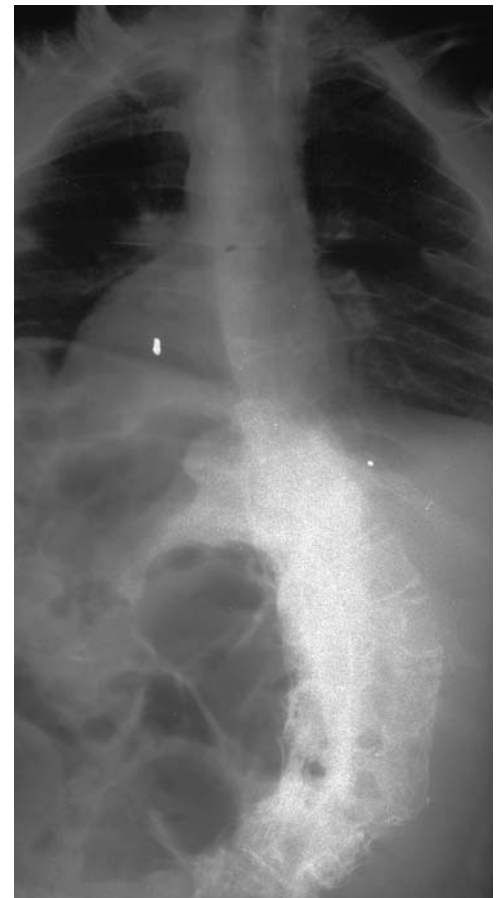

Figure C9.15.3

osteotomies of the previous fusion mass must extend at least past the apex of this curve if correction of the deformity is to be accomplished. If anterior instrumentation was used, it usually needs to be removed, and the anterior disk spaces need to be osteotomized to allow for correction. If the deformity

is a proximal fall-off into severe kyphosis or scoliosis, the anterior disks must be excised to T2–T3 if at all possible, and the disectomy should extend to at least T6–T7 because posterior osteotomies will need to be performed this far distally. Sharp, short, high thoracic curves are extremely stiff and hard to correct; therefore, a significant amount of the correction needs to be obtained



Case 9.16 Ryan

Ryan, a 16-year-old boy, presented to the CP clinic saying that he was unable to sit. He had severe spastic quadriplegia but had normal cognitive function and was a sophomore in high school. He was unable to sit and stayed reclined, which made interaction in school difficult. He had an anterior instrumentation followed by a posterior instrumentation 4 years ago. Over the past 2 years, he had noticed progressively more problems with sitting (Figure C9.16.1). A physical examination demonstrated an extremely rigid spine with a fixed severe pelvic obliquity. Radiographs demonstrated a Dwyer instrumentation with a Harrington rod posteriorly with severe pelvic obliquity (Figure C9.16.2). He was taken to the operating room where the anterior instrumentation was removed and osteotomies were made through the fusion disk segments

from T11 to L4. One week later he was taken back to the operating room where the posterior wound was opened, the distal part of the rods were cut and removed, and osteotomies were performed posteriorly from T11 to L3. He was then instrumented to the pelvis and the rods were attached to the proximal Harrington rods (Figure C9.16.3). Good trunk balance was accomplished, but he needed a third procedure 3 months later to realign his hips. This demonstrates a case of largely historical interest because this type of instrumentation is now recognized as being inappropriate for children with spastic quadriplegia. Although this is a large operation, these deformities can still be safely corrected, and it is especially beneficial in a healthy, cognitively intact individual such as is demonstrated in this case.

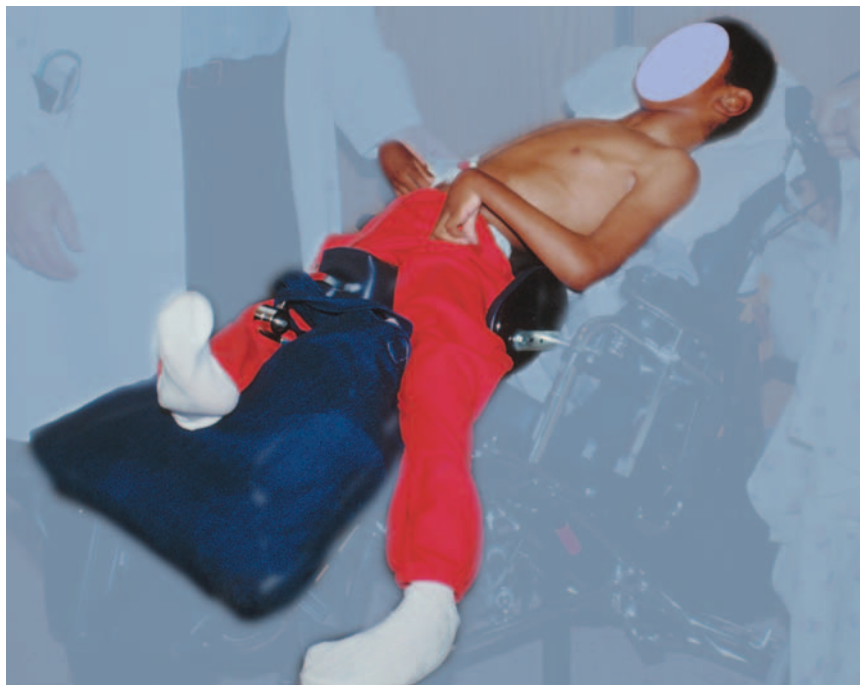

Figure C9.16.1

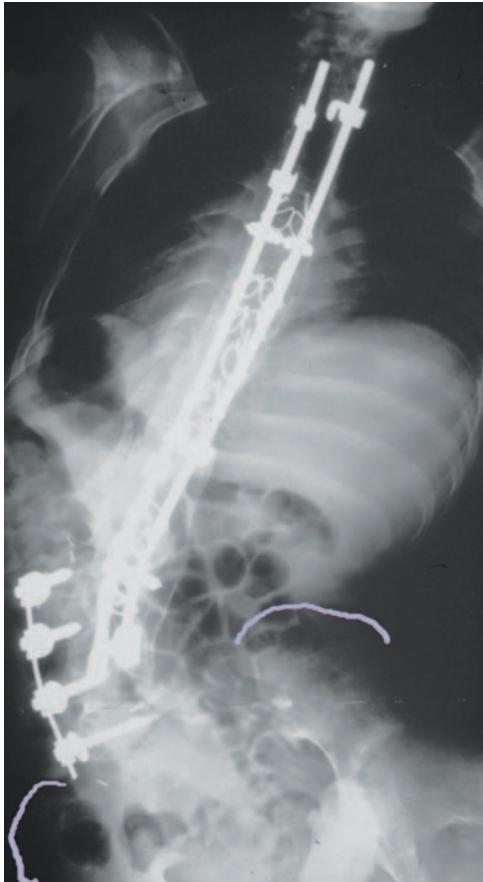

Figure C9.16.2

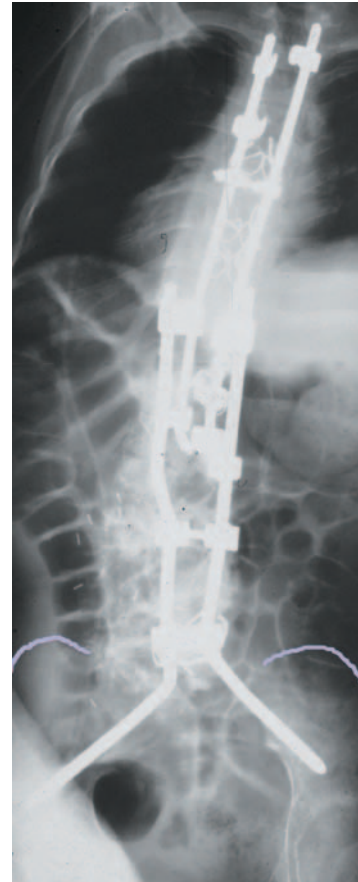

Figure C9.16.3

in the midthoracic area. If a rod is present distally, it too can usually be cut off and then the proximal rod can be attached to the distal end.

Torsional Collapse

Another reason for requiring revision in the past has been severe torsional collapse causing respiratory restriction when the unconnected independent rods twisted across each other (Case 9.4). This problem is mainly of historical interest because these unconnected rods are no longer used. This whole instrumentation system has to be removed, and multiple osteotomies and pseudarthrosis levels have to be taken down with the insertion of a new rod. Wires can sometimes be salvaged in this construct and used with the new rods. New wires do have to be passed, and sometimes this can be done between fusion masses where the mature fusion mass may have a medullary space and provide good strength. Attempts may also be made to pass wires in the sublaminar space; however, this is difficult in sublaminar spaces where previous wires had been passed. Usually, dense scarring is present in the epidural space, which can sometimes be subperiosteally elevated with blunt elevators and then new wires can be passed.

Pseudarthrosis

Pseudarthrosis has been a problem in the past with other instrumentation systems and if it does occur, the pseudarthrosis must be cleaned and copious amounts of bone graft applied, followed by rigid compression fixation across

the pseudarthrosis site. Bone grafting alone, especially in children with CP, is not likely to work (see Figure 9.16).⁴⁵

Hardware Failure

Another indication requiring revision surgery is when there has been acute failure of the hardware. In the Unit rod, this usually occurs after the rod has been cut and then connected with connecting devices. These rod-connecting devices, especially if only one level of connection is used, have a high failure rate. Based on our failure rate, we now always use at least two levels of connections, either one end-to-end connector and one side-to-side connector, or two side-to-side connectors. However, as soon as this failure is recognized, the patient should be returned to the operating room and the instrumentation repaired, especially if the failure is relatively acute, before any bone fusion has occurred. Again, this complication can be avoided with proper rod connection.

Correcting Deformity Post Dorsal Rhizotomy

Posterior dorsal rhizotomy was popular in the late 1980s and the early 1990s and has left a group of children with significant spinal deformities who have no posterior laminae for fixation. As noted in the section on hyperlordosis, the fixation requires the use of pedicle screws. The incidence of spinal deformity after dorsal rhizotomy is probably higher; however, the real difference is unknown.⁴⁶ Spinal deformity after dorsal rhizotomy occurs primarily in nonambulatory children. The most common severe deformity is hyperlordosis, which can occur with scoliosis or as an isolated deformity (Case 9.9). If the Fazano technique of thoracolumbar laminectomy is utilized, then a thoracolumbar junctional kyphosis tends to develop. Treatment of this deformity is as previously outlined in the specific deformity sections.

Spondylolysis and spondylolisthesis occur in children who had the five-level lumbar laminectomies at a significantly higher rate than the normal population. In ambulatory children with diplegia who had these dorsal rhizotomies, approximately 20% will have asymptomatic spondylolysis and spondylolisthesis.⁴⁷⁻⁵⁰ It is unclear how great a problem these asymptomatic lesions will be over the lifetime of these children. There are occasional children who develop severe multiple level spondylolysis and spondylolisthesis requiring surgical stabilization. The risk factor for developing spondylolysis and spondylolisthesis appears to be active ambulatory children with diplegic pattern involvement.⁴⁹ These lesions have not been reported in nonambulatory dependent sitters.

Correcting Spinal Deformity in Ambulatory Children

Occasionally, children with hemiplegic or diplegic pattern CP develop scoliosis with a pattern similar to idiopathic adolescent scoliosis. This scoliosis may be idiopathic adolescent scoliosis; however, there is no way of knowing for sure. If the scoliosis has a pattern consistent with idiopathic adolescent scoliosis and children are ambulatory with diplegia or hemiplegia, then indications for treatment similar to idiopathic adolescent scoliosis should be applied. There are also ambulatory children with CP who clearly have long curves based with an apex at the thoracolumbar region with significant truncal malalignment. These more typical neuromuscular curves often extend well into the lumbar spine and often have a significant element of hyper- or hypolordosis. These neuromuscular curves should be treated as CP spinal deformities, with instrumentation going to the pelvis using the Unit rod (Case 9.17). There is a widely circulated orthopaedic myth that fusion to the pelvis in ambulatory children with CP will prevent them from walking

postoperatively. This myth has never been substantiated in the literature and probably originated in the early days of posterior spinal surgery with the use of Harrington rods, which removed all these children's lumbar lordosis when it was used for a fusion to the pelvis. Removing all this lumbar lordosis and utilizing the old Harrington rod instrumentation to the pelvis would make it hard for children to walk after fusion. We instrumented many ambulatory children to the pelvis using the Unit rod, and none had any substantial change in their ambulatory ability.

Spinal Deformity in Very Young Children with Cerebral Palsy

Occasionally, children develop a spinal curve that is very stiff with a severe magnitude as early as age 3 to 5 years. These curves may approach 90° in magnitude and may become very stiff, making orthotic management difficult. Orthotic management also usually fails because the children have difficulty tolerating the orthosis. If the curve is in the thoracic area only, a limited anterior and posterior fusion in the thoracic area using sublaminar



Case 9.17 Allison



Allison, a 10-year-old girl with mild mental retardation and ambulatory spastic diplegia, presented with a severe neuromuscular type scoliosis that her mother felt was impacting her ability to walk. An examination showed no change in her spasticity, and she was not taking any medications. Based on the severity of the scoliosis, it was recommended that she have a full spinal fusion with the Unit rod instrumentation (Figure C9.17.1), which she had without problems. Six months after surgery she was walking as well or better than preoperatively, and by 1 year after surgery her gait was more stable than preoperatively according to her mother.

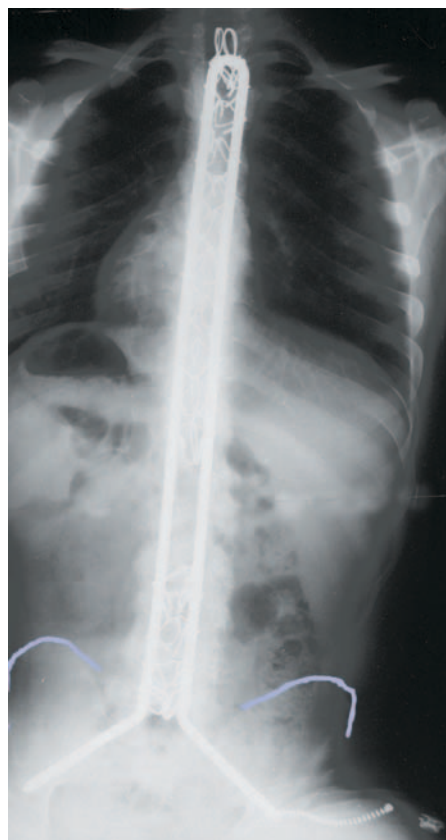

Figure C9.17.1

wires and the superior part of the Unit rod is the recommended treatment. The goal of this treatment is to extend the fusion to the pelvis in case the curve deteriorates as the children grow. This extension will at least allow children to gain height through growth from the lumbar vertebrae. In one child, this growth continued substantially, and a scoliosis in the lumbar spine has not developed; therefore, no additional treatment was required (Case 9.18). In a second child, growth continued for 6 years and then a rather severe curve extending into the lumbar spine and pelvis developed, requiring a revision surgery. Substantial height was gained, however, and treatment was successful (Case 9.19). Another child was treated with an early thoracic only fusion and did well for 3 years until she developed an unassociated acute lymphocytic leukemia, of which she died. There was only minor loss of correction over the 3-year period. Another option that may be tried is to implant a spinal rod that is fixed with sublaminar wires but does not have a fusion. It is hoped that children will continue to get taller, growing off the superior end of the rod. The phenomena has been well documented to occur in children with muscular dystrophy who were not fused and continued to grow into their adolescent years.⁵¹

Spinal Deformity in Very Small Children Who Are Older

Growth inhibition in children with severe neurologic disability may be significant with children being only 15 kg in weight at 10 years of age, but also having severe scoliosis. These children should be instrumented and fused, but instead of using the regular 6.5-mm-diameter Unit rod as used in the normal larger child, the thinner 5.0-mm Unit rod should be used. The large Unit rod can be used in most children up to 15 kg in size; however, it is extremely difficult, as the rod gets shorter and because of its severe stiffness, to be able to manage it in the small thin osteoporotic pelvis. The smaller Unit rod is available up to 330 mm in length and is much easier to use and has sufficient strength for these small children. The thinner rod should not be used in taller children because of the risk of rod fracture and the development of pseudarthrosis, which would subsequently require a revision.

Doing Posterior Spinal Fusion When Families Refuse Blood Transfusions

Some families will refuse a blood transfusion because of religious beliefs, but still desperately want their children to have a spinal fusion. In general, we strongly advise these parents to leave the children alone and accept the consequence of the scoliosis. However, we have done an instrumentation and fusion without transfusion when families strongly insisted on two occasions. This technique requires that only the spinous processes be exposed to the point that the interspaces can be opened and the sublaminar wires passed. The distal (pelvic) end of the wound is exposed and the Unit rod is inserted into the pelvis, and then the wires at the distal half of the wound are tightened onto the rod, leaving the rod protruding proximally. Bone graft is then applied over the rod and the wound is closed around this packed bone graft as far proximally as possible. If the blood loss is less than 5% of the blood volume, the superior half of the wound is similarly opened, the rod wired into place, and the wound closed. The goal of the surgery is to complete the whole operation with less than 10% loss of the blood volume. If 10% of the blood volume loss is encountered, the rod should be cut off and the wound closed at the level of surgery. The operation can then be completed in 2 to 3 weeks when children have made new blood. This is a very inadequate surgery because there is no decortication and no facetectomy, with only very minimal bone exposure. A high rate of pseudarthrosis is expected.



Case 9.18 David

David, a 5-year-old boy presented being unable to ambulate with mild lower extremity spasticity, mental retardation, and very poor motor control. A relatively stiff thoracic scoliosis was noted. Because of his young age and relatively straight lumbar spine, he was fused only to T12

(Figure C9.18.1). Over the next 10 years, he completed his growth to a height of 170 cm, gradually developing the ability to do assisted ambulation in the home. His spine remained straight (Figure C9.18.2).

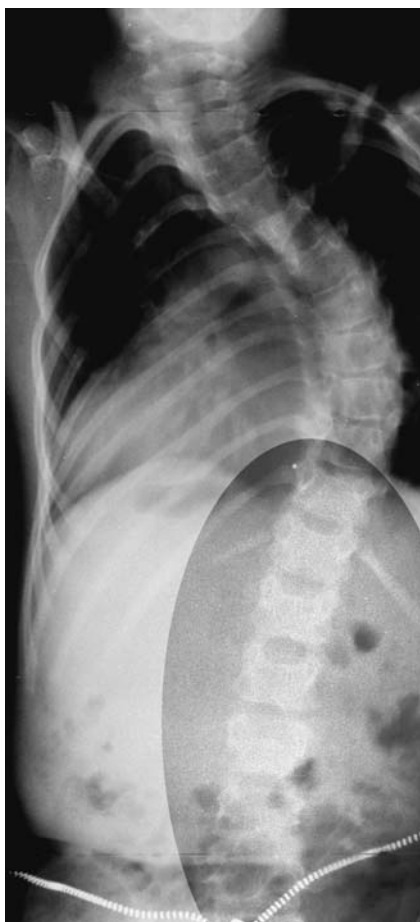

Figure C9.18.1

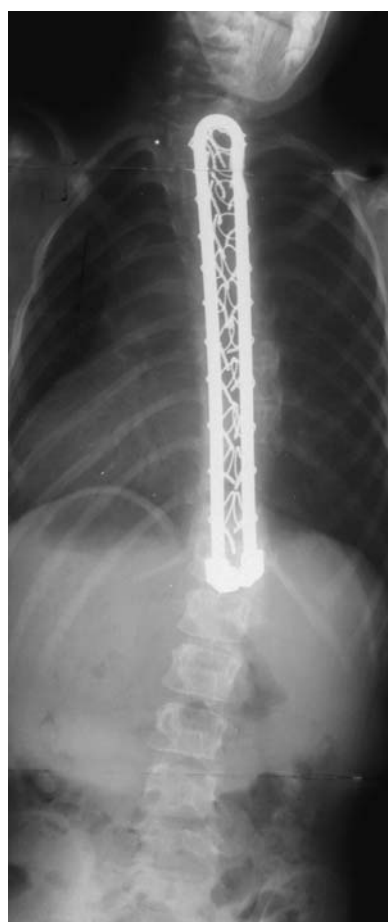

Figure C9.18.2

One child, who was done 10 years ago, was lost to follow-up less than 1 year following surgery and the other child was done only in the past year and a half, so there is no long-term follow-up available for this procedure.

Dealing with Families Who Refuse Spinal Fusion

There are families who choose not to have a spinal fusion even when it is the best choice for their children. It is important for families to have a good understanding of what it means for their children to continue to grow as



Case 9.19 Roger

Roger, a 4-year-old boy with severe spastic quadriplegia, presented with his mother with a concern about his increased scoliosis. He also had grand mal seizures with poor seizure control, was a poor feeder, and had gastroesophageal reflux, which was being medically managed. He was scheduled to have a gastrostomy tube inserted. A radiograph demonstrated a 60° very stiff scoliosis. Because he had many gastrointestinal problems, he was a poor candidate for spinal bracing; therefore, we agreed to see him again in 4 months. During that time, he was fed by a gastrostomy tube and had gained 2 kg in the previous 2 months. A spine radiograph showed a scoliosis that had

progressed to 80° and was very stiff (Figure C9.19.1). He was instrumented from T1 to T12 with sublaminar wires because the majority of the scoliosis was in the thoracic spine (Figure C9.19.2). He was then followed for 6 years as he grew, until he again developed increasing deformity distal to his previous instrumentation (Figure C9.19.3). He had an anterior lumbar release and was instrumented to the pelvis, attaching to the proximal rod (Figure C9.19.4). He had good trunk balance and had gained height by taking this two-step approach. Because of his seizures and poor feeding history, he would have been a very poor candidate for a subcutaneous growing rod.

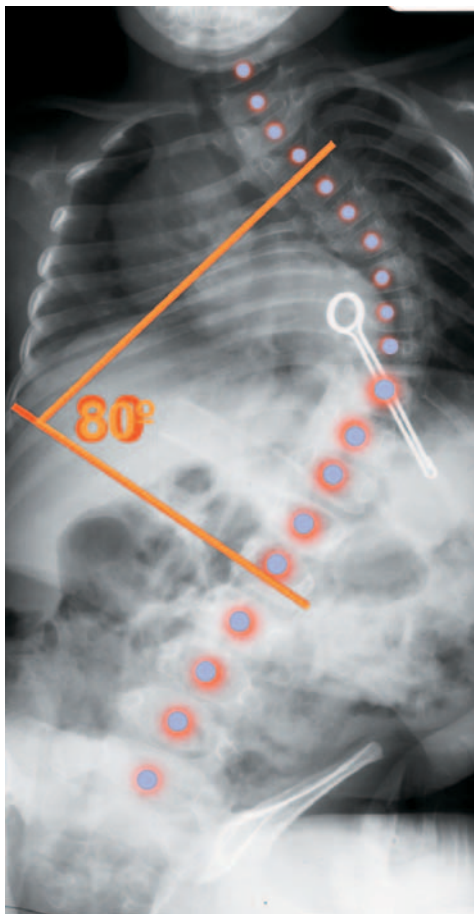


Figure C9.19.1

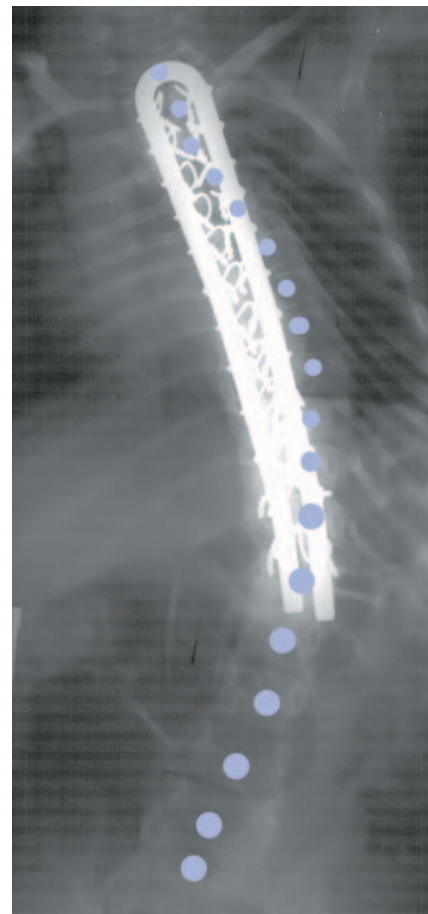


Figure C9.19.2

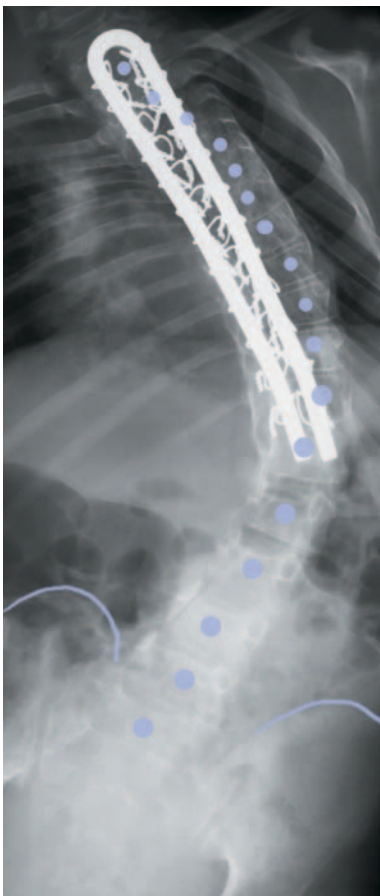

Figure C9.19.3

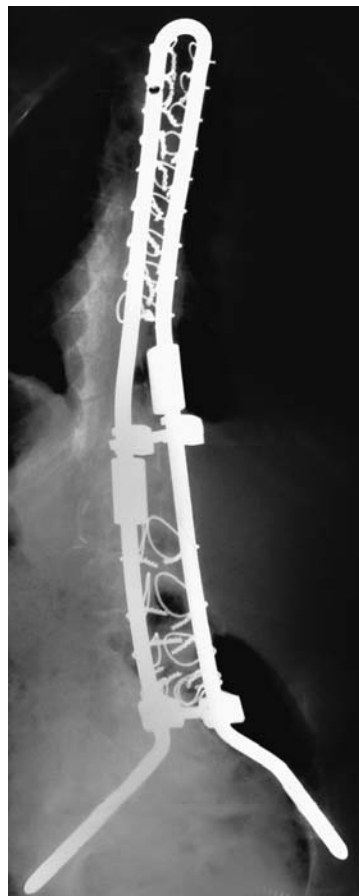

Figure C9.19.4

their scoliosis gets worse. Occasionally, families refuse to have the surgery in cognitively high-functioning children with excellent long-term functional potential in educational and occupational endeavors. Again, these families need to be apprised of the consequence of continued worsening of the scoliosis, and that later correction of the scoliosis would have to include an anterior spinal release as well. It is a family's legal right to choose not to have the spinal fusion, and physicians should make an effort to maintain a good relationship with these families. Often, as the children develop more deformity and more difficulty over time, these families will choose to have the spinal deformity corrected when the risks are higher and the correction is more difficult.

Handling Families and Children When a No Resuscitation Status Is Requested

An ethically and philosophically difficult situation may arise for families who choose to provide children only comfort care. Comfort care means families want to provide all care to make their children as comfortable and as happy as they can, but do not want treatment that will prolong their children's lives. Many medical professionals feel that a spinal fusion goes beyond comfort care; however, for families who are managing and caring for their children at home, the ability to spend long periods of time in a wheelchair is an important part of the comfort care. This spinal fusion allows families to

take their children grocery shopping or to church, etc. As these children become more scoliotic, they have to spend more of their time reclined in a lying position. It is very difficult to take near adult-sized individuals out in public in a device that looks like a rolling bed. Also, there are families who perceive that the children are very uncomfortable with the increasingly severe scoliosis and want to do something to make them more comfortable. Clearly, this is a high-risk surgical group, and two of our acute deaths have occurred in this group. This is a situation with a high philosophical and ethical dilemma. If physicians are not comfortable with this dilemma, families should be referred for other opinions. If children really are too high risk to consider, and the families talk to two or three additional surgeons who all think this way, they will likely accept these opinions, or they will continue to look for someone who is willing to help them. This ethical and philosophical problem is often hard for operative anesthesia and nursing staff, as well as intensive care unit physicians and nursing staff, to understand (Case 9.6). These professionals should also be able to decide that they are comfortable with the ethical decisions of the families, or they should be allowed to not participate in the care of these children.

When problems arise and families decide that they want no further intervention, physicians in most circumstances should not be surprised, as this issue should have been addressed with families preoperatively. It is difficult after working hard on a surgical procedure for families then to say they want everything stopped. This may be especially hard for consultants to understand who have not had the extensive family contact or experience in dealing with this population of individuals with severe disabilities as the neuroorthopaedist has.

Cervical Spine Problems

Extensor Posturing

Extensor posturing at the cervical spine is almost always associated with generalized extensor posturing, either with generalized dystonia or opisthotonic posturing. In some children, this is definitely a dystonia with major torsional elements of the head and neck. These children have no contractures, and when they are broken out of the extensor posturing and during sleep, will lie in normal positioning, often sleeping in a flexed position. The etiology of the neurologic deficit in children with relatively pure dystonia is usually a chemical insult such as glutaric aciduria acidosis affecting primarily the basal ganglia. Other children tend to remain in the extended position most of the time and develop neck and back extension contractures (Figure 9.19). In the typical spastic opisthotonic posturing, the most common etiology of the neurologic deficit tends to be from severe anoxia, such as near drowning, or severe residuals of septic meningitis, which produces severe diffuse brain injury.

Treatment of both types of extensor posturing should first focus on having a properly adjusted wheelchair with all caretakers instructed on proper seating of the children. These children should be placed in 90° of hip flexion and knee flexion with their necks in a neutral position. If contractures preclude this in spastic children, muscle release or lengthening of the hip extensors should be performed. Occasionally, lengthening of the knee extensors is required. This type of muscle lengthening is rarely needed in purely dystonic patients because they do not have muscle contractures. Botulinum toxin injection into the neck extensor muscles also provides excellent relief in spastic and dystonic children; however, these usually lead to major disappointment

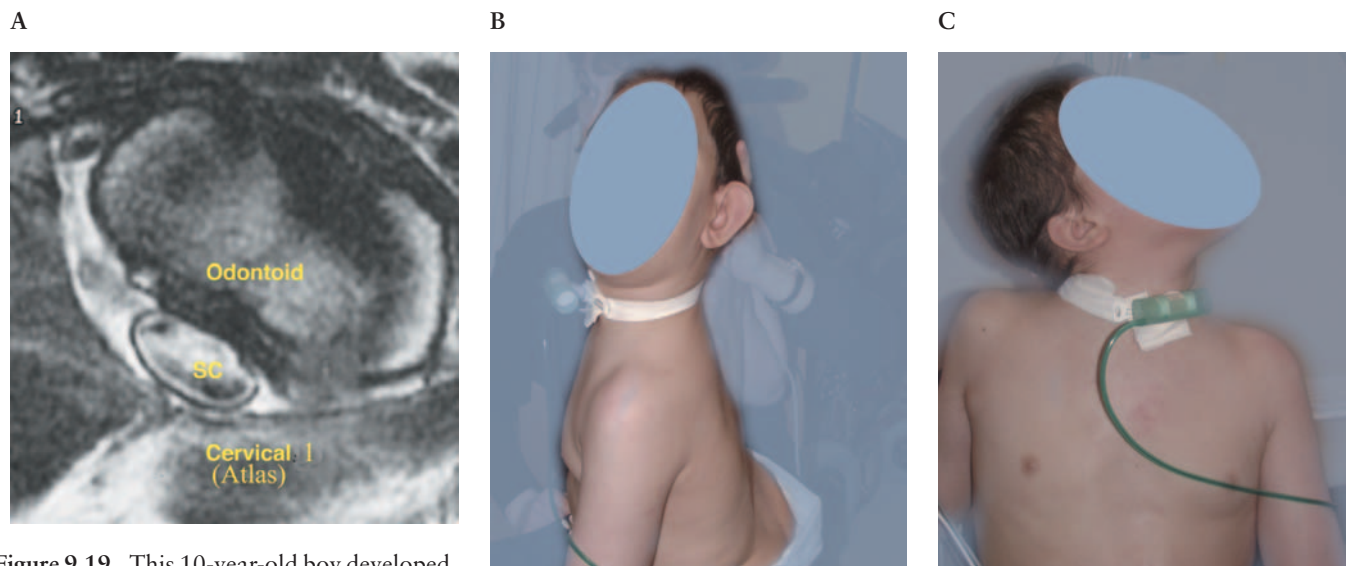


Figure 9.19. This 10-year-old boy developed severe scoliosis and increased respiratory problems. He underwent a Unit rod instrumentation and fusion. During the postoperative period, the respiratory condition did not improve, making extubation difficult. He eventually required a tracheostomy but continued with bradycardia, and an MRI of the brain, which demonstrated compression of the upper cervical spinal cord by a rotatory subluxation of C1 on C2, was performed (A). He had opisthotonic posturing for many years and as the scoliosis got worse, this too seemed to increase (B,C). We have seen three patients with a similar history, and we now work up all children with any evidence of neurologic change who also have long-term severe opisthotonic posturing.

in families. The first injection gives an excellent result, the second injection usually gives a good result, and then by the fourth injection 1 to 1.5 years later, there is no longer any benefit. The use of intrathecal baclofen has been reported to work in children with extensor posturing.⁵² In general, a very high dose is required and the catheter should be placed at least to the lower cervical spine level. The outcome of intrathecal baclofen use is not as dramatic as it is with the more generalized lower extremity spasticity. It has also been our experience that relatively pure dystonia has a better outcome than the opisthotonic spastic posturing pattern. Another treatment for children with relatively pure dystonia that has been promoted in some centers is pallidotomy.⁵³ We have no experience with pallidotomy for this patient population; however, personal communication with physicians experienced with pallidotomy report excellent results in some children and very minor benefit in others.

Occipital Subluxation, Posturing

A small group of children have a torticollis pattern of spasticity, which may be part of a scoliosis pattern or a residual of a spastic opisthotonic posturing in which the extension has diminished (see Figure 9.19). Occasionally, this posturing may lead to rotatory subluxation. The residuals of these posturing events may lead to neurologic deficits.^{54–56} We had one case in which increasing respiratory problems prompted us to do a workup that found a significant myelopathy from a compression from a rotatory subluxation at C1–C2). Children who have cervical posturing deformities and have a change in their neurologic function, or a dramatic change in their breathing, should have an MRI scan of the cervical spine to make sure that a cervical myelopathy is not causing the neurologic change. If myelopathy is demonstrated, fusion and stabilization are usually indicated (Figure 9.20). We have had one child who was found dead in bed after myelopathy was identified and surgical stabilization was recommended. If the primary complaint is respiratory difficulty, children may also be posturing to open an obstructed airway, and this may be a secondary posturing response. This posturing response may also be secondary to symptomatic gastroesophageal reflux, in which case it is usually intermittent and associated with discomfort.

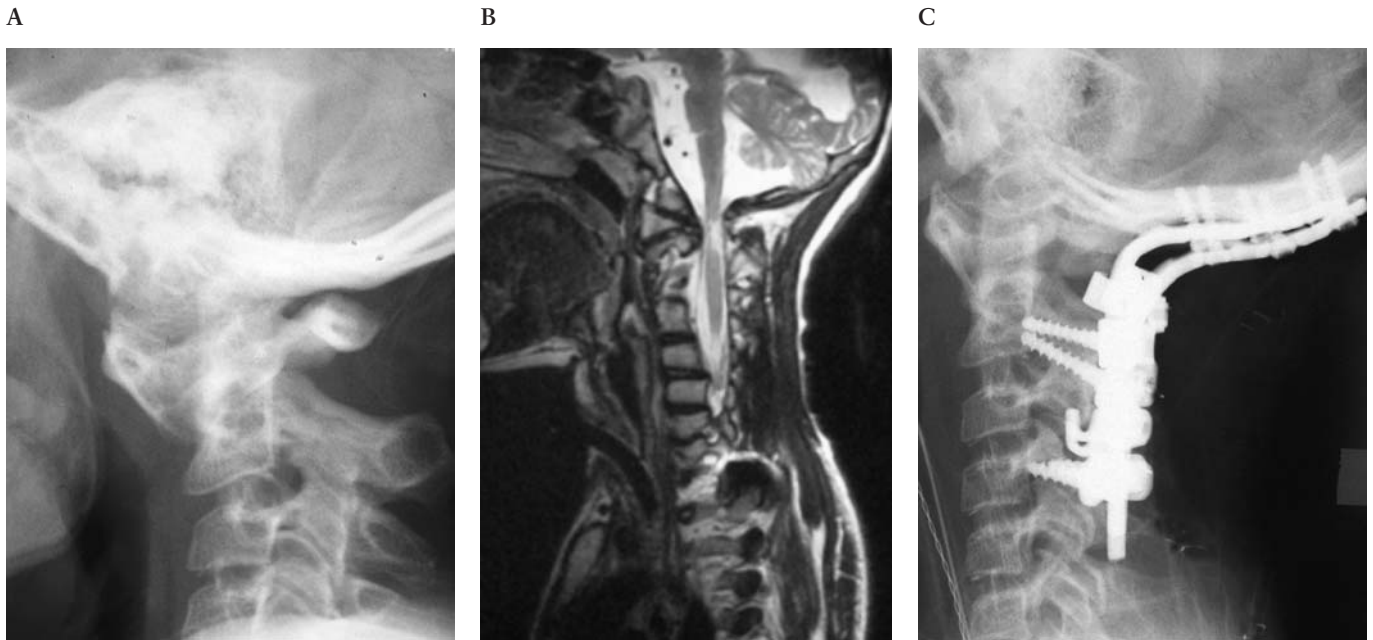


Figure 9.20. Cervical spine instability is not common in children with CP; however, it does occur. This 10-year-old boy had progressive loss of hand function, stance ability, and respiratory problems. A lateral spine radiograph showed anterior subluxation of C1 on C2 (A). This was followed up with an MRI scan that showed substantial compression of the spinal cord in the area of the instability (B). The subluxation could not be reduced; therefore, he had a posterior C1 laminectomy followed by posterior instrumentation and fusion (C). By 2 months following surgery, the required deficits had recovered.

Cervical Spine Spondylosis

Degenerative arthritis with disk degeneration and herniation are common in middle-aged and older individuals with athetoid pattern CP. Multiple reports have documented this process,^{57–62} which is due to hypermobility from the athetoid movement disorder.⁵⁴ Although acute episodes of pain often respond to conservative treatment, if neurologic deficit is present, localized decompression and fusion are often needed.^{62, 63} This problem occurs exclusively in adulthood, as we have never seen the problem in the pediatric population.

Inability to Hold Up the Head

Severe weakness due to hypotonia so that the head cannot be held upright in children with CP may be caused in part by severe thoracic kyphosis. Correction of the kyphosis usually leads to dramatic improvement in the ability to hold the head upright, or for wheelchair seating to be adjusted so the head can be held in a normal position (Figure 9.21). There are children with severe weakness, mostly children with muscular dystrophy and spinal muscular atrophy, for whom this is much more of a problem and in whom consideration of inclusion of the cervical spine in the posterior fusion is a reasonable option.

Severe Upper Thoracic Kyphosis with Lower Cervical Lordosis

Some children with severe thoracic kyphosis will make all efforts to hold their heads upright so they can see forward and as a consequence, develop significant cervical lordosis or extension contractures. Often, these individuals with thoracic kyphosis sit in wheelchairs for prolonged periods. When the thoracic kyphosis is corrected without the cervical extension contracture being recognized, the children will only be able to gaze at the ceiling when they are sitting upright (Figure 9.22). Checking the range of motion of the

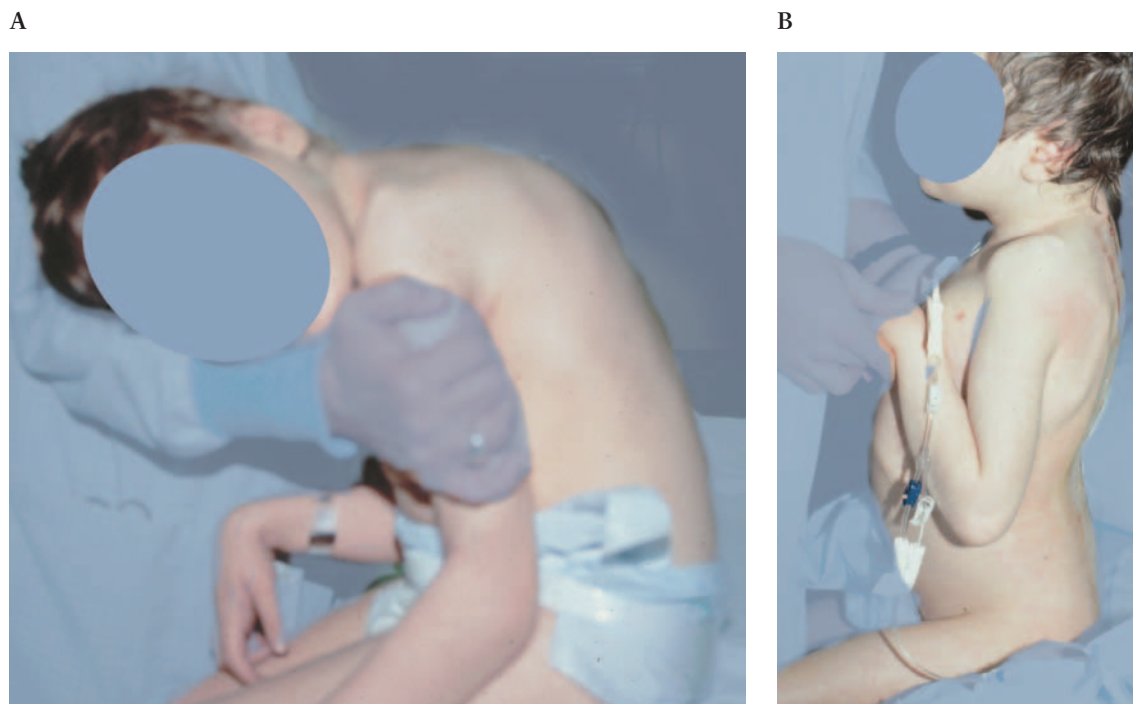


Figure 9.21. Severe kyphosis makes head control and seating very difficult. This 11-year-old boy had lost complete head control as his kyphosis became more severe (A). With correction of the kyphosis, he developed good head control in sitting as early as 1 week after the surgery (B). Correction of the kyphosis places the head in a mechanically more advantageous position, making head control easier.

cervical spine before correcting thoracic kyphosis is important. If a fixed cervical lordosis is present, soft-tissue release of the cervical extensor muscles may be indicated. Rarely, if children are unable to flex sufficiently at the cervical spine after correction of the kyphosis, a delayed paraspinal muscle lengthening and removal of the posterior nuchal ligament may be required.

Spondylolisthesis

The etiology of lumbar spondylolysis and spondylolisthesis is due to the stress of upright standing and probably is made worse with hyperlordosis. Thus, spondylolysis and spondylolisthesis are never seen in nonstanding quadriplegia⁶⁴; however, they may be more common in ambulatory diplegia, although it is not clear that the incidence is higher than in normal similar-aged individuals.⁴⁷ From our experience, spondylolysis and spondylolisthesis probably occur more frequently in athetosis, especially in individuals who are so severe that they can barely ambulate. As noted in the section on dorsal rhizotomy, there is definitely a well-defined increase in the incidence of both spondylolysis and spondylolisthesis in individuals who had multiple level lumbar laminectomies and who are ambulatory with diplegia.^{47–50}

Natural History

The natural history for most spondylolysis and spondylolisthesis is asymptomatic development and it is an incidental finding on a spine radiograph done for another reason. These children definitely follow a course similar to a lesion seen in a child without CP, and primarily remain asymptomatic. Another group of children present with low back pain of an acute nature that lasts more than several days. A workup usually defines a spondylolysis and conservative treatment provides symptomatic relief. Again, the natural history in this group is very similar to similar-aged normal individuals.

Treatment

If the discovery of the spondylolysis and spondylolisthesis is an incidental finding on a radiograph performed for unrelated reasons, such as minor trauma or abdominal radiographs, no treatment or follow-up is indicated.⁴⁷ For children who present with an acute episode of low back pain that has lasted for more than 1 week, a workup is indicated. If the children's neurologic examination is unchanged from previous examinations, then a lumbar spine radiograph, including oblique views, should be obtained. If these radiographs show a spondylolysis or spondylolisthesis, treatment with a lumbar sacral flexion orthosis is indicated. If the radiographs are normal, then a technetium bone scan should be ordered. If the spondylolysis is demonstrated on the bone scan, treatment is indicated. The primary treatment for the acute pain is fitting children with a lumbar sacral flexion orthosis (LSO), which decreases the lumbar lordosis. This orthotic usually makes children much more comfortable immediately; however, a short course of an anti-inflammatory and activity modification may also be added as indicated by symptoms. The orthosis is prescribed to be worn during all waking hours except for bathing. The LSO is used for 3 months and then gradually weaned off over a 1-month period. If the children still have pain, or the pain recurs, the orthosis is again worn for another 3-month period. In almost all children the pain resolves, and only very rarely is there any progression of the spondylolisthesis. We only monitor children whose spondylolisthesis is more than a 25% slip or who continue to have bouts of pain.

Surgical treatment is indicated only in children who have failed several courses of orthotic treatment or in whom the spondylolisthesis progresses to 50% slippage. This indication occurs only rarely, probably at a rate similar to the normal population. We have had experience with only 1 child who needed a fusion of approximately 30 children who were treated for the acute symptoms of spondylolysis or spondylolisthesis (Case 9.20). The high rate of spondylolysis and spondylolisthesis in ambulatory children with diplegia who have had dorsal rhizotomies is worrisome; however, at this time, we have only seen one child on a second opinion referral with a severe multiple level spondylolisthesis who definitely needed a posterior fusion. Because many of these children are not yet skeletally mature individuals, it is difficult to predict the significance of these lesions.

Pelvic Malalignment

Problems of the pelvis fall between the hip and spine; however, we prefer to think of the pelvis as part of the spinal segment because the only direct way of approaching pelvic malalignment is in considering the pelvis as the caudal end of the spine. This thinking allows correcting pelvic malalignments during spinal instrumentation.

Pelvic Obliquity

The definition and measurement of pelvic obliquity depends on whether children are standing or sitting. Often, pelvic obliquity has been defined based on the horizontal plane of the space in which the children are placed. This definition works well for flexible pelvic obliquity, especially in standing children in whom the radiograph is made with them standing upright, or the pelvis is measured from markers placed on the anterosuperior iliac crest during gait analysis. However, the definition does not work well for children




Figure 9.22. This 15-year-old boy with quadriplegic involvement had severe kyphosis corrected, which placed his head into much more extension (A). Because he had a fixed cervical lordosis that was not recognized preoperatively, this neck extension was now fixed and he could no longer look forward. This boy required a surgical release of the cervical lordosis followed by orthotic control (B). This case illustrates the importance of examining the mobility of the cervical spine before correcting kyphosis.



Case 9.20 Antonio



Antonio, a 12-year-old ambulatory boy with severe athetosis, complained of low back pain that was worse after he walked a long distance or at the end of the day. A physical examination showed no significant contractures except

for increased femoral anteversion, but he had some tenderness with forced extension of the lumbar spine. A radiograph demonstrated a chronic spondylolisthesis with a grade 1 to 2 slip (Figure C9.20.1). His gait pattern showed the high variability of the athetoid movement disorder. After treatment with a lumbar flexion lumbosacral orthosis for 5 months, the pain immediately returned. He then had an in situ fusion of L4 to the sacrum (Figure C9.20.2). After the fusion healed, all the pain resolved.

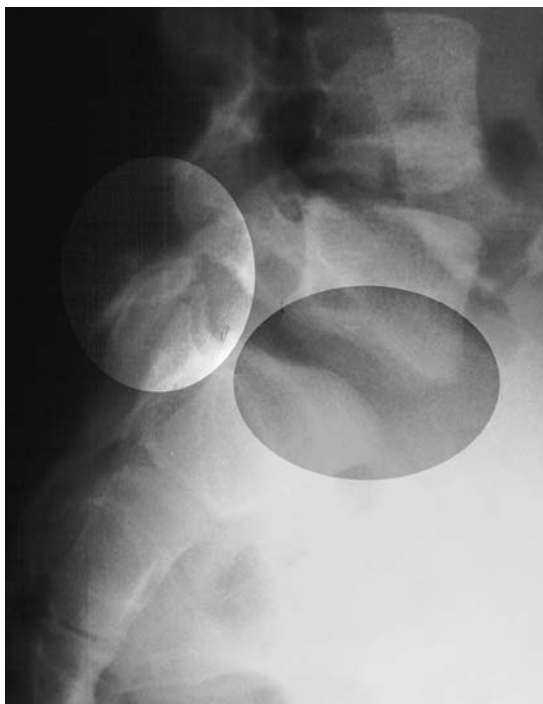

Figure C9.20.1

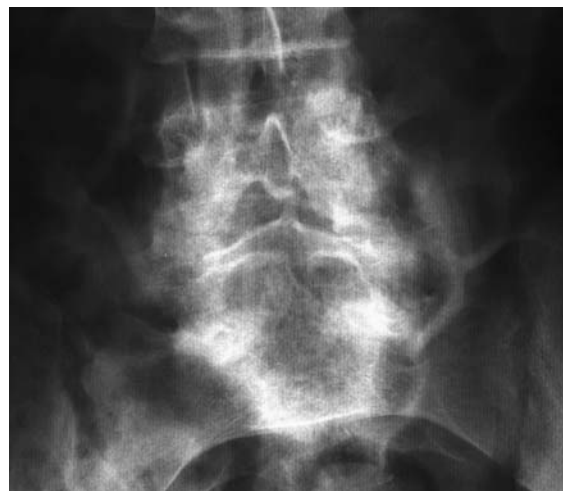

Figure C9.20.2

who are dependent sitters and have a combination of flexible and fixed pelvic obliquity. The pelvis-to-room horizontal plane may be much more reflective of how the technician seated a child for the radiograph than any real measure of pelvic obliquity as defined by the pelvis's position relative to the spine and trunk. In these children, it is better to measure the obliquity of the pelvis from a line drawn between the centers of T1 to L5 as a straight vertical line. Measuring the alteration of the pelvis from a 90° angle to this vertical line is much more representative of a true measure of children's functional pelvic obliquity (Figure 9.23).

Etiology

The cause of abnormal pelvic obliquity is divided into suprapelvic and infrapelvic etiologies. The suprapelvic pelvic obliquity is caused by an extension of the scoliosis into the pelvis.⁶⁵ The degree of flexibility of the pelvic obliquity is determined by the flexibility of the scoliosis.

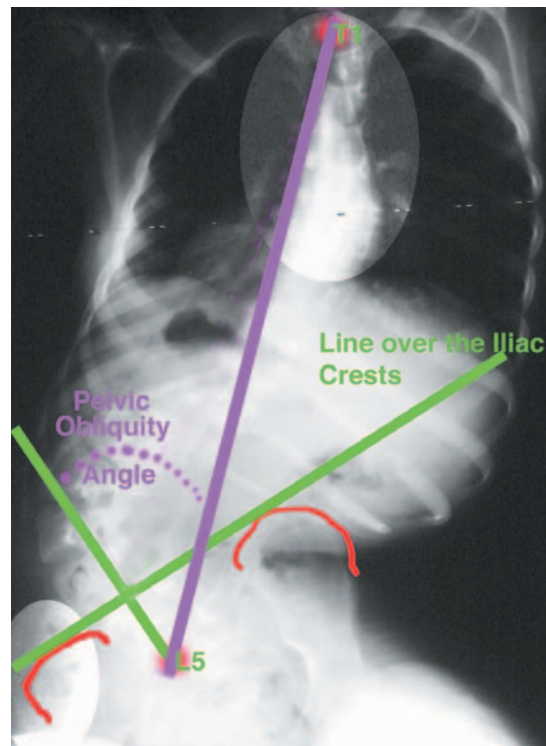


Figure 9.23. The best way to measure pelvic obliquity is by drawing a line across the iliac crest, then draw a perpendicular line at the midline of the iliac crest. Next draw a line from T1 to the crossing point pelvic lines. This measures pelvic obliquity relative to the body posture, and the goal from surgical correction should be to have this corrected to less than 5°.

Fixed infrapelvic pelvic obliquity is caused by an asymmetric contracture of the hip abductors in sitting children and in some standing children. This obliquity is a part of the windblown hip deformity discussed in more detail in the hip chapter. This fixed deformity is caused by some combination of hip joint and muscle contractures with hip adduction on one side and hip abduction on the other side. There is also a flexible pelvic obliquity seen in ambulatory children and best measured on gait analysis. This deformity may be secondary to functional or actual limb length inequality or severe asymmetric weakness of the hip abductors. It may also be combined with a mild fixed deformity secondary to contractures.

Natural History

The natural history of pelvic obliquity tends to follow the course of the primary etiology. Therefore, if the etiology of the pelvic obliquity is scoliosis that continues to become increasingly more severe, the pelvic obliquity also increases until the ilium rides inside the chest, often causing significant pain from the formation of bursitis between the ribs and the ilium. The infrapelvic pelvic obliquity tends to follow the contractures, which often stabilize after growth is completed. The flexible deformity follows its specific etiology completely.

Treatment

Treatment of pelvic obliquity is based on diagnosing the specific cause of the deformity. If the cause is a suprapelvic pelvic obliquity from scoliosis, then correcting the scoliosis is required. If the primary cause is infrapelvic, correcting the fixed deformities is required. If the cause is limb length inequality, the exact reason for the limb length inequality needs to be determined and then addressed. If the problem is muscle weakness or hip joint instability, these have to be evaluated as the possible treatments. If a definite primary source

can be identified, the treatment is usually very clear cut. However, there are often two causes that are both causative and often additive. A frequent combination is children who have a suprapelvic cause from scoliosis and an infrapelvic cause from a windblown hip with spastic hip disease. In these situations, carefully assessing the stiffness of the spine is important, as some younger children will have a suprapelvic aspect only as a secondary adaptive deformity for what is primarily an infrapelvic etiology. If the spinal deformity is very flexible, then the hip should be considered the primary etiology and should be addressed first with the goal of waiting several years to correct the spine, allowing further growth (Case 9.21). If this assessment is correct, the scoliosis will partially correct after the hips have been corrected, and children will do well in the short term. However, if this judgment was in error, then the pelvis will stay very oblique and there will be problems seating children that require the scoliosis to be corrected in the short term, usually in 4 to 6 months after the hip surgery.

If the evaluation determines that the hip and spine are equally involved, or the spine is the primary etiology, then the spine should be corrected first with the hips corrected 4 to 6 months later. Earlier hip surgery increases the risk of severe heterotopic ossification. By correcting the suprapelvic cause of the pelvic obliquity, the pelvis becomes a stable base in which the hip surgery will be accomplished more easily and more successfully.

Seating Adjustment

The outcome of pelvic obliquity treatment should be an 80% to 90% correction of all pelvic obliquity, and as a consequence, there should never be a need to make seating accommodations for pelvic obliquity after treatment. Children who have uncorrected pelvic obliquity only rarely have problems with skin breakdown because of their normal sensation. They do, however, develop discomfort in seating. The best seating adaptations are the use of closed-cell foams, in which the seat is partially built up to accommodate the pelvic obliquity. If an attempt is made to completely accommodate children with some flexibility, the pelvic obliquity will often just get worse, which is not the goal of the seating adaptations.

Anterior Pelvic Tilt

Increased anterior pelvic tilt is common in children with CP and is present in both ambulatory and nonambulatory individuals. Measurements using radiographs and measuring the sacrofemoral angle, which measures the angle between the L5 and S1 disk and the femur, are seldom used. The most common measurement of anterior pelvic tilt is from gait analysis. This measurement uses the angle formed by the anterosuperior iliac crest to the posterosuperior iliac crest relative to room horizontal plane.

Etiology

Just as with pelvic obliquity, there are suprapelvic and infrapelvic causes of the abnormal pelvic tilt. The most common cause of increased anterior pelvic tilt is fixed increase in lumbar lordosis. Another suprapelvic cause is severe abdominal muscle weakness, which is less common in children with CP than in some other neurologic diseases. Fixed posterior pelvic tilt is rare in children with CP; however, it may be due to decreased lumbar lordosis or lumbar kyphosis that is fixed (Case 9.22).

The infrapelvic cause of fixed increased anterior pelvic tilt is hip flexion contracture, and the flexible increased anterior pelvic tilt may result from either spastic hip flexors or weakness of the hip extensors. The infrapelvic

cause of the posterior pelvic tilt is primarily contracted hip extensors or, in the worst case scenario, the type 1 anterior hip dislocation. Flexible posterior pelvic tilt is most commonly due to spastic and contracted hamstrings, causing the posterior pelvic tilt in seating.

Natural History

The natural history very much follows the specific cause. If the cause worsens, so does the anterior pelvic tilt, which may get very severe to the point of causing pain at the place where the anterosuperior iliac spine is in contact with the anterior thigh. In an insensate child this may cause a decubitus ulcer, although, in sensate children with CP, pain develops so that they will not tolerate sitting. In most severe cases of posterior pelvic tilt, adaptive compensatory thoracolumbar kyphosis may develop and become a fixed deformity in itself.



Case 9.21 Clarissa

Clarissa, an 8-year-old girl with severe spastic quadriplegia, presented for a second opinion concerning her progressive scoliosis. Her parents were most concerned about her increasing problems with sitting, which they perceived came primarily from her scoliosis. She had been prescribed a spinal orthosis to help with sitting and control her scoliosis. She was fed orally and was small for her age but appeared well nourished. She was taking tegretol for seizure control and had not had a seizure for 6 months. She was a dependent sitter and had minimal function in her hands. On physical examination she was noted to be diffusely spastic with mild shoulder contractures. The spine had a flexible scoliosis and the hips were limited to 10° of abduction on the left side and 50° of abduction with some limited adduction on the right side. The knees had a popliteal angle of 60° bilaterally, and the feet were controlled with solid ankle-foot orthotics with minimal fixed deformity. Observation of her sitting demonstrated rather poorly adjusted chest laterals, as she was hanging over the lateral on the right side. A radiograph of the spine demonstrated 48° of scoliosis (Figure C9.21.1), and the right hip was dislocated and the left hip appeared to be abducted in the classic windblown deformity (Figure C9.21.2). Based on this assessment, it was concluded that she had a primary infrapelvic pelvic obliquity due to the spastic hip disease. It was recommended to her parents that she have a repair of the hips by bilateral femoral shortening derotation, varus osteotomy, adductor muscle lengthening, and peri-ilial pelvic osteotomy (Figure C9.21.3). Following this procedure, she could sit much better until age 12 years when her sitting again deteriorated.

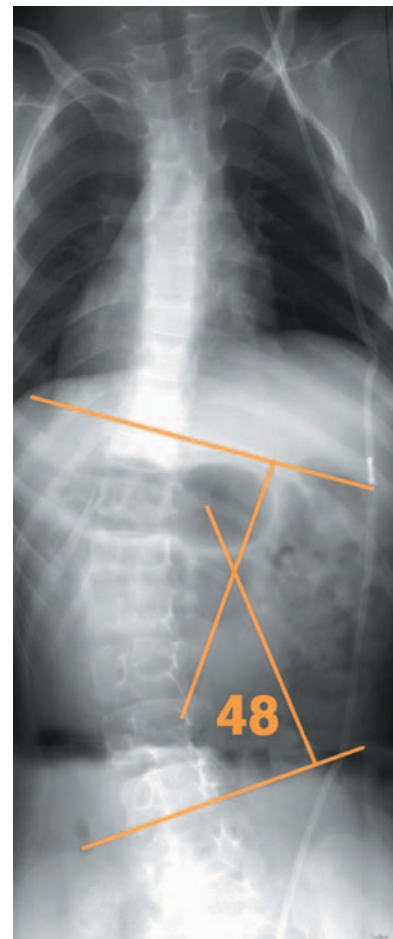

Figure C9.21.1

rated, and the pelvic obliquity now was caused by supra-pelvic pelvic obliquity coming from a progressive 74° scoliosis (Figures C9.21.4, C9.21.5). This was corrected with a Unit rod instrumentation and she was again comfortable as a sitter (Figure C9.21.6). This case demon-

strates the importance of making the correct diagnosis of the pelvic obliquity, because correcting the spine will not help treat the symptoms of infrapelvic pelvic obliquity and vice versa. When in doubt, the spine should be corrected first if there is a significant scoliosis.

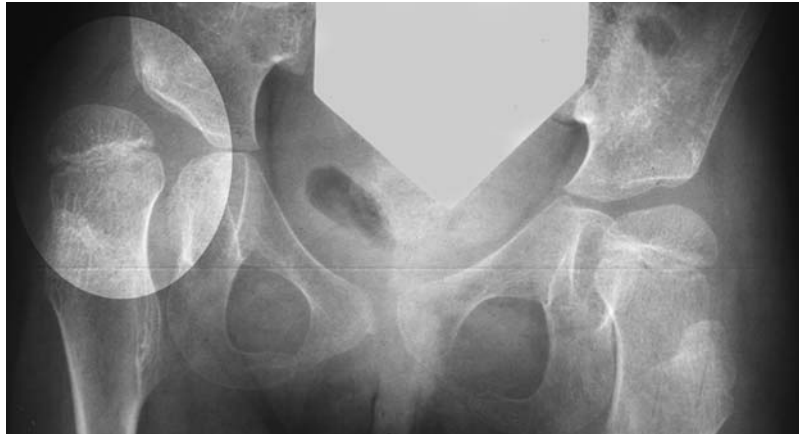

Figure C9.21.2

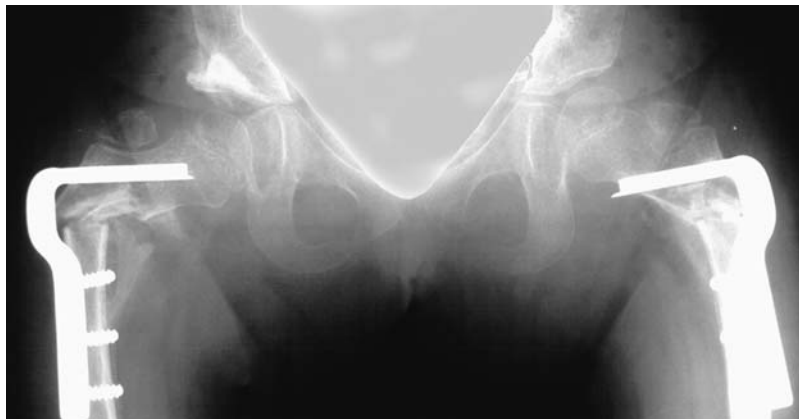

Figure C9.21.3

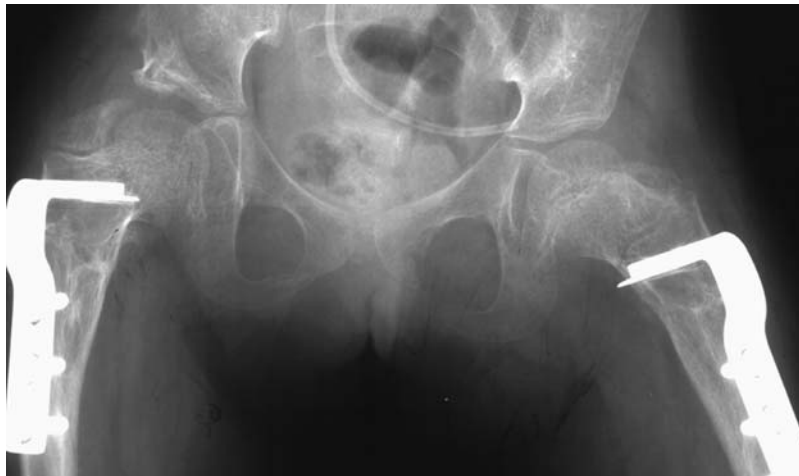

Figure C9.21.4

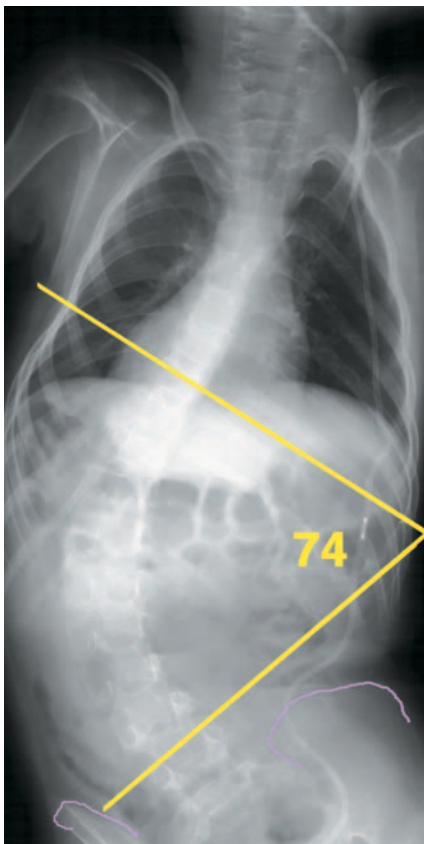


Figure C9.21.5

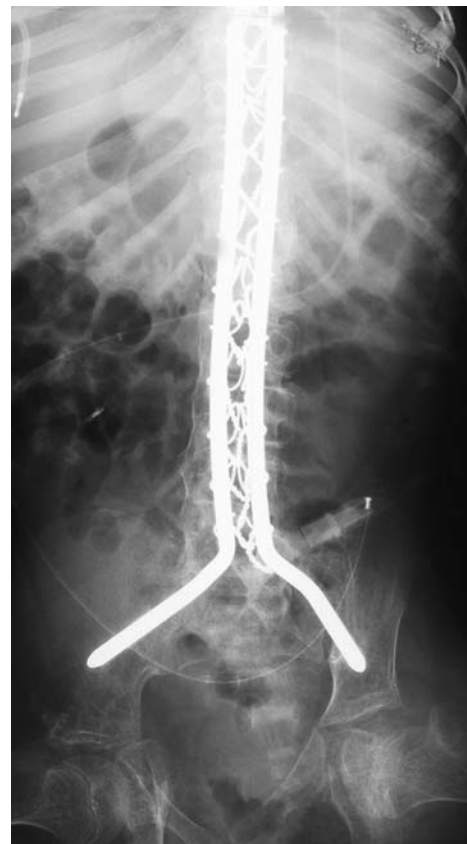

Figure C9.21.6

Treatment

The treatment of abnormal pelvic tilt requires a clear definition of the exact etiology. If the cause is a suprapelvic anterior pelvic tilt caused by increased lumbar lordosis, the lordosis may need to be corrected if the goal is to improve the anterior pelvic tilt. If the problem is an infrapelvic cause, the specific etiology should also be corrected. A very common cause of posterior pelvic tilt in sitting in childhood is the spastic or contracted hamstring. These spastic, contracted hamstrings respond very well to lengthening or to seating children with increased knee flexion, which inactivates the hamstring.

Pelvis Rotational Malalignment

Rotational malalignment relative to the rest of the trunk occurs in two situations. It occurs secondary to the scoliosis in which the pelvis rotates anteriorly on the elevated side in sitting. Pelvic rotation also has an infrapelvic cause due to asymmetric hip rotation in which the hip that is internally rotated causes the ipsilateral side of the pelvis to rotate posteriorly. These malrotations are not often noticed by families or children as primary problems, but in the suprapelvic cause, they usually complain of the child sitting with a long leg on the side that is rotated forward. For children who walk and have an infrapelvic rotational problem, complaints tend to be directed more at intoeing. Treatment for the suprapelvic cause is by correction of the scoliosis, whereas correction of the infrapelvic cause requires gait analysis and often femoral derotation.



Case 9.22 Sherrill

Sherrill, a 13-year-old girl with severe spastic quadriplegia, limited upper extremity function, and normal cognitive function, presented with a complaint of severe back pain from sitting. Further history demonstrated that for many years she had increased lumbar lordosis during sitting, which the physical therapist thought was due to hip flexion contractures. Over the past year, she had grown rapidly and the lordosis had increased significantly. In the past 3 months, there had been a significant increase in her back pain, especially related to sitting time. There had been no change in her bowel or bladder control. On physical examination she had a fixed lumbar lordosis with hip

flexion contractures, and the Thomas test was positive at -30° . A radiograph demonstrated lumbar lordosis of 105° with significant thoracic kyphosis (Figure C9.22.1). Following an anterior wedge excision of disks from T12 to L4, posterior spinal fusion was performed with the Unit rod (Figure C9.22.2). Sitting balance and comfort increased greatly, although she complained of neuritic type pain in her legs postoperatively. This was treated with electrical stimulation, antiinflammatories, and antidepressant medications with slow resolution. By 1 year after the surgery, the neuritic pains had resolved and she remained comfortable.

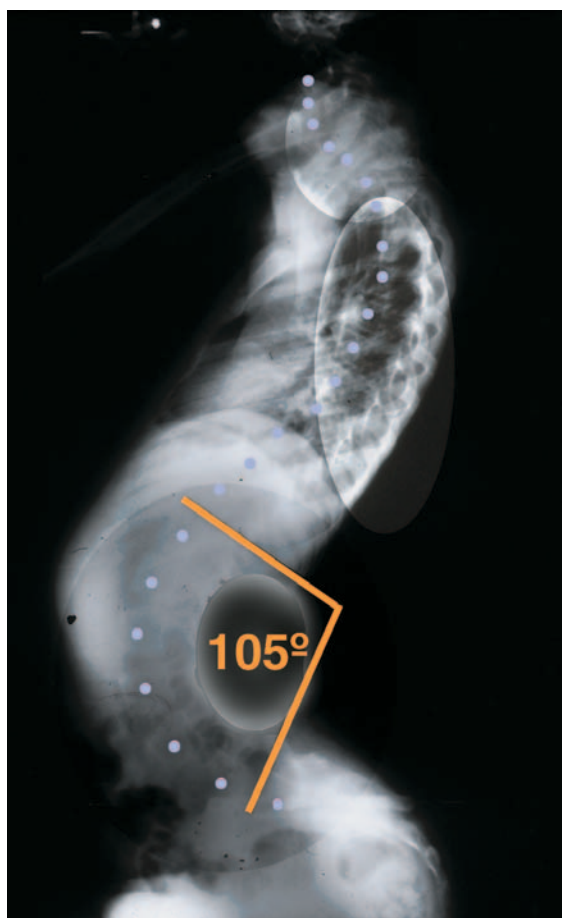
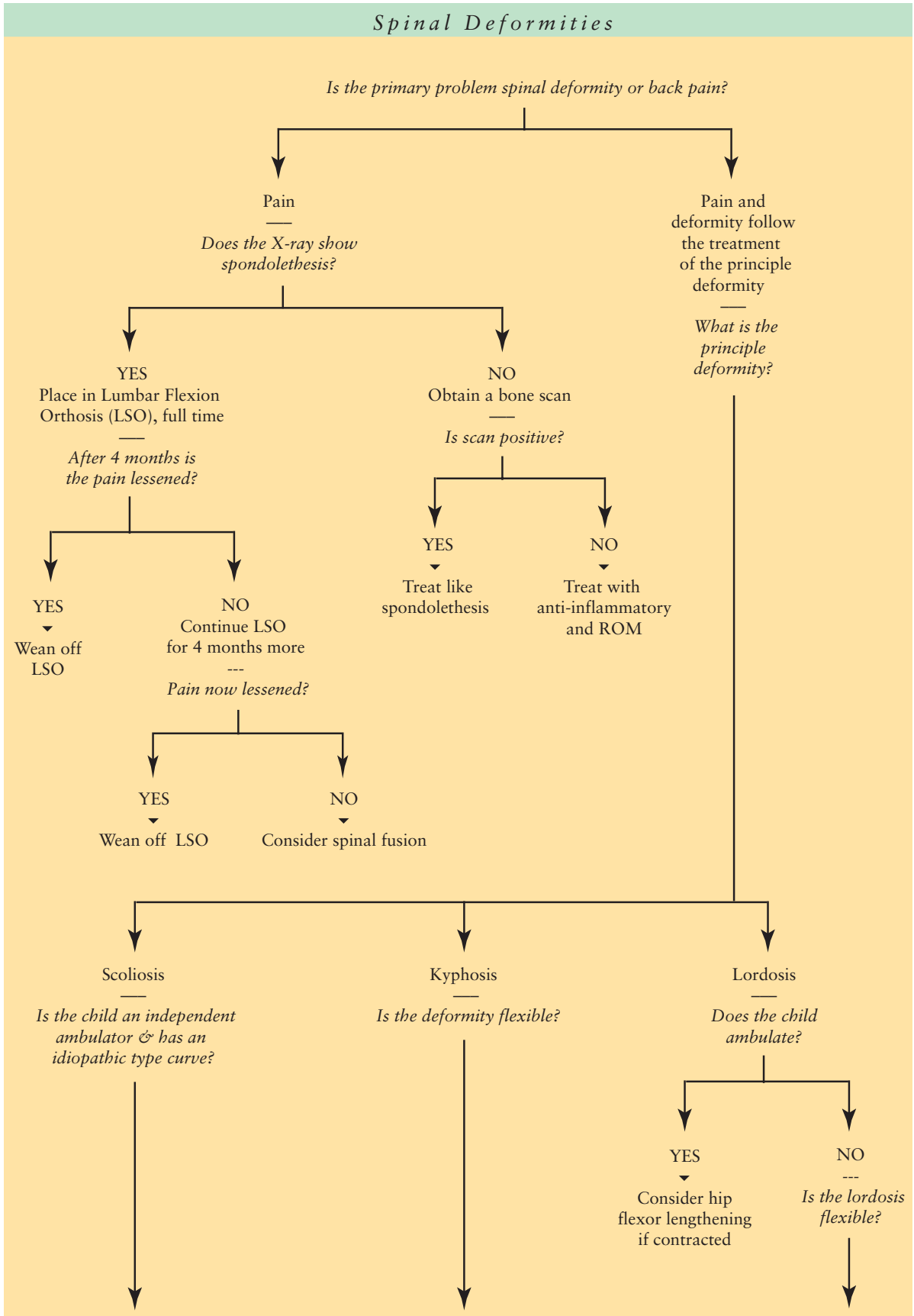
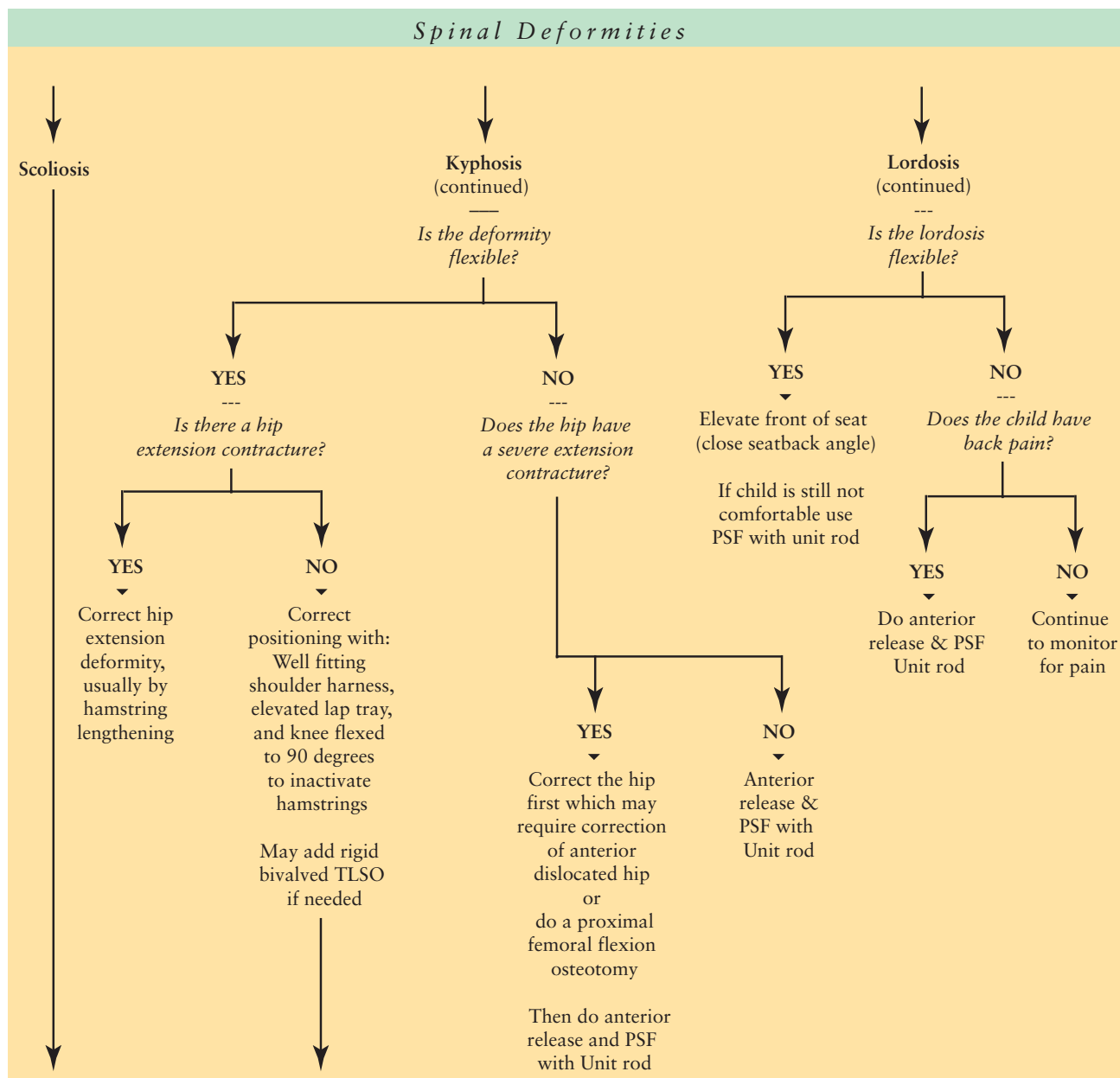


Figure C9.22.1

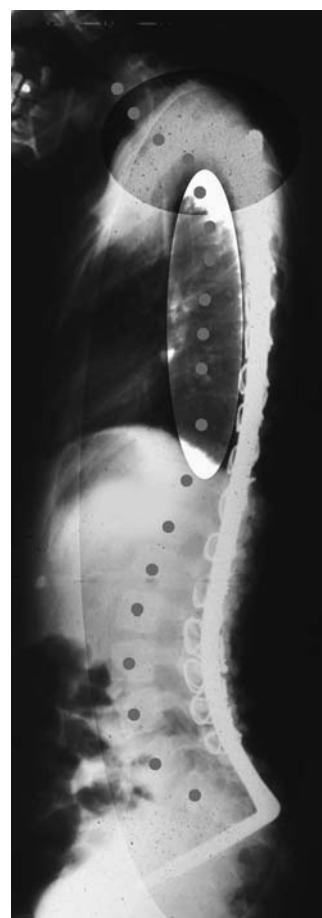

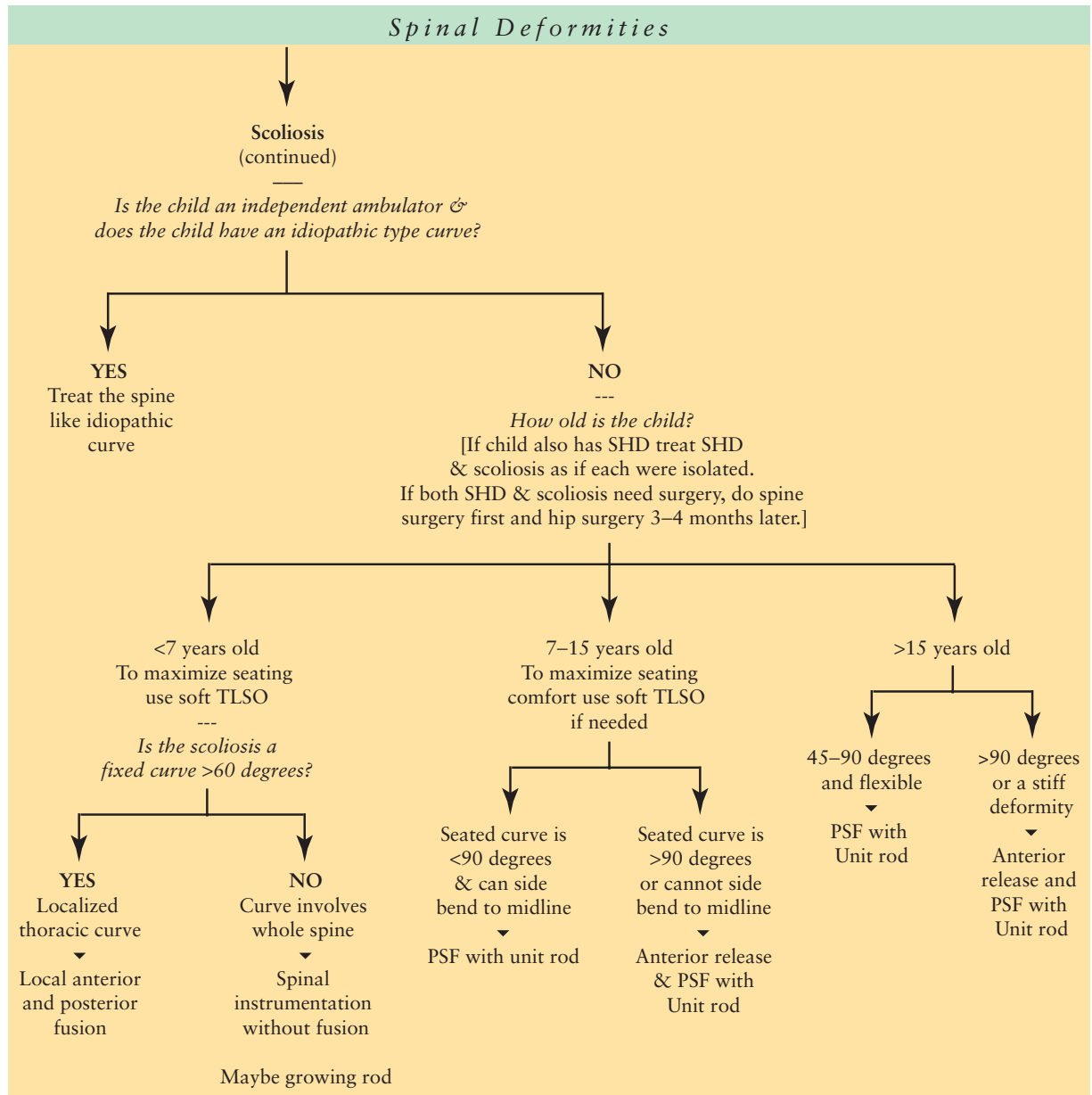
Figure C9.22.2





References

1. Edebol-Tysk K. Epidemiology of spastic tetraplegic cerebral palsy in Sweden. I. Impairments and disabilities. *Neuropediatrics* 1989;20:41–5.
2. Madigan RR, Wallace SL. Scoliosis in the institutionalized cerebral palsy population. *Spine* 1981;6:583–90.
3. Miller A, Temple T, Miller F. Impact of orthoses on the rate of scoliosis progression in children with cerebral palsy [see comments]. *J Pediatr Orthop* 1996;16:332–5.
4. Saito N, Ebara S, Ohotsuka K, Kumeta H, Takaoka K. Natural history of scoliosis in spastic cerebral palsy. *Lancet* 1998;351:1687–92.
5. Majd ME, Muldowny DS, Holt RT. Natural history of scoliosis in the institutionalized adult cerebral palsy population. *Spine* 1997;22:1461–6.



6. Bohmer CJ, Klinkenberg-Knol EC, Niezen-de Boer MC, Meuwissen SG. Gastroesophageal reflux disease in intellectually disabled individuals: how often, how serious, how manageable? *Am J Gastroenterol* 2000;95:1868–72.
7. Bunnell WP, MacEwen GD. Non-operative treatment of scoliosis in cerebral palsy: preliminary report on the use of a plastic jacket. *Dev Med Child Neurol* 1977;19:45–9.
8. Terjesen T, Lange JE, Steen H. Treatment of scoliosis with spinal bracing in quadriplegic cerebral palsy. *Dev Med Child Neurol* 2000;42:448–54.
9. Leopando MT, Moussavi Z, Holbrow J, Chernick V, Pasterkamp H, Rempel G. Effect of a Soft Boston Orthosis on pulmonary mechanics in severe cerebral palsy. *Pediatr Pulmonol* 1999;28:53–8.
10. Bonnett C, Brown JC, Grow T. Thoracolumbar scoliosis in cerebral palsy. Results of surgical treatment. *J Bone Joint Surg [Am]* 1976;58:328–36.

11. Brown JC, Swank S, Specht L. Combined anterior and posterior spine fusion in cerebral palsy. *Spine* 1982;7:570-3.
12. Comstock CP, Leach J, Wenger DR. Scoliosis in total-body-involvement cerebral palsy. Analysis of surgical treatment and patient and caregiver satisfaction. *Spine* 1998;23:1412-24;discussion 1424-5.
13. Sussman MD, Little D, Alley RM, McCoig JA. Posterior instrumentation and fusion of the thoracolumbar spine for treatment of neuromuscular scoliosis. *J Pediatr Orthop* 1996;16:304-13.
14. Gau YL, Lonstein JE, Winter RB, Koop S, Denis F. Luque-Galveston procedure for correction and stabilization of neuromuscular scoliosis and pelvic obliquity: a review of 68 patients. *J Spinal Disord* 1991;4:399-410.
15. Ferguson RL, Allen BL Jr. Considerations in the treatment of cerebral palsy patients with spinal deformities. *Orthop Clin North Am* 1988;19:419-25.
16. Boachie-Adjei O, Lonstein JE, Winter RB, Koop S, vanden Brink K, Denis F. Management of neuromuscular spinal deformities with Luque segmental instrumentation. *J Bone Joint Surg [Am]* 1989;71:548-62.
17. Jevsevar DS, Karlin LI. The relationship between preoperative nutritional status and complications after an operation for scoliosis in patients who have cerebral palsy [published erratum appears in *J Bone Joint Surg Am* 1993;75(8):1256]. *J Bone Joint Surg Am* 1993;75:880-4.
18. Lipton GE, Miller F, Dabney KW, Altiok H, Bachrach SJ. Factors predicting post-operative complications following spinal fusions in children with cerebral palsy. *J Spinal Disord* 1999;12:197-205.
19. Bell DF, Moseley CF, Koreska J. Unit rod segmental spinal instrumentation in the management of patients with progressive neuromuscular spinal deformity. *Spine* 1989;14:1301-7.
20. Montgomery DM, Aronson DD, Lee CL, LaMont RL. Posterior spinal fusion: allograft versus autograft bone. *J Spinal Disord* 1990;3:370-5.
21. Swank SM, Cohen DS, Brown JC. Spine fusion in cerebral palsy with L-rod segmental spinal instrumentation. A comparison of single and two-stage combined approach with Zielke instrumentation. *Spine* 1989;14:750-9.
22. Smucker JD, Miller F. Crankshaft effect after posterior spinal fusion and unit rod instrumentation in children with cerebral palsy. *J Pediatr Orthop* 2001;21:108-12.
23. Yazici M, Asher MA, Hardacker JW. The safety and efficacy of Isola-Galveston instrumentation and arthrodesis in the treatment of neuromuscular spinal deformities. *J Bone Joint Surg [Am]* 2000;82:524-43.
24. Bulman WA, Dormans JP, Ecker ML, Drummond DS. Posterior spinal fusion for scoliosis in patients with cerebral palsy: a comparison of Luque rod and Unit Rod instrumentation. *J Pediatr Orthop* 1996;16:314-23.
25. Dias RC, Miller F, Dabney K, Lipton G, Temple T. Surgical correction of spinal deformity using a unit rod in children with cerebral palsy. *J Pediatr Orthop* 1996;16:734-40.
26. Rinsky LA. Surgery of spinal deformity in cerebral palsy. Twelve years in the evolution of scoliosis management. *Clin Orthop* 1990;100-9.
27. Smith RM, Emans JB. Sitting balance in spinal deformity. *Spine* 1992;17:1103-9.
28. Cassidy C, Craig CL, Perry A, Karlin LI, Goldberg MJ. A reassessment of spinal stabilization in severe cerebral palsy. *J Pediatr Orthop* 1994;14:731-9.
29. Levine DS, Dugas JR, Tarantino SJ, Boachie-Adjei O. Chance fracture after pedicle screw fixation. A case report. *Spine* 1998;23:382-5; discussion 386.
30. Harada T, Ebara S, Anwar MM, et al. The lumbar spine in spastic diplegia. A radiographic study. *J Bone Joint Surg [Br]* 1993;75:534-7.
31. Onimus M, Manzone P, Lornet JM, Laurain JM. Surgical treatment of scoliosis in bed-ridden patients with cerebral palsy. *Rev Chir Orthop Reparatrice Appar Mot* 1992;78:312-8.
32. Krismer M, Bauer R. The Luque-Galveston operation in the treatment of neuropathic pelvic tilt. *Orthopade* 1990;19:309-14.
33. M'Rabet A, Dubousset J. Treatment of spinal deformities in patients with cerebral palsy. *Rev Chir Orthop Reparatrice Appar Mot* 1988;74:647-58.

34. Theroux MC, Corddry DH, Tietz AE, Miller F, Peoples JD, Ketrwick RG. A study of desmopressin and blood loss during spinal fusion for neuromuscular scoliosis: a randomized, controlled, double-blinded study. *Anesthesiology* 1997;87:260-7.
35. Givon U, Miller F. Shortening of a unit rod protruding into the hip joint: case report and description of a surgical technique. *J Spinal Disord* 1999;12:74-6.
36. Lubicky JP, Spadaro JA, Yuan HA, Fredrickson BE, Henderson N. Variability of somatosensory cortical evoked potential monitoring during spinal surgery. *Spine* 1989;14:790-8.
37. Ecker ML, Dormans JP, Schwartz DM, Drummond DS, Bulman WA. Efficacy of spinal cord monitoring in scoliosis surgery in patients with cerebral palsy. *J Spinal Disord* 1996;9:159-64.
38. de Gauzy JS, Roux FE, Henry P, Cahuzac JP. Somatosensory evoked potentials during surgery of scoliosis: significance of epidural recording. *Rev Chir Orthop Reparatrice Appar Mot* 1999;85:387-92.
39. Bohmer CJ, Niezen-de Boer MC, Klinkenberg-Knol EC, Deville WL, Nadorp JH, Meuwissen SG. The prevalence of gastroesophageal reflux disease in institutionalized intellectually disabled individuals. *Am J Gastroenterol* 1999;94:804-10.
40. Leichtner AM, Banta JV, Etienne N, et al. Pancreatitis following scoliosis surgery in children and young adults. *J Pediatr Orthop* 1991;11:594-8.
41. Shapiro G, Green DW, Fatica NS, Boachie-Adjei O. Medical complications in scoliosis surgery. *Curr Opin Pediatr* 2001;13:36-41.
42. Del Beccaro MA, McLaughlin JF, Polage DL. Severe gastric distension in seven patients with cerebral palsy. *Dev Med Child Neurol* 1991;33:912-6.
43. Szoke G, Lipton G, Miller F, Dabney K. Wound infection after spinal fusion in children with cerebral palsy. *J Pediatr Orthop* 1998;18:727-33.
44. Sponseller PD, LaPorte DM, Hungerford MW, Eck K, Bridwell KH, Lenke LG. Deep wound infections after neuromuscular scoliosis surgery: a multicenter study of risk factors and treatment outcomes. *Spine* 2000;25:2461-2466.
45. Dias RC, Miller F, Dabney K, Lipton GE. Revision spine surgery in children with cerebral palsy. *J Spinal Disord* 1997;10:132-44.
46. Turi M, Kalen V. The risk of spinal deformity after selective dorsal rhizotomy. *J Pediatr Orthop* 2000;20:104-7.
47. Hennrikus WL, Rosenthal RK, Kasser JR. Incidence of spondylolisthesis in ambulatory cerebral palsy patients. *J Pediatr Orthop* 1993;13:37-40.
48. Peter JC, Arens LJ. Selective posterior lumbosacral rhizotomy for the management of cerebral palsy spasticity. A 10-year experience. *S Afr Med J* 1993;83:745-7.
49. Peter JC, Hoffman EB, Arens LJ. Spondylolysis and spondylolisthesis after five-level lumbosacral laminectomy for selective posterior rhizotomy in cerebral palsy. *Childs Nerv Syst* 1993;9:285-7; discussion 287-8.
50. Peter JC, Hoffman EB, Arens LJ, Peacock WJ. Incidence of spinal deformity in children after multiple level laminectomy for selective posterior rhizotomy. *Childs Nerv Syst* 1990;6:30-2.
51. Miller F, Moseley CF, Koreska J. Spinal fusion in Duchenne muscular dystrophy. *Dev Med Child Neurol* 1992;34:775-86.
52. Albright AL, Barry MJ, Painter MJ, Shultz B. Infusion of intrathecal baclofen for generalized dystonia in cerebral palsy. *J Neurosurg* 1998;88:73-6.
53. Lin JJ, Lin GY, Shih C, Lin SZ, Chang DC, Lee CC. Benefit of bilateral pallidotomy in the treatment of generalized dystonia. Case report. *J Neurosurg* 1999;90:974-6.
54. Amess P, Chong WK, Kirkham FJ. Acquired spinal cord lesion associated with os odontoideum causing deterioration in dystonic cerebral palsy: case report and review of the literature. *Dev Med Child Neurol* 1998;40:195-8.
55. Haslam RHA. 'Progressive cerebral palsy' or spinal cord tumor? Two cases of mistaken identity. *Dev Med Child Neurol* 1975;17:232-7.
56. Thompson GH, Likavec MJ, Archibald I, Rush T. Atlantoaxial rotatory subluxation, congenital absence of the posterior arch of the atlas, and cerebral palsy: an unusual triad. *J Pediatr Orthop* 1985;5:232-5.
57. el-Mallakh RS, Rao K, Barwick M. Cervical myelopathy secondary to movement disorders: case report. *Neurosurgery* 1989;24:902-5.

58. Epstein NE. Circumferential cervical surgery for spondylostenosis with kyphosis in two patients with athetoid cerebral palsy. *Surg Neurol* 1999;52:339–44.
59. Hanakita J, Suwa H, Nagayasu S, Nishi S, Ohta F, Sakaida H. Surgical treatment of cervical spondylotic radiculomyelopathy with abnormal involuntary neck movements. Report of three cases. *Neurol Med Chir (Tokyo)* 1989;29:1132–6.
60. Harada T, Ebara S, Anwar MM, et al. The cervical spine in athetoid cerebral palsy. A radiological study of 180 patients. *J Bone Joint Surg Br* 1996;78:613–9.
61. Hojo M, Nakahara I, Tanaka M, Oda Y, Kikuchi H. Surgical treatment of atlantoaxial dislocation in a patient of athetoid cerebral palsy. *No Shinkei Geka* 1994;22:887–91.
62. Racette BA, Lauryssen C, Perlmutter JS. Preoperative treatment with botulinum toxin to facilitate cervical fusion in dystonic cerebral palsy. Report of two cases. *J Neurosurg* 1998;88:328–30.
63. Nishihara N, Tanabe G, Nakahara S, Imai T, Murakawa H. Surgical treatment of cervical spondylotic myelopathy complicating athetoid cerebral palsy. *J Bone Joint Surg [Br]* 1984;66:504–8.
64. Rosenberg NJ, Bargar WL, Friedman B. The incidence of spondylolysis and spondylolisthesis in nonambulatory patients. *Spine* 1981;6:35–8.
65. Letts M, Shapiro L, Mulder K, Klassen O. The windblown hip syndrome in total body cerebral palsy. *J Pediatr Orthop* 1984;4:55–62.

Hip

The hip joint is the largest joint in the body and is the joint that causes the most problems both from a functional perspective and at the level of walking, sitting, and lying in children with cerebral palsy (CP). Hips in children with CP are normal at birth, and the problems develop slowly as the children grow and deform under the influence of abnormal forces caused by the CP. A second group of children with CP do not actually develop deformity; however, the infantile shape of their proximal femur does not resolve because there is not enough normal force present. In summary, these children develop contractures and increased abnormal forces that lead to dislocation and dysplasia, or alternatively, they fail to resolve the infantile torsional malalignment. After addressing the concerns of equinus contractures in children with CP, hip problems are the next main area of interest to orthopaedists treating these children. The treatment of hip problems has the largest literature base in the area of orthopaedic management of CP. A review of the abstract listings in the National Library of Medicine revealed 496 references published from 1963 to 2000 that address hip problems in children with CP. Although the literature is extensive, much of it does not include any standardized control or standardized radiographic measurements and has a poor description of specific patterns. A substantial body of this literature addresses the natural history of the problem of hip dysplasia, and its etiology has been fairly well understood. The evaluation of treatment outcomes suffers especially from poor categorization, poor standard evaluation procedures, and, most of all, very poor long-term follow-ups.

Spastic Hips

Hip problems in children with CP first need to be divided by children's level of tone into either spastic children or those children who are hypotonic. The spastic (hypertonic) group should also include children with movement disorders such as athetosis and dystonia. The hypertonic hips can be subdivided further by the direction of the dysplasia or the abnormal force into postero-superior, anterior, inferior and, additionally, by several contracture patterns that may be independent of or concurrent with dysplastic hips. These contracture patterns include windblown hips and hyperabducted hips. The hypotonic hips in children with CP are a little more diffuse and are harder to further categorize.

Posterosuperior Hip Subluxation

The most common dysplastic hip problems in children with hypertonia or spasticity are posterosuperior hip subluxation, dislocation, or dysplasia.¹ These problems comprise the typical spastic hip dysplasia (SHD), which is discussed in most of the literature. Based on an extensive review by Cooke,¹ in which attention was paid to the specific pattern of dislocation, 98% to 99% of spastic children with hip subluxation or dislocation have this typical posterosuperior pattern.

Etiology

The etiology of spastic hip disease has been worked out fairly clearly both through clinical review and, more importantly, through modeling.^{2, 3} The concept of an abnormal force caused by adductor muscles was first suggested in a paper by Keats in 1963⁴ and was the basis upon which he advocated doing adductor lengthening to prevent the spastic hip at risk from dislocating. Since that time, there have been many other clinical studies in which different primary etiologies for spastic hip disease were presented. These etiologies include femoral neck valgus as a primary cause,⁵⁻⁹ and in one study, the femoral valgus was believed to be the direct cause of the dislocation, but the adductor spasticity and weak gluteus medius were believed to cause the valgus.¹⁰ Femoral anteversion has also been indicated as a primary or contributing cause by numerous authors.⁵⁻⁹ Various muscle contractures and spasticity have been felt to be either contributing or primary causes, with the adductor muscles being mentioned in 59 different articles as the primary cause of spastic hip dislocation. Other muscles that have been indicted in the literature are the iliopsoas¹¹⁻¹³ and hamstrings.¹²⁻¹⁵ Another common perception of the cause of hip subluxation is acetabular dysplasia, or malrotation, listed in 12 separate references. Femoral head deformity has been noted as an etiology in the dislocation as well. Based on this literature, the general consensus is that the adductor muscles are the primary etiology in the cause of spastic hip subluxation.

The most important clinical evaluation of the etiology of spastic hip subluxation was performed by Reimers and published in 1980.¹⁶ In this study, he evaluated many different types of muscle surgery and concluded that the primary etiology of hip subluxation was abnormal force created by the adductor muscles. This primary etiology was followed by the influence of the hamstrings, and last, by the iliopsoas, which had the least direct effect. To promote a better understanding, modeling studies have been used to better delineate the contributions of specific anatomical aspects of the hip.^{2, 3} Computer modeling can determine the impact of the forces by constructing a mathematical model of each muscle and having this model in its anatomically correct place in three-dimensional space. The model then allows the muscles to contract to generate force as well as to adjust the muscle's fiber length to simulate contracture. The muscle model also allows altering femoral neck shaft angles so that varus and valgus, as well as various degrees of anteversion, can be modeled. Based on this mathematical model, in evaluating a large number of different variations, it is clearly demonstrated that the problems in the spastic hip are due to two specifically different elements of the pathomechanics.³

The two elements of abnormality in the spastic hip are a hip joint reaction force that is too high and a force vector in the wrong direction in the spastic hip, placing an abnormal force on the developing acetabulum. The etiology of the high hip joint reaction force appears to occur because there is too much co-contraction of muscles, which is clear to clinicians who ex-

amine hips. This co-contraction in which hip flexors, hamstrings, adductors, and abductors are all contracting at the same time generate forces substantially higher than children generate standing on the hip. The etiology of the hip joint reaction force vector being in the wrong direction comes primarily from the position of the hip. The posterosuperior dislocation pattern is caused when the hip is positioned in adduction and flexion (Figure 10.1). This finding is completely consistent with the clinical experience in which the vast majority of subluxated hips and dysplastic hips are positioned in adduction and some degree of flexion. The direct cause of this hip positioning is an abnormal pattern of muscle length and contraction force. The primary muscle that causes adduction and flexion is the adductor longus; however, this is closely followed by the gracilis and the medial hamstrings, and then the adductor brevis.

Based on this understanding of the etiology of posterosuperior subluxation, it is clear that the hip must be positioned so that it is anatomically normal, with some abduction near extension. Also, the hip joint reaction vector must be directed into the central and medial aspect of the hip joint, but in such a way that the hip joint reaction force is not too high. Based on the mathematical model of the muscle, when muscle contractures or spasticity of the adductor muscles are modeled, the only way this positioning can be obtained is by lengthening the adductor muscles. If the hip is forced into abduction and placed so that the hip joint reaction force vector is in the proper direction, the very high force magnitude would cause damage to the hip joint. This damage has been reported in a clinical review report of insensate spastic hips in children with spinal injuries.¹⁷

In summary, the primary pathology of the most common pattern of posterosuperior subluxation in the spastic hip is confirmed by both clinical evaluation¹⁶ and mathematical modeling³ to be caused by overactivity of the adductor longus and gracilis. Secondary deforming forces are the iliopsoas, hamstrings, and adductor brevis, followed by the much less common but still deforming force muscles, the adductor magnus and pectineus.

Secondary Pathology

The primary pathology is the process that initiates the deformity; however, the hip tries to respond to these pathomechanics. The anatomical pathology that develops because of these pathomechanics is the femoral head starts to migrate posteriorly, laterally, and superiorly in the acetabulum under the influence of the leg being positioned in adduction, flexion, and often internal rotation. This movement and abnormal force cause the acetabular rim to become deformed, opening up and developing a channel that is directed posterosuperiorly.¹⁸ The decreased medial pressure allows the triradiate cartilage to grow wider, thereby causing a widening appearance of the teardrop on radiographs.¹⁹ Because the force in the femoral epiphysis is increased on the medial aspect of the epiphysis with a large lateral shear force, the femur responds by developing a valgus femoral neck shaft angle. Therefore, the etiology of the femoral neck shaft angle is another response to the abnormal pathomechanics and position of the femoral head in the acetabulum; however, it is not a primary cause of hip subluxation (Figure 10.2). The etiology of this femoral neck shaft angle has been studied extensively using modeling, specifically finite element analysis of the developing growth plate.²⁰ Based on this finite element analysis, in which it is presumed that the growth plate wants to decrease its shear force, the developing hip joint will grow into valgus so the epiphysis will be at a right angle to the resultant joint reaction force vector. Because of the pathology, the only way that a femoral head and neck will grow into its anatomically normal degree of varus is

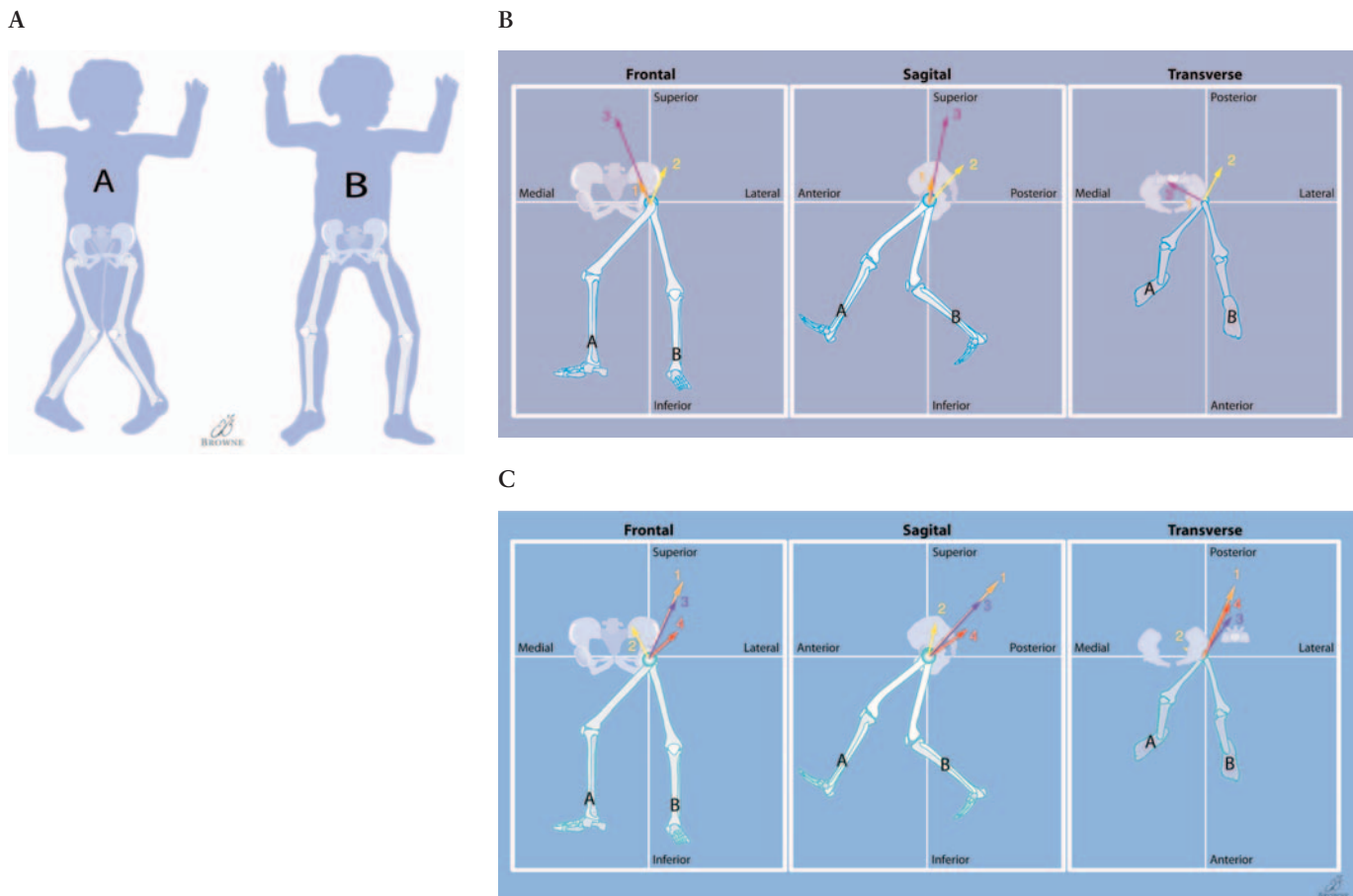


Figure 10.1. The hip joint reaction force is a vector with both magnitude and direction. Both aspects of the hip reaction force are very sensitive to the position of the hip joint and the level of muscle contraction.³ This hip position and muscle force sensitivity are clearly demonstrated on a mathematical model of the hip force with the normal leg lying in the physiologic position (A, Position B), where the force is low and centrally directed (B, Position B, Vector 1) compared with the spastic hip in the same position (B, Position B, Vector 3) and the spastic hip lying in the typical spastic position (Position A) where the force is higher and directed more posterolaterally (B, Position A, Vector 2). This clearly demonstrates a low magnitude and a superomedial direction of the vector in the normal hip (B, Position B, Vector 1). The spastic hip in the typical spastic position has a somewhat higher magnitude but the direction has shifted to be more posterior and very lateral, clearly showing why these hips dislocate (B, Position A, Vector 2). If the hip is forced into the physiologic position, such as with the use of a strong orthotic, the magnitude becomes very high although the direction is better than with the spastic position. This high magnitude would likely cause severe damage to the hip joint, and this is the reason forceful bracing should not be used on the hips of young children. The modeling can also be used to evaluate the impact of different combinations of surgery (C). The spastic hip in the spastic position starts with a high force (C, Position A, Vector 1). By doing muscle lengthenings but leaving the hip in the same position, the force has only a slight reduction (C, Position A, Vector 3), and by adding a varus osteotomy but not changing the position, the force is again only slightly reduced but still poorly directed (C, Position A, Vector 4). If the position of the limb is changed after a muscle lengthening procedure, the force vector is reduced and normally directed (C, Position B, Vector 2). This modeling shows the importance of force reduction by muscle lengthening and the importance of correct limb positioning.

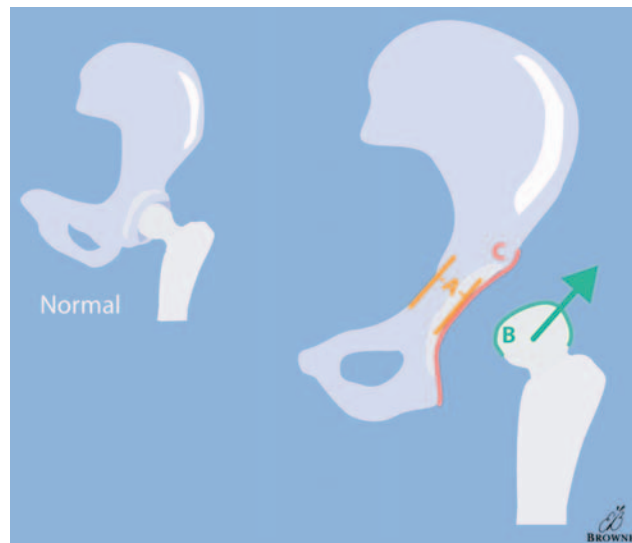


Figure 10.2. The anatomical pathology in the spastic hip develops when the femoral head is forced posterolaterally and superiorly (B). This bends open the lateral rim and labrum and the acetabulum (C). Because the femoral head no longer compresses the medial wall of the acetabulum, the triradiate cartilage grows laterally, thereby widening the medial wall of the acetabulum and decreasing the depth of the acetabulum (A). As the femoral head continues to be laterally displaced, the lateral side of the femoral head is no longer weight bearing and develops severe osteoporosis. The weakened osteoporotic femoral head may then collapse under the tension of the reflected head of the rectus tendon, causing an indentation in the lateral aspect of the femoral head.

through the influence of active standing with active abductor muscle moment (Figure 10.3).

A continued high degree of anteversion is another aspect of the secondary pathology of hip subluxation. This anteversion is believed to be secondary to the anteversion of infancy, which does not resolve because the normal forces on the hip joint are not present. Documentation that this anteversion gets worse under the influence of spastic muscles is poor. Modeling studies in this area have been difficult to perform and, at this stage, are not very definitive. Clinical studies suggest that the primary cause of hip subluxation is failure to resolve anteversion²¹; however, there is some suggestion that if anteversion is corrected in very young children (less than 4 years) it may recur.²²

Another secondary change that progressively becomes worse is when the hip adductor spasticity maintains the hip in a flexed, adducted, and internally rotated position, the muscles gradually develop more contracture. These contractures occur especially in the hip adductors, flexors, internal rotators, and often hamstrings. At the same time, the hip abductors and flexors tend to become overstretched and less effective in their ability to contract. The abnormal force direction also causes eccentric ossification of the femoral epiphysis, often with some medial flattening, especially as the hip starts to subluxate.

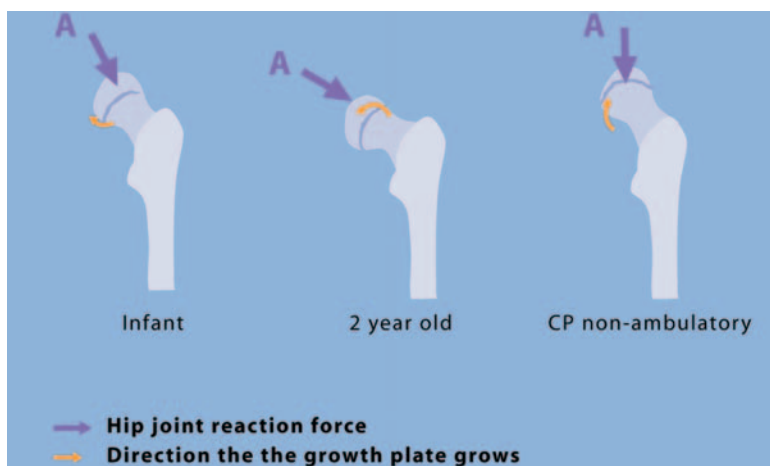


Figure 10.3. The degree of femoral neck valgus is largely determined by the force the proximal femur encounters during the childhood growth period. Based on the appearance of a completely flaccid and paralyzed hip, there is probably an approximately 150° neck shaft angle as the genetic blueprint from which this alternation is made. Also, an infant starts with approximately 150° of femoral neck shaft valgus (A). By the time a child has been walking for 1 year at age 2 years, the femoral neck is about 130° (B); however, for a very spastic nonambulatory child, the femur may increase the valgus to 170° (C). Apparently the femur wants to decrease shear stress in the growth plate so it will grow to be at right angles to the principal force as experienced over time in the capital femoral epiphysis.

Tertiary Changes

The late changes of spastic hip disease include an acetabulum that becomes very shallow because of lateral growth of the triradiate cartilage. In addition to developing a very wide teardrop, this triradiate cartilage may actually form somewhat of a ridge in the center of the acetabulum because there are no opposing forces. Also, the posterosuperior aspect of the acetabular labrum opens up and becomes a fairly deep trough or channel through which the femoral head is migrating further superiorly, laterally, and posteriorly. As the femoral head is migrating through this channel, almost all its force is on the medial side; therefore, the femoral head often develops some flattening along its medial side. Concurrently, there is no force on the lateral aspect of the femoral head except for some soft-tissue force; therefore, the lateral aspect of the femoral head often becomes quite osteoporotic. As the osteoporosis increases, a deep channel from the reflected head of the rectus and the hip joint capsule may develop. As the femoral head either migrates further or stays in this severely abnormal position, the cartilage of the femoral head gradually becomes degenerated and develops deep pitting, and the femoral head has the appearance of late-stage degenerative arthritis. As this deformity continues, the femoral head becomes very triangular in shape from the collapse caused by the severe lateral osteoporosis and compression of the medial side due to high force. The femoral head then takes on a wedge shape. Also, during this later stage, in addition to contractures developing in the adductor muscles, the medial aspect of the hip joint capsule becomes further contracted as well (Figure 10.4).

Natural History

The natural history of spastic hip disease follows a very clear pattern with a defining feature being that the hip at birth in these children is completely normal (see Figure 10.4). If the hips are not completely normal at birth, then these children have developmental hip dysplasia (DDH) and not spastic hip disease, and their treatment needs to be quite different.

Childhood

The childhood stage of spastic hip disease is when almost all the spastic hip pathology begins. This stage is defined as the period from ages 1 to 8 years; however, the highest risk period is from ages 2 to 6 years. Most children with CP start developing spasticity in their second year of life, and as they grow bigger and the brain is developing, the spasticity gets worse. Also, the muscles are growing stronger so that they can generate more force with the spasticity. This higher force then causes the pathomechanics discussed previously. In younger children, because most of their acetabulum is cartilage, the hips are most susceptible to developing instability and anatomical deformity. In these young children, the initial sign of the hip at risk for developing subluxation is when abduction with the hip and knee extended becomes limited. This is an absolutely crucial screening aspect of the physical examination that should be consistently performed on all spastic children. As the force continues to get worse, radiographs start demonstrating lateral migration of the femur. The early stages of subluxation are always silent with no evidence of pain. As the subluxation becomes more severe, some children will have periods of pain as their hips develop some synovitis response. This pain occurs when they have very high force from great spasticity, and the hip starts to migrate laterally, developing severe subluxation that reaches 60% to 80%. Once the hip starts developing subluxation as demonstrated by the migration percentage (MP) measured radiographically in childhood, it is always

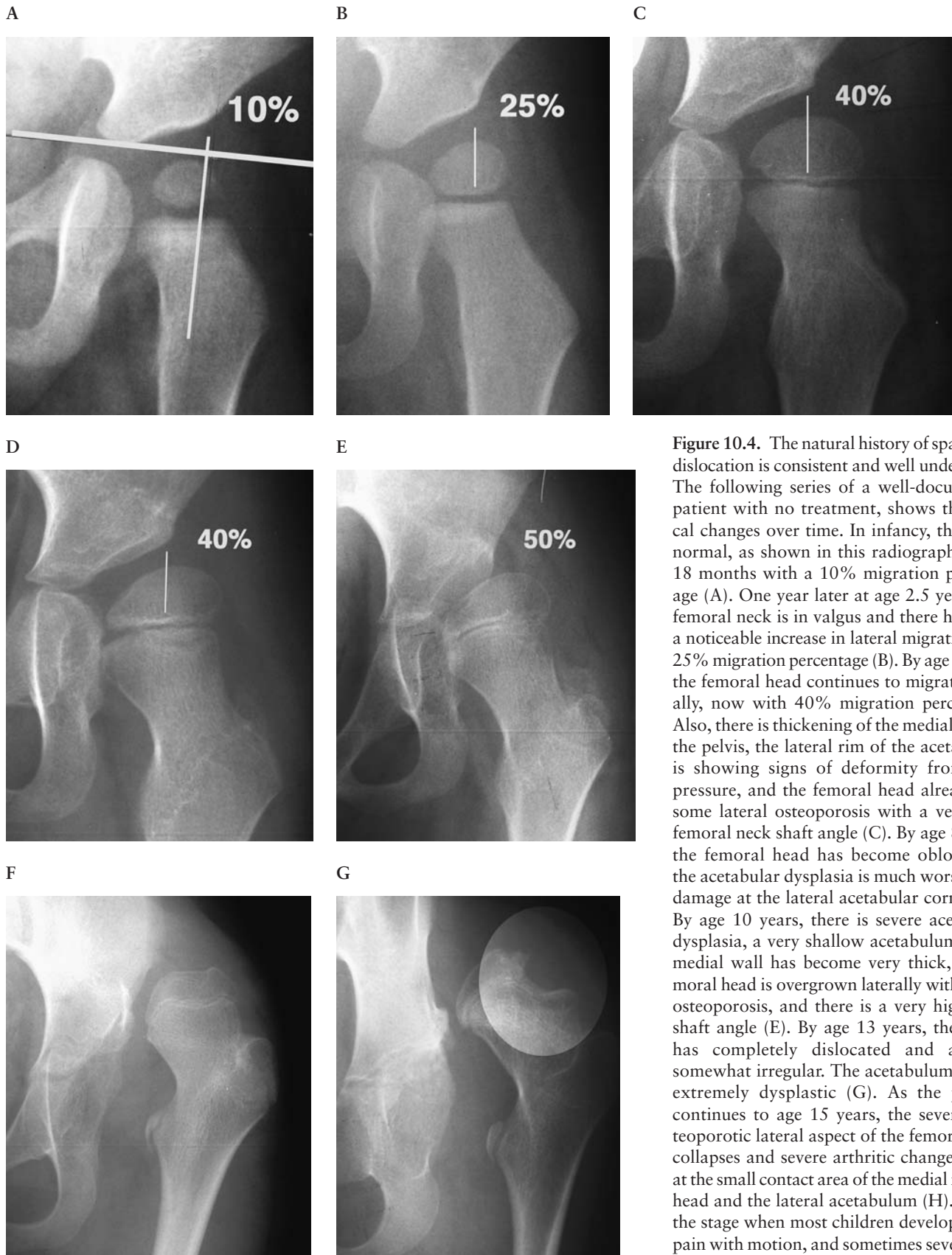

Figure 10.4. The natural history of spastic hip dislocation is consistent and well understood. The following series of a well-documented patient with no treatment, shows the typical changes over time. In infancy, the hip is normal, as shown in this radiograph at age 18 months with a 10% migration percentage (A). One year later at age 2.5 years, the femoral neck is in valgus and there has been a noticeable increase in lateral migration to a 25% migration percentage (B). By age 5 years, the femoral head continues to migrate laterally, now with 40% migration percentage. Also, there is thickening of the medial wall of the pelvis, the lateral rim of the acetabulum is showing signs of deformity from high pressure, and the femoral head already has some lateral osteoporosis with a very high femoral neck shaft angle (C). By age 8 years, the femoral head has become oblong and the acetabular dysplasia is much worse, with damage at the lateral acetabular corner (D). By age 10 years, there is severe acetabular dysplasia, a very shallow acetabulum as the medial wall has become very thick, the femoral head is overgrown laterally with severe osteoporosis, and there is a very high neck shaft angle (E). By age 13 years, the femur has completely dislocated and appears somewhat irregular. The acetabulum is now extremely dysplastic (G). As the process continues to age 15 years, the severely osteoporotic lateral aspect of the femoral head collapses and severe arthritic changes occur at the small contact area of the medial femoral head and the lateral acetabulum (H). This is the stage when most children develop severe pain with motion, and sometimes severe pain at rest develops.

progressive. Subluxation tends to increase at a rate of approximately 2% per month²³ if the migration index is less than 50% or 60%. Once the migration index reaches 50% to 60%, the hip may go to full dislocation in childhood very quickly, sometimes going from 60% to 100% within several months.

Adolescence

The adolescent period, from the ages of 8 to 18 years, is a time when the skeleton is much more mature with less cartilage in the hip joint and much more bone. During this time, the risk for the development of spastic hip disease in a hip that is otherwise normal goes from a relatively low risk at age 8 years to no risk by skeletal maturity. For children who come to preadolescence with some hip subluxation in the range of 30% to 60%, the subluxation may continue to progress; however, the progression is usually quite slow, less than 1% per month.²⁴ During the period of rapid adolescent growth, the development of pelvic obliquity and scoliosis may impact the hips. For hips with mild to moderate subluxation, and if the hip is on the high side of the pelvic obliquity, it has an increased risk of developing further subluxation. However, if the hip is on the down side of the pelvic obliquity, a subluxated hip may actually reduce and end up having a normal radiographic appearance.²⁴

Adult

The natural history of spastic hips in adults is not as well defined. If the hip is normal, defined as an MP of less than 25% or 30%, the risk of developing hip subluxation in adulthood is virtually nonexistent. If the hip has mild to moderate subluxation, defined as 30% to 60%, there may rarely be some progression in adulthood. Most hips seem to remain stable. However, individuals who reach adulthood with hip subluxation of greater than 60% will, slowly over time, go to full dislocation in almost all cases.²⁵

The major disability caused by spastic hips with subluxation or dislocation as the children age is limitation of motion, sometimes severely interfering with custodial care. As an example, it is very difficult to provide adequate perineal care during menstrual cycles for a young adult woman with severe hip adduction contractures from fixed hip dislocation. As outlined above, the subluxated and dislocated hips become arthritic and, like many arthritic joints, become painful. There is a myth in the medical community that the hips do not ever become painful in individuals who are noncommunicative. The fact that these individuals develop painful hips from neglected dislocations is absolutely clear to physicians who routinely care for these individuals; however, it is often difficult to determine how much pain individuals are experiencing. Just as with elderly individuals who have degenerative joints, sometimes individuals with severe changes on radiographs have only mild pain and others with mild radiographic changes have severe pain. This same discrepancy is seen in people with spasticity and hip dysplasia. Although the published literature varies widely, probably 50% to 75% of individuals with spastic hip dislocation experience enough pain that it is recognized by the caretakers or medical personnel.²⁶ Although not entirely conclusively defined, we found that subluxated hips had less pain than dislocated hips.²⁵ There are no good data on how near normal spastic hips have to be to remove the risk of becoming painful with aging.

Diagnostic Evaluations

The most important work in evaluating the diagnostic monitoring of children with the typical posterolateral spastic hip disease was done by Reimers.¹⁶ The most important screening technique for monitoring and evaluating

spastic hips at risk is the physical examination. This examination, which was popularized by Rang et al.,²⁷ is the monitoring of the degree of hip abduction with the hips and knees fully extended (Figure 10.5). All spastic children should have this measure of hip abduction monitored every 6 months during childhood at least to age 8 years. This monitoring can be performed by a trained physical therapist; however, we personally prefer to monitor this in the CP clinic and keep a diligent record in a database. For children who demonstrate some limitation of hip abduction, meaning less than 45° on each side, the secondary evaluation process is a supine anteroposterior radiograph of the pelvis.

Hip Radiograph

The standard anterosuperior supine radiograph of the pelvis with the legs in neutral or relatively neutral position should be obtained every 6 to 12 months if the hip abduction is less than 45°. The MP of this radiograph must be measured and recorded (Figure 10.6). It is not appropriate to only look at the radiograph, because it is impossible to tell the difference between an MP of 20% and one of 35% without measuring. It is no more appropriate to only look at an anteroposterior pelvis radiograph of a spastic child than it is to monitor idiopathic scoliosis by obtaining a scoliosis radiograph and only looking at it without measuring the curve. The measurement of the parameter that is most predictive of outcome is clearly the MP, as demonstrated by Reimers.¹⁶ Another measure of the lateral migration that is used in the monitoring of DDH is the center-edge angle. The center-edge angle is a poor measure for spastic hip disease and has a correlation coefficient of only 0.7 when compared with the MP. The reason the center-edge angle is not a good measure is that it requires defining a center rather than a line in the femoral head, and also requires defining a point in two-dimensional space of the lateral acetabulum. Both these points are often quite diffuse in these young and growing children, making the measurement of the center-edge angle quite inaccurate. The center-edge angle is also a measure that is not linear, but follows the sine curve. Therefore, changes in the area of interest, between 20% and 40%, tend to fluctuate wildly based on these inaccuracies and make monitoring for treatment methods extremely poor. In summary, the center-edge angle has no role in the ongoing monitoring of spastic hip disease. Additional radiographs, such as frog-leg lateral and weightbearing radiographs of the hips, also add no information to the monitoring and treatment decision making for children with spastic hip disease. Because these children often require many radiographs over their lifetime, it is important to limit radiographs to only those that directly add to the clinical decision making, thereby limiting the radiation exposure of these children as much as possible.

Computed Tomography Scans

The use of computed tomography (CT) scan to evaluate hips with spastic hip disease has been extensively reviewed in the literature. It is important to note that not all hips have a typical posterosuperior subluxation of the femoral head, and by far the best mechanism for evaluating the direction of the hip dysplasia is the CT scan.^{28–31} The CT scan is especially useful to clearly define the position of the femoral head. Sometimes direct anterior subluxation or dislocation can have an almost normal radiographic appearance or a very minimal abnormality. At other times, the femoral head can be situated laterally so that it is very difficult to tell whether this is a lateral anterior subluxation or dislocation or a posterolateral subluxation or dislocation. The CT scan is extremely accurate in defining this position. Using the CT scan to evaluate the exact area of the deformity of the acetabulum is also useful;

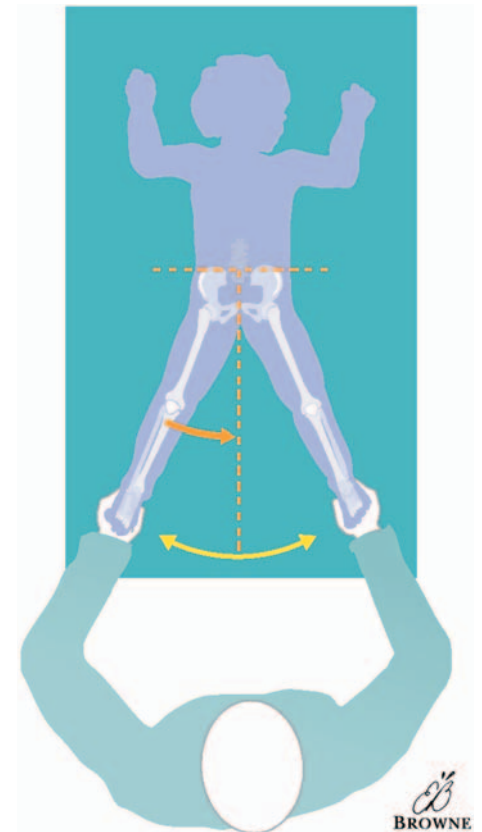
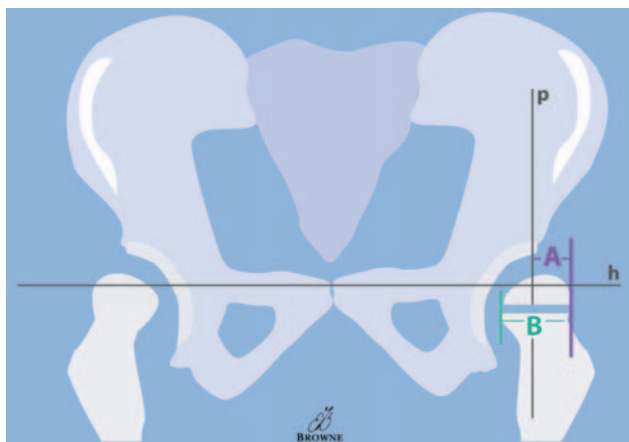


Figure 10.5. The primary screening and physical examination method is to record the hip abduction with the hips and knees extended. This is the most sensitive physical examination measure to determine at risk and subluxated spastic hips. It is important to make sure that asymmetric abduction is noted by observing motion of the pelvis as the hip is abducted.

Figure 10.6. The most important measure to monitor on the radiograph for monitoring spastic hips is the Reimers migration percentage (MP). This should be an anteroposterior supine radiograph with the child's hips in the extended and relatively normal position. The hip should not be forced into abduction or external rotation if the child resists. The first line on the radiograph should be the transverse Hilgenreiner's line (*h*), which goes through the center of the triradiate cartilages. If the triradiates are fused or not apparent, the inferior border of the acetabulum or ischium may also be used. Next, a perpendicular Perkins' line is drawn from the lateral corner of the acetabulum (*p*). The medial and lateral borders of the femoral epiphysis are next defined. Next, a measure of the distance from the Perkins' line to the lateral border of the acetabulum is measured (A); then the whole width of the femoral epiphysis is measured (B). The migration percentage (MP) is equal to A divided by B ($MP = A/B$). Acetabular index can also be monitored; however, accurate measurements are often difficult.



however, in the more typical standard posterosuperior subluxation in which the leg contracture and position are predominantly situated in adduction flexion and internal rotation, it does not add much clinical information. In summary, not all children who are anticipated to have hip reconstruction need to have a CT scan; however, if there is any concern about understanding the exact direction of the subluxation as part of the preoperative planning, a CT scan should be obtained. Computed tomography scan has also been demonstrated to be an excellent mechanism for measuring femoral neck anteversion, especially if a normal femoral neck shaft angle is present.^{32, 33} The use of the CT scan to measure anteversion is most useful after the femoral neck shaft angle has been corrected and abnormal effects of the femoral osteotomy are present.

Ultrasound

Ultrasound of the hip has been used extensively in the evaluation of infants with DDH; however, it has no currently defined role in the evaluation of subluxated spastic hips. Ultrasound is, however, a noninvasive and inexpensive mechanism that can be used to measure femoral anteversion. It is especially useful in measuring femoral anteversion in spastic children who have not had previous hip surgery and have high femoral neck shaft angles.³⁴

Bone Scan

Technetium bone scans may be used to evaluate the source of unknown pain in children who are noncommunicators. These scans are especially useful when evaluating children who have a stable subluxated hip or a dislocated hip that has not been painful previously but suddenly develops discomfort without a readily apparent source. The use of the bone scan in this situation allows defining whether there is any reaction in the hip joint that may be the source of the pain. Technetium bone scan also allows localizing occult fractures, such as fractures in the femoral neck. If there is a question of heterotopic ossification developing when the radiograph is still normal, the bone scan will be clearly positive even if the radiograph is still normal.

Arthrography

Arthrography of the hip has been used extensively in evaluating and deciding treatment processes for DDH and Perthes disease of the hip. There have been reports of using hip arthrography in spastic hips³⁵; however, this test only confirms what is well known and adds no useful clinical information

that can help in diagnostic decision making. There is no routine role for hip arthrography in spastic hip disease.

Treatment

In planning the treatment algorithm, it is important to make sure that children have spastic hip disease, meaning that the hip problems are caused by force pathomechanics occurring in childhood and not DDH, which is an abnormal hip emanating from infancy. Likewise, it is important to understand that this discussion applies only to children who are hypertonic, not hypotonic children whose hip dislocation is due to low muscle force. The important factors in making a treatment algorithm require knowing the age, the degree of abduction of the hip, and the MP from a radiograph. The hip treatment is then divided into three areas, which follow. The first area is prevention, in which the treatment is addressed at the root cause of the spastic hip disease. The second area is reconstruction, in which the treatment is primarily directed at reversing the secondary effects of spastic hip disease. The third, or palliative, area is the treatment directed at addressing the tertiary symptoms and deformities of spastic hip disease.

Prevention

The goal in the treatment of all spastic hip disease should be the prevention of hip dislocation. The question of how important having located hips in children with such severe CP has occasionally been raised. Dislocated hips definitely cause pain and functional problems; however, the very best observation in this area comes from Dr. Mercer Rang, who stated that he never saw a child with CP who he thought would be better off with a dislocated hip than a reduced hip.³⁶ Based on the understanding of the long-term problems that dislocated hips cause and that preventative therapy is relatively benign and effective, all children, except those who have an expected life expectancy of only a very few years, should be managed aggressively to prevent hip dislocation. As noted in the natural history, the high-risk period for the development of hip subluxation is from the ages of 2 to 6 years, and this is the most important time for screening the spastic hips.

Dr. Rang has made an excellent contribution by focusing on screening and educating medical care providers that these hips do not suddenly dislocate overnight nor do they dislocate without physical examination evidence that the process is in progress.³⁶ The bedrock of preventative treatment is physical examination screening of all children with spastic hip disease, every 6 months to age 8 years. This screening should focus on recording the hip abduction with hips and knees extended. Children whose abduction is less than 45° are considered at risk and are required to have hip radiographs. The goal of the screening in the prevention phase is to identify children whose hips have early subluxation. There is no indication to treat hips at risk, such as hips that have only limited abduction in growing children. No evidence exists that orthotic treatment of these hips has any impact. Additionally, there are many children who have hips at risk throughout their whole childhood and never develop subluxation. Therefore, there is no indication for surgical treatment until evidence of subluxation becomes apparent. This approach to treating spastic hips is exactly the same approach that is used in newborn screening of DDH all over the world. Just as it has been documented to dramatically decrease the number of adult dislocated hips, screening of spastic hips also decreases the number of dislocated hips in children with spasticity.¹²

Treatment Indications

Children younger than 8 years of age who have an MP greater than 25% and less than 60% with hip abduction less than 30° should be scheduled for soft-tissue release (Case 10.1). In young children, up to age 4 years, soft-tissue release is an appropriate response even if the migration index is close to 100%. Although the outcome of the soft-tissue lengthening will be much less optimistic, it does allow waiting several years until reconstruction is undertaken (Case 10.2).¹² Soft-tissue release is also indicated in a small



Case 10.1 Amber



Amber, a 3-year-old girl with severe spastic diplegia, presented with a complaint that she was not able to walk. She was born prematurely but currently had no other active medical problems. She just began to speak with simple multiple sentences. She also started to self-feed with a spoon. On physical examination a mild degree of upper extremity spasticity was noted but she had good motor control. Moderate spasticity was noted through the lower extremities. Hip abduction was 15° on the left side and 25° on the right side. Popliteal angles were 45° bilaterally and ankle dorsiflexion was to 10° with knee extension. She was able to sit independently with hand support and could stand when leaning against a chair. Radiographs of

her hips, which demonstrated migration percentage of 38% on the right and 60% on the left, were obtained (Figure C10.1.1). Both acetabula already had significant dysplasia. Within 6 weeks, she was scheduled for lengthening of the adductors and iliopsoas. At the 8-month postoperative clinical follow-up, a radiograph showed migration percentage (MP) of 30% on the right and 34% on the left (Figure C10.1.2). Over the next several years, she continued to be monitored, and by the 5-year follow-up, the hips were normal radiographically with MP on the right of 14% and 17% on the left (Figure C10.1.3). By skeletal maturity at age 16, she had normal hips (Figure C10.1.4).

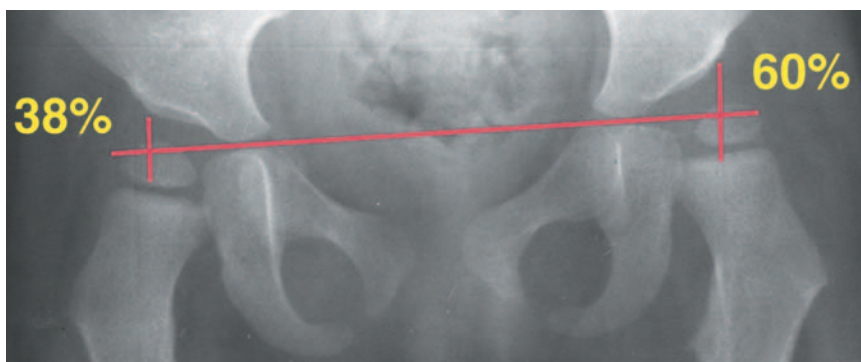

Figure C10.1.1

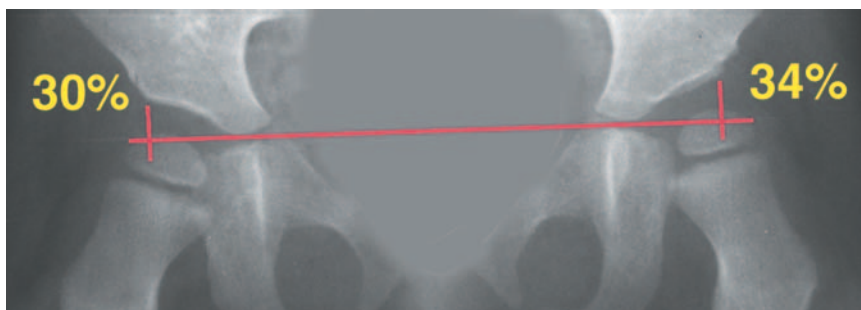

Figure C10.1.2

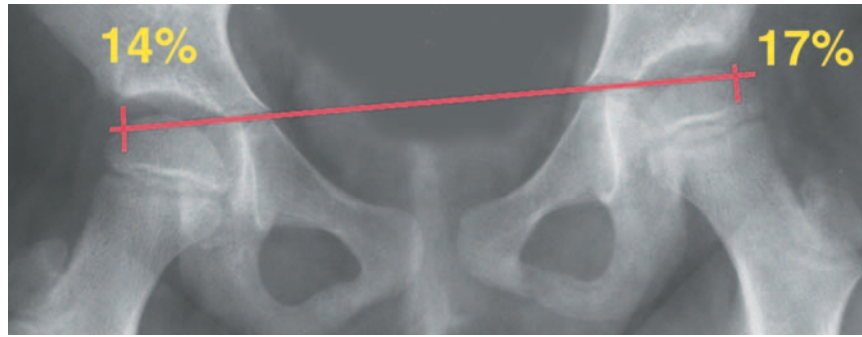


Figure C10.1.3

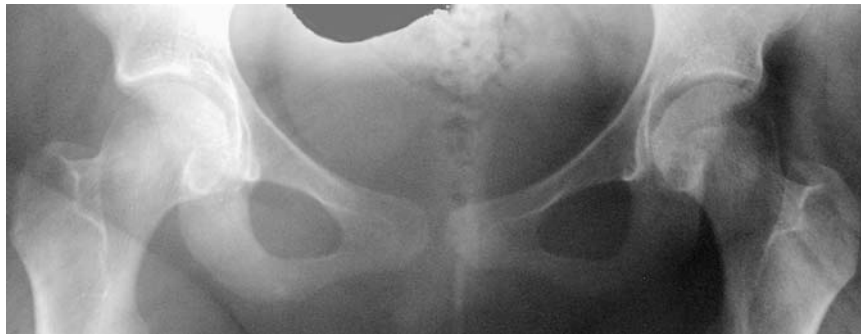

Figure C10.1.4

group of children who may have hip abduction between 30° and 45° but are demonstrated to have progressive hip subluxation, having been monitored to go from 20% to 40% or to 50%. However, all children who have hip abduction substantially greater than 45° likely do not have spastic hip disease and should be considered to have hypotonic hip disease and are not treated using this treatment algorithm. This treatment algorithm, which is based on the importance of age, hip abduction, and migration index, has well-defined treatment criteria and defined outcomes.¹² There are studies that suggest age is not important^{37, 38}; however, both clinical experience and monitoring in our own research demonstrate that age is extremely important.^{12, 23} Children definitely do best if they are under age 5 or 6 years at the time of muscle lengthening. It makes very little sense to expect any positive remodeling results from soft-tissue lengthening alone in a subluxated hip over age 8 years. The importance of migration percentage has been defined in many publications,^{12, 23, 37-39} as well as clinical experience demonstrating that the more severe the deformity and subluxation, the less positive a response from soft-tissue lengthening alone.

Specific Treatment

Adductor lengthening is the first proposed surgical treatment of spastic hip subluxation⁴⁰ and has been reported as the treatment option in 69 separate references dating back to 1957. In spite of this consensus, there is very large variation in selection criteria and methods of doing the adductor lengthening, ranging from percutaneous adductor tenotomy to many combinations of open lengthening. The other problem with many of these studies addressing adductor lengthening is that they have very poorly defined inclusion criteria and very poorly and variably defined outcomes criteria. The first



Case 10.2 Elise

Elise was a 2-year-old girl with severe spastic quadriplegia. Her mother's main concern was that she sat poorly. She was born prematurely at 22 weeks gestation and had bronchopulmonary dysplasia for which she still required oxygen therapy. Her feeding was by gastrostomy tube, and she was being treated for active seizures. She had limited head control, was a dependent sitter, and had no hand function. Examination demonstrated trunk hypotonia, with upper and lower extremity spasticity. Hip abduction was 0° on the right and 30° on the left. Popliteal angles were 60° bilaterally. Radiographs of her hips showed a right hip almost dislocated with 87% MP percentage and 53% MP on the left (Figure C10.2.1). Because of her young age and multiple medical problems, soft-tissue release was recommended. Her mother was told that there was a greater than 50% chance that Elise would need additional surgery on her hips, however, not for several

years, which would allow her to grow and perhaps her lungs would also get better. She had an aggressive lengthening with complete release of the gracilis, adductor longus and brevis, iliopsoas, and proximal hamstring, along with an anterior branch obturator neurectomy on the right side. On the left side, she had aggressive lengthening with complete release of the gracilis, adductor longus, iliopsoas, and proximal hamstring. After 2.5 years follow-up at 5 years of age, she had no problems with her lungs, her seizures were well controlled, she was still gastrostomy tube fed, and she had poor sitting balance. Her hip radiographs showed an excellent response on the right side with migration percentage of 23%, which was almost dislocated; however, the left, which had a less aggressive lengthening, was now severely dysplastic with a 50% subluxation (Figure C10.2.2). Reconstruction can be recommended and may have less risk with her improved respiratory function.

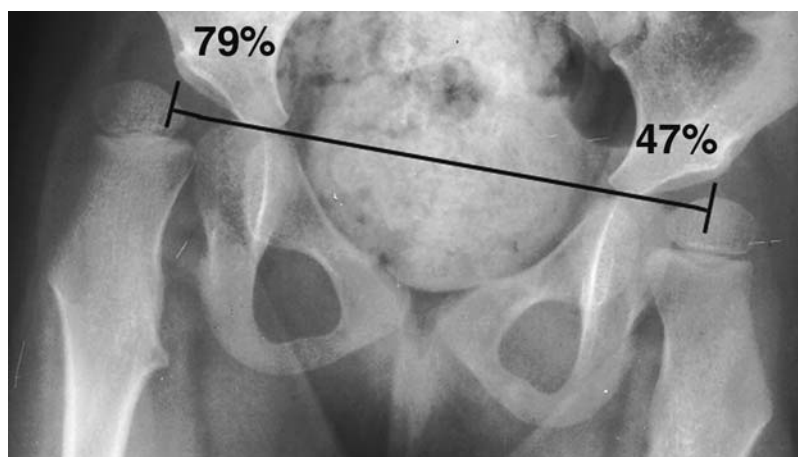


Figure C10.2.1

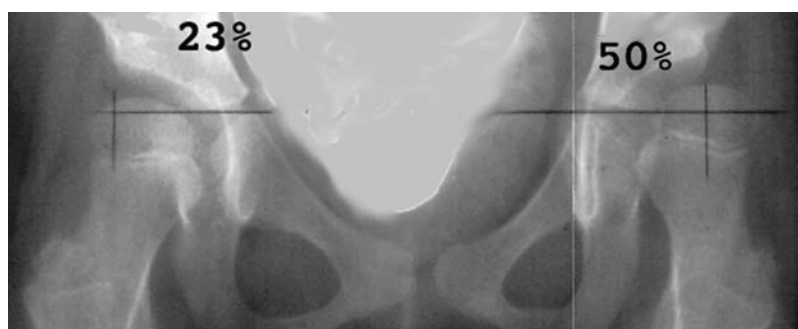


Figure C10.2.2

publication that had clear inclusion and outcomes criteria as well as a concise treatment algorithm was not published until 1985.²⁷ Currently, it is not possible, based on the multiple options presented in the literature, to make any assessment in comparing one type of soft-tissue treatment versus another because of the great variation. Our general assessment is that any soft-tissue tension reduction on the adductor side is better than doing nothing; however, the best balance yields the best outcome.

In an attempt to review the literature carefully, it is difficult to be sure that percutaneous adductor lengthening has a worse outcome than an open adductor lengthening because of the extremely poor and variable inclusion and outcomes criteria. It is our perspective, however, that percutaneous adductor tenotomy definitely has a poorer outcome than a more adequate open lengthening. A typical example is the suggestion that open and percutaneous adductor lengthening are equal³⁹; however, the outcome of both these procedures is substantially less than the reported results in more adequate open lengthening in which 80% of children should have normalized hips.^{12, 27} This suggests that two inadequate procedures are equal to themselves, whether they are open or percutaneous does not matter, and an adequate open procedure yields a better outcome. The specific treatment plan outlined here is based on understanding obtained from modeling³ and careful clinical evaluation of important muscles,¹⁶ as well as an evaluation of clinical outcomes.^{12, 27}

Operative Procedures

The procedure should be an open procedure in which the adductor longus and the gracilis are completely transected. Iliopsoas lengthening should include a complete transection in children who clearly are not going to be ambulators, and the surgery should be a myofascial lengthening for children who have possible ambulatory ability. Adductor brevis myotomy is performed until children have 45° of hip abduction with hip and knee extended without any force under anesthesia. Proximal hamstring lengthening is performed if the popliteal angle is greater than 45°. Anterior branch obturator neurectomy is performed if children have greater than 60% migration and are not expected to have ambulatory ability in the future.

Following the operative procedure, children should be checked in the outpatient clinic at 4 weeks for wound check and then at 6 months after surgery when the first postoperative radiograph is obtained. At this time, children should have hip abduction greater than 45° and the MP should be in the normal range or have a substantial improvement. If the hip MP is 25% or less, these children should have the next radiograph obtained in 1 year, if the MP is still abnormal but improved, the next radiograph is obtained in 6 months. These children should be followed up every 6 months, again monitoring hip abduction and monitoring hip radiographs annually if they are in the normal range until the children are 8 years old or have two consecutive normal hip radiographs, at which time radiographs are usually obtained every 2 years.

The Outcome of Preventative Treatment

The outcome of preventative treatment has been difficult to assess because many published reports use different types of releases with poorly defined indications. Outcome measures are also variable and poorly defined. The first report with clear, consistent indications, a consistent procedure, and that followed with rigid outcomes criteria was published in 1985.²⁷ Most of the review discussion of outcome is from the publication that uses the criteria outlined previously, with rigid criteria for outcomes.¹² A good outcome

required a hip whose MP was less than 25% at final follow-up (Case 10.1). A fair outcome was a hip whose MP was between 25% and 40% (Case 10.3). A poor outcome was any individual whose MP was 40% or greater (Case 10.2). These criteria were used to evaluate 74 children who had 147 adductor lengthenings performed at an average age of 4.5 years, with an average preoperative MP of 34%. At the 6-month follow-up visit, MP reduced to 27%.



Case 10.3 Ethan

Ethan, a 2-year-old boy, presented with spastic quadriplegia. Hip abduction was limited to 25° bilaterally; however, the radiograph showed normal hips with less than 10% migration (Figure C10.3.1). One year later, the hip abduction was 20° bilaterally and the hip radiograph showed definite left hip subluxation with 40% migration (Figure C10.3.2). He had bilateral adductor longus tenotomy, gracilis tenotomy, and iliopsoas and proximal hamstring lengthening. A radiograph 18 months later revealed improved hip position on the left with a 29% migration (Figure C10.3.3). Hip abduction was 45°. By 9 years of age, the hip migration was slightly increased at 33% and 30%, and he had developed definite acetabular dysplasia (Figure C10.3.4). He could stand for transfers but had no

ambulatory ability. By the end of growth at age 16 years, he developed slight pelvic obliquity that caused his right hip to reduce and the left hip remain stable. By this age, the hip adduction had again decreased to 25° on the left and 35° on the right (Figure C10.3.5). This is an example of the intermediate outcome in which the child is left with a definite abnormal hip including mild subluxation and acetabular dysplasia; however, in a nonambulatory individual, this may remain stable throughout a lifetime. There is little research evidence to guide treatment decision making for these intermediate hips. This type of hip does need monitoring, and if the hip develops progressive subluxation or becomes painful, it should be treated.

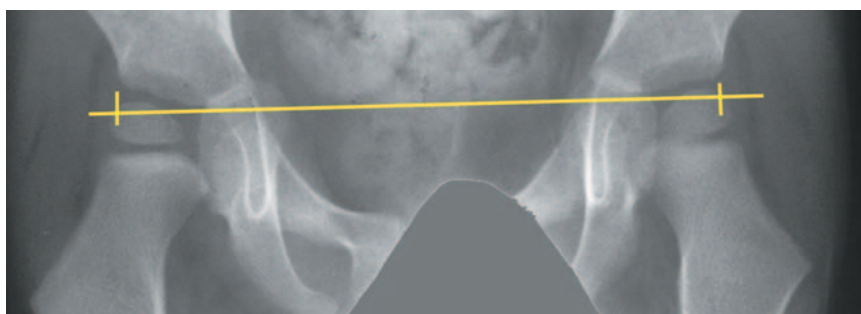


Figure C10.3.1

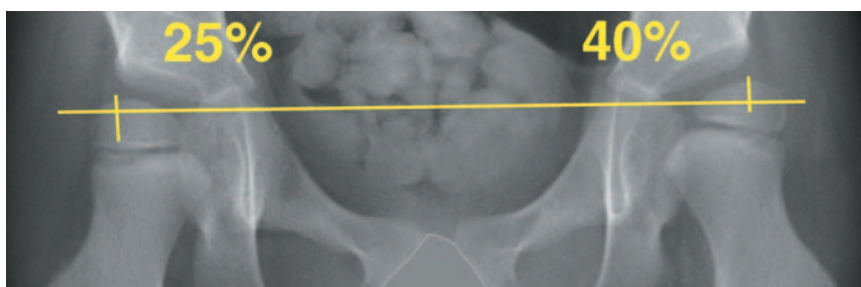


Figure C10.3.2

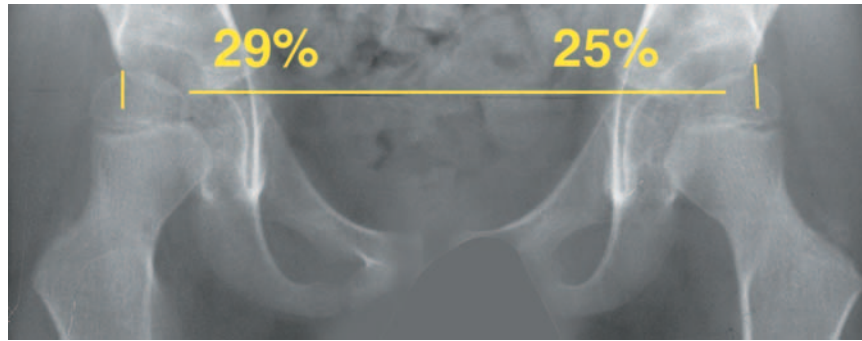


Figure C10.3.3

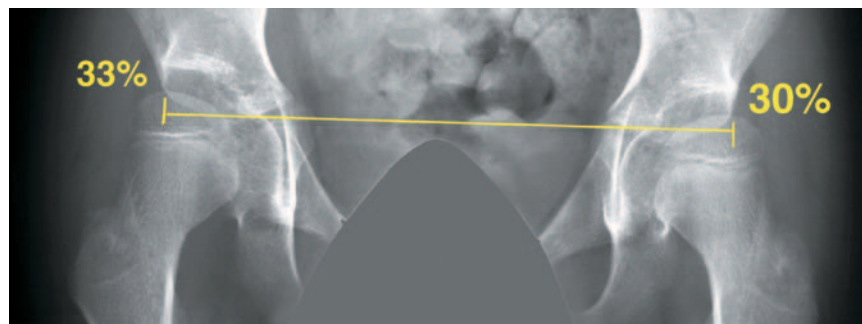


Figure C10.3.4

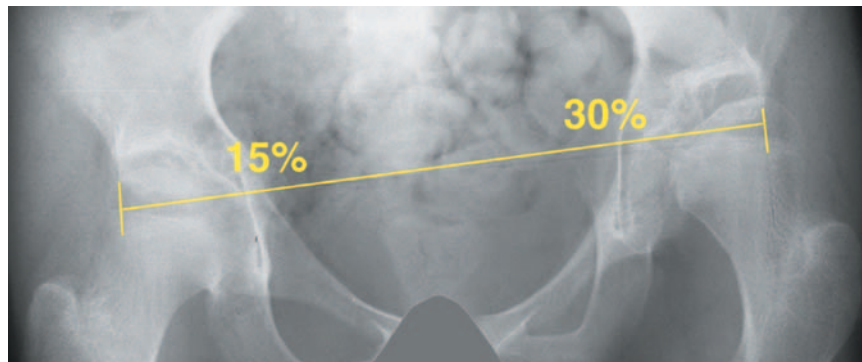


Figure C10.3.5

By a mean 48-month follow-up, MP reduced further to 22% (Table 10.1). Twenty-nine hips that had adductor lengthenings had a preoperatively normal MP, meaning less than 24%, and at final follow-up, 76% of these hips had a good rating, 10% were fair, and 14% were poor outcomes. Seventy-seven percent of the hips were initially mildly subluxated, meaning they had an MP between 25% and 40%, for a mean MP of 31%. At final follow-up, 56% of these hips had good outcomes, 36% had fair outcomes, and 8% had poor outcomes. There were 32 moderately subluxated hips with an MP between 40% and 60%, for a mean of 46%. At final follow-up these hips were graded as 38% being good, 50% fair, and 13% poor. Nine hips were severely subluxated initially with a mean migration percentage of 73%. At

Table 10.1. Migration percentage response over time.

	Preoperative	Postoperative 1	Postoperative 2	Postoperative 3	Postoperative 4
Normal	16	17	20	19	20
Mild	31	26	26	26	23
Moderate	46	33	31	28	24
Severe	73	52	37	34	

Numbers are migration percentage in %: normal is <25%, mild 25%–40%, moderate 40%–60%, and severe >60%. Follow-up times are 6 months postoperative for the initial follow-up, 12 to 18 months for the second follow-up, 36 months for the third follow-up, and 48 months for the fourth follow-up.¹²

final follow-up, 33% of these hips were good, 22% were fair, and 44% were poor and graded as failures¹² (Table 10.2). These data demonstrate that the majority of the improvement occurs in the first 6 to 12 months postoperatively but that hip MP continues to improve gradually (see Table 10.1). It is important to continue to monitor these hips until skeletal maturity since the good outcomes decrease to approximately 70%.

The MP response for ambulators and nonambulators does not differ, although nonambulators clearly had less aggressive adductor lengthenings, and less severe neurologic involvement, which explains this discrepancy. The acetabular index was 19° for hips that had a good outcome, which steadily dropped to a mean of 13° at final follow-up. The hips with fair and poor outcomes had a slightly higher acetabular index starting at 23°, but it also slowly dropped. Additionally, hips that had a poor outcome had much less improvement than the hips that had a fair outcome. The problem with using acetabular index as either a monitor of response of the hip or as an indication for surgery is that the difference between 19° and 23° is well within the measurement error (see Table 10.1). There was a large amount of overlap, so that these two groups were not well separated. The measurement error for the acetabular index is $\pm 3.2^\circ$ for interobserver variation.⁴¹ The hip abduction in all groups improved over 45° at the first follow-up, and similarly for all groups, gradually lost the degree of the range of motion that had been gained initially. Interestingly, the hips with a good outcome definitely did maintain better range of motion, having gone from 30° preoperatively, ending at 48° immediately postoperatively, but settling back to only 43° by the 4-year follow-up. However, hips with a fair outcome had similar initial response but by the 4-year follow-up, had only 27° of abduction remaining. A similar response was noted in the popliteal angle, which dropped dramatically after hamstring lengthenings, but then rebounded almost to its preoperative level, especially in the fair group.

We also attempted to evaluate the impact of asymmetric surgery. Ten patients who had undergone asymmetric adductor lengthenings, meaning they either had the adductor brevis lengthened on one side and not the other or they had an anterior branch obturator neurectomy on one side and not the

Table 10.2. Migration percentage relative to severity.

	Normal	Mild	Moderate	Severe
Good	76	56	38	33
Fair	10	36	50	22
Poor	14	8	13	44

Numbers are migration percentage in %: normal is <25%, mild 25%–40%, moderate 40%–60%, and severe >60%, which is the preoperative state of the hips. The final follow-up was graded good, meaning migration percentage (MP) was less than 25%, fair outcome was a MP between 25% and 40%, and a poor outcome had a MP greater than 40%.¹²

other, were evaluated. Of these 10 patients, 6 had an asymmetric MP pre-operatively and at final follow-up, 4 patients still had an asymmetric MP with 2 of these having reversed their asymmetry (Case 10.4). Based on this evaluation, attempting to make the children's hips symmetric by doing somewhat asymmetric hip surgery is beneficial, but unless there is a definite fixed abduction contracture present, adductor lengthening should be performed on both sides. Even those hips that had normal radiographs at the time of adductor lengthening still had a 14% failure rate. This failure rate occurred because, in several cases having asymmetric lengthenings, the side that had more lengthening became the abducted side and the side that was previously normal now became adducted. Without this attempt to maintain symmetry by releasing both sides, the results probably would have been worse. These results further substantiate that unilateral hip surgery should not be done unless there is a definite fixed abduction contracture present.

Other Treatment

Adductor lengthening is the only published treatment that has a positive effect on the treatment of hip subluxation short of bony reconstruction. Physical therapy is often mentioned as a useful adjunct to maintaining range of motion and helping the hips; however, the only published article has no radiographic documentation of benefit to the hip.⁴²

Iliopsoas Transfer

Lateral transfer of the iliopsoas to the greater trochanter was developed for augmenting the paralytic condition present in spina bifida. This technique has also been applied to children with spasticity under the presumption that the strong iliopsoas would provide abductor strength and reduce the hip into the joint. Sharrard and Burke report success maintaining reduction in 23 of 24 hips.⁴³ However, others report failure rates of 42%⁴⁴ and 55%.⁴⁵ The pathomechanics of spastic hip disease involve a combination of force vectors in the wrong direction; therefore, when the force vector is too high, this procedure does not make good theoretical sense as a treatment for spastic hip disease. Based on the published reports of extremely high failure rates and the poor theoretical benefit, this procedure should not be used in the treatment of spastic hip subluxation or dislocation.

Adductor Transfer

Posterior transfer of the adductor muscle mass including adductor longus, brevis, and gracilis is a procedure developed with the goal of providing extensor strength and thereby giving better balance to the hip muscles. Root and Spero advocated that children were functionally better even though this was a bigger surgery with more complications.⁴⁶ However, two studies with direct comparison of adductor tenotomy with adductor transfer^{47, 48} found no difference on the effect of hip subluxation. In addition, there is an extremely high rate, up to 33%, of the transferred muscles detaching.⁴⁹ There is also a high rate of pelvic obliquity over the long term, with 85% of patients developing pelvic obliquity, during which time 36% of hips also subluxated further.⁵⁰ Based on these reports of poor results and the technical problems involved in this operative procedure coupled with it not making good theoretical sense, this procedure should be abandoned in the treatment of spastic hip disease. Again, this procedure does not try to alter the force vector very much because the adductors are still strong. It only tries to balance the hip force by creating more extensor force, and thereby if it did actually work, would increase the already too high hip joint reaction force.



Case 10.4 Courtney

Courtney, a 2-year-old girl with spastic quadriplegia, presented with a very asymmetric hip abduction. On the right, the hip abduction was limited to 10° and on the left, abduction was to 60° with some contracture of the abductors, allowing adduction to only neutral. The radiograph showed 55% subluxation on the right side (Figure C10.4.1). She had a right adductor longus, gracilis, and iliopsoas lengthening and only a minimal adductor longus lengthening on the left. By 6 months after surgery, the right hip had 20% migration and the left hip was up to 35% migration (Figure C10.4.2). She was then lost to follow-up for 18 months until she returned at age 4 years with a dislocated left hip and a severe windblown hip

deformity (Figure C10.4.3). This hip was reconstructed; however, some of the windblown deformity was still present radiographically 4 weeks after reconstruction (Figure C10.4.4). By 1 year after surgery, the windblown deformity had again become very severe. At this time, the plates were removed, and the left hip had a complete adductor release and the right hip had an almost complete abductor release (Figure C10.4.5). This case demonstrates the effect of doing too much asymmetric release of the hip adductors; however, during the reconstruction, the failure was in not doing enough asymmetric release of the adductor muscles. In some of these hips, it is very difficult to find the right balance.

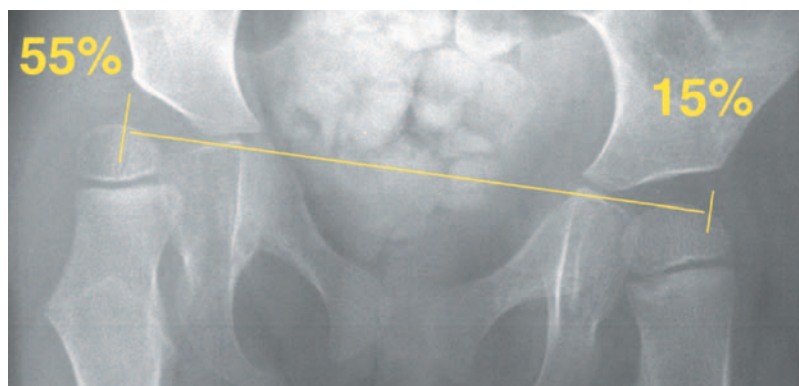


Figure C10.4.1

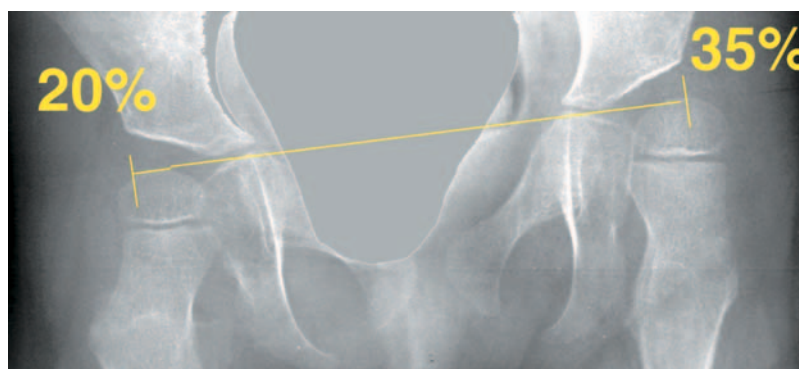


Figure C10.4.2

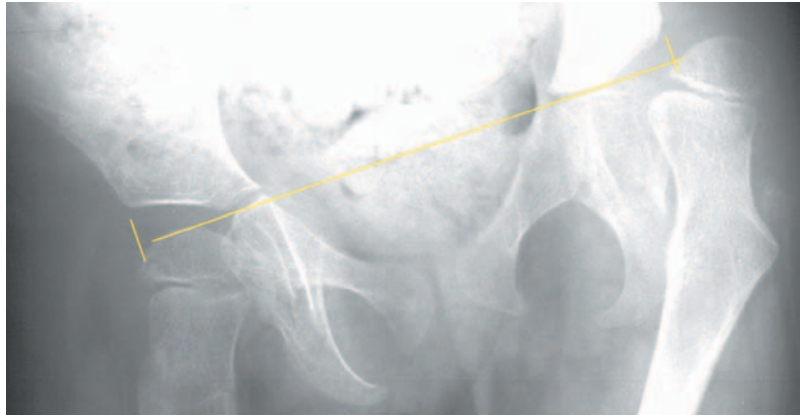


Figure C10.4.3

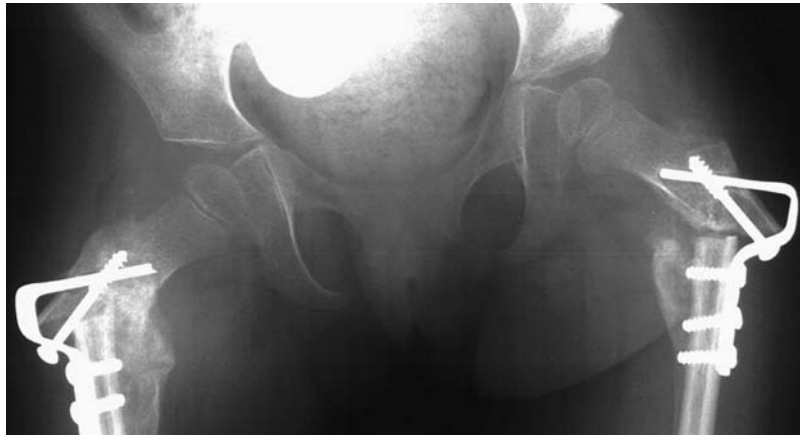

Figure C10.4.4

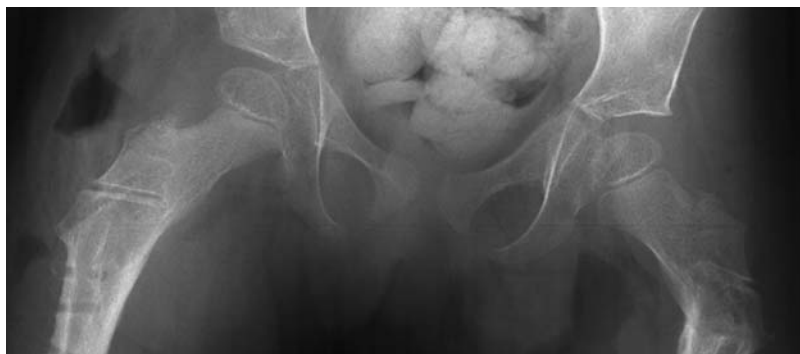


Figure C10.4.5

Botulinum Toxin Injection

Botulinum toxin has become a very popular short-term treatment of spastic individual muscles. There have been discussions at meetings about the use of botulinum toxin in the adductor muscles to prevent spastic hip subluxation; however, there are no published data evaluating the success of this treatment. Botulinum toxin has only a 3- to 4-month effectiveness, followed by

which the spasticity returns. Because spastic hip subluxation is a long-term problem, most children obtain significant effect from botulinum toxin for only three or four injections at the most. The use of botulinum toxin for the treatment of spastic hip disease must be limited to strict clinical trials with very careful monitoring, and immediately proceeding to soft-tissue lengthening if the subluxation is not resolving quickly or if it shows any signs of getting worse. Good outcome is obtained from the preventative treatment of spastic hip subluxation in approximately 80% of children with one soft-tissue lengthening.¹² Therefore, any failure rate from the use of botulinum toxin higher than this would be extremely difficult to justify.

Intrathecal Baclofen

The use of intrathecal baclofen is currently becoming popular for decreasing spasticity. Intrathecal baclofen permanently decreases spasticity so long as the pump is in place; however, there are no published data on its positive impact on hip subluxation. At this point, it is too expensive and too complicated to be used as a primary treatment for spastic hip disease.

Dorsal Rhizotomy

Dorsal rhizotomy is a procedure that was very popular in the early 1990s as a treatment of spasticity. There were several studies suggesting that dorsal rhizotomy increased the risk and rate of hip subluxation because it usually did not address spasticity in the iliopsoas.^{51, 52} Other studies, however, suggest that it may have some positive effect on the spastic hip by lowering spasticity, although these studies were both very poorly controlled with very poorly defined outcome measures. Based on this published literature, which suggests a positive effect of the rhizotomy, it seems reasonable that decreasing spasticity in some patients would decrease the incidence of hip subluxation. However, dorsal rhizotomy is clearly not nearly focused enough and is much too large an operative procedure considering the excellent outcome with a fairly small and well-defined soft-tissue lengthening.

Abduction Orthosis

Abduction orthoses have been suggested as being beneficial in the treatment of spastic hip subluxation^{53, 54}; however, there is no documentation to demonstrate either their ability to prevent subluxation or that there is any radiographic change in the subluxation. Both these reports note the difficulty that these abduction orthoses cause added burden to families and discomfort. Based on clinical reports of the aggressive use of abduction bracing in insensate spastic children, there is clear documentation that harm can be caused to the developing hip by increasing the force in the hip joint and causing severe deformities of the proximal femur.¹⁷ This harm is not likely to occur in children with CP because the level of pain it would cause would make it clear to all caretakers that the children are not able to tolerate the orthotic. Based on the current understanding of the etiology, it is not sensible to use an abduction orthosis to try to force the spastic hip into abduction as this just dramatically increases the force in the hip joint and most likely will not be successful in preventing subluxation. Therefore, the use of hip abduction orthoses to prevent hip subluxation is not recommended in children with spasticity.

The use of a hip abduction orthosis after adductor lengthening to maintain the hip in the abducted position makes more theoretical sense because the total hip joint reaction force has been decreased by the muscle lengthening. However, it is almost impossible to get symmetric abduction; there is a tendency for the hip that abducts easiest to abduct further and allow the

other hip to adduct. Using aggressive postoperative abduction orthoses in this way can actually lead to or cause windblown deformities and pelvic obliquity. It has been suggested that there is a substantial benefit of improving the outcome of soft-tissue release⁵⁵ by using postoperative orthoses, and compared with using no abduction orthoses,¹² there may be a slightly better outcome in the degree of subluxation of the hips. However, this slightly improved outcome must be balanced against the number of children who need to be treated for hyperabduction and windblown deformities.⁵⁵ This number is much greater than was noted when no abduction orthoses were used.¹² Recurrent subluxation is easier to address and less functionally disabling than severe windblown deformities or abduction deformities of the hip; therefore, using any fixed abduction orthoses postoperatively is not preferred.

Complications of Preventative Treatment

The primary complication of preventative treatment is failure to normalize the hips. As noted in the outcome documentation, 11% of children at a 4-year follow-up required additional surgery because their migration percentage continued to be greater than 40%.¹² If the subluxation initially improves, has a tendency to stabilize, and the adduction contracture recurs, doing a second adductor lengthening can be considered. A second adductor lengthening, however, is documented to have only 50% of the positive effect of the initial adductor lengthening.¹⁶ Therefore, if the initial adductor lengthening has failed, and a recurrent adduction contracture develops with residual hip subluxation, it is better to proceed and do a reconstruction. Based on current understanding and follow-up, the failure rate with the need for further surgery for hip subluxation will be between 10% and 20%.

Some children, mainly children who were poor sleepers preoperatively, will develop very difficult sleep disorders after surgery for hip subluxation. This issue needs to be addressed as outlined in the general postoperative complications follow-up section.

Pain

Most of the postoperative pain in children with soft-tissue release is resolved by 3 to 4 weeks after the surgery. Typically, by the second postoperative day, children are relatively easy to hold and handle without too much discomfort. Range-of-motion exercises should be pain free by 4 weeks postoperatively. If pain continues, especially if children initially get a little better and then get worse again, the development of heterotopic ossification should be suspected. If pain is continuing at the 4- to 8-week period, radiographs are recommended (Case 10.5). Occasionally, an occult fracture that is generally in the distal femur may also occur, but this is quite rare. This occult fracture is much more common if children have been placed in a cast or other continuous immobilization. If the radiographs are normal and the pain is still substantially higher than expected, a bone scan, which will demonstrate the evolution or development of heterotopic ossification or an occult fracture, should be obtained.

Infections

Wound infections may occur in the adductor wound; however, they are usually superficial with suture abscesses or irritation from the suture. These superficial wound infections are easy to treat with local cleaning and drying. If there is local cellulitis, the addition of an oral antibiotic may be useful. If a deep wound infection develops with drainage from the adductor, children need to be returned to the operating room, the whole wound opened, aggressively irrigated, and debrided as indicated. If there is considerable



Case 10.5 Kara

This 4-year-old girl, Kara, had an adductor and iliopsoas lengthening for hip subluxation. By 4 weeks after surgery, range-of-movement exercises of her hip were still very painful. A radiograph was obtained that was thought to be normal (Figure C10.5.1). Gradually, over the next

3 months, her pain went away, and when the 6-month postoperative radiograph was made, the heterotopic ossification in the tendon of the iliopsoas was clear (Figure C10.5.2).

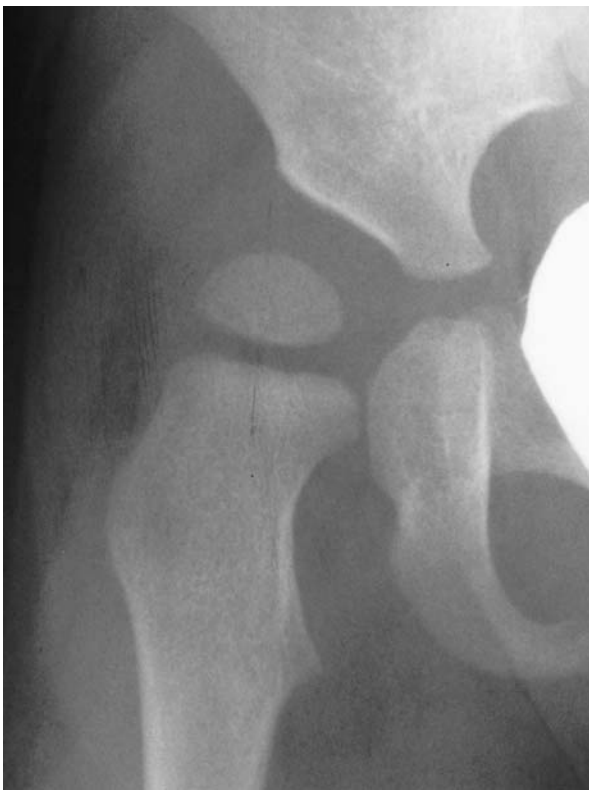

Figure C10.5.1

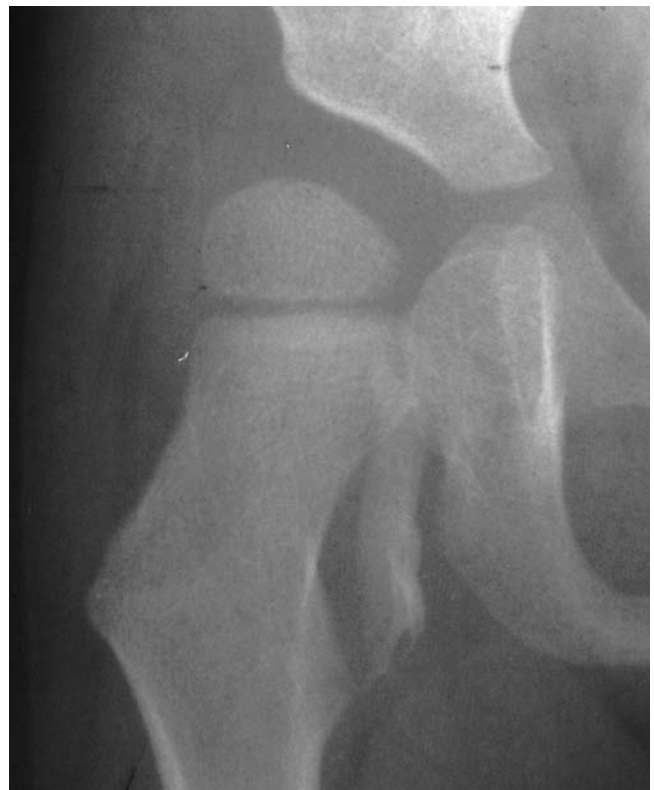

Figure C10.5.2

necrotic tissue, the wound may need to be packed with a Betadine-soaked dressing and these children returned to the operating room in 2 days for pack removal. As soon as the wound is clean, it can be tightly closed over suction drains and treated with intravenous antibiotics as indicated by the wound culture.

Hyperabduction

Hyperabduction deformities may form because of too much lengthening of the adductor or the addition of obturator neurectomy. If no abduction casting or orthoses are used, these deformities are extremely rare. If the hyperabduction deformities do become fixed, they may need to be treated with repeat surgical lengthening of the abductors or a varus osteotomy.

Reconstruction

Reconstructive treatment is required for those spastic hips whose secondary deformities are too severe for the body to recover without direct treatment. Reconstructive treatment is primarily directed at reducing the femoral head into the appropriate place in the acetabulum, followed by reconstruction of the acetabulum to correct its bony deformity. The goal of reconstruction is to leave children with an anatomically normal hip joint, with normal posture and normal range of motion. In this sense, reconstruction has the same goal as prevention treatment; however, reconstruction is a much more extensive surgical procedure with a longer rehabilitation. Using appropriate monitoring and screening, only one child of every four children who are treated with soft-tissue lengthenings will need reconstruction.

Indications for Reconstructive Treatment

The primary indication for reconstruction is any child whose hip has severe subluxation of greater than 60% or has a dislocated hip. Any child whose hip MP is greater than 40%, and who is over age 8 years, is also indicated for reconstructive treatment (Case 10.6). Reconstructive treatment should not be considered in children with very severe degenerative arthritis of the hip joint and a severe deformity of the femoral head. In general, the femoral head should be relatively round and the acetabulum should have a fairly good shape without an excessive amount of medial wall widening. Reconstruction works best for children who have severe subluxation or recent dislocation in whom the secondary acetabular deformity of excessive medial wall growth and of femoral head deformity has not occurred. For children with open tri-radiate cartilage and some thickening of the medial wall or femoral head deformity, reconstruction is still an option. This area is not very clearly defined and depends somewhat on the experience of the surgeon, the willingness of



Case 10.6 Shamika

Shamika, a 9-year-old girl with severe spastic quadriplegia and severe mental retardation, was brought to the clinic from a residential home where the caretakers felt she was having severe pain. They reported that if she did not move she would be quiet; however, any movement would cause her to cry out. She also cried when she sat. She was fed by gastrostomy tube, took medication to control seizures, and had chronic constipation. She had never had pneumonia. On physical examination she had good head control but could not prop-sit, she did not weight bear, and had mild scoliosis. The left hip lacked 20° to come to neutral abduction. The right hip abducted 70° but could not be brought to the neutral adduction. The popliteal angle on the left was 90° and on the right it was 60°. The feet were in severe planovalgus. On physical examination she cried with attempted left hip abduction and all attempts to sit, stand, or change her position. Radiographs were obtained

that demonstrated a dislocated left hip with moderate degenerative changes in the femoral head but a well-formed acetabulum. The hip clearly appeared to be the source of the pain, and the radiograph was consistent (Figure C10.6.1). A reconstruction was performed with an adductor lengthening on the left and bilateral femoral varus derotation shortening osteotomy with a peri-ilial pelvic osteotomy (Figure C10.6.2). She was mobilized immediately, and by 3 months all the preoperative pain had resolved. She was sitting all day and not crying with dressing and other position changes. At final follow-up at age 20 years, 11 years after reconstruction, the hips had symmetric range of motion with full extension and flexion, abduction to 20°, but rotation limited to 20° internally and 30° externally (Figure C10.6.3). No hip pain was present, and the hip appeared to have a nearly normal configuration.

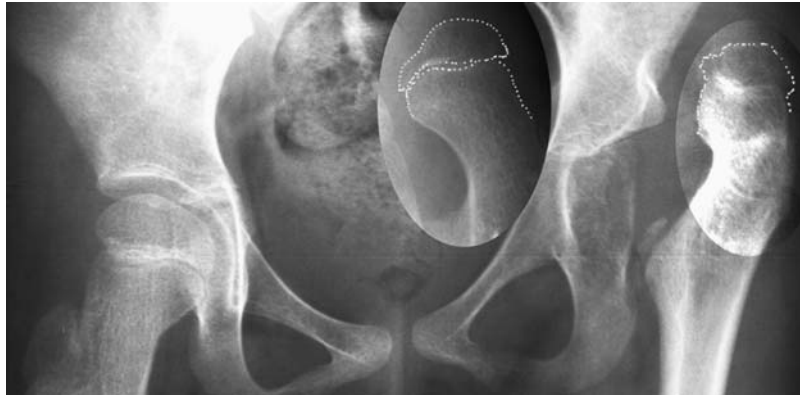

Figure C10.6.1

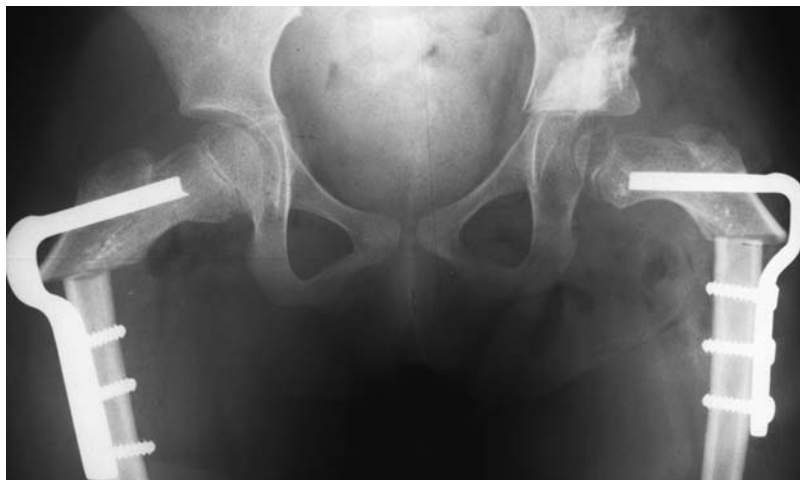

Figure C10.6.2

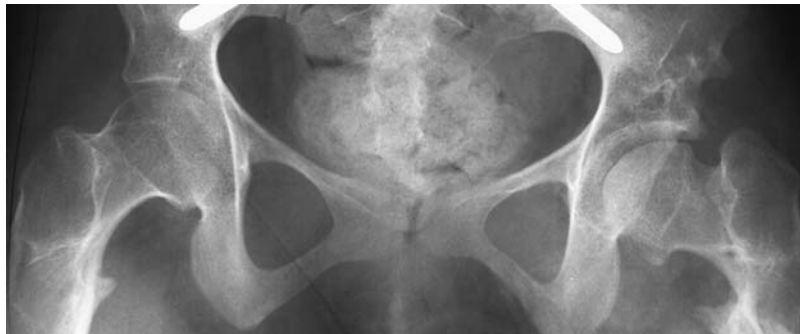

Figure C10.6.3

children and parents to risk failure, and the level of discomfort and function of the children. In general, younger children, between 6 and 12 years of age, who are having pain from a severely subluxated or dislocated hip can have the reconstructive treatment indications pushed harder because more remodeling capability remains (Case 10.7). Conversely, fully mature children with a substantial triangular-shaped femoral head have very little possibility of getting a good result from reconstruction because of limited ability for remodeling.



Case 10.7 Andrea

Andrea, a 15-year-old girl with a severe spastic diplegic pattern, presented with a complaint of severe pain in the right hip. She used to walk with a walker; however, her walking decreased related to both her increased size and the development of intermittent hip pain 3 years prior. One year prior she had undergone a dorsal rhizotomy because of increased hip pain. Following the rhizotomy, she had never been able to stand. She had mild mental retardation, fed herself, and was very clear that her hip hurt with almost any motion. On physical examination she was noted to be somewhat overweight at 70 kg and was extremely hesitant about all aspects of the examination. Because of this hesitation, good range-of-motion data could not be obtained; however, the left lower extremity had no spasticity and no apparent contractures. The right hip caused pain with motion but also had no spasticity. A radiograph showed the right hip to be dislocated with

moderate to severe arthritis; the left hip appeared to be normal (Figure C10.7.1). The growth plates were just closing. She had been sent as a second opinion from a physician who had recommended a proximal femoral resection. Her parents wanted to try to get her back to ambulating with a walker again and were very hesitant to have a resection. After an extensive discussion in which her parents stated that they were willing to risk a second operation if reconstruction failed, a reconstruction was performed. After the reconstruction, the hip subluxated inferiorly due to no muscle tone (Figure C10.7.2). However, immediate motion was pursued, and within 6 months, all the pain had resolved. By a 6-year follow-up at age 21 years, she had painless free motion of the hip except for very limited rotation (Figure C10.7.3). She still could not stand because of extreme weakness that persisted from the very aggressive dorsal rhizotomy.

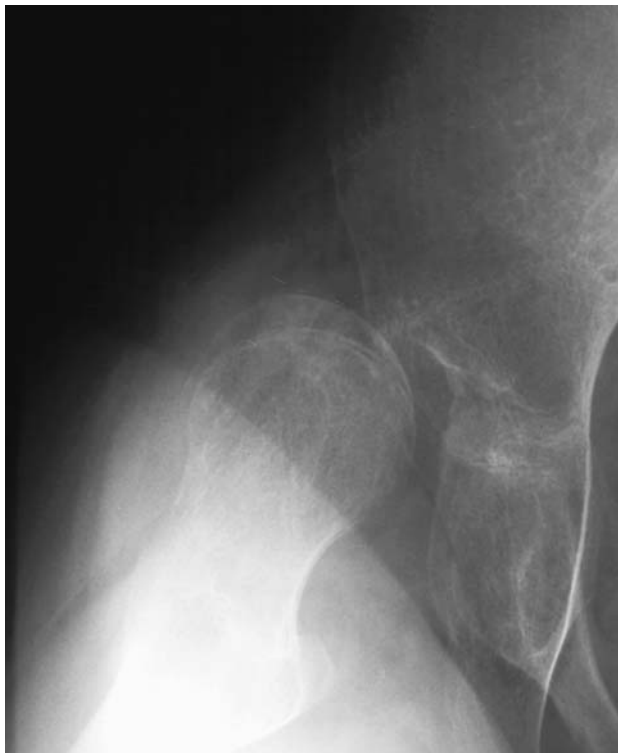

Figure C10.7.1

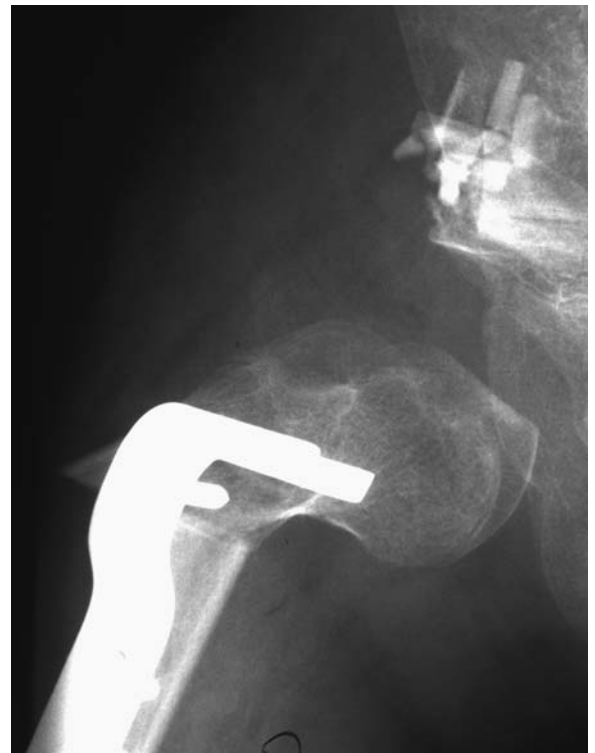

Figure C10.7.2

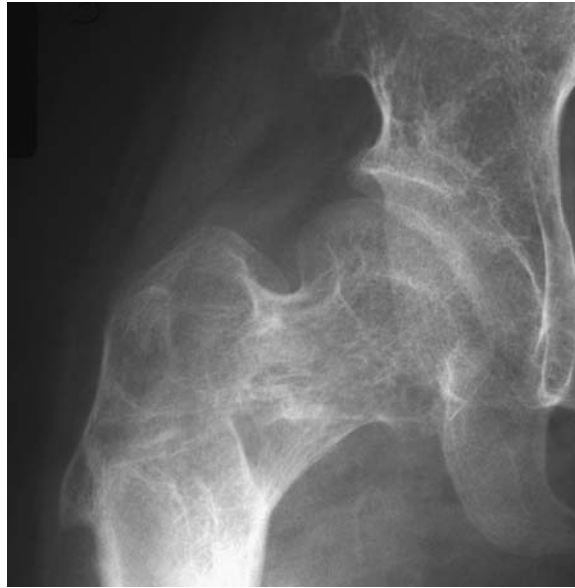

Figure C10.7.3

Recommended Treatment

Surgical reconstruction should include three major areas of the hip joint. First, it is important to correct the pathomechanics, which is the original etiology. The abnormal hip joint reactor force vector has to be corrected by adequate lengthening of the hip adductor muscles. The high-force environment that has caused this should be treated by adequate femoral shortening so that the hip joint is no longer under high force after reconstruction. The second major aspect of a reconstructive procedure is correction of the acetabular deformity, which is of such severity that it will not be able to remodel and needs to be corrected directly. The third major aspect of a reconstruction is making all attempts to leave children with symmetric movement of the hips and symmetric limb lengths.

The standard hip reconstruction involves open adductor lengthening, followed by a varus shortening derotational osteotomy of the femur and a reconstruction of the acetabulum using a peri-iliac acetabular osteotomy. The peri-iliac osteotomy and the Dega osteotomy are somewhat confusing, and the use of the Dega osteotomy for spastic hip disease was initially described as extending posteriorly into the sciatic notch.¹⁵ This sciatic notch approach has now been altered⁵⁶ so that the osteotomy is directed toward the posterior triradiate cartilage. The San Diego osteotomy continues to use the anterior approach to the hip capsule rather than the medial approach, which is advocated in the peri-iliac approach. Cast immobilization continues to be used after the pelvic osteotomy by some, as opposed to the immediate mobilization used after the peri-iliac osteotomy. However, outcomes of both procedures are very similar.

Outcome of Reconstruction Treatment

The outcome of reconstruction treatment is excellent and very predictable, as long as the indications are not pushed too hard in children who have closed growth plates and more severe degenerative arthritis and deformity (Case 10.6). Two centers have reported that 95% of hips should have an essentially normal reduction and function.^{13, 56} This reconstruction is a one-

time procedure with results that last a lifetime. Range of motion continues to be excellent, with hip flexion more than 90° near full extension in almost all patients and abduction of at least 20° or 30°. Many children will have some limitation of hip internal and external rotation and some children will develop progressive, recurrent hip adduction contractures. As these adduction contractures develop, it is important to not let them become very severe because there is a tendency for windblown deformities to develop in adolescence. These early windblown deformities are more easily treated with recurrent soft-tissue lengthenings than by waiting for them to become too severe.

Pain was a major problem for some children before reconstruction. In 18 patients, there were 23 painful hips before reconstruction, and of these 23 hips, 1 child continued to have some discomfort requiring occasional analgesia at a final follow-up of more than 2 years, and 1 hip failed at 9 months, requiring reconstruction.¹³ Therefore, the treatment of painful dislocated hip has a 90% success rate. Both these hips that continued to have pain were hips in which the triradiate cartilage was closed and the indication for this procedure was pushed a little beyond its limit.

Other Reconstructive Treatment Options

There have been many reports^{8, 25, 57} that suggest using varus osteotomy plus adductor lengthening in the treatment of hip subluxation. All these reports, however, report 20% to 30% failure rates and none has very clear inclusion criteria. The failures are almost all redislocations. Some of these reports use the archaic pins and plaster technique for doing hip osteotomies, which tends to leave children with severe torsional malalignments as one hip goes into internal rotation and the other hip into external rotation.²⁵ Varus osteotomy alone to address hip subluxation yields similar outcomes as hip adductor lengthening in children who meet very stringent criteria. These children must be young, less than 8 years of age, have a hip subluxation that is less than 40%, and have a normal sourcil or a type I sourcil of the acetabulum. However, if these criteria are not met, the long-term failure rate of varus osteotomy alone is high, using the criteria of success as less than 25% migration index with a normal acetabulum (Cases 10.8, 10.9). Under these rigid criteria of good outcome by which reconstructive procedures are assessed, the failure rate for varus osteotomy would be 70% or 80%. Based on these data and understanding, a varus osteotomy should not be performed without a concomitant acetabular procedure in any child who does not meet the criteria of being less than 8 years, having less than 40% migration index, and having a normal sourcil at the acetabulum. The major indication for using varus osteotomy alone in the reconstructive procedure is doing varus shortening derotational osteotomy of a limb to bring symmetry to patients who do not have hip subluxation. This procedure should be done on the normal side in almost all unilateral hip subluxations of patients undergoing full reconstruction, especially in those who have any degree of abduction contracture or windblown deformity. If the varus osteotomy is not done to treat the abducted hip, the reconstructed hip will very quickly be driven into adduction and a recurrent adduction contracture will develop.

Other Pelvic Osteotomies

Many other pelvic osteotomies have been used for doing reconstruction. The Pemberton osteotomy is an osteotomy that extends into the ilium to the triradiate cartilage as well, but it hinges the osteotomy on the transverse arm of the triradiate cartilage rather than the anteroposterior arm of the triradiate cartilage (Figure 10.7). This osteotomy therefore opens the pelvic cut at exactly 90° anterior to the peri-ilial osteotomy described here. The



Case 10.8 Jose

Jose, a 5-year-old boy with severe spastic diplegia, could do some walking with a walker. His mother was most concerned about the slow progress with his walking ability and his feet crossing over. On physical examination he had hip abduction of 20° on each side, 90° of internal rotation, and no external rotation of the hips. Popliteal angles were 60° bilaterally. A radiograph demonstrated bilateral hip subluxation of 90% on the right and 80% on the left (Figure C10.8.1). It was decided that he should have a femoral varus derotation osteotomy, adductor lengthening, and distal hamstring lengthening (Figure C10.8.2). Following surgery, he was slow to regain his walking ability, and by 1 year after surgery, his left leg was again

becoming adducted and internally rotated. The radiograph showed subluxation (Figure C10.8.3). This subluxation was monitored for 2 more years, with more severe subluxation present (Figure C10.8.4), then was reconstructed. However, not enough acetabular coverage could be obtained because of a widened triradiate cartilage (Figure C10.8.5), and he again subluxated, and developed hip pain at age 13 years (Figure C10.8.6). He developed a severe windblown deformity. In retrospect, this very poor outcome started with the poor decision to avoid reconstruction of the acetabulum at age 5 years and was secondarily followed by an inadequate reconstruction at the acetabular reconstruction.

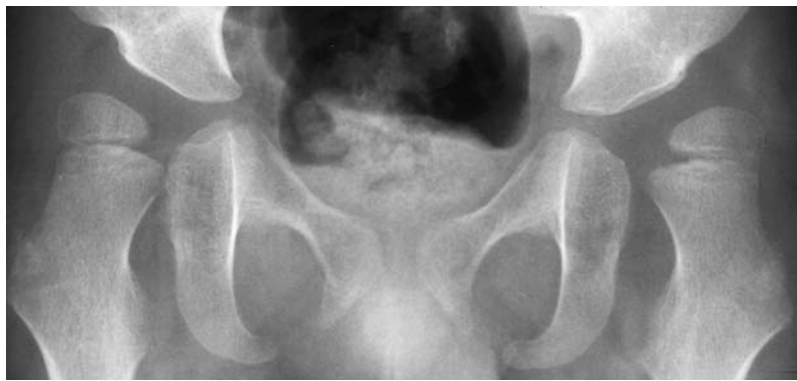

Figure C10.8.1

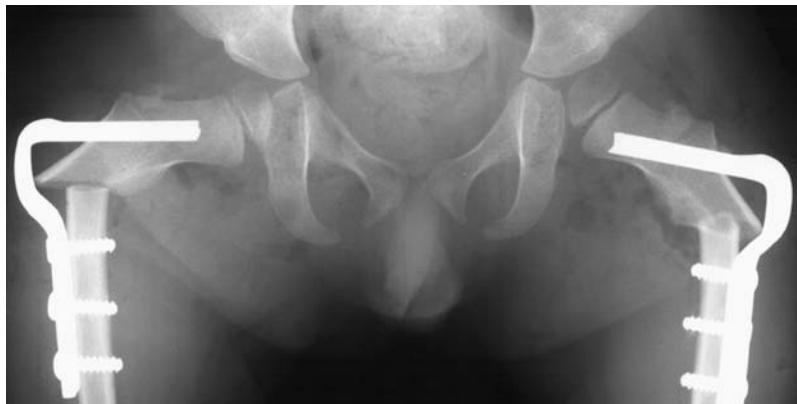

Figure C10.8.2

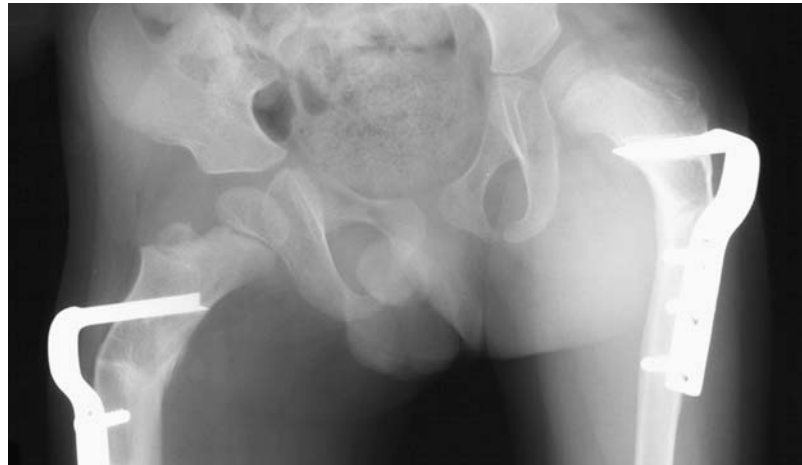

Figure C10.8.3

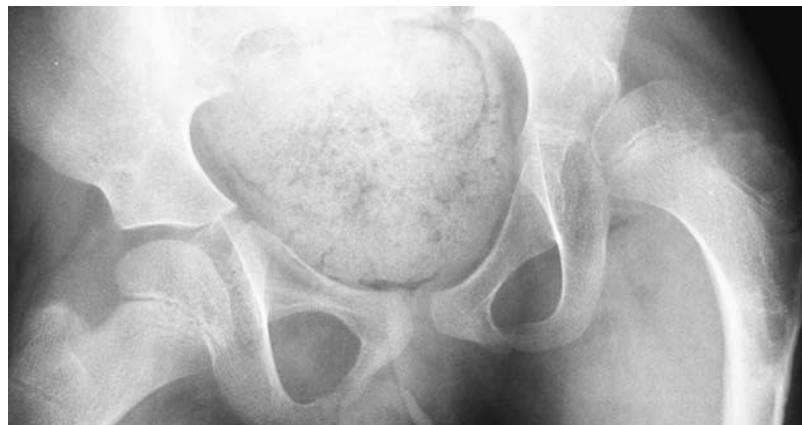

Figure C10.8.4

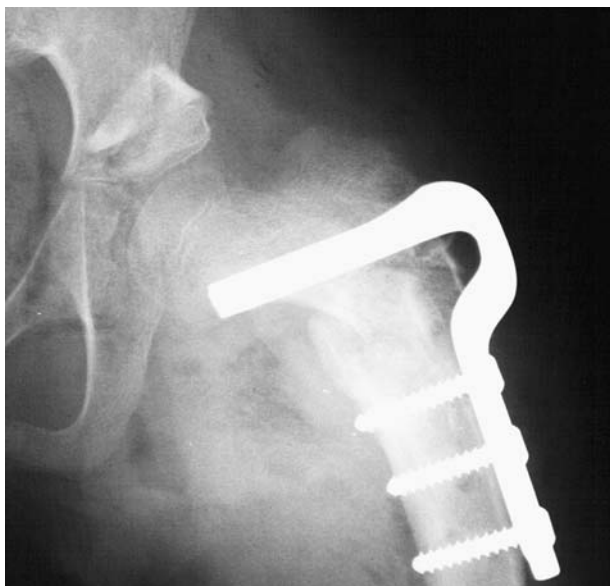

Figure C10.8.5

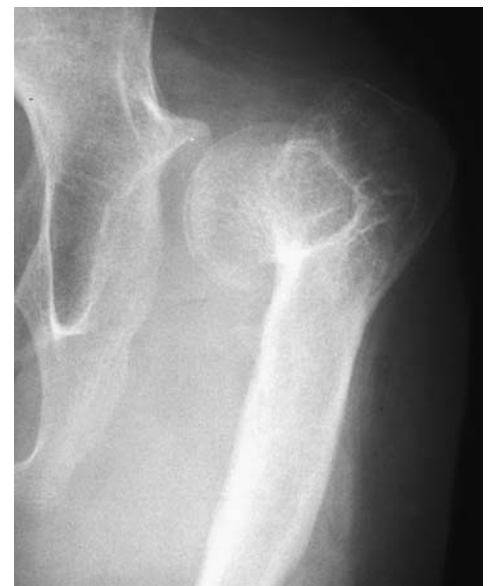

Figure C10.8.6



Case 10.9 Brittany



Brittany, a 6-year-old girl with a moderate quadriplegia, could feed herself, had some speech, and had moderate mental retardation but no ambulatory ability. Her mother was concerned about her crossing-over legs. Physical examination demonstrated hip abduction limited to 15° bilaterally and a 45° popliteal angle. Radiographs of the hip demonstrated severe hip subluxation (Figure C10.9.1). She had lengthening of the hip adductors and femoral derotation osteotomies. Initially, at 1 year after surgery (Figure C10.9.2), and by the 5-year follow-up, the hips looked very good (Figure C10.9.3). However, by 8 years of follow-up, she had developed a severe adduction and

hip flexion contracture with intermittent pain in the left hip (Figures C10.9.4, C10.9.5). An aggressive adductor lengthening was then performed; however, during anesthesia the hip could be felt to be subluxating posterolaterally. Although the positioning improved (Figure C10.9.6), the pain did not, and she required a reconstruction that stabilized her hip (Figure C10.9.7), and all pain was resolved. By 3 years after the reconstruction, she is pain free with an excellent range of motion (Figure C10.9.8). The addition of the pelvic osteotomy at the time of the initial varus osteotomy at age 7 years most likely would have avoided the need for adolescent surgery.

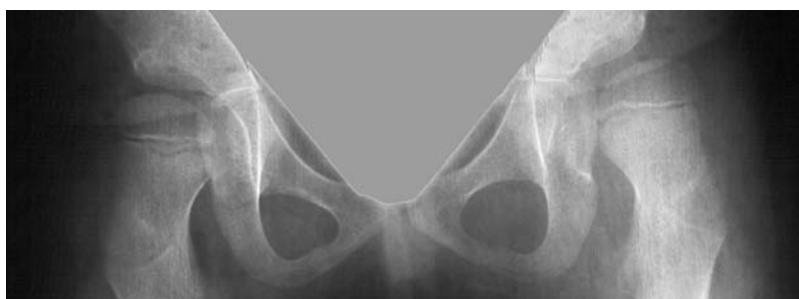

Figure C10.9.1

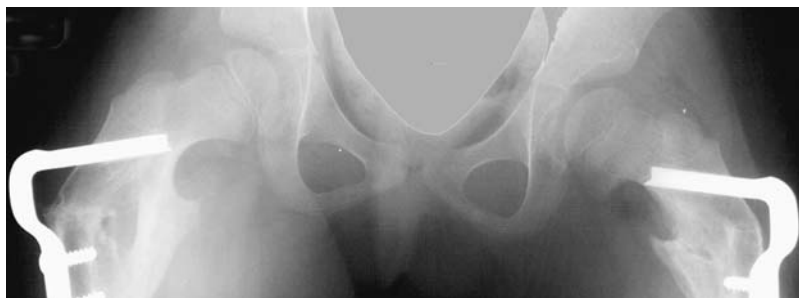

Figure C10.9.2

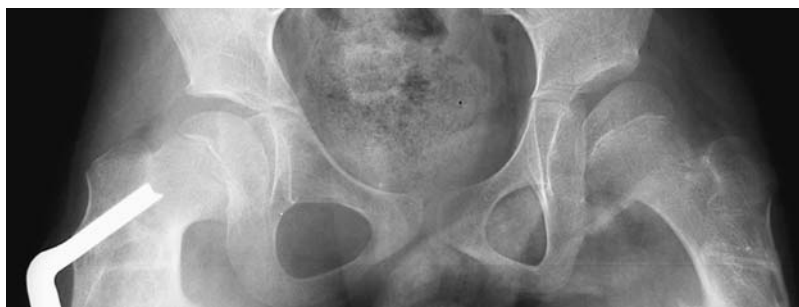

Figure C10.9.3

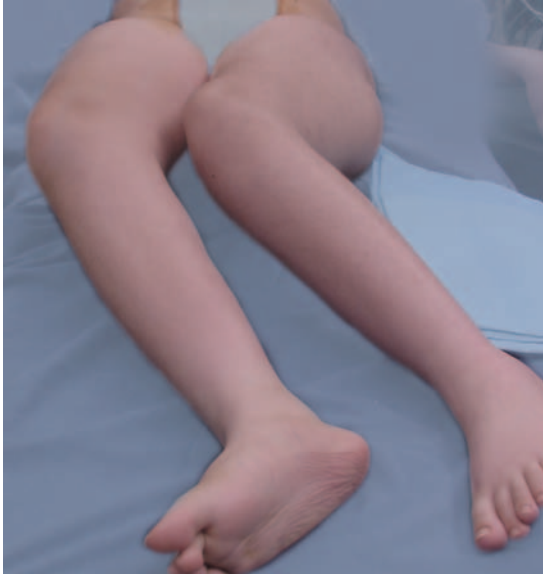

Figure C10.9.4

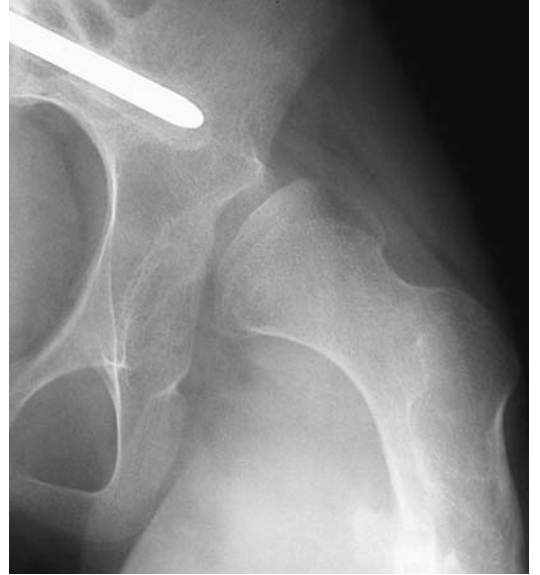

Figure C10.9.5

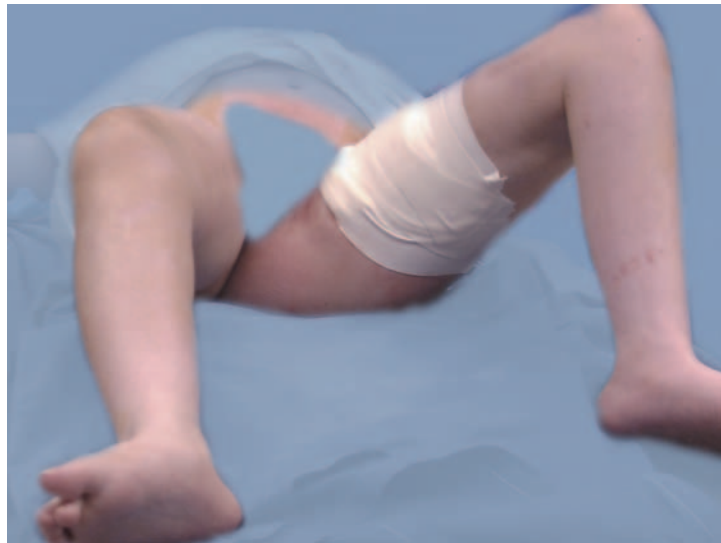

Figure C10.9.6

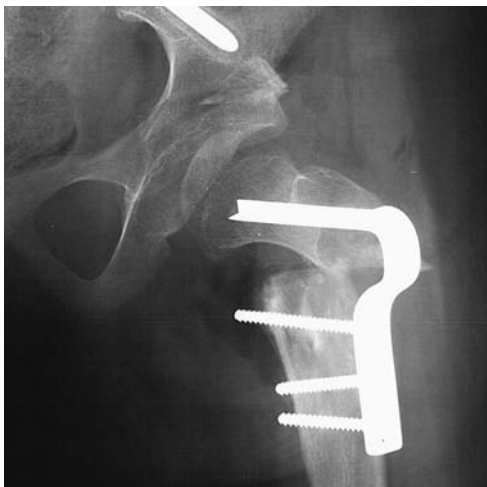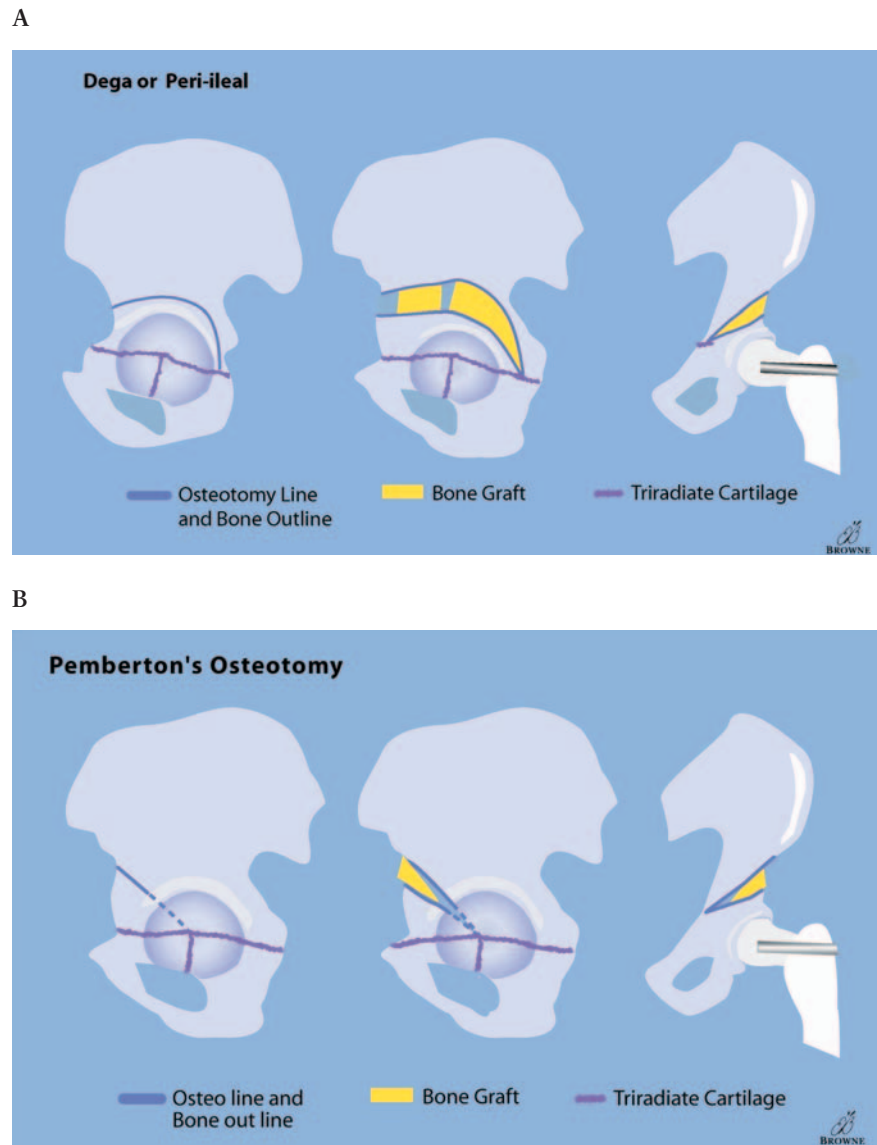


Figure C10.9.7

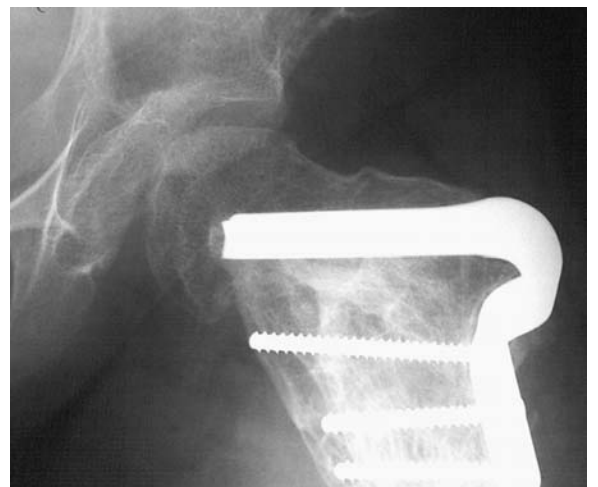

Figure C10.9.8

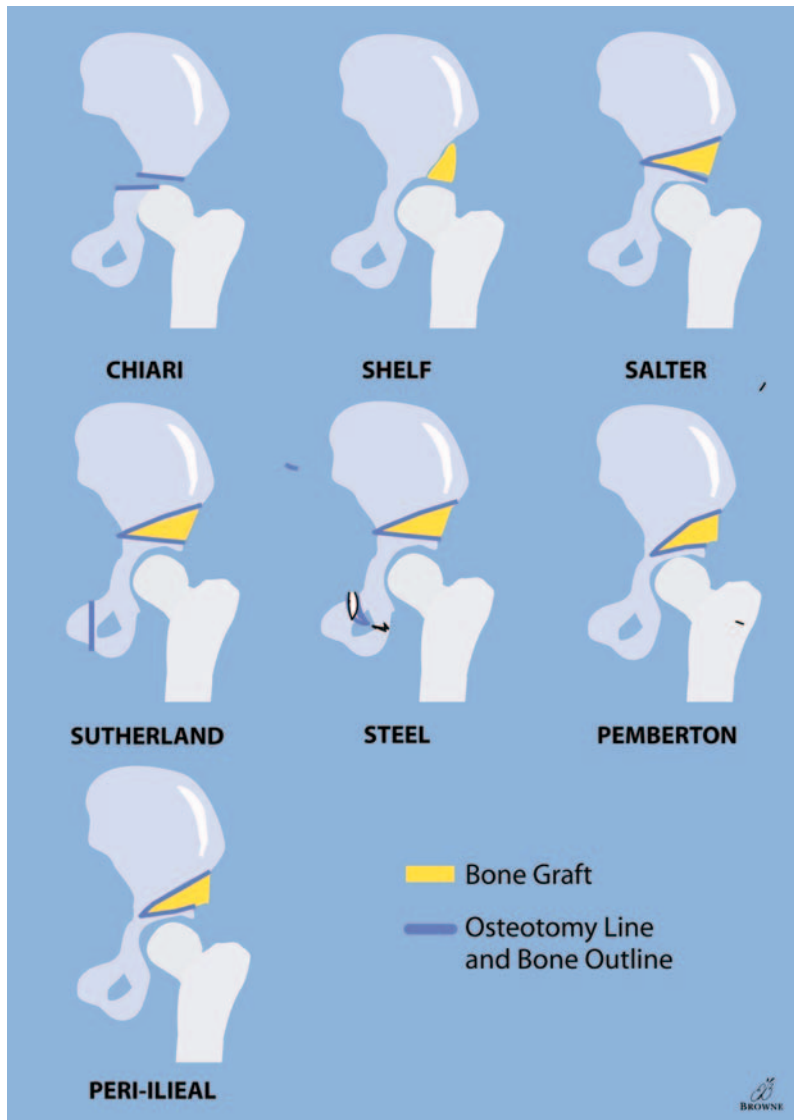
Figure 10.7. The pelvic osteotomy that most directly provides the correction of the acetabular deficiency present in the typical posterosuperior hip dislocation is the peri-ileal osteotomy, which hinges on the antero-posterior limb of the triradiate cartilage. The cut extends to the posterior border of the triradiate cartilage (A). For a rare anterior-deficient acetabulum, usually seen with an anterior hip dislocation, Pemberton's pelvic osteotomy is most appropriate. This osteotomy is hinged on the transverse or medial lateral limb of the triradiate cartilage. This osteotomy provides excellent anterior coverage but poor posterosuperior coverage (B). Other osteotomies have all been described for use in spastic hips; however, the published experience is minimal or poor for all other types (C).



Pemberton osteotomy is the primary procedure for use in anterior acetabular dysplasia present in anterior hip dislocations. The Pemberton osteotomy has been reportedly used for typical posterosuperior dislocations,^{58, 59} for which 95% and 100% good outcomes, respectively, were reported. However, both these reports provide rather poor quantitative data with one article⁵⁸ not even reporting the MP and neither precisely defining what procedure they were doing except to say that it was a Pemberton osteotomy. The difference between the peri-ileal osteotomy and the Pemberton osteotomy is one of only a small angle degree; therefore, the small angulation differences in many individuals may not be that important. Likewise, it has been somewhat difficult to determine whether Dega extended the osteotomy into the sciatic notch or the triradiate cartilage. In a fairly detailed report by Dega near the end of his career,⁶⁰ he gives a good description of the osteotomy, which extends into the sciatic notch as was detailed by Mubarak et al.¹⁵ The peri-ileal osteotomy has been developed by extending the posterior cut away from the sciatic notch and into the posterior limb of the triradiate cartilage, which provides a more posterior and inferior opening of the osteotomy. Although

C

Figure 10.7 (continued).



the difference between the peri-iliac osteotomy, the Dega osteotomy, and Pemberton osteotomy is primarily one of direction and of unclear significance, trying to focus the best coverage onto the area where there is the greatest dysplasia is important. Based on this review of the peri-iliac, Dega, and Pemberton osteotomies, the classic Pemberton osteotomy in which there is only an anterior opening will result in more posterior dislocations if pushed to the limit for children with severe posterosuperior dysplasia.

Shelf acetabular arthroplasty has also been reported specifically for children with CP,^{61, 62} but again these reports provide very poor information as to exactly what were the indication criteria and their failure criteria. Range of motion and pain are mainly used in these reports for defining failure, but in spite of this, there is a high variability of failure with successes reported at 69%, 90%, and 80%, all of which are lower than all the peri-iliac or Dega osteotomy reports. The problem with the shelf acetabular arthroplasty is dislocation posterior to the shelf arthroplasty, which therefore removes the capability for the acetabulum to allow itself to remodel and to continue to

grow. Shelf acetabular arthroplasty clearly should not be done in children who have not reached adolescence. This procedure may have an occasional place as an augmentation to a peri-iliac osteotomy, but it is important to be careful to avoid too much dissection or adding too large a graft, as there have been two case reports of autofusion after shelf arthroplasty in spastic children.^{63, 64} Also, an excellent shelf may be present on a radiograph, but the hip is dislocated out posterior and superior to the anterior shelf (Case 10.10).

Several reports promote Chiari pelvic osteotomy⁶⁵⁻⁶⁷; however, these same authors report failures from either pain or redislocation in approximately 20% of patients. This failure rate is clearly much higher than the peri-iliac osteotomy reports (Case 10.11). The Chiari pelvic osteotomy may have a limited role in adults with painful hip subluxation and severe degenerative arthritis in whom the goal is to avoid total hip replacement, at least temporarily.⁶⁶

The Salter redirection osteotomy is specifically not recommended by Salter himself for children with CP. Other authors have reported using the Salter osteotomy for children with CP⁶⁸⁻⁷⁰; however, none of these reports allows any actual assessment of the role of this procedure and the outcomes. This procedure is contraindicated in children with spasticity because it not only provides coverage in the wrong location, but it provides that coverage by taking it from the area where these children have the most deficient acetabulum.

Steel⁷¹ reports that his triple pelvic osteotomy has many failures in children with CP. Good results were reported in a small series^{69, 72}; however, these papers provide few data to support the optimistic view. This procedure is not recommended in children or adults with CP because the prime deformity is a mostly posterior, opened-up acetabulum, which is difficult to address with this procedure. Furthermore, it is difficult to provide rigid fixation allowing immediate motion without the use of spica cast immobilization with this procedure.



Case 10.10 Alyssa

Alyssa, an 8-year-old girl with spastic quadriplegia, was initially seen in the CP clinic as a second opinion because her parents felt her left hip was causing her pain. She was noncommunicative, a dependent sitter, was actively being treated for renal failure due to a familial kidney condition not related to the CP, and had seizures that were controlled with dilantin. She was fed orally but could not feed independently. She had undergone a hip reconstruction 2 years previously but had never been very comfortable since the cast was removed. Further specifics concerning the procedure were not available. On physical examination her left hip was fixed in 20° of adduction and the hip motion caused her to cry. Flexion to 90° was present, but extension was limited to -40°. The right hip had an abduction contracture of 30° and had not had previous surgery. The radiograph showed a posterolateral hip dis-

location with a proximal femur, which had had a varus osteotomy, and a very prolonged lesser trochanter (Figure C10.10.1). This was felt to represent the residual effects of a shelf acetabuloplasty, with a hip that dislocated behind the shelf. The femoral head had a moderate degree of degenerative changes, but she still had wide-open growth plates. The hip was reconstructed using the standard pelvic osteotomy and adductor lengthening on the left with a bilateral femoral shortening osteotomy (Figure C10.10.2). The hip has done well over a 6-year follow-up period until she was at skeletal maturity (Figure C10.10.3). This case shows how difficult it is to get the shelf posterior to avoid the hip dislocating out the back of the joint. This is also a poor plan because the abducted right hip was not addressed and the adductors were not lengthened.

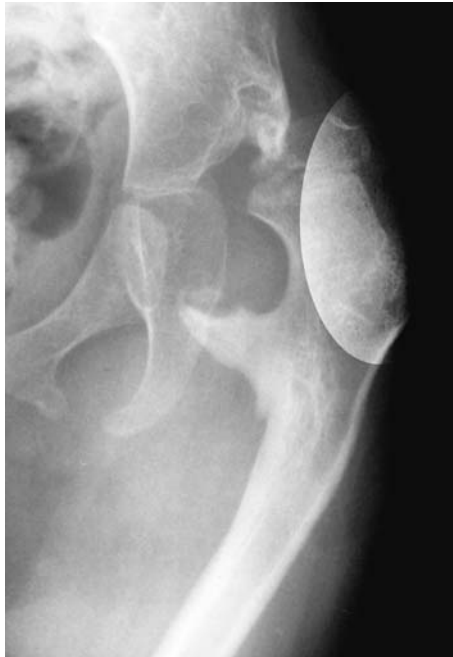

Figure C10.10.1

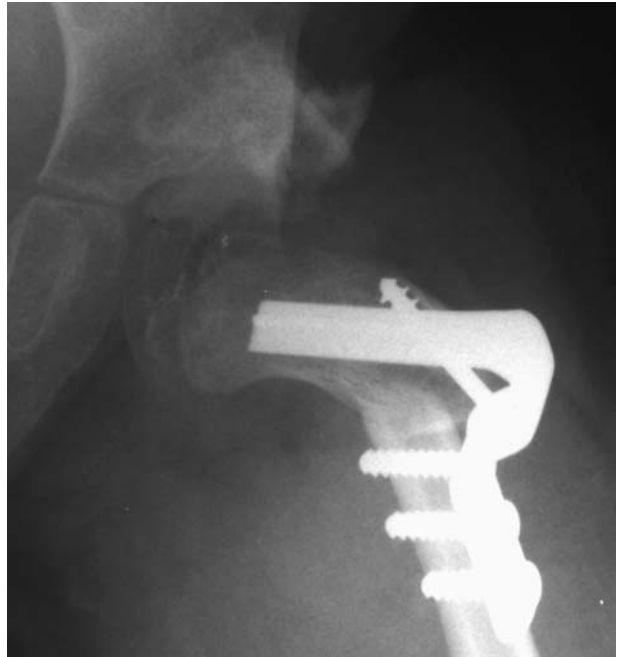

Figure C10.10.2

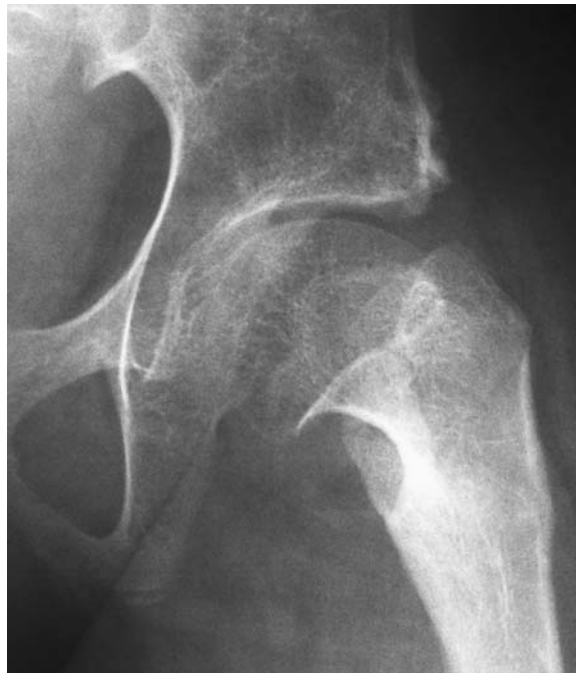

Figure C10.10.3

Complications of Reconstruction

The primary and most frequent complication after reconstructive procedures is the development of a wound infection at the site of the varus osteotomy (Case 10.12). If a deep wound infection occurs, the wound needs to be opened, packed with antibiotic dressings, and treated with oral antibiotics if



Case 10.11 Antwain

Antwain, a 15-year-old boy with spastic diplegia, was an independent ambulator who presented to the CP clinic with the complaint of pain in the right hip. Over the past 3 years, he had gradually noticed the onset of this pain, and now it was limiting him so that he had a hard time getting through the school day, and he did not want to go out with friends. He was in the 10th grade in a regular high school and was totally independent in all activities of daily living. His right hip had full flexion, extension to -20° , abduction only to neutral, and had pain with forced abduction. Popliteal angles were 60° . Radiographs demonstrated marginally open growth plates, a normal left hip, and a right hip with dislocation and severe acetabular

dysplasia (Figure C10.11.1). He had a Chiari osteotomy and slowly was able to return to walking, so at age 20 years he again walked independently but complained of problems when he sat and pain when he walked long distances. Physical examination showed only 20° of flexion from -10° of extension. There was no motion in rotation or abduction or adduction. Radiographs showed a severely degenerative hip (Figure C10.11.2). This case shows the relatively poor outcome of Chiari osteotomy in an adolescent with spasticity. Antwain would have been better off with a fusion because he functioned like a hip fusion but still had the pain of an arthritic hip.

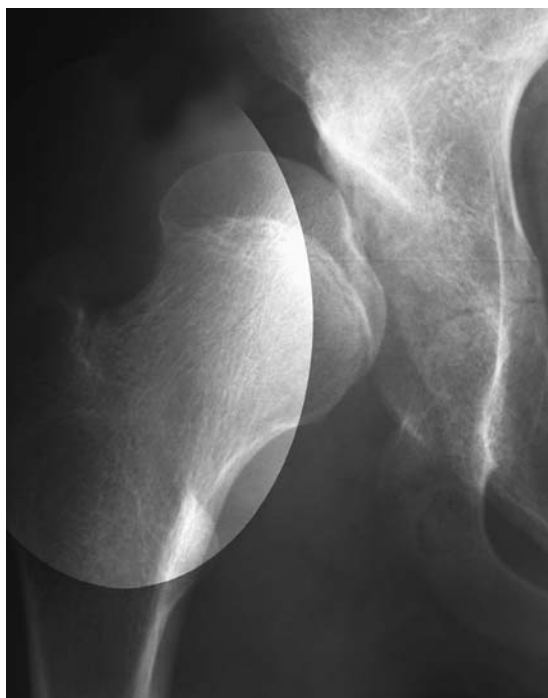


Figure C10.11.1

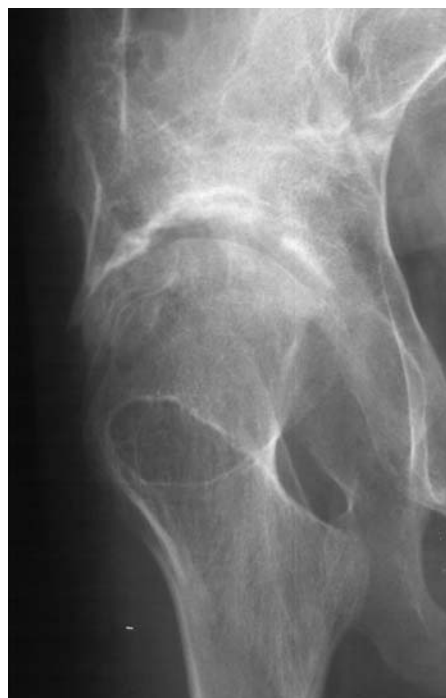

Figure C10.11.2

children are not febrile. Dressing changes are performed twice daily, and as soon as there is no cellulitis present, oral antibiotic treatment can be discontinued, 10 to 14 days after initiation. Local wound care is continued, allowing the wound to remain open or granulate closed until the osteotomy is healed. Adductor wound infections are treated as previously noted and the pelvic osteotomy site has an extremely low infection rate, as we have never seen a deep wound infection in the pelvic osteotomy site. Infections in the



Case 10.12 Derek

Derek, a 12-year-old boy with spastic quadriplegia, had a reconstruction of the right hip with an adductor lengthening, peri-iliac pelvic osteotomy, and femoral osteotomy. Postoperatively, he did well and was discharged home with his mother on postoperative day 6. On postoperative day 18, his mother called to say that he had a temperature of 39.8°C, was refusing to eat, and seemed to have pain in the hip. He was brought in for a clinical examination, which showed a femoral osteotomy wound with erythema and seropurulent drainage. The other wounds were dry and without erythema. Radiographs demonstrated no change and the white blood cell count was 15,300. The wound was gently palpated and noted to open easily down to the plate. A culture swab was sent for culture, the wound was packed with betadine-soaked gauze, and he was admitted and started on cephalothin. In 24 hours, the culture showed a growth of *Staphylococcus aureus* sensitive to the cephalosporin. After 2 days in the hospital he was afebrile; his mother was taught to do wound packing dressing changes twice a day and he was discharged home to continue with oral antibiotics and dressing changes. At an outpatient visit in 1 week the wound was clear of purulent drainage and the dressing

was changed to a betadine wet to dry dressing. The antibiotics were continued for 1 more week. Four weeks after discharge, the wound was showing signs of closing with granulation tissue that bled with each dressing change (Figure C10.12). The dressing was now switched to being changed once a day. By 2 months following discharge only a small 1-cm opening persisted, which drained fluid that looked like synovial fluid, with the plate being completely covered. Dressing changes were changed to dry dressings and changed as needed. The drainage varied from day to day, but by 4 months after the initial infection, he still had a persistent drainage at least every other day. His mother felt he was somewhat uncomfortable with motion of his hip. The radiograph showed complete union of the osteotomy and he was scheduled for removal of the hardware. Following plate removal, he had 5 days of intravenous antibiotic then was discharged home on another 10-day course of oral antibiotics. The wound was primarily closed except for a small area where the previous drainage been present, and this was covered by a dry dressing sponge after being initially packed with a betadine-soaked sponge. After 3 weeks, the entire wound was healed without drainage. All motion of his hip was now pain free.

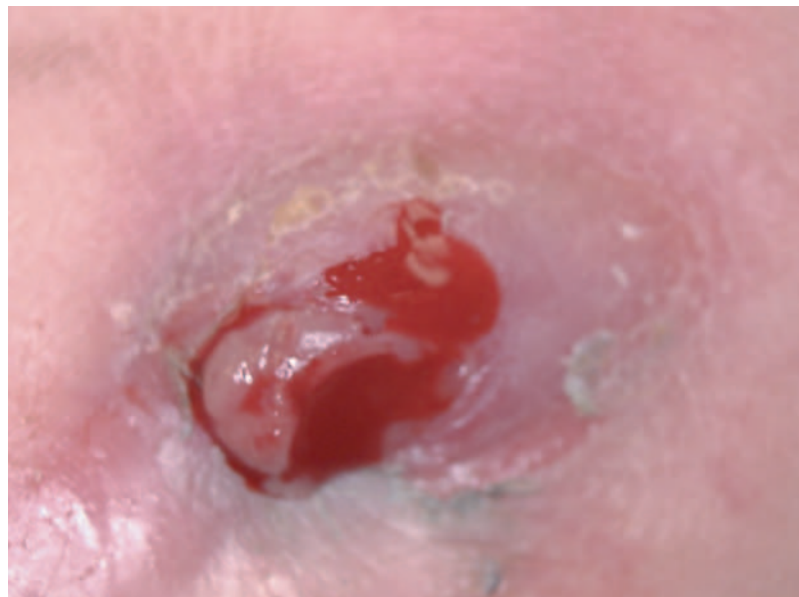

Figure C10.12

pelvic osteotomy site, however, should be treated with open irrigation and packing, followed by possible secondary closure.

Loss of Fixation

Loss of fixation of the plate or fracture of the proximal bone may occur, and this usually needs to be corrected with repeat open reduction and the addition of more screws or a wire. If it is difficult to gain solid fixation, cast immobilization occasionally does need to be used.

Repeat Early Dislocation

Repeat early dislocation occurs primarily in individuals who are being treated for hypotonic hip disease or who have overlying paralysis with spasticity. There are children in whom the limit of reconstruction has been stretched because of a severe femoral head deformity and also acetabular deformity. The surgeon will decide to do a repeat open reduction if it may increase stabilization, or leave the hip alone, gaining range of motion. If the hips are symptomatic, the surgeon will proceed to salvage treatment (Case 10.13).



Case 10.13 Samantha

Samantha, a 10-year-old girl with severe quadriplegia, presented with a complaint of severe hip adduction that made perineal care difficult. With forced abduction, the hips were also painful. She had severe mental retardation and was completely dependent in all her care needs. Physical examination confirmed the history. A radiograph demonstrated bilateral hip dislocation with severe acetabular dysplasia and widening of the triradiate cartilage (Figure C10.13.1). Bilateral reconstruction was performed with adductor lengthening, femoral shortening varus osteotomy, and peri-ilial pelvic osteotomy. It was very difficult to obtain intraoperative stability of the hip joint, especially on the left side. In the immediate postoperative period, both

hips remained in good position (Figure C10.13.2). At the follow-up visit at 4 weeks after surgery, her mother noted the left hip seemed shorter and did not abduct as much as the right side. A radiograph showed the left side to have dislocated again (Figure C10.13.3). Considering the difficulty in gaining stability during the reconstruction, it was believed that a repeat attempt would not be any more successful. Therefore, after discussion with the family, it was elected to leave the hip dislocated. Over a 6-year follow-up, the hip remained pain free and with adequate range of motion to allow easy sitting, lying, and perineal care. In spite of the repeat dislocation, her mother still felt the surgery was successful.

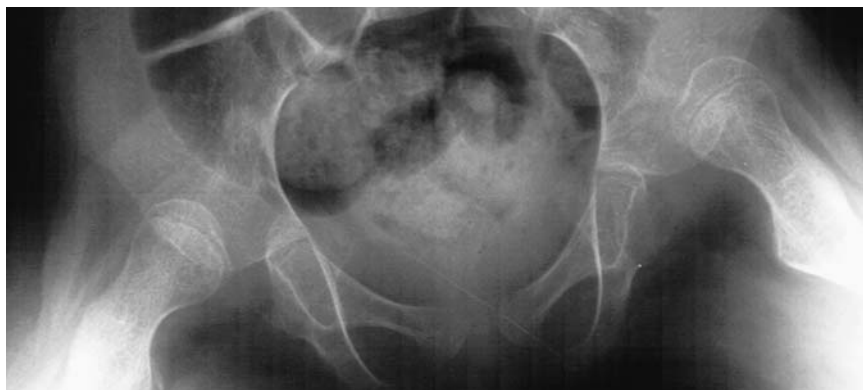

Figure C10.13.1

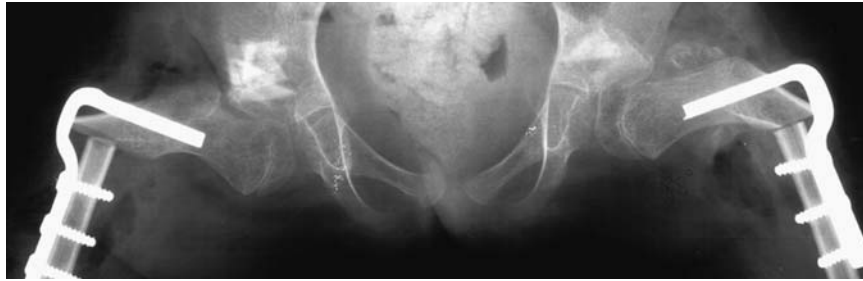

Figure C10.13.2

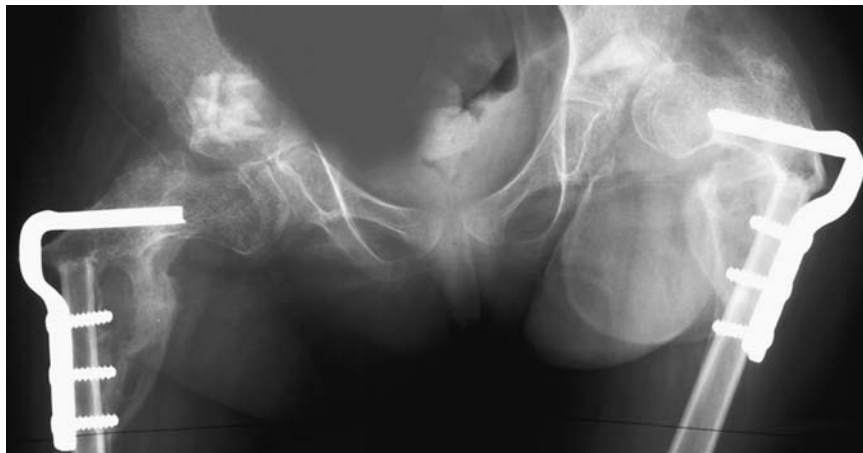

Figure C10.13.3

Heterotopic Ossification

The development of heterotopic ossification is usually noted when there is a persistently high level of pain. This ossification may occur with exuberant callus formation and sometimes occurs as pericapsular ossification (Case 10.14).

Sleep Problems

The postoperative pain sometimes causes children to develop very poor sleep patterns, become depressed, and lose their appetite. This pain should be treated using a standard postoperative protocol that depends primarily on antidepressants, such as amitriptyline hydrochloride (Elavil).

Prolonged Hip Pain

Prolonged pain in the hip joint may occur because of degenerative arthritis, which can be treated using a steroid injection protocol. If the pain is persistent after three steroid injections, additional palliative treatment should be considered (Case 10.15).

Avascular Necrosis

Avascular necrosis following reconstruction has not been encountered at our facility in any patient; however, it has been reported.⁵⁶ Avascular necrosis may be due to either the anterior approach to the hip capsule or more likely, to immobilization in casts, which puts increased pressure on the hip joint. Treatment of the avascular necrosis should be with gentle range of



Case 10.14 Henri

Henri, an 18-year-old boy, had a reconstruction for a dislocated hip. A good, stable hip was obtained; however, he continued with significant pain with range of motion even at the 6-month follow-up. Radiographs at this time demonstrated periacetabular ossification (Figure C10.14.1). He was injected with deposteroid several times over the next 6 months and gradually had a decrease

in his pain, although at the 18-month follow-up he was still uncomfortable with full hip extension and hip rotation. The heterotopic ossification had matured (Figure C10.14.2). Often, this ossification slowly resolves over the 6- to 18-month period following surgery, although this has not happened in this boy.

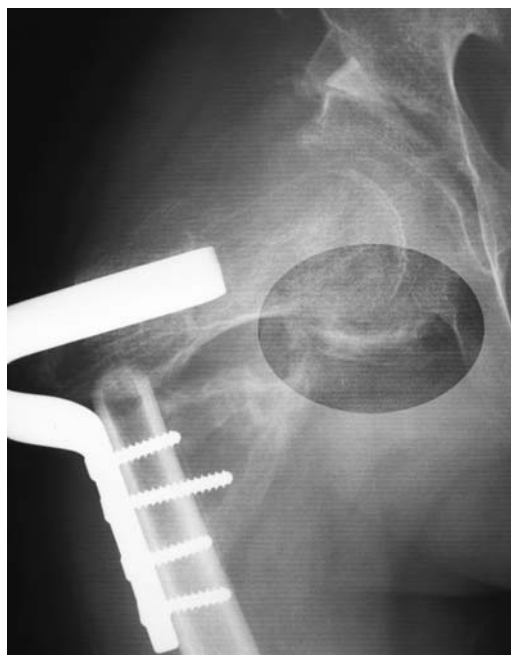

Figure C10.14.1

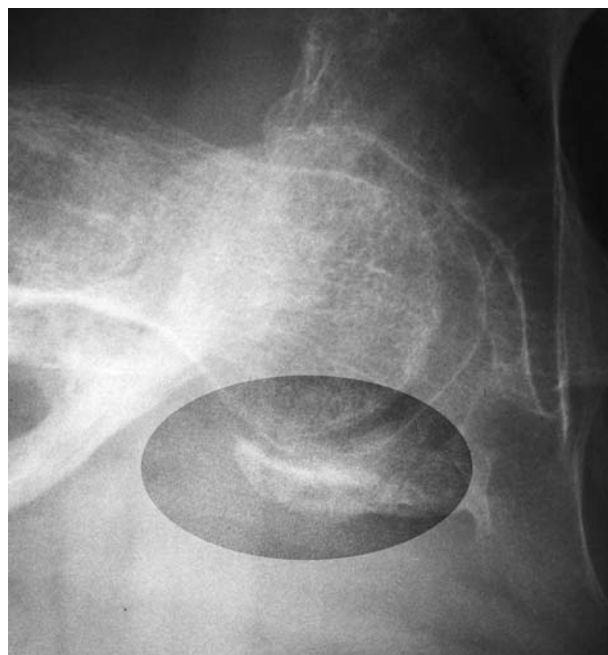

Figure C10.14.2

motion, and then after its resolution, it will need to be addressed with the residual remaining deformity.

Intraarticular Extension of Pelvic Osteotomy

Osteotomy extending into the acetabulum is sometimes done intentionally, especially in a child with a closed triradiate cartilage, because it is not possible otherwise to open the wedge. If this extension should occur inadvertently, it usually does not cause any long-term problems, and it is important to start and continue to work on the range of motion immediately postoperatively.

Other

Premature closure of the triradiate cartilage has not been reported with either the periliacal osteotomy or the Pemberton osteotomy in children with CP.



Case 10.15 Aaron

Aaron, an 11-year-old boy with a severe spastic quadriplegia, had increased problems with sitting. His parents did not feel that he had much pain; however, dressing and bathing were getting more difficult as he had severe adduction deformities. He was orally fed and had seizures that were well controlled by medication. He had severe mental retardation. On physical examination he was noted to have severe upper extremity spasticity, and the hips could not be brought to neutral abduction on either side. Hip flexion was to 100° and popliteal angles were 70° . Radiographs of both hips showed completely dislocated hips with a more dysplastic acetabulum on the right (Figure C10.15.1). He underwent bilateral adductor lengthening, varus derotation osteotomy, and peri-iliac pelvic osteotomy. His recovery went well for the first month, but his parents noted that he slept and ate very poorly due to continued hip pain. He was then started on amitriptyline hydrochloride, 25 mg in the evening. After 4 weeks, he slept and ate a little better so the amitriptyline was increased to 50 mg per night. After 3 months, he ate and slept well; however, he had not tolerated therapy. Specif-

ically, he tolerated hip range of motion very poorly. After a 3-week rest from therapy, another attempt at therapy caused severe pain. At 4 months after surgery, a radiograph showed a well-healed osteotomy, but there was erosion on the medial side of the joint on the right side where the growth plate had caused a ridge to form in the acetabulum (Figure C10.15.2). The pain was believed to be caused by degenerative arthritis from the incongruent hip joint. The hip joint was then injected with deposteroid and gentle range of motion was again started. After 2 weeks, he tolerated hip motion somewhat better. A second injection was given 1 month after the first and the pain continued to improve; finally, by 1 year after surgery, the hip plate was also removed to make sure it was not causing pain. The erosions were still there, although the pain was greatly decreased (Figure C10.15.3). Over the next year he became completely pain free, and by the 5-year follow-up, the hip remodeled almost completely so he had excellent flexion motion, 30° of abduction, and 20° of adduction, but he still continued to have only 20° of total rotation (Figure C10.15.4). The excellent remodeling is typical of hips in children with open growth plates, and the steroid injections seem to decrease the inflammation and allow this remodeling to continue.

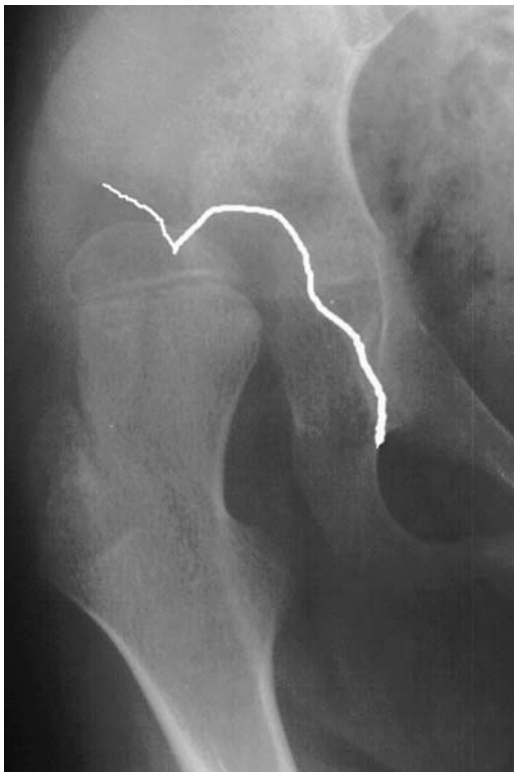

Figure C10.15.1

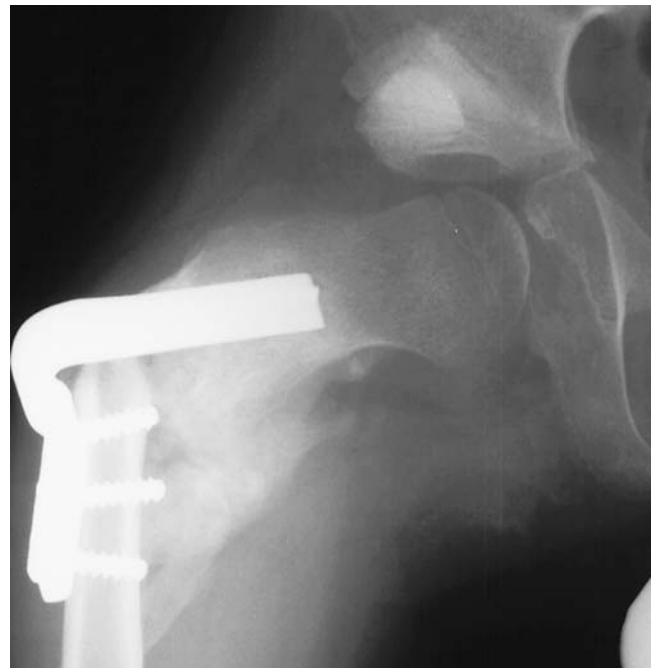

Figure C10.15.2

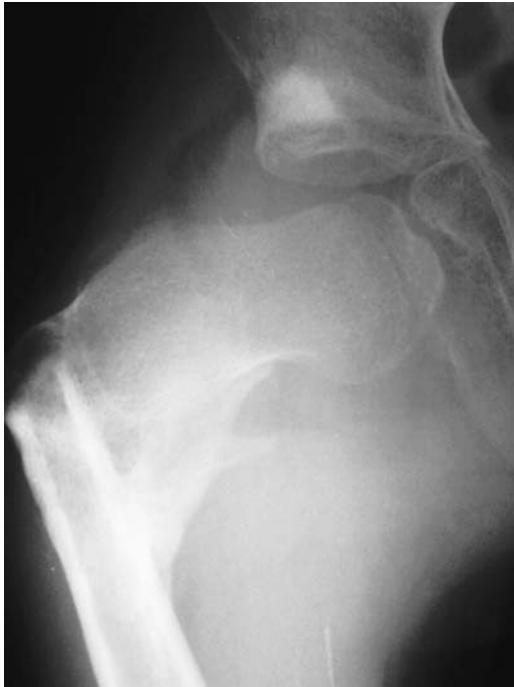

Figure C10.15.3

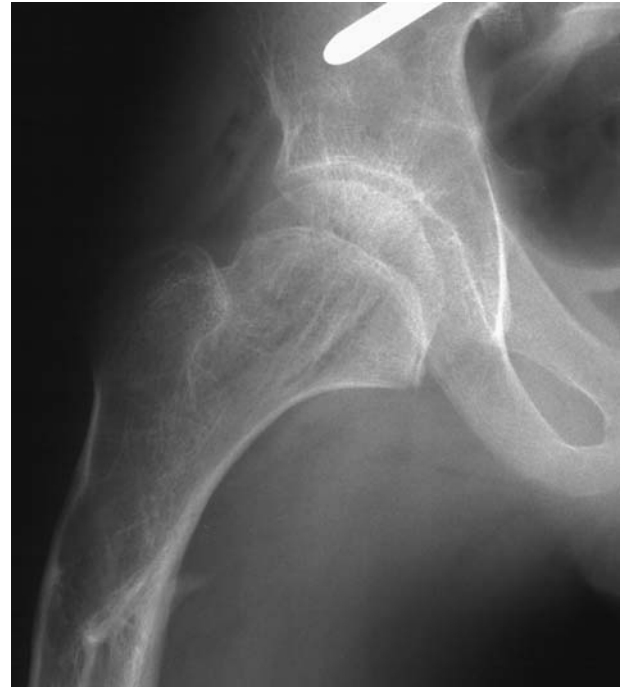

Figure C10.15.4

Prominent hardware, especially the blade plate on the lateral side, may become tender. This plate should be removed if it continues to be tender after the osteotomy has healed or if it continues to create wound breakdown.

Fractures during rehabilitation are most common at the distal femur and proximal tibia and have a much higher incidence in those children treated with casts. These fractures need to be treated appropriately, without trying to immobilize them for too long.

Palliative Treatment

Hips that have failed reconstruction, continue to be painful, and have other substantial limitations are clearly indicated for palliative treatment in which the goals are quite different. The goals of palliative treatment are to do a resection procedure of the severely deformed joint to remove the source of pain and/or improve the function or range of motion. In general, the primary goal of palliative treatment is relieving children of the pain being generated by the dislocated hip. The secondary goals of the palliative treatment are to improve children's function by either making the hip joint stable or increasing the range of motion to improve their sitting or walking function (Case 10.16). When adults or teenagers first present with painful, dislocated, and degenerated hips, the hips should first be treated similar to degenerative arthritic joints in elderly individuals. The initial line of treatment should focus on decreasing the stress on the joint by decreasing the range of motion and physical therapy, and stopping standing or any other activity to put the joint to rest temporarily. At the same time, children should be treated with a therapeutic dose of antiinflammatory. If the pain does not resolve rapidly, or if it recurs on two or three occasions within a short period of time, surgical treatment is indicated.



Case 10.16 Daphne

A 14-year-old girl, Daphne, presented with severe spastic quadriplegia and severe mental retardation and was a totally dependent sitter. Her mother noted some problems with sitting. Physical examination demonstrated -20° of abduction and flexion to 90° with mild scoliosis. Radiographs of the hip showed a dislocated hip with significant degenerative changes in the femoral head (Figure C10.16.1). The right hip had previous surgery and was pain free but had no motion, being fixed in 20° of abduction and 40° of flexion. Because there was no evidence of pain, sitting adjustments, including opening the seat-to-back angle to accommodate the fused right hip and a good chest lateral, were ordered. This change worked well for 2 years until she developed severe scoliosis and required a spinal fusion. The left hip was still pain free at the time of the spine fusion but had increased deformity

of both sides of the hip joint (Figure C10.16.2). Four months following the spine surgery, severe pain developed in the left hip making sitting impossible, as well as making all care related to dressing, bathing, and toileting very uncomfortable with constant crying. After a discussion of the high risk of failure with her mother, the hip was reconstructed with muscle lengthening, varus osteotomy, and peri-iliac pelvic osteotomy (Figure C10.16.3). By 9 months postoperatively, she was still in severe pain and all attempts with medication treatment and steroid injections were of no help. She then had an interposition arthroplasty, and within 4 weeks she was pain free and able to sit (Figure 10.16.4). In retrospect, this case with almost a fully mature hip had too much deformity to expect a reconstruction to work. She should have had an interposition arthroplasty immediately.

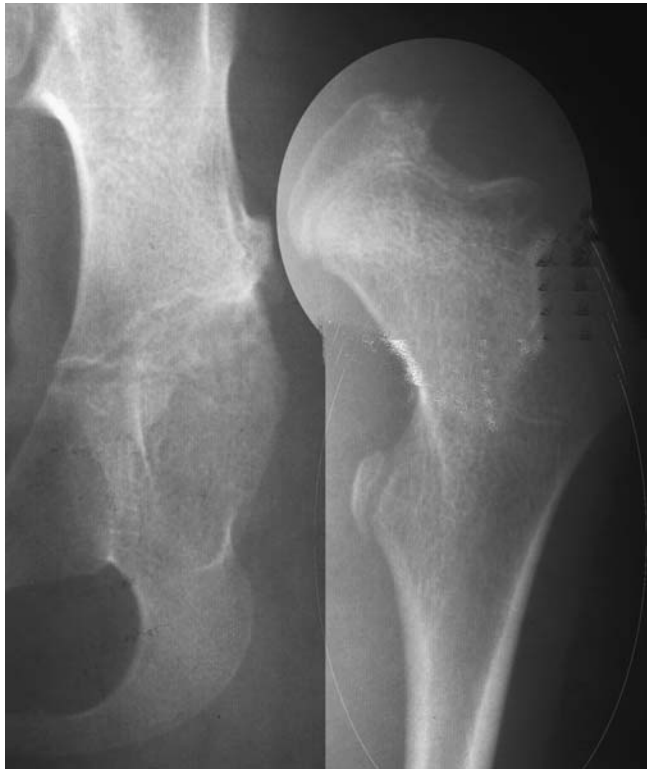

Figure C10.16.1

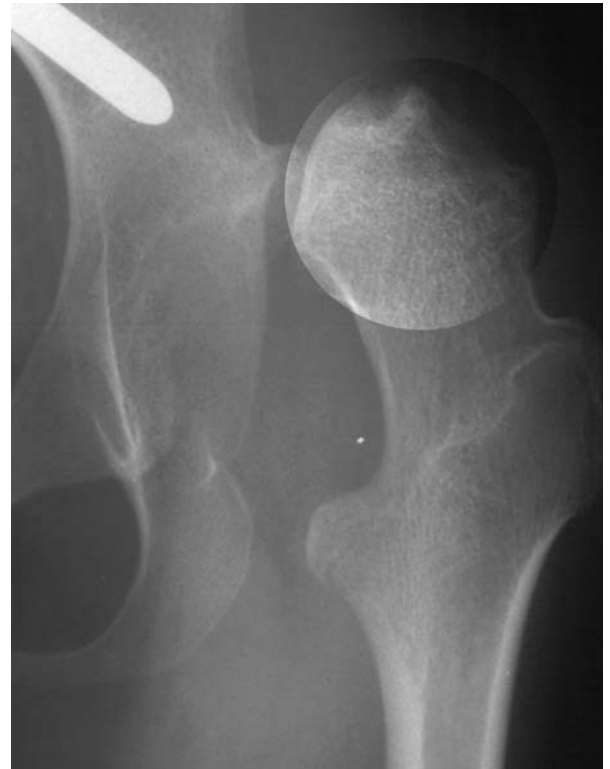

Figure C10.16.2

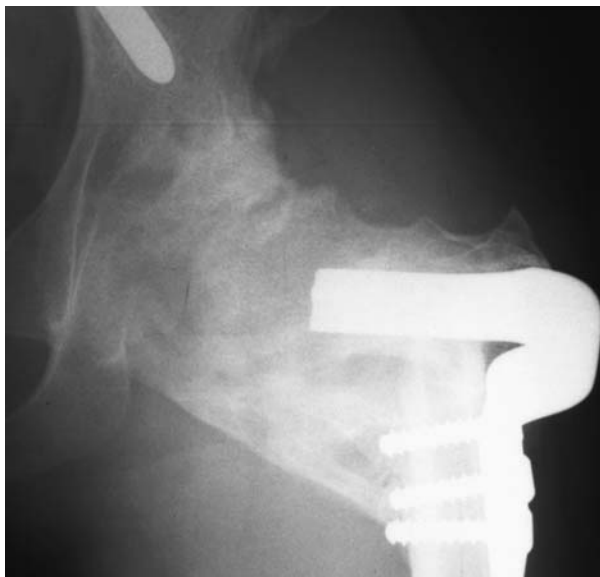

Figure C10.16.3

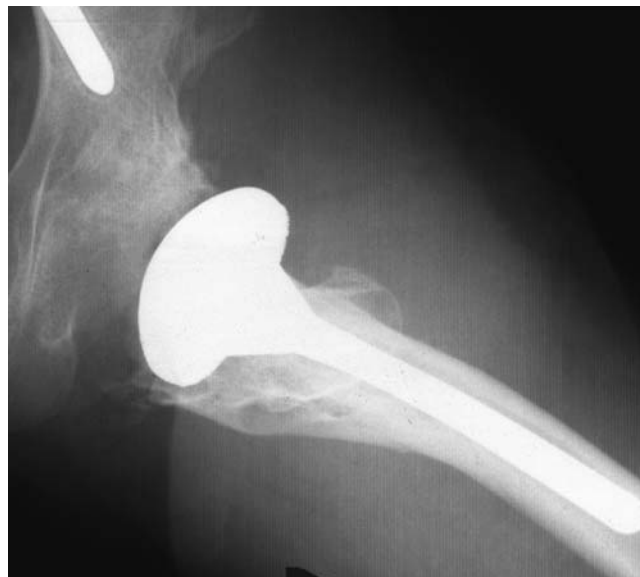

Figure C10.16.4

Recommended Treatment

The recommended treatment is based largely on children's function and somewhat on their size and general health.

Total Hip Replacement

For children, adolescents, or adults who are able to stand and bear weight for transfers or household ambulation, and definitely for individuals who are community ambulators, the primary palliative treatment should be a total hip replacement using a standard, commercially available hip prosthesis if the bones are large enough. This procedure provides the best stable joint, and in adults or young adults, it can be done with acceptable risk. Many reports (totaling 68 patients) in the literature⁷³⁻⁷⁷ all conclude that the major complication of total hip replacement is the risk of dislocation. Some authors suggest routine use of postoperative spica cast immobilization. Excellent long-term prosthesis survival, with 95% survival at 10 years, has been reported although two prostheses required revision for loosening and malrotation.⁷³ When doing a standard total hip replacement, short-leg casts with broomsticks between them should be used to avoid hip flexion, internal rotation, and adduction. This position is the primary cause of hip dislocation and tends to be a position most individuals who have spastic hip dislocation want to go into when they have pain or discomfort. If the hip prosthesis tends to be very unstable, then the use of a single-leg spica for 4 to 6 weeks may be indicated. If patients dislocate the hip, and the hip can be reduced closed, a single-leg spica cast may be used for 4 weeks to maintain the reduction until some fibrous healing occurs (Case 10.17). If children had previous hip surgery and have developed any degree of heterotopic ossification, postoperative radiation is recommended; generally 600 rads of radiation as a single dose on postoperative day 1 or 2, or two doses of radiation, 400 rads each, on postoperative days 2 and 3, are given.

Interposition Arthroplasty

If children have open growth plates, or are adolescents who weigh more than 20 or 25 kg but are totally nonweight bearing, an interposition arthroplasty using a standard shoulder prosthesis is recommended (Case 10.18). The shoulder prosthesis serves as a spacer between the bone ends. It is not



Case 10.17 Qu Ran

Qu Ran, a 17-year-old boy with mental retardation and diplegia, presented with the caretaker's complaint that he refused to walk and had become wheelchair bound over the past 6 months. Before this, he was a community ambulator. A dislocated left hip was believed to be the etiology of the pain, which caused him to stop walking (Figure C10.17.1). He had a total hip replacement, which was stable immediately following surgery (Figure C10.17.2). However, 3 weeks after discharge, his caretaker brought

him back to the clinic with the complaint that he seemed to have more pain in the past 24 hours. A radiograph showed a dislocated hip (Figure C10.17.3). The hip was reduced closed and he was placed in a single leg spica for 1 month. Six months after he was removed from the spica, he was again walking in the community, although he had significant limitation of hip motion with only 60° of flexion, full extension, no rotation, and only 20° of abduction (Figure C10.17.4).

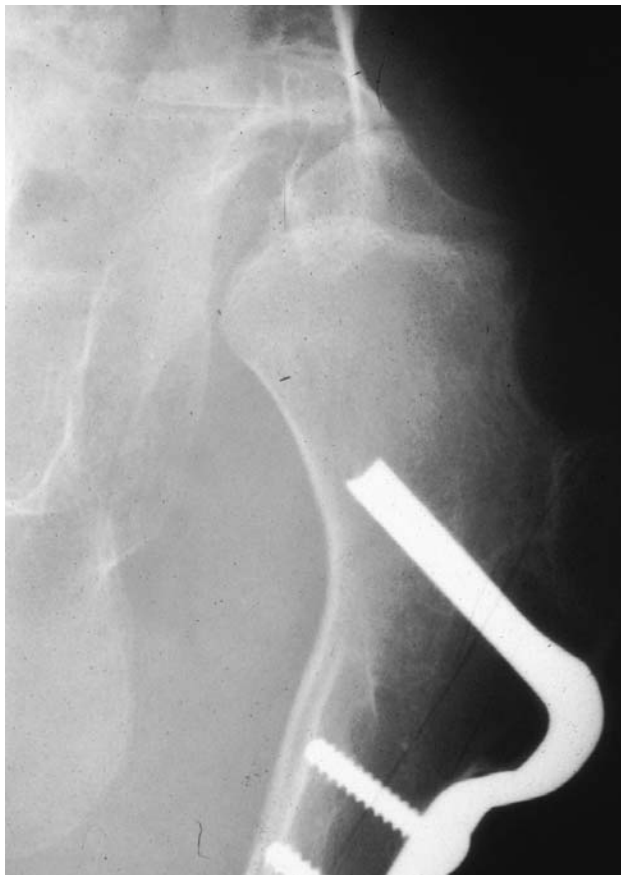

Figure C10.17.1

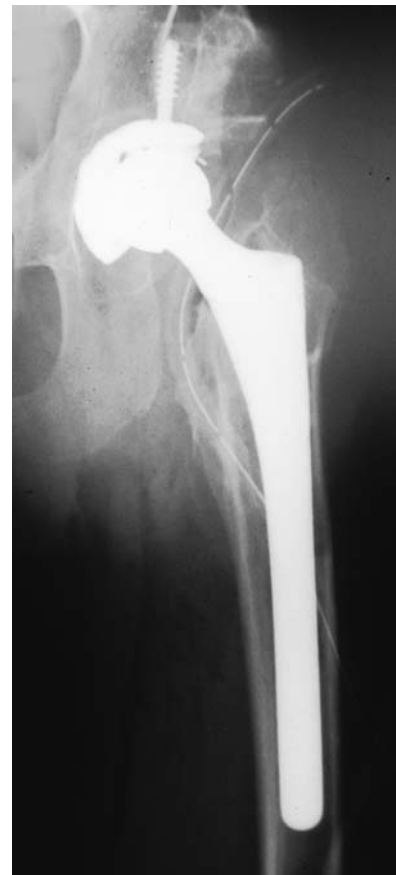

Figure C10.17.2

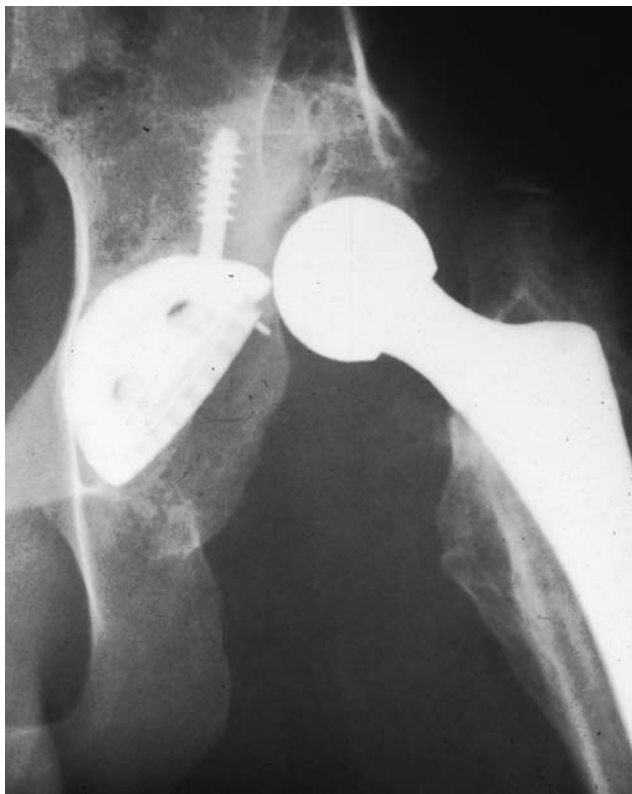


Figure C10.17.3

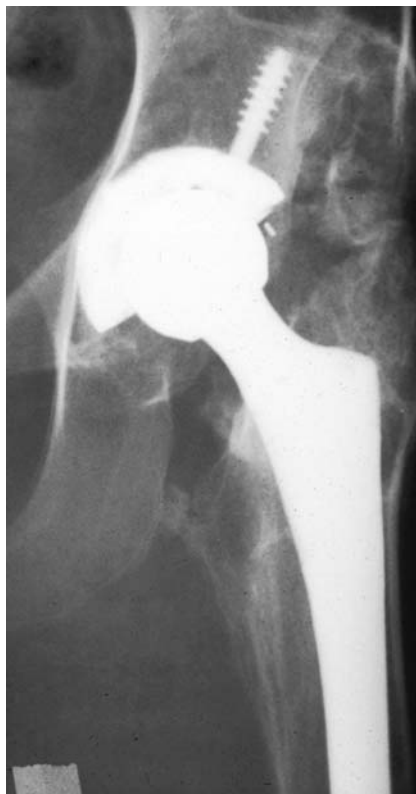

Figure C10.17.4

crucial that the prosthesis remain in a reduced position, although an attempt is made during the operative procedure to suture soft tissue around it to hold it in the false acetabulum or real acetabulum. If there is raw bone exposed in the acetabulum, a glenoid component is placed to cover this raw bone. Postoperatively, these patients can be maintained in an abduction pillow, or can be placed in the short-leg cast with broomsticks and then gotten up into a wheelchair if there are concerns about severe spasticity. These patients tend to be quite comfortable quickly and there is no need for prolonged traction. The results of this procedure have demonstrated good pain relief that is more quickly acquired than with the femoral resection.⁷⁸ Other interposition materials to consider are covering the end of the femur with methyl methacrylate or, alternatively, designing a femoral prosthesis that just makes a cap on the end of the femur (Case 10.19). The cost of these custom prostheses is two to three times higher than the off-the-shelf shoulder prostheses because they are custom made, and they do not work any better or worse.

Resection Arthroplasty

If children are very small, weighing less than 20 or 25 kg, and especially if they have open decubitus ulcers or are otherwise in very poor health, the primary procedure to consider is a subtrochanteric resection or Castle procedure.^{79, 80} This procedure is performed by choosing a resection level at the level of the ischium and then resecting the whole proximal femur, trying to resect the bone of the femur in the muscle plane and not in the subperiosteal plane. A sleeve of the rectus femoris and vastus lateralis is then sewn over the end of the proximal femur to provide a cover and to try to make a soft-tissue



Case 10.18 Randall

Randall, a 16-year-old boy with severe quadriplegia who was nonweight bearing, presented for a second opinion because he had developed a severe painful dislocated hip. One year prior, he had undergone a femoral head and neck resection. Although he seemed to get some pain relief after the initial surgical pain decreased, as soon as his ac-

tivity increased to sitting all day, his hip pain had become more severe than ever (Figure C10.18.1). After considering all the options, he underwent an interposition arthroplasty with a shoulder prosthesis, and he was pain free within 4 weeks and has remained pain free for 10 years (Figure C10.18.2).

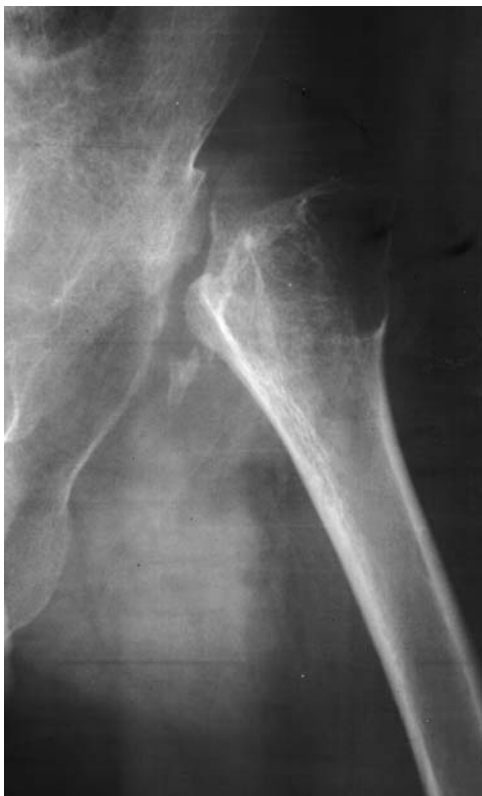

Figure C10.18.1

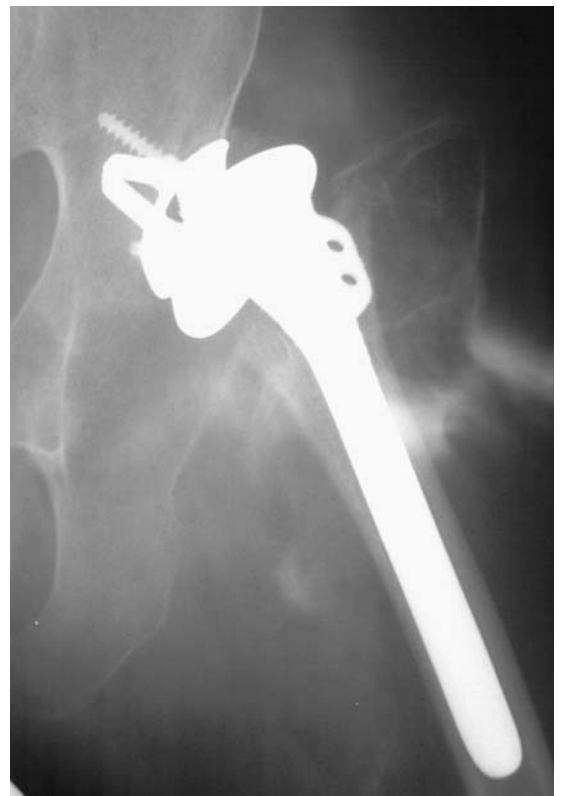

Figure C10.18.2

interposition preventing the end of the femur from contacting the acetabulum (Case 10.20). Generally, it is recommended that these individuals be maintained in distraction traction for 6 weeks to allow the soft-tissue interposition to heal and stabilize this resection. We have also performed this procedure in a very small child using short-leg casts with broomsticks. There have also been reports using external fixators to hold these resections. It is important to notify the parents or caretakers that this procedure takes 6 to 9 months to obtain relief of pain.⁸¹ Therefore, there should be no expectation of immediate pain relief, and there is almost never immediate pain relief except when the children are in traction. In the long term, not all these children will become pain free. In a review of 12 hips, 3 failed, requiring further



Case 10.19 Robyn

Robyn, a 14-year-old girl with extremely severe spasticity from quadriplegic pattern CP, was seen for a second opinion. She had severe scoliosis; however, the main problem her parents were concerned about was severe bilateral hip pain with almost any motion. On the right hip she had a proximal femoral resection 2 years previously, and 9 months previously she had a left femoral resection and a repeat right femoral resection. The right femur was very short with approximately half the bone length missing.

She appeared on physical examination to have severe pain with any hip motion (Figure C10.19.1). Her parents were told that the scoliosis had to be addressed first with a correction of the pelvic obliquity, which was performed without a problem. A custom-molded prosthesis was then made for interposition arthroplasty, which provided almost immediate pain relief (Figure C10.19.2). Over an 8-year follow-up, she has continued to do well.

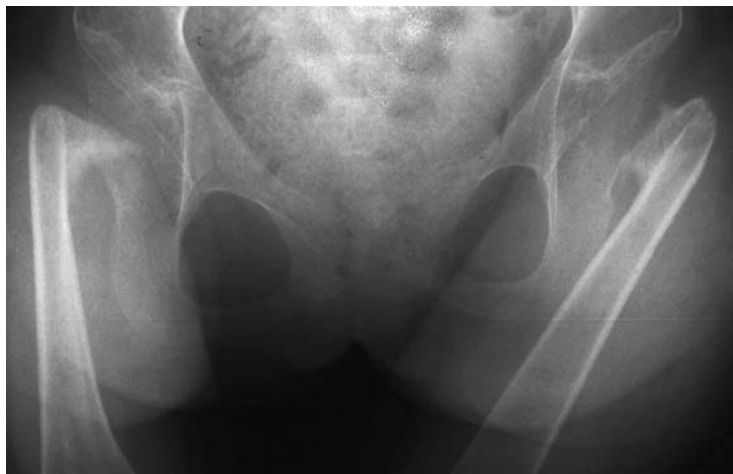

Figure C10.19.1

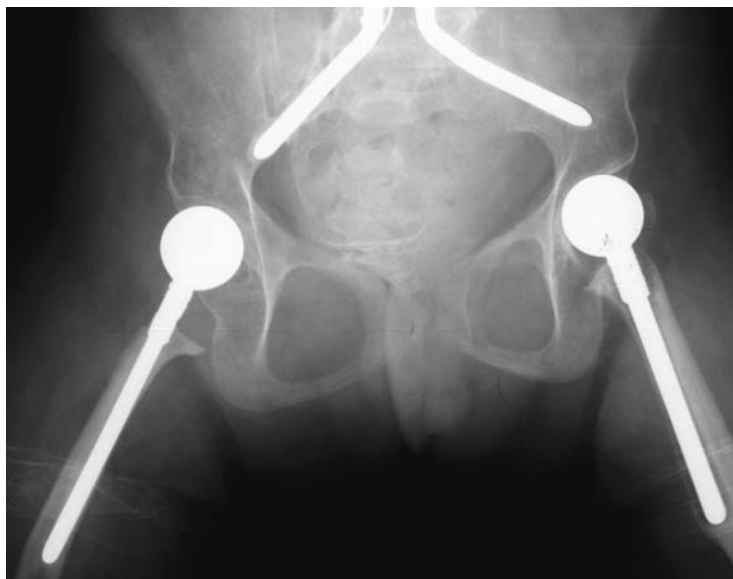

Figure C10.19.2



Case 10.20 Alomah

Alomah, a 15-year-old girl with spastic quadriplegia, was brought in for an evaluation because of skin breakdown over the greater trochanter on the right side. Her aunt, who was her caretaker, felt she had hip pain and she refused to lie in any position except on her right side. On physical examination she was noted to have a 2-cm-wide decubitus ulcer extending to the greater trochanter with a dislocated hip with significant degenerative changes. Motion of both hips was painful, and although the left hip appeared radiographically to not have much degen-

erative change, it was in a fixed anterior dislocation (Figure C10.20.1). A bilateral resection arthroplasty, which allowed primary closure of the decubitus, was performed. She was maintained in traction for 4 weeks. Following the traction, she was mobilized back into her wheelchair, and by 6 months postoperatively, she had reduced pain with no skin breakdown. By 1 year postoperatively, she was pain free (Figure C10.20.2), although a significant amount of ossification occurred at the area of the resection.

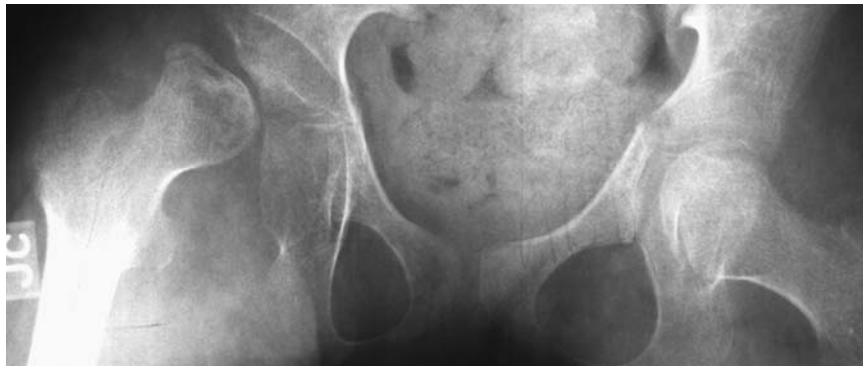

Figure C10.20.1

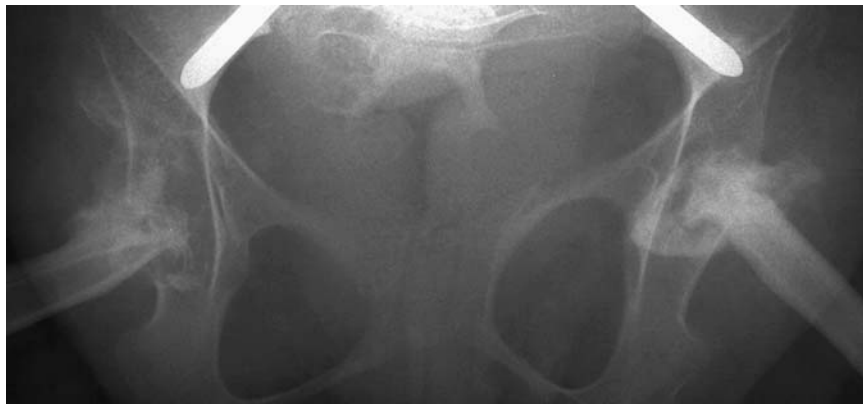

Figure C10.20.2

treatment.⁸⁰ Adults do substantially better,⁸² although a small series of children were reported to obtain good results over the long term as well.⁷⁹

In spite of attempts to provide soft-tissue coverage over the end of the femur, almost all these joints develop heterotopic ossification and there is proximal migration with recurrent contact between the ends of the femur

and the pelvis. Using a radiation treatment to prevent heterotopic ossification is not routinely recommended; however, if individuals had previous hip surgery and have developed heterotopic ossification, it should be considered because most of these children, even with primary resections, develop a significant amount of heterotopic ossification. Sometimes, almost the essence of a new femoral head may emerge, and in some children, the proximal migration and heterotopic ossification becomes so painful that further resection or revision to an interposition arthroplasty are the salvage procedures.

Other Treatments

There have been many other treatment options discussed for the palliative treatment of the subluxated, dislocated, and painful spastic hip. The use of proximal femoral osteotomy is discussed frequently at meetings; however, there are no published reports reviewing the outcome of this procedure. Our experience primarily has been seeing children after someone else has done this procedure and having to take down these valgus osteotomies and do another palliative procedure (Case 10.21). Clearly, there are some children and young adults who develop relatively pain-free hips with this procedure, but it is unclear how often it is successful. From personal experience in following children, there is a 50% to 75% failure rate, but this is somewhat biased because we have not done this procedure as a palliative procedure. The subtrochanteric valgus osteotomy is an excellent procedure for the hip that is pain free but fixed in a poor position. This osteotomy is also an excellent operation to reposition the leg (Case 10.22). Another option in doing a valgus osteotomy, as defined by McHale and associates,⁸³ is combining the valgus osteotomy with a femoral head resection or Girdlestone resection. They have reported good motion and pain resolution in five children using this procedure. We have no experience with this procedure; however, it does seem to be a reasonable option for some children although it is not clear what specific advantage it provides over doing interposition arthroplasty.

Femoral Head Resection

Resection of the femoral head alone is described as the Girdlestone procedure and has been used to treat severe degenerative arthritis, especially before the development of total hip replacement. There continues to be some discussion of the use of the Girdlestone resection in spastic hips; however, there are no specific reports evaluating this procedure except for the report comparing it with the Castle procedure.⁸⁴ This review clearly demonstrates that the Girdlestone is not as good at relieving pain as the subtrochanteric resection, and revisions are quite common (Case 10.18). Unless the Girdlestone procedure is combined with a valgus osteotomy, as described by McHale and associates,⁸³ this procedure is not recommended for spastic hips.

Hip Fusion

Another alternative to dealing with a painful hip is to resect the arthritic portion and do a hip fusion. There has been one report⁷⁵ of eight attempted hip fusions. Six of these attempts had a good result, one needed a repeat procedure to obtain fusion secondary to a pseudarthrosis, and the other was converted to a total hip replacement. Hip fusion is a good and reasonable option for young, healthy walkers who have unilateral spastic hip disease and no scoliosis. We have seen patients of Dr. Patricia Fucs in San Palo, Brazil, who have excellent function following hip fusion (Case 10.23). Hip fusion should be considered as an alternative to total hip replacement in young and functional individuals.



Case 10.21 Abdulla

Abdulla, a 15-year-old boy with severe quadriplegia and mental retardation, was cared for in a chronic care facility. The caretakers felt his hips were hurting because he cried whenever he was moved, especially during diapering and bathing, which was becoming more difficult because of his fixed hip adduction. On physical examination, both hips were noted to be severely adducted, neither of which could abduct to neutral. All attempts at hip movement seemed to cause a pain response (Figure C10.21.1). He had a bilateral femoral valgus osteotomy, which greatly improved his leg positioning and allowed easier perineal care and diapering (Figure C10.21.2). Two years after the osteotomy, he was still having severe pain with almost all movement. He then had an interposition hip arthroplasty with a shoulder prosthesis, and by 6 months after surgery, he was pain free (Figure C10.21.3).

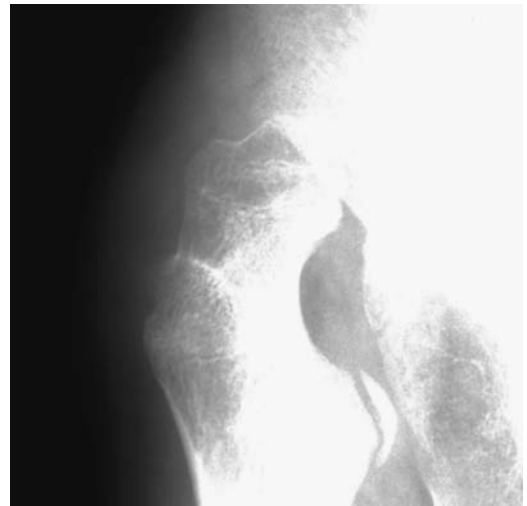


Figure C10.21.1

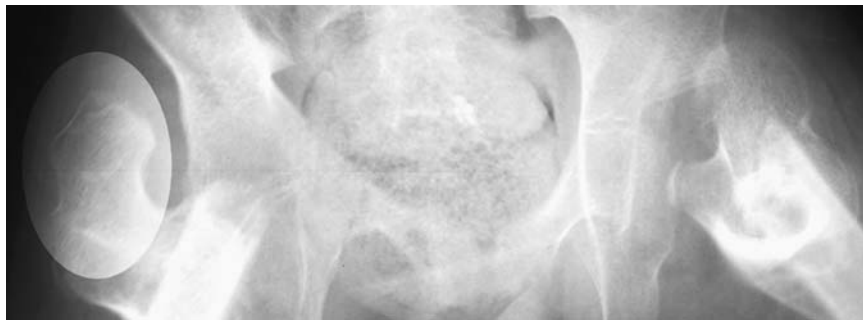

Figure C10.21.2

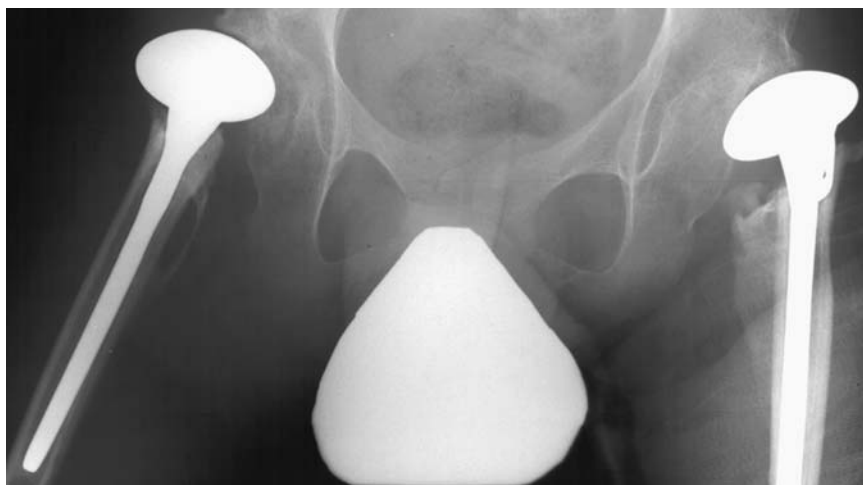

Figure C10.21.3



Case 10.22 Katreena

This 14-year-old girl, Katreena, with a spastic diplegia, was initially seen with severe scoliosis and pelvic obliquity that was corrected with a spine fusion. After the fusion, the severely adducted left hip made walking very difficult. She had never had pain in this hip, and the hip was a known dislocation from DDH diagnosed shortly after her birth. On physical examination her left hip had -30° of abduction and extension to only -40° . External rotation

was to neutral. A radiograph showed a dislocated left hip with a well-formed false acetabulum (Figure C10.22.1). Because of her advanced age and because this is a DDH and not spastic dislocation, it was thought that reduction was not a possibility. She had a well-formed false acetabulum; therefore, a valgus repositioning osteotomy was performed, which greatly improved her ability to walk (Figure C10.22.2).

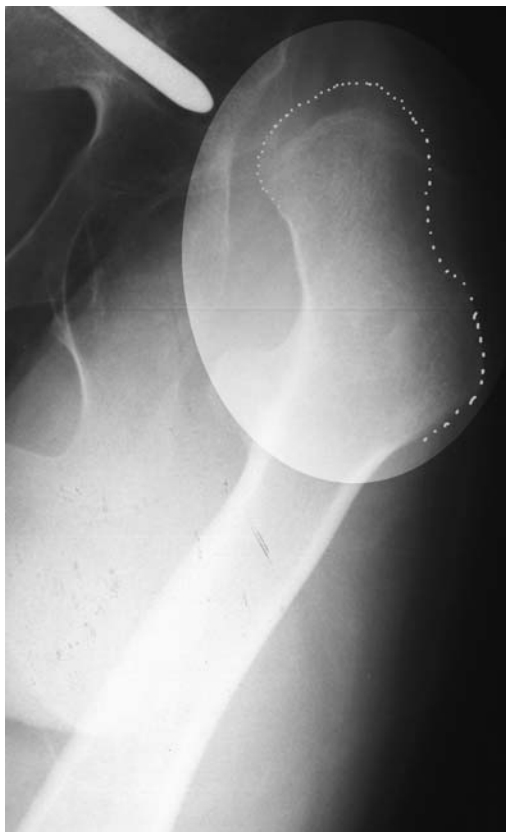

Figure C10.22.1

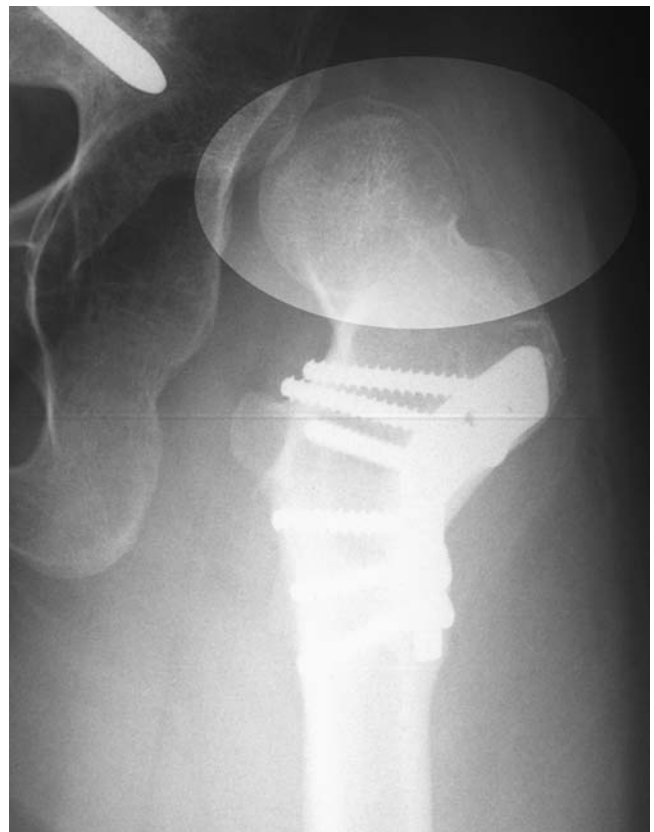


Figure C10.22.2

Complications of Palliative Treatment

Chronic Pain Syndrome

The main complication of palliative treatment is when pain relief is not obtained. It is very important to be aware that adolescents and young adults with CP and spastic hip disease can also develop chronic pain syndrome from having this prolonged, severe pain secondary to the dislocated hip. Addressing the hip problem in these individuals, who are often addicted to narcotics



Case 10.23 Champheng

Champheng, a 14-year-old boy with type 4 left side spastic hemiplegia, was a community ambulator in a regular school and complained of pain in his left hip that limited ambulation. He had mild mental retardation but was independent in activities of daily living. On physical examination he complained of pain with range of motion of the left hip, and the hip had almost no rotation, being fixed in 20° of internal rotation, flexion from -20° to 90°, and abduction to only neutral. The left lower extremity

was 5 cm short. The right hip was normal and there was no scoliosis. A radiograph demonstrated a dislocated hip with severe tertiary degenerative changes with almost closed growth plates (Figure C10.23.1). A hip fusion was performed, and by 2 years after surgery he was again a full community ambulator (Figure C10.23.2). He was even able to ride a bicycle (Figure C10.23.3). (Case material from Dr. Patricia Fucs, San Palo, Brazil.)

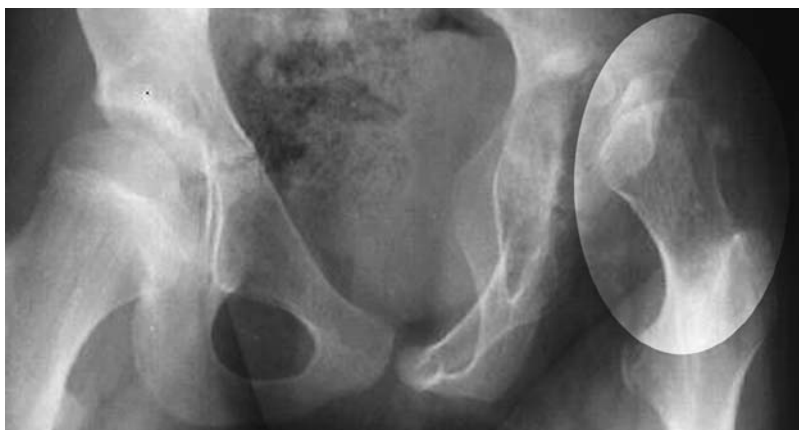

Figure C10.23.1

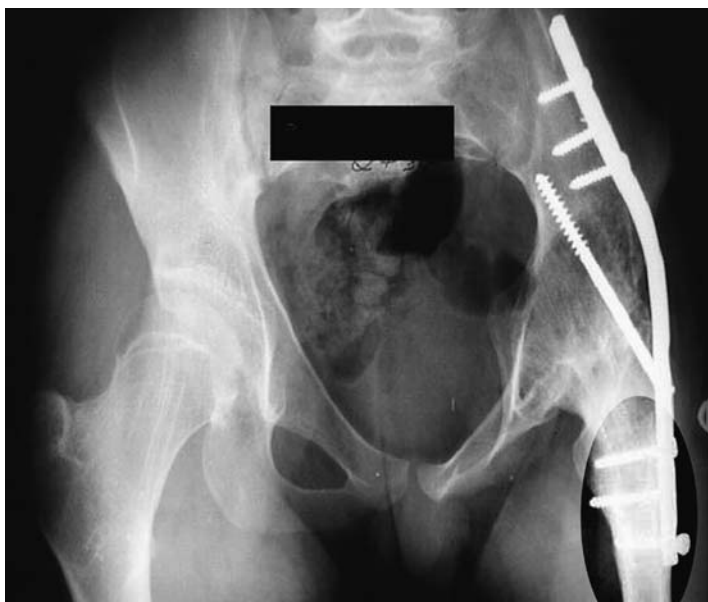

Figure C10.23.2



Figure C10.23.3

and have developed the full pain personality, is not likely to improve their perception of comfort. Surgery in these individuals needs to be undertaken with great hesitation and then should include treatment by a team who can manage the chronic pain syndrome. Of two such children we have seen, one had an interposition arthroplasty and continued with her narcotic addiction. Although she felt she had very little pain relief, her caretakers believed the hip caused little pain after the interposition arthroplasty. The other child, whom we saw for a second opinion, had a valgus osteotomy performed at another facility. However, it was clear, based on the multiple analgesic and narcotic medications that this child was taking and the child's personality, that the real problem was more the chronic pain syndrome than the exact amount of pain from the hip. This is an extremely difficult phenomenon, in which one does need to treat the source of the pain to be able to treat the chronic pain syndrome, but it can be very frustrating and nonrewarding. If individuals are convinced that there is a substantial amount of pain, then it is certainly reasonable to treat it. A treatment that is most guaranteed to get rid of the pain should be chosen, either a fusion or a hip implant procedure because any resection arthroplasty or osteotomy is likely to take months to get full pain relief. Major attempts should be made to wean the individuals from the narcotic medications and increase the use of antidepressants and other nonaddictive pain medications.

Persistent Pain

The continuation of pain after the resection arthroplasty, either the Girdlestone or the Castle procedure, is relatively common. Additional surgical treatment should not be planned for at least 1 year because these hips often continue to improve substantially for up to 1 year after the resection arthroplasties. If the pain is continuing after 1 year, then additional treatment is indicated and the options are either to do additional resections or, better yet, to proceed and then do some type of an interposition arthroplasty to try to get something between the two ends of the bones (Case 10.19). Likewise, if a problem should develop with an interposition arthroplasty, such as with a total hip or total shoulder prosthesis, it is most appropriate just to remove this prosthesis and perform a resection arthroplasty. This is an especially reasonable option if the prosthesis becomes infected.

Another substantial complication from a functional perspective of both resection arthroplasty and the shoulder interposition arthroplasty is that a major limb length discrepancy is usually present if this is a unilateral procedure. In general, the age and level of function of these individuals indicate that the best way to manage limb length discrepancy is with adapted seating because they are nonambulatory and nonweight bearing by definition of having had this procedure.

Anterior Dislocation of the Hip

Anterior dislocation of the hip is a condition that occurs with a specific pattern; however, there may be a slight overlap in a few children. In general children with anterior dislocation tend to present differently and have a very definitive anterior location of the femoral head, which is different from the much more commonly defined posterolateral superior dislocation discussed previously. In the typical posterosuperior dislocation in which the lower extremity is positioned in adduction, internal rotation, and flexion, the acetabular dysplasia is somewhat more lateral or more posterior, but never directly anterior. In anterior dislocation, there are two very specific positional patterns

in hypertonic (spastic) children. These patterns tend to be either one or the other and do not have any overlap in our experience. The first pattern of anterior dislocation is an extended, adducted, externally rotated hip with a fixed knee extension contracture. The extended hip and knee tend to cause seating difficulty, often leading to midthoracic kyphosis (Case 10.24). The second pattern is a severely abducted, flexed, and externally rotated hip with a severe knee flexion contracture (Figure 10.8). There is also a third pattern in children who are hypotonic and develop anterior hip dislocations but have no fixed contractures.⁸⁵ The incidence of true anterior hip dislocation has not been well defined except in the review of Samilson et al.,⁸⁶ in which they reported six anterior dislocations in 406 children with CP who had dislocated hips. Anterior dislocations in children with hypotonia are often overlooked or misdiagnosed as typical posterolateral dislocations and sometimes are not even recognized as dislocations because the radiographs tend to be very difficult to interpret. The CT scan will show the anterior displacement of the femoral head clearly, and a careful physical exam is almost always able to palpate the femoral head in the femoral triangle (Case 10.24).

Etiology

An extensor pattern at some level is the driving force causing the anterior dislocation in children with spasticity who develop anterior dislocations. Children who have had extremely aggressive adductor iliopsoas lengthenings and anterior branch obturator neurectomy are left with tight hamstrings. Often these children are placed in a cast in the extended and abducted position. This iatrogenic deformity becomes fixed in the cast and gradually becomes worse when the cast is removed. This iatrogenic deformity occurred in most of the patients reported in an earlier study,⁸⁷ in which 5 of 11 cases were definitely iatrogenic. In our later report,⁸⁵ we only had 4 cases with this type of iatrogenic etiology and most of them occurred secondary to the neurologic pattern. The iatrogenic cause of anterior dislocation should completely disappear with more careful, less aggressive lengthening of the adductor iliopsoas and adding hamstring lengthening when indicated and not using spica casting.

Hyperextension posturing commonly develops in hypertonic children who have had an acute brain injury. This extreme extensor posturing may develop gradually during the childhood growth period as well. During the evolution of the brain injury, the hyperextension posturing may dissipate and return toward a flexor posture in some of these children who have acute severe hyperextension posturing. If this change occurs, some children may develop a mild anterior subluxation that will reverse and actually can go to a posterior dislocation. Also, many of these children have severe neurologic involvement and very abnormal pathomechanics; therefore, many with anterior dislocation have a great amount of global acetabular deficiency. These acetabula often have a wide teardrop with very poor acetabular depth, making reconstruction very difficult.

Natural History and Treatment

The specific treatment for anterior hip dislocation has to be based on the specific pattern of the anterior dislocation. In type I, with the extended, adducted, externally rotated hip and fixed knee extension contracture, sitting requires hyperflexion of the lumbar spine, causing the development of a fixed lumbar kyphosis, often with secondary changes in the thoracolumbar vertebrae typical of adolescent lumbar Scheuermann's disease (Case 10.24). This



Case 10.24 Jason

Jason, a 13-year-old boy, presented with quadriplegia and severe mental retardation, with his caretaker's primary complaint being that he could no longer sit (Figure C10.24.1). There was no apparent pain if he was not forced to sit. On physical examination he appeared thin but well nourished, although he only weighed 21 kg at age 13 years. His spine had a flexible, sharp kyphosis at the thoracolumbar junction without scoliosis, his hips could extend to 40° but flexion was limited to 20°, and knee flexion was limited to 15° (Figure C10.24.2). His feet were in severe equinus. Radiographs of the spine showed the sharp thoracic kyphosis at T12 to L2 (Figure C10.24.3). The hip radiographs appeared to have an anterior dislocation (Figure C10.24.4), which was confirmed by a CT scan (Figure C10.24.5). His primary problem of sitting was believed to be due to kyphosis, which was caused by the fixed hip dislocation. Because of his small size, he had proximal femoral resections and anterior knee releases by Z-lengthening of the quadriceps tendon to allow knee flexion. His spine remained flexible but with severe secondary apophyseal changes from the long term forced flexion (Figure C10.24.6). After 4 months, these procedures were followed by a posterior spinal fusion (Figure C10.24.7). Although another 8 months were required for his hip resection to become pain free (Figure C10.24.8), by 1 year after surgery he could comfortably sit upright. This case is a typical example of the type I anterior hip dislocation.

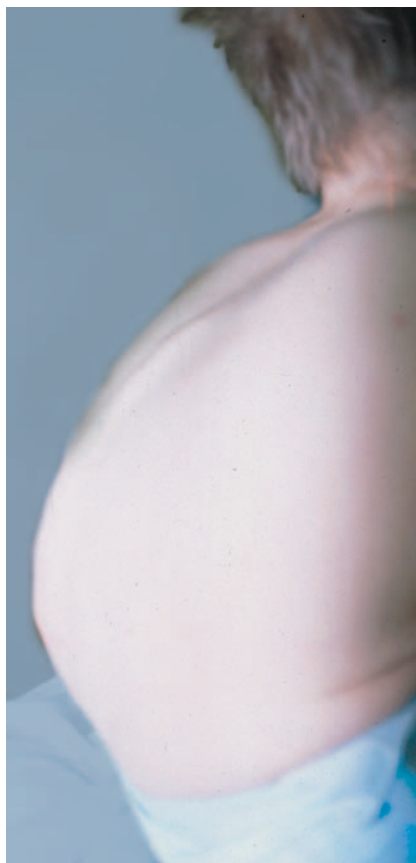

Figure C10.24.1

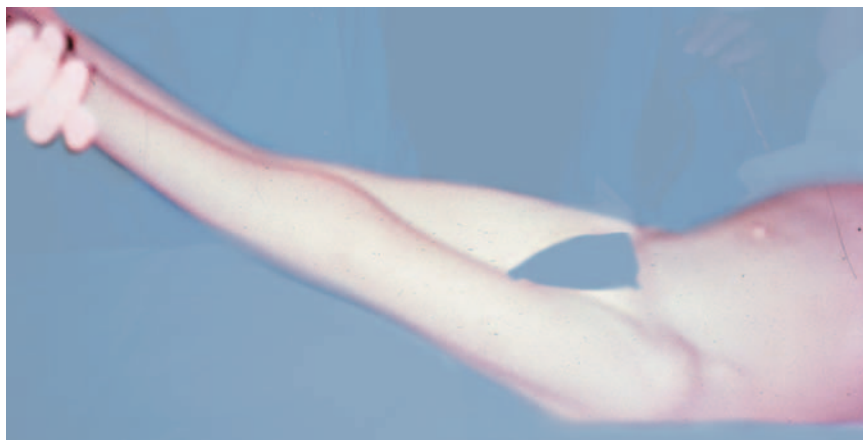

Figure C10.24.2

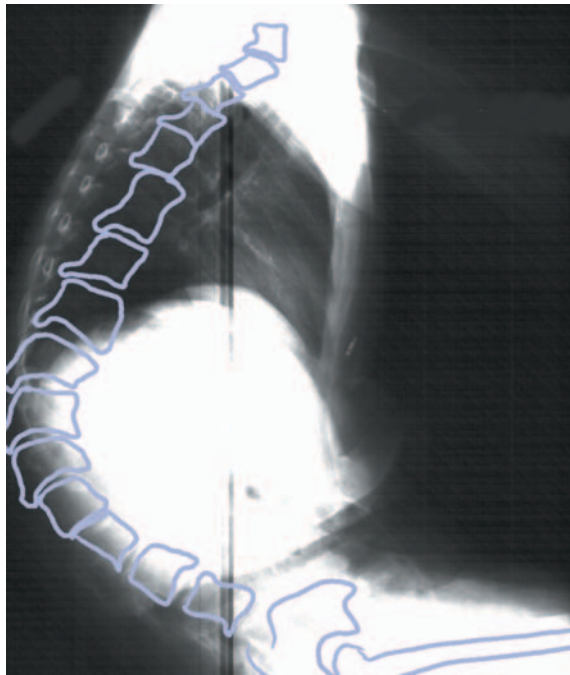


Figure C10.24.3

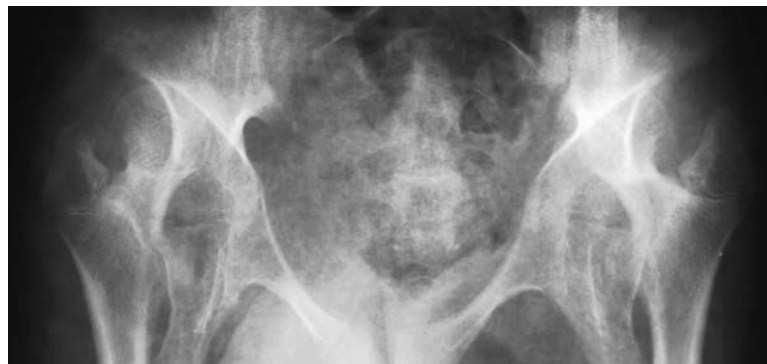

Figure C10.24.4

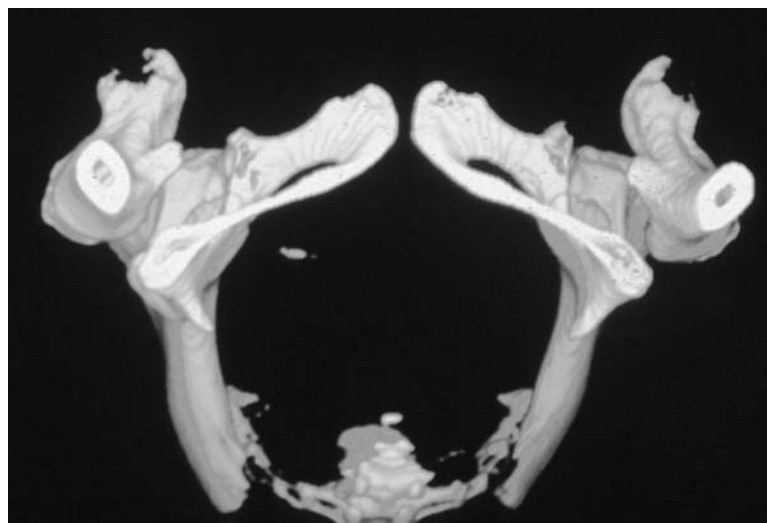


Figure C10.24.5

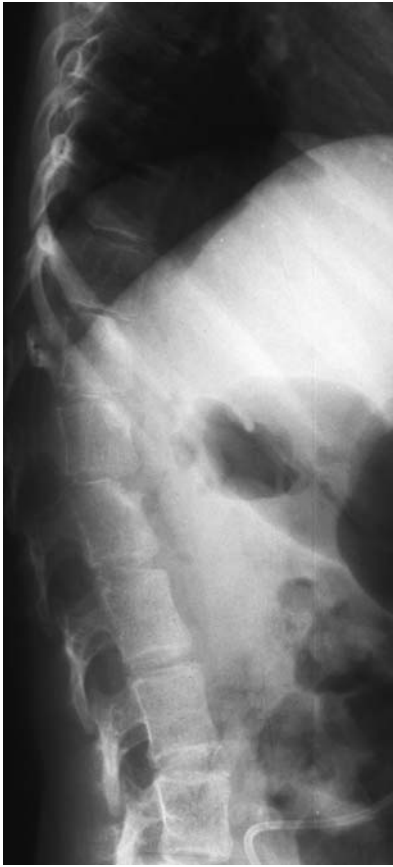

Figure C10.24.6

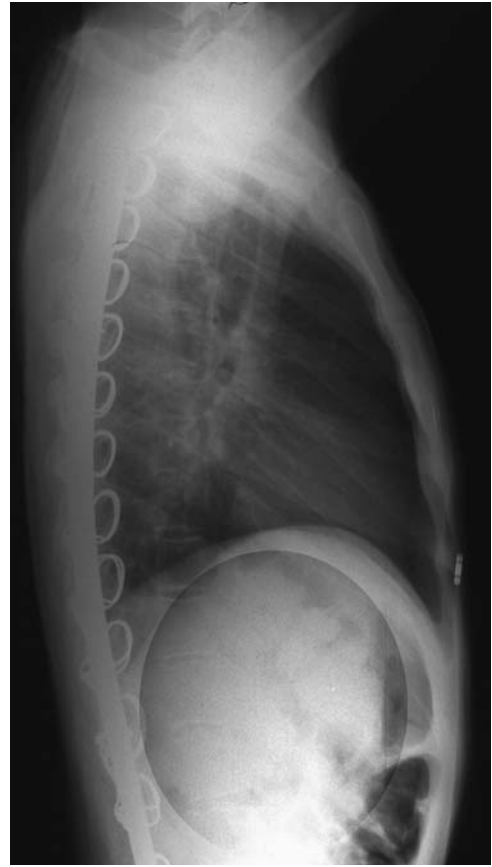


Figure C10.24.7

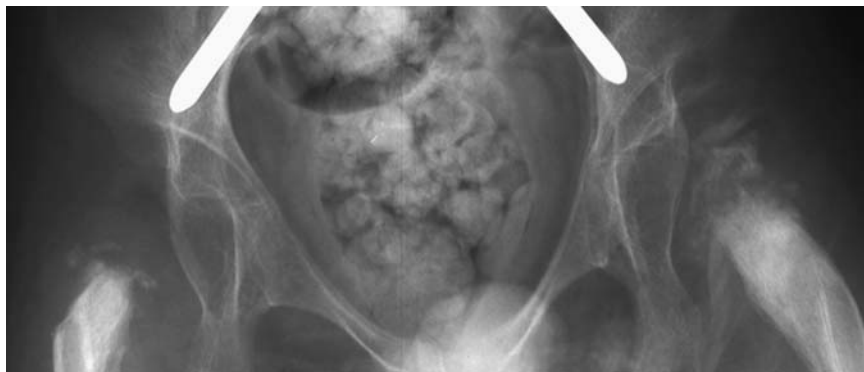


Figure C10.24.8

kyphosis tends to get very stiff as children grow and the posture becomes fixed so that they cannot lie in the extended position. In the early phase, these type I hip dislocations can be reduced with a fairly palpable sensation of the femoral head, reducing posteriorly into the acetabulum. All these children with significant fixed extensor posturing will develop a fixed anterior dislocation if they do not change their neurologic pattern. Our experience has been that type II deformities become fixed if left over time. However, the

A



B



Figure 10.8. Anterior hip dislocation presents with three types. In type 1, there is a fixed knee extension contracture, with the hip being adducted, extended, and externally rotated (A). In type 2, the knees have a fixed flexion contracture with the hips being abducted, extended, and externally rotated. The very prominent femoral head can be seen protruding in the inguinal areas (B). Type 3 presents in the hypotonic individual with no contractures.

natural history of the hypotonic hips are hips that come in and out of reduction and do not become fixed in the dislocated position. Several of these children whom we have seen have dislocated both anteriorly and posteriorly.

Type I Anterior Hip Dislocation

The type I anterior dislocation of the hip has an extended, externally rotated, adducted lower extremity with a fixed knee extension contracture; therefore, treatment requires addressing these fixed deformities. All children whom we have seen with this pattern of anterior hip dislocation have not had pain at the hip joint after the hip dislocation becomes fixed. However, it is impossible to provide seating for these children because they cannot bend at the knees or at the hips and are therefore required to be in a lying position. These children are often propped up so their spines develop fixed, thoracic kyphotic deformities, and yet they are still unable to be seated. When children who have apparently extended hip and extended knee contractures are seen, it is important that a CT scan of the hip be obtained if there is any question as to whether this is an anterior hip dislocation (Case 10.24). The goal of treatment for type I pattern anterior hip dislocations is always to try to get children into a more adequate seating posture.

Treatment

The recommended treatment requires that an adductor lengthening be performed with shortening and varus osteotomy in the intertrochanteric region of the femur with a Pemberton pelvic reconstruction osteotomy. The Pemberton osteotomy often requires a great amount of opening, extending anteriorly into the pubis, because this region of the acetabulum is usually very deficient. If possible, the hip should be stabilized in the operating room so that it cannot easily dislocate anteriorly with a small amount of external rotation of the hip. The hip must be able to flex to 90° or 100° at the conclusion of this procedure. Generally, this flexion is easiest to achieve by substantial femoral shortening, although in some cases, lengthening of the gluteus maximus is also appropriate. A very aggressive lengthening of the quadriceps, usually a Z-type lengthening of the quadriceps tendon, is required followed by careful closing of the soft tissue because this anterior skin and subcutaneous tissue over the knee may be quite tight as a result of the prolonged fixed knee extension contracture. If children have developed fixed spinal kyphotic deformities already, these should be addressed within 3 to 4 months after the hip surgery. If this deformity is left in place, children will tend to be placed back into the wheelchair position in the extended hip position, which fosters the same deformity these children had before the hips were treated. Not correcting both deformities is a common cause of failure in the treatment of this deformity, so that 2 years after the hip and knees have been addressed, children look the same as before, even though the hips may not be dislocated.

Other treatment options include a subtrochanteric resection (Castle procedure) if children are very small or have extremely severe dysplasia or degenerative changes of the femoral head. In two children in whom we have done femoral resections, pain continued for 9 to 12 months, which is somewhat disappointing because these children often do not have much pain before the procedure (Case 10.24). Another option to consider when children are seen early is muscle lengthenings, including the gluteus maximus, adductor, and quadriceps lengthening. We have no experience doing muscle surgery alone with this pattern of dislocation.

Type II Anterior Hip Dislocation

Seating is almost impossible for patients with extended, abducted, and externally rotated hips with a fixed knee flexion contracture. The fixed knee flexion contracture usually involves hamstring contractures that may have a popliteal angle of 100° to 120°, and as much as 40° to 60° of fixed knee flexion contracture present. These children often have trouble even with side lying and have to remain supine or prone. In our experience, these hips have become painful with time because they are somewhat more mobile than the type I anterior dislocations, which are in full extension of the hip and knee.

Treatment

Indications for treatment usually involve difficulty with seating as well as pain that is often present when seating attempts are made. These children may also have spinal scoliosis or kyphosis; however, this is not typically part of the pattern as with the type I dislocation (Case 10.25).

Recommended treatment is a lengthening of the gluteus medius and minimus with intertrochanteric varus osteotomy and femoral shortening,



Case 10.25 Conan

Conan, an 8-year-old boy with spastic quadriplegia and mental retardation, presented because his mother felt his hips were coming out of the joint. She was unsure how much pain this was causing. He was otherwise in good health and was fed by mouth. On physical examination he was noted to be lying in external rotation with severe hip flexion, knee flexion, and hip abduction (Figure C10.25.1). Masses could be seen in the inguinal area bilaterally (Figure C10.25.2), and with hip flexion, these were felt to be the femoral head, which could be reduced easily. The knees had popliteal angles of 90° . It was difficult to tell how much fixed knee flexion contracture was present,

but it was thought to be approximately 30° . Radiographs showed no degenerative change but demonstrated an apparent anterior hip dislocation (Figure C10.25.3) that was confirmed with CT scan (Figure C10.25.4). His spine was straight. He was reconstructed with bilateral femoral osteotomies, a Pemberton-type pelvic osteotomy, and also had distal hamstring lengthening (Figure C10.25.5). Postoperatively, the hips remained reduced and the knees had a fixed contracture of 30° , which was not believed to cause any problems. He could now be positioned in a more normal posture (Figure C10.25.6).



Figure C10.25.1

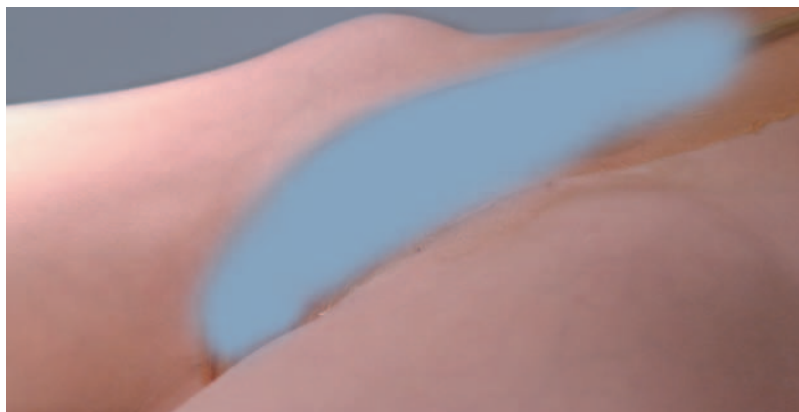

Figure C10.25.2

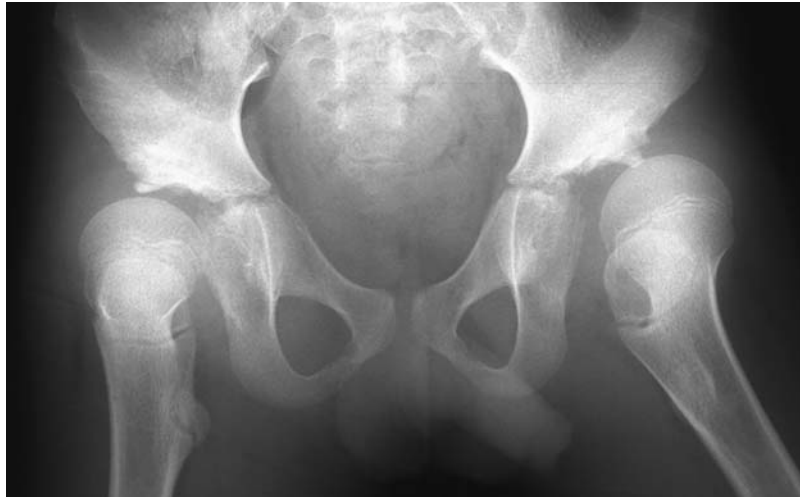

Figure C10.25.3

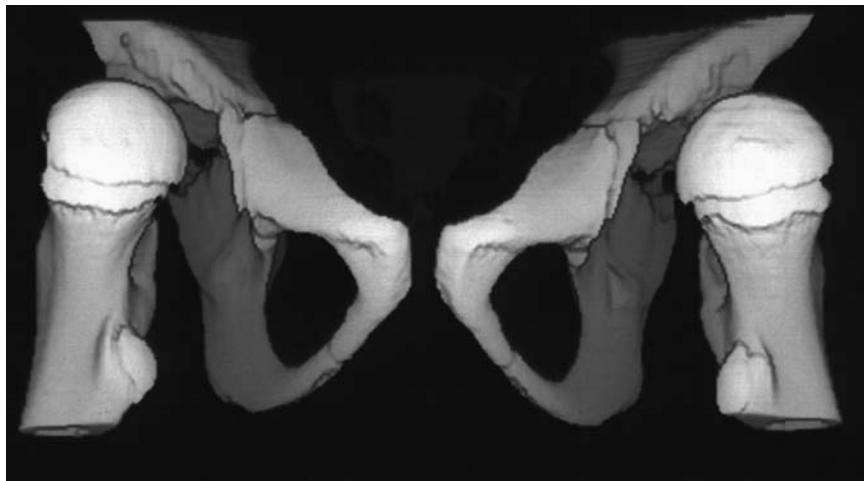


Figure C10.25.4

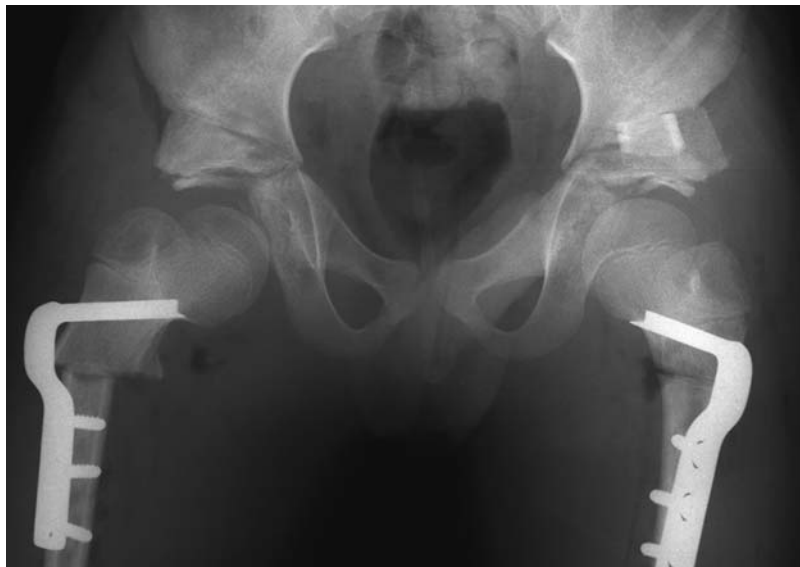

Figure C10.25.5

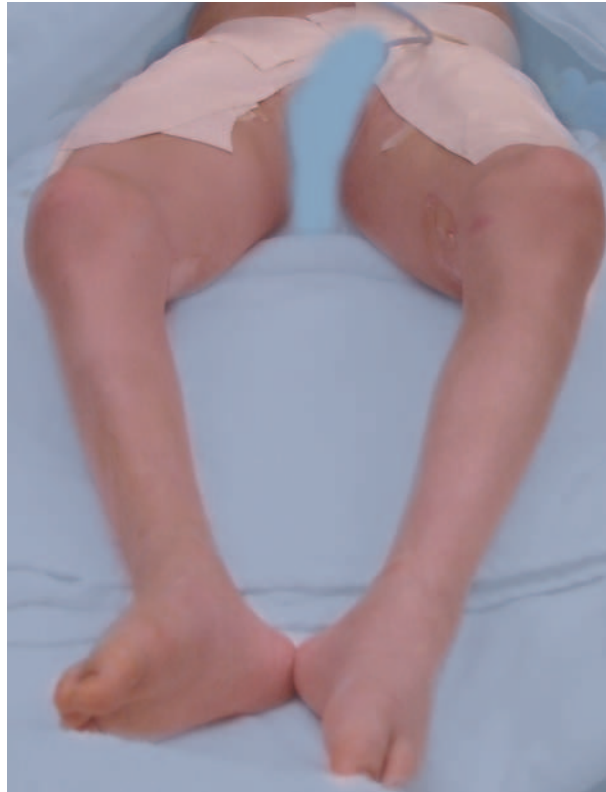

Figure C10.25.6

and again having to do an anterior Pemberton osteotomy, often with an acetabulum that is extremely deficient. These children need extensive distal hamstring lengthening as well and usually need to be held in short-leg casts that are fixed together either with plaster or sticks to hold the hips out of this externally rotated position postoperatively.

Other Treatment Recommendations

The resection arthroplasty in the subtrochanteric region is another reasonable option for treating these children. We have had experience with attempting to do muscle lengthenings in three children with intermittent dislocations. In two of these three children, the anterior dislocation was resolved; however, it converted into a posterior dislocation (Case 10.20). The other child continues to have intermittent anterior dislocations. Therefore, with a failure in three of three attempts, muscle release surgery is not appropriate if the hip is developing anterior instability.

Complications

Complications from treatment of type II hip dislocations are primarily related to the problem of the severe knee flexion contractures, which make postoperative positioning difficult so that children do not fall back into the preoperative pattern. The other major complication is that these children often have a severely deficient acetabulum and therefore care must be taken not to convert them from an anterior into a posterior dislocation.

Type III Anterior Hip Dislocations Present in Hypotonic and Hypermobile Hips

The major problem with type III anterior dislocated hips is that they are frequently missed as a diagnosis (Case 10.26). Many of these children are fairly functional, often with mental retardation, and are unable to be very specific



Case 10.26 Aidan



Aidan, an 11-old-boy with severe mental retardation, presented for a second opinion. His mother complained that he walked well using a walker and even did some independent ambulation, but that he had walked only a little since hip surgery 1 year previously. He was otherwise in good health. On physical examination he could walk with a posterior walker for a short distance. Hip range of motion was full with no apparent pain. The left hip had clear instability on physical examination, although it was not possible to determine if it was anterior or posterior. A radiograph showed the left hip to be subluxated, although only minimally (Figure C10.26.1), and a CT scan was

obtained that showed the hip to be clearly anteriorly subluxated (Figure C10.26.2). An anterior reconstruction with repeat varus was performed, adding a large shelf to the large anterior acetabular, a Pemberton-type turndown pelvic osteotomy (Figure C10.26.3). The hip was thought to be stable intraoperatively. Over the next year, he returned to walking freely with his walker and then started independent ambulation. With a 5-year follow-up, he has continued to be a full community ambulator and showed good remodeling of the hip, and the hip remained stable on physical examination (Figure C10.26.4).

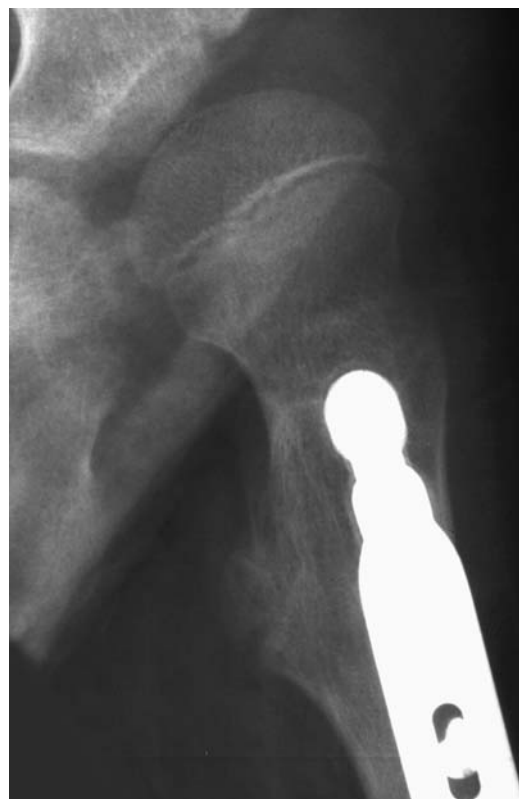

Figure C10.26.1

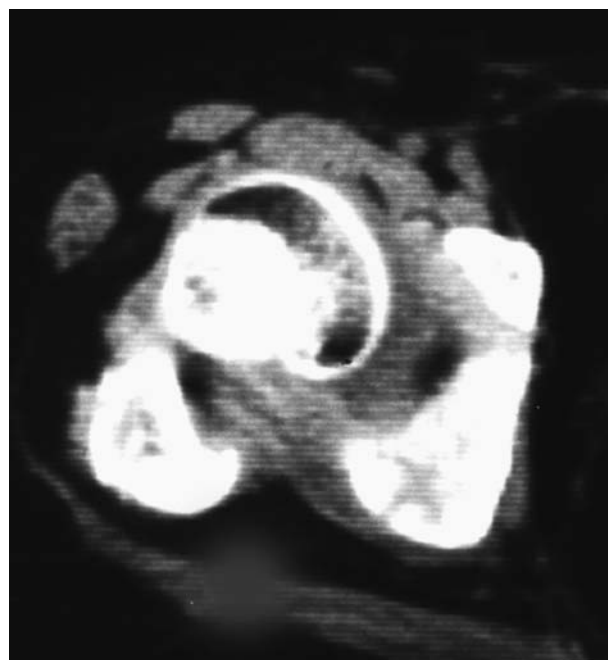


Figure C10.26.2

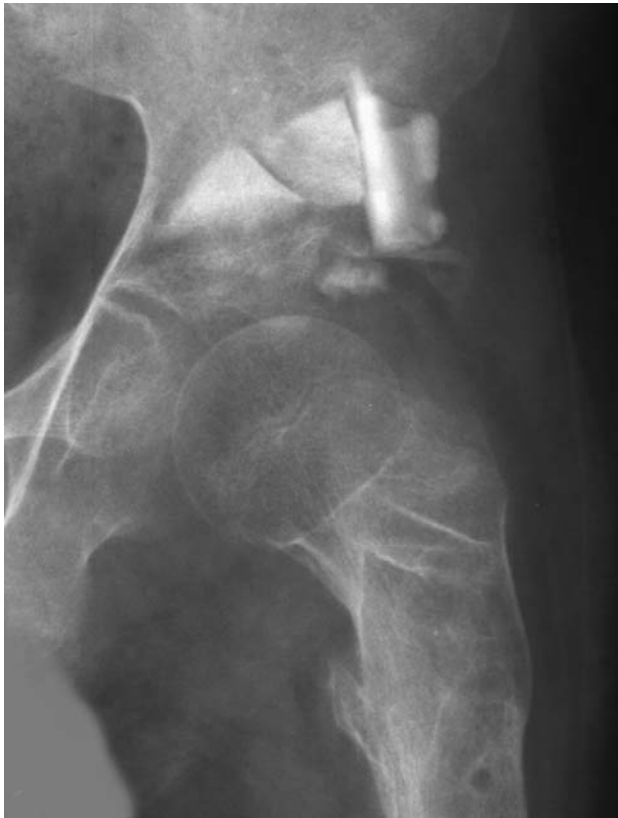

Figure C10.26.3

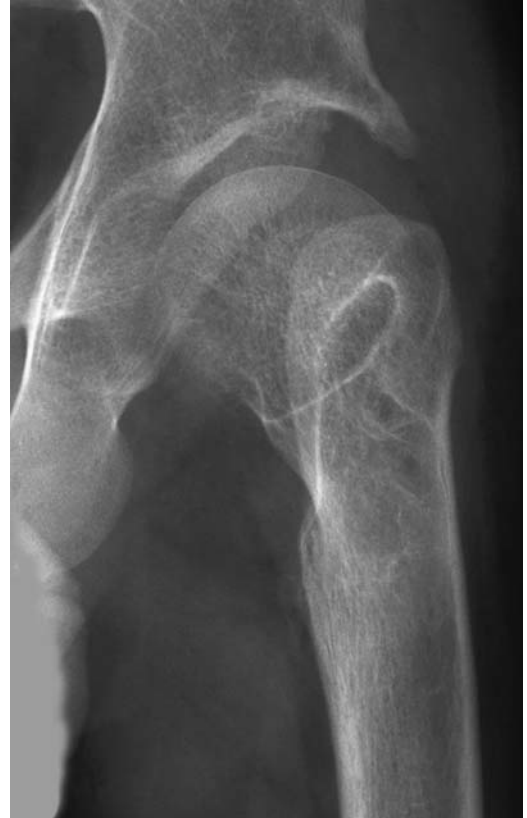

Figure C10.26.4

about their complaints. In two patients we have seen, the presenting symptom of an anterior dislocation was the child's refusal to bear weight. In another child, the radiograph was interpreted to be a posterior dislocation and an operative procedure was performed for posterior coverage; however, the patient continued to have great difficulty with walking. Most of these children seemed to have pain with weight bearing, although they often have a difficult time expressing the pain. While children are being examined, movement of the hip often demonstrates that it subluxates anteriorly and seems to cause them discomfort. If the radiographs are not clear, or if there is any question based on the position that the hip seems to anteriorly dislocate, these children need to have CT scans of their hips, which will clearly document the anterior displacement of the femoral head. The physical examination is not as consistently reliable as it is with the types I and II anterior dislocations because of the large range of motion.

Treatment

The indication for treating a type III anterior dislocation is generally patients who are either having pain while sitting or are having decreased ambulatory ability and refusing to ambulate. As soon as children refuse to ambulate, and type III anterior dislocation has been diagnosed, immediate reconstruction is recommended. The longer children are nonambulatory, the more difficult it will be to get them ambulating again. In two patients whom we have treated, both returned to full community ambulation after they had completely stopped walking for short periods of time because of their anterior hip

dislocations. In this hypotonic group, we have seen several multidirectional dislocators. Using splinting to control position and reconstructing the acetabulum when a more definitive directional pattern gets established is the recommended treatment (Case 10.27).

In type III anterior dislocation, there is no need for muscle release surgery because there is no restricted motion. The focus should be on an anterior opening Pemberton osteotomy in which good anterior coverage is obtained. Most of these children still need to have a mild varus shortening osteotomy to allow the femoral head to be brought inferiorly and posteriorly so it does not have too much pressure on the turndown of the Pemberton osteotomy. We have tried to do the Pemberton osteotomy without varus femoral shortening and have found that the operative procedure is often blocked and it is extremely difficult to get sufficient coverage anteriorly. There may also be circumstances where an anterior shelf can be added to help augment the anterior deficiency. These children may be easier to manage by placing them in short-leg casts with the legs internally rotated with some mild abduction. In this position, children can still be gotten out of bed into a wheelchair, and the anterior acetabulum is allowed to firm up before stress is placed across the acetabulum. Many of these children lie with their legs externally rotated during sleep, which further irritates the anterior



Case 10.27 Stephanie

Stephanie, a 4-year-old girl with moderate hypotonic quadriplegia, was first seen at age 4 years when her mother felt the right hip was popping out. She had severe mental retardation with no communication. Head and trunk control was present, but she could not sit independently. On physical examination, full range of motion was present at the hips, knee, and ankle with mild spasticity at the gastrosoleus. With high extension and external rotation, the right hip could easily be felt to dislocate anteriorly. With flexion and internal rotation, it reduced easily. Radiographs of both hips showed anterior dislocations (Figure C10.27.1). Her mother was instructed to prevent ab-

duction external rotation by tying the knees together very loosely using a string through the pant legs at the level of the knees. When seen in 6 months, her mother reported that this technique was working well but she still dislocated. Possible reconstruction was discussed but her mother felt she was doing well and preferred no intervention. Over the next 3 years, the anterior dislocation gradually decreased, as her mother was very diligent in preventing the initiating postures, and the hip was developing well (Figure C10.7.2). Then at age 9 years, Stephanie was seen with the right hip flexed and adducted, which was causing her pain (Figure C10.27.3). This was noted

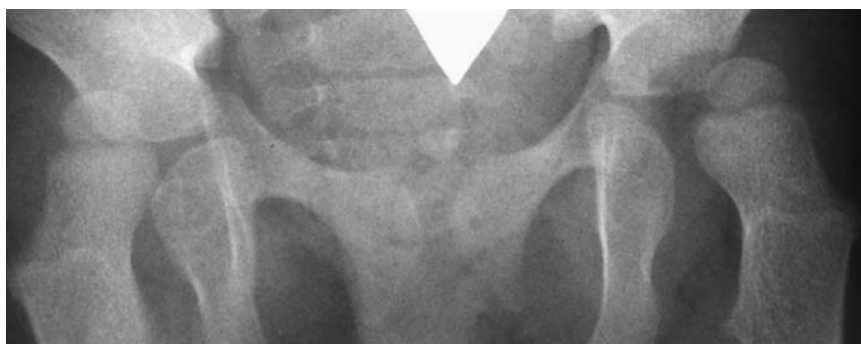

Figure C10.27.1

to be a posterolateral dislocation, which was reduced in the clinic, and her mother was shown how to reduce dislocations if they should occur. She continued to have intermittent anterior dislocations over the next several years, and on many occasions her mother could not reduce a posterior dislocation and brought her to the clinic for us to reduce her. By age 12 years, when she was growing rapidly, her mother could no longer position her to keep the hip reduced and she developed a fixed posterior dislocation (Figure C10.27.4) with severe adduction and

flexion making seating difficult (Figure C10.27.5). The mother only agreed to allow reconstruction after she also developed severe scoliosis. The scoliosis was corrected first followed by the hip reconstruction (Figure C10.27.6). By this time, the hip was in a fixed dislocation for 18 months with hip adduction and flexion (Figure 10.27.5); however, following reconstruction, the hip was again in good position (Figure C10.27.7). By the 3-year follow-up, the hip remodeled and she was stable and pain free (Figure C10.27.8).

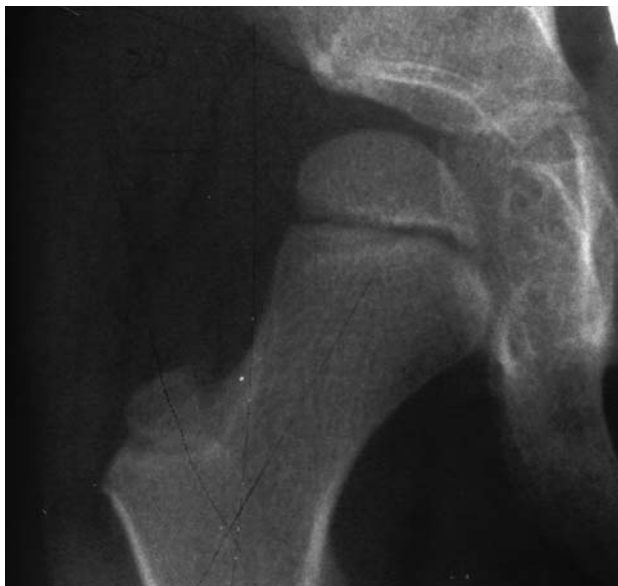

Figure C10.27.2

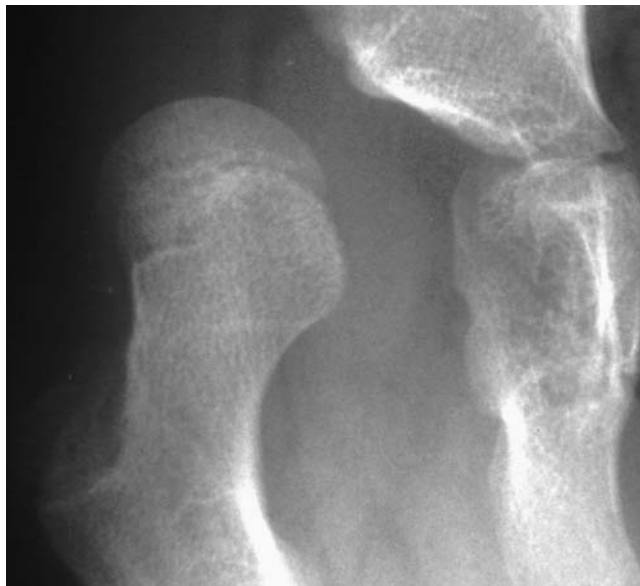

Figure C10.27.3



Figure C10.27.4

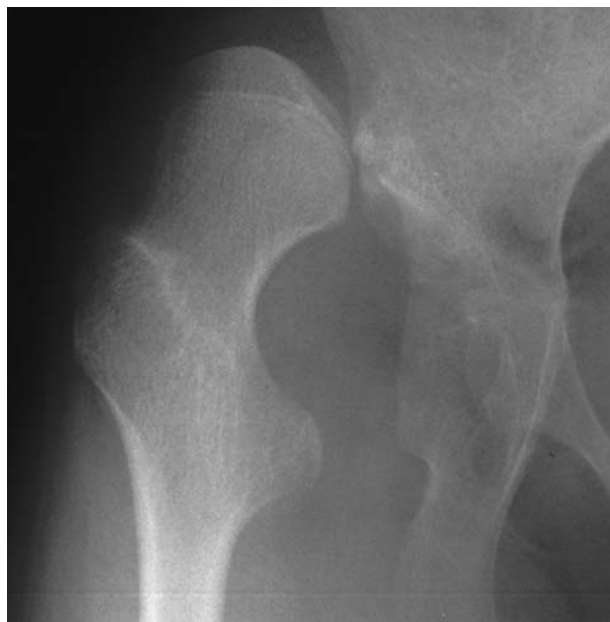

Figure C10.27.5

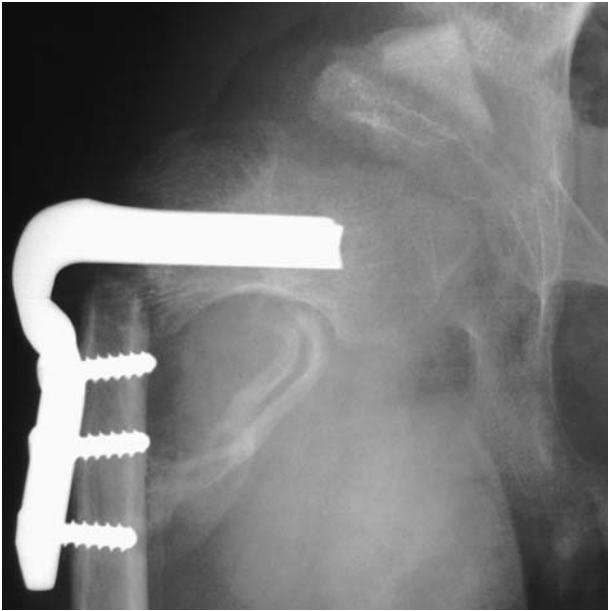


Figure C10.27.6

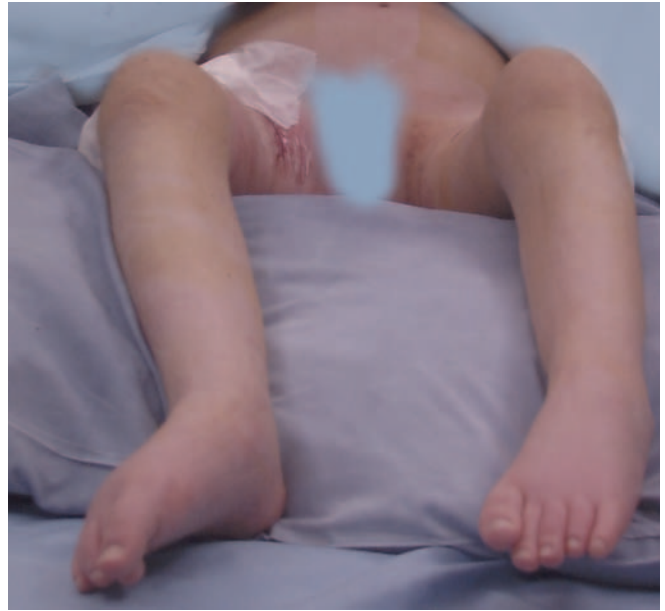

Figure C10.27.7

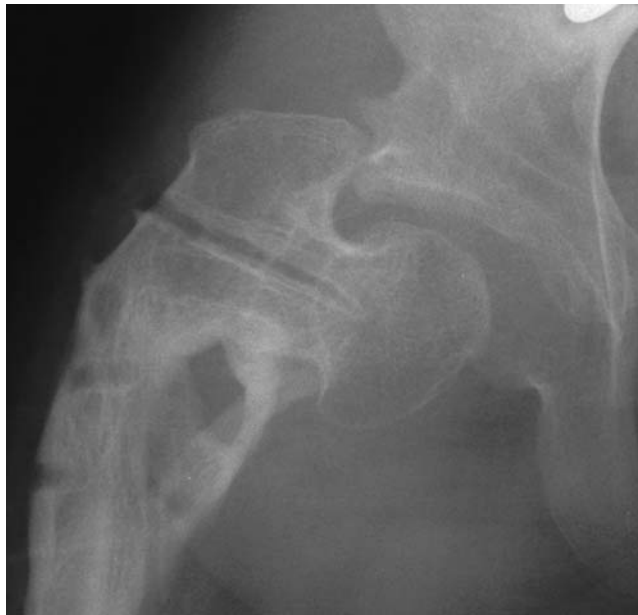

Figure C10.27.8

instability. For this reason, we have tried to keep these children in either internally rotating orthotics or have asked parents to keep their children's legs together to prevent them from lying with their lower extremities in the abducted, externally rotated position.

Complications

The major complication of a type III anterior dislocation is that a recurrent dislocation will occur. If children are ambulators, it is reasonable to make a second attempt to get the hip reconstructed. We have had experience with

one child in whom a second acetabular reconstruction was required; this was successful in maintaining the hip reduced and keeping the child walking until she became a young adult. We anticipate, although we have no experience, that these individuals should maintain stable hip joints once they reach full adulthood.

Inferior Hip Dislocation

Direct inferior dislocations of the hip are very rare. We have only treated one such deformity and have had the opportunity to examine another patient (Case 10.28). Both these individuals had tremendous difficulty with seating because their legs were fixed in a severe, abducted hip and knee-flexed position making seating almost impossible. In one of these patients, the knee had



Case 10.28 Travis

A 13-year-old boy, Travis, had severe spastic quadriplegia, poorly controlled seizures, was fed by a gastric tube, and had a tracheal diversion. He was brought by his mother because of difficulty sitting and a complaint from the mother that he sometimes got his knee stuck in his axilla when lying. On physical examination he had fixed hip

flexion of 120°, abduction of 20°, and 60° knee flexion contractures. A hip radiograph showed inferior hip subluxations (Figure C10.28.1). A redirection varus femoral osteotomy did not greatly change the hip position but allowed easier sitting and lying in a more normal position (Figure C10.28.2).

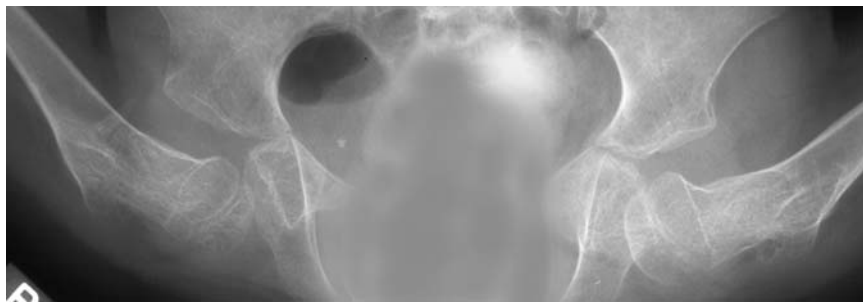

Figure C10.28.1

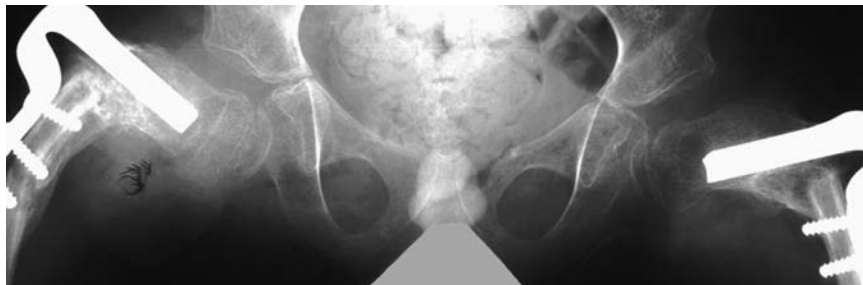


Figure C10.28.2

a tendency to become lodged in the patient's axilla. Our single treatment experience with this type of inferior dislocation is a varus repositioning osteotomy that allowed this individual to sit much better. The hip did not become painful, although this child had severe neurologic involvement that required a tracheostomy. Six years after the varus osteotomy, this child died of aspiration through his tracheal diversion.

Hyperabducted and Extended Hip Deformities

A small group of children develop severe, bilateral abducted hips. Some of the children have extension contractures and have more or less flexion. This deformity creates great difficulty with seating⁸⁸ and is a very socially unappealing posture for adolescents and young adults (Case 10.29).

Etiology

There are children in whom the etiology of this hyperextended and abducted position is iatrogenic, related to too much adductor and iliopsoas lengthening with obturator neurectomies.⁸⁷ There are also children who have been kept for a prolonged time in abduction orthoses to treat spastic hip subluxation following adductor lengthening, which increases the development of hyperabduction contractures.⁵⁵ There are many children, however, presenting with this hyperabduction deformity who have had no treatment whatsoever and seem to develop this deformity due to their pattern of neurologic involvement. Another large group of children develop this deformity unilaterally and it becomes a windblown hip posture. This hip posture as discussed later.

The natural history of this hyperabduction deformity is not well documented; however, in our experience, it generally does not get progressively worse as children get older. The problem occurs as children get older and bigger, making it more difficult to accommodate the deformity. With some attention to seating modifications, many of these children develop good patterns of sitting and can often spend long periods of time lying in a side lying position. This deformity is a very cosmetically objectionable posture, especially for adolescent and young adult females, to be lying in the hyperabducted hip-flexed position every time they are not sitting in their wheelchairs. Some of the children and many caretakers are bothered by this posture. Although it seems that this posture is a precursor to the type II anterior hip dislocation, no good documentation exists to suggest that it leads directly to anterior hip dislocation or inferior hip dislocation. This evolution of deformity may occur, but is so rare that it is not recognized as part of the precursor posture. A much more common bony deformity that occurs from this position as children grow, and especially as they go into adolescence, is the development of protrusio acetabuli from too much direct medial pressure. This is exactly opposite of what is seen when the widened teardrop with anterior or posterosuperior dislocations are present. This acetabular protrusio may lead to degenerative arthritis in some young adults. Protrusio acetabuli may also leave children who are osteoporotic at risk for getting an acetabular fracture (Case 10.29).

Treatment

Treatment of the hyperabducted hip deformity can be divided into those with mild deformity and those with more severe deformity. Mild deformities are defined as hips having a passive adduction so they can be brought to neutral



Case 10.29 Reba

Reba, a 15-year-old girl with severe mental retardation and spastic quadriplegia, was seen for routine follow-up and was noted to have severe hip abduction contractures. She had never had any hip surgery, and at that time, her mother did not feel she had any pain. The school care providers felt the hyperabduction deformity was very cosmetically objectionable because she was always in this position except when restrained in her wheelchair (Figure

C10.29.1). Her mother, however, was not bothered by the appearance. Physical examination showed the hips with maximum extension to only -50° and adduction to only -30° bilaterally. Radiographs of the hips showed that she had acetabular protrusio (Figure C10.29.2). She sat well in her wheelchair, which was extra wide and fitted with bilateral hip guides. At this time, her mother wished no treatment.

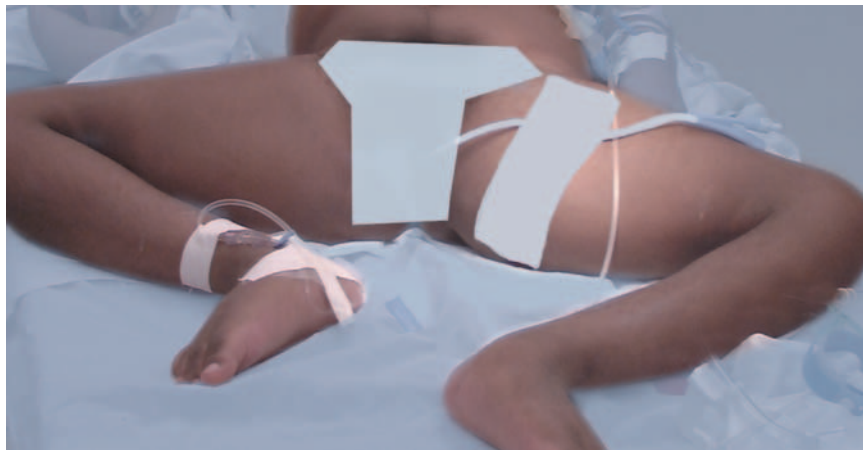


Figure C10.29.1

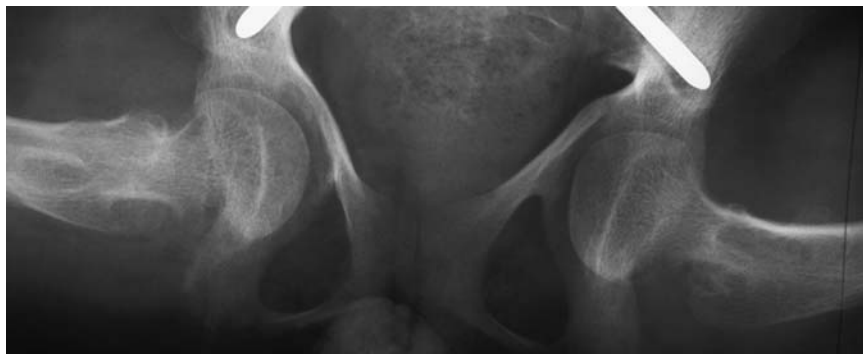

Figure C10.29.2

and at least 45° of hip flexion is present. In children with open growth plates, muscle lengthening should be the primary procedure. However, the muscle lengthening will probably not work if there is a substantial acetabular protrusio already present. The muscle lengthening should involve a myotomy of the posterior gluteus medius just above the greater trochanter, sectioning the

gluteus maximus just proximal to its insertion on the femur until more than 90° of hip flexion is possible. In general, all the short external rotators including the piriformis and gemellus should also be released, and sometimes an incision in the posterior capsule is needed if it is contracted and preventing internal rotation. In most children, this treatment needs to be combined with addressing the severe hamstring contracture, which can be accomplished by proximal hamstring lengthening through the lateral incision. This procedure is somewhat more difficult than doing it through the medial approach because the sciatic nerve is more in the direct approach to the muscles.

Postoperative Management

After muscle lengthening, focus needs to be on gaining range of motion, especially adduction and flexion, as well as keeping children positioned in hip flexion and adduction. Children's primary seating chairs need to have at least an 80° back-to-seat angle so that they will be sitting with more than 90° of hip flexion. There is an initial tendency for this position to be somewhat uncomfortable for these children, and parents and therapists also want to position the children with a seatback angle at 110° or 120°, but this just fosters recurrence of the hip extension and abduction contracture. Parents are also encouraged to have children side lying during sleep. The most common problem after this muscle lengthening is recurrence of the contracture, and postoperative monitoring should focus primarily on this recurrence.

For the moderately or more severely involved abduction contracture defined as those with less than 45° of hip flexion and less than 0° of hip adduction, a varus shortening osteotomy to reposition the lower extremity should be included in the treatment. This osteotomy should be the primary procedure for adolescents who have neared skeletal maturity and for children who have had protrusio acetabuli. Again, the rehabilitation following this procedure should focus on getting children back up into the wheelchair quickly, working on range of motion to maintain the adducted position, and working on hip flexion. These are the primary postures that need to be corrected to have good sitting posture.

Hip Flexion Contracture

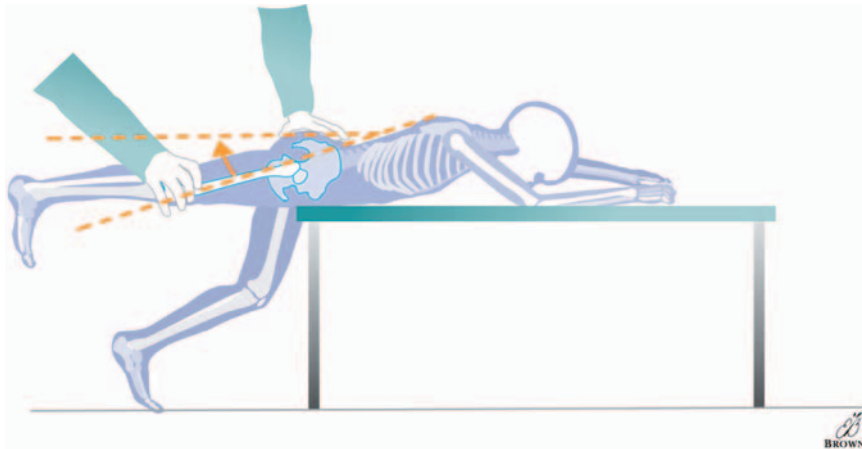
Fixed hip flexion contracture is a very common deformity present in adolescents or young adults who have CP and spend almost all their time sitting in a wheelchair. This deformity becomes part of their wheelchair posture. If individuals are nonweight bearing, the flexion contractures themselves are not usually of much significance. For adolescents or young adults who are doing transfers or household ambulation, a hip flexion contracture of 30° to 40° is usually well tolerated by compensatory lumbar lordosis and does not need to be treated. For children who ambulate independently, a hip flexion contracture that yields a Thomas test of 20° to 30° often causes increased lordosis and prevents full hip extension in midstance phase, and is therefore somewhat restrictive. In this situation, lengthening the hip flexors may be indicated, but care should be taken that the disability from loss of hip flexion power is not greater than the flexion contracture. Occasionally, some children or adolescents develop severe hip flexion contractures up to 90° to 100°. However, this is quite rare in individuals who do not have some concomitant paralysis. This pattern of contracture is primarily encountered in those individuals who have concomitant spinal cord injury or spina bifida with their spasticity. When this type of severe hip flexion contracture develops, it

is almost always in the context of an equally severe knee flexion contracture, and if treatment is contemplated, both must be addressed simultaneously.

Assessment and Measurement of Hip Flexion Contracture

Several different techniques for measuring hip flexion contracture have been proposed and evaluated; however, each technique has its positives and negatives. Techniques are rated on variable ease of use, reliability, and reproducibility. The supine test in which the opposite leg is flexed to flatten the lumbar lordosis and the hip flexion recorded, known as the Thomas test, is the easiest to use in an outpatient clinic. The prone hip flexion test is done with a child lying prone as both legs are dropped off the end of the bed so that the lumbar lordosis is reduced. With the child in the prone position and both hips flexed, one leg is gradually extended until movement is palpated in the pelvis (Figure 10.9). This test may be slightly more accurate and

A



B

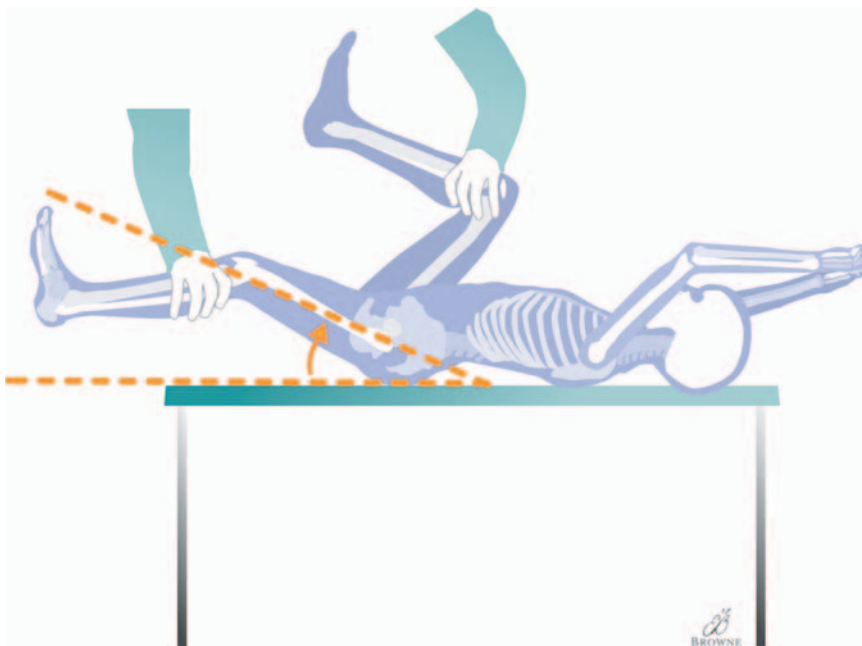

Figure 10.9. Physical examination measure of hip flexion contracture is often difficult. The prone hip flexion test as described by Staheli is useful for a smaller and cooperative child (A). For an uncooperative child or a very large individual, the supine test as described by Thomas is easier and reasonably reliable (B).

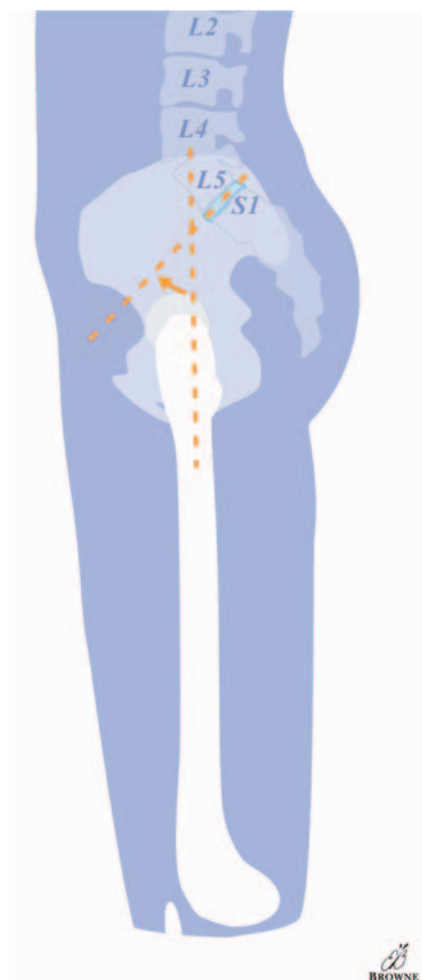

Figure 10.10. If there is a need to assess the degree of hip flexion in stance compared with the amount of lumbar lordosis, the radiographic sacrofemoral angle can be measured by obtaining a lateral standing radiograph that includes the lower lumbar spine to the distal aspect of the femur. A line is then drawn across the anterior aspect of the superior end plate of L5 and a line is drawn along the long axis of the femur. The subtending angle is normal between 45° and 60°. A lower angle indicates increased hip flexion in stance and a higher angle indicates abnormal hip extension in stance.

reproducible.⁸⁹ The prone hip flexion test is used in the gait laboratory when more accurate measurements by physical examination are obtained. For children who can stand independently, radiographic measurement of the lumbo-sacral femoral angle can be used (Figure 10.10). This is the measure we prefer when wanting to carefully measure hip flexion contracture in standing individuals, although it is still difficult to determine whether this increased sacral femoral angle is due to hip flexion contracture or caused by a compensation for lumbar lordosis.

Etiology

The etiology of hip flexion contracture in individuals who are nonambulatory and spend all their time sitting in a wheelchair is that they are not getting stretched out of that wheelchair posture. For these children, learning to spend time in the prone, stretched-out position, especially at night as they are growing, is important. Also, many adolescents who are going through their adolescent growth spurt are gaining weight and becoming heavier, and there is a tendency for caretakers and school personnel to stop placing them in standers and stretching them out because of the difficulty in moving the children. As a consequence, these individuals are spending increasing time in the wheelchair seating position and less time getting out of the wheelchair and having their hip flexors stretched out either by prone lying or by therapy exercises during their most rapid growth period. These hip flexion contractures occur most rapidly during the adolescent growth period, although they continue to become more fixed if children do not stretch into the young adulthood phase.

Natural History

The natural history of hip flexion contractures is of slow progression through childhood. In nonambulatory children, especially during adolescence, these hip flexion contractures become much more severe. Also, hyperlordosis tends to develop during this time, and it is not clear whether this hyperlordosis develops as a response to the increased flexion contracture or if the increased flexion contracture is the cause of the hyperlordosis. The two often increase simultaneously and one is probably feeding into the other rather than one being the cause and the other being the secondary compensatory effect. For many children, their primary adduction and abduction contractures or windblown deformities result from fixed hip flexion contractures, because when they lie supine, they have a tendency to either abduct or adduct and are unable to lie easily with hips extended in a comfortable position. As these children tend to consistently fall to one side or another, the hips start developing adduction or abduction contractures based on their predominant posture.

Treatment

In many children, the hip flexion contracture is really a secondary deformity. For instance, in children with spastic hip subluxation, the primary deforming force is the adductors. In children with windblown hips, combined adductor and contralateral abduction contractures are often the primary causes. In these individuals, the hip flexion contracture is frequently treated as the secondary deformity, which is appropriate. In these situations, lengthening of the iliopsoas is the primary treatment for the hip flexion contracture because it is the primary hip flexor. Children who are nonambulatory,

or are not anticipated to be ambulatory, should have a complete tenotomy of the iliopsoas tendon well above the lesser trochanter to avoid formation of heterotopic ossification. In children who have ambulatory capability, it is important to do a more proximal myofascial lengthening so that the iliacus muscle is left intact and only the tendon of the psoas muscle is lengthened. This lengthening helps to reduce pressure on the hip joint and also treats the hip joint flexion contracture. In many of these children, the initial Thomas test may be 20° or 30° in the operating room, and then reduces to 0° following lengthening of the iliopsoas muscle. In older children, the iliopsoas is often not isolated as the cause of the hip flexion contracture, but the cause includes the pectineus. Therefore, performing a myotomy of the pectineus if sufficient extension is not obtained by lengthening only the iliopsoas is reasonable. Again, this should be considered primarily in nonambulators, as doing too much hip flexor lengthening will greatly reduce the strength of the hip flexor for ambulators and cause significant disability during ambulation. If the hip flexion contracture is associated with abduction, it often involves a contracture of the tensor fascia lata, which should be sectioned at the same time. It is important in ambulators to be very conservative in lengthening of hip flexors because hip flexor weakness will make it difficult for them to advance their legs, step up on curbs, and use stairs, as well as get onto buses. Also, these individuals often complain that it is difficult to step into bathtubs.

In nonambulatory children with more severe flexion contractures than previously discussed, sectioning the sartorius and rectus femoris as well may occasionally be reasonable. However, these additional muscle lengthenings seldom provide sufficient length to gain the amount of extension that is desired because the neurovascular bundle is often tight as well, making further soft-tissue lengthening difficult.

Osteotomy

Extension osteotomy is the treatment of choice for severe hip flexion contractures with more than 45° Thomas tests and also after spinal fusion has been performed to reduce lumbar lordosis. The extension shortening osteotomy is especially useful if there is unilateral flexion contracture that has been difficult to resolve. An ipsilateral knee flexion contracture is often present; therefore, it is important to treat both the hip and knee flexion contracture at the same time or the hip flexion contracture will continue to be present functionally because children are unable to extend the knee for standing. It is important to realize that a combined knee and hip contracture cannot be treated by proximal shortening extension osteotomy with the goal of having the soft-tissue sleeve become lax enough to allow full extension at the knee by doing just a knee capsulotomy or knee hamstring lengthening. We have attempted this procedure on two occasions and found that the soft-tissue sleeve was too adherent and could not be shifted. In this circumstance, both a distal and proximal femoral osteotomy may be needed because both joints should be addressed as independent problems.

Treatment of hip flexion contractures will work only in individuals who will routinely use the end of the range, which is obtained by either the osteotomy or soft-tissue lengthening. This outcome is certainly true for knee flexion contracture treatment as well. If individuals sit in a wheelchair in the wheelchair posture all the time, and never stretch out, these contractures will redevelop. These contractures are best treated in individuals who do a significant amount of household walking as a minimum. Treatment of these contractures tends to have a high failure rate in individuals who are only doing transfer weight bearing.

Windblown Hips

Windblown hips are relatively common in children with quadriplegic pattern involvement in whom one hip develops internal rotation, adduction, and hip flexed posture, whereas the other hip becomes abducted, externally rotated, and often flexed, although sometimes extended at the hip. This severe form of asymmetric posturing starts occasionally becoming a fixed deformity as young as age 3 or 4 years, but is more typically clinically apparent in late childhood at around 8 to 10 years of age. This asymmetric posturing becomes a real problem during adolescence as children are having a significant amount of longitudinal growth. The windblown hip deformity describes the position of the hips relative to the pelvis and, as such, is a different deformity than pelvic obliquity. This deformity is often associated with pelvic obliquity in the same child. Also, the adducted hip in the windblown hip syndrome may have varying degrees of hip dysplasia to full dislocation present, although in some children the hips remain normal.

Etiology

The exact cause of windblown hip deformity is not known; however, asymmetric activity of the muscles in very young children has been associated with its development.⁹⁰ Also, unilateral hip surgery has been shown to lead to later windblown hip deformity.^{91, 92} The impact of soft-tissue surgery, in attempting to develop or regain symmetry, is very complex. If children present with very asymmetric muscle activity, then soft-tissue lengthening should be asymmetric in an attempt to gain symmetry; however, it is extremely difficult to predict exactly how much asymmetric surgery should be done to gain symmetry (Case 10.4). In our review of soft-tissue lengthenings, 10 children had asymmetric surgery, meaning they had either the addition of an anterior branch obturator neurectomy or had the adductor brevis resected on one side and not the other. Of the 10 children who had asymmetric surgery, 6 had an asymmetric MP before the soft-tissue lengthening. At follow-up, 6 still had an asymmetric migration index; however, 4 of the 6 who were asymmetric at follow-up were initially symmetric on radiographs.¹² Based on the assessment of these patients, no good, rational reason of how to precisely do asymmetric surgery to make children become symmetric at final follow-up and avoid the windblown hip deformity could be given.

Asymmetric Neurologic Involvement

The etiology of windblown hip deformities falls into two groups. One group, which is the least common, includes children who have a very asymmetric neurologic disability with a postural drive into abduction, external rotation, and extension on one side and flexion, internal rotation, and adduction on the other side.⁹⁰ As these children get older, this position becomes more fixed by the development of fixed muscle contractures, and overcorrection by surgical release is almost impossible. Scoliosis and pelvic obliquity secondary to lordoscoliosis often occur as early as 6 to 10 years of age in this group. These children tend to get progressively worse, and it can become extremely difficult if not impossible to provide seating if the hip and spine deformities are not addressed aggressively in late childhood or very early adolescence. These children also tend to have severe quadriplegic spastic involvement patterns.

Symmetric Neurologic Involvement

The second and much more common cause of windblown hip deformity is demonstrated by children who are very sensitive to asymmetric surgery^{91, 92}

and who have high tone bilaterally as young children between the ages of 2 and 6 years. For these children, it is often very difficult to determine any asymmetry in the severe adductor, internal rotation, and hip flexor tone as well as increased hamstring tone. Very often, however, the MP in one hip is higher, and under anesthesia, the contracture on one side is asymmetric (Case 10.4). The etiology of the windblown hip deformity in these children is one in which high tone on both sides is present; however, one side gradually develops slightly more adduction, forcing the other side into abduction. This asymmetry of power continues to develop, and as the adducted hip becomes more abducted, the adductors have more mechanical advantage and can overpower the adductors on the opposite side, which have less mechanical advantage as the hip is starting to abduct. As the hip abducts over center, the adductor muscles lose all their mechanical advantage, and this advantage shifts to the abductors and external rotators. This process follows the analogy of a tree that starts to lean, and as the tree continues to lean, its tendency will be to fall over in the direction that it is leaning. Many children with windblown hip deformities start with this gradual lean, in which it is impossible to tell early on in what direction they are going.

As this windblown deformity develops, it becomes progressively more fixed, and when children are placed in a seating position, the pelvis is forced into a position of pelvic obliquity to allow both legs to be placed on the seat. This is the etiology of infrapelvic pelvic obliquity. No evidence exists that this infrapelvic pelvic obliquity goes on to cause scoliosis or any other spinal deformity, although parents and caretakers are often concerned that this may occur. In some circumstances this windblown deformity causes a pelvic obliquity that feeds into a suprapelvic pelvic obliquity, which is caused by the development of scoliosis. Because both the scoliosis and the pelvic obliquity seem to progress most rapidly during adolescent growth, they may be present in the same patient, feeding on each other to make the pelvic obliquity progress. This rapid progression of the pelvic obliquity during rapid growth in adolescence may also force the adducted high hip into fairly rapid dislocation because of the much more fixed adducted position that the hip is taking. Likewise, on some occasions in a mildly subluxated hip, if the hip ends up being on the downside of the combined windblown pelvic obliquity progression, it may actually relocate and become normal.²⁵

Natural History

The natural history of a windblown hip deformity typically starts in middle childhood and starts developing fixed contractures by late middle childhood. The asymmetric muscle tone and fixed contractures tend to progress most rapidly during the adolescent growth spurt, and the disability from difficulty seating also becomes substantially more noticeable. Many of these children also develop scoliosis with pelvic obliquity, and if this deformity is allowed to progress without intervention, the natural history is for it to become very severe and fixed to the point of making it almost impossible for these children to be placed in a seated position.

Treatment

Treatment of windblown hip deformity should begin with stretching exercises and proper positioning.^{54, 90} Quantitative documentation of the ability to prevent windblown hip deformity by using exercises and positioning is not available. The use of cast immobilization or orthotics is often mentioned; however, there is no documented positive benefit in any significant group of

children over their full growth period.⁹³ Asymmetric surgery, either muscle lengthening or femoral osteotomy,^{91, 92} has a definite negative effect in some children, and the goal of correcting the asymmetry by doing asymmetric surgery also does not have a very predictable outcome.^{12, 91} Correcting the asymmetry has been attempted, but the children must continue to be followed throughout the whole growth period and repeat corrections may need to be done as they grow.

Indications for Specific Treatment

The usual indication for treatment of asymmetric hip positioning in young children, meaning under age 5 years, is the presence of a subluxated hip. Therefore, indications for treatment are primarily directed by the physical examination and radiographs of the hip dysplasia. In children, bilateral adductor surgery should always be performed, regardless of whether the radiographs are asymmetric, unless there already is a definitely fixed abduction contracture present. This fixed abduction contracture has to be severe enough that neutral positioning is not possible. Even in children who have relatively good abduction on the contralateral side from the subluxated hip, adductor lengthening should be done at this young age because the deformity will invariably switch if unilateral surgery is performed (Case 10.4). There is almost never an indication to do surgical treatment for asymmetric hip deformities in childhood if the hip radiograph is normal. At this age, continuing with range-of-motion exercises and positioning is preferred.

Middle Childhood

In middle childhood, from ages 5 to 10 years, the most usual indication for treatment continues to be the presence of a subluxated or dislocated hip. The treatment of the asymmetric contracture is again directed by indications based on the hip subluxation. If the hip radiograph is normal, the abduction contracture is increasing so that passive adduction is limited to less than 0°, and a fixed adduction contracture is present on the opposite side, problems with seating are usually beginning. Children at this age, who have this degree of contracture and the beginnings of some difficulty with seating, are indicated to have muscle lengthening, usually adductor and hip flexor lengthening on the adducted side and a limited abductor lengthening and external rotator release on the abducted side. In middle childhood, care must still be taken to not do a too aggressive lengthening of the adductor on the adducted side or the abductor on the abducted side, as this whole deformity may completely reverse and become windblown in the opposite direction.

Adolescence

In late childhood and early adolescence, between the ages of 8 and 12 years, the windblown deformity usually first presents as a substantial functional disability. If children have not been previously managed appropriately, hip radiographs may still show hip subluxation, which needs to be the primary indicator driving the appropriate surgery to be performed. Again, at this age, if the hip radiograph is normal in a reconstructed hip with a developing windblown deformity, not allowing it to become too severe is important. At this age, muscle lengthening surgery is recommended if the adduction on the abducted side is less than neutral, and if there is a significant fixed adduction contracture on the opposite side. Muscle lengthening can be much more aggressive at this age, especially if it is following hip reconstruction surgery. The risk of overcorrecting and having a windblown

deformity going in the opposite direction is small. If the hip has become very severely contracted, but radiographs are still relatively normal, femoral varus shortening osteotomies and aggressive muscle adductor lengthenings should be considered.

Adult

The windblown hip deformity, when it initially presents or has become a significant problem in full adolescence or young adulthood, is usually a very fixed deformity. If this deformity presents primarily a seating or perineal care problem but the hips are radiographically normal, then either an attempt at muscle lengthening is indicated or a bony reconstruction is required. In general, if the hips have been reconstructed and the acetabulum and femoral head have a congruent joint, an attempt at soft-tissue lengthenings should be the first priority. However, if the hip abduction deformity is such that the amount of adduction that can be obtained is less than -30° , the possibility of correction with muscle lengthening alone is not good. Most of these hips have severe coxa valga of 160° to 180° , which makes muscle balancing almost impossible. At this age and stage, overcorrection is not a concern; therefore, complete release of all the abductors, hip extensors, and external rotators may be performed without worry of either overcorrecting or causing a hip dislocation. If muscle lengthening is to be performed, all the muscles of the greater trochanter in the muscle tendinosus portion should be released, including all the gluteus medius and tensor fascia lata (Case 10.30).

There is a significant contracture of the gluteus maximus in some patients, and in others there is more of a hip flexion contracture present. The contracted muscle should be released; however, if the gluteus maximus is allowing hip flexion to 90° , there is no need for it to be released. On the adducted side, all adductor muscles, including the pectineus, anterior branch obturator neurectomy, and all the adductor brevis, gracilis, and adductor longus have to be incised. If some contracture continues in the adductor, the magnus should be sectioned as well. If all the medial hamstrings are noted to be tight, they should be sectioned through the medial approach.

Contracture of the hip capsule is present in some young adults, and the hip capsule can also be incised through the medial approach; however, if the deformity is so severe that the hip capsule needs to be incised, there usually is not good maintenance of this release. This is especially true if there is any incongruity in the femoral head so that it is not completely round. In this situation, it is far better to just do a valgus shortening osteotomy on the adducted side and a varus shortening osteotomy on the abducted side. In severe and neglected cases in late teenagers or young adults, the abducted deformity may become very fixed with the addition of protrusio acetabuli. After correction by osteotomy, this abducted hip may remain painful due to the degenerative arthritis caused by the prolonged high pressure and protrusio.

Other Treatment Options for Windblown Hips

Orthotic Management

It is very difficult to conceive of an orthosis in which the windblown hip can be corrected. Almost every hip abduction orthosis works by abducting one side of the hip against the other (Figure 10.11). In the windblown hip deformity, the hip that adducts will invariably follow the hip that is abducted; therefore, this abductor bracing will make both the hip deformities worse. For this reason, hip abduction orthoses may often be the cause of windblown hip deformities, and there is almost no imaginable reason why hip abduction bracing would be useful. Several attempts have been made to



Case 10.30 Cody

Cody, a 14-year-boy with severe quadriplegia and mental retardation, was evaluated based on the caretaker's primary complaint that he could not sit (Figure C10.30.1). There was mild pain in the right adducted hip with at-

tempts to range the hip into abduction. On physical examination the hips were noted to be in a severe wind-blown position with a dislocated right hip and severe coxa valga (Figure C10.30.2). He had a reconstruction with a

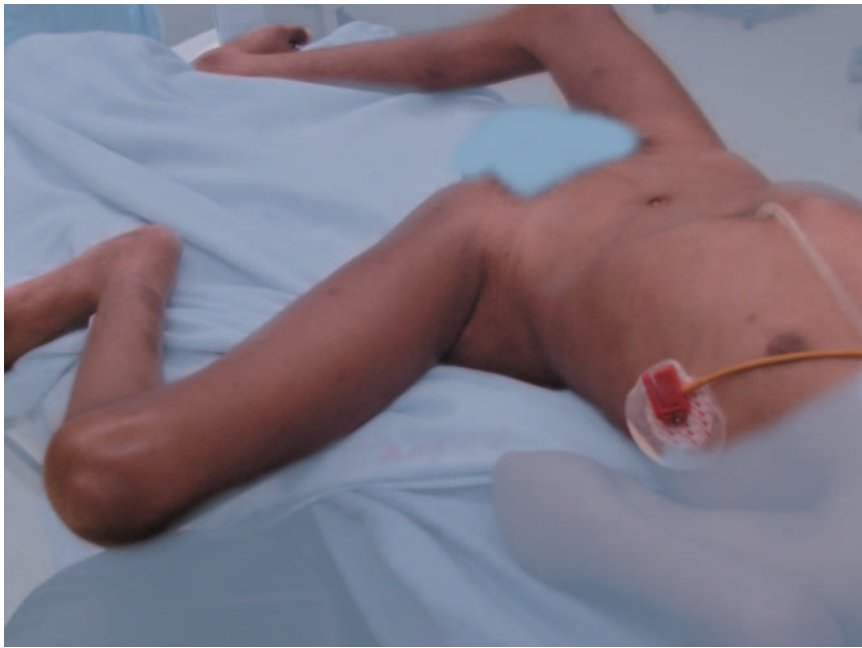

Figure C10.30.1

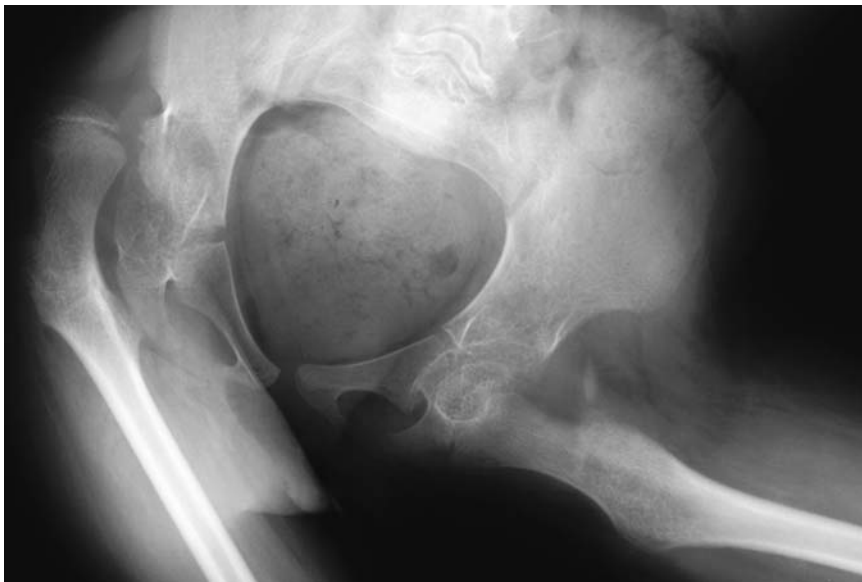

Figure C10.30.2

right pelvic osteotomy and extensive bilateral femoral varus shortening osteotomies. The right adductors and left abductors were also released. Good symmetry was obtained after the surgery (Figure C10.30.3). This symmetry was maintained for 3 years, up to age 17 years when

he was last seen. In the interim 3 years, he developed a proximal femur fracture on the right, which was treated by removing the blade plates and repeat plating of the fracture (Figure C10.30.4). He was at low risk for development of a recurrent windblown deformity.

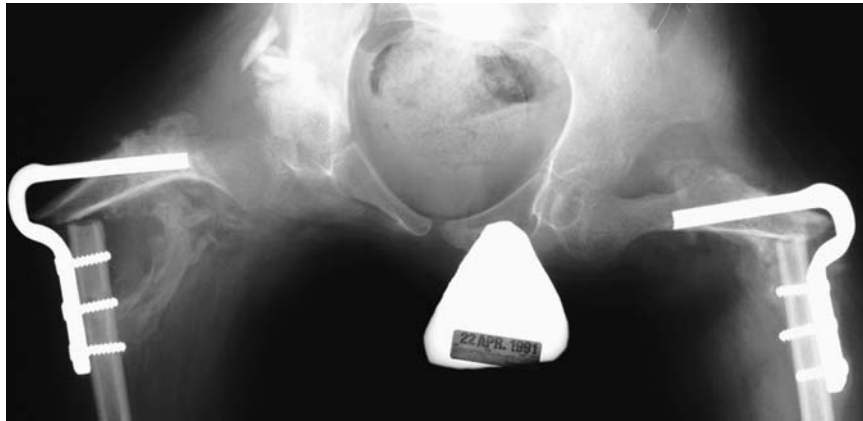


Figure C10.30.3

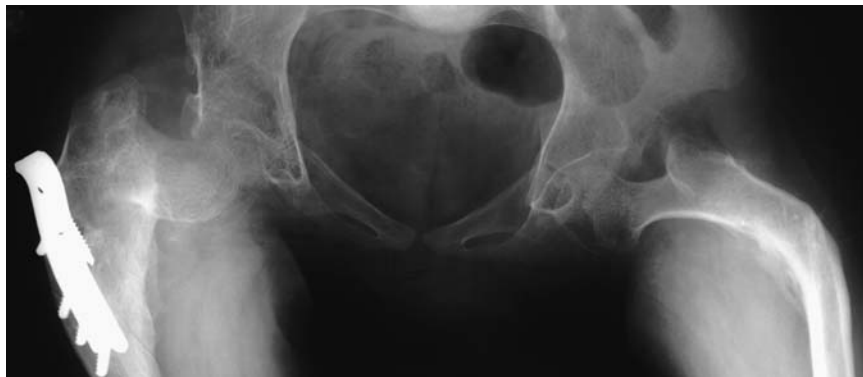

Figure C10.30.4

design seating systems to correct the windblown hip deformity. The windblown deformity produces a pseudo-Galeazzi deformity where one leg appears longer when children are sitting. Anterior pads are placed against the knees to force the apparently longer leg back and try to control the pelvic rotation (Figure 10.12). Theoretically, this should work; however, it is so uncomfortable that these children cannot tolerate staying in this device for very long.

Tone Reduction

Almost all children who develop windblown hip deformities have moderate to severe lower extremity spasticity and most have quadriplegic pattern CP. There is no documented benefit from doing tone reduction procedures, such as dorsal rhizotomies or intrathecal baclofen, to prevent the development of a windblown posture. There may be less risk of developing

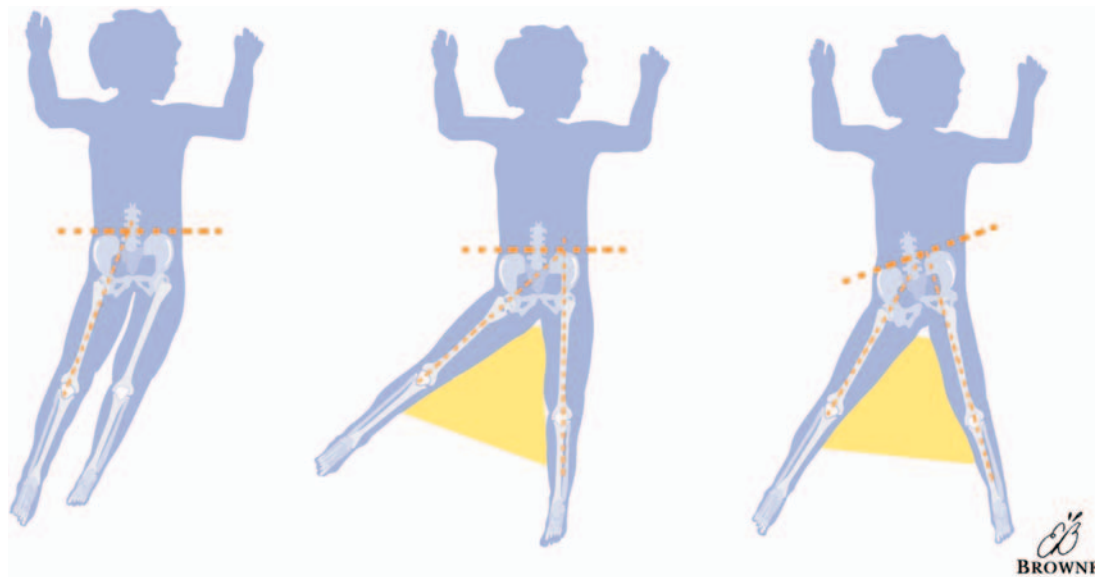


Figure 10.11. Abduction bracing of the hips to stretch hip adductors has a very high incidence of causing the development of a windblown hip deformity. Unless the orthotic has a way to be rigidly fixed to the pelvis, which can only be done by the use of percutaneous pins, the counteracting force is always the opposite limb. This means the net force will be the same in both limbs, so if one adductor is strong, either more spastic or more contracted, it will equalize the force to the weaker, less spastic or less contracted hip, causing it to abduct further. As the abducted hip increases its abduction, the adducted hip becomes more adducted, which is the exact development of the windblown hip deformity.

windblown deformity when young children have undergone dorsal rhizotomy; however, this is not documented and, in our opinion, the decrease in windblown deformity is easily eclipsed by the high frequency of severe hyperlordosis that many of these children develop. Botulinum toxin and phenyl blocks are too short acting to have any long-term benefit on the development of windblown deformities, which occur over the whole childhood growth period and especially during the adolescent period of development. The use of intrathecal baclofen presently has too short a history of clinical use to have produced any evidence as to whether it provides any benefit.

Windblown Hip Deformity and Pelvic Obliquity

A full discussion of pelvic obliquity is presented in Chapter 9. There are two identified patterns of pelvic obliquity, of which one is the infrapelvic pelvic obliquity. In the infrapelvic pelvic obliquity, the obliquity develops because of fixed contractures in the hip joints, more specifically the windblown hip deformity. The infrapelvic pelvic obliquity resolves when the windblown hip deformity is corrected. The other type of pelvic obliquity, suprapelvic pelvic obliquity, is caused by scoliosis, which causes the pelvis to go into obliquity because of the position of the spine (Figure 10.13). Suprapelvic pelvic obliquity may cause the hips to develop a windblown hip deformity; however, there is no indication that the scoliosis and pelvic obliquity will cause a fixed windblown deformity, or that the infrapelvic pelvic obliquity caused by the windblown hip deformity will cause scoliosis. Both these obliquities frequently progress rapidly during adolescent growth and probably feed into each other, each making the other progress even faster. In a situation where the pelvic obliquity that was caused by windblown hip deformity and the scoliosis are progressing rapidly, if treatment is contemplated and both the scoliosis and the hip deformities are severe, then the spine should be corrected first to provide a stable pelvic base into which to reduce and correct the hip deformities. The hip surgery should be performed approximately 4 months after the spine surgery to avoid the development of heterotopic ossification (Case 10.31).

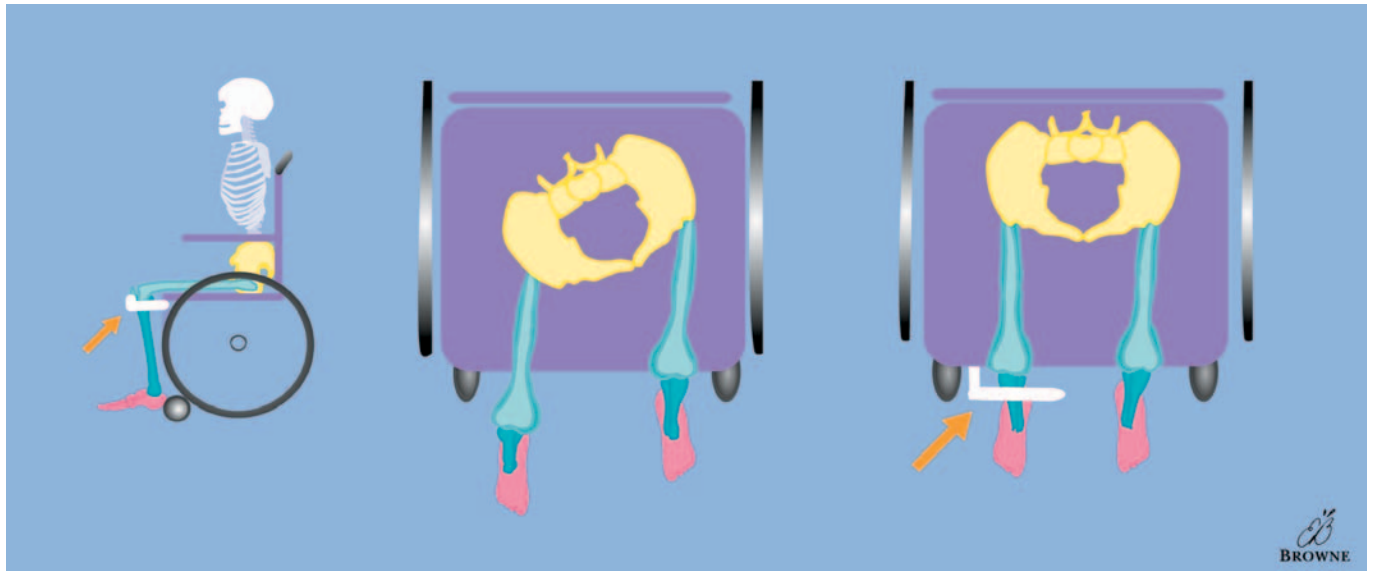


Figure 10.12. One mechanism for attempting orthotic management of a windblown hip is to use an anterior knee pad, in which the abducted hip is pushed posteriorly against the posteriorly restrained pelvis, in the wheelchair. This mechanism makes mechanical sense; however, most children do not tolerate the force that is required to really counteract the drive of strong abduction and adductor combination. This method does make sense as a possible prevention for mild symmetries or after muscle release, but patient acceptance is not good.

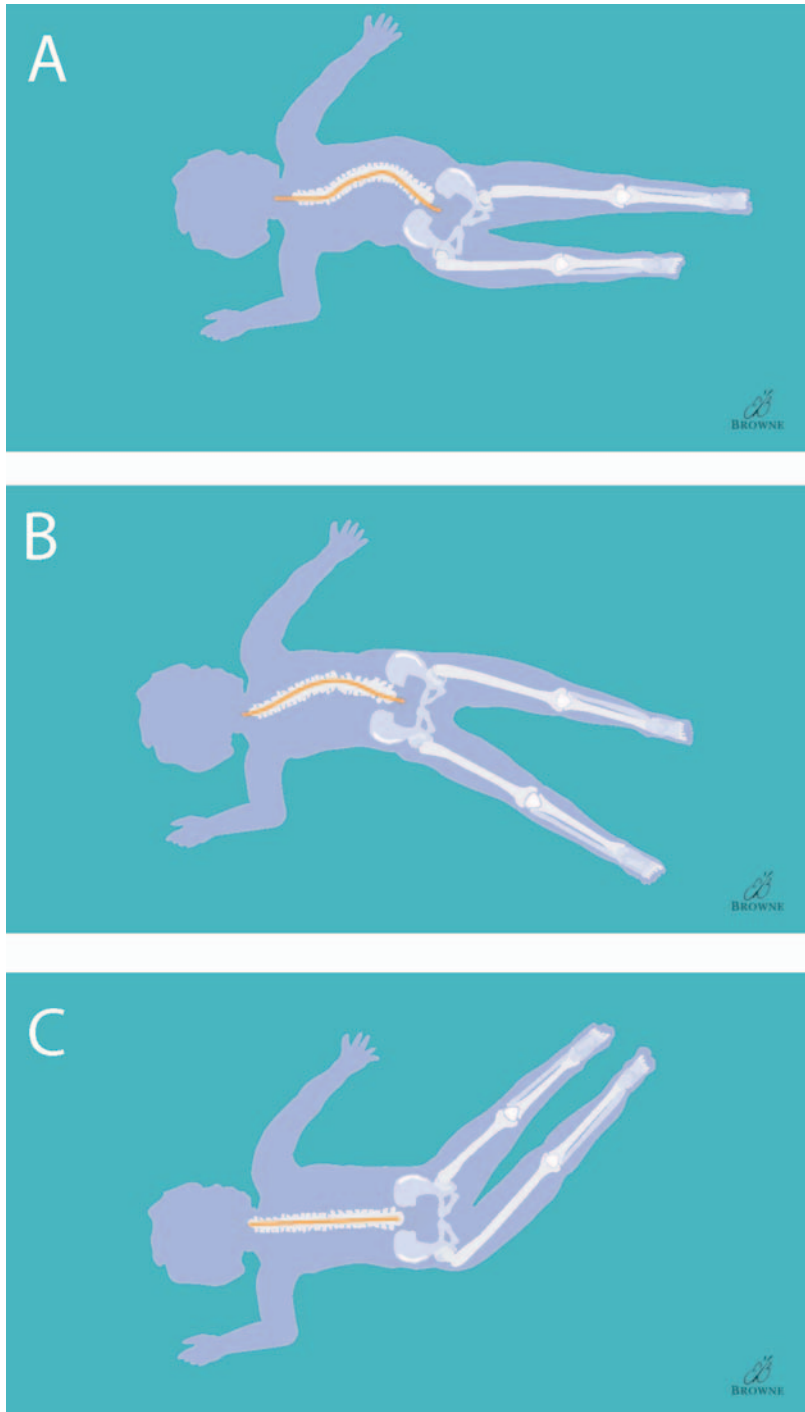
Anteversion, Coxa Valga, and Internal Rotation Contracture

Internal rotation deformity of the hip joint is the most common problem involving all children with CP because it affects highly functional walkers to dependent sitters. This internal rotation deformity causes problems with seating by making the knees cross the midline and the feet displace laterally, often outside the confines of the wheelchair, and places these children at risk for developing a foot or leg injury. For children who predominantly sit, this internal rotation deformity generally becomes most problematic in late childhood and adolescence as the contracture gets somewhat worse and the lower extremity is getting much longer. For ambulatory children, the internal rotation may be a substantial problem in early childhood as they are learning to walk and do not have very good motor control. Some of the motor control issues may help resolve this internal rotation; however, treatment is often required.

Anteversion and Coxa Valga Relationship

Many publications ascribe subluxation of the spastic hip to an increased femoral anteversion or internal rotation in addition to the coxa valga.^{94–97} However, modeling studies suggest that femoral anteversion, which is the torsion of the femur, has very little direct significance to hip subluxation.³ There may be some influence from this anteversion because the modeling studies do show that positioning of the limb is extremely important. When a substantial amount of anteversion is present, there is a tendency for the limb to want to fall into internal rotation, and when there are contractures of the hamstrings and hip flexors present, then the internal rotation almost always becomes a component of hip adduction. This combination of hip adduction with hip flexion is clearly the position that is the worst for the typical posterosuperior hip dislocation. Anteversion may have some indirect influence in developing this flexed adducted posture that children's lower extremities take preferentially. This same posture also tends to be present

Figure 10.13. The etiology of pelvic obliquity may be either suprapelvic or infrapelvic. Often the body is relatively straight with both scoliosis and pelvic obliquity (A). In suprapelvic pelvic obliquity (B), a fixed scoliosis is present that forces the pelvis into the oblique position. The hips then adapt. In infrapelvic pelvic obliquity (C), the hips develop a fixed windblown deformity that causes the pelvis to position in the oblique posture. The spine then accommodates with a flexible scoliosis posture.



in the windblown hip deformity; however, the severely abducted side of the windblown hip often has a significant amount of anteversion present as well, so it is not the anteversion directly that leads to the hip subluxation and adducted position.

Apparent Coxa Valga

Coxa valga, which is defined as an increased femoral neck angle relative to the femoral shaft, is present in some degree in almost all children with spastic



Case 10.31 Tatiana

Tatiana, a 15-year-old girl with a moderate spastic quadriplegia, presented with a complaint of severe right hip pain and greatly decreased ability to sit. She had mild mental retardation, spoke well, and self-fed, but was dependent in other activities of daily living. At age 10 years, she had a hip reconstruction that was extremely painful and she had severe difficulty tolerating the cast that was used following that surgery. Over the past year, the family reported that she had become extremely anxious as her hip pain had increased, which put great stress on her family caretakers. Physical examination was very difficult because of her anxiety. She had a significant degree of pelvic obliquity with scoliosis, definite pain with motion of the right hip, right hip adduction flexion contracture,

and a left hip abduction contracture. This windblown appearance was present while lying (Figure C10.31.1). Radiographs confirmed the physical examination (Figure C10.31.2). Because of her maturity and degree of scoliosis, this was thought to be a suprapelvic and infrapelvic pelvic obliquity and therefore both sides had to be corrected. She was first referred for psychiatric management of her anxiety, then the spine was corrected. Four months later, the hip was reconstructed (Figure C10.31.3) so she was in a normal lying position (Figure C10.31.4). She was comfortable in sitting and moving without any problems. This is a typical case in which the spine must be corrected first to get a successful correction of the hips even though the primary complaint is hip pain.

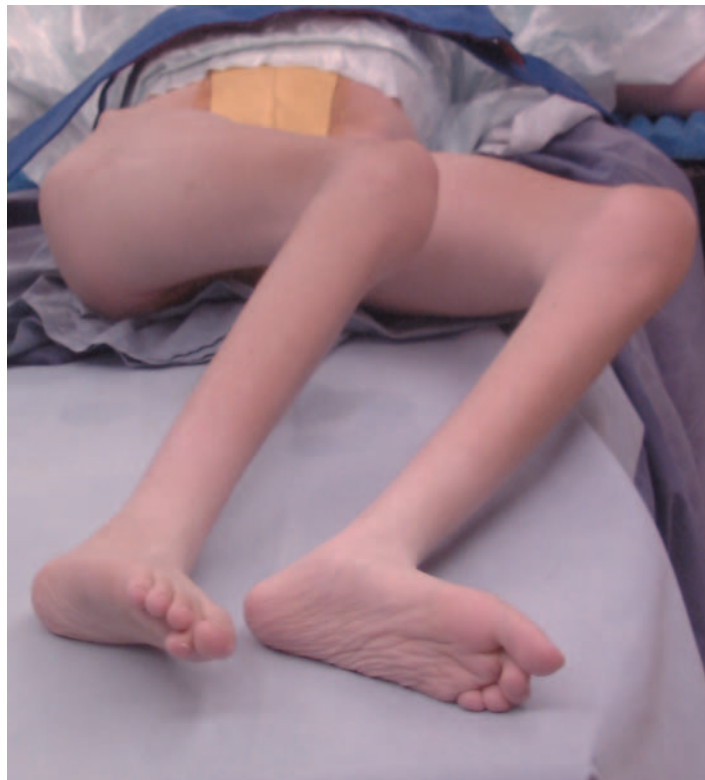

Figure C10.31.1

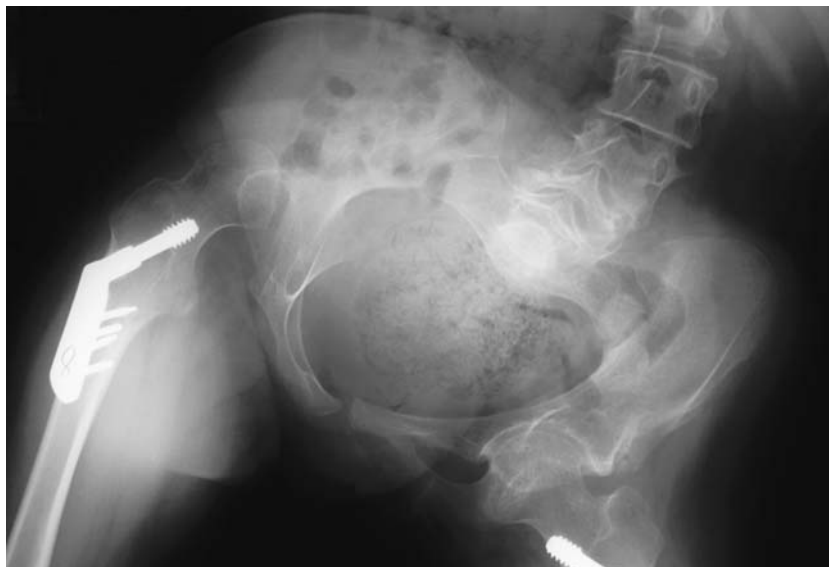

Figure C10.31.2

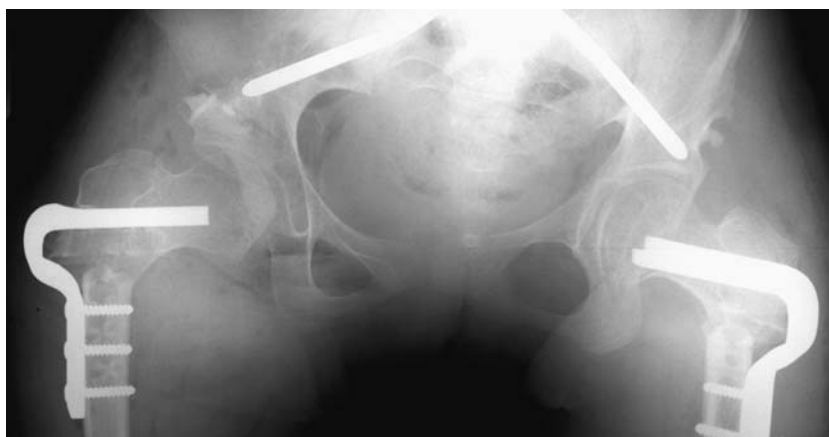

Figure C10.31.3

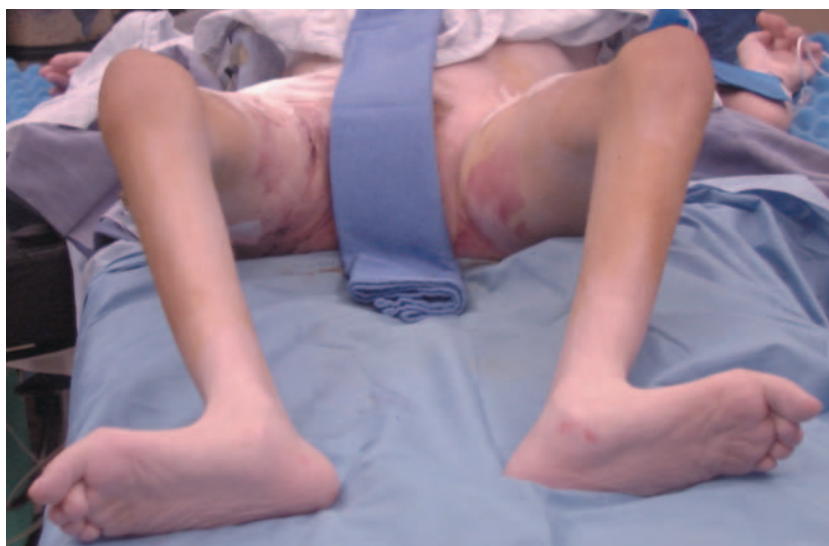

Figure C10.31.4

lower extremities, especially those who are nonambulatory. It is important to be aware that the valgus that is really present is almost always significantly less than is apparent on the typical anteroposterior radiograph. This apparently high coxa valga is secondary to increased femoral anteversion with the hip also positioning in internal rotation that many of these children prefer. This internal rotation gives the appearance of valgus and an oblique profile of the proximal femur. The relationship between coxa valga and femoral anteversion, as anatomical definitions of proximal femoral shape, are very important to understand when treating children with spastic hips.

Defining Anteversion

Femoral anteversion is typically described as internal torsion of the femur; however, a more specific definition demonstrates that this torsion can occur at different places along the femur. For example, if there is displacement of the epiphysis, such as happens in slipped capital femoral epiphysis, the presentation of external femoral torsion or retroversion appears. Fractures at the base of the neck may cause angulation, which causes either increased anteversion or retroversion, and the torsion may also occur anywhere along the femoral shaft. In children with CP, this torsion occurs as a gentle twisting throughout the whole shaft of the femur. Assuming that the torsion is present in the whole femoral shaft, the presumption can also be made that the proximal femur, with its muscle attachments on the greater and lesser trochanter, is in normal alignment with the femoral head and neck. Another common definition of anteversion that is used for measurement purposes is defined as the anterior projection of the femoral head and neck relative to a plane in the femur in line with the femoral knee joint axis. When using this concept of anterior projection of the femoral neck, extreme care must be taken to understand how this concept interacts with coxa valga. As the coxa valga increases, specifically as the femoral neck shaft angle goes from 90° in which all anterior projection is anteversion, to 180° of coxa valga, the anterior projection of the femoral neck no longer includes any degree of anteversion. It must be understood that if this measurement technique is used to measure anteversion, it must be used only when there is normal or relatively low degrees of coxa valga, primarily with coxa valga less than 120° . This understanding is very important in children with CP if measurements of anteversion and coxa valga are being made. As the coxa valga comes to 180° , its anterior projection is really an intertrochanteric flexion deformity of the femur and does not reflect anteversion at all.

Measuring Anteversion and Coxa Valga

There are many techniques for measuring femoral anteversion. Each of these techniques has its positive and negative attributes and each measures slightly different deformities; therefore, it is important to understand the specific technique that is being used when discussing a specific amount of anteversion or coxa valga.

Physical Examination

The physical examination measurement of anteversion is best done with children in the prone position, measuring internal and external rotation of the hip, and making sure there is no rotation of the pelvis. With the knee flexed, there is a very long lever arm with which to measure and record the degree of this range of motion. One of the problems of relying only on this physical examination range of motion is that it is very difficult to sort out the difference between internal rotation contracture of the muscles from bony femoral anteversion (Figure 10.14). This measurement of the range of femoral

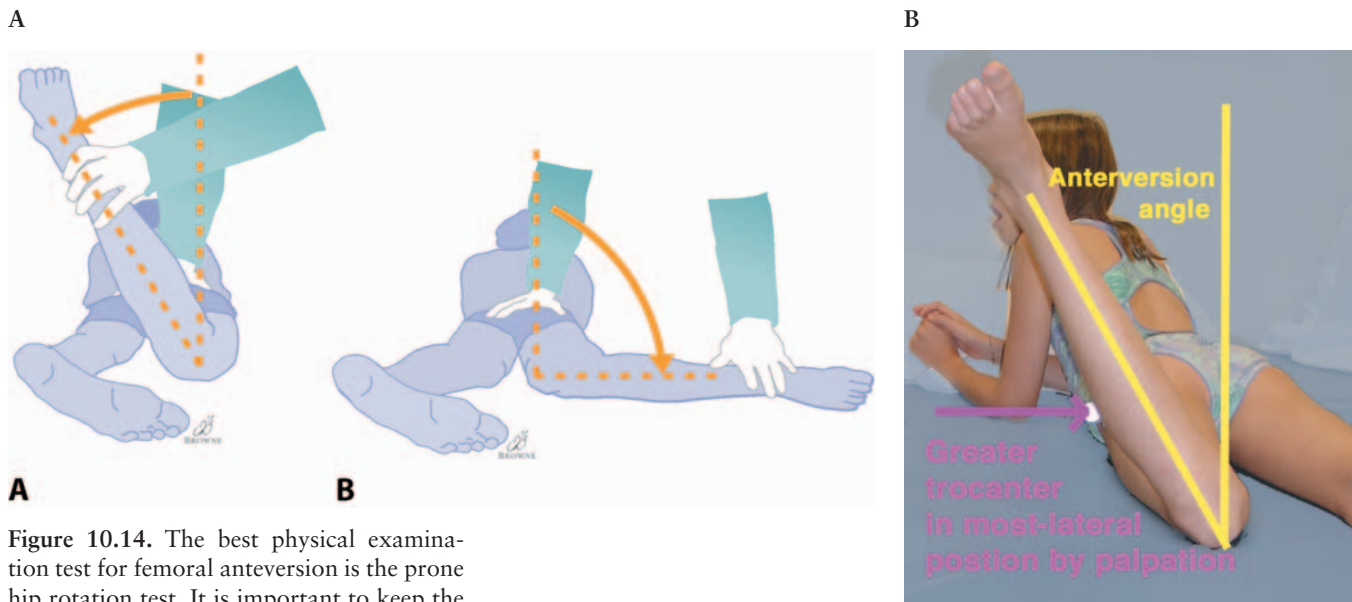


Figure 10.14. The best physical examination test for femoral anteversion is the prone hip rotation test. It is important to keep the pelvis stable, so a hand should stay on the pelvis to fix the pelvic position. The degree of internal and external rotation is then measured as the angle subtended by the tibia to the vertical line (A). Another physical examination measure of femoral anteversion is the prone hip rotation measure. With this measure, the greater trochanter is palpated, and when it is felt to be in the most lateral position, the angle of the tibia subtended to a vertical line defines anteversion (B). Accuracy of this measure is not very good.

anteversion can be combined with simultaneously palpating the greater trochanter on the lateral aspect. On palpation, when the greater trochanter reaches its most lateral position midway between anterior and posterior, this is the direct lateral position of the greater trochanter and therefore the proximal femur is in its sagittal plane profile. Measuring the degree of internal rotation at this point gives an estimate of the degree of femoral anteversion. This same measurement can also be made with the children lying supine, allowing the legs to drop off the end of the table with the knees flexed. The advantage of this assessment of anteversion is that it is extremely easy and simple; however, the disadvantage is that it is limited to individuals who are very slender and to those who have not had hip surgery, which would obliterate the palpable landmarks. This is the typical measurement of anteversion done in the clinic to continue to monitor children's internal and external rotation.

Radiographic Measurement

Standard radiographic measurements of anteversion were initially developed by Dunlap et al.,⁹⁸ using a positioning frame with known angles and then using triangulation calculations of anteversion and femoral neck shaft angle. This technique depends on absolute proper positioning, which is difficult in children with severe spasticity or contractures.⁹⁹ This technique also requires making calculations of the measured angles, or using look-up tables that are typically unavailable in the usual clinical environment. This technique is also not appropriate if the neck shaft angle is very high, specifically greater than 150°, because it presumes that the anterior projection of the femoral head and neck is femoral anteversion. When this assumption no longer holds true, specifically with neck shaft angles between 150° and 180° and less accurately between 150° and 120°, this technique cannot be used. This technique is mainly of historical interest because it was the first technique used to make a quantitative measurement of femoral anteversion and coxa valga, although it is seldom used today.

CT Scan

Computed tomography scan measurement is probably the most widely used clinical technique for measuring femoral neck anteversion. This tech-

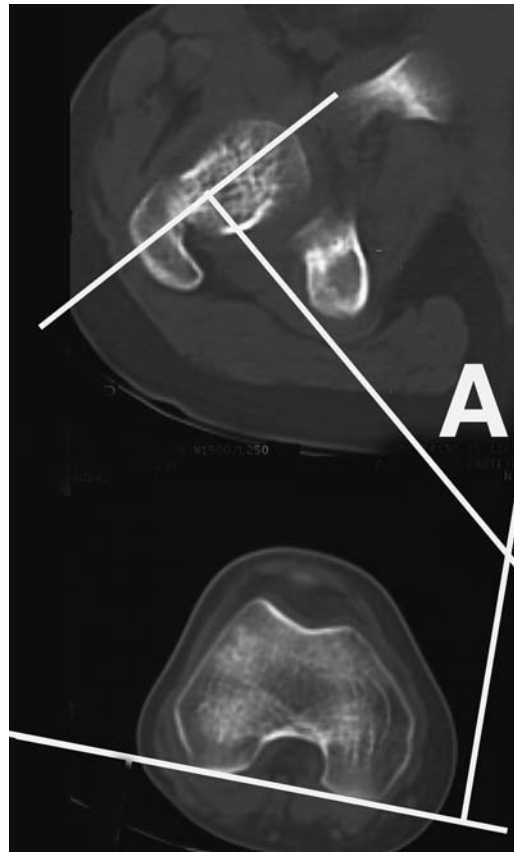


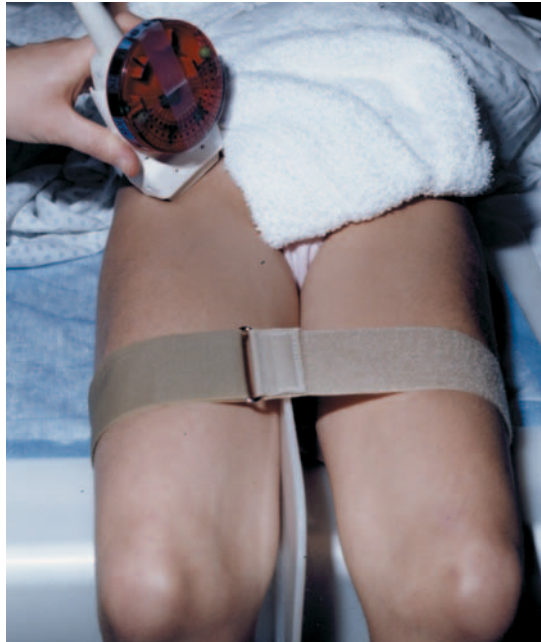Figure 10.15. Measurement of anteversion using CT scan is well defined and very accurate if the femoral neck shaft angle is normal. This method measures the anterior projection of the femoral neck relative to the knee joint axis as defined by the posterior femoral condyles. The two cuts must be made without moving the limb, and the angle subtended (A) defines anteversion.

nique assumes that the anteversion is measurable by the degree of anterior projection of the femoral neck, and because of this assumption, it is very important to understand its major limitation, namely, that it is limited to those individuals with relatively normal femoral neck shaft angles. The typical technique for using CT scan to measure the femoral anteversion is placing a child in the CT scanner so that the limbs are held in a fixed position that does not allow movement. Cuts are made at the level of the distal femur to define the posterior femoral condyles or the centers of the femoral condyles to define the knee joint axis plane, and then transverse cuts are made across the proximal femur to define the anterior projection of the femoral neck shaft angle (Figure 10.15). The angle between these two planes on the image is then measured as the anteversion.^{33, 34, 95, 100} Using overlying proximal femoral images has been described because, as the femoral neck shaft angle becomes more vertical, a single image no longer works to define the anterior projection. It is crucial to understand that as more of these images are layered on top of each other, femoral anteversion is no longer being measured; instead more anterior projection of the femur, which is the femoral head and neck to shaft flexion, is being gradually measured. Currently, CT is the most appropriate mechanism for measuring anteversion in individuals who have had hip surgery and are left with femoral neck shaft angles that are relatively normal, and have bony landmarks that may be difficult to define with ultrasound, which is another technique for measurement.

Ultrasound

Ultrasound has been described using several slightly different techniques that all involve some variation of positioning the limb. This recognized

Figure 10.16. Femoral anteversion can also be measured with the use of ultrasound. This technique requires positioning the limbs so the tibias are vertical; this defines the posterior femoral condyle. The ultrasound is used and the anterior flat plane of the extracapsular femoral neck is defined. An inclinometer is attached to the ultrasound head and when the flat plane is horizontal on the monitor, the angle can be read.



position defines the distal knee joint axis plane. Positioning should be followed by ultrasound imaging of the proximal femur, either of the femoral head and neck or the anterior flat surface.^{34, 84, 94, 101} The preferred technique for ultrasound measurement of femoral anteversion is positioning the patients in a device with their legs flexed over the end of the table and held in position so that the knee joint axis is parallel to the table on which they then lie. The ultrasound transducer is then fixed with an inclinometer. As the anterior plane of the femur is imaged, care is taken to make the image of the proximal femur parallel to the transverse plane on the screen (Figure 10.16). When the image is parallel, the degree of anteversion is read off the inclinometer. The areas of the proximal femur that can be imaged are the femoral head and neck, which then uses the same anterior projection of the femoral head and neck theory as used for CT scan and radiographic measurements. This technique is less accurate and suffers from the same problems as noted previously.³⁴ Using the anterior flat surface, which is the extracapsular anatomical projection of the proximal end of the femoral neck onto the femoral shaft, is favored. This area is a flat plane on the anterior aspect of the proximal femur, which is always parallel to the femoral neck. Intraoperatively, this anterior flat surface is used extensively for direction of implant insertion and is very reliable as a measure of femoral anteversion. This flat plane can also be measured on CT scan if the correct cut is made just slightly distal to the femoral neck.

Ultrasound has the advantage that it can be done relatively quickly and cheaply. After the ultrasound measurement of anteversion is made, children then can be turned into a prone position, and the limbs internally rotated to the degree of the measured anteversion. An anteroposterior pelvis radiograph should be obtained, which will provide a good measurement of the sagittal plane profile of the proximal femur and an accurate assessment of the coxa valga. The use of ultrasound to measure anteversion also has some drawbacks. First, it requires a technician who is trained and familiar in doing this technique as well as requiring some positioning devices for it to be done accurately. In some children with severe contractures and severe spasticity,

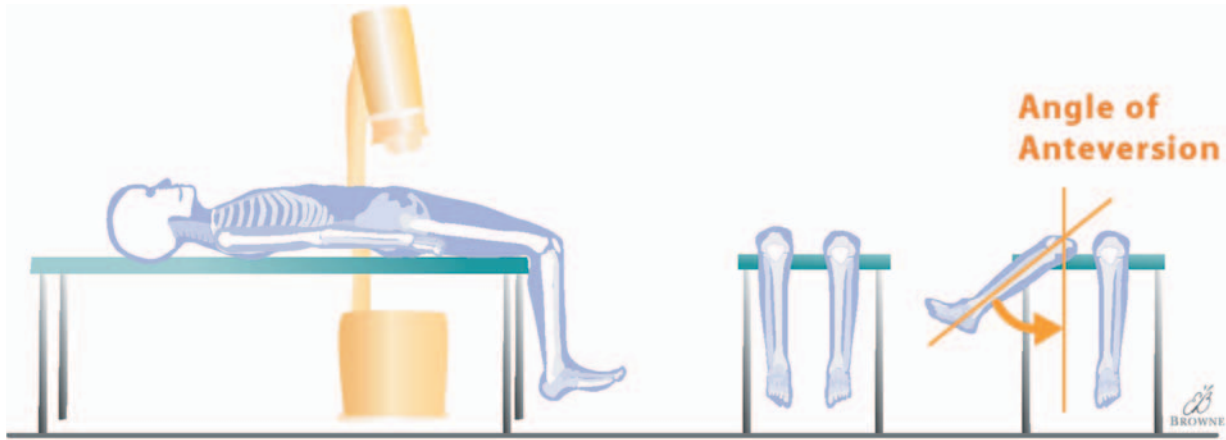


Figure 10.17. Femoral anteversion may also be measured using a fluoroscope. This technique also uses the posterior femoral condyles by dropping the feet off the table so the knees are flexed and the tibia is completely vertical. The proximal femur is imaged and the tibia is internally rotated until there is a true anteroposterior view of the proximal femur. The amount of internal rotation is now measured by using the tibia as the angle guide.

it is also not possible to place them into the positions that are required to accurately make these measurements. The second major area in which femoral anteversion measurements using ultrasound are not possible is in children who have had previous femoral osteotomies or surgery of the proximal femur. This surgery often obliterates the surface of the bone shaft with irregularities, which make determining the proper plane by ultrasound impossible. In summary, this technique of ultrasound measurement is best used to monitor children who have not had previous surgery if physicians feel this monitoring is necessary.

Fluoroscopy

Another technique for measuring femoral anteversion is with fluoroscopy. This technique involves observing the proximal femur and identifying that point when the amount of rotation of the femur has the anteroposterior projection of the proximal femur in its best profile. In this position, the degree of internal rotation is measured with the knee flexed, demonstrating the degree of femoral anteversion.¹⁰⁰ This position also allows obtaining a radiographic image of the proximal femur in maximum profile and allows measurement of the true coxa valga present (Figure 10.17). Other techniques using fluoroscopy have made radiographic images with the knee in its direct anteroposterior plane and then made a radiographic image with the hips internally rotated until the proximal femur is in full sagittal plane profile. Using triangulation, the difference in the length of the femoral neck is assessed to calculate anteversion. This technique does exactly the same thing as measuring the degree of internal rotation directly, but it adds the complexity and measurement errors inherent in having to measure the radiographs.²¹ The major problem with the use of fluoroscopy to measure femoral anteversion is that it requires a technician or radiologist who understands the concept to be present and requires the availability of a fluoroscopy suite, which often has to be scheduled. Fluoroscopy is the ideal mechanism for measuring anteversion in the operating room when hip reconstruction is contemplated. In this situation, the fluoroscope is available in the standard operating procedure and checking the degree of anteversion and getting an accurate assessment of proximal femoral coxa valga adds no additional time.

Magnetic Resonance Imaging Scan

One study reports using magnetic resonance imaging (MRI) scan to measure femoral anteversion and documents that the MRI scan has the same accuracy and problems inherent with CT scan.¹⁰² The main reason for using

the MRI scan over the CT scan is if a CT scanner is not available, or if a child is having an MRI scan for another reason and there is a desire to measure femoral anteversion at the same time. No other major benefits are known, and certainly the bone image is never quite so good on MRI scan as it is on CT scan.

Measurement Summary

There are many methods for measuring femoral anteversion and femoral neck shaft angle, each measuring slightly different things and having some variation in the degree of accuracy. There is no consensus about which technique for measuring femoral anteversion is the best, and as noted previously, each has its drawbacks and benefits. There also is no consensus about when femoral anteversion and coxa valga need to be measured accurately. For most of the children being followed, the assessment of femoral anteversion can be done accurately enough by continuing to monitor the physical examination of the internal and external rotation of the hip and occasionally adding the palpation of the lateral trochanter measurement. For research projects in which more accurate measurements of the influence of femoral anteversion on a deformity are necessary, we believe more accurate imaging methods are required. The use of ultrasound is easy, sufficiently accurate, and inexpensive to use for those children who do not have severe deformities and who have not had hip surgery. In more complicated patients who have had hip surgery and have developed recurrent internal rotation, it is often not clear exactly where this deformity is coming from (Case 10.32). There is often a concern of recurrent or residual uncorrected anteversion being present. In these individuals, the best method for measuring anteversion is the CT scan because low to normal neck shaft angle is usually present as these children already had the coxa valga corrected. The irregular surfaces of the femur can be more easily dealt with by having a whole outline of the proximal femur, which is provided by the CT scan. In the operating room, using the fluoroscope to understand coxa valga and femoral anteversion is routine as part of the operative procedure. However, it is not necessary to make an absolute measurement of the degree of femoral anteversion preoperatively in all children who have severe internal rotation and are being brought to the operating room to have this corrected. If children have not previously had hip surgery, and are being scheduled for surgical correction of the internal rotation deformity of the femur, increased femoral anteversion is the problem and measurement of the anteversion beyond the physical examination is not routinely needed.

The Etiology of Femoral Anteversion and Coxa Valga

Femoral anteversion is a normal position of the femur in infants. Femoral anteversion varies from 40° to 60° at birth, and then slowly resolves with growth until the normal 10° to 20° of anteversion is reached by age 8 years. There is a significant variation in the magnitude of anteversion at birth. In children with spasticity, the normal resolution of this anteversion does not occur because the spasticity and poor motor control do not provide a mechanical environment in which the femur derotates itself. In addition, children with spasticity who maintain this high degree of infantile anteversion often have decreased motor control, which means they have less ability to compensate for this tendency to internally rotate from the increased femoral anteversion. A second aspect that may magnify the persistent infantile femoral anteversion begins to show up in middle childhood with the development of internal rotation contractures, which further magnify the persistent



Case 10.32 Steven

At age 14 years, Steven, a boy with spastic quadriplegia, was evaluated with asymptomatic hip subluxation (Figure C10.32.1). His parents were concerned about the severe internal rotation position of the left hip. A hip reconstruction was performed, which gave him excellent position (Figure C10.32.2). Following this reconstruction, he did well for 5 years; however, his parents noted the slow returning of the internally rotated posture. They were concerned that he was again developing a dislocated hip; however, the radiographs were normal (Figure C10.32.3). On physical examination he was noted to have adduction of the left hip limited to 10° , full flexion, and extension; however, the left hip external rotation was only to -20° . A CT scan showed a posterior displacement of the femoral head with almost posterior subluxation and 30° of anteversion (Figure C10.32.4); this was thought to primarily reflect an internal rotation soft-tissue contracture. A soft-tissue release, including adductor lengthening, a gluteus medius and minimus release, and release of the anterior tensor fascia lata allowed the hip to externally rotate, and the femoral head reduced nicely into the joint by 1 year later (Figure C10.32.5).

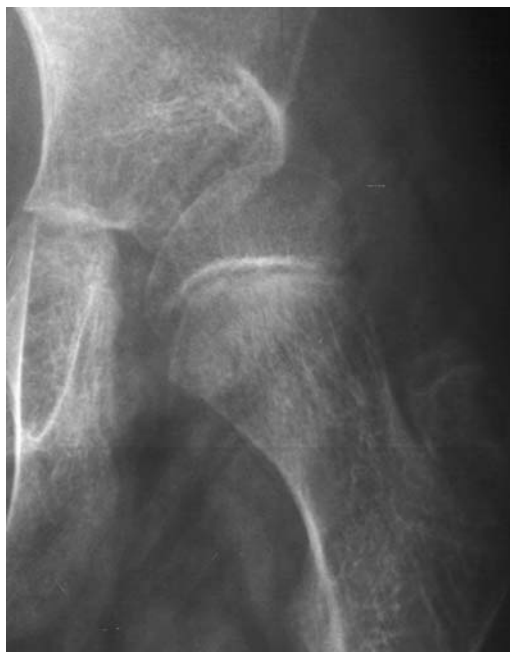

Figure C10.32.1

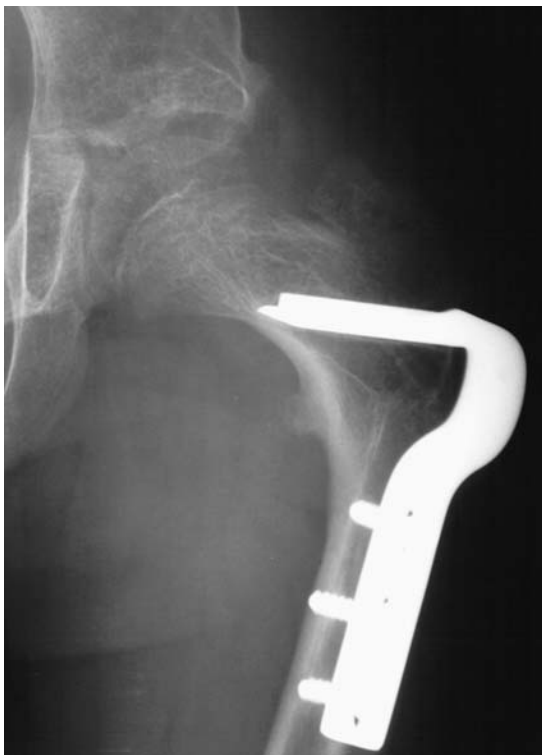

Figure C10.32.2

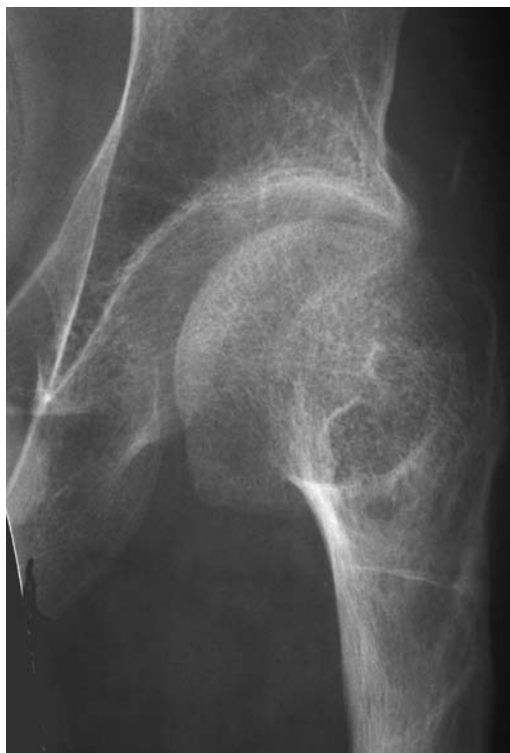

Figure C10.32.3

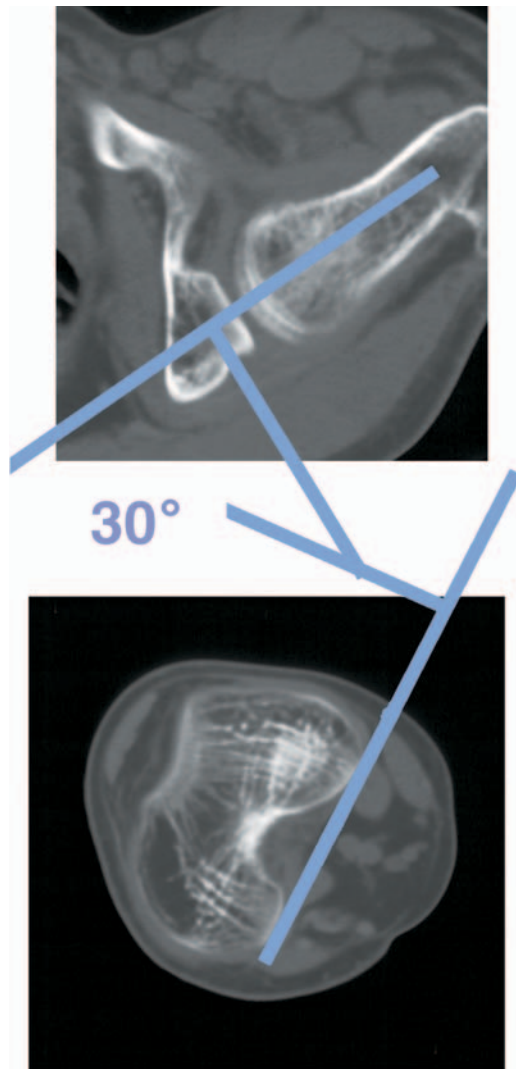


Figure C10.32.4

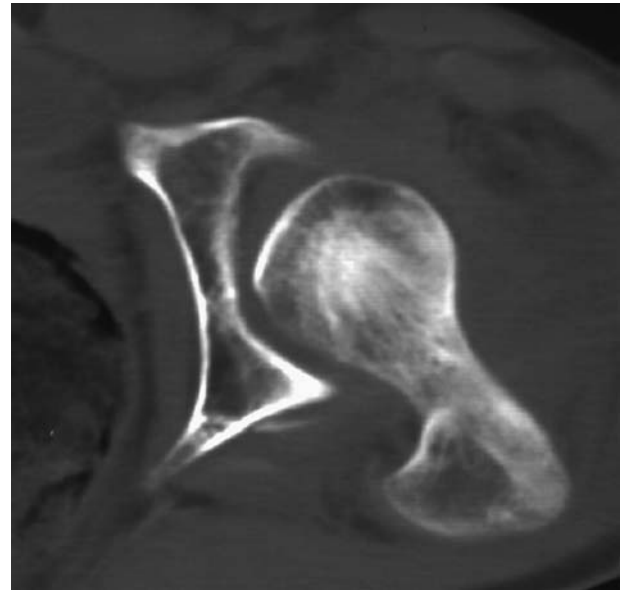


Figure C10.32.5

internal rotation. These contractures often become quite problematic in adolescence. A third cause of this internal rotation may be related to poor motor control and poor balance. Some children seem to gain stability from internal rotation of their legs, thus providing better balance in their walking gait. Some of these children have their femoral anteversion corrected, and then over several years as they gain better walking speed, will tend to return to the posture of internal rotation at the hips. However, on imaging, the femoral anteversion has not returned, but the internal rotation contractures have slowly returned.

Muscle Contractures

Spastic and contracted internal rotator muscles definitely contribute to the internal rotation posture that many children with CP have at their hips. Based on modeling work, there is a great variability in the lever arm and ability of individual muscles to cause internal rotation of the hip.^{103, 104} Our unreported modeling agrees with the published literature, but also shows that the predominant rotator of the hip in most positions of flexion to extension

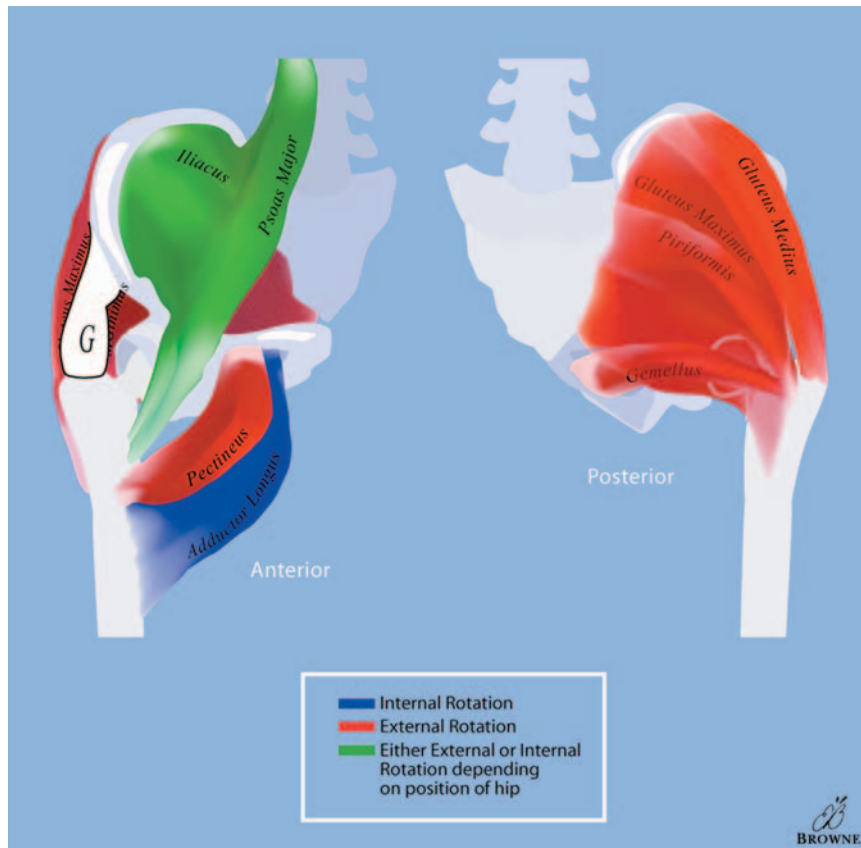


Figure 10.18. The muscles that produce internal and external rotation are a complex combination also determined by the position of the hip joint. As an example, the iliopsoas can be either an internal or external rotator, depending on the position of the hip joint. The adductor longus, brevis, gluteus minimus, and medius are the primary internal rotators of the hip joint. Gluteus maximus, tensor fascia lata, and the short external rotators are the primary external rotator motors.

is the anterior one third of the abductor medius and minimus. This muscle becomes an especially powerful internal rotator of the hip after correction of coxa valga, in which the femur is dropped into 100° of varus. On physical examination, these anterior abductor muscles can often be palpated as being the most tight muscles pulling the hip into internal rotation. Based on various degrees of hip flexion, the adductor longus, adductor brevis, and medial hamstrings may also have internal rotation moments.^{91, 105} As the hip flexes, more of these muscles have an internal rotation moment advantage, which may explain why it is so common to see internal rotation associated with hip flexion and external rotation with hip extension.¹⁰³ The gluteus maximus, which is the strongest hip extender, also depends on the neck shaft angle as a lever arm for it to be a significant hip external rotator. Certainly, the external rotation deformities are often held in a fixed external rotation position by significant contractures of the short external rotators, including the piriformis and the gemellus (Figure 10.18).

Etiology of Coxa Valga

Coxa valga is an anatomical deformity that has no recognizable factor or mechanism for assessment by physical examination. Again, infants are born with approximately 150° of coxa valga and this gradually drops to the adult normal of 115° to 120° by age 8 years under the influence of the abductor force and walking. Most of this correction actually occurs by the time children are 2 to 3 years of age. There are many studies that clearly document that the degree of coxa valga seen on the standard anteroposterior radiograph is often an apparent coxa valga due to the internal rotation of the proximal femur.⁹⁶ However, it must be recognized that many children with CP have

some degree of real coxa valga, and in some children, it is as severe as 180° , with 150° to 160° being relatively common in children with severe spasticity and nonweightbearing conditions. Although this coxa valga has been attributed to cause spastic hip subluxation and spastic hip dislocation,^{5, 7, 8} the current understanding based on multiple factor analysis from clinical effects⁹⁵ and the results of modeling studies³ indicate that this coxa valga deformity is not the etiology of the dislocation. Another typical example of the fallacy of this assumption that coxa valga is the cause of hip dislocation can be seen in the femoral neck shaft angle of the abducted hip in the wind-blown hip syndrome. Very often, the coxa valga on the windblown abducted side is even worse than the coxa valga on the dislocated adducted side. This is fairly simple and direct evidence that the coxa valga of the femoral neck is not the etiology of the dislocation.

The direct cause of the coxa valga is the abnormal force on the proximal femoral growth plate. Using the understanding of Wolff's law, it is clear that the growth plate tries to decrease this sheer force as a summated effect over time. Using this assumption, three-dimensional finite element modeling of the proximal femoral growth plate has confirmed that the femur will grow into varus if a child is in a regular weightbearing stable hip environment and will grow into valgus if the child does not have a balanced hip abductor.²⁰

Another simplistic way of understanding what the growth plate is attempting to do is to recognize that it always wants to maintain itself at a right angle to the net joint reaction force vector. Therefore, when a baby is born with a 150° neck shaft angle, as she gets to the age of 1 year and starts to walk, the abductor muscle power is increasing. As the abductor muscle force increases, it causes a joint reaction force vector that points the femoral head into the center of the acetabulum. As the abductors get stronger, the femoral neck shaft angle will drop into more varus as the hip joint reaction force vector goes into more varus. This process is totally independent of neurologic control or genetic modeling, as demonstrated by patients who have a completely normal development with normal neck shaft angles up to age 2 years, and then through accidents or other reasons, become nonambulatory and have a change in their pathomechanics (Case 10.33). The femoral neck shaft angle will follow the pathomechanics, not the genetic program that appears to have been present. For nonambulatory children, the resultant joint reaction force vector becomes almost vertical with the femoral shaft because the hip abductors are either at a disadvantage or are being overpowered by the hip adductors. Both the adducted hip and the severely abducted hip develop a high degree of femoral neck shaft angle or coxa valga because the resultant hip joint reaction force vector tends to be very nearly parallel with the femoral shaft.

Understanding the pathomechanics of the valgus neck shaft angle also explains why there is no impact on the neck shaft angle from having children weight bearing, such as in a standing frame. This type of weight bearing does not impact the degree of femoral neck shaft valgus because these children are usually not using a functioning abductor muscle against the body mass area to cause a more horizontal joint reaction force vector that drives the hip medially, which is needed to cause the femoral neck shaft angle to go into varus or to stay in varus (Figure 10.19). This also demonstrates why, when varus osteotomy is performed in young children, especially those at age 2 years or younger, that all the femoral neck shaft angle will recover to where the mechanical system is determining it should be. This ability for remodeling the femoral neck shaft angle starts to diminish substantially in late childhood. By the adolescent growth spurt, the ability for the femoral neck shaft angle to remodel itself either into varus or recover back into coxa



Case 10.33 Tyrone

Tyrone, 2-year-old completely normal boy, fell into the family pool and sustained a near drowning, which left him with a spastic quadriplegia. A radiograph of his hip at the time of the initial injury demonstrated a normal hip (Figure C10.33.1). By age 7 years, 5 years after the insult, the hip had the typical appearance of the valgus femoral neck with spastic hip subluxation (Figure C10.33.2), which was vastly different from the normal neck shaft angle that should have developed by this time (Figure C10.33.3). This process is totally independent of neurologic control or genetic modeling, as demonstrated by this boy who had completely normal development with normal neck shaft angles up to age 2 years.

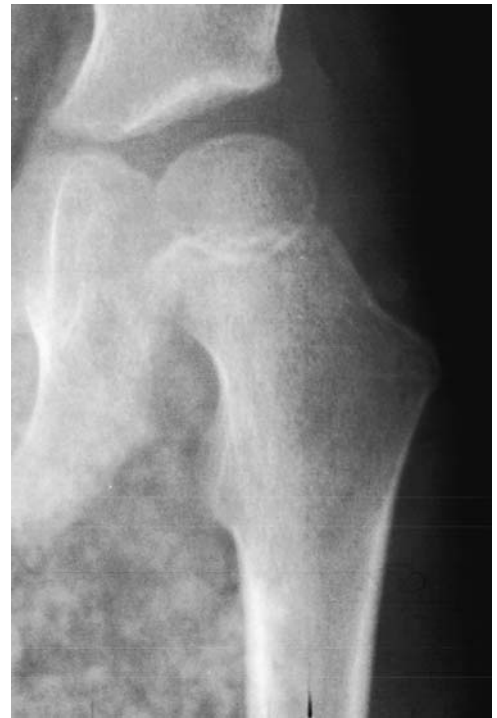

Figure C10.33.1

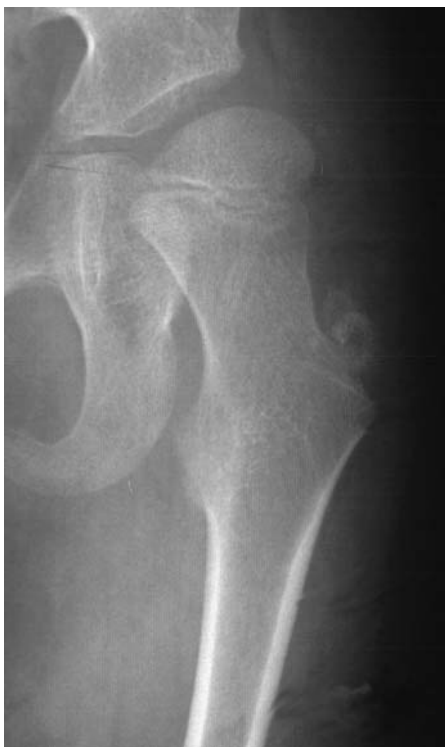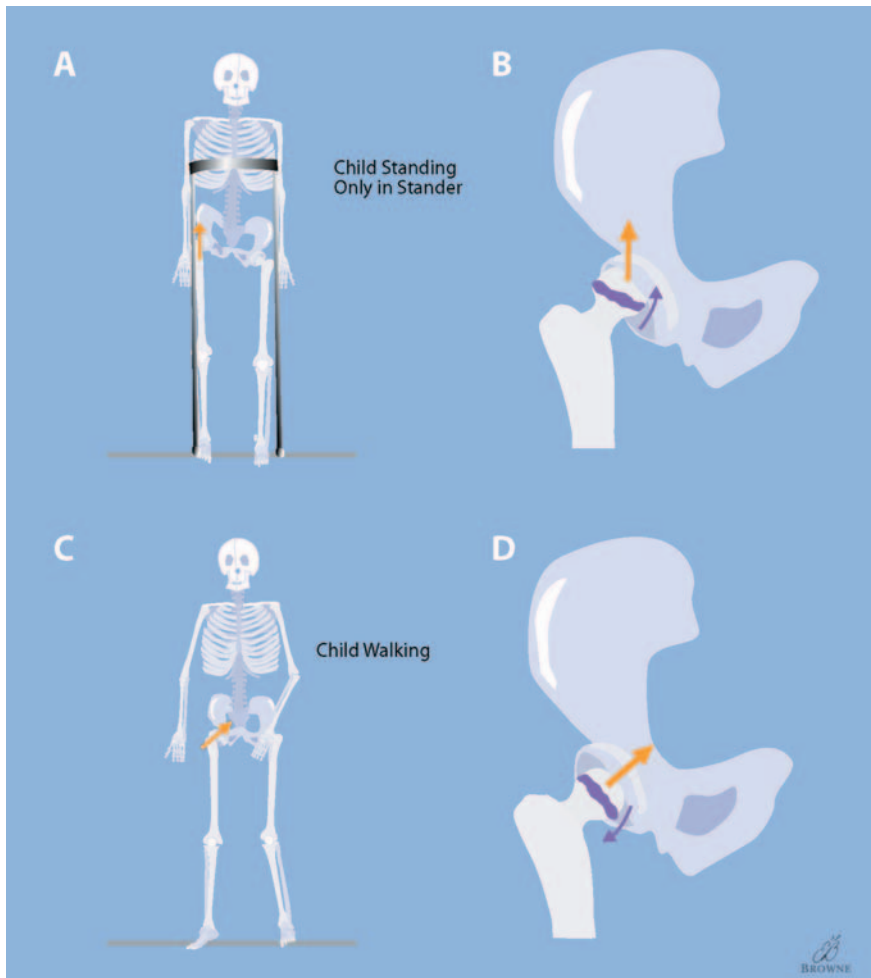


Figure C10.33.2

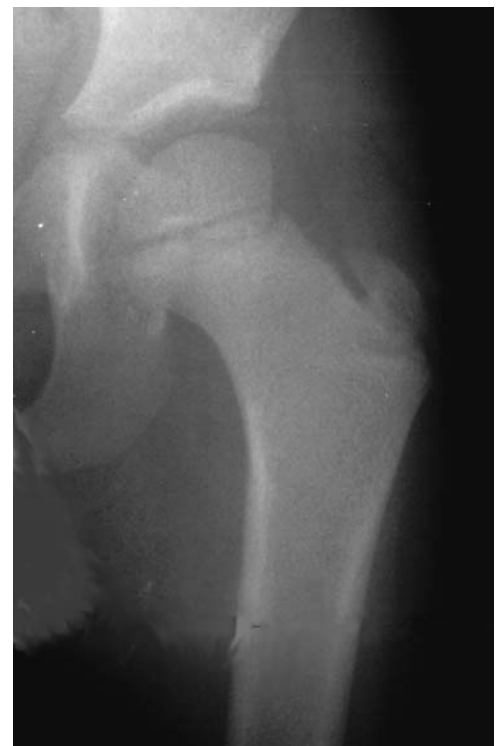

Figure C10.33.3

Figure 10.19. Because the proximal femoral epiphysis determines femoral neck shaft angle and it responds by trying to decrease principal shear stress, weight bearing in a stander or walking with a walker is not likely to impact the femoral neck shaft angle. This angle can only be impacted if the hip abductor has a forceful contraction against a fixed limb in which the abductor moment arm causes the hip joint reaction force to medialize. Weight bearing in the stander or walking in a walker does cause bone stress and should increase the bone mass even if it does not impact the shape of the proximal femur.



valga is lost because there is not enough growth potential remaining for the growth plate to respond.

Natural History

The natural history of the internal rotation deformities, which include both femoral anteversion and the spastic internal rotator muscles, is fairly consistent. Often, the internal rotation is noted in young children, and as these children start standing and walking, it may cause substantial difficulty because both knees are hitting together and they will trip. Children who gain the ability to do independent walking often have sufficient motor control and will start attempting to correct the anteversion. This muscular attempt at correcting the internal rotation sends mechanical messages to the bone, causing the bone to derotate as it grows, and this is the means by which infantile femoral anteversion is corrected in normal children. Most of this internal rotation will be corrected by the age of 5 to 7 years. However, some children have such severe femoral anteversion that their ability to continue making progress toward walking independence becomes blocked as young as age 4 years. This failure to progress is often a combination of motor control and femoral anteversion, which is especially a problem if some internal tibial torsion is combined with the femoral anteversion. Some clinical studies suggest

that femoral anteversion can recur, especially if it is corrected in children younger than age 4 years²²; however, in our experience, the anteversion will not recur if it is corrected after age 5 to 7 years. The internal rotation posture may recur due to spastic or contracted internal rotator muscles. Because of this natural history of responsiveness of the bone to torsional change, it is better to correct anteversion later and, if at all possible, try to avoid correcting it before age 5 to 7 years.

Another aspect of the internal rotation posture in walking is often seen during the adolescent growth spurt, when independent ambulators may develop slightly more internal rotation than they had in late childhood. This increased internal rotation typically resolves as these children complete the adolescent growth spurt, and they will return to the posture that they had in late childhood. If there is a substantial increase in anteversion, it is better to wait 6 to 12 months to see if this increase will slowly resolve rather than rushing into a surgical correction. After these children stabilize following the adolescent growth spurt, their anteversion is not likely to change when they enter adulthood, and surgical correction of the anteversion should be considered if internal rotation causing mechanical or cosmetic concerns continues. These concerns include knocking of knees together with hip flexion or heel whip with fast walking or running.

Treatment of Femoral Anteversion

Internal rotation of the hip is caused by either femoral anteversion or spastic internal rotator muscles; however, some elements of both most often are present. The primary focus of treatment should be the femoral anteversion because it is easy to correct with minimal side effects. The primary treatment is femoral derotation osteotomy, and the time for considering this surgery should be related to the severity of the deformity. In ambulatory children who have significant symptoms with internally rotated gait secondary to internal rotation at the hip, the best time for correction is between the ages of 5 and 7 years. At this time, there is less risk for development of recurrent bony anteversion. In addition, motor planning, motor control, and balance have also started to plateau at this age. This plateau will allow children's function to be at a maximum by the beginning of formal elementary education, which is the main focus of middle childhood. If internal rotation at the hip is of marginal significance at the ages of 5 to 7 years, waiting with the goal of seeing how this internal rotation develops at adolescence is reasonable. The slow resolution and improved motor control make this a deformity that does not need to be addressed in some individuals. However, if the internal rotation continues to be a cosmetic concern or a functional problem after puberty, it should be corrected. Correcting anteversion is not done to prevent or treat hip subluxation; however, if hip subluxation or dislocation is present and femoral osteotomy is required, then the femoral anteversion should be corrected at the same time, with the goal of leaving 0° to 10° of anteversion. In children who have had anteversion corrected and who develop significant internal rotation contractures that are interfering with seating or walking, internal rotator muscle lengthening should be considered. It is mandatory to ensure by CT scan that no recurrent femoral anteversion or residual anteversion from the prior correction is present in these patients.

Methods for Correcting Anteversion

There are three general regions of the femur where femoral osteotomies may be performed to correct the femoral anteversion: the proximal, middle, or distal femur. Because the source of anteversion in children with spasticity

tends to be torsion of the whole femur, there is no benefit from the functional perspective of correcting the torsion at one level or another.

Proximal Femoral Derotation

Proximal femoral osteotomy is the primary site of correction of femoral anteversion for children who have concurrent spastic hip disease. Children with open growth plates also are treated best with proximal femoral osteotomy, using the standard proximal femoral osteotomy and blade plate fixation. If this femoral osteotomy is being done unilaterally, it is very important to ensure that there is no change in the femoral neck shaft angle, as any osteotomy that produces varus may cause a concurrent shortening. The proximal femoral derotation osteotomy may be performed using a six-holed straight plate; however, the blade plate is preferred because it is easier and simpler to use. When a derotation osteotomy only is done proximally, there is no clear evidence to recommend the intertrochanteric region, thus leaving the lesser trochanter with a distal fragment, or the subtrochanteric region, leaving the lesser trochanter with a proximal fragment. If the osteotomy is done in the intertrochanteric region, thus leaving the lesser trochanter with a distal fragment, as the femur is externally rotated distally, the lesser trochanter and origin of the iliopsoas is rotated more anteriorly, thereby providing a slight lengthening of the iliopsoas. While the lesser trochanter is being rotated anteriorly, the iliopsoas loses all its ability as an external rotator, and if rotated too far externally, it can become an internal rotator. The degree of hip flexor lengthening obtained with the anterior rotation of the iliopsoas is fairly minimal; therefore, doing the proximal osteotomy in the subtrochanteric region just below the lesser trochanter has the advantage of not risking developing the iliopsoas into an internal rotator and fostering recurrent internal rotation later.

Midshaft and Distal Femoral Osteotomy

Midshaft osteotomies of the femur for derotation are ideal for individuals who have completed growth and have closed growth plates. This is an ideal location to perform the osteotomy, which can then be fixed with an intermedullary nail and transfixation screws (Figure 10.20)

Distal femoral osteotomy for derotation should be reserved for individuals who need concomitant correction of severe fixed knee flexion contractures or a valgus deformity of the distal femur. The distal femoral osteotomy can be fixed with a blade plate.

Other options for the treatment of femoral anteversion include performing a midshaft femoral osteotomy with the use of a six-hole compression plate. This option is advocated by some surgeons and provides acceptable femoral derotation. However, our experience is that proximal osteotomy allows for a smaller exposure, but the midshaft femoral osteotomy may be better for surgeons who are not very familiar with doing proximal femoral osteotomies in children.

Distal femoral osteotomies performed by the percutaneous method, fixed with K-wires, and placed in long-leg casts have also been reported.¹⁰⁶ This technique adds the risk of development of varus or valgus deformities at the knee and, in addition, it requires the use of long-leg casts with all of the inherent complications of cast immobilization. This technique is a poor option for children with CP.

Orthotic Treatment

Derotation bands of cloth and metal orthoses known as twister cables have been advocated; however, there is no documented benefit from these

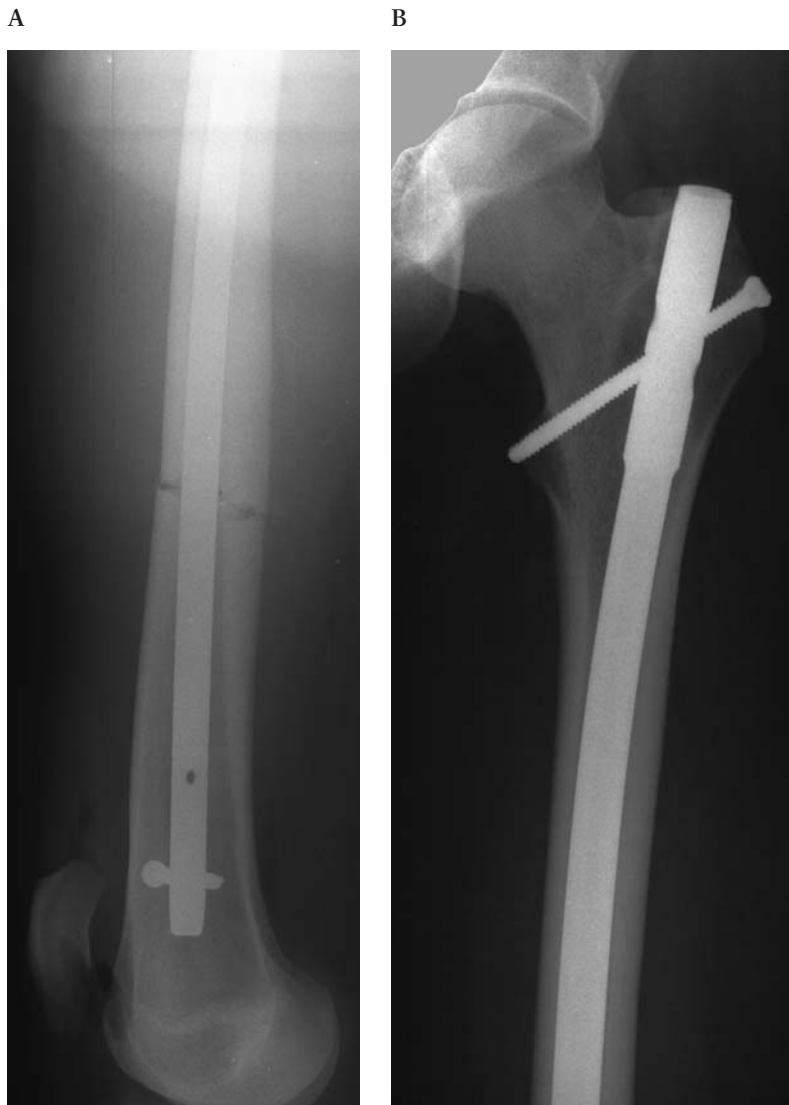

Figure 10.20. Correction of femoral anteversion in the midshaft level is easy to perform and easy to fix with an intramedullary nail and transfixation screws (A,B). This technique is only possible in individuals who are fully mature, usually over age 16 years.

devices in the literature. In our experience, when these devices work, they tend to slow children down, making walking much more difficult, although the children look better when standing. A potentially serious side effect of these derotation devices is that they get their distal fixation on the foot, thereby putting a large amount of stretch through the knee ligaments. The knee ligaments probably are the most vulnerable tissue for intermittent high torsion, acute stretching rather than the long, slow derotation that is required to impact the bone deformity. Therefore, these devices are also contraindicated because of the risk of causing damage. Almost all children with CP will not tolerate these devices for long because of the discomfort they cause. For these multiple reasons, there is no role for the use of derotating springs, twister cables, or other derotation braces.

Muscle Lengthening

Treatment of spastic internal rotation, caused by spastic internal rotator muscles or contracted internal rotator muscles, is best done by lengthening of the offending muscles if radiographic measurements have documented

that increased femoral anteversion is not a problem. It is crucial to remember that a femur should not be derotated to cause retroversion, because this can lead to posterior dislocation of the femur. Femoral anteversion should never be corrected past neutral. In spite of corrected femoral anteversion, doing muscle lengthenings for internal rotation is reasonable and has some positive benefit if patients still continue to internally rotate. These muscle lengthenings are especially beneficial in nonambulatory children in whom all the anterior abductors are tight and are causing internal rotation. These muscles can be released off the greater trochanter without any risk of causing functional problems. We have had good success with this procedure in children who have moderate degrees of internal rotation. However, it is sometimes difficult to find all the muscles that are causing an internal rotation force, but they may include adductor brevis and longus, and some contribution from the medial hamstrings. These corrections are best approached by doing careful palpation of the children in different positions of hip flexion when in the operating room to determine what muscles are limiting the external rotation. The anterior hip capsule is sometimes contributory and may need to be released as well. In ambulatory children, releasing the anterior abductors should be done with caution. The tendon of the abductors tends to be underneath, or deep to the muscle belly. However, a myofascial lengthening of the anterior abductors improves the internal rotation. Careful lengthening in the myofascial plane of these anterior abductors can substantially improve internal rotation and it can be done safely without causing too much abductor weakness.¹⁰⁷

Another attempt at treating internal rotation by muscle surgery was the anterior transfer of the gluteus medius advocated by Steel.¹⁰⁸ The theory of this procedure is that the gluteus medius is advanced anteriorly and inferiorly to provide more of an external rotation lever arm. Although initially reported as very successful,¹⁰⁸ many of these patients ended up having little external rotation and many developed relatively severe hip flexion contractures. We have seen several of these patients who continued to have substantial internal rotation, and in spite of this internal rotation, they have very severe fixed hip flexion contractures that are very hard to treat. This procedure has no role in the current treatment of children with CP.

Hypotonic Hips

Hypotonic hip disease includes a poorly defined group of children who have general hypotonia. This discussion is limited to children who have hypotonia secondary to an encephalopathy, and therefore excludes all children who have hypotonia secondary to severe myopathy or muscle diseases. However, the problem with these children is very similar to that of children who have severe muscle weakness secondary to spinal muscular atrophy or flaccid paralysis due to spinal cord injury or spina bifida. Many of the children with static encephalopathy and hypotonia end up having some chromosomal anomalies, which are often undefined or poorly defined. In addition, this condition may be combined with soft-tissue hyperlaxity such as is seen in Down syndrome or Ehlers–Danlos syndrome. However, increased soft-tissue laxity is substantially different from hypotonia and although both may be present concurrently, this is not the typical presentation. The problems of weak and/or hypotonic children are quite different in their response to surgical treatment than those with severe soft-tissue laxity. The focus of this discussion is primarily on those children who have hypotonia secondary to a static encephalopathy.

Etiology

The etiology of hypotonic hip disease is opposite that of spastic hip disease. With hypotonic hip disease, the hip comes out of the joint because there is insufficient muscle force to hold it in the joint. This poor muscle force also leads to the development of poor acetabular depth because there is not enough pressure against the medial wall of the acetabulum to foster good acetabular depth growth. For this reason, most of these children will have a global acetabular dysplasia and many have MP of 40% or more, although no instability is present and there is a good medial shape to the acetabulum. These children often have wide hip abduction; however, they frequently want to position themselves with internal rotation. They are at risk for developing both anterior and posterior dislocations. Ambulatory children with substantial hypotonia seem to be at more risk for developing anterior dislocation because they spend much more time with their hips extended and often fall into external rotation. Anterior dislocation should be a major consideration in any child with substantial hypotonia who suddenly refuses to walk, or stops walking (Case 10.26). Anterior dislocation should also be considered when the external rotation seems to have suddenly gotten worse. Most of these children with significant external rotation, as demonstrated by external foot progression angle, still have increased femoral anteversion or normal femoral anteversion. Anatomical retroversion is very rare, especially in this hypotonic group.

The Natural History of Hypotonic Hip Disease

Children with hypotonia and increased range of hip motion need to have routine radiographs similar to children with spastic hip disease. However, the treatment indications are very different. Many of these children start with higher than normal MPs in the range of 35% to 45%. In spite of this dysplasia, many hips remain stable throughout all of childhood. These children need to continue to be followed with careful physical examination, evaluating instability using the Barlow test and ensuring that both anterior instability as well as posterior instability are checked. So long as the migration index remains at 50% or less and the hip remains stable by physical examination, no specific treatment is indicated. Some children tend to develop sleeping postures that have their hips in adducted and internally rotated positions, or alternatively, in severely externally rotated positions, which may put them at risk for anterior hip abduction. If these positions are noted by parents and there is any development of instability, trying to maintain these children positioned in an anatomically neutral sleeping posture is recommended. By maintaining the hips in a neutral position, the hip capsules will occasionally tighten up and the children will develop hip stability as growth continues. A small group of children will suddenly develop a dislocation that becomes fixed, or present with a fixed hip dislocation, but have good range of motion of the hip and no pain (Case 10.34). For these children who also are generally hypotonic, the surgical treatment is less predictable; therefore, it is most reasonable to continue just monitoring their hips (Case 10.35). There are also a group of hypotonic children who have multidirectional dislocations, and bracing in one direction will only drive the hip out of the joint in the other direction (Case 10.27).

Treatment

As noted in the natural history, this is a very diverse group of children. The treatment responses in this group of children are also much more variable



Case 10.34 Gregory

Gregory, a 14-year-old boy with Down syndrome and quadriplegia, was monitored for hip dysplasia. He had wide abduction to 60° but a dysplastic acetabulum radiographically (Figure C10.34.1). At 16 years of age, his mother reported that she thought his left leg was shorter.

On physical examination the range of motion was unchanged and he had no pain. A dislocated hip was noted on a radiograph (Figure C10.34.2). He was followed without intervention for 5 years until he turned 21 years with no change in his status.

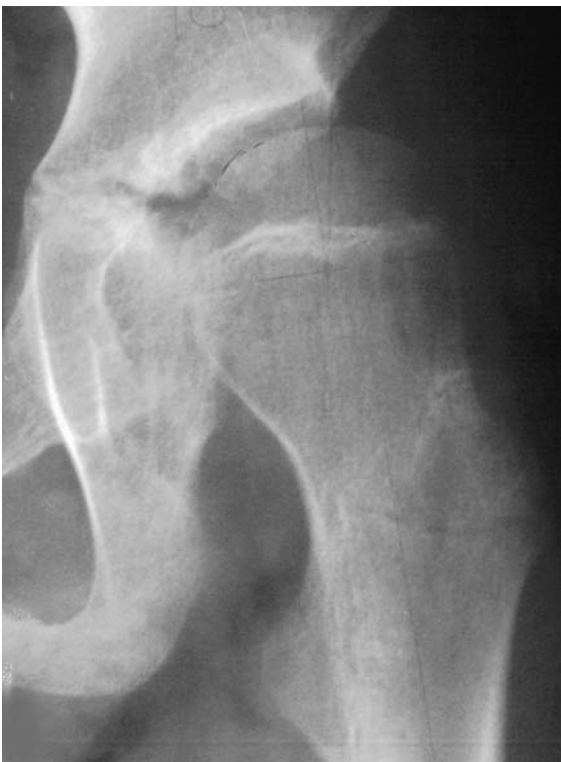

Figure C10.34.1

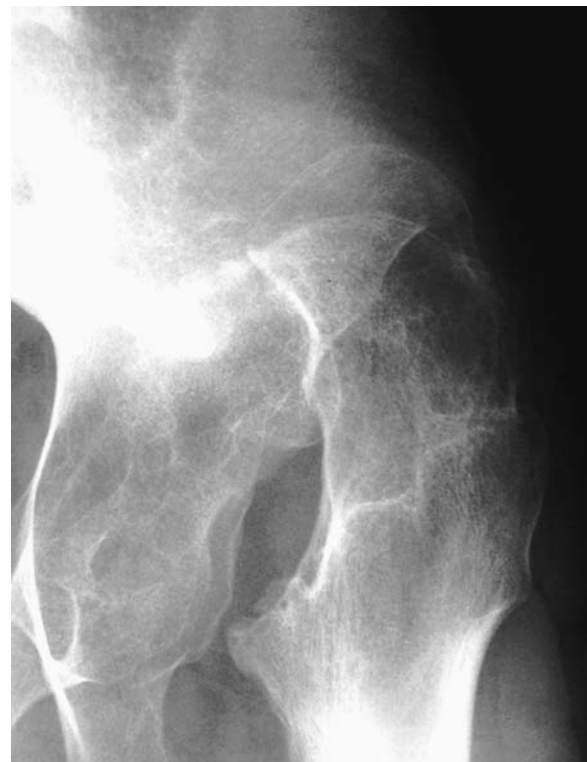

Figure C10.34.2

and have not been well studied; therefore, clear and predictable outcomes of treatment cannot be given to the families. The first level of treatment should be maintaining a relatively anatomically neutral resting position for nonambulators, meaning avoiding severe hyperabducted, flexed, and external rotation postures or, alternatively, avoiding severe flexed and adducted postures in sleeping. Avoiding these positions can be accomplished with minimal, narrow abduction wedges used during sleep, or alternatively, sewing the legs of pajamas together so that the children sleep with their legs in relatively neutral position. These children often tolerate this orthotic management much better than children with spasticity, who become more uncomfortable when they are forced into positions that the spastic muscles are resisting.

For ambulatory children who are developing more problems with gait or suddenly stop walking, and have been diagnosed as having hip dislocation,



Case 10.35 Wade

A 7-year-old boy, Wade, had severe mental retardation and hypotonia but was an independent ambulator. He was evaluated because his mother felt he was very clumsy. He had increased range of motion in the hip, knee, and ankle with clear hypotonia. A radiograph of the hips showed dislocating hips (Figure C10.35.1). A varus femoral osteotomy was performed (Figure C10.35.2), which was followed in 2 years by recurrent subluxation of the hips (Figure C10.35.3). At this time, his mother noticed that his walking was decreasing. The hip was again reconstructed (Figure C10.35.4), which included a pelvic peri-iliac osteotomy and varus shortening osteotomy, which obtained a good reduction and coverage (Figure C10.35.5). His walking returned to normal; however, by 5 years after the reconstruction, at 16 years of age, he again decreased his walking and was again subluxating (Figure C10.35.6). Another reconstruction was performed (Figure C10.35.7), and again his gait improved until age 20 years when he again seemed to decrease his walking and the hip was again noted to be subluxating (Figure C10.35.8). Because

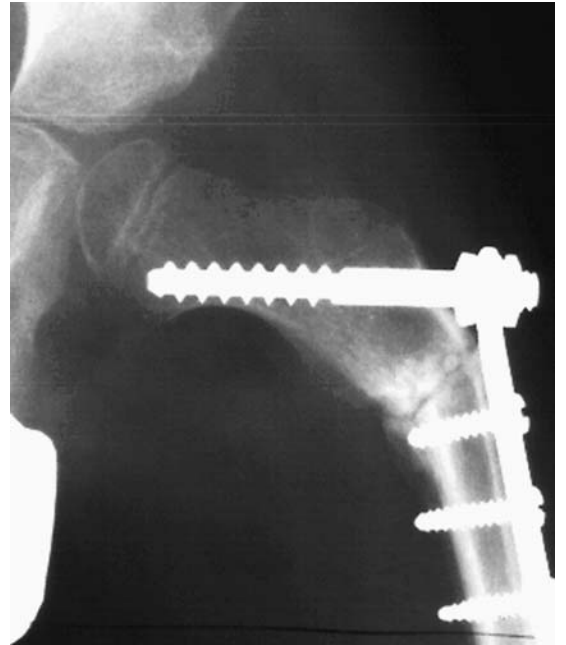


Figure C10.35.2

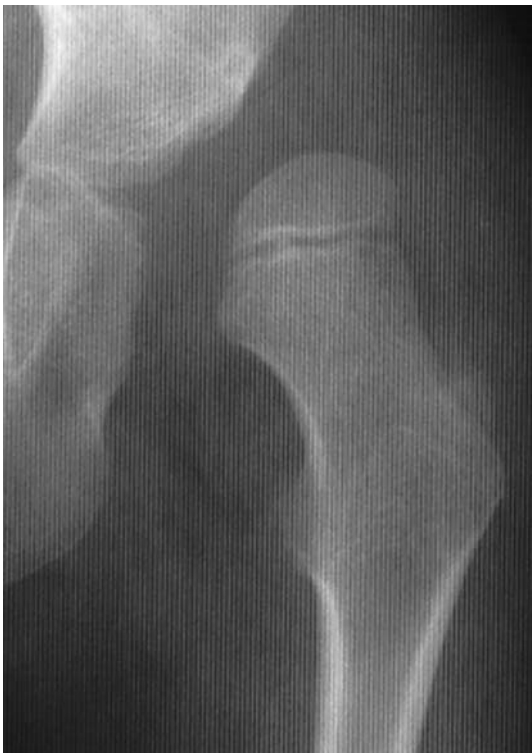

Figure C10.35.1

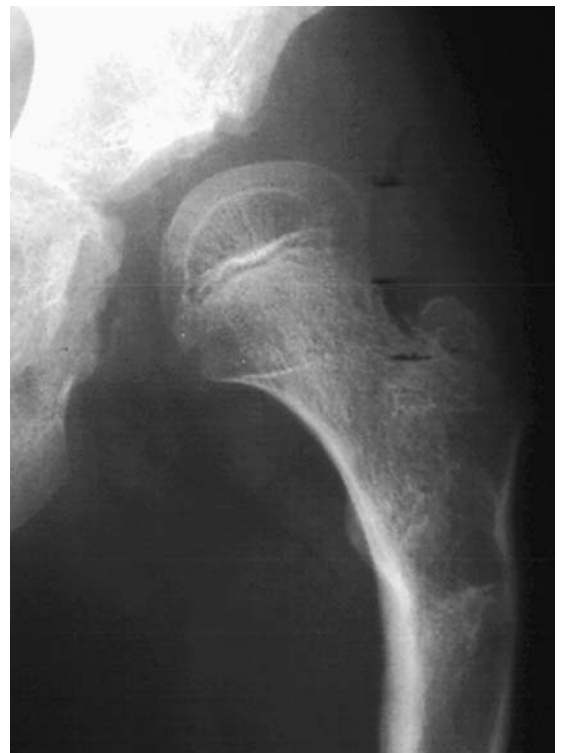

Figure C10.35.3

these unstable hypotonic hips are not common, there is not enough experience to make definite recommendations; however, if the reconstructions are done early and

include the acetabulum, they seem to do better. It is very difficult to maintain hip reduction when there is little or no muscle force.

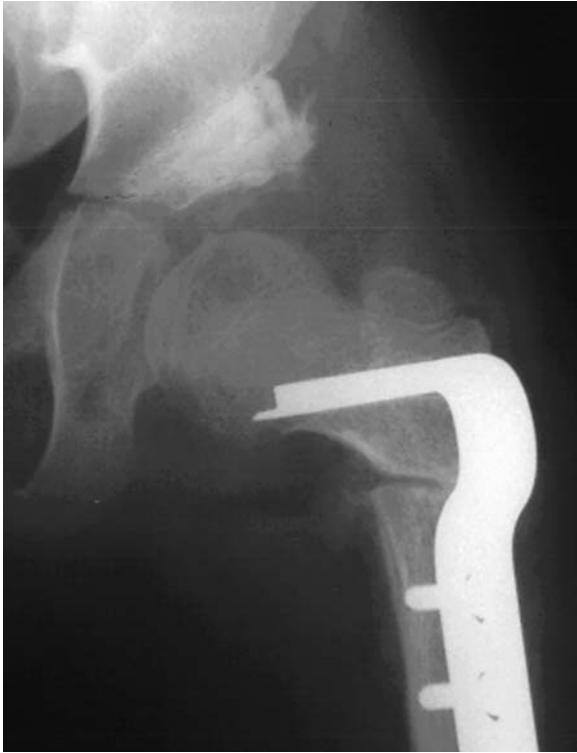

Figure C10.35.4

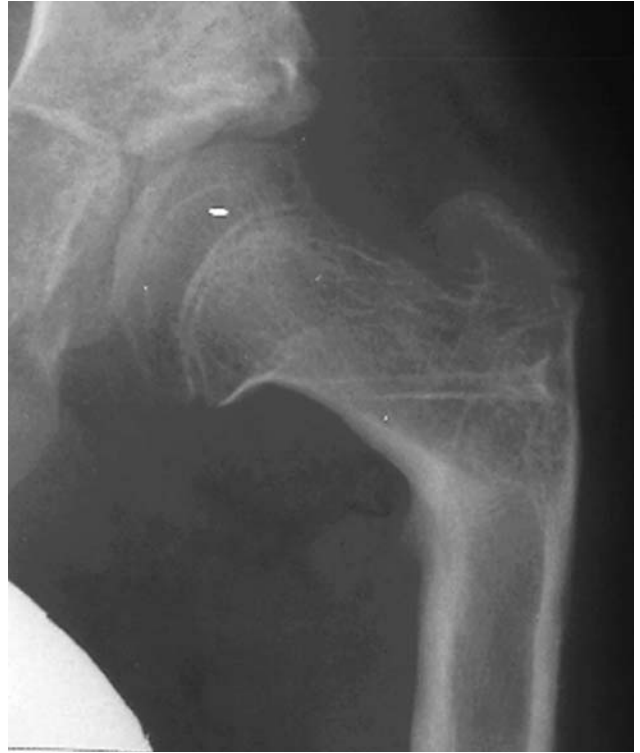

Figure C10.35.5

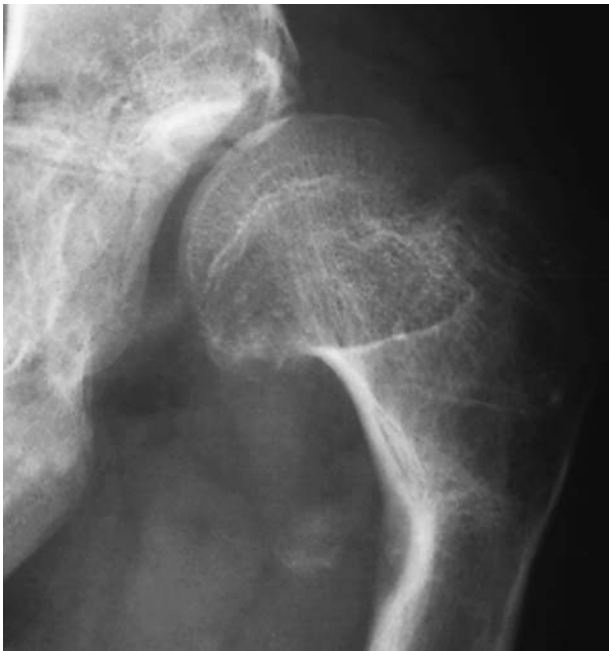

Figure C10.35.6

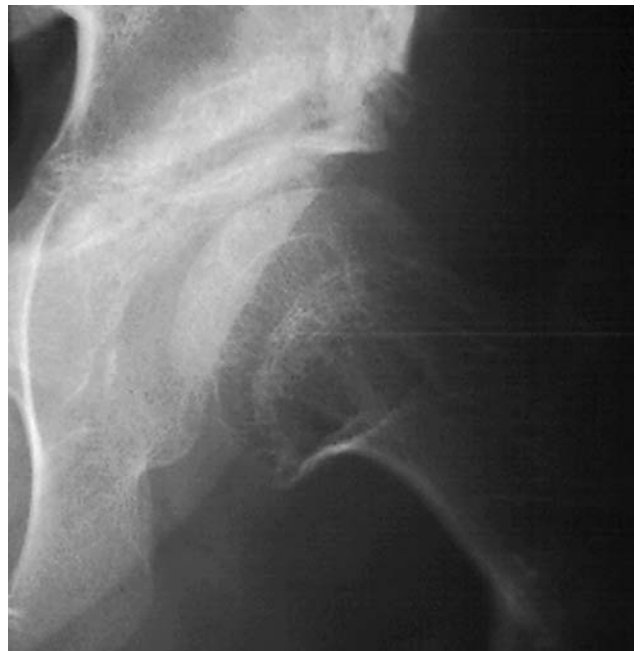

Figure C10.35.7

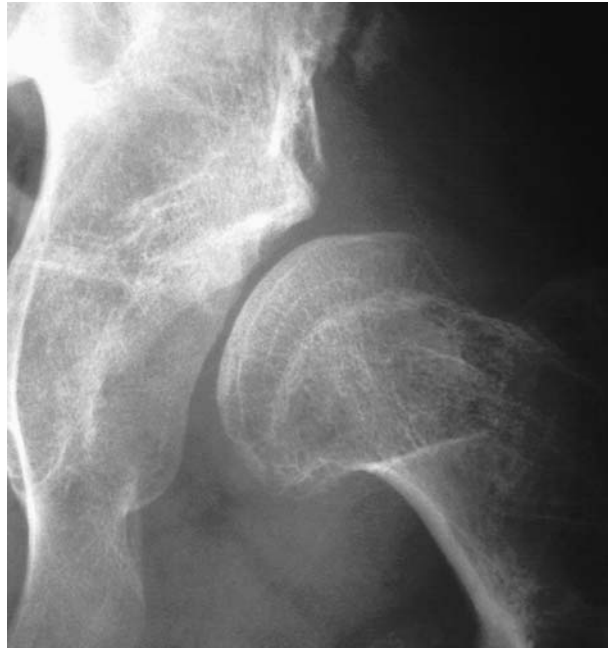

Figure C10.35.8

immediate reconstruction of the hip joint is indicated. The surgical procedure does not involve any muscle surgery because there are no muscle contractures present (Case 10.36). This procedure has to focus primarily on developing stable acetabular reconstruction by increasing the size of the acetabular coverage and trying to increase its depth. A peri-iliac osteotomy is used for posterosuperior dislocations and the Pemberton osteotomy for anterior dislocations. Usually, a femoral varus osteotomy with mild shortening is indicated to bring the femoral head inferiorly so that sufficient acetabular turn-down can be performed. It is very difficult to do the acetabular reconstruction without first having the femoral osteotomy in place to provide a decompression of the hip joint. However, overshortening the femur should be avoided because there is very little muscle tension that will take up the shortness.

Special Hip Problems

Developmental Hip Dysplasia in Spastic Children

A major and long-term problem for orthopaedists has been the confusion of developmental hip disease that occurs at infancy and spastic hip disease that occurs in childhood in children with spasticity. These two conditions have very distinctly different features, different etiologies, and different treatments. However, children with spasticity may also have DDH. Often, children who are diagnosed as having DDH as infants may not be recognized as having CP and will be treated appropriately for DDH. This treatment is completely appropriate and usually leads to a reasonably good outcome. Many children who were either very premature or have other substantial



Case 10.36 Janelle

At age 7 years, a girl, Janelle, with a known diagnosis of Down syndrome, presented because she was unable to walk. She had never been ambulatory and had increased movements in the upper extremity. There was a history of birth anoxia. On physical examination she had increased range of motion, and extremity movement in the athetoid pattern. She was unable to stand without support. Radiographs demonstrated a dislocated hip on the right and a normal hip on the left (Figure C10.36.1), and a CT scan of the head and cervical spine were obtained to rule out other central nervous system pathology. A reconstruction of the right hip including only a peri-ilial osteotomy of the pelvis and capsular plication was performed (Figure C10.36.2). Initially, the hip was stable (Figure C10.36.3); however, in 2 years it again dislocated and she was reconstructed with a femoral osteotomy and pelvic osteotomy (Figure C10.36.4). Again, the hip remained stable for 2 years, at which time the hip became a fixed dislocation (Figure C10.36.5). Now at age 9 years, a third reconstruction included adding a large bank bone graft shelf along with the femoral osteotomy and pelvic osteotomy (Figure C10.36.6). She has completed growth and remained with a stable hip 5 years after this last reconstruction (Figure C10.36.7). She is able to do weightbearing transfers but has limited balance due to the athetoid

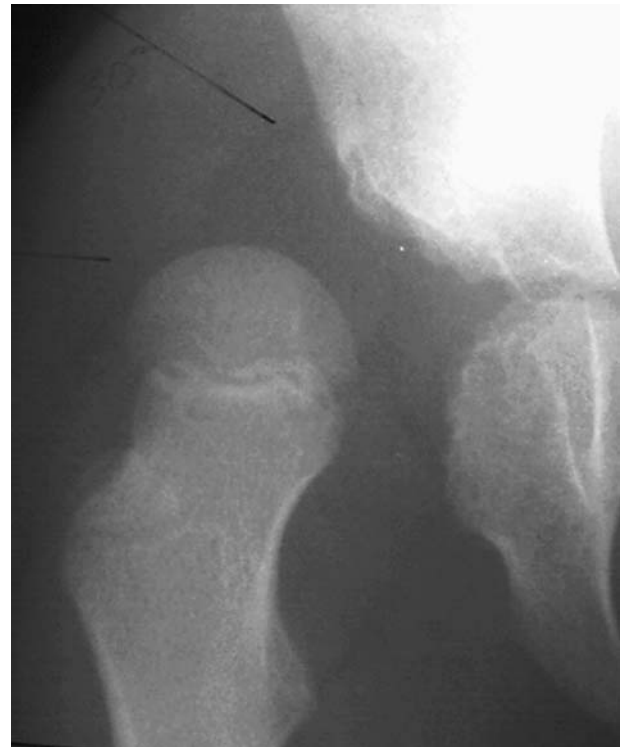

Figure C10.36.1

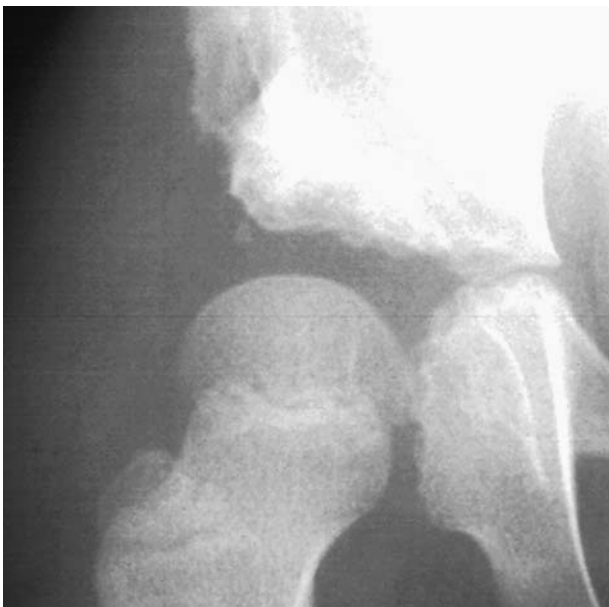

Figure C10.36.2

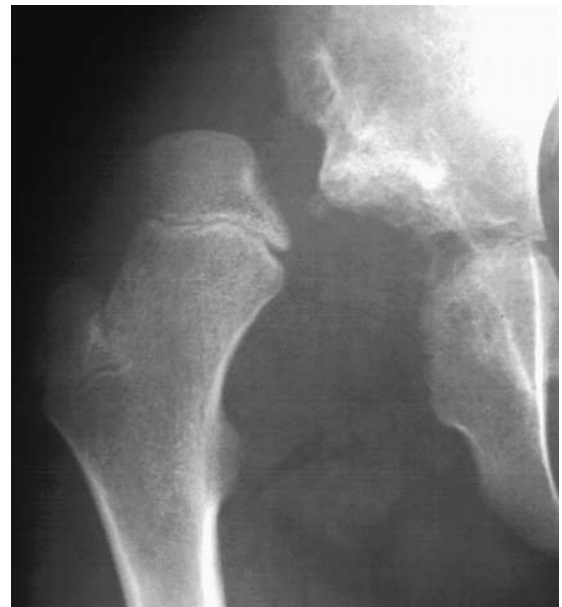

Figure C10.36.3

movement. This case shows how important it is to keep working on the hips and that it is possible to get a good

outcome, although it is very difficult in children with the combination of Down syndrome and CP.

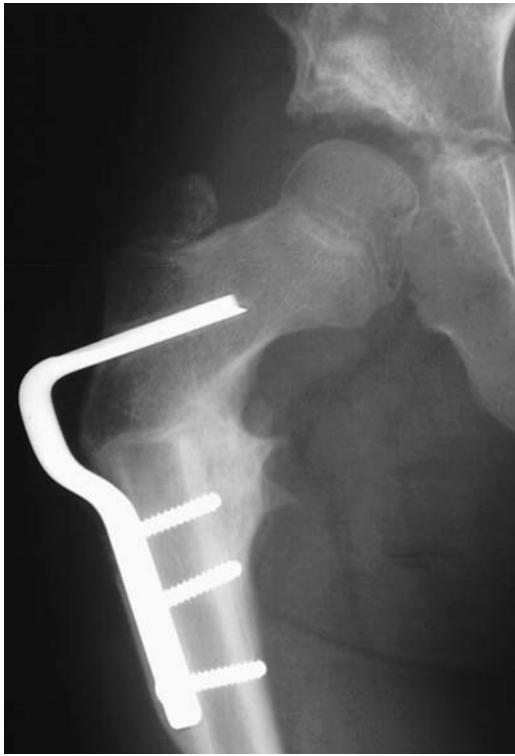

Figure C10.36.4

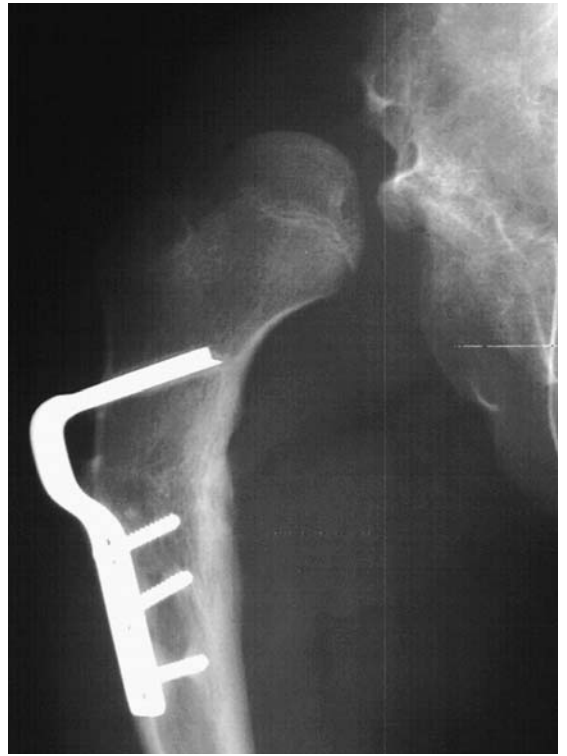


Figure C10.36.5

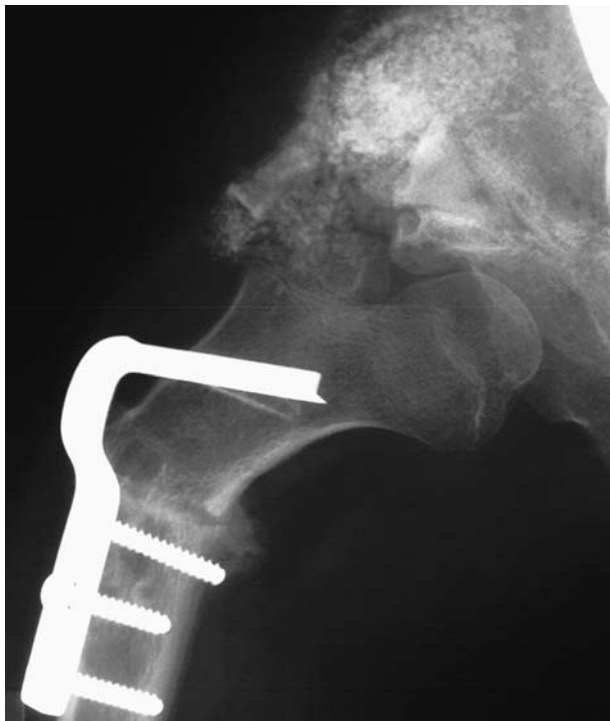

Figure C10.36.6

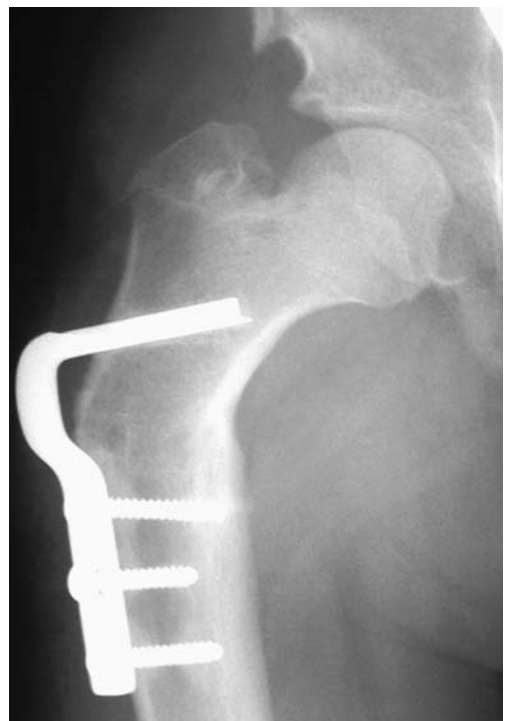

Figure C10.36.7

medical problems in infancy may also be found to have DDH. Many of these children may be perceived to have very poor survival chance early on and do not receive any treatment of their hips. In general, regardless of children's other concurrent medical problems, the DDH should be treated with a standard treatment protocol, which usually starts at infancy with the use of a Pavlik harness. Indications for operative treatment in these children should be the same as for children who are otherwise normal. Only in children who are in such medically fragile condition so as not to tolerate treatment, or in children in whom long-term survival is definitely not expected, should treatment be withheld. The outcome and response to DDH treatment is best when started earliest, and this also holds true for children who will eventually end up with CP. Children who present with DDH at 6 to 12 months of age and the presence of recognized CP, should still be presumed to have DDH and be treated as such. Usually, an open reduction is required at this age.

There is a time between the ages of 1 and 2 years when it may be difficult to tell whether children have DDH or spastic hip dislocations. These are often children who first present at the age of 1 to 2 years with severe spasticity and have the presence of an established hip dislocation. Most of these are probably DDH hips whose range of motion is substantially diminished because of spasticity. At this age, if children have a fixed hip dislocation, it should be treated as a DDH with open reduction and femoral shortening. Almost all children who have spastic hip disease at this age, even if the hip is almost dislocated, do not have a fixed dislocation and can be treated with muscle lengthening alone. However, a principle to remember in this gray zone is that these dislocated hips will never get easier to treat or be less of a problem for children by just waiting. Between the ages of 1 and 2 years, if children present with a subluxated hip and spasticity, it should always be considered spastic hip disease and treated with muscle lengthening unless there was a previously verified DDH.

Established Developmental Dislocation

For established dislocated DDH hips in older children with CP, the treatment philosophy that is in line with the DDH treatment for that specific age should be used rather than the spastic hip disease indications (Case 10.22). An occasional dilemma may present when new patients are being seen for the first time and there are no previous hip radiographs. If these children are 8 years of age or older and have a dislocated hip with very severe acetabular deficiency, it may still be difficult to determine whether this is a missed DDH or a spastic hip disease. The principles outlined previously for the treatment of spastic hip disease do not work for DDH because the hip dislocation occurred much earlier and there is generally much less acetabulum present to reconstruct. It may be very difficult to tell the difference between DDH and spastic hip disease when the spastic hip dislocation occurs between the ages of 2 and 3 years and the children are seen at age 10 years. In this scenario, the spastic hip dislocation may mimic the DDH more closely. However, this condition should seldom happen because it would indicate children who really have not been receiving appropriate medical care. No child with spasticity should ever present with a dislocated hip at age 6, 7, or 8 years without having previous radiographs to verify when that hip dislocation occurred. Children should also seldom present at this age with a dislocated hip. It is much less common to have children with CP present with a dislocated hip than normal children with DDH because the ease of determining a spastic hip dislocation is much more clear, as it is always empirically obvious that these children have CP.

Slipped Capital Femoral Epiphysis

Slipped capital femoral epiphysis has never been reported in a spastic hip and we have never seen a slipped epiphysis in a spastic hip. We have seen one child who developed a slipped capital femoral epiphysis on the normal side. This boy had hemiplegia, was severely obese, and started complaining of pain on his normal side. The presence of coxa valga is probably protective of the slipped capital femoral epiphysis in the spastic hip, although even hips that have had a varus osteotomy have not had a slipped epiphysis.

Perthes Disease in Children with Spasticity

Perthes disease also has not been reported in children with spastic hips and we have seen only one case. Use of orthotics is extremely difficult in these children, but otherwise the hips should be treated as they would be in normal children with Perthes disease.

Hip Dislocation in Children with Down Syndrome and Cerebral Palsy

Children with Down syndrome often develop hip dislocation secondary to muscle laxity and hypotonia from the Down syndrome. The problems related to dislocation of hips in normal Down syndrome children are a major problem but are not addressed here. When Down syndrome is combined with CP, there are additional problems in treating the hip dislocation due to the spasticity. For nonambulatory children with Down syndrome who have CP and present with a dislocated hip that is asymptomatic, it is best to leave the hip alone (Case 10.34). The combination of soft-tissue laxity present in children with Down syndrome and spasticity makes reducing and maintaining these hips very unpredictable. We have followed several children with this scenario until age 21 years and none have developed hip pain and all have maintained relatively good range of motion of the hip. There is no other published report of outcome in children with this combination.

For children who are being followed with the combination of Down syndrome and CP and do develop a hip subluxation or dislocation, treatment should be considered. We have treated one child who developed pain as the hip dislocated. This child was doing some weightbearing transfers, which became impossible when her hip dislocated. Aggressive reconstruction of the acetabulum with some muscle lengthening and varus osteotomy has ultimately been successful in maintaining this girl's hips reduced, although two acetabular reconstructions were required (Case 10.36). There is merit in trying to maintain a reduced hip if children have standing ability and if the dislocation has been noted to develop or is of a very short-term duration. These children require the use of some abduction bracing or bivalve casting to maintain position because they often want to sleep in very peculiar anatomical positions, such as with their legs hyperflexed so that their feet may be above their shoulders.

Complications of Hip Problems in Children with Cerebral Palsy

Wound Infections

Wound infections from hip surgery occur primarily at the site of a femoral osteotomy. Superficial wound infections also occur in groin wounds and the

anterior pelvic osteotomy site; however, these infections readily respond to local wound care, cleaning, and keeping the wound dry. Often, these are suture infections that will resolve once the suture is removed. Prophylactic antibiotics, usually a broad-spectrum cephalosporin, should be used for one dose immediately preoperatively followed by two doses postoperatively. Prophylactic antibiotics have been demonstrated to decrease the risk of infection in hip surgery in children with CP.¹⁰⁹

Deep wound infections in the adductor wounds are rare, occurring in approximately 1 in 400 open adductor tenotomies, and almost all of these are in revision adductor tenotomies. We have not seen a deep wound infection in a primary open adductor tenotomy in children with CP. Using a careful closure of a longitudinal incision in the fascia and a good, careful, tight closure of transverse subcutaneous tissue and a good subcuticular skin closure are important in avoiding infections in the adductor wound. It is important to prevent the deep hematoma from leaking out into the wound and becoming secondarily infected. It is also crucial to keep a sterile, sealed dressing in place using an adhesive-backed plastic for the first 5 to 7 days postoperatively so the adductor wound does not become soiled with stool or urine. The main reason deep wound infections occur in revision surgery is that there is often a great deal of scar with no good fascial layer, which makes good, tight closure at the conclusion of the procedure much more difficult. There is often much more aggressive release required as well, which puts more tension on the closed skin wound.

Adductor Wound Infections

If a deep wound infection occurs with gross purulent drainage from the deep muscle lengthening site, the children should be returned to the operating room and the wound opened widely, debrided, and irrigated. If there is significant necrotic tissue that cannot be debrided, the wound should be packed with an iodine-soaked solution, and then these children must be returned again for a dressing change in 48 hours. When the wound has good, clean tissue, the skin and subcutaneous tissue can be closed tightly in one layer with nonabsorbable sutures. The deep wound dead space should be closed using a suction drain, which is brought out distally in the medial thigh. These drains should be attached to constant suction; we have not used any irrigation. Usually, the drainage decreases significantly after 24 to 48 hours; however, the drain should be left in place until there is almost no drainage at all. This often requires 3 to 5 days, but the drain should not be left in longer than 7 days because of the risk of secondary infection. Throughout this process, children should be treated with intravenous antibiotics based on the culture results from the wound. Antibiotics are used for approximately 7 days after the drain is removed. Although we have never seen a deep wound infection from a pelvic osteotomy, if it should occur, the same approach for treating that wound is recommended.

Femoral Osteotomy Infections

Deep wound infections at the site of the femoral osteotomy are much more common, occurring in approximately 2% of femoral osteotomies at our facility.^{13, 109} Most of these infections occur in nonambulatory children who are very thin. When it is clear that there is a deep infection, the wound should be opened widely and treated with dressing changes, usually starting with an iodine-soaked dressing, and antibiotics. If children present with only local symptoms with a wound that is opening and freely draining with minimal cellulitis and no systemic fever, the wound can be opened in the outpatient

department and dressing changes started along with oral antibiotics. If children are febrile, or have a significant local cellulitis, they should be admitted to the hospital and started on intravenous antibiotics with wound opening and packing. As the wound cellulitis resolves and the children become afebrile, they can be discharged home on the appropriate oral antibiotics as determined by the result of the wound culture. As the purulent drainage decreases, dressing changes should be switched to saline to allow the development of healthy granulation tissue. After 7 to 10 days, when the wound no longer has any cellulitis, the antibiotic may be discontinued. No attempt should be made to close this wound back over the plate, nor should the plate be removed until the osteotomy has healed. Sometimes the wound will close over on its own, but in our experience, there is a high rate of recurrent infection so long as the plate is in place.

When radiographs show adequate healing of the osteotomy site, children are brought back to the operating room and all the hardware is removed. The wound can be loosely closed, and the children are again given oral antibiotics based on the results of the culture at the time the plate is removed. Sometimes there is a significant amount of drainage and some necrotic bone, all of which can be well irrigated and cleaned out at the time of the plate removal. This drainage does not need to be treated as a deep osteomyelitis, and in every child whom we have treated following hardware removal, the wound has closed within 2 to 3 weeks. We have never seen a recurrent infection. After the wound has closed completely, usually in 2 to 3 weeks, the oral antibiotics are discontinued. We have never seen a child in whom the osteotomy would not heal, even if the wound was left open with an exposed plate. However, these children are often uncomfortable while the plate is exposed, especially with range of motion and ambulation. It is important to continue maintaining and gaining range of motion and pushing the children into ambulation, standing, and walking as much as they will tolerate. This movement helps with the healing process of the bone.

Femoral Osteotomy Nonunions

Nonunions of the femoral osteotomy, using the described technique,¹⁰⁹ occur in approximately 1 in 300 osteotomies based on our experience. Approximately the same number of recognized delayed unions occur. There is no definite pattern of occurrence; however, there are several important factors that will help avoid nonunions. First, it is important to use a large enough plate so that it will not fail by breaking or pulling free of the bone before the union occurs. Good compression of the medial cortex at the time of the internal fixation must be ensured, and there should always be at least good opposition of the medial cortex with slight medialization of the distal fragment. Importantly, the distal fragment should not be allowed to lateralize because this provides for a very poor mechanical construct (Case 10.37). Delayed unions, when they occur, usually require approximately 6 months to go to union. There is no definite time for determining that a delayed union has become a nonunion; however, a good rule is that children should have asymptomatic union by 6 months postoperatively (Case 10.37).

Assuming that there should be an asymptomatic union of the bone by 6 months postoperatively, a cutoff point was arbitrarily chosen to make the diagnosis of a nonunion. This cutoff point is any child whose femoral osteotomy site has continued evidence of nonhealing on radiographs and is symptomatic. If nonunion occurs, the children are returned to the operating room where the plate is removed, and a larger or more stable plate inserted



Case 10.37 Jose

Jose, a 6 year-old-boy with spastic diplegia, ambulated with a posterior walker and had severe internal rotation coming from femoral anteversion. Femoral derotation osteotomies were performed. By 1 month following the surgery, he was back to using the walker for slow ambulation. After 3 months, he was comfortable weight bearing on the left side but complained of pain on the right hip. Radiographs demonstrated good healing of the left femur, but the right proximal femur appeared to be moving into slight varus; however, the plate felt stable on physical examination and there was no pain with range of motion (Figure C10.37.1). At that time, we stopped the physical therapy for 6 weeks and allowed him to walk when he wanted to. His mother was encouraged to allow him to do some household ambulation but not push him. Radiographs after 6 weeks showed improving callus with no further varus angulation and no pain on physical examination (Figure C10.37.2). Physical therapy was again started with the goal of increasing his ambulation, and by 8 months he was pain free and the radiographs showed full consolidation of the callus (Figure C10.37.3). The main reason for the development of this delayed union was lateralization of the distal fragment, which did not provide good medial calcar compression and, therefore, the tension loading of the plate converted into a loading bearing device for which it was not designed.

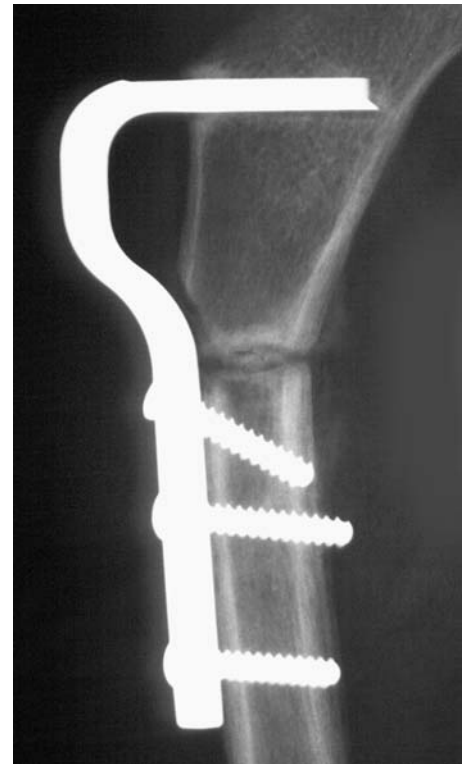


Figure C10.37.1

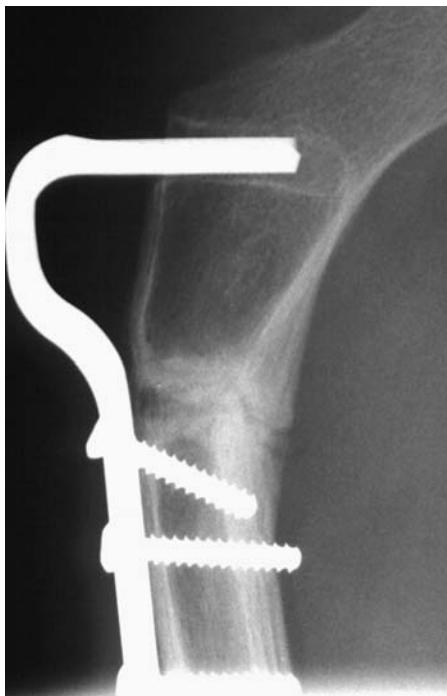


Figure C10.37.2

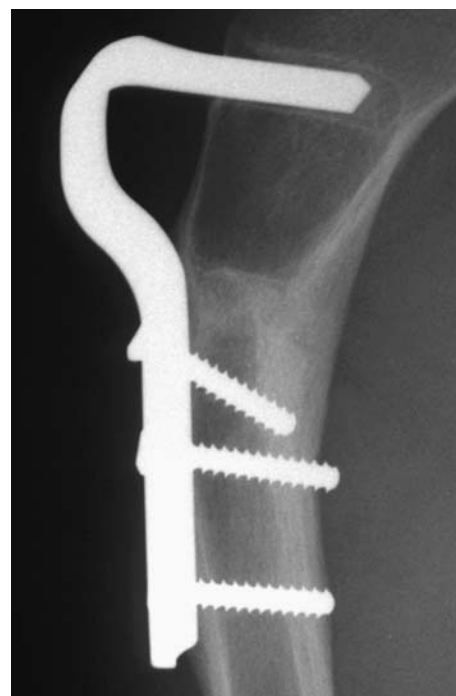

Figure C10.37.3

with strong compression, followed by bone grafting along the anteromedial aspect of the osteotomy site. Taking down a fibrous nonunion is not recommended, and the nonunions that we treated have healed well with just repeat compression and applying anteromedial bone grafting. We used crushed bank bone; however, the use of iliac crest bone may provide better osteogenic potential. The important aspect of this treatment is the proper rigid internal fixation with compression and returning the children to weightbearing status. Some parents will be hesitant to push their children back into standing because they may believe some of the problem was caused by weight bearing. However, most of the delayed unions and nonunions occur because of technical errors at the time the osteotomy was performed and not because of the children's activity.

Fractures of the Femur

Fractures of the proximal femur that occur as a complication of femoral osteotomy are most common surrounding the blade plates. These fractures may be acute fractures or bone failures, or fractures occurring from stress risers with the plate in place and a healed osteotomy. Occasionally, a fracture may also occur after plate removal.

Acute fractures are defined as occurring before the osteotomy union is solid. In our experience, these fractures occur in approximately 1 in 200 osteotomies and, in almost every case, are due to technical errors at the time of the osteotomy.

Fixation Failure

Failure of the proximal fixation may occur when the plate pulls out of the proximal fragment, as may occur if a plate that is too small is used. A plate may occasionally pull out in children who also have severe osteoporosis and in whom the next larger plate is too large. In general, this situation should be recognized at the time of the initial procedure and should be addressed before the wound is closed. If the largest size plate possible is placed into the femoral neck and it still continues to be loose, then the fixation should include the addition of a cerclage wire with a longitudinal K-wire to hold the plate in the proximal fragment. After the plate is inserted and before the wound is closed, the plate should be pulled to make sure that it does not come out laterally very easily.

If the osteotomy is made too close to the insertion of the blade plate, there may be a fracture of the lateral bridge of the proximal fragment (Case 10.38). This fracture can be avoided by ensuring that there is an adequate lateral bridge or ensuring that the distance from the insertion of the blade plate to the osteotomy site is wide enough. A common error is measuring the hypotenuse of this triangle instead of its direct right angle leg and thereby getting a lateral bridge that is too narrow. The fixation of the blade plate requires a strong lateral cortical buttress against which compression can be applied. If a lateral fracture occurs and there is room in the femur, the blade plate should be moved more proximally and placed into the center of the femoral neck as far as possible into the femoral head. Often, this means that a plate with more added valgus has to be used and a lateral cerclage wire is generally required because there is not enough lateral bone for the compression. It is important for surgeons to remember that the blade plates may be bent into more of a valgus position if the need arises. The problem with putting too much valgus into the plates, however, is that the ability to compress the osteotomy site, which is important to prevent nonunions, is lost. This is why these plates are made only in 90° and 100° angles.



Case 10.38 Darris

Darris, an 11-year-old boy with spastic diplegia, was seen with in-toeing due to increased anteversion. A derotational proximal femoral osteotomy was performed (Figure C10.38.1). He did well postoperatively, being mobilized to ambulatory weight bearing as tolerated using a walker. Ten days after surgery when he was at home, he

tripped slightly and felt a severe pain in his hip. A radiograph was obtained that showed a proximal femoral fracture (Figure C10.38.2). The immediate postoperative radiographs were carefully reviewed and showed an osteotomy site that was too close to the blade insertion, therefore making the lateral femoral bone support too narrow. The insertion site should be in the area between the two lateral bends in the plate (Figure C10.38.1, *yellow area*).

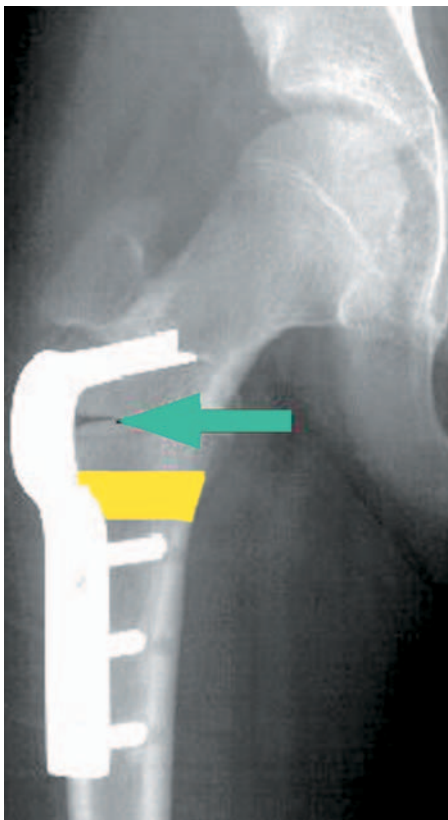


Figure C10.38.1

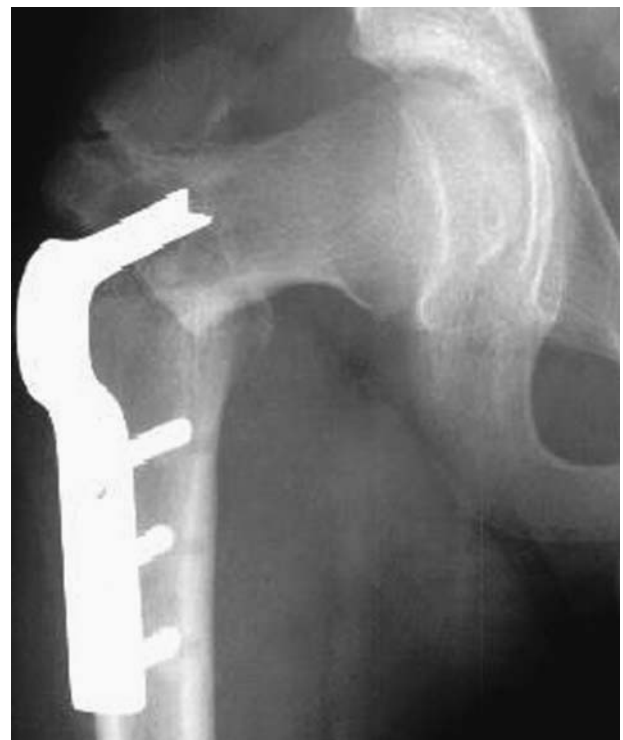

Figure C10.38.2

Trochanteric Fracture

Fracture of the greater trochanter occurs when the insertion point of the blade is into or too close to the apophysis of the greater trochanter. The fracture may then propagate into the femoral head, with a fragment of the femoral head and neck and trochanter elevating, or only the greater trochanter may fracture free of the plate (Case 10.39). This fracture can be avoided by never inserting the blade into the apophysis of the greater trochanter and by always staying in or below the subchondral bone of the greater trochanteric apophysis. If the fracture goes into the greater trochanter only, and the greater



Case 10.39 Shauna

Shauna, a 12-year-old girl with severe diplegia, was a household ambulator with a posterior walker. She developed a left hip dysplasia that slowly progressed and was believed to merit hip reconstruction. Because of significant leg lengthening discrepancy, she also had a femoral shortening osteotomy on the right side. Although she was moderately obese, the operative procedure and postoperative course went well until the fifth day postoperatively, when the physical therapist reported increased pain with movements of getting her from the bed to chair. A physical examination demonstrated increased pain and an external rotation deformity of the femur indicating a probable fracture. The radiograph demonstrated a fracture proximal to the blade (Figure C10.39.1). This left the femur with a free femoral head and trochanter (Figure C10.39.1, #1), and two separate pieces (Figure C10.39.1, #2 and #3) still stabilized with the plate. The cause of this fracture was a technical error of placing the blade insertion site into the trochanteric apophysis and possibly not inserting the plate blade in the same anteroposterior track

as the chisel, which can have the effect of cutting off the femoral neck. This created a very demanding three-part fracture situation that we resolved with a removal of the plate, then fixed the distal two fragments with a small anterior plate (Figure C10.39.2A). A new plate was bent to the intended degree of varus, approximately 120°, and was inserted parallel to the femoral neck until it was just short of the epiphysis (Figure C10.39.2B). This was followed by a cancellous screw inserted above the plate chisel so it got good bone hold right up to the epiphysis (Figure C10.39.2C). A tension band wire was then inserted through the greater trochanter, pulled down, and twisted around the screw, and then brought through a small hole drilled anterior to posterior in the distal fragment (Figure C10.39.2D). The blade was then fixed with new screws in the distal fragment. The tension band wire was tightened so it was lateral to the plate. In this way, it helped prevent the plate from backing out (Figure C10.39.3). A single leg spica cast was used to support the construct until there was early callus formation; however, if a

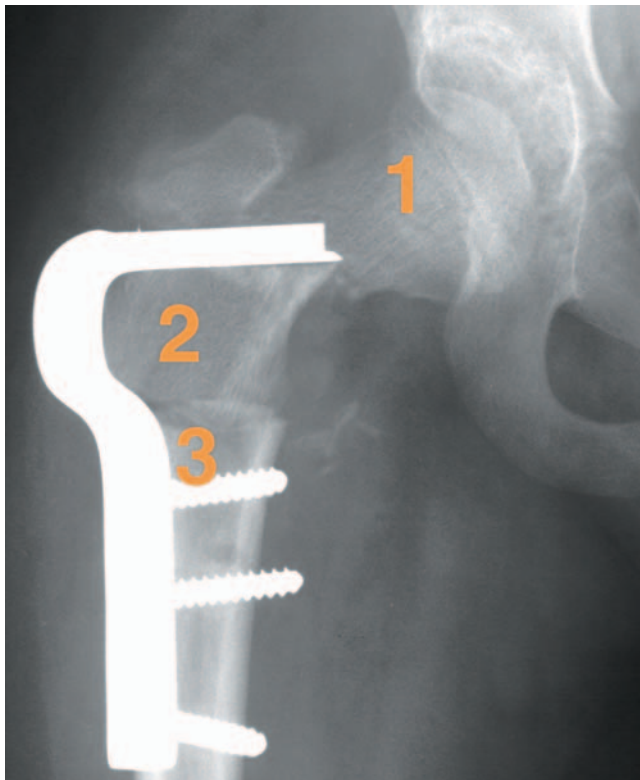


Figure C10.39.1

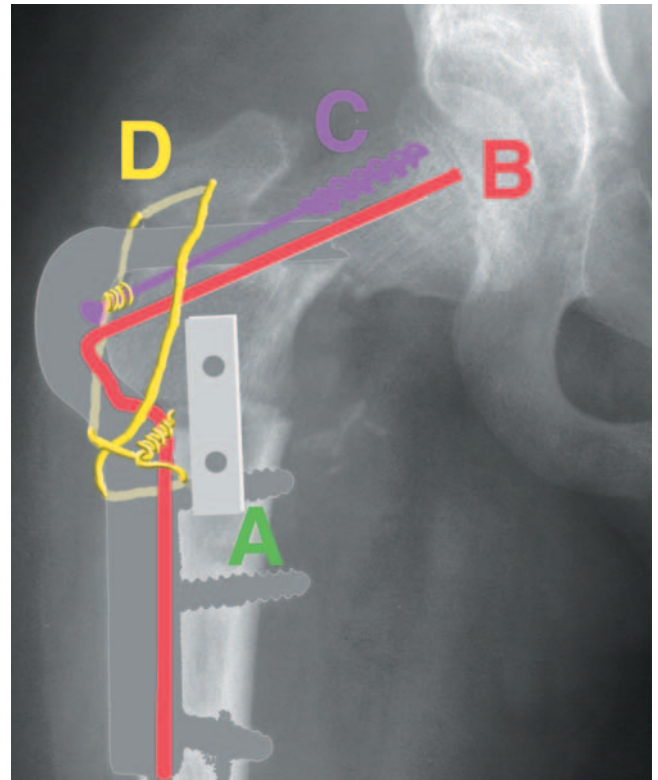


Figure C10.39.2

construct feels stable, no cast may be needed. This patient developed a wound infection and had the hardware removed after the osteotomy was healed (Figure

C10.39.4). This is a rare complication; however, the outcome tends to be good if the deformity is appropriately fixed and healing is obtained.

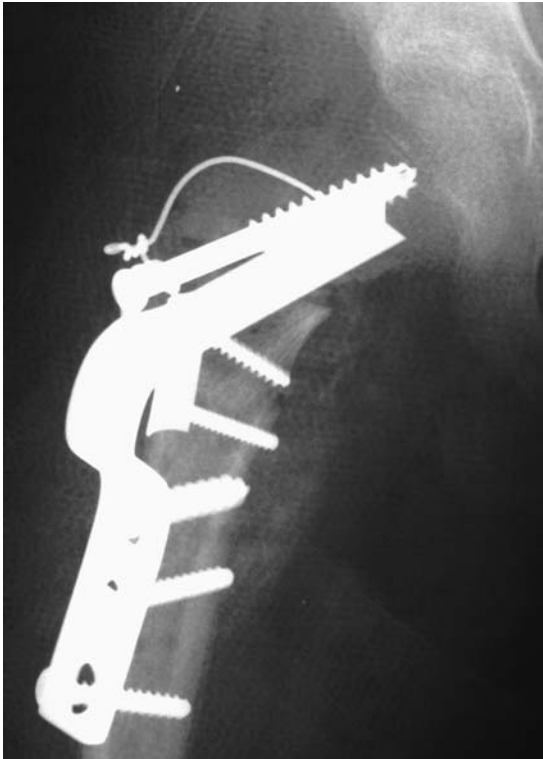

Figure C10.39.3

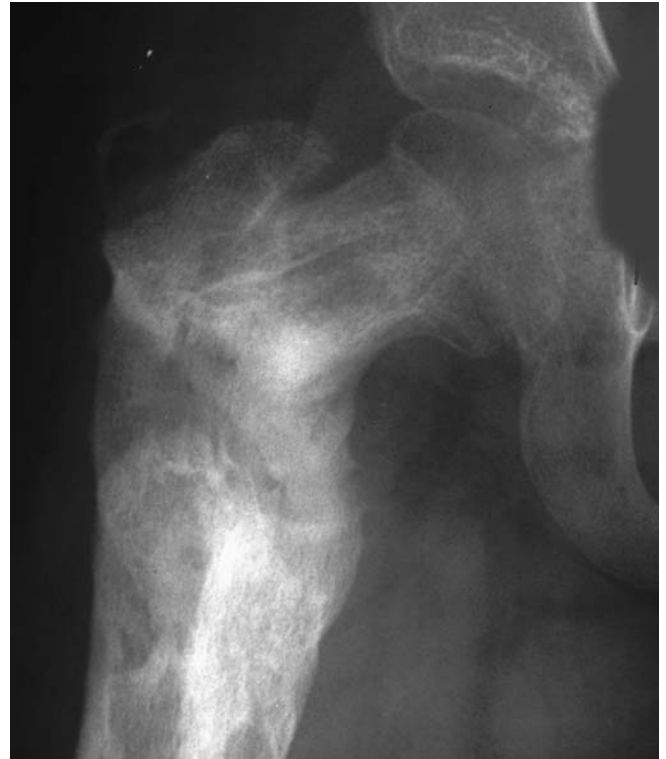

Figure C10.39.4

trochanter lifts off significantly, it can be repaired by an open reduction using cerclage wires or cables to bring the trochanter back down to the plate. However, if the fracture propagates into the femoral neck and head, such that the proximal fragment includes a component of the femoral neck and head with the greater trochanter, an open reduction with exchange of the plate is required. In this open reduction and plate exchange, screws are placed into the proximal fragment and a new plate is inserted, usually in a much more valgus position, into the femoral head along with lateral cerclage wires. This open reduction is somewhat complicated to perform and it is often helpful to have the middle piece between the proximal fracture and the distal osteotomy fixed to the distal fragment using a small anterior plate. This fracture should be diligently avoided by ensuring that entering too far proximally into the apophysis of the greater trochanter does not occur.

Distal End of Plate Fractures

Fractures of the distal fixation occur when the screws pull out of the bone. This failure can be repaired by shortening the distal fragment an additional 5 to 10 ml, providing new bone to put new holes. Additionally, if the bone is very osteoporotic, cancellous screws may be utilized to get better fixation and, occasionally, a nut on the cortical screw can be used medially to ensure

there is good fixation in the bone. Occasionally, a fracture may develop in the proximal fragment that propagates along the distal or middle screws. This situation leaves a two-fragment fracture with the blade plate and its osteotomy fixation intact, but with a fracture just below the plate. Most of these fractures should be treated by open reduction using either anterior plates or interfragmentary screws (Case 10.40). Occasionally, flexible nails, which are passed in the intermedullary region around the screws, may be used (Figure 10.21).

Later fractures that occur as stress risers from the plate site with the blade plate in place should be treated with removal of the blade plate and repeat open reduction with a device most appropriate for the fracture pattern. Likewise, fractures immediately after plate removal should be treated as de nova fractures and usually require an open reduction or internal fixation with



Case 10.40 Samuel

Samuel, a 15-year-old boy with mild diplegia and severe mental retardation, presented with his mother complaining that he had refused to walk for the past 3 months. Before this time, he was a full community ambulator, although she noticed that he had slowed down over the past year. This slowdown was attributed to his rapid growth. He expressed no complaint of pain. On physical examination he had full range of motion of the right hip; however, there seemed to be some discomfort. When he tried to stand, he would put no weight on the leg. A radiograph demonstrated a subluxated hip, which was reconstructed with a femoral osteotomy and peri-iliac pelvic osteotomy (Figure C10.40.1). He was discharged home with instructions for physical therapy to start gait training. Two weeks later, his mother returned him to the clinic and said she found him in bed with the leg hung through the bedside rails. He did not express much discomfort but his mother felt the leg looked different after she got him out of the side rail. On physical examination his leg was short and externally rotated. A radiograph demonstrated a fracture through the proximal screw holes in a long oblique pattern (Figure C10.40.2). He was returned to the operating room for an open reduction with intrafragmentary screws and then placed in a cast for 8 weeks. By 6 months after surgery, he was again an independent community ambulator, and by the second-year follow-up, his hip had remodeled well (Figure C10.40.3). This case demonstrates the difficulty in assessing pain level in some individuals with mental retardation and the care that has to be taken to address deformity concerns.

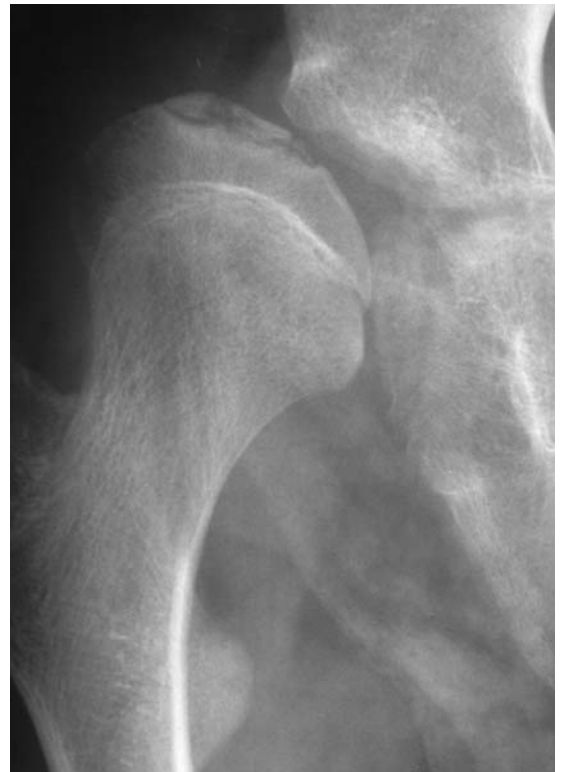

Figure C10.40.1

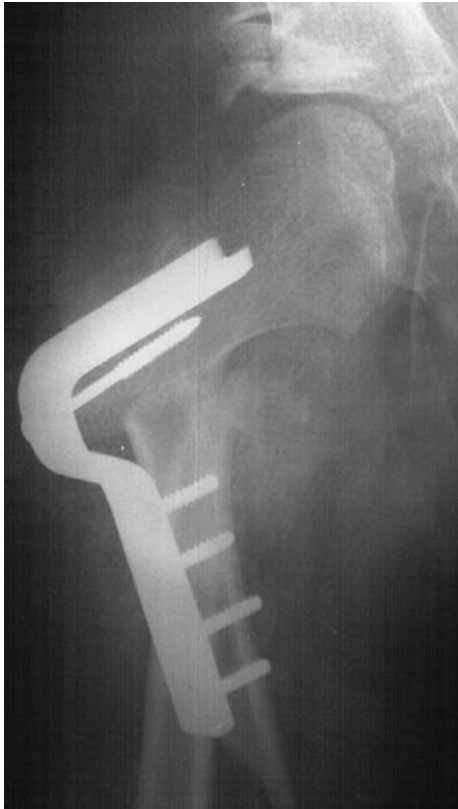

Figure C10.40.2

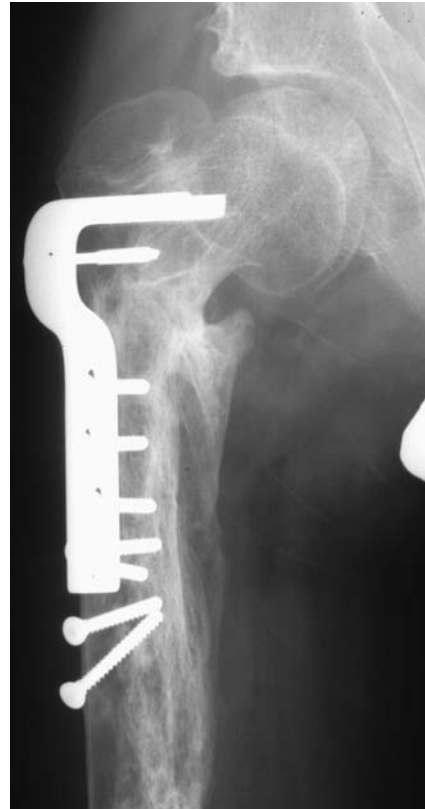

Figure C10.40.3

repeat plating, or occasionally the use of intermedullary flexible nails. It is crucial to ensure that the proximal fragment is not allowed to fall into too much varus or lose the derotation that had been obtained.

Recurrent Contracture and Dislocation

The incidence of recurrent dislocation varies greatly based on the specific procedure. Failure rates with the recommended peri-iliac osteotomy, varus derotation, and soft-tissue lengthenings vary from 0% to 4% on long-term follow-up.^{13, 56} Recurrent dislocations are related to the severity of the acetabular deformity and the development of severe recurrent contractures over time. It is very important to continue following the children, and if they start to develop recurrent fixed contractures, these need to be addressed with repeat soft-tissue lengthenings. Also, the redislocation rate is much higher for hypotonic hips, and a different level of skepticism toward the results needs to be communicated to the parents (Case 10.35).

If the recurrent dislocation occurs early, in the first 4 weeks postoperatively, a very careful assessment of the surgery and why the dislocation occurred is required. If the redislocation results from such severe acetabular deficiency that the reconstruction could not adequately recreate a stable acetabulum, then further attempts to provide a stable reduction should be postponed until these children are rehabilitated. If the hip then becomes painful, it would be treated with a palliative approach. However, if children with spastic hip dislocation had a successful reconstruction and years later developed a recurrent adduction and hip flexion contracture followed by a hip

subluxation or dislocation, the treatment regimen should be quite different. In general, as these patients are followed, as soon as their maximum abduction is less than 0° , a repeat adductor lengthening should be performed. Similarly, a second bony reconstruction should be considered when the hip migration percentage becomes greater than 40% (Case 10.13).

Recurrent, complete full dislocations are more common in children who have anterior dislocations or a hypotonic pattern of dislocation. We have treated two children with a hypotonic anterior dislocation who required a second acetabular reconstruction, and both have remained located and ambulatory over more than 5-year follow-up. Although very rare in children with CP, direct posterior dislocations also have a high rate of recurrence after the peri-iliac osteotomy. Reconstruction of a direct posterior dislocation can be accomplished using a posterior pelvic osteotomy and/or shelf arthroplasty or only bone graft, which is fixed to the acetabulum with screws. Primary and recurrent direct posterior and posteroinferior dislocations are much more common in spastic incomplete spinal cord injuries. If there is significant spasticity present in children with spinal cord injury as the etiology of the spasticity, there needs to be awareness of a much higher incidence of repeat dislocation. This higher incidence probably results from having little strength in the gluteus maximus.

Leg Length Discrepancy

Leg length discrepancy secondary to problems of the hip may be due to asymmetric contracture of hip muscles, asymmetric varus osteotomy, hip subluxation or dislocation, or suprapelvic pelvic obliquity.

Caused by Adductor Contracture

A very common cause of perceived leg length discrepancy occurs secondary to asymmetric contracture of the hip abductors or adductors. This contracture leads to sitting or standing positions in which a great limb length discrepancy is apparent. When this contracture is mild, it is often better to not accommodate the contracture in seating with asymmetric wedges or in standing with a shoe lift. As these contractures and apparent limb length discrepancies get more severe, some accommodation with mild shoe lifts may be needed. In general, no more than half of the apparent limb length discrepancy should be corrected, because if too much correction is made more rapid development of more asymmetry is fostered. Likewise, in seating, if children develop an apparent limb length discrepancy, some of the adduction and contralateral abduction to keep them sitting in a fairly neutral position should be accommodated. If an attempt is made to keep the legs in a perceived normal position, the pelvis and trunk will often rotate, causing the abducted side to rotate forward so that these children are sitting in a sideways position in the wheelchair. As these asymmetries become more functionally significant, they need to be addressed with soft-tissue releases.

Secondary to Varus Osteotomy

The best treatment of limb length discrepancy occurring secondary to a unilateral varus osteotomy is avoiding doing unilateral osteotomies. Almost all children should have symmetric surgery; however, a derotational osteotomy, in which some inadvertent varus was obtained, may occasionally be performed unilaterally. This inadvertent varus is typically less than 1 cm and should not cause any functional difficulty. Sometimes, however, this slight limb length discrepancy from the varus osteotomy may be magnified by asymmetric adduction contracture and will need to be accommodated. If a

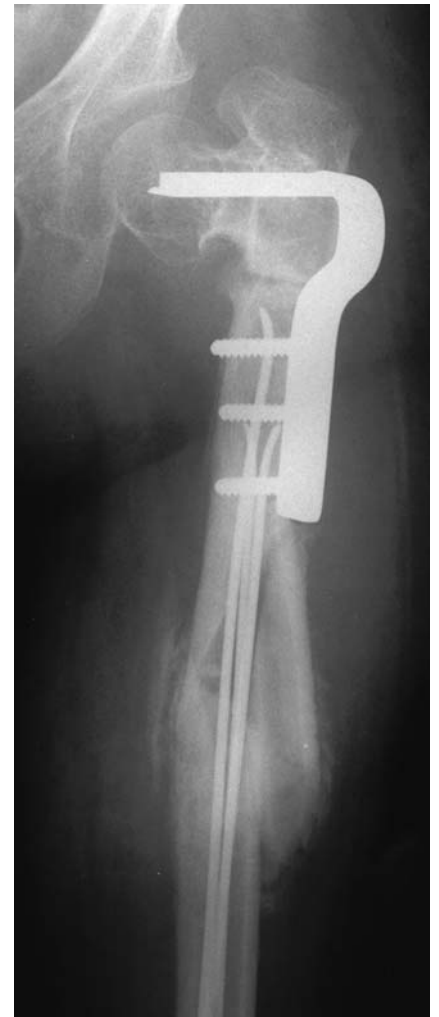

Figure 10.21. Fractures of the femoral shaft below the instrumentation are most common. This fracture occurred 8 weeks after a proximal femoral osteotomy, and the osteotomy was not thought to have enough healing to allow removal of the blade plate. An excellent alternative is to introduce flexible nails, which can be passed up the femoral canal past the screws from the blade plate. Maintenance of length and stability was desired in this girl, who could do weightbearing transfers. No cast immobilization was used.

major asymmetric varus osteotomy was performed, there may be as much as 3 to 4 cm of limb length discrepancy. This degree of limb length discrepancy has to be addressed for standing with the use of a major shoe lift and in sitting with a cutout of the seat. If this discrepancy occurs in young growing children, the leg length discrepancy is equalized by contralateral femoral epiphyseodesis after careful monitoring with scanograms. However, it is difficult to predict precisely how much remaining growth is present in non-ambulatory children. Another option to gain leg length equality is a varus shortening osteotomy on the long side.

Dislocated Hip

Leg length discrepancy may be a sign of a dislocated or subluxated hip, which should be ruled out with an appropriate radiograph. When hip dislocation is causing limb length discrepancy, the hip needs to be treated according to the indications for treatment previously discussed.

Pelvic Obliquity

Leg length discrepancy secondary to pelvic obliquity may be caused by asymmetric contractures in the windblown deformity. However, this discrepancy also occurs as a suprapelvic pelvic obliquity coming from significant scoliosis. In general, children with CP who develop a suprapelvic pelvic obliquity actually tend to lean into the scoliosis in such a way that the pelvis may be relatively straight when they are sitting. Seat cutouts may often be required. Other adaptive mechanisms to accommodate this pelvic obliquity may also be required until the discrepancy is surgically corrected.

Heterotopic Ossification

Heterotopic ossification in children with CP has been a problem only at the hip. It tends to occur after hip surgery, especially if the hip surgery is done concurrently with or in close proximity to spine surgery. Ossification of the hip has been reported to occur following hip surgery that is concurrent with spinal fusion¹¹⁰ or dorsal rhizotomy.¹¹¹ In rare situations, heterotopic ossification may develop in hips after spinal fusion with no concurrent hip surgery.¹¹⁰ This ossification occurred in two children whom we have seen, and it tends to lead to severe heterotopic ossification and complete fusion of the hip joint.

After Adductor Lengthening

Heterotopic ossification after adductor, iliopsoas, and proximal hamstring lengthening is extremely common. The most common source of this heterotopic ossification is along the tendon sheath of the iliopsoas. This ossification is rarely a clinical problem; however, there may be some prolonged discomfort for 3 to 4 months as the heterotopic ossification matures. Some children will have pain longer during active range of motion, especially with forced hip flexion. A very long, thin piece of heterotopic bone may develop in the sheath of the iliopsoas in some of these children, and we have seen several in whom a fracture of this long piece of heterotopic ossification developed. When this fracture develops, it often causes pain or discomfort for approximately 3 or 4 weeks and then resolves. The heterotopic ossification of the iliopsoas rarely requires any supportive or interventional treatment beyond using occasional acetaminophen or ibuprofen for pain control and continuing with gentle range of motion. Heterotopic ossification in the iliopsoas tendon sheath can be decreased by ensuring that the tenotomy is performed well away from the apophysis of the lesser trochanter.

When heterotopic ossification occurs at the site of the proximal hamstring lengthening, it is usually much more severe and somewhat more difficult to treat, but fortunately it is also much more rare.¹¹² These children's hips are often very painful for no apparent reason, but a workup including a bone scan will show the development of substantial heterotopic ossification. The typical scenario is children who, at 4 to 6 weeks postoperatively, have a normal radiograph but are continuing to have severe pain at the hip with any activity. A bone scan, which should often be obtained at this time, may confirm the heterotopic ossification by showing very hot uptake in the area of the surgery site (Case 10.41). At the time when the bone scan is hot but the radiograph is normal, there is no benefit from the use of diphosphonates or radiation because the process is already too far along. These children instead should be started on maximum antiinflammatories, usually using ibuprofen or naproxen. Although indomethacin may be better for treating heterotopic ossification, it is not approved for use in children and is not sufficiently better than approved drugs.

Often, the discomfort will make sleeping and eating difficult. During the most acutely painful phase, a narcotic analgesic such as acetaminophen with codeine or oxycodone may be needed. An additional moderate to high dose of diazepam is required to decrease any signs of spasticity so that the muscles will stay relaxed and will not further irritate the heterotopic ossification. After 8 to 10 weeks, this discomfort should start to diminish and the medication, especially the narcotics and diazepam, should be weaned. If children are still having problems at this point, an antidepressant, usually amitriptyline hydrochloride (Elavil), should be started. Amitriptyline is an excellent drug to promote pain control and improve sleep and general attitude. During this period, gentle range of motion should be performed as much as possible to avoid the development of a fused hip. Gradually, as the active process decreases and if the hip has not gone on to full fusion, the hip range of motion should start increasing (Case 10.41).

Other common situations in which heterotopic ossification may occur are associated with proximal femoral resections,^{81, 82, 84, 113} adductor lengthenings,¹¹⁴ exuberant callus at a femoral osteotomy site,¹¹¹ and along the capsulotomy site following femoral reduction. The gluteal fossa of the ilium may also develop heterotopic ossification after perforation of the ilium with the pelvic end of a spinal rod.

Prophylactic Treatment of Heterotopic Ossification

One specific recommendation for prevention of heterotopic ossification is avoiding concomitant hip surgery with spine surgery.^{110, 111} Either a release of some factors from the spine surgery area or the magnitude of the procedure increases the incidence of hip ossification. Removing lateral blade plates at the time of spine surgery is appropriate; however, no other hip surgery should be performed for at least 4 months following spinal fusion or dorsal rhizotomy. After 4 months, the risk of heterotopic ossification diminishes. We have not seen any increased risk of heterotopic ossification in hip surgery if it is performed 4 months or later following spinal surgery.

It is not clear if there are children who might benefit from other prophylactic treatments of heterotopic ossification. Children who have developed heterotopic ossification from muscle surgery and are now required to have more substantial hip surgery, such as femoral resection, are at very high risk for developing significant heterotopic ossification. For these children, prophylactic radiation treatment on postoperative day 1 or 2 may be considered. It is difficult to identify exactly which of these children will develop significant symptomatic heterotopic ossification. We have no experience using



Case 10.41 Nathan

Nathan, 12-year-old boy with severe diplegia and mild mental retardation, was noted to have hip adduction of only 15° bilaterally and a popliteal angle of 70° . Because he was moderately obese, perineal care was difficult. Adductor and proximal hamstring lengthening was performed to aid in perineal access to improve custodial care. Four weeks after surgery, his mother complained that he refused to eat, would not sleep, and seemed in pain with any movement of his hips. On physical examination, swelling and mild erythema was noted in the proximal thigh. It was extremely painful to do any hip movement. A radiograph that was thought to be normal was obtained

(Figure C10.41.1). Because of the severe pain, a bone scan was obtained that showed severe early heterotopic ossification (Figure C10.41.2). He was then started on anti-inflammatories, amitriptyline, and very gentle and mild range of motion. Over the next 3 months, the pain gradually decreased, and as the pain decreased, hip range of motion slowly increased even though the radiograph showed more ossification (Figure C10.41.3). The range of motion increased to a very functional level and slowly the ossification had some resorption. By 7 years after the muscle surgery, the ossification was still visible (Figure C10.41.4); however, he had almost full hip range of motion.

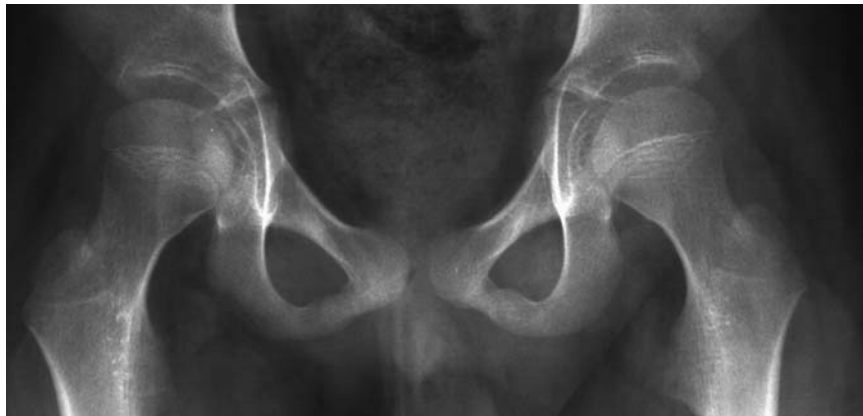

Figure C10.41.1

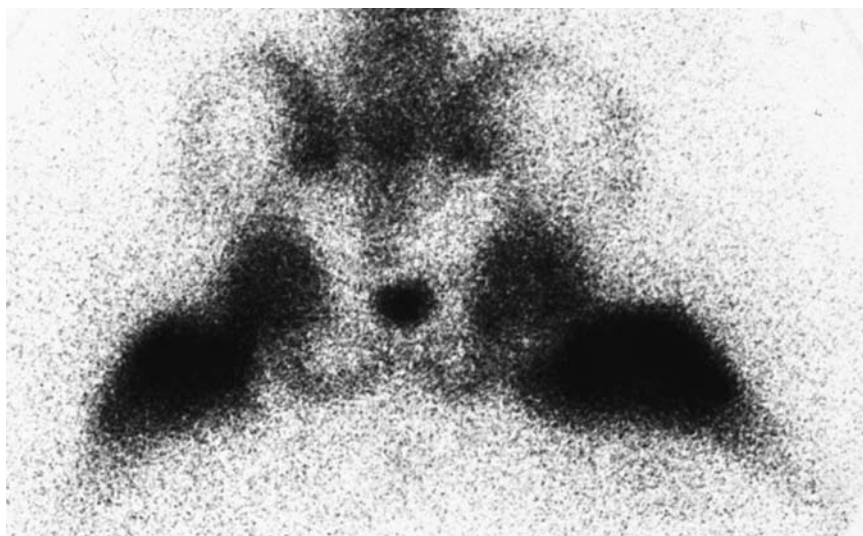


Figure C10.41.2

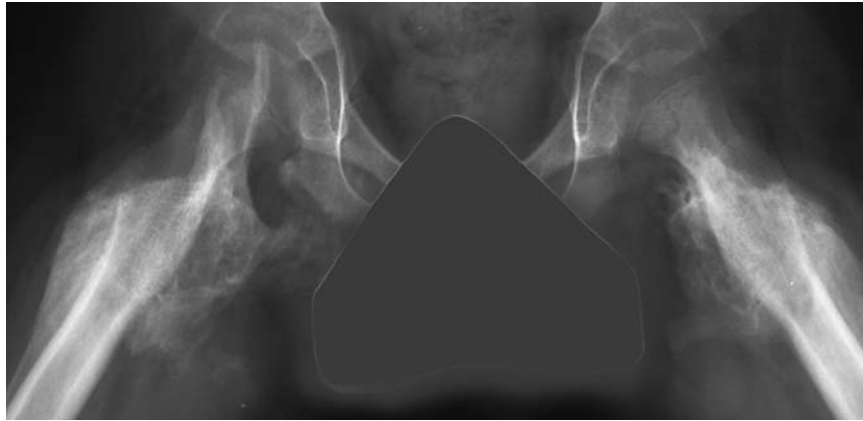


Figure C10.41.3

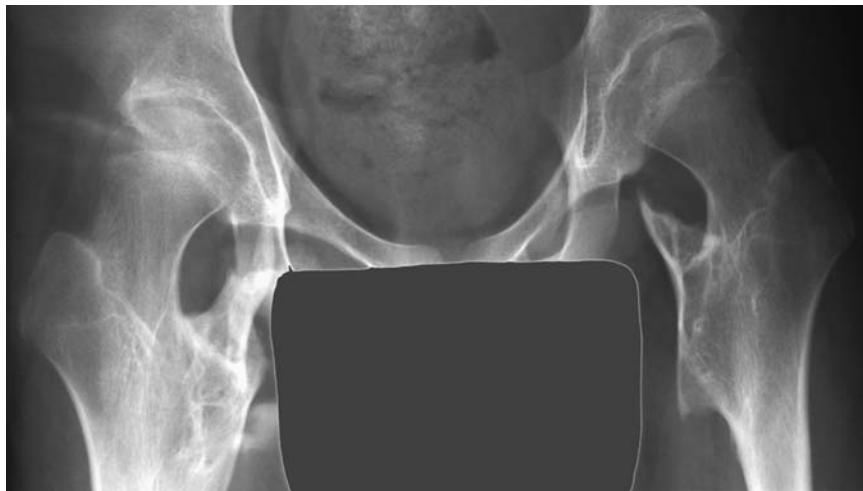

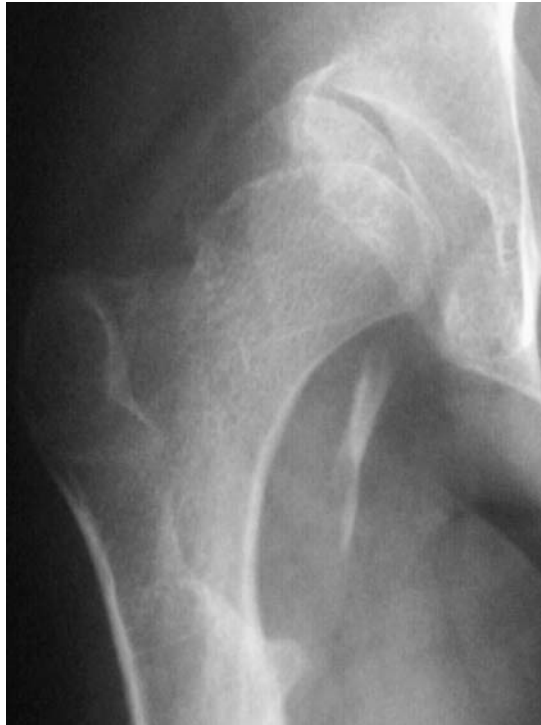Figure C10.41.4

diphosphonates and, based on published data, we are not very optimistic that they would be useful.^{115, 116}

Treatment

Most children who develop heterotopic ossification, especially those who develop the strands of ossification along the iliopsoas, will need no treatment after it has matured. These children will have unlimited range of motion and no pain (Figure 10.22). Significant heterotopic ossification rarely occurs in proximal hamstring lengthening and may look very severe radiographically; however, if the hip does not go on to fusion, it tends to resolve gradually and seldom causes any problems or requires treatment (Case 10.41). The same is true for those children who develop extremely exuberant callus in conjunction with femoral osteotomy, pericapsular ossification, or ossification secondary to proximal femoral resection. Indications for surgical resection of the heterotopic ossification should include decreased range of motion or lesions that cause persistent pain after maturation. Surgical excision can be planned after maturity of the heterotopic ossification lesion is demonstrated by having a bone scan, usually approximately 1 year after onset, with activity

Figure 10.22. A small, thin amount of heterotopic ossification may develop in the iliopsoas tendon after myofascial recession. This seldom causes any pain; however, occasionally in a very active child this small wisp of bone can fracture and cause hip pain for 4 to 6 weeks until it heals. No immobilization is needed.



that is equal to surrounding bone.¹¹⁷ After the surgical excision, the site should be treated with radiation either using a 600-rad single dose on postoperative day 1 or 2, or two doses of 400 rads each on postoperative days 2 and 3.¹¹⁸ There are currently no good data that demonstrate the effectiveness of this type of radiation treatment in children with CP; however, in our experience, the outcome is excellent with no recurrence of the heterotopic ossification after resecting small lesions from the ilium. For large lesions, especially those that involve a hip fusion, there is a remarkable tendency for the heterotopic ossification to slowly return in spite of this radiation treatment. Based on the adult data, the most effective preventative method for avoiding recurrent heterotopic ossification is the use of radiation, and we believe this must apply to children as well. Radiation does have long-term risks, such as the development of malignancy, which need to be considered in the balance of the risk–benefit ratio.

Postoperative Hip Pain

Hip pain is present in all children after hip surgery, and control of this pain is a mandatory part of the orthopaedic management of these children. The standard pain treatment program should anticipate that it will take 6 to 8 weeks after surgery until most of the pain is resolved. If there continues to be a significant amount of pain present by 8 to 12 weeks after hip reconstruction or muscle lengthening, the cause of this pain needs to be specifically diagnosed and treatment designed based on the diagnosis. Many potential causes of this pain can be identified.

The development of heterotopic ossification should be suspected, especially if children are continuing to have severe pain after only having muscle surgery. If radiographs are normal and heterotopic ossification is suspected, a bone scan, which will identify the early stages of heterotopic ossification, should be obtained (Case 10.41).

Plate Bursitis

Bursitis over the lateral trochanter and the lateral aspect of the blade plate can be identified by the presence of point tenderness in this region, especially when the hip is internally and externally rotated. If there is inflammation with erythema, a deep wound infection needs to be ruled out. If the presence of a deep wound infection is in question, the wound should be aspirated down to the plate. Chronic bursitis over the plate that develops because children have been either sitting or lying on the plate is more common. This deep wound infection or chronic bursitis tends to occur late, usually 6 to 12 months following surgery. In the acute phase, it is often just wound erythema and inflammation from high weight bearing over the prominent plate. Most typically this bursitis occurs while children are side lying, although it may also occur when they are sitting. In this instance, careful physical examination of children lying supine and side lying, and then sitting in the typical wheelchair posture, is very important to determine where the problem is occurring. The posture then needs to be addressed with appropriate relief. If difficulty with posture results from seating, seating adaptations such as seating wedges are necessary. If problems with posture are coming from the side lying position, caretakers should be given instructions on using a blanket roll under the ilium as the children side lie to help lift some of the weight off the lateral aspect of the hip (Figure 10.23). If this is a chronic bursitis over the plate and the osteotomy has healed, the plate should be removed. If the plate cannot be removed immediately, the bursa can be injected with a deposteroid such as triamcinolone acetate, 40 to 80 mg.

Medial Plate Protrusion

Medial protrusion through the calcar or the femoral neck by the blade plate may cause pain by producing an iliopsoas bursitis. This bursitis is most typically a problem in children who have had derotation to improve their walking ability but continue to have increased pain 3 to 9 months after surgery and are not quite making the rehabilitation progress expected. These children typically refuse to stand with the hip fully extended. Often, the primary complaint is not pain but rather the inability to make progress in rehabilitation, especially in the ability to gain straight upright standing. On physical examination, it is often very difficult to localize the problem because when these children are relaxed they have full hip range of motion with no pain. There usually seems to be no reason why these children should not be able to make progress in rehabilitation or gain straight upright stance. Radiographs may show only some slight medial protrusion of the blade plate and, occasionally, if the rotation of the femur is not correct, this may not even show as the plate is directed slightly anteriorly. In this clinical scenario, the plate should

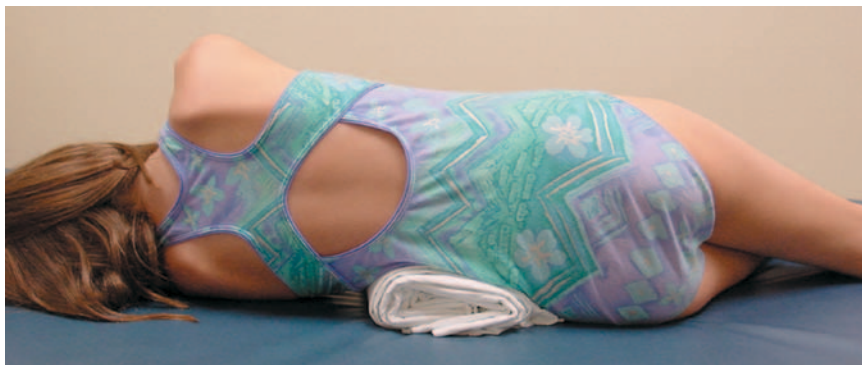

Figure 10.23. A common complaint after proximal femoral osteotomy is that the child is not comfortable side lying. An easy solution is to suggest that the caretakers roll up a soft blanket and place it just proximal to the hip joint. This usually makes the side lying much more comfortable.



Case 10.42 Gabriel

Gabriel, a 6-year-old boy with diplegia, had a femoral derotation osteotomy. He made slow progress in his recovery; however, he seemed not to be able to get back to independent standing and walking even by 1 year after surgery. Although the radiograph did not show the plate

perforating the medial cortex, it was close, and was felt to probably penetrate the femoral neck anteromedially under the iliopsoas tendon (Figure C10.42). The plate was removed and he was walking upright and independent 3 months after the surgery.

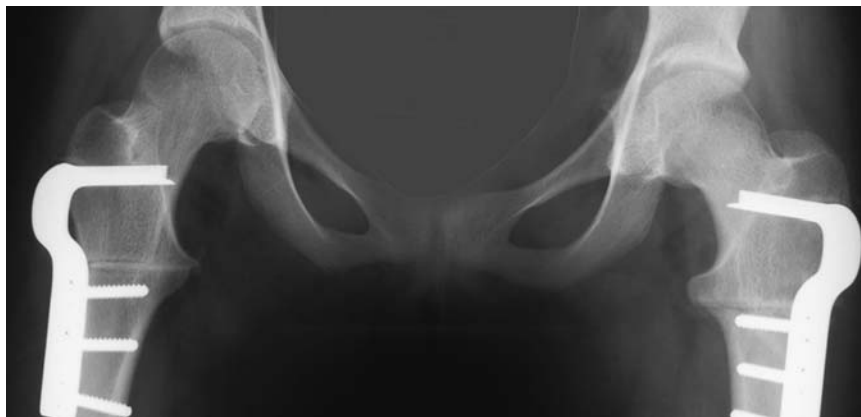

Figure C10.42

be removed once the osteotomy has healed, and in some children, dramatic progress in rehabilitation is then obtained (Case 10.42).

Degenerative Arthritis

Acute degenerative arthritis may occur and cause severe hip pain in the rehabilitation phase between 3 and 6 months following hip reconstruction. Typically, these children do as expected, gaining range of motion and improved comfort until approximately 6 to 10 weeks postoperatively, when the hip pain slowly starts getting worse. By approximately 4 months after surgery, the pain may be so severe that any movement of the hip joint causes pain. In some of these children, a small range of motion is comfortable, but as soon as the hips are moved outside this window, they are very painful. Radiographs will typically demonstrate some narrowing of the hip joint space (Case 10.15). This narrowing often occurs in children who have a small ridge identified at the level of the triradiate cartilage in the acetabulum.

During reconstruction, good coverage and reduction of the femur is obtained, but the femoral head sits somewhat laterally against this medial ridge. As the range of motion is started, this medial ridge is worn down, causing symptoms of degenerative arthritis and synovitis in the hip joint. When these symptoms are identified at the initial stage, antiinflammatory medication should be started following an antiinflammatory dose schedule usually using ibuprofen or naproxen. The hip joint should be injected with a deposteroid or 80 mg triamcinolone acetate, with a small dose of approximately 1 ml

bupivacaine hydrochloride. This local anesthetic injection will quickly demonstrate that acute degenerative arthritis is the source of the pain, as the pain should be gone for 6 to 8 hours. A significant decrease in the pain should be expected in 48 to 72 hours after steroid injection.

The hip joint injection of the steroids and bupivacaine hydrochloride can be performed in the outpatient clinic if physicians are confident that they can palpate the anatomy of the hip joint and are able to enter the hip joint. However, in older children or in children with less-clear landmarks, it is better to perform the injection in the radiography suite under fluoroscopic control. Steroids can be injected every 4 weeks for up to three injections if the pain has not made substantial improvement. At the same time, if the children are also having trouble sleeping and are eating poorly, an antidepressant, typically amitriptyline hydrochloride (Elavil) twice a day, should be started. The antidepressant will improve pain control, sleep, and general attitude.

The outcome of treatment in this scenario has a very high success rate, with complete resolution of the hip pain in 3 to 6 months. Substantial remodeling of the hip joint with recreation of hip joint space often occurs as new cartilage seems to heal in the hip joint. However, this remodeling really only works in children who have open growth plates, and we would be very hesitant to expect this kind of outcome in adults. We have had no experience using this regimen except in children with open growth plates. At 1 year after reconstruction, in spite of these problems, there is usually good recreation or maintenance of hip joint space on radiographs.

Sudden Pain in Therapy

Following hip surgery, children who are doing very well with improved range of motion and a decrease in postoperative pain may suddenly develop increased pain in physical therapy. When this sudden increased pain occurs, it is very important to do a careful physical examination to ensure that an acute fracture has not occurred. The most common site of an acute fracture following hip reconstruction is in the distal metaphysis of the femur or the proximal metaphysis of the tibia (Figure 10.24). These fractures are frequently missed by emergency room doctors and primary care physicians because families and therapists believe the pain is focused on the hip, where it has been throughout this rehabilitation phase. These fractures are especially common in children who have been in spica casts. The fractures themselves are not hard to diagnose if a careful clinical examination is performed, as there is usually obvious swelling and tenderness present in the area surrounding

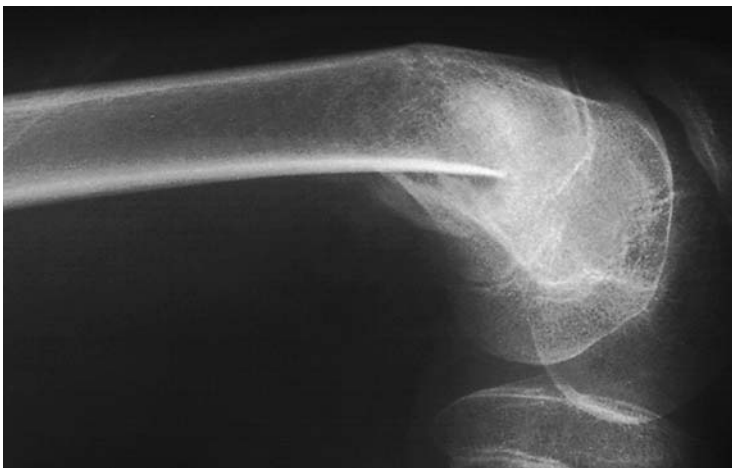

Figure 10.24. It is very important to do a careful examination of the child, as evidenced by this girl who had prolonged hip pain for 6 months requiring steroid injection. Then, 8 months postoperatively when she had been comfortable for several months, she again presented in severe pain. The parents felt the pain was due to recurrent hip pain. The local doctor obtained hip radiographs that appeared unchanged; however, when the severe pain continued for 1 week, she returned for an orthopaedic evaluation. Because of the long experience of hip pain, the resident ordered another hip radiograph that again was unchanged. A physical examination of the child was then performed and a clearly swollen and erythematous knee was noted. A radiograph demonstrated the typical insufficiency fracture.

the knee joint. However, if radiographs and physical examination do not look at the knee joint, these fractures will not be found. Occasionally, there may also be a fracture surrounding the plate, so doing a good physical examination and making a radiograph of the proximal femoral osteotomy site are also important. Another consideration, especially in the period from 4 to 9 months postoperatively, should be the possibility of a fracture of a thin piece of heterotopic ossification in the sheath of the iliopsoas. These fractures usually become painful and then resolve relatively quickly. Evulsion fractures of the lesser trochanter may also occur.

Continued or increased pain in the hip following hip reconstruction in children who are noncommunicative can be a real challenge. Caretakers often will feel that the pain is coming from the hip, but a full examination does not seem to demonstrate any evidence of pain. When pain exists in noncommunicative children, other sources of pain need to be considered and the appropriate and typical workup should then proceed.

Avascular Necrosis

Avascular necrosis has been reported following spastic hip reconstruction^{56, 119}; however, we have never seen a definite case of avascular necrosis. Both reports of avascular necrosis used cast immobilization, which may explain part of its cause. Abducting spastic hips against the spasticity has been shown to produce avascular necrosis in insensate children.¹⁷ If avascular necrosis develops, the recommended treatment is to continue with range of motion and wait for the avascular necrosis to run its course, then address the remaining residual problems (Case 10.43).

Lateral femoral head collapse may also occur when there is an insufficient capsulotomy and postoperative rehabilitation attempts to stretch the contracted medial capsule. Often, the lateral aspect of the severely subluxated femur is very osteoporotic and when high pressure is applied to this osteoporotic femoral head, it may be caused to collapse. This collapse can be prevented with an adequate medial capsulotomy to allow adequate abduction. We initially presumed that 0° of abduction was sufficient intraoperatively to not require a capsulotomy; however, we now believe that abduction to at least to 20° or 30° in the operating room is possible. This means more medial and more aggressive capsulotomies need to be performed, which has not led to avascular necrosis and has decreased the incidence of finding compression of these osteoporotic lateral femoral heads. It is impossible to ensure that some collapse of the lateral femoral head was not due to avascular necrosis; however, this collapse does not have the appearance of a full avascular necrosis as reported.⁵⁶ This may also explain why avascular necrosis occurs when these osteoporotic femoral heads are forced into the acetabulum and then held in a fixed cast, which may limit the blood flow to the femoral head. When lateral collapse occurs, it usually creates a flattening of the superolateral border of the femur, limiting abduction similar to the protrusion that becomes present in the hip of Perthes disease with lateral extrusion. If this collapse occurs and abduction becomes limited, the best treatment is to do a valgus osteotomy to accommodate the deformity.

Thrombophlebitis and Pulmonary Embolism

We have never seen children or young adults up to age 21 years with CP who have had thrombophlebitis or pulmonary embolism. There are also no reports in the literature that substantiate this occurrence. We have had two children with severe heterotopic ossification who were initially diagnosed as



Case 10.43 Jeffrey

Jeffrey, a 5-year-old boy with diplegia, was starting to ambulate. He had femoral derotation to correct severe internal rotation deformities. Postoperatively, he had prolonged increased spasticity and could not be returned to his preoperative ambulatory status. A radiograph of the hip was relatively normal (Figure C10.43.1). Five years after surgery, the hip pain increased and the radiographs showed significant evidence of avascular necrosis (Figure C10.43.2). By persisting with gentle range of motion, the hip seemed to remodel and the pain subsided (Figure C10.43.3). (Case data provided by Dr. Henry Chambers, San Diego, CA.)

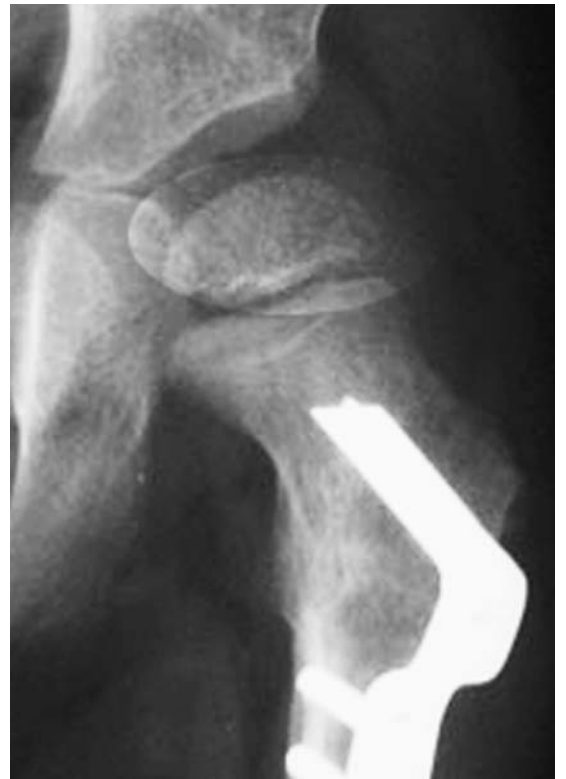

Figure C10.43.1

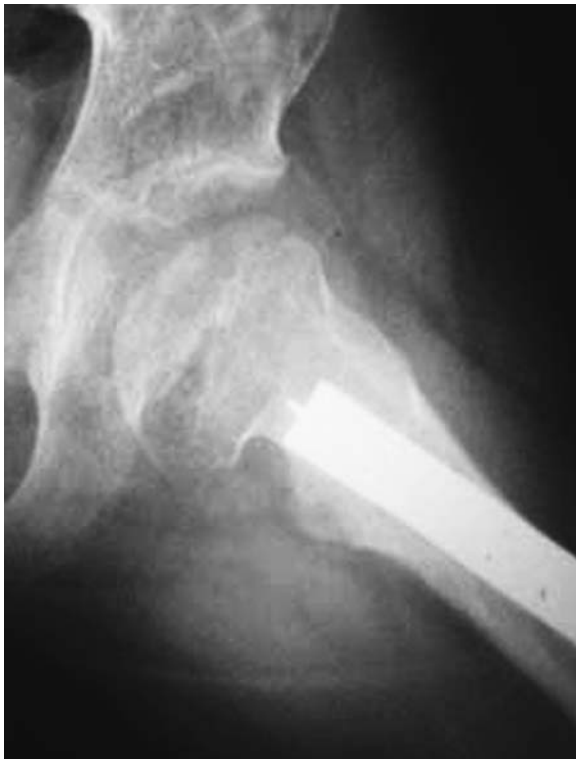

Figure C10.43.2

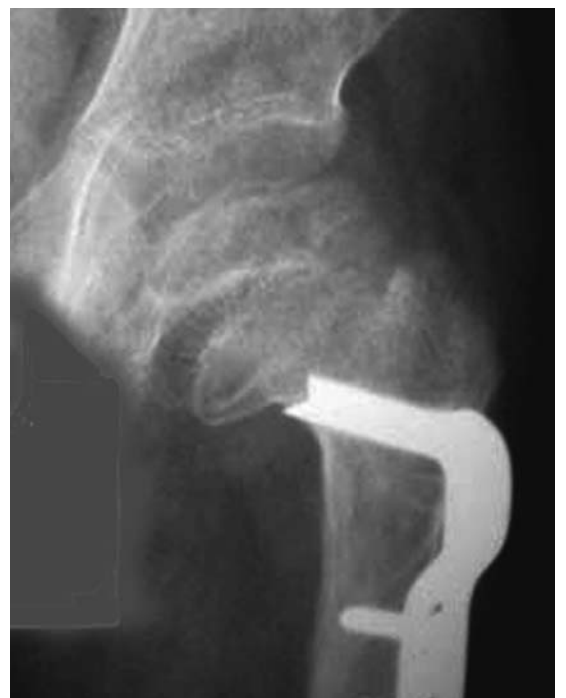

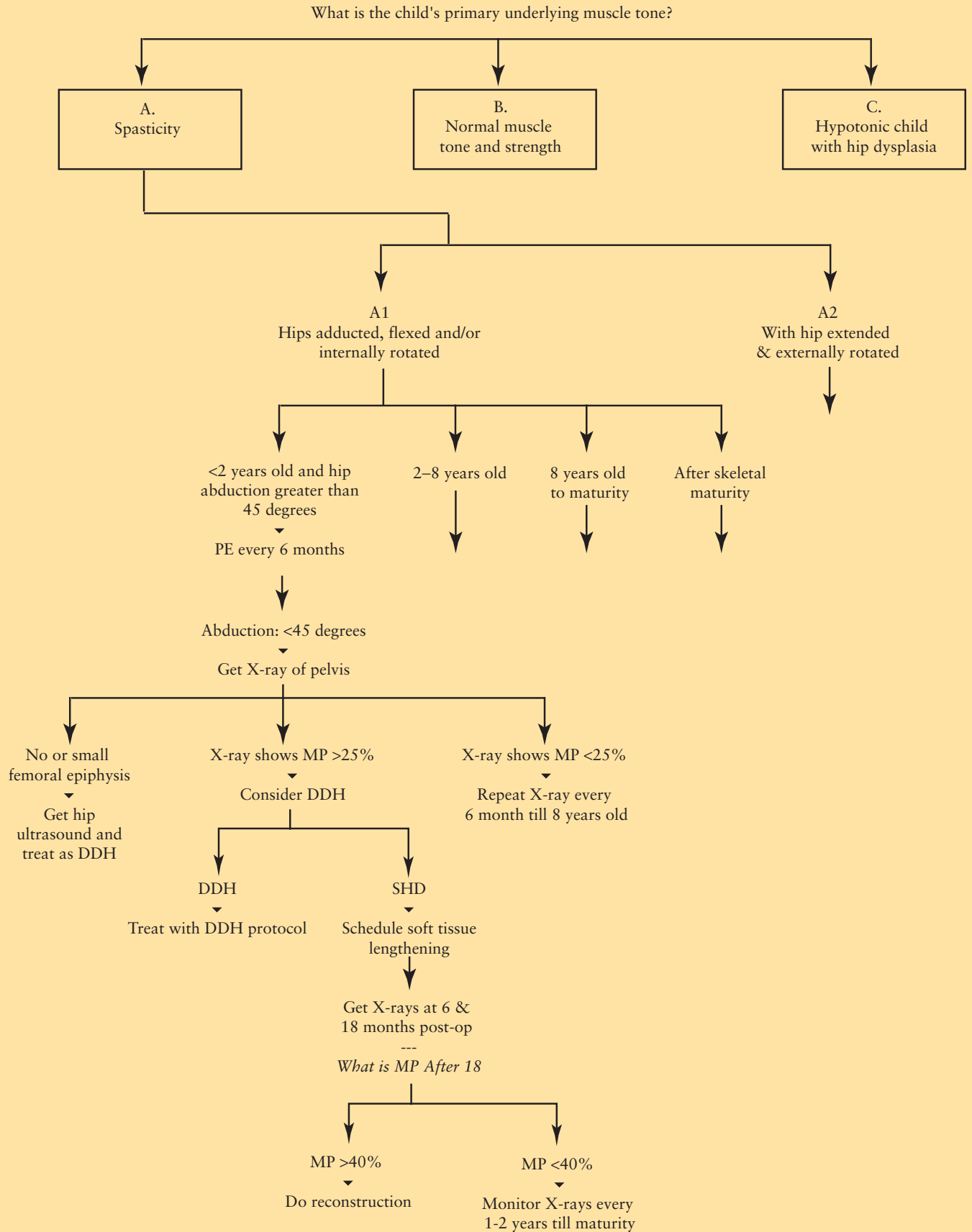
Figure C10.43.3

having deep venous thrombosis based on an ultrasound Doppler flow study. A bone scan should be obtained on any child with swelling in the legs, in whom deep venous thrombosis is believed to be present, to rule out heterotopic ossification before we would consider anticoagulation therapy. The consideration for deep venous thrombosis treatment is contraindicated until heterotopic ossification has been ruled out by a bone scan.

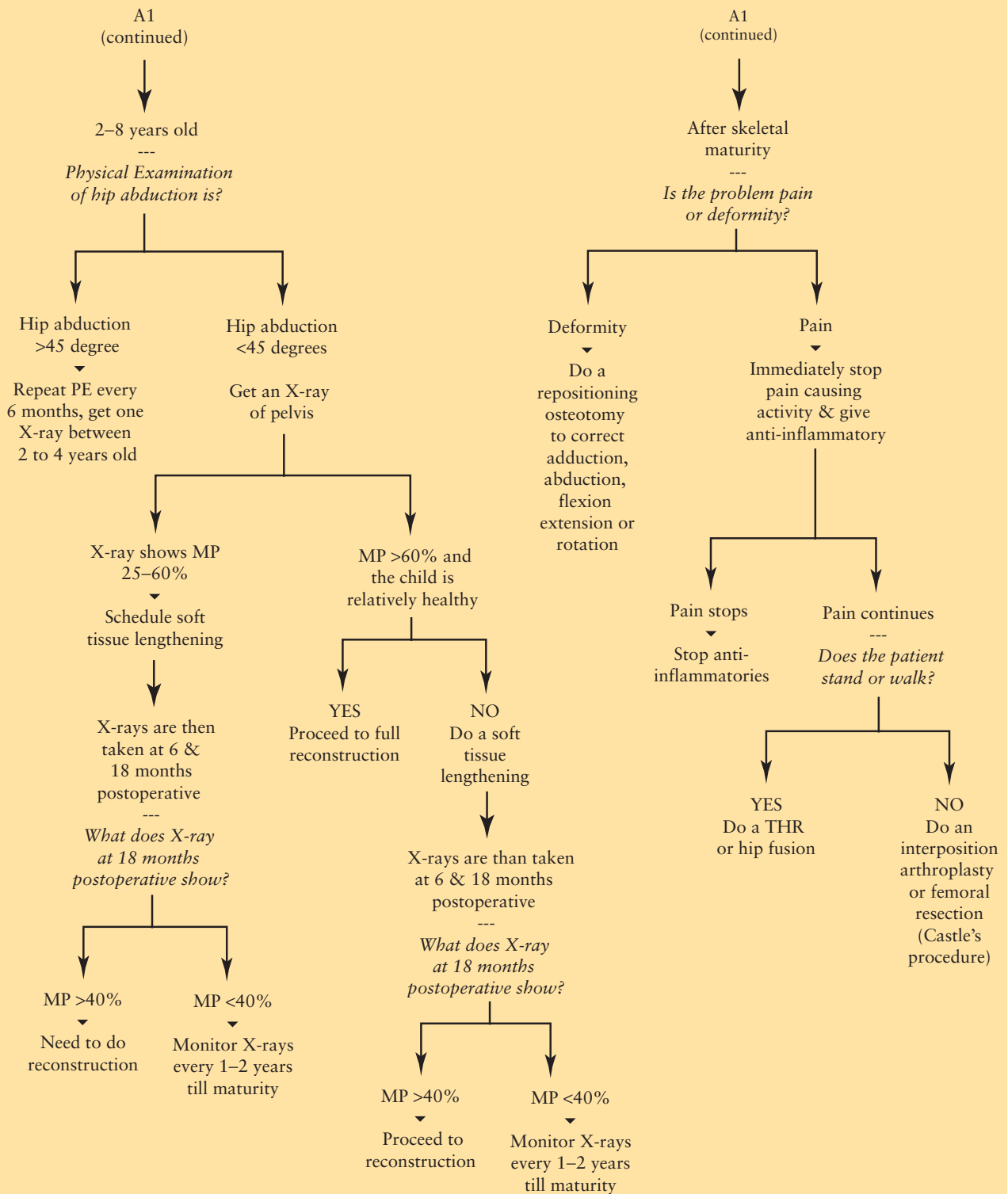
Hip Joint Stiffness

Persistent decreased range of motion after hip reconstruction may be due to heterotopic ossification. Otherwise, this decreased range of motion may also be caused by pain and acute degenerative arthritis that was previously discussed. Children who are placed in prolonged cast immobilization may develop stiffness of the hip that cannot be mobilized. With the elimination of casting, the problem of hip stiffness and limited range of motion almost completely disappears. There are several other procedures, especially the shelf arthroplasty and the Chiari osteotomy, which have a very high risk for developing a severe limitation of hip range of motion. Therefore, these procedures should be avoided as well.

Spastic Hip Disease



Spastic Hip Disease



Spastic Hip Disease

A1
(continued)

8 years old to maturity

What does the hip X-ray show?

MP <40%

Plan to monitor
X-ray every 2 years

MP >40%

Is the degenerative joint
disease severe?

YES

Does the child
have pain?

YES

Does the child
walk or stand?

YES

Do a THR
or hip fusion

NO

Monitor hip
till pain
develops

NO

Do interposition
arthroplasty or
femoral resection
(Castle)

NO

Plan to do a reconstruction now
before arthritis severe

Does the hip have pain after the
reconstruction?

Is the hip still painful 3 months
after reconstruction?

YES

Inject hip with steroids
and continue passive
ROM

Is the pain gone?

YES

Monitor X-rays
1 year post-op

NO

Repeat steroid
injections 2 times

Is the pain gone?

YES

Monitor X-rays
1 year post-op

NO

Child stands or walks?

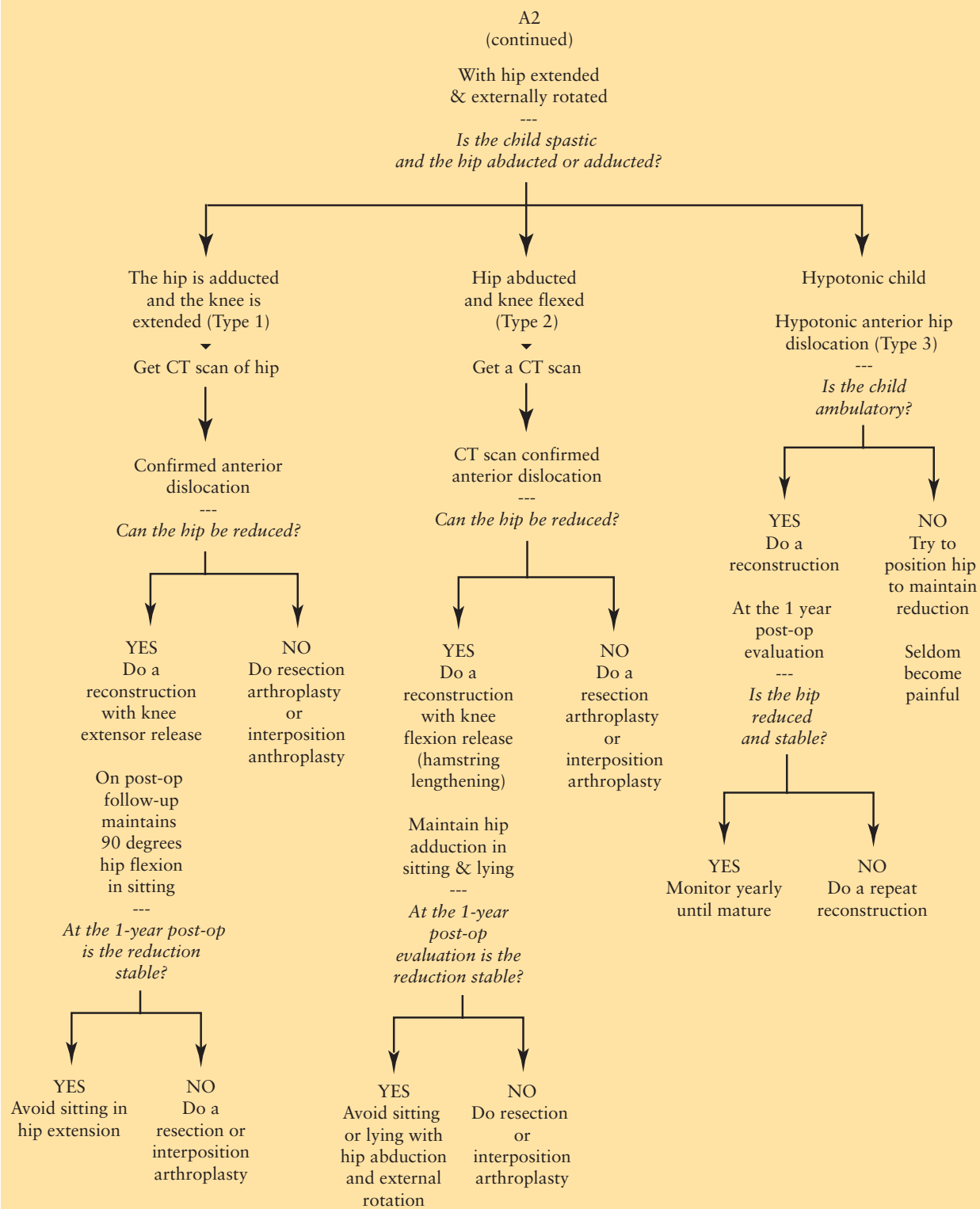
YES

Do THR
or hip fusion

NO

Do resection
or interposition
arthroplasty

Spastic Hip Disease



References

1. Cooke PH, Cole WG, Carey RP. Dislocation of the hip in cerebral palsy. Natural history and predictability. *J Bone Joint Surg [Br]* 1989;71:441–6.
2. de Windt FH, Spoor CW, Huson A, Duijfjes F. A model for the study of hip dysplasia in the spastic child. *Acta Orthop Belg* 1984;50:143–7.
3. Miller F, Slomczykowski M, Cope R, Lipton GE. Computer modeling of the pathomechanics of spastic hip dislocation in children. *J Pediatr Orthop* 1999;19:486–92.
4. Keats S. Early preventive surgery in the modern management of the preschool child. Need a cerebral palsied child be a crippled child? *Int Surg* 1972;57:398–405.
5. Eilert RE, MacEwen GD. Varus derotational osteotomy of the femur in cerebral palsy. *Clin Orthop* 1977:168–72.
6. Fettweis E. Spasm of the adductor muscles, pre-dislocations and dislocations of the hip joints in children and adolescents with cerebral palsy. Clinical observations on aetiology, pathogenesis, therapy and rehabilitation. Part II. The importance of the iliopsoas tendon, its tenotomy, of the coxa valga antetorta, and correction through osteotomy turning the hip into varus (author's transl). *Z Orthop Ihre Grenzgeb* 1979;117:50–9.
7. Fujiwara M, Basmajian JV, Iwamoto M. Hip abnormalities in cerebral palsy: radiological study. *Arch Phys Med Rehabil* 1976;57:278–81.
8. Hoffer MM, Stein GA, Koffman M, Prietto M. Femoral varus-derotation osteotomy in spastic cerebral palsy. *J Bone Joint Surg [Am]* 1985;67:1229–35.
9. Vizkelely T, Renyi-Vamos A, Szoke G. Surgical treatment of the hip in cerebral palsy. *Acta Chir Hung* 1991;32:215–24.
10. Heimkes B, Stotz S, Heid T. Pathogenesis and prevention of spastic hip dislocation. *Z Orthop Ihre Grenzgeb* 1992;130:413–8.
11. Lundy DW, Ganey TM, Ogden JA, Guidera KJ. Pathologic morphology of the dislocated proximal femur in children with cerebral palsy. *J Pediatr Orthop* 1998;18:528–34.
12. Miller F, Cardoso Dias R, Dabney KW, Lipton GE, Triana M. Soft-tissue release for spastic hip subluxation in cerebral palsy. *J Pediatr Orthop* 1997;17:571–84.
13. Miller F, Girardi H, Lipton G, Ponzio R, Klaumann M, Dabney KW. Reconstruction of the dysplastic spastic hip with peri-ilial pelvic and femoral osteotomy followed by immediate mobilization. *J Pediatr Orthop* 1997;17:592–602.
14. Feldkamp M, Denker P. Importance of the iliopsoas muscle in soft-tissue surgery of hip deformities in cerebral palsy children. *Arch Orthop Trauma Surg* 1989;108:225–30.
15. Mubarak SJ, Valencia FG, Wenger DR. One-stage correction of the spastic dislocated hip. Use of pericapsular acetabuloplasty to improve coverage. *J Bone Joint Surg Am* 1992;74:1347–57.
16. Reimers J. The stability of the hip in children. A radiological study of the results of muscle surgery in cerebral palsy. *Acta Orthop Scand Suppl* 1980;184:1–100.
17. Rink P, Miller F. Hip instability in spinal cord injury patients. *J Pediatr Orthop* 1990;10:583–7.
18. Brunner R, Picard C, Robb J. Morphology of the acetabulum in hip dislocations caused by cerebral palsy. *J Pediatr Orthop B* 1997;6:207–11.
19. Kahle WK, Coleman SS. The value of the acetabular teardrop figure in assessing pediatric hip disorders. *J Pediatr Orthop* 1992;12:586–91.
20. Ribble T, Santare M, Miller F. Response of the femoral epiphysis to force: a finite element modeling study. Newark, Delaware: University of Delaware, 1998.
21. Bobroff ED, Chambers HG, Sartoris DJ, Wyatt MP, Sutherland DH. Femoral anteversion and neck-shaft angle in children with cerebral palsy. *Clin Orthop* 1999:194–204.
22. Brunner R, Baumann JU. Long-term effects of intertrochanteric varus-derotation osteotomy on femur and acetabulum in spastic cerebral palsy: an 11- to 18-year follow-up study. *J Pediatr Orthop* 1997;17:585–91.
23. Miller F, Bagg MR. Age and migration percentage as risk factors for progression in spastic hip disease. *Dev Med Child Neurol* 1995;37:449–55.

24. Frischhut B, Krismer M. Pelvic tilt in neuromuscular diseases. *Orthopade* 1990; 19:292–9.
25. Bagg MR, Farber J, Miller F. Long-term follow-up of hip subluxation in cerebral palsy patients. *J Pediatr Orthop* 1993;13:32–6.
26. Hodgkinson I, Vadot JP, Metton G, Berard C, Berard J. Prevalence and morbidity of hip excentration in cerebral palsy: review of the literature. *Rev Chir Orthop Reparatrice Appar Mot* 2000;86:158–61.
27. Silver RL, Rang M, Chan J, de la Garza J. Adductor release in nonambulant children with cerebral palsy. *J Pediatr Orthop* 1985;5:672–7.
28. Brunner R, Robb JE. Inaccuracy of the migration percentage and center-edge angle in predicting femoral head displacement in cerebral palsy [see comments]. *J Pediatr Orthop B* 1996;5:239–41.
29. Buckley SL, Sponseller PD, Magid D. The acetabulum in congenital and neuromuscular hip instability. *J Pediatr Orthop* 1991;11:498–501.
30. Kim HT, Wenger DR. Location of acetabular deficiency and associated hip dislocation in neuromuscular hip dysplasia: three-dimensional computed tomographic analysis. *J Pediatr Orthop* 1997;17:143–51.
31. Zimmermann SE, Sturm PF. Computed tomographic assessment of shelf acetabuloplasty. *J Pediatr Orthop* 1992;12:581–5.
32. Horstmann H, Mahboubi S. The use of computed tomography scan in unstable hip reconstruction. *J Comput Tomogr* 1987;11:364–9.
33. Mahboubi S, Horstmann H. Femoral torsion: CT measurement. *Radiology* 1986; 160:843–4.
34. Miller F, Liang Y, Merlo M, Harcke HT. Measuring anteversion and femoral neck-shaft angle in cerebral palsy. *Dev Med Child Neurol* 1997;39:113–8.
35. Heinrich SD, MacEwen GD, Zembo MM. Hip dysplasia, subluxation, and dislocation in cerebral palsy: an arthrographic analysis. *J Pediatr Orthop* 1991;11: 488–93.
36. Rang M. Cerebral palsy. In: Morrissy R, ed. *Lovell and Winter's Pediatric Orthopedics*, Vol. 1. Philadelphia: Lippincott, 1990:465–506.
37. Cottalorda J, Gautheron V, Metton G, Charmet E, Maatougui K, Chavrier Y. Predicting the outcome of adductor tenotomy. *Int Orthop* 1998;22:374–9.
38. Turker RJ, Lee R. Adductor tenotomies in children with quadriplegic cerebral palsy: longer term follow-up. *J Pediatr Orthop* 2000;20:370–4.
39. Cornell MS, Hatrick NC, Boyd R, Baird G, Spencer JD. The hip in children with cerebral palsy. Predicting the outcome of soft tissue surgery. *Clin Orthop* 1997: 165–71.
40. Keats S. Combined adductor-gracilis tenotomy and selective obturator-nerve resection for the correction of adductor deformity of the hip in children with cerebral palsy. *J Bone Joint Surg [Am]* 1957;19A:1087–90.
41. Spatz DK, Reiger M, Klaumann M, Miller F, Stanton RP, Lipton GE. Measurement of acetabular index intraobserver and interobserver variation. *J Pediatr Orthop* 1997;17:174–5.
42. Nogen AG. Medical treatment for spasticity in children with cerebral palsy. *Childs Brain* 1976;2:304–8.
43. Sharrard WJ, Burke J. Iliopsoas transfer in the management of established dislocation and refractory progressive subluxation of the hip in cerebral palsy. *Int Orthop* 1982;6:149–54.
44. Brunner R, Baumann JU. Clinical benefit of reconstruction of dislocated or subluxated hip joints in patients with spastic cerebral palsy. *J Pediatr Orthop* 1994; 14:290–4.
45. Uematsu A, Bailey HL, Winter WG Jr, Brower TD. Results of posterior iliopsoas transfer for hip instability caused by cerebral palsy. *Clin Orthop* 1977:183–9.
46. Root L, Spero CR. Hip adductor transfer compared with adductor tenotomy in cerebral palsy. *J Bone Joint Surg [Am]* 1981;63:767–72.
47. Reimers J, Poulsen S. Adductor transfer versus tenotomy for stability of the hip in spastic cerebral palsy. *J Pediatr Orthop* 1984;4:52–4.
48. Schultz RS, Chamberlain SE, Stevens PM. Radiographic comparison of adductor procedures in cerebral palsied hips. *J Pediatr Orthop* 1984;4:741–4.

49. Loder RT, Harbuz A, Aronson DD, Lee CL. Postoperative migration of the adductor tendon after posterior adductor transfer in children with cerebral palsy. *Dev Med Child Neurol* 1992;34:49–54.
50. Scott AC, Chambers C, Cain TE. Adductor transfers in cerebral palsy: long-term results studied by gait analysis. *J Pediatr Orthop* 1996;16:741–6.
51. Abbott R. Complications with selective posterior rhizotomy. *Pediatr Neurosurg* 1992;18:43–7.
52. Greene WB, Dietz FR, Goldberg MJ, Gross RH, Miller F, Sussman MD. Rapid progression of hip subluxation in cerebral palsy after selective posterior rhizotomy. *J Pediatr Orthop* 1991;11:494–7.
53. Feldkamp M, Guth V, Buschken S, Klein D. Etiology of hip dislocation in children with cerebral movement disorders and possibilities of conservative treatment using rotating and spreading plates and electrostimulation. *Z Orthop Ihre Grenzgeb* 1985;123:182–8.
54. Letts M, Shapiro L, Mulder K, Klassen O. The windblown hip syndrome in total body cerebral palsy. *J Pediatr Orthop* 1984;4:55–62.
55. Houkom JA, Roach JW, Wenger DR, Speck G, Herring JA, Norris EN. Treatment of acquired hip subluxation in cerebral palsy. *J Pediatr Orthop* 1986;6:285–90.
56. McNerney NP, Mubarak SJ, Wenger DR. One-stage correction of the dysplastic hip in cerebral palsy with the San Diego acetabuloplasty: results and complications in 104 hips. *J Pediatr Orthop* 2000;20:93–103.
57. Herndon WA, Bolano L, Sullivan JA. Hip stabilization in severely involved cerebral palsy patients. *J Pediatr Orthop* 1992;12:68–73.
58. Gordon JE, Capelli AM, Strecker WB, Delgado ED, Schoenecker PL. Pemberton pelvic osteotomy and varus rotational osteotomy in the treatment of acetabular dysplasia in patients who have static encephalopathy. *J Bone Joint Surg Am* 1996;78:1863–71.
59. Shea KG, Coleman SS, Carroll K, Stevens P, Van Boerum DH. Pemberton pericapsular osteotomy to treat a dysplastic hip in cerebral palsy. *J Bone Joint Surg Am* 1997;79:1342–51.
60. Dega W. Osteotomia trans-iliakalna w leczeniu wrodzonej dysplazji. *Chir Narz Ruchu Orthop Pol* 1974;39:601–13.
61. Lyne ED, Katcherian DA. Slotted acetabular augmentation in patients with neuromuscular disorders. *J Pediatr Orthop* 1988;8:278–84.
62. Zuckerman JD, Staheli LT, McLaughlin JF. Acetabular augmentation for progressive hip subluxation in cerebral palsy. *J Pediatr Orthop* 1984;4:436–42.
63. Alonso JE, Lovell WW, Lovejoy JF. The Altdorf hip clamp. *J Pediatr Orthop* 1986;6:399–402.
64. McHale KA. Bilateral spontaneous arthrodesis of the hip after combined shelf acetabular augmentation and femoral varus osteotomies. *J Pediatr Orthop* 1991;11:108–11.
65. Dietz FR, Knutson LM. Chiari pelvic osteotomy in cerebral palsy. *J Pediatr Orthop* 1995;15:372–80.
66. Nishioka E, Momota K, Shiba N, Higuchi F, Inoue A. Joint-preserving operation for osteoarthritis of the hip in adult cerebral palsy. *Aust N Z J Surg* 2000;70:431–7.
67. Osterkamp J, Caillouette JT, Hoffer MM. Chiari osteotomy in cerebral palsy [published erratum appears in *J Pediatr Orthop* 1988;8(5):628]. *J Pediatr Orthop* 1988;8:274–7.
68. Brunner R. Which procedure gives best results in reconstructing dislocated hip joints in cerebral palsy? *Acta Orthop Belg* 1998;64:7–16.
69. Cesari B, Touzet P, Journeau P, Padovani JP, Rigault P, Pouliquen M. Value of pelvic osteotomy in the management of the hip in children with cerebral palsy. *Rev Chir Orthop Reparatrice Appar Mot* 1995;81:310–6.
70. Pope DF, Bueff HU, DeLuca PA. Pelvic osteotomies for subluxation of the hip in cerebral palsy. *J Pediatr Orthop* 1994;14:724–30.
71. Steel HH. Triple osteotomy of the innominate bone. A procedure to accomplish coverage of the dislocated or subluxated femoral head in the older patient. *Clin Orthop* 1977;116–27.

72. Jerosch J, Senst S, Hoffstetter I. Combined realignment procedure (femoral and acetabular) of the hip joint in ambulatory patients with cerebral palsy and secondary hip dislocation. *Acta Orthop Belg* 1995;61:92–9.
73. Buly RL, Huo M, Root L, Binzer T, Wilson PD Jr. Total hip arthroplasty in cerebral palsy. Long-term follow-up results. *Clin Orthop* 1993;148–53.
74. Skoff HD, Keggi K. Total hip replacement in the neuromuscularly impaired. *Orthop Rev* 1986;15:154–9.
75. Root L, Goss JR, Mendes J. The treatment of the painful hip in cerebral palsy by total hip replacement or hip arthrodesis. *J Bone Joint Surg [Am]* 1986;68:590–8.
76. Waters RL, Mulroy S. The energy expenditure of normal and pathologic gait. *Gait Posture* 1999;9:207–31.
77. Weber M, Cabanela ME. Total hip arthroplasty in patients with cerebral palsy. *Orthopedics* 1999;22:425–7.
78. Gabos PG, Miller F, Galban MA, Gupta GG, Dabney K. Prosthetic interposition arthroplasty for the palliative treatment of end-stage spastic hip disease in non-ambulatory patients with cerebral palsy. *J Pediatr Orthop* 1999;19:796–804.
79. Baxter MP, D'Astous JL. Proximal femoral resection-interposition arthroplasty: salvage hip surgery for the severely disabled child with cerebral palsy. *J Pediatr Orthop* 1986;6:681–5.
80. Castle ME, Schneider C. Proximal femoral resection-interposition arthroplasty. *J Bone Joint Surg [Am]* 1978;60:1051–4.
81. Widmann RF, Do TT, Doyle SM, Burke SW, Root L. Resection arthroplasty of the hip for patients with cerebral palsy: an outcome study. *J Pediatr Orthop* 1999;19:805–10.
82. McCarthy RE, Simon S, Douglas B, Zawacki R, Reese N. Proximal femoral resection to allow adults who have severe cerebral palsy to sit. *J Bone Joint Surg [Am]* 1988;70:1011–6.
83. McHale KA, Bagg M, Nason SS. Treatment of the chronically dislocated hip in adolescents with cerebral palsy with femoral head resection and subtrochanteric valgus osteotomy. *J Pediatr Orthop* 1990;10:504–9.
84. Perlmutter MN, Synder M, Miller F, Bisbal R. Proximal femoral resection for older children with spastic hip disease. *Dev Med Child Neurol* 1993;35:525–31.
85. Selva G, Miller F, Dabney KW. Anterior hip dislocation in children with cerebral palsy. *J Pediatr Orthop* 1998;18:54–61.
86. Samilson RL, Tsou P, Aamoth G, Green WM. Dislocation and subluxation of the hip in cerebral palsy. Pathogenesis, natural history and management. *J Bone Joint Surg [Am]* 1972;54:863–73.
87. Bowen JR, MacEwen GD, Mathews PA. Treatment of extension contracture of the hip in cerebral palsy. *Dev Med Child Neurol* 1981;23:23–9.
88. Szalay EA, Roach JW, Houkom JA, Wenger DR, Herring JA. Extension-abduction contracture of the spastic hip. *J Pediatr Orthop* 1986;6:1–6.
89. Bartlett MD, Wolf LS, Shurtleff DB, Stahell LT. Hip flexion contractures: a comparison of measurement methods. *Arch Phys Med Rehabil* 1985;66:620–5.
90. Nwaobi OM, Sussman MD. Electromyographic and force patterns of cerebral palsy patients with windblown hip deformity. *J Pediatr Orthop* 1990;10:382–8.
91. Abel MF, Blanco JS, Pavlovich L, Damiano DL. Asymmetric hip deformity and subluxation in cerebral palsy: an analysis of surgical treatment. *J Pediatr Orthop* 1999;19:479–85.
92. Carr C, Gage JR. The fate of the nonoperated hip in cerebral palsy. *J Pediatr Orthop* 1987;7:262–7.
93. Feldkamp M. Asymmetric posture of the hip-joints in cerebral palsy (author's transl). *Z Orthop Ihre Grenzgeb* 1976;114:317–23.
94. Kolban M. Variability of the femoral head and neck antetorsion angle in ultrasonographic measurements of healthy children and in selected diseases with hip disorders treated surgically. *Ann Acad Med Stetin* 1999;Suppl:1–99.
95. Laplaza FJ, Root L. Femoral anteversion and neck-shaft angles in hip instability in cerebral palsy. *J Pediatr Orthop* 1994;14:719–23.
96. Laplaza FJ, Root L, Tassanawipas A, Glasser DB. Femoral torsion and neck-shaft angles in cerebral palsy. *J Pediatr Orthop* 1993;13:192–9.

97. Yamaguchi O. A radiological study of the hip joint in cerebral palsy. *Nippon Seikeigeka Gakkai Zasshi* 1993;67:1–11.
98. Dunlap K, Shands A, Hollister L, Gaul J, Streit H. A new method for determination of torsion of the femur. *J Bone Joint Surg [Am]* 1953;53A:289–311.
99. Haspl M, Bilic R. Assessment of femoral neck-shaft and antetorsion angles. *Int Orthop* 1996;20:363–6.
100. LaGasse DJ, Staheli LT. The measurement of femoral anteversion. A comparison of the fluoroscopic and biplane roentgenographic methods of measurement. *Clin Orthop* 1972;86:13–5.
101. Elke R, Ebnetter A, Dick W, Fliegel C, Morscher E. Ultrasound measurement of femur neck anteversion. *Z Orthop Ihre Grenzgeb* 1991;129:156–63.
102. Tomczak RJ, Guenther KP, Rieber A, Mergo P, Ros PR, Brambs HJ. MR imaging measurement of the femoral antetorsional angle as a new technique: comparison with CT in children and adults. *AJR Am J Roentgenol* 1997;168:791–4.
103. Delp SL, Hess WE, Hungerford DS, Jones LC. Variation of rotation moment arms with hip flexion. *J Biomech* 1999;32:493–501.
104. Schmidt DJ, Arnold AS, Carroll NC, Delp SL. Length changes of the hamstrings and adductors resulting from derotational osteotomies of the femur. *J Orthop Res* 1999;17:279–85.
105. Davids JR, Foti T, Dabelstein J, Bagley A. Voluntary (normal) versus obligatory (cerebral palsy) toe-walking in children: a kinematic, kinetic, and electromyographic analysis. *J Pediatr Orthop* 1999;19:461–9.
106. Staheli LT. Torsion: treatment indications. *Clin Orthop* 1989:61–6.
107. Joseph B. Treatment of internal rotation gait due to gluteus medius and minimus overactivity in cerebral palsy: anatomical rationale of a new surgical procedure and preliminary results in twelve hips. *Clin Anat* 1998;11:22–8.
108. Steel HH. Gluteus medius and minimus insertion advancement for correction of internal rotation gait in spastic cerebral palsy. *J Bone Joint Surg [Am]* 1980;62:919–27.
109. Beauchesne R, Miller F, Moseley C. Proximal femoral osteotomy using the AO fixed-angle blade plate [see comments]. *J Pediatr Orthop* 1992;12:735–40.
110. Krum SD, Miller F. Heterotopic ossification after hip and spine surgery in children with cerebral palsy. *J Pediatr Orthop* 1993;13:739–43.
111. Payne LZ, DeLuca PA. Heterotopic ossification after rhizotomy and femoral osteotomy. *J Pediatr Orthop* 1993;13:733–8.
112. Lee M, Alexander MA, Miller F, Steg NL, McHugh BA. Postoperative heterotopic ossification in the child with cerebral palsy: three case reports. *Arch Phys Med Rehabil* 1992;73:289–92.
113. Nakajo M, Endo H. Heterotopic ossification with hemiplegia caused by cerebral apoplexy. *Seikei Geka* 1969;20:1193–201.
114. Ushmann H, Bennett JT. Spontaneous ankylosis of the contralateral hip after unilateral adductor tenotomy in cerebral palsy. *J Pediatr Orthop B* 1999;8:42–4.
115. Banovac K. The effect of etidronate on late development of heterotopic ossification after spinal cord injury. *J Spinal Cord Med* 2000;23:40–4.
116. Thomas BJ, Amstutz HC. Prevention of heterotopic bone formation: clinical experience with diphosphonates. *Hip* 1987:59–69.
117. Freed JH, Hahn H, Menter R, Dillon T. The use of the three-phase bone scan in the early diagnosis of heterotopic ossification (HO) and in the evaluation of Didronel therapy. *Paraplegia* 1982;20:208–16.
118. Seegenschmiedt MH, Goldmann AR, Wolfel R, Hohmann D, Beck H, Sauer R. Prevention of heterotopic ossification (HO) after total hip replacement: randomized high versus low dose radiotherapy [see comments]. *Radiother Oncol* 1993;26:271–4.
119. Root L, Laplaza FJ, Brouman SN, Angel DH. The severely unstable hip in cerebral palsy. Treatment with open reduction, pelvic osteotomy, and femoral osteotomy with shortening. *J Bone Joint Surg Am* 1995;77:703–12.

Knee, Leg, and Foot

Although the knee is the largest joint in the lower extremity, it creates fewer problems in children with cerebral palsy (CP) than the hip, foot, or ankle. It is not clear exactly why the knee joint is relatively immune to the pathomechanics that affect the hip and foot; however, because the muscles primarily control motion in a single plane, there is less opportunity to create severely maldirected force vectors. Most of the stability of the knee is due to its inherent ligamentous stability, the strength of which is usually able to overcome the weak abnormal muscle forces in varus, valgus, or torsional malalignment planes. The high stress on the extensor side of the joint may lead to patella alta and stress reactions in the patella. Stiff knee and crouch gait patterns are most defined by the position of the knee; however, most of the etiology of these problems emanates from the foot.

Ankle equinus was the first CP deformity that received significant attention. In Germany in the early 1800s, Louis Stromeyer developed the Achilles tenotomy. An English physician, William John Little, who himself had hemiplegic pattern CP, had Dr. Stromeyer do an Achilles tenotomy for him.¹ He was so impressed with the result that he became a great proponent of tenotomy for CP. He also studied the causes of CP and wrote so extensively that even today in England CP is still referred to as Little's disease. By the early 1900s, Achilles tenotomy was well established and attention was directed at the varus component, which sometimes accompanies the equinus. A whole series of tenotomies, lengthenings, and tendon transfers were devised for the tibialis anterior and posterior. By the mid-1900s, many operations were developed for polio patients, such as subtalar fusions, triple arthrodesis, and multiple foot osteotomies. These operations were applied to the spastic feet of children with CP as well.

The role of the foot in gait function was much better defined in the 1980s, changing the focus from isolated foot deformities to a more global evaluation of the lower extremity. Because of the history focused on correcting clearly recognizable problems, there is almost no literature or data available to discern the natural history of various foot deformities. Almost all procedures devised to correct foot deformities have some positive results based on review of the literature. Poor results are reported only on rare occasions. This tendency to prefer reporting good results over bad combined with no defined natural history against which to compare published results makes an objective assessment of many reported foot procedures difficult. In spite of this problem, a better understanding of the role of the foot in gait has led to current recommendations that are based in part on the reported literature and in part on theory still needing clinical validation. The problems of the

foot and ankle include tibial torsion, ankle valgus, and subtalar varus and valgus deformities, as well as forefoot and toe deformities.

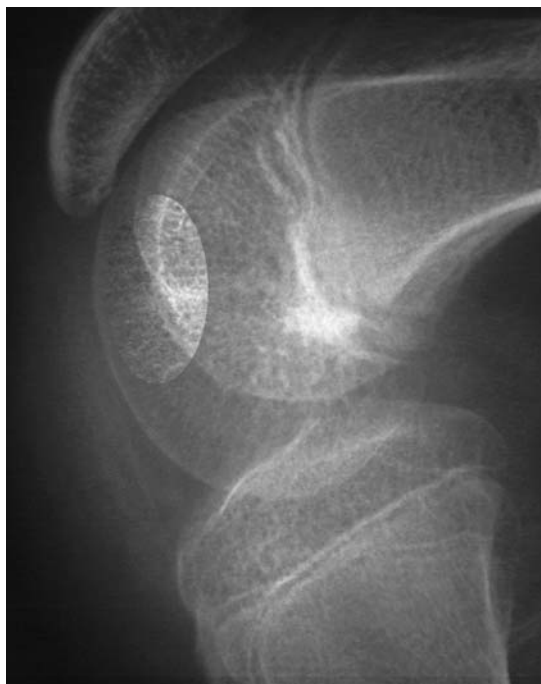
Knee Flexion Contracture

By far the most common problem occurring in the knee is contracture of the hamstring muscles, which, if left untreated, leads to fixed knee flexion contracture. The fixed knee flexion contracture can become severe, with deformity of the femoral condyles (Figure 11.1). These contractures can occur in children with all types of CP, and usually occur during the most rapid growth period.

Etiology

The cause of hamstring contracture is directly related to spasticity and relative decreased growth rate of the length of the muscle fibers. Knee flexion is the only major joint in the lower extremity that has only one relatively small single joint muscle. Most of the function is by multiple joint hamstring muscles. The short head of the biceps is small in comparison to other hamstring muscles. This muscle is also active predominantly in early swing phase to assist knee flexion if it is needed.² The popliteal muscle is too small to have significant mechanical impact on knee flexion. There are six multiple joint muscles that are major flexors of the knee. In CP with decreased motor control, managing these complex motor units is difficult. The sartorius, which assists hip flexion and knee flexion in swing phase, seldom develops pathologic contracture causing impairment. The reason for this is unclear, but the antagonist of the sartorius probably overpower the sartorius and does not allow a contracture to develop. The gracilis, which is active primarily in swing phase,² is more often identified as a hip adductor causing limited hip abduction because a contracture limits hip abduction more than knee flex-

Figure 11.1. This 13-year-old girl has a fixed knee flexion contracture of 35°. The lateral knee radiograph shows flattening and some indentation of the lateral femoral condyle. These changes in the femur suggest that correction of the knee joint contracture will be difficult with a capsular release because there is a tendency for the joint to hinge at the point of this flattened area. If correction of the knee contracture is indicated, correction with a distal femoral extension osteotomy is a better choice.



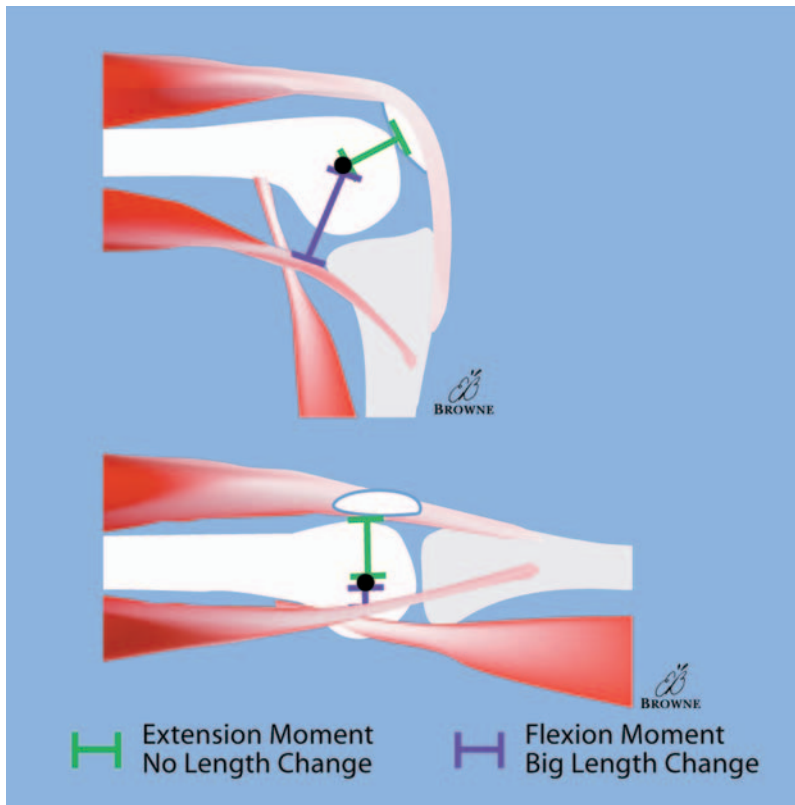
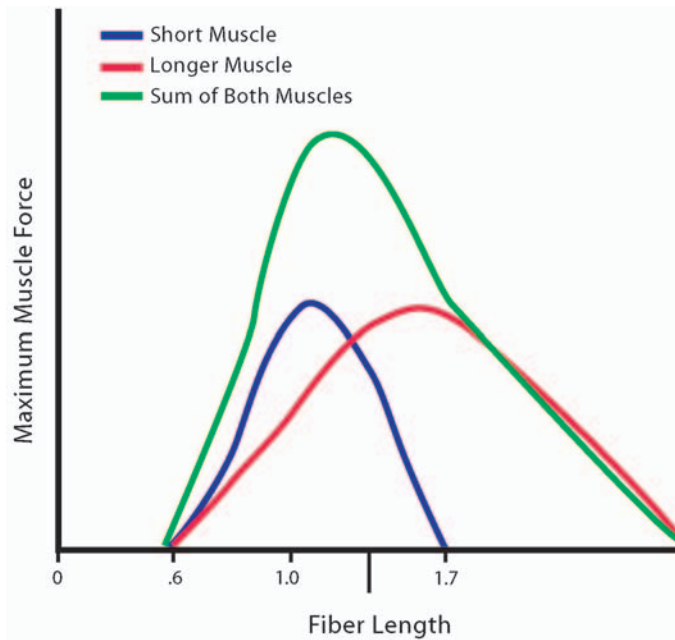


Figure 11.2. The position of the knee joint is a strong indicator of the moment arm advantage of the knee flexors. The hamstrings and the gastrocnemius both have substantial increase in the moment arm advantage as flexion increases. The knee extensors have very little change in the moment arm length with change in the joint position.

ion. The gracilis is mainly a hip adductor because the adductor moment arm of the gracilis is much longer at the hip than the knee flexion moment arm at the knee. The gastrocnemius is a secondary cause of knee flexion contracture, usually in the presence of a severe contracture of the knee with significant ankle equinus. Because the moment arm at the ankle is much longer than the moment arm at the knee, equinus tends to develop primarily. However, as the knee develops increased flexion, the knee flexion moment arm of the gastrocnemius increases, and as a consequence, the gastrocnemius becomes a more important contributor to increasing knee flexion deformity.

The semitendinosus, semimembranosus, and long head of the biceps femoris, all of which are also hip extensors, are the three major knee flexors. For practical purposes of treating children, all three of these muscles normally activate in mid- and terminal swing to decelerate knee flexion. These muscles remain active on into weight acceptance to stabilize the knee and assist in hip extension. Depending on the hip and knee joint position, these muscles go from eccentric contraction, to isometric contraction, to concentric contraction all in the same activation cycle. The moment arm length also varies greatly with specific hip and knee joint position, with the knee making the most dramatic changes (Figure 11.2). This joint is the only place in the body where two clearly different muscles have almost the same origin and insertion. The semitendinosus and semimembranosus have different fiber lengths, with the semitendinosus having a shorter fiber length and a proximally based muscle belly with a distal tendon, whereas the semimembranosus is a distally based muscle with a proximal tendon and longer muscle fibers. The configuration of these two muscles, which activate at the same time, allows the motor control system to use a wider length–tension curve. This length–tension curve has a longer and broader range when the

Figure 11.3. The hamstring muscles have different fiber lengths with almost the same insertion sites. These significantly variable fiber lengths cause a summation of the length-tension response so the active area tends to be wider with a wider strength response region.



two muscles are added together (Figure 11.3). The long head of the biceps, whose muscle fibers are the longest, is added to these two muscles and an even broader length–tension curve is available for muscle function. This broader length–tension curve is an elegant solution to provide high muscle force over a long range of combined hip and knee flexion. However, this biologic solution requires very complex control that often is not available in children with CP. As seen before, a strong chaotic attractor in the face of decreased motor control increases system stiffness through spasticity and shortens the joint range of motion over which there is active control. This scenario occurs equally in the semitendinosus, semimembranosus, and long head of the biceps; however, because the semitendinosus starts with shorter fiber lengths, it is always the most contracted muscle, followed by the semimembranosus, and then the biceps. In general, a release of the semitendinosus will give about 10° to 15° of increased popliteal angle, whereas the semimembranosus will give another 10° to 15° until the end of the biceps contracture is encountered. Another function of the hamstring muscles is to assist with torsional control of the knee joint. If the biceps is left as the predominant muscle force, it tends to cause a mild external rotation moment through the knee joint. This moment is primarily important if the knee is already experiencing a significant external torsion moment because of significant external foot progression angle.

Secondary Pathology

As the hamstring muscles develop contractures that prevent the knee from getting into full extension, a fixed flexion contracture of the knee starts to develop. This fixed flexion contracture primarily involves a contracture of the posterior knee capsule, as the capsule never gets fully stretched out. This lack of stretching occurs because children always lie in bed or sit in a chair with the knees flexed and stand in a knee-flexed position. These knee flexion contractures may start to develop as early as 5 to 7 years of age and become progressively worse in middle childhood. During early and middle childhood, these contractures are very supple, and with appropriate treatment of the

hamstring contracture, the knee flexion contracture can be stretched out easily. However, as children enter adolescence, this contracture gets worse, usually going to 15°. During adolescence, the knee flexion contracture develops into a very solid endpoint, and it is at this time when physical stretching has a limited ability to impact upon this fixed contracture.

Tertiary Changes

If the knee flexion contracture becomes progressively more severe, to where it is more than 30°, secondary changes can develop in the knee joint with flattening of the femoral condyles. These changes in the contour of the femoral condyles will often cause the tibia to start to hinge against the condyles rather than rotating around the arc of the condyles. This hinging may cause additional deformity by causing indentations into the femoral condyles (Case 11.1).

Natural History

Although there are no formal studies of the natural history of knee flexion contractures, the syndrome is common and presumably well understood. Usually, the hamstring contractures develop in early childhood, presenting in sitting children as the inability to sit for long periods. These children may be excellent W-sitters, which inactivates the tight hamstrings. If children walk, they are usually toe walkers with relatively extended knees in the prancing gait pattern. In middle childhood, knee flexion contractures usually develop if children are left untreated. In middle childhood, sitting often becomes more difficult except when the knees are flexed to 90° or more. The gait pattern of children with hamstring contractures in middle childhood often starts to develop more knee flexion, but still includes walking on the toes, often with ankle equinus. During the adolescent growth spurt, the knees will drop into more flexion in midstance as the feet collapse and the full crouched gait pattern is developed. During this time, the fixed knee flexion contracture often gets worse. The knee flexion contracture tends to be worse in children who do no standing and spend all day sitting in a wheelchair. These individuals will usually go on to develop tertiary changes of knee flexion contracture. Ambulatory individuals with hamstring contractures and decreased motor control who are untreated often have a very strong chaotic attractor to the crouched gait pattern.

Diagnostic Evaluations

The primary diagnostic evaluation for monitoring knee flexion is the popliteal angle used to measure hamstring contracture (Figure 11.4). Although this test is somewhat subjective with the spastic hamstring, major changes in muscle length can be easily monitored. Consistent measurement with the hip at 90° of flexion, and avoiding any force that causes pelvic rotation, will provide a relatively consistent measure. Normal popliteal angles increase with age but should be less than 45° to 50° at all ages.³ It is not uncommon for children with contracted hamstrings to have popliteal angles of 90°. The difference of 15° to 20° is considered to represent a real difference between different examinations. Fixed knee flexion contracture can be measured with much greater accuracy, definitely within 5° with the goniometer. All normal children should have no flexion contracture; however, contractions of 10° or less are not mechanically very significant. However, these small contractures can help drive the system toward the crouched posture as growth continues



Case 11.1 Renada

Renada, a 15-year-old girl with severe spastic diplegia, complained that she could not stand upright to assist with transfers as she used to be able to do. She was in a regular high school and had an aide, but toileting was difficult if she could not stand upright. On physical examination, the popliteal angles were 90° bilateral and the fixed knee flexion contracture was 45° (Figure C11.1.1). Radiographs

already showed some tertiary changes, which were flattening of the femoral condyles or the shape of the condyles changed from round to elliptical. Posterior subluxation of the lateral tibial plateau is also evident (Figure C11.1.2). This type of fixed knee flexion contracture is not amenable to correction by soft-tissue surgery.

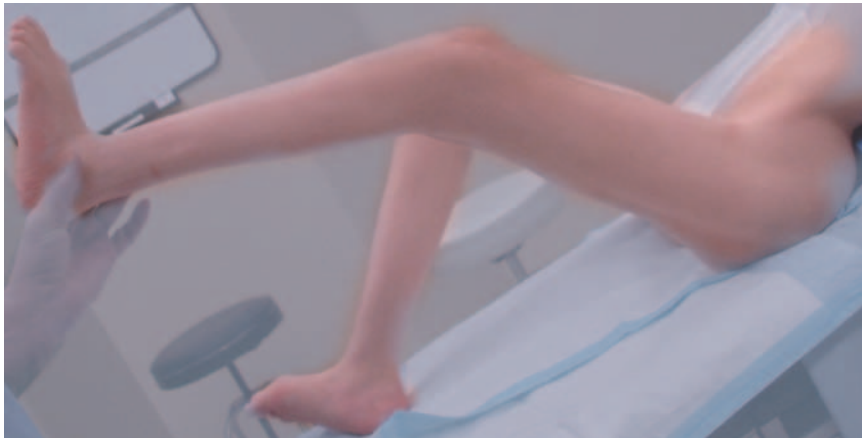

Figure C11.1.1

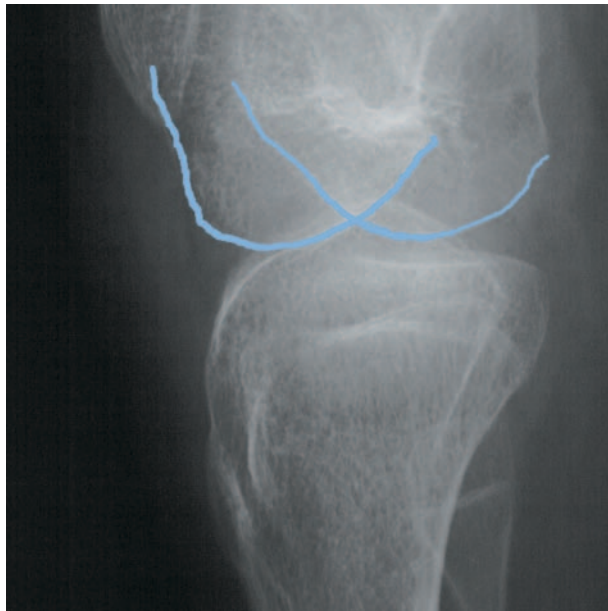

Figure C11.1.2

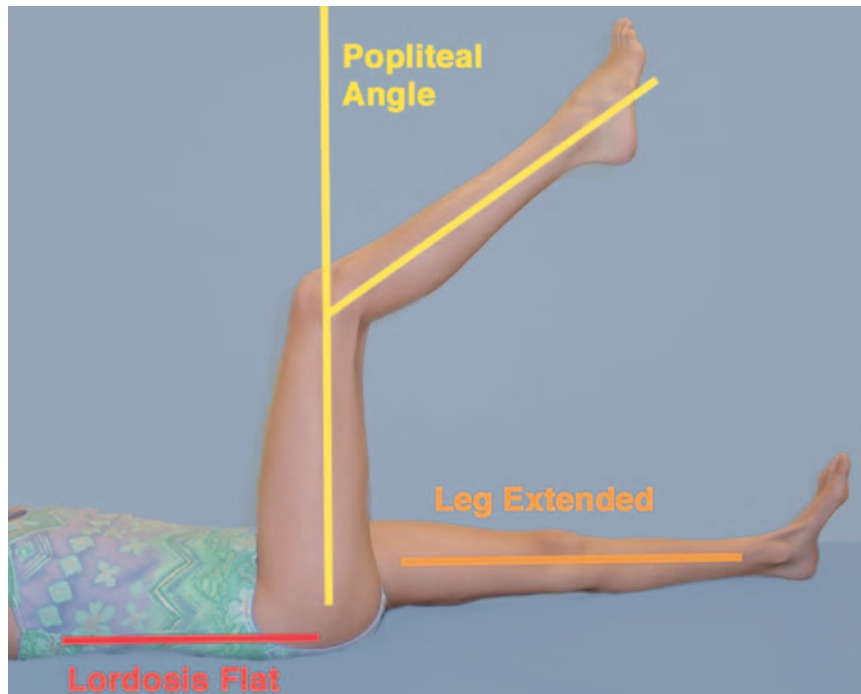


Figure 11.4. The physical examination assessment of the hamstring length is best measured with the popliteal angle measure. The hip needs to be held at 90° flexion and the knee is then extended until the pelvis starts to move. The angle subtended by the tibia to a vertical line defines the popliteal angle. The contralateral hip should always remain fully extended. The goal in this test is not to see how much the hamstring can be stretched but to measure the point where the muscle reaches its end of passive extension with minimal force.

to cause more hamstring shortening. These contractures have to be monitored very closely.

The use of muscle modeling from kinematic data has been reported.^{4–7} These models have demonstrated that many children with a crouched gait pattern have origin-to-insertion lengths that are in the normal range. These models are very limited, as they can provide no information about the position on the length–tension curve relative to the influence of muscle fiber shortness or variable moment arm lengths. These data are interesting but cannot add much useful clinical data in individual children. If this simplistic modeling could be expanded to include force and moment arm data, then they might be useful to decide which muscle needs to be lengthened. The problem is that inputs that include individual muscle force and fiber length needed to make these calculations are not available. The best data to decide treatment options come from the physical examination and the kinematic and electromyographic (EMG) data. At this time, it is impossible to understand the precise reason for hamstring contracture in deciding how much length is needed. Therefore, the effects of the treatments need to be conceptualized as the major goal of treatment being a perturbation to move the function away from the strong flexion attractor, which is driving the knee into more flexion and an increased crouched gait posture.

Hamstring Contractures: Treatment

Indications

The physical effects of hamstring contractures vary widely, with some children having relatively severe hamstring contractures as measured by the popliteal angle, but almost no recognized negative functional impact. Children with CP who are taught to do passive muscle stretching should usually spend some time stretching the hamstrings. How useful this stretching is remains unknown; however, not stretching leads to faster contracture development.

Figure 11.5. Velcro closure knee immobilizers are most useful for stretching the hamstrings after lengthening. If there is a goal of stretching the gastrocnemius with casts, the knees must be immobilized in extension as well with the use of knee immobilizers.



The use of night splints has been found to be helpful for decreasing hamstring contractures, even if they are used on only one limb.⁸ We have used night splints, and have also found that they work when families can use the soft Velcro-enclosed splints; however, fewer than 25% of our patients have been able to maintain a program of 12 weeks or longer. The use of these splints adds another stress to families and children that is not well tolerated (Figure 11.5). We still try, and those children who need the splinting least because they have the smallest contracture seem to tolerate it best. This finding is typical of splinting for contractures, but the answer may be to start earlier and stay with it longer, using only nighttime knee extension splinting. Here again, family compliance is a major problem as this simple device becomes a major annoyance. There have been several reports of using Botox combined with splinting.^{7, 9} Neither of these studies followed the children for any period of time past the acute phase, but both reported subjective improvements at best. Our experience is that hamstring injections with botulinum toxin provide temporary benefit in very young children, but have no real role in older children with significant fixed contractures.

The indications for surgical lengthening of hamstrings have to be evaluated in conjunction with other problems, not only increased popliteal angle (Table 11.1). For young children with hip subluxation and a popliteal angle greater than 45°, hamstring lengthening should be added to the adductor lengthening. For children in middle childhood who are having significant problems sitting because of tight hamstrings, lengthening is indicated (Case 11.2). Knee flexion contractures that are over 10°, especially if progression has been documented, require hamstring lengthening. For ambulatory children in whom surgical reconstruction is planned, initial contact knee flexion of more than 20° or greater than 20° midstance knee flexion in the presence of a popliteal angle of greater than 45° indicates the need for hamstring

Table 11.1. Indications for hamstring lengthening.

1. As part of muscle-lengthening procedure for young children when the popliteal angle is greater than 50° under anesthesia
2. Progressive fixed knee flexion contracture greater than 5° to 10°
3. Difficulty seating, pulling forward out of the wheelchair because of spastic or contracted hamstrings
4. Severe whole spine kyphosis in sitting that resolves when the hamstrings are inactivated
5. Increased knee flexion at foot contact; normal should be less than 20°
6. Increased knee flexion in midstance (more than 20°) with popliteal angle greater than 50°



Case 11.2 Bariya

Bariya, a 7-year-old girl with moderate spastic quadriplegia, presented with her mother who complained that she could only W-sit on the floor and she had developed skin breakdown in the middle of her back from sitting in her wheelchair and her school chair (Figure C11.2.1). Her mother also worried that she was hunched over, which was only apparent while she sat upright (Figure C11.2.2). On physical examination her spine was very flexible (Fig-

ure C11.2.3); however, her popliteal angles were 90° bilaterally, her hip abduction was 35° , and she had full hip flexion and extension. She had no knee flexion contracture. It was recommended to her mother that she have a distal hamstring lengthening that would allow her to long-sit on the floor. After this surgery, she no longer had problems with skin breakdown when she was sitting, and her mother felt she sat more upright.

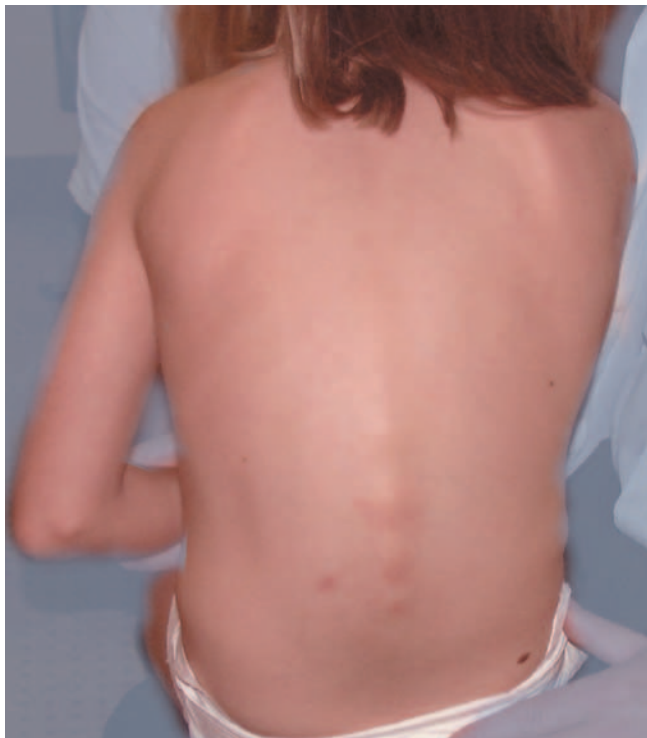

Figure C11.2.1

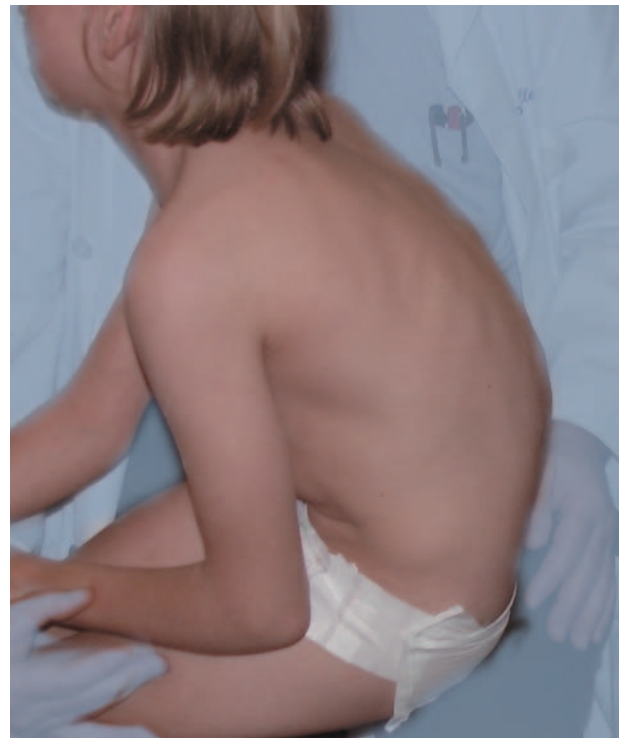


Figure C11.2.2

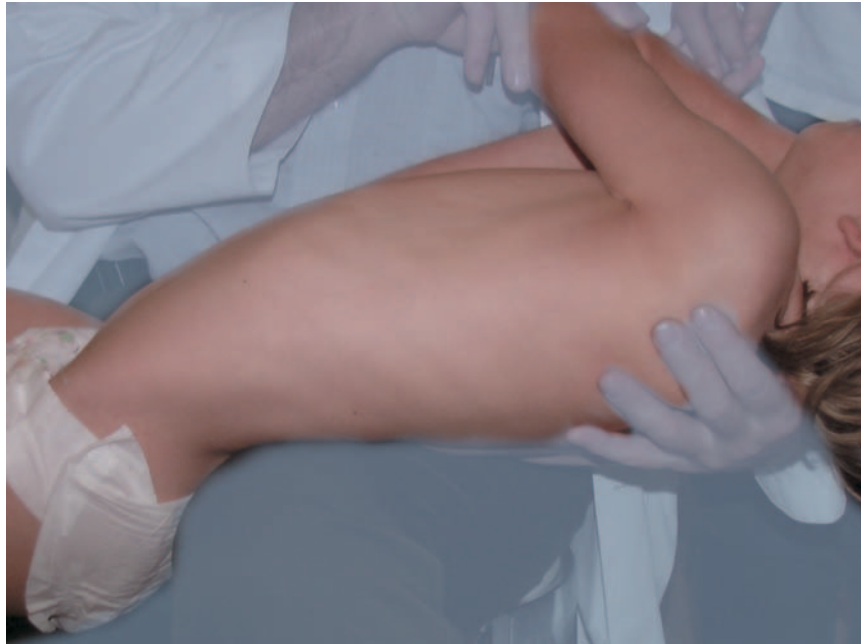

Figure C11.2.3

lengthening. Also, there will be almost constant hamstring activity through stance phase on the EMG with a contracted hamstring on physical examination in a few children. This constant EMG activity, or EMG activity that has a significant premature activation in initial swing, also indicates the need for hamstring lengthening.

Specific Treatments

As already noted, nighttime splinting occasionally combined with Botox injections may provide improved muscle length in a few moderate hamstring contractures. Nighttime splinting will not be of any significant use in severe contractures. Surgical lengthening is the primary treatment for addressing severe, functionally impairing hamstring contractures. The most common surgical approach is to do distal lengthening with a tenotomy of the semitendinosus, and a myofascial lengthening of the semimembranosus and the biceps. It is very important not to overlengthen, because this can cause the hamstring to become incompetent, often leading to poor control of knee extension in swing phase and to back-kneeing in stance phase, as well as having decreased hip extension force at initial contact. When doing the lengthening, the maximum length should be only to a popliteal angle of 30° . Do not try to get a zero popliteal angle in the operating room. If the popliteal angle is 30° to 40° in ambulatory children who have an internal or neutral foot progression angle, the biceps should not be lengthened. This popliteal angle will allow the biceps to maintain power at the knee and hip during the rehabilitation phase; however, if the foot progression angle is greater than 20° externally, the biceps should be lengthened as well. Therefore, the biceps will not be an unopposed external rotator of the knee in a situation where there is already an increased external rotation moment through the knee joint. Postoperative management usually consists of using knee extension splinting for 8 to 12 hours per day. The day after surgery, a physical therapist starts passive range of motion of the knee joint, and moves to strengthening

as soon as the tendons have formed fibrous healing and the postoperative pain resolves, typically at approximately 6 weeks postoperatively.

Proximal hamstring lengthening may also be considered. This lengthening is useful especially for young children who are having hip adductor lengthening for spastic hip disease. Here, the hamstring lengthening can be done through the same incision, and is very easy in smaller children. As children get to late childhood, their increased size makes this approach more difficult. Also, we have seen severe heterotopic ossification in one preadolescent with proximal hamstring lengthening. Postoperative management is the same, with immediate range of motion and the use of extension splinting for 8 to 12 hours per day for 12 weeks, and then if the hamstring is not overlengthened, nighttime splinting continues as long as tolerated by patients and families.

Outcome of Treatment

Hamstring lengthening improves knee position in stance and the velocity of knee extension in swing phase.^{10, 11} However, if hamstring lengthening is performed alone, the knee will become more extended in stance but will have less flexion in swing, developing an increased stiff knee gait pattern (Figure 11.6).^{12, 13} If children have only medial hamstring lengthening, there will be slightly less anterior pelvic tilt postoperatively than if both medial and lateral hamstring lengthening had been performed.¹⁴ This effect on pelvic tilt is not of great clinical significance, except if the anterior pelvic tilt is combined with a significant iliopsoas contracture, in which case the psoas should be lengthened as well. Hamstring lengthening does not lead to weakness in the hamstring after full rehabilitation.¹⁵ Hamstring lengthening also leads to increased strength in the quadriceps, especially at 30° of knee flexion,¹⁵ probably because there is now less co-contraction in this range of joint motion. In addition to improving knee extension at initial contact and midstance phase, the evidence for functional improvement in stride length and velocity, which should occur if there is consistent increased knee extension at initial contact, has not been consistently documented. Most studies show minimal change in stride length or velocity after hamstring lengthening.^{11, 15, 16} Knee recurvatum may resolve slowly if hamstrings gain strength and recontraction occurs.¹⁷ During this time, the use of plantar flexion-limiting orthotics is important to assist the hamstrings and prevent back-kneeing from becoming a fixed position. The orthotic may also improve stride length and velocity.¹⁶

The outcome of hamstring lengthening to prevent progressive knee flexion contracture has not been well defined, but one report found a significant positive effect 4 years after the proximal hamstring lengthening with mean knee flexion contracture having reduced from 16° to 9°.¹⁸ Our experience has been that hamstring lengthening is effective if there is some follow-through with splinting or doing range-of-motion exercises, so the knee gets

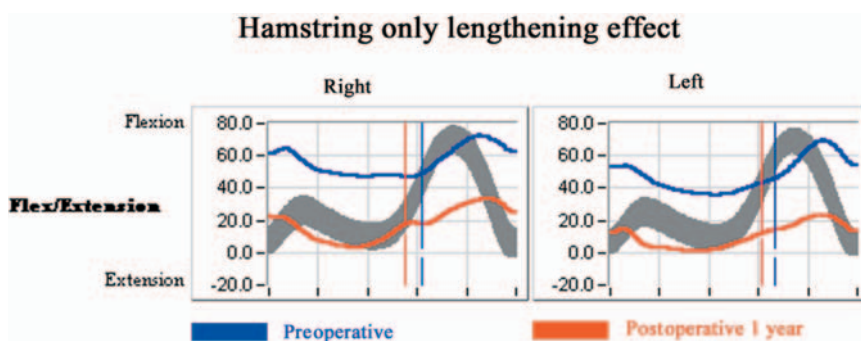


Figure 11.6. Correction of stance phase knee flexion by lengthening the hamstrings and mechanically correcting the foot deformities gives a predictable increase in knee extension. This 10-year-old boy had a severe crouch gait, and 1 year after hamstring lengthening and correction of planovalgus feet, the stance phase knee flexion improved 30° to 40°. However, the total knee range of motion did not improve at all. The decrease in knee flexion in swing phase is due to the spastic rectus muscle, which should have been transferred at the same time.

stretched into full extension daily. If children are allowed to sit and lie with the knees flexed all the time, the knee flexion contracture will not be impacted by hamstring lengthening. Stretching is most helpful if children have had problems with sitting and, after surgery, can now long-sit, which is an excellent mechanism to keep stretching out the hamstrings. There are very few data to evaluate the impact of distal versus proximal lengthening of the hamstrings. One report documented that there is no increase in anterior pelvic tilt with proximal as opposed to distal lengthening.^{19, 20} Sitting posture improves with proximal lengthening.²¹ A major advantage of proximal lengthening in young children becomes evident if a second lengthening is needed, and the distal tendons are free of scar and easy to lengthen.

Other Treatment

There are other variations of hamstring lengthenings. Some surgeons prefer to do the semitendinosus tenotomy distally and a semimembranosus tenotomy proximally. There are no reports on these variations. Also, there are some who prefer to do Z-lengthening of the semitendinosus instead of a tenotomy, which tends to scar back to the semimembranosus on which it lies. Again, there are no data to support the additional complexity of this procedure. Percutaneous tenotomy can be performed on the semitendinosus; however, this is too dangerous and not well enough controlled to try for the semimembranosus and biceps.

The Eggers procedure was defined in the middle part of the 1900s. In this procedure, the tendons of the semimembranosus, semitendinosus, and biceps femoris were removed from the tibia and sutured to the posterior aspect of the femur to provide for hip extension but remove their effect on knee flexion.²² This procedure led to severe recurvatum and has been completely abandoned. Although the Eggers procedure has a poor reputation,²³ there are no published reports of poor results. There are still a few discussions about transferring the semitendinosus to the femur so it will be a hip extender but have no impact on knee flexion. There have been no reports on this procedure. The size of this muscle makes it unlikely that the procedure would have a significant impact on hip extension, although we have no experience with this procedure. We have seen several children in whom both the semitendinosus and semimembranosus were transferred to the femur, and these children ended with back-kneeing gait patterns and severe stiff knees in swing phase. Therefore, transferring the semitendinosus probably does no harm, but the semimembranosus must be left on the tibia.

Complications of Treatment

The most common complication of hamstring lengthening is recurrent contracture. The need for repeat hamstring lengthening for children who had a lengthening when under 5 years of age is probably 75%, although there are no reliable published data. One report of lengthening at a mean of 6.9 years reported a recurrence rate of 12% at 2.5 years follow-up.²⁴ In our experience, the recurrence rate is very much related to children's activity and the amount of knee extension stretch they receive. Repeat lengthenings seem to have approximately the same result as the primary lengthenings; however, they are technically more difficult to perform because of the significant amount of scar. It is important to find normal muscle planes and to make sure that the lengthening of the hamstring occurs in the desired muscle. The risk of nerve and vascular injury in recurrent hamstring lengthening is higher; however, with proper care, it can be performed safely.

Wound infections, or wound dehiscence, is an occasional problem with hamstring lengthening. These wounds can be easily treated with local care

using wet to dry dressing changes, and antibiotics should be used only if there is active cellulitis. The wound may end up with a wider scar, but more aggressive treatment is seldom warranted.

Proximal hamstring lengthening may occasionally develop a hematoma, which causes significant discoloration of the proximal thigh. No specific treatment is indicated as these hematomas resolve without difficulty. Also, after healing from proximal hamstring lengthening, the hamstring may develop a midthigh mass in which the semimembranosus and semitendinosus have retracted distally, similar to the increased muscle size seen when the long head of the biceps brachii ruptures. The muscle will often reattach and continue to function as a hip extensor through the fascia and tendon attachment proximally.

Nerve injury can occur as a direct insult during surgery. During proximal hamstring lengthenings, the sciatic nerve can be injured if it is mistaken for the semimembranosus tendon. For children undergoing proximal hamstring lengthening, the anesthesia should not include neuromotor paralysis, and by using electrocautery, the nerve will be demonstrated clearly. As the electrocautery comes close to the nerve, activation will be noted. Also, always making sure that tendons are well exposed and clearly visible will prevent accidental nerve injury. In addition, it is also wise to use a nerve stimulator on tendons before they are transected. At the knee, the peroneal nerve is most vulnerable during biceps tendon lengthening. During revision lengthenings, if there is a severe hamstring contracture, it is important not to overstretch the released tendons, as a nerve palsy may occur secondary to the stretch. Postoperative nerve palsies may also occur during physical therapy when stretching of the lengthened muscle cannot serve its normal protective role. These children will be extremely uncomfortable, and this pain should be a signal to physical therapists to decrease the aggressive stretching. Children should not be placed in full extended knee casts and then be expected to sit upright. This upright position places too much stretch on the sciatic nerve and may cause a nerve palsy. Even children with severe mental retardation will have enough pain to not want to sit in this posture. Risk of nerve palsy means these children need to be stretched out very slowly so the nerve will gain length (Case 11.3).

Knee extension fractures at the distal femur may occur in individuals with osteoporosis and osteopenia in whom too much force is used to stretch the lengthened hamstrings. These fractures are usually insufficiency fractures that allow correction of knee flexion contracture. The major problem caused by these fractures is that they require 4 weeks of immobilization and are an unexpected side effect of the surgery from the perspective of the parents. Although these fractures are a rare complication, they have rarely caused any unwanted side effects and usually even improve the outcome.

Moderate Knee Flexion Contracture

Indications and Treatments

Children with moderate knee flexion contractures who are 10 years old or older will usually have great difficulty in stretching out knee flexion contractures when they are greater than 10° to 15°. In children with ambulatory skills, these knee flexion contractures usually need to be addressed surgically if the goal is to decrease the contracture. The specific indication is somewhat ambiguous, with a knee flexion contracture of less than 10° seldom causing mechanical problems, and a contracture of more than 20° seldom not causing limited midstance phase knee extension and limited extension in terminal swing. For a knee flexion contracture between 10° and 30°, the primary



Case 11.3 Carlos



Carlos, a 16-year-old boy with moderate quadriplegic pattern athetosis, presented with a complaint of increased difficulty with ambulation. He was a household ambulator and had been a partial community ambulator but over the past several years, he found walking more difficult. He was in 11th grade in a regular high school and planned to attend a university. He could self-feed but needed some assistance with dressing. He had no medical problems except the CP. On physical examination he was noted to have internal rotation of the left hip of 90° and external rotation of -20° . The right side had 60° of internal and 35° of external rotation. Hip abduction on the left was 15° and on the right it was 25° . Flexion and extension of the hips were normal. The left knee had a popliteal angle of 80° and a knee flexion contracture of 30° . In the right knee, the popliteal angle was 70° with a 10° knee flexion contracture. The flexion contracture of the left knee had a very firm end feel and in the right knee had a slightly softer end feel. The left foot was externally rotated with a thigh-foot axis of 45° external and severe planovalgus foot. The left ankle was at neutral dorsiflexion with the knee flexed, and knee extension dorsiflexion was -15° . The right foot had a moderate planovalgus and the same ankle range of motion as the left foot. The kinematics demonstrated internal rotation of the left hip, increased knee flexion at foot contact and midstance, and poor support at the left foot due to external rotation and planovalgus. After extensive discussion with Carlos and his family, he had a left femoral derotation osteotomy, bilateral hamstring lengthening, left knee capsulotomy, right triple arthrodesis, and bilateral gastrocnemius lengthenings. The knee was placed in a knee cylinder cast overlying the short-leg cast used to position his foot. By using a stocking between the leg cylinder and the short-leg cast, the knee cast could be removed and used as a splint. In the postoperative period he had severe pain, and at 24 hours he started to complain of numbness in his toes on the left side. The knee cast was removed; however, the pain and

numbness continued. The short-leg foot cast was also split and opened widely; however, the dense decreased sensation persisted, and by 48 hours the diagnosis of a dense sciatic nerve palsy was made. By now the severe pain was controlled with a high dose of morphine and diazepam. Gentle knee stretching with passive range of motion was initiated by a physical therapist. The left knee was splinted in 10° of knee flexion when he was lying, and when he was mobilized into a wheelchair, the knee was allowed to flex as much as was comfortable. By 10 days after surgery the pain was decreasing and he was discharged with physical therapy instructions for home, which were to include passive range of motion every day to neutral, but always with the hip extended. He was to start weight bearing and he was to wear the knee extension splint 12 to 18 hours a day, always with 10° of knee flexion with the hip extended. At 2 weeks after discharge, he was evaluated and found to have a dense sensory loss over the whole exposed forefoot and toes, and pain was still an intermittent problem but was not limiting therapy. At this visit, the knee splint was switched to full extension, which he was to continue to use 12 to 18 hours a day, always with the hip extended. He was to increase his gait training. At 8 weeks after surgery, the foot cast was removed, and he was noted to have minimal sensation on the foot and no evidence of muscle activity in the dorsiflexors or plantar flexors. He was placed in an AFO with therapy instructions to start ankle range of motion. There was no pain at this time. At 6 months following surgery, he started complaining of neuritic pain in the foot, and there was a return of gastrocnemius and dorsiflexor activity. The knee range of motion was from -5° of extension to 130° of flexion. By 16 months after surgery, almost all sensation had returned and good muscle strength was returning. By the 2-year follow-up, he had full knee extension and apparent normal sensation and motor power in the left leg and foot. His gait pattern was substantially improved and he was happy with the outcome of the surgery.

treatment indication is a posterior knee capsulotomy using the medial approach, always combined with hamstring lengthening. A lengthening of the medial head of the gastrocnemius is usually performed as well. A separate lateral approach may also be used but is usually not required. As the contracture gets to 20° to 30° , a radiograph should be obtained to document that there is no bony deformity of the femoral condyles that would preclude full knee extension.

The postoperative management of children requires keeping the knee extended in a splint or bivalve cast for 12 to 18 hours per day for 6 weeks. The knee should have passive range of motion, and if possible, it is best to give the knee some time out of the splint so the joint does not become stiff. Night-time knee splinting should be encouraged for up to 6 months, or as long as patients and families will tolerate.

Outcome of Treatment

There are no published reports of results following knee capsulotomy for spastic contractures in children with CP. Our experience has been that if children are ambulatory and obtain full knee extension intraoperatively, there will seldom be a recurrent contracture if the full extension is maintained for 6 months (Case 11.3). There are two problem areas with knee capsulotomy. The first problem is capsulotomies for contractures that are too severe, in which it is not possible to get full extension. This contracture is typically a flexion contracture of 30° to 45°, which is simply too much contracture to overcome with hamstring lengthening and knee capsulotomy. The second problem is recurrent contracture, which has an especially high risk in individuals who do not walk, or in children who spend a significant amount of time with the knees flexed. In these individuals, especially those who are full-time sitters, this procedure is seldom indicated unless there is some evidence that the individuals would do better without such a severe knee contracture.

Complications of Treatment

The most common complication of knee capsulotomy is sciatic nerve palsy. Sciatic nerve palsy is especially common when the knee capsulotomy is combined with correction of equinus foot deformity (Case 11.3). Many of these lesions occur after the surgery, especially if children are in a fixed cast that incorporates both the knee and ankle. If there is any evidence of decreased sensation, or more pain than expected, the knee needs to be allowed to fall into some flexion and the foot should be allowed to fall into some equinus. Daily gentle stretching into full extension of the knee, with the hip fully extended and the foot in equinus, will maintain the knee extension without further injuring the nerve. It is important not to allow the knee to fully flex, and the extension that was gained should be maintained. Often, the sciatic palsy will also cause the foot to swell, and the foot often has increased warmth from the sympathectomic effect of the sciatic palsy. Usually, after 1 to 2 weeks, the pain subsides and individuals will tolerate full knee extension in a splint when lying with the hip extended. Then, gradually, as the pain decreases and the children are able to tolerate, increased flexion of the hip is added to the knee extension. Typically, the stretch lesions of the sciatic nerve require approximately 12 to 18 months to make a full recovery. All five of the sciatic palsies we have treated have recovered, and there has been no loss of the knee extension that had been gained intraoperatively. If the nerve continues to be painful, especially if there is neuritic paresthesia, short-term use of an antidepressant, such as amitriptyline (Elavil), can be helpful. Although the end result 1 year later has always been positive, the postoperative period can be very traumatic for children, families, therapists, and doctors.

Vascular compromise can also occur from stretching the posterior knee structures. We have had one adolescent who developed an avascular foot 24 hours after the capsulotomy. Blood flow immediately returned when the cast was removed; however, he developed an anterior compartment syndrome with this vascular insult. Careful monitoring is required.

Hypertension has been recognized to occur after knee flexion contracture release. Hypertension was well known to occur during the poliomyelitis

era, but has also been reported in children with CP.^{25, 26} We have had only a few occasions of hypertension following knee flexion contracture release; however, in this limited experience, the hypertension did not resolve with knee flexion. Hypertension has to be recognized as a rare problem that can occur with hamstring lengthening only, although it is more common with more severe stretching, such as in knee capsulotomies.

Mechanical knee instability may occur especially if the release of the posterior capsule is extended medially to include the medial collateral ligament. We treated one child who developed a medial instability requiring repair. Also, the posterior capsule can be cut; however, if children are heavy and are functional standers, posterior instability can develop. We had one child who required repair of an iatrogenic posterior instability of the knee. Also, the capsulotomy has to be performed above the attachment of the meniscus so it does not disturb the meniscotibial attachment and create an unstable meniscus.

Severe Knee Flexion Contracture

Indications and Treatments

Severe knee flexion contractures are those with more than 30° of fixed knee flexion contracture. Many of these will develop flattening of the distal end of the femoral condyles, which precludes normal articulation with the tibial plateau. If the contracture is treated with capsular release, the tibia may start to hinge open instead of sliding around the condyles. When deformity of the femoral condyle has been noted to occur and there is a desire to correct the flexion contracture, a distal femoral extension osteotomy is indicated. Correction of this severity of knee flexion contracture will almost always be in individuals who, for some reason, have not received appropriate medical care and have functional ability that can be improved with treatment of the flexion contracture. Many individuals, especially those who are sitters and fully dependent for lifting transfers, will receive no functional benefit from correction of the contracture. Those who will benefit are individuals with ambulatory ability who, through lack of medical care, were allowed to become so contracted that they can no longer ambulate. Some of these individuals knee walk, and others do some standing and walking with a deep crouch gait. For those in whom functional gait is expected, a full understanding of why this severe contracture developed is required. If families have neglected these children, then doing an operation that requires aggressive and prolonged physical therapy will be doomed to failure unless the social situations are altered. If children live in an area where there is no medical care, this operation cannot be done unless they are kept in a rehabilitation facility for at least 1 year until the rehabilitation is complete, or the contracture will just reoccur. If there is not at least 1 year of aggressive follow-up, these children will again regress to where they started. If there is social understanding of why the neglect occurred and a remedy is found, then the outcome of treatment is very worth the effort. This operation is usually only part of a larger treatment plan involving the correction of severe crouched gait. Sometimes, based on a full assessment, not only do the feet need to be corrected, but hip flexion contractures may also need to be corrected.

When children have met all the criteria, the operative procedure includes hamstring lengthening followed by an extension shortening distal femoral osteotomy, which is usually fixed with a blade plate. Because the bone shortening decreases the tension on the posterior soft tissues, there is much less risk of developing a sciatic nerve palsy. However, this release of tension also means the anterior extensors of the knee are redundant. Many of these children start

with a high-riding patella. Usually, if they have not had a rectus transfer, one should be done at the time of the extension osteotomy. The high-riding patella is corrected by plicating the patellar ligament in a pants-over-vest fashion. If children are skeletally mature, the tibial tubercle can be transferred distally and rigidly fixed with a screw. The postoperative course allows immediate passive knee range of motion to 90° of flexion, and a knee immobilizer is used to protect the osteotomy for 4 weeks, or until there is some level of healing radiographically. Weight bearing in standing is allowed based on the perception of stability obtained at the time of the intraoperative fixation (see Chapter 7, Case 7.22).

Outcome of Treatment

When the correct therapy is obtained and patients are motivated, correction of the knee flexion contracture can be performed very reliably. However, if there is no follow-through with a change in activity or therapy, the contracture will almost invariably reoccur. This procedure is relatively uncommon and is performed primarily on individuals who have had some level of medical neglect, or they would not have been allowed to get this severe. The environmental and social causes of this severe contracture need to be understood before treatment is undertaken or a poor outcome will result.

Other Treatment

Another option that has been discussed to address these severe contractures is the possible use of external fixators with distraction and slow correction of the contracture. Many of these children have some level of osteopenia or osteoporosis and often would not be good behavioral candidates for this procedure. We have no experience with this treatment; however, there is one report of a small number of children treated in which a positive outcome was noted.²⁷ We would not recommend this procedure because the osteopenia and behavioral characteristics of most children who need this type of treatment would make child management very difficult. Also, an immediate corrective osteotomy is reliable and allows surgeons to address the related problems, such as the spastic rectus muscle and the patella alta, at the same time.

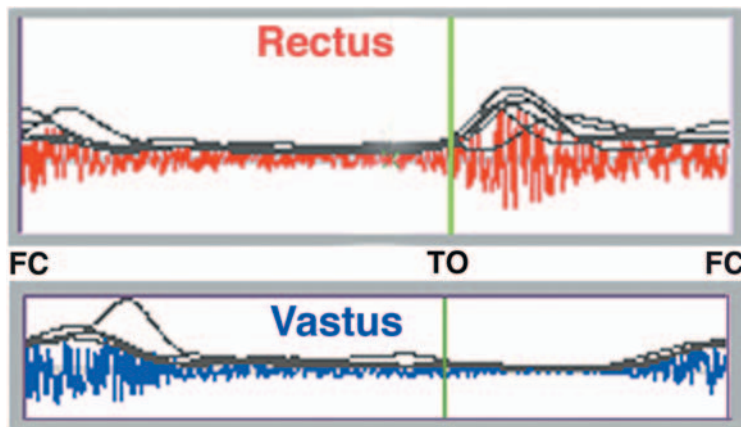
Complications of Treatment

Complications, such as nonunions and malunions of the osteotomy, are possible but have not been encountered. Wound infection and joint stiffness have also not been significant issues. One year of rehabilitation is required to develop the real benefit of this procedure. Length of rehabilitation is the major difference between capsulotomy and extension osteotomy. The capsulotomy recovery is much quicker because the operation requires no bone healing. In the capsulotomy, however, there is a higher risk of sciatic nerve palsies.

Knee Extension Pathology: Inadequate Knee Flexion

The knee extensors include the quadriceps muscles and fascia latae. As opposed to the knee flexor muscles, almost all the power-generating ability of the knee extensor muscles are single-joint muscles that include the whole vastus group. This group of muscles makes up 80% to 85% of the force-generating capacity of the knee extensor muscle group. The remaining strength comes from the rectus, and only minimal additional strength is added by the small fascia latae. In children with CP, the fascia latae seldom causes problems, and if it does, it is more often recognized as causing hip flexion and

Figure 11.7. The indication for rectus transfer should ideally be a child with symptoms of a stiff knee gait, decreased and late knee flexion in swing phase, and significant swing phase activity of the rectus but no activity in swing phase of the vastus. This is an example of the ideal EMG pattern to indicate a rectus transfer.



abduction than causing knee extension contracture. The vastus muscles usually only cause problems in end-stage severe contractures, primarily in non-ambulatory children who have had prolonged severe extensor posturing. The rectus muscle, which is a two-joint hip flexor and knee extensor, is often the cause of most knee extension problems. The primary function of the rectus muscle in gait is to transfer momentum force of the increasing knee flexion in terminal stance and initial swing to hip flexion. This muscle modulates the degree of maximum knee flexion in initial swing phase, so the limb will swing under the body in a shortened limb position and not strike the floor, but with enough forward momentum so the foot will be ready to accept weight when the body has moved in front of the contralateral push-off foot. This process requires a high level of motor control, but adds significantly to making a smooth energy-efficient gait pattern. The rectus muscle should be active primarily in terminal stance and initial swing. The vastus muscles provide stability at initial contact and in weight acceptance. The vastus muscles are also active in stair climbing as knee extensors in middle stance phase. The rectus is usually more active in descending an incline as a decelerating muscle. The most important knee extensor in normal gait, especially in late weight acceptance and midstance, is the gastrocnemius through its action on the ankle combined with the momentum of forward motion and the ground reaction force. Therefore, the increased knee flexion typically seen in midstance in the crouched gait pattern is not due primarily to pathology in the quadriceps because these muscles should not even be activated in normal midstance phase (Figure 11.7). The primary problem of increased knee flexion in midstance is due to abnormal gastrocnemius, foot, and ankle mechanics in the syndrome called lever arm disease by Gage.²⁸ This syndrome is often combined with knee flexion contractures and occasionally hip flexion contractures.

Stiff Knee Gait

The primary problem caused by the knee extensor group is a stiff knee gait in swing phase, which is almost always due to increased activity of the rectus muscle. Increased activity of the rectus muscle seems to be a response of the limited motor control available. With limited motor control, a system that is stiffer and has fewer degrees of freedom is easier to control. In children with severe motor impairments, such that they can only stand, the whole quadriceps muscle may be activated. As more motor control is available, only the rectus muscle is kept activated continuously, and with still better control, the rectus is only overactive to keep the knee too stiff, causing toe

drag during swing phase. The activity of the rectus is assessed primarily by the amount of knee flexion in initial swing and the EMG activity. Sometimes the EMG will have increased activity, but there is adequate knee flexion defined as 60° of knee flexion peaking between 25% and 30% of swing phase. The increased EMG means that the electrical activity is increased, but the force generated is not abnormal for the mechanical milieu of the limb. If the peak knee flexion is less than 50° or 60°, or the peak flexion is later than 30% of swing, then the rectus is overactive, causing a dynamic contracture limiting knee motion. The symptoms created are toe drag during swing phase and very rapid shoe wear with the front of the shoes wearing through, sometimes in as short a time as 4 to 6 weeks, secondary to the toe dragging.

Knee Extension Contractures

For a few children with significant and prolonged extensor posturing, muscle contractures of the vastus and rectus muscles may develop. These contractures are almost always combined with hip extension contractures and equinus ankle contractures. In the most advanced form, this contracture development includes the type 1 anterior hip dislocation, in which the hip and knee are extended and the hip is adducted and severely externally rotated. A few children develop this pattern without an anterior hip dislocation (Case 11.4). Knee extension contractures are functionally disabling because it is very difficult to seat these children with the knees fully extended, especially as they reach adult size.

It is important to note that back-kneeing in stance phase is seldom directly or even indirectly secondary to the vastus or rectus muscles. These quadriceps muscles usually are not even contracting in midstance phase in children who are back-kneeing. The cause of stance phase back-kneeing is related to the foot and ankle force couple, with a secondary contribution of the hamstrings. Very weak vasti will be accommodated by full knee extension at foot contact so as to avoid the need for the stabilizing effect of the vastus muscles during weight acceptance. Therefore, back-kneeing is not the result of overactivity of a quadriceps muscle, but may be primarily due to weakness of the quadriceps muscle in which the motor control system is protecting the muscle by back-kneeing (Table 11.2).

Secondary Pathology

Children with crouched gait pattern of increased knee flexion in midstance may start to depend on the vastus muscles as the main muscle power to prevent the knee from collapsing into more flexion. These patterns of crouch will often demonstrate EMG activity in the vastus muscles throughout all of stance phase, combined with a consistent and increased knee extension moment. This constant force on the vastus muscles, which are often somewhat spastic as well, causes decreased muscle fiber growth. The constant force also causes the patellar tendon and patellar ligament to grow, with the net effect of the patella gradually moving more proximal than its normal position. This proximal patellar movement is called patella alta. Because the patella alta moves the patella out of the femoral groove, the moment arm over the fulcrum of the patella decreases, requiring even more muscle force for the quadriceps to prevent collapse of the knee. As the force increases, there is usually more patella alta, and as the patella alta increases, more force is required (Case 11.5). This process occurs especially during the rapid weight gain of adolescent growth and when untreated may cause adolescents to stop walking. This increasing crouch is a purely mechanical set of problems that can be treated and should not be the cause of adolescents discontinuing ambulation.



Case 11.4 Angelique

Angelique, a 10-year-old girl with severe spastic quadriplegia, presented with her mother whose main concern was that she had increased difficulty when she sat in her wheelchair because of the extended knees. This problem had been present for many years, and her mother could not remember how long it had been since she could flex her knees. The physical examination demonstrated hip flexion to 90°, abduction to 30° bilaterally, knee extension to neutral, and flexion to 25°. Both feet had a severe equino-

varus fixed position (Figure C11.4.1). To improve the knee flexion, she had Z-lengthening of the quadriceps tendon and was splinted in 90° of knee flexion for 3 months (Figure C11.4.2). Starting on postoperative day 3, the splint was removed every day and the knee was ranged from full extension to maximum flexion. By 6 months follow-up, she had maintained 90° of knee flexion and could be seated much more easily in her wheelchair.

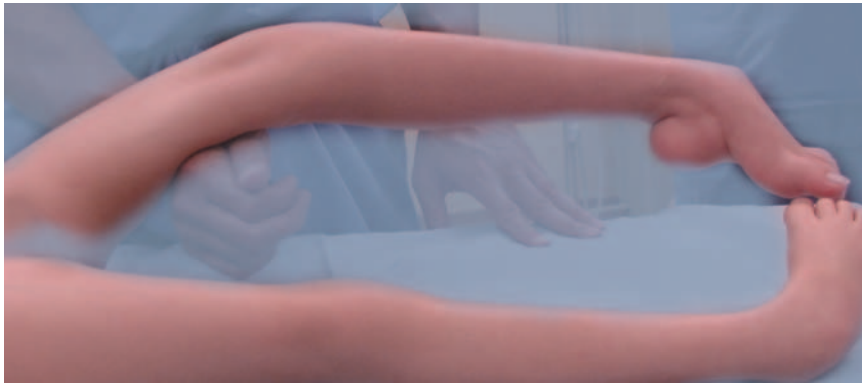

Figure C11.4.1

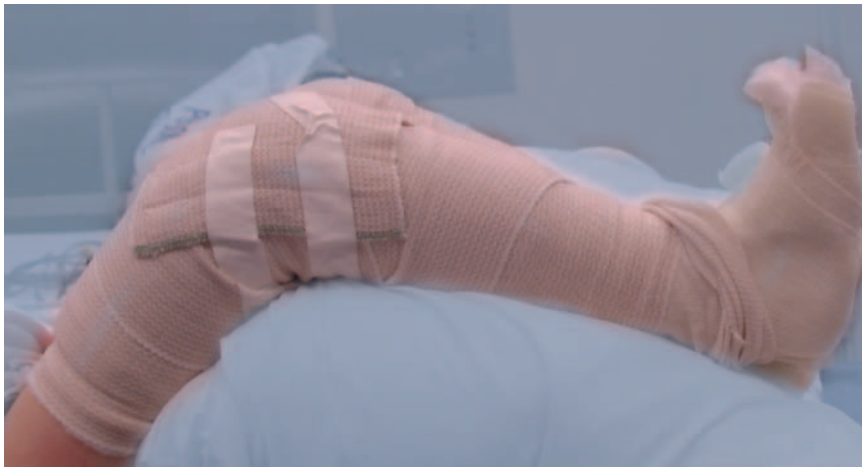

Figure C11.4.2

Table 11.2. Cause of back-knee and crouch gait: different compensations for the same underlying mechanical problems.

1. Poor mechanical foot function: Usually planovalgus with external rotation
• Treatment: Stabilize the foot with the appropriate surgery or orthotics
2. Severe torsional malalignment: Usually internal rotation of the hip and/or external tibial torsion
• Treatment: Correct torsional malalignment
3. Contracture of the hamstring and gastrocnemius
• Treatment: Try to get the correct balance by lengthening muscles
4. Hip contracture: Flexion causes crouch, extension causes back-kneeing
• Treatment: Correct contracture
5. Crutch use: Tends to cause back-kneeing because of the forward fall of the center of mass
• Treatment: Difficult, use AFO to prevent ankle plantar flexion, try posterior walker, make sure no gastrocnemius contracture, monitor carefully for progressive hyper-extension deformity, if present have to use knee-ankle-foot orthosis (KAFO) with knee extension block hinge
6. Fixed knee flexion contracture: Causes crouch gait
• Treatment: Requires surgical correction if greater than 15° to 20° and the functional goal is community ambulation

This process of proximal migration of the patella also occurs in very severe and neglected cases of fixed extension contractures (Case 11.4).

Tertiary Changes

As the patella moves proximally and the high stress gets worse, the patella starts to develop stress fractures. The most common high stress reaction in the patella is apophysitis of the distal pole. A radiograph of the patella demonstrates fragmentation of the distal pole of the patella. This reaction tends to cause inflammation and pain, making walking uncomfortable and more difficult. Any condition that makes the stress on the patella worse will tend to increase this reaction and the subsequent pain. By not understanding the cause of crouch, and doing ill-advised Achilles tendon lengthenings, patellar symptoms have been shown to be increased.²⁹ After the distal pole patellar fragmentation, tibial tubercle apophysitis is the next most common stress reaction. This reaction is very similar to the typical jumper's knee seen in otherwise normal adolescents.³⁰ The least common but most symptomatic reaction is a stress fracture of the patella (Case 11.5). This fracture may occur in the center or toward the proximal end of the patella. If this stress fracture is ignored, the patella will appear to stretch out and become much longer than normal. This elongated patella occurs as a stress fracture tries to heal, but the two halves of the patella are slowly pulling apart. Catastrophic failure of the patella, with an acutely displaced patella fracture, may occur on top of the patella stress fracture, but this is very rare.³¹

Diagnostic Studies

The diagnostic evaluation of stance phase problems leading to crouch must include a full evaluation of the reasons for the crouch. The primary cause of crouch is often a foot moment arm that is not stiff or stable enough, typically due to significant planovalgus foot deformity. Another reason may also be a significant ankle-foot torsional malalignment with the knee joint. A physical examination should focus on the foot position and alignment and the force-generating ability of the gastrocnemius and soleus muscles. Next,



Case 11.5 Felicia

Felicia, a 12-year-old girl with spastic diplegia, complained of severe knee pain on the right, which made ambulation more difficult. The knee was not painful if she was not walking. On physical examination, she was noted to walk with a front-based walker, in approximately 30° to 40° of midstance knee flexion with severe planovalgus, especially of the right foot. Hip range of motion was mildly diminished at all end ranges. The knee had a 10° flexion contracture on the left, 5° on the right, and popliteal angles of 85° bilaterally. The anterior aspect of the left patella was swollen and very tender. A radiograph was obtained, which demonstrated a stress fracture of the distal pole of the left patella and planovalgus feet (Figures C11.5.1, C11.5.2). She had left triple arthrodesis, bilateral hamstring lengthenings, and gastrocnemius lengthenings. After the foot fusion healed, she was placed in a ground reaction AFO. All knee pain resolved after the surgical treatment, and a follow-up radiograph 2 years later showed complete healing of the patellar fracture, but she is now left with an elongated patella (Figure C11.5.3).

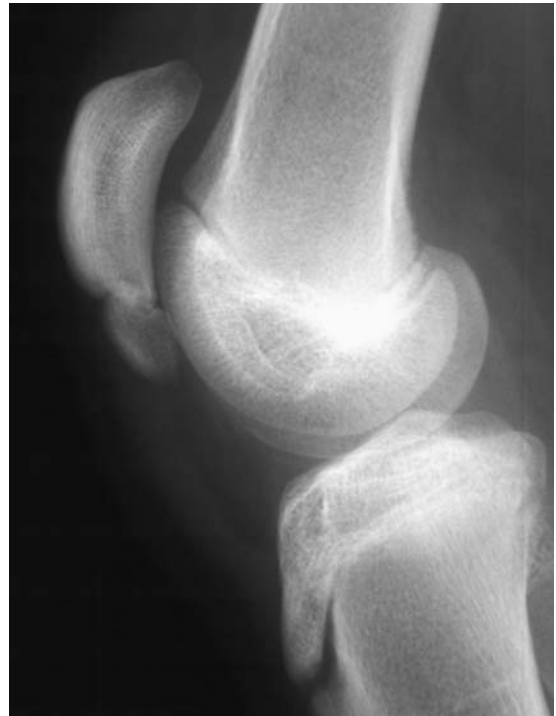

Figure C11.5.1

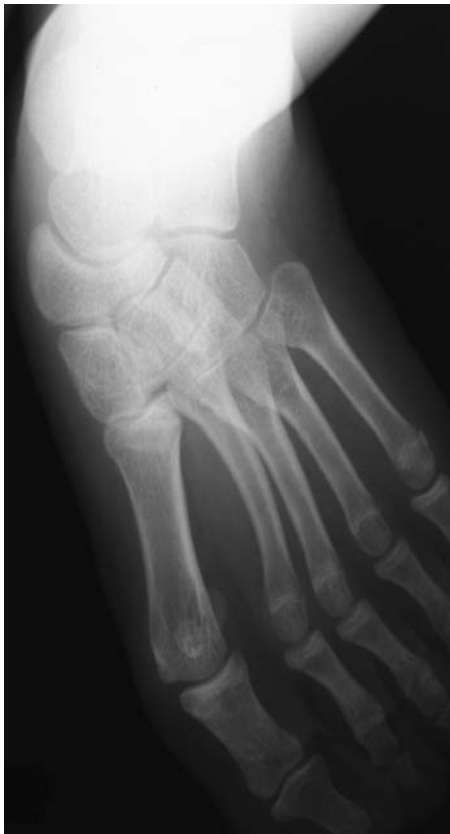

Figure C11.5.2

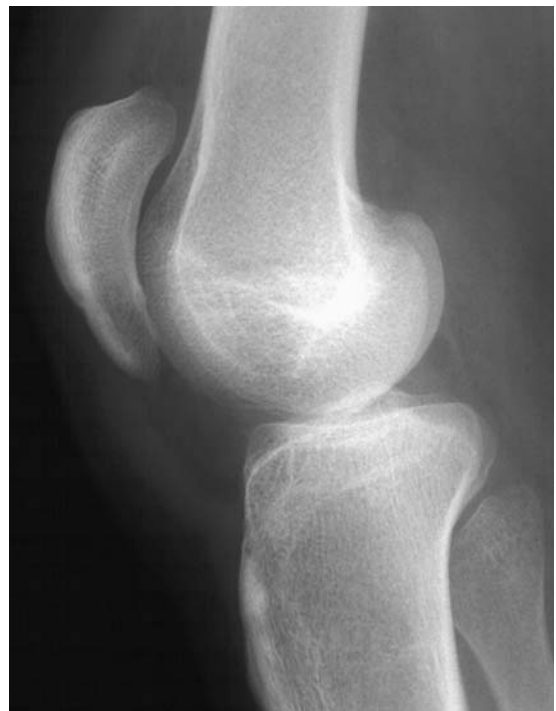

Figure C11.5.3

the degree of contracture of the hamstring and knee capsule has to be evaluated along with the hamstring EMG. Hip flexion contractures and torsional alignment with the forward line of progression of the knee joint axis are also important. Next, a radiograph of the knee should be obtained to rule out a stress fracture of the patella and demonstrate the presence or absence of patellar or tibial apophysitis.

The evaluation of dynamic rectus contractures requires measuring knee flexion in swing in the presence of EMG activity in initial swing phase and into midswing. Also, there should be evidence of symptomatic problems, such as toe drag and rapid shoe wear.

Treatment of Dynamic Knee Stiffness

The treatment of dynamic stiffness of the knee in swing phase is first to make sure the correct etiology is identified (Table 11.3). Another cause of stiff knee gait can be a very slow gait, defined as less than 50 cm per second. Also, very poor push-off and weak hip flexors combine to decrease the available power in which to initiate swing phase. In addition, the knee must have mobility and not be fixed and immobile. If the spastic rectus is found to be the problem by excluding other causes, and the knee has decreased flexion of less than 60° and late knee flexion of greater than 30% of swing phase with an overactive EMG, transfer of the distal tendon of the rectus muscle is indicated (see Table 11.3). Transfer to the sartorius or semitendinosus is most common. We prefer a transfer to the sartorius because it is easy and very simple; however, there is no evidence that the distal site of transfer matters.³² It is important to transfer the muscle rather than just release it, as the release will reattach and allow the muscle to become active again.³³ Also, proximal release is not as effective as distal transfer.³⁴

Other Treatment

The use of botulinum toxin injections can give some sense of the expected improvement; however, they are seldom needed because the criteria for doing rectus transfers are well defined. Except to improve the associated problems, such as weakness of hip flexors or push-off, there have been no other treatments for this problem.

Table 11.3. Causes of stiff knee gait.

1. Decreased hip flexor power due to the insufficient muscle power or poor position
 - Treatment: Correct hip flexion contracture (but this seldom improves stiff knee gait)
2. Poor ankle power generation
 - Treatment: Get the foot into ideal position usually by lengthening gastrocnemius or correcting other foot deformities
3. Knee joint axis is malaligned with the forward line of progression
 - Treatment: First identify the cause, either femoral anteversion or tibial torsion, then correct the deformity; this correction can make a major improvement especially if the knee axis progression is more the 15° out of line with the forward line of progression
4. Spastic or out-of-phase rectus muscle
 - Treatment: Transfer the rectus from the distal insertion to another area, usually the sartorius or semitendinosus, so the rectus can no longer function as a knee extender
 - Indications:
 - A. EMG activity of the rectus in early and middle swing phase
 - B. Plus decreased ($\pm 55^\circ$) knee flexion in swing phase
 - C. Plus (or) late peak knee flexion in swing phase (>30% of swing time)
 - D. Plus symptoms of stiff knee gait, i.e., toe drag, rapid shoe wear, tripping
 - E. Plus functional walking speed (>75 cm/s)

Outcome of Treatment

The outcome of rectus transfer is consistent and well studied, with gains of 12° to 18° of knee flexion in swing phase expected.^{35, 36} Children with more severe involvement, meaning a continuously firing rectus, did not gain as much as children with only prolonged rectus activity³⁶; however, significant co-contraction with the vastus muscles does not seem to have a negative impact on the outcome.³⁷ It has been our unconfirmed sense that children with a very slow gait of less than 50 cm per second gain very little functional benefit from the rectus transfer. Also, there is less benefit of doing the rectus transfer in young children less than 7 years of age, as these children often demonstrate increased knee stiffness again as they go through middle childhood and adolescence.

However, there are unreported data from another laboratory that rectus transfers change very little over a 5- to 10-year follow-up. This result is also our experience if the transfer is done in late middle childhood or adolescence. However, our current perception is that young children under age 6 years and those who walk slowly, less than 50 cm per second, have less improvement and tend to lose the gains in knee flexion seen immediately postoperatively. This small change suggests that the stiff knee is providing a functional benefit that these children need, and at a minimum, there is a strong attractor to knee stiffness in this group of young children who typically have more significantly decreased motor control ability.

Complications of Treatment

Complications of rectus transfers are few, and most involve problems with the skin. In some children, the anterior knee has a tendency to form a very wide scar, which is also an area, especially in girls, that is very cosmetically apparent. Good attention to subcutaneous closure seems to decrease this problem; however, it is not possible to completely eliminate the problem. Actual wound infection is very rare, and most open wound problems are related to wound dehiscence from the increased skin tension. These wound problems can be treated easily with local wound care, and antibiotics are given only if there is significant cellulitis.

Another complication that we have seen is the reattachment of the rectus to the quadriceps, usually through a residual part of the rectus tendon that was not removed in the first procedure. We reexplored several children who had excellent early results of the rectus transfer, but deteriorated significantly in 3 to 4 years to where the rectus transfer had lost all its effect, and found very large tendon fragments of the rectus still attached to the quadriceps tendon. These explorations help to regain some of the knee flexion, but not as much as the initial procedure. This problem should be avoided by aggressive palpation of the rectus to make sure all of the tendon is removed at the original surgery.

Patella Alta

Patella alta is a common finding in adolescents and adults with spastic gait. Most commonly, patella alta is associated with crouch gait. Because the primary cause of crouch gait is never problems with the knee extensor mechanism, the treatment of crouch is not directed at the knee extensors; however, the symptoms of the crouching may be focused on anterior knee pain related to the patella alta. In fact, the knee extensors require treatment only on rare occasions. The primary causes of crouch have to be identified in each indi-

vidual patient, and each component has to be addressed before considering treatment of the extensor mechanism.

Indications and Treatments

The indications for direct treatment of the knee extensor mechanism are based on pain from either high stress response or redundancy of the extensor mechanism. Children with pain from tibial tubercle or patellar pole apophysitis or stress fractures of the patella almost always respond with appropriate treatment of the primary causes of the crouched gait. After the primary pathomechanics of the crouch position have been corrected, the extensor mechanism may need additional protection with the use of a dorsiflexion-limiting ground reaction ankle-foot orthosis (AFO). Direct surgical treatment is indicated only after correction of the primary causes of crouch and using the AFO for several months, during which the apophysitis continues to be severely painful. When the pain continues after the crouch has been corrected, it is often localized around fragmentation ossicles or ossification. One attempt at injecting this area with a depocorticosteroid may remove the pain. If the pain is still present, resection of the ossicles and fibrous scar tissue is indicated. For reasons that are not clear, even after resection of this tissue, the pain often persists and resolves only slowly, often requiring another year of rehabilitation.

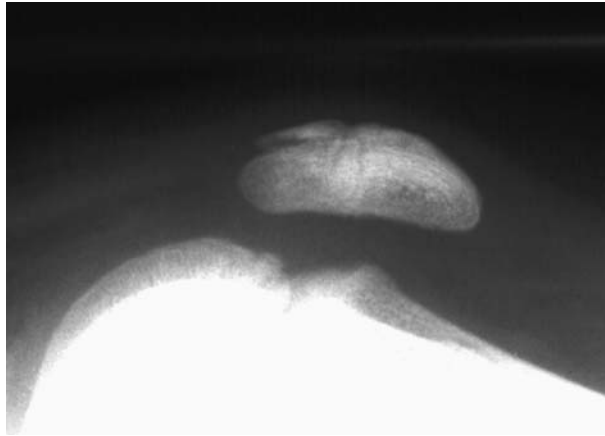
The major problems of the extensor mechanism in the crouched gait syndrome are patella alta and an elongated patellar tendon causing an extension lag. In severe cases, adolescents may have 15° to 30° of lag after flexion contracture of the knee joint has been corrected by posterior capsulotomy and hamstring lengthening. This extensor lag responds well to strengthening exercises^{38, 39} and orthotic control using articulated ground reaction AFOs. However, it must be emphasized that strengthening and orthotics will work only if the severe knee flexion contractures and foot deformities are corrected. In the severe crouched posture, often having 45° or greater of knee flexion in midstance and a fixed knee flexion contracture greater than 30°, a distal femoral extension osteotomy is required to correct the fixed flexion deformity. With knee flexion contracture of this severity, especially when it is corrected by distal femoral osteotomy, there is severe redundancy of the extensor mechanism. In almost all cases of distal extension osteotomy, the excessive length of the patellar ligaments should be addressed by either distal transfer of the tibial tubercle or plication of the patellar ligament.

Outcome of Treatment

Pain from high stress in the extensor mechanism is usually short term and resolves with activity limitations. For children with significant crouched gait, correction of the primary etiology of the crouch will almost always resolve the pain from the stress reaction. Although radiographic evidence of patella alta and fragmentation apophysitis is common, surgical treatment is rarely required.^{30, 40, 41} In our experience, when surgical correction is required, pain relief can be very slow; however, there is one report that suggests pain relief is almost immediate.²⁹

Plication of the patellar ligament or distal transfer of the tubercle has been reported primarily in the older literature,^{42, 43} in which the primary treatment of crouch was not as appropriate and complete as is common today. Also, there are no data from postoperative gait evaluations. With current understanding of the etiology of crouched gait, the need for femoral extension osteotomy and plication of the patellar ligament is required only in rare

Figure 11.8. This 12-year-old girl with diplegia was growing rapidly and complaining of knee pain. On physical examination she had popliteal angles of 60° and a positive Ely test at 100° . She was tender over the patella, especially the distal pole. Her gait was remarkable only for a mild crouch gait. The radiograph demonstrated a stress fracture of the patella with a stress reaction of the distal pole. She was given instructions on hamstring and quadriceps stretching and given a pair of solid-ankle AFOs with a wide anterior tibial strap to improve the effectiveness of the plantar flexion knee extension couple. This orthotic unloaded the knee extensors and the pain rapidly decreased. The AFO wear was continued for 1 year, then she was again weaned from the orthotic, and she has remained pain free for the past 5 years.



neglected cases, making it difficult to accumulate enough cases to understand the medium-term and long-term outcomes.

Complications of Treatment

The primary complications of treating painful stress reactions is the prolonged nature of the pain (Figure 11.8). This pain may require prolonged physical therapy for stretching and strengthening exercises of the knee extensor mechanism. Acute disruption of the stress fracture can occur, but is rare. If acute disruption occurs, the displacement has to be repaired surgically.

Complications of treating the extensor lag by surgical plication are mainly due to excessive shortening and not removing the rectus muscles from the quadriceps tendon. These complications may lead to a severe stiff knee in swing phase and even a fixed knee extension contracture. After the extensor mechanism has been tightened, the knee should be able to flex easily to 90° intraoperatively. The extensor muscles cannot be stretched if only 45° of flexion is present after patellar plication. These extension contractures are disabling, especially from knee stiffness in swing phase, and may cause problems with sitting and with coming to standing from a sitting position.

Fixed Knee Extension Contractures

A mild to moderate fixed knee extension contracture, which allows knee flexion past 90° , is common but almost never of any clinical consequence. Usually, the severe contracture limits motion to less than 30° to 40° of knee flexion and is very disabling, especially impairing seating. Only rarely does a severe extension contracture occur spontaneously in individuals who can stand or walk. In rare situations, with individuals who can stand or walk, the extension contracture causes great difficulty in coming to stand. Usually, these individuals require some help or lifting to come to the standing position. In almost all severe extension contractures, the primary contracture occurs in the vastus muscles, and the rectus is relatively less contracted because there is a combination of hip and knee extension contractures in most cases. The treatment of severe knee extension contracture is a Z-lengthening of the quadriceps tendon. In individuals who can stand and walk, a V-Y-lengthening is preferred to allow better maintenance of continuity of the tendon. At least 90° of knee flexion should be obtained at the time of the lengthening. The postoperative management must include 8 to 12 hours per day of splinting the knee in flexion with some passive knee range of motion every day. In most individuals, 70° to 90° of knee flexion is preserved after full rehabilitation

of 3 to 6 months. Individuals should sit in a wheelchair with the knees flexed, and it is strongly recommended that the elevating leg rests be removed from the wheelchair because there is a natural response by caretakers to raise the feet when the individuals are a little uncomfortable. If the extension contracture is to be treated, individuals must spend a significant amount of time sitting with the knees flexed because they almost never flex the knees in bed, where they typically lie in full extension (Case 11.4).

Outcome of Treatment

The long-term outcome of tendon lengthening for knee extension contracture has not been reported. Our experience suggests that the outcome for maintaining knee flexion is excellent if individuals can be seated in hip and knee flexion for most of the day. However, if caretakers tend to allow children to return to the preoperative fully extended posture for most of the day, the knee extension contractures will recur within 1 year.

Other Treatment

The only other treatment option besides surgical lengthening is to keep these individuals in a reclined and extended position. This position makes transportation difficult and limits the ability of individuals to interact with their environment by being in the full or semireclined position.

Complications of Treatment

The main complication of knee extension contracture release is operative wound problems. Usually, the skin on the anterior aspect of the thigh is not very supple because there has been no knee motion. When the extension contracture is released, the skin is very tight from being required to stretch along with the elongated muscle. When doing an extension contracture release, a longitudinal skin incision should always be used or it will be very difficult to close the skin wound. Even with a longitudinal incision, the wound may have problems healing because the severe stretch tends to cause some wound dehiscence. By allowing some healing for 2 to 3 weeks before pushing hard to gain the final degree of flexion, the wound may heal better. However, it is important not to wait too long to begin flexion stretching exercises because the contracture tends to start setting up, which makes the rehabilitation difficult and compromises the end result.

Patellar Subluxation

Patella alta, which means the patella is riding superiorly out of the femoral groove, is common in children with spastic lower extremities. This position appears to lead to dysplasia of the femoral groove and patellar subluxation. Few children develop symptoms from patellar subluxation; however, patellar dislocation on the lateral side of the femur occurs at least as commonly as in normal children. There are no published reports on patellar instability in children with CP; however, we have accumulated a series of cases. Often, the dislocated patella can be easily reduced but then becomes a recurrent problem, causing pain and mechanical instability of the knee. The dislocation in ambulatory children becomes a definite problem requiring surgical reconstruction, as children cannot walk with a dislocated patella. Children who are sitters will often become relatively uncomfortable from the dislocated patella.

The patellofemoral pain that is typical in adolescent girls also occurs in children with CP. If adolescents have no history of patellar dislocation and

have no severe torsional malalignments of the lower extremity, this anterior knee pain tends to have a course very similar to the normal adolescent knee pain, in that it slowly resolves as growth completes and weight gain stabilizes. A small group of adolescents with spastic gait develop severe anterior knee pain due to severe torsional malalignment with increased femoral anteversion and external tibial torsion. When this torsional malalignment is present with severe anterior knee pain, the pain will usually not subside until the torsional malalignment is corrected.

If the dislocated patella is ignored, it will often cause progressive knee flexion contractures with severe external rotation deformities by causing external rotation through the knee joint.

Indications and Treatments

For children who are ambulatory, there is an apparent loss of function with the dislocation of the patella. This loss of function can be restored by surgical realignment of the patellofemoral mechanism. If the patella dislocation is associated with knee flexion contracture or hamstring contracture, these should be corrected concurrently. If there is a severe external rotation foot progression angle, this should be corrected concurrently. The patella is then aligned by a mild release of the lateral retinaculum and advancement of the vastus medialis. Usually, the increased Q-angle between the patella and the tibial tubercle can be corrected by medial transposition of the tibial tubercle if the tibial epiphysis is closed. However, if patellar dislocation occurs in children before epiphyseal closure, then transfer of the semitendinosus is the preferred way to give a medially directed vector to the insertion of the patellar ligament.

If adolescents have severe torsional malalignments with femoral anteversion and external tibial torsion, correction of the torsional malalignment is the primary treatment. This treatment usually requires a femoral and tibial derotation osteotomy with correction of any other secondary problems contributing to an abnormal gait.

Patellar dislocation occurs in nonambulatory children. If dislocation is recognized, reconstruction is recommended to avoid the severe tertiary changes that occur with a dislocated patella. If children present with a fixed dislocated patella that seems to be long standing, reconstruction is not advised unless there is some other problem, such as pain or skin breakdown from severe contracture.

Outcome of Treatment

All children we have treated for recurrent patellar dislocation have developed stable and pain-free patellar joints. There have been no significant complications from this treatment.

Other Knee Pathology

Knee Mechanical Instability

Children with spasticity have reduced knee range of motion during walking and running. This increased stiffness provides increased stability to the knee joint. As a consequence, there are fewer typical instability injuries, such as torn ligaments and menisci. Because there is a decreased incidence, there may be tendency by neuro-orthopaedists to overlook these injuries as a possible cause of children's complaints of knee pain. We have seen several children

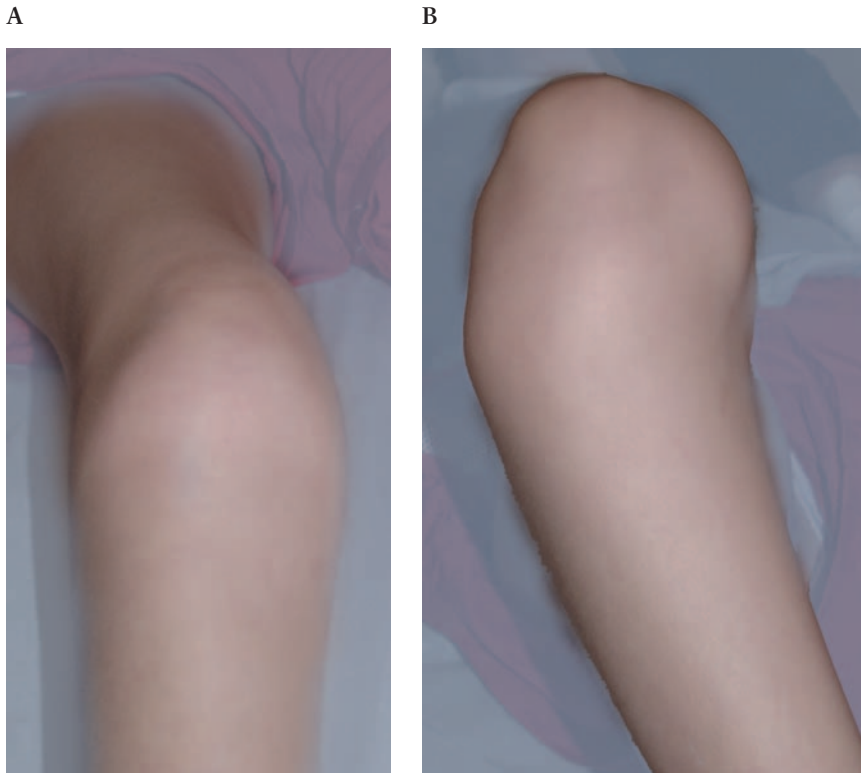


Figure 11.9. This 12-year-old boy developed severe lateral rotatory subluxation of his knee, probably from having the foot restrained against severe spastic internal rotation of the hip. Some adjustment of the wheelchair has made him less painful; however, a surgical reconstruction is required. The first stage in decreasing the stress on the knee is to decrease the force of the internal hip rotation by a femoral derotation or hip internal rotator release. This approach is sometimes enough.

with torn menisci and anterior cruciate tears who related a specific clear traumatic event, which was initially ignored. On the other side, we have also seen many children who have had knee arthroscopies by sports-trained orthopaedists for clear extraarticular knee problems, such as knee pain from severe torsional malalignment. The possibility of internal knee derangement has to be considered in individuals with spastic gait patterns; however, these injuries seem to be less common than in otherwise normal individuals. When internal derangement and mechanical instability are suspected, the workup and treatment should be the same as in normal individuals.

A few children develop instability of the knee that is atypical and may be related directly to the spasticity. We have seen several children who developed a severe posterolateral instability suggesting overpull of the biceps tendon (Figure 11.9). None of these children had medial hamstring lengthenings before the instability. This instability tends to have a period of time where it progresses very rapidly, during which time it often causes a significant amount of knee pain. Often, as the instability progresses, the tibia may be subluxated medially with some posterior instability on the lateral side.

Indications for Treatment

If children have a typical ligament injury, it should be treated similar to age-matched normal individuals. If a severe posterolateral and medial instability develops, a reinforcement procedure using the fascia lata and capsular plication may be required. These instabilities are rare and always seem to have considerable individual differences with respect to where the major lesion resides. Careful evaluation by arthroscopy is required to rule out meniscal instability or meniscal tear. There are no published reports evaluating the outcome of ligament reconstruction in individuals with spasticity. Our limited

experience suggests that these individuals experience pain relief and increased stability of the knee joint; however, there is usually significant persistent laxity.

Intraarticular Pathology

Intraarticular derangements of the knee, such as torn menisci, loose bodies, or plica, can all occur in children with spasticity. These intraarticular derangements are less likely to occur than in normal age-matched children; however, workup and treatment is the same as for any other individuals. Also, it is important to remember that children presenting with acute knee effusion may have an inflammatory lesion as well. We have diagnosed three children with rheumatoid arthritis, all of whom initially presented with knee effusions. We have also diagnosed patients with Lyme disease, in which the most common presenting joint is the knee joint, although it may present in any joint in the body. Even children who never go out into wooded areas may still be at risk for Lyme infections if they live with animals or household members who spend time in tick-infested areas.

Varus and Valgus Deformity

Major bone malalignments around the knee are uncommon in children with CP. Only on rare occasions do varus or valgus deformities develop that are severe enough to merit surgical correction (Case 11.6). A few children develop anterior tibial growth arrest, possibly from high stress on the patellar tubercle, or perhaps from aggressive stretching of knee flexion contractures. The exact cause remains unclear. However, all these children are nonambulatory with severe spasticity. When they developed a rather severe recurvatum deformity; they were not ambulating and the recurvatum did not seem to cause clinical problems.

Indications and Treatment

For rare children who present with either significant clinical varus or valgus deformity, there is usually a concomitant internal-external tibial torsion present, which was probably the initiating lesion. Surgical correction by proximal tibial osteotomy should include correction of the torsional deformity with the varus and valgus deformity. Because all the children we have seen with recurvatum were nonambulatory and maintained adequate knee flexion for seating, no treatment has been required.

Tibial Torsion

The common cause of tibial torsion in the normal population is intrauterine positioning in the last trimester of pregnancy⁴⁴ (Figure 11.10). Children with normal motor control usually slowly outgrow most abnormal torsion by age 8 to 10 years, and during the early and middle childhood years, these children may be somewhat more clumsy but otherwise function well. Surgical correction is only rarely required in normal children.⁴⁵ Children with spasticity are usually not at increased risk for developing tibial torsion in infancy; however, their limited motor control makes accommodation difficult and the bone does not receive the mechanical stimulus to correct malrotation with growth. Internal tibial torsion is most common; however, external tibial torsion also occurs.⁴⁴ External tibial torsion has been well recognized in normal children to be frequently combined with residual increased femoral



Case 11.6 Douglas

Douglas, a 15-year-old boy with spastic diplegia with normal cognition and who was a full community ambulator, presented with increased pain in the right knee. Over the past year, this pain got so severe at times that it limited his ability to go to school. He lived on a farm and was able to do almost all farm work. On physical examination he was noted to have internal rotation of 75° in the left hip and 60° in the right hip. External rotation was 10° in the left hip and 35° in the right hip. Hip abduction was 10° on the left and 25° on the right. Popliteal angles were 60° bilaterally with no knee flexion contracture. The left knee had normal varus-valgus alignment; however, the right knee had a definite significant valgus deformity. The external tibial torsion measured 50° external trans-

malleolar-to-thigh axis. The radiographs demonstrated a significant proximal tibial valgus deformity (Figure C11.6.1), which appeared to be due to a stress reaction in the proximal tibial growth plate, probably caused by the high stress from the external tibial torsion in a boy who was very active. He was reconstructed with a proximal tibial varus derotation osteotomy (Figure C11.6.2), and because of internal rotation of the femur on the left, he also had a femoral derotation of the left femur with mild added varus, which caused the left femur to shorten by 1.5 cm. This would equal the expected remaining growth from the right tibial epiphysis, which was fused during the osteotomy. After healing of the osteotomy he had complete resolution of his knee pain.

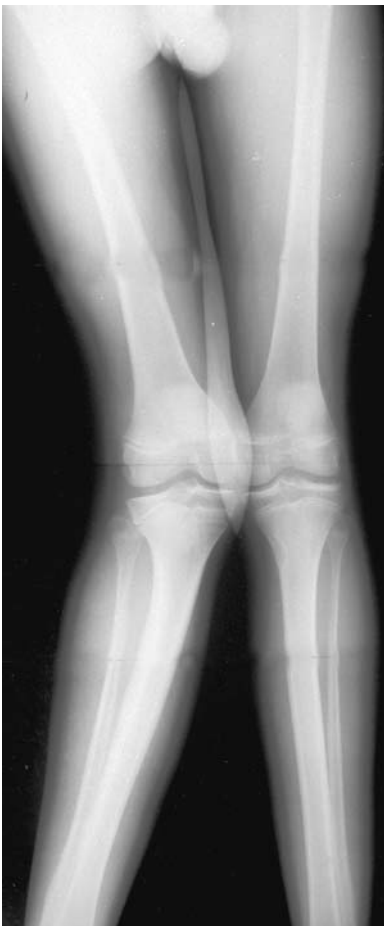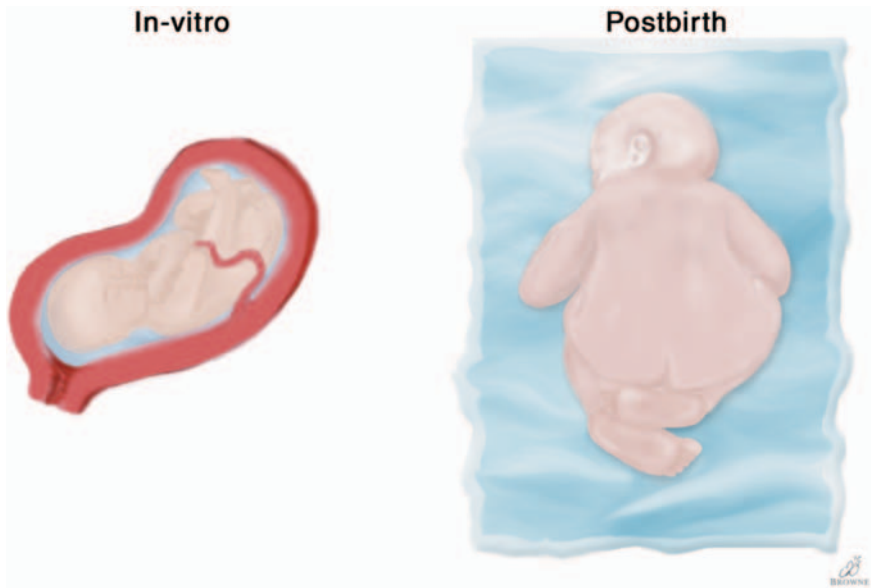


Figure C11.6.1

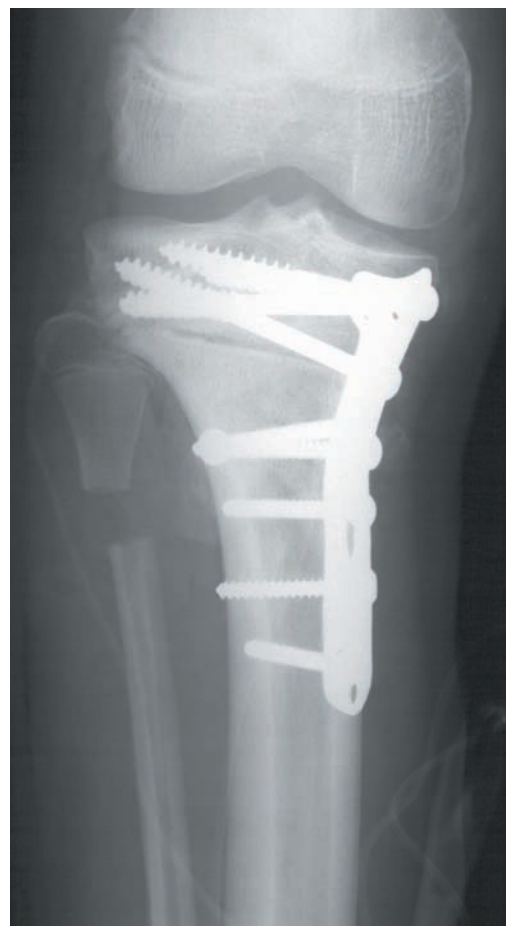

Figure C11.6.2

Figure 11.10. Torsional malalignments of the feet and tibias are often a residual of in utero positioning. This in utero positioning is even maintained by some infants. As an infant grows, the muscle forces help to direct the limb to grow in the anatomically correct alignment. For children with poor motor control or spasticity, this normal direction of the muscle forces is missing or even abnormal enough to direct the growth into more abnormal alignment. Therefore, many children with CP have persistent tibial torsion and variable foot malalignments.



anteversion leading to a knee joint malalignment with patellofemoral problems.⁴⁶ In this balanced deformity, the bones also do not receive the mechanical corrective force messages during growth. Although there are no substantiating data, children with CP do not appear to have a higher incidence of tibial torsion than normal children. However, there is a major difference in children with CP in that they do not correct tibial torsional deformities as well with growth and often have substantial disability from the tibial torsion requiring surgical correction.

Natural History

Children with CP who have significant torsional malalignment by age 5 to 7 years of more than 10° internal foot progression angle, or more than 40° of external foot progression angle secondary to tibial torsion, cannot be expected to have substantial improvement. Similarly to normal children by age 8 to 10 years, the remaining tibial torsion will not improve further with growth. In some children, tibial torsion seems to get worse if there are high torsional moments. For example, children with increasing planovalgus feet often slowly develop more external foot progression angle, some of which is coming from external torsion through the tibia. Part of this progressive external rotation may also be coming from the rotation through the knee joint, but it is hard to separate torsional knee joint subluxation from torsion through the tibial bone.

Diagnostic Evaluations

Measurement of tibial torsion is somewhat subjective, even with the use of CT scanning in which proximal and distal transverse cuts are made (Figure 11.11). In children, the proximal tibia is usually somewhat rounded, and the definition of a plane is ambiguous. Distally, the transmalleolar axis is the usual anatomical location chosen, but this may not completely represent tibial torsion, as it can be impacted by rotation of the fibula around the tibia, with torsion through the knee joint.⁴⁷ Use of ultrasound for measuring tibial torsion was reported to be a more specific measure as opposed to tibial

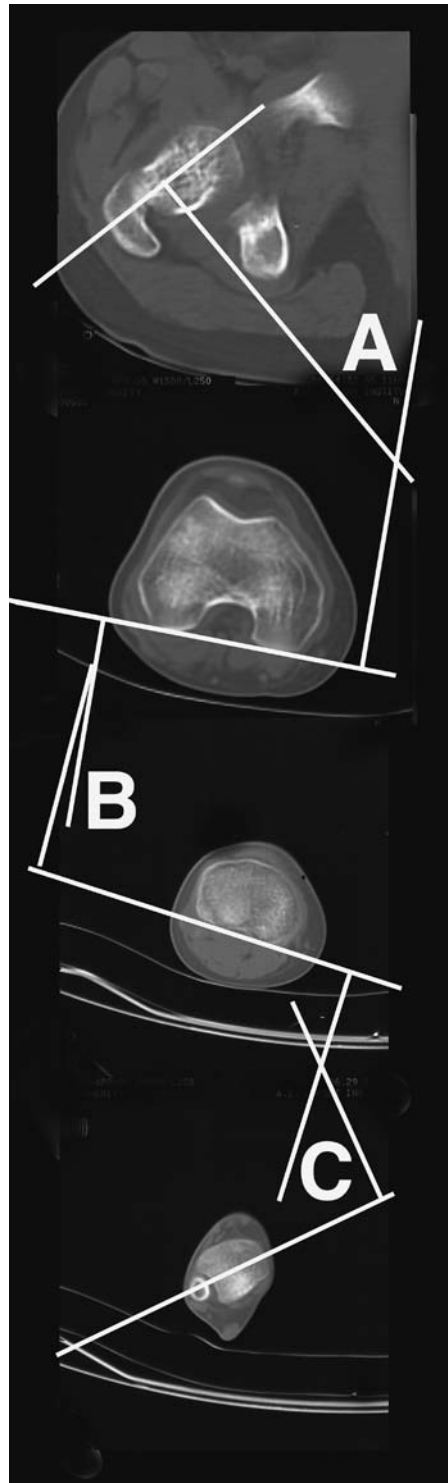
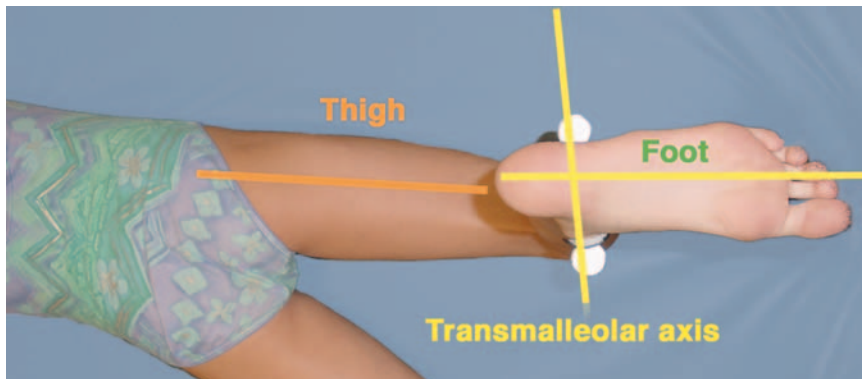


Figure 11.11. Measuring tibial torsion using CT scan can be incorporated as whole limb torsional assessment. This is an extension of the use of CT scan to measure femoral anteversion. The proximal cut in the tibia needs to be just distal to the knee joint in the plateau and the distal cut needs to be just proximal of the ankle in the plafond. The reference lines are the posterior femoral condyles, posterior border of the tibial plateau, and the center of the fibula and distal tibia. These cuts provide measurements of knee joint rotation (B) and tibial torsion (C), in addition to the femoral anteversion (A).

rotation around the fibula.⁴⁸ Physical examination measures of tibial torsion are usually defined by the transmalleolar axis-to-thigh angle with the knee flexed 90° (Figure 11.12). Tibial torsion is kinematically defined as torsion of the tibia, which is defined mathematically during kinematic evaluation as the rotation of the ankle joint axis to the knee joint axis.⁴⁹ Attention to the foot progression angle is important as well. With subtraction of pelvic

Figure 11.12. Assessment of the torsional alignment should include a measurement of the foot-to-thigh angle, best done with the child lying in the prone position. Attention should also be given to the transmalleolar thigh axis, which is the best measure of tibial torsion.



rotation, hip rotation, and foot-to-ankle rotation, the residual angle should represent tibial torsion.

Treatment

The only effective treatment for tibial torsion, either internal or external torsion, is tibial osteotomy. Tibial osteotomy is indicated for ambulatory children ages 5 to 7 years when the tibial torsion is causing substantial disability. Parents will note severe clumsiness with tripping and a clear malalignment of the foot. Some children may have a combination of femoral anteversion and tibial torsion, such that a 100° internal foot progression angle is present (Case 11.7). At this young age, more than 20° of internal foot progression angle caused by internal tibial torsion indicates the need for a derotational osteotomy. More than 40° of external tibial torsion indicates the need for derotation as well. Correction of more mild deformities should wait until the children are at least 8 to 10 years old because some of the mild deformities will correct enough with growth to not require operative correction. By adolescence, the foot progression angle should be 0° to 20° external. Alterations from this range, especially if they are unilateral, are cosmetically very noticeable. Malrotation outside this range is also mechanically impairing, with more deformity causing more impairment. There are no good studies of malrotation in children with CP; however, an evaluation in children with spina bifida found that external rotation greater than 20° caused



Case 11.7 Goutam



Goutam, a 4-year-old boy with normal cognitive function and spastic diplegia secondary to prematurity, presented because of difficulty with ambulation. He walked with a walker at age 2 years, and by age 3 years, he walked independently. Over the past year his parents and therapist felt he had made very little progress because his feet kept getting caught and would hit each other. On physical examination he had 90° of internal rotation of both hips and

20° of external rotation. Abduction was 35° bilaterally, popliteal angles were 65° bilaterally, knee flexed dorsiflexion was 15° , and knee extended dorsiflexion was 5° . Transmalleolar axis-to-thigh angles were 20° internally and foot-to-thigh angle was 35° internally. Observation of his gait showed an independent ambulator with good balance; however, he was toe walking with knee flexion and had severe in-toeing, which appeared to come from

both the hips and tibias. Kinematics showed high knee flexion at foot contact, plantar flexion, internal foot progression angle, internal rotation of the hips, and excessive pelvic rotation during walking. Because he had not progressed for 1 year even though he was only 4 years old, a reconstruction with bilateral femoral and tibial osteotomies and hamstring and gastrocnemius muscle lengthenings were performed. The tibial osteotomies were performed by the closed technique and treated with pins-in-plaster (Figure C11.7.1). The cast had a flat sole applied so he could start immediate gait training (Figures C11.7.2, C11.7.3). These flat rubber soles provide stability in stance and will not fall off the way cast shoes will. After 3 weeks, the proximal pins were removed through a cast window and he walked for another 4 weeks in the same casts. After the casts were removed, he made rapid progress and was independently ambulating by 3 months postoperatively, and by the end of the first year, was much more stable in his gait pattern. He only had tibial osteotomies to correct the rotational profile with excellent correction of the foot progression angle. On the left side the analysis shows that correction occurred at the hip; however, there is also a large change in the knee varus-valgus, which means the knee axis was not properly identified in the preoperative evaluation. Also note that there is excellent improvement in the power generation due to the rotational correction with tibial osteotomies and gastrocnemius lengthening. There is a major shift of power generation from the hip to the ankle due to these corrections. Note that kinetics were only obtained on the left on the preoperative evaluation (Figure C11.7.4).

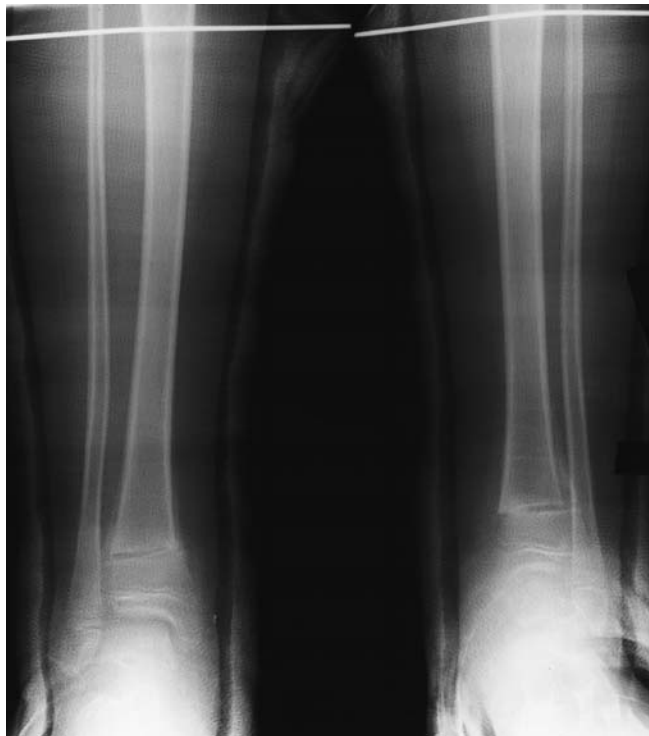

Figure C11.7.1

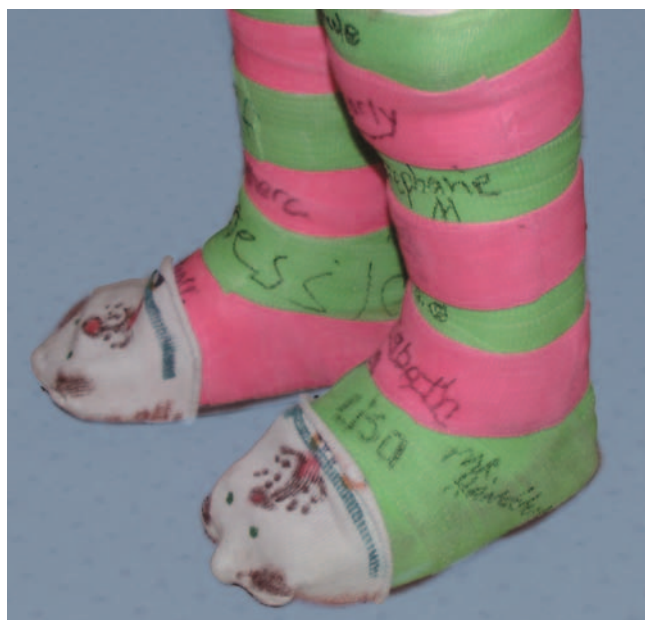

Figure C11.7.2

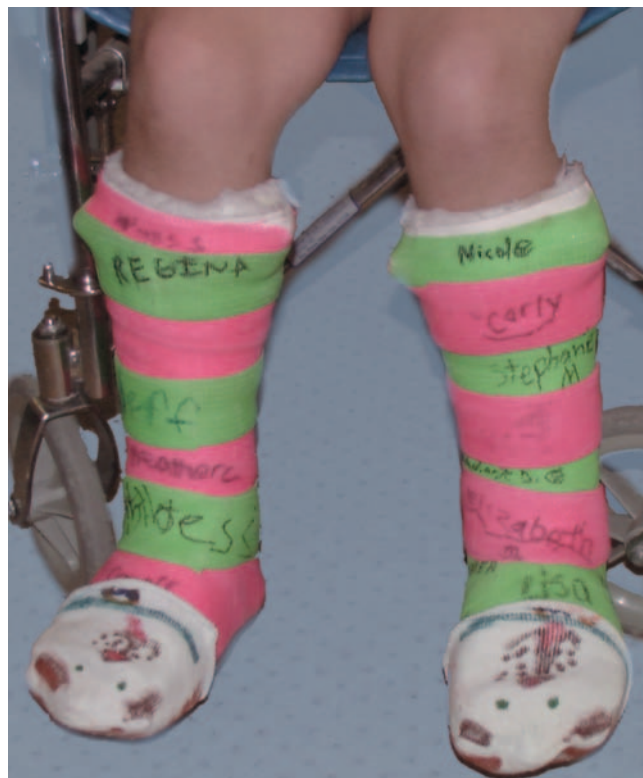

Figure C11.7.3

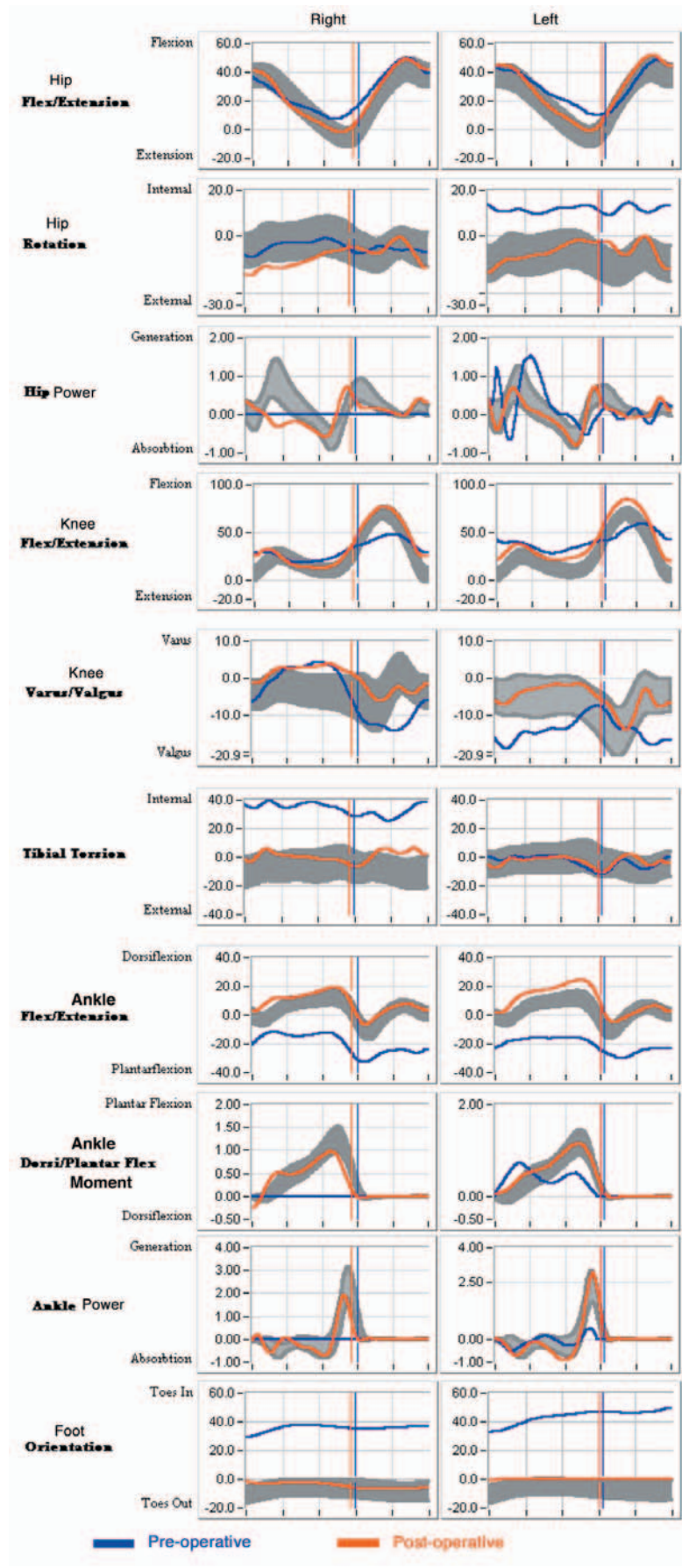


Figure C11.7.4

mechanical malalignment that made orthotic use inefficient.⁵⁰ As the mechanics are the same for weight bearing, this alignment is a good parameter to use for children with CP. Some children have torsional malalignments in several locations. For example, children may have increased femoral anteversion, internal tibial torsion, and equinovarus foot deformity. With combined femoral and tibial torsional malalignment, each deformity should be evaluated as to its own severity. If both deformities are thought to be clinically significant, both should be corrected to neutral rotation at the same time. If the equinovarus foot is involved, a decision has to be made about which is most significant. Tibialis anterior or tibialis posterior tendon surgery should not be combined with an external rotation osteotomy of the tibia, as this leads to a high rate of overcorrection. Usually, it is better to do the tibial osteotomy if both are involved. Tibial torsion may be corrected concurrent with planovalgus foot correction.

The operative procedure to correct tibial torsion in all individuals should be performed in the supramalleolar region because of decreased complications and excellent healing ability.^{49, 51–53} Only in those few individuals who need correction of knee varus or valgus at the proximal tibia should the derotation be performed proximally.⁵⁴ For children with an open distal tibial epiphysis, multiple percutaneous drillholes are used to make the osteotomy, which is then immobilized in a short-leg pins-in-plaster cast. If more than 30° of derotation is required, a similar fibular osteotomy is made 2 to 3 cm proximal to the tibial osteotomy. For individuals with closed growth plates, the osteotomy is fixed with an intermedullary rod and cross-locking screws.

Outcome of Tibial Osteotomy

The outcome of tibial osteotomy is very reliable with improved foot progression angle.⁵⁵ The only combination of procedures that is at high risk for overcorrection is the combination of posterior tibialis tendon surgery with correction of internal tibial torsion. Overcorrections requiring repeat surgery occurred in 8 of 15 limbs with this combination of procedures.⁵⁶ There are a few children who, over time, will develop a recurrent tibial torsion if the deformity was initially undercorrected, or develop an opposite deformity if it was initially overcorrected. These recurrent deformities of the tibia are usually related to increasing foot deformities, most commonly planovalgus deformity with an external foot progression angle. Typical children with recurrent deformity had a tibial osteotomy at age 5 years and, by adolescence, developed a severe planovalgus foot deformity that required surgical correction. By this time, they have developed a substantial external tibial torsion, which needs to be corrected again.

Other Treatments

There is no effective treatment for tibial torsion except tibial derotation osteotomy. Other techniques, such as an open osteotomy with internal fixation with plates,⁵² the use of crossed K-wires at the osteotomy site with a long-leg cast,^{45, 51} or using cast immobilization alone, have been reported.⁵⁷ The percutaneous osteotomy is quick and effective. The pins-and-plaster technique allows immediate full weight bearing with removal of the proximal pin 3 to 4 weeks postoperatively when there is enough callus to prevent derotation.

Complications

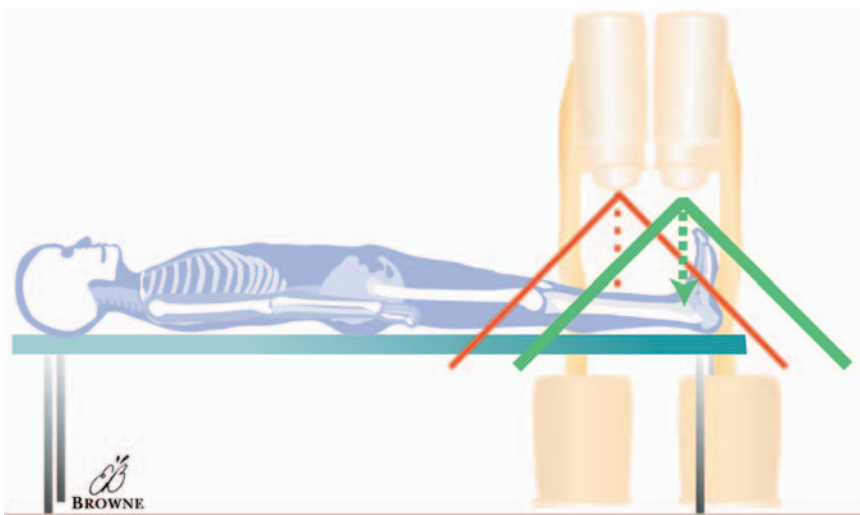
The complications of residual, or new, ankle varus or valgus malalignment have been reported to be higher when both the tibia and fibula are osteotomized, compared with a tibial osteotomy alone when only cast immobilization was used.⁵⁷ Nonunions of the tibia are rare; however, we have had

several delayed unions that required more than 6 months for healing. All these delayed unions occurred in adolescents with closed growth plates, which is the reason we have switched to using intermedullary rods in fully mature individuals. Compartment syndrome,⁵⁷ tibia to fibula cross-union, late fracture, and late epiphyseal closure⁵² are other reported complications. Wound infections and nerve paralysis are rare and have not occurred in our population.

Ankle Valgus

Valgus deformity of the ankle joint has been well recognized as part of the external rotation planovalgus collapse of the paralyzed foot most commonly seen in spina bifida.⁵⁸ This same association has been reported in spastic planovalgus feet^{59, 60} as an unrecognized contributor of hindfoot valgus. Also, there is a well-defined syndrome of increasing ankle valgus when a section of the fibula is resected for use as bone graft.⁶¹ Although the ankle valgus in spastic feet is not as profound as in the paralyzed foot of spina bifida, it is nevertheless significant in some children. The valgus of the ankle joint cannot be recognized if the appropriate radiographs are not obtained. Appropriate radiographs include an anteroposterior view of the ankle joint centered on the ankle (Figure 11.13). With the common addition of torsional deformities and the goal of wanting to see a radiograph of the whole tibia, very poor images of the ankle joint are often made. Ankle valgus has not been reported as an isolated lesion and is almost always associated as a secondary lesion of planovalgus, usually including external tibial torsion. Based on this association, the etiology of the ankle valgus is most likely due to eccentric loading of the ankle joint, causing a partial growth arrest of the lateral aspect of the ankle joint. This loading also causes the fibula to be shorter as part of the valgus ankle syndrome. Many valgus ankles in children with spasticity also seem to have a complex rotational malalignment of the talus in the ankle mortise, which has not been well defined. Usually, there is more dysplasia of the anterior lateral ankle mortise than the posterior aspect. This deformity makes the valgus worse in dorsiflexion and less significant with plantar flexion.

Figure 11.13. When planning corrections of foot deformities, especially planovalgus, it is important to obtain anteroposterior radiographs of the ankle mortise to rule out significant ankle valgus as a component of the deformity. The correct radiographic view is not often obtained, as there is a need to view the whole tibia; however, to obtain an accurate view of the alignment of the ankle mortise, the beam should be perpendicular to the ankle joint. If the positioning is such that the beams are very divergent at the ankle joint, accurate assessment of valgus is not possible.



Natural History

The natural history of ankle valgus in spastic feet is not defined. Based on our experience, the valgus gets worse during adolescent growth, then remains stable after the completion of growth. Correction of the deforming force by correcting the planovalgus foot and external and tibial torsion is not enough to cause spontaneous correction of the valgus ankle joint in children with growth remaining.

Diagnostic Evaluations

The correct radiographs are centered on the ankle joint with a long enough image of the tibia above to measure the long axis of the tibia. The rotational position of the ankle should be to produce an anteroposterior mortise view showing the profile of the talus.

Indications and Treatments

Because the ankle valgus is almost always a secondary deformity, there is no role for correction of only the ankle valgus. This correction should be part of a reconstruction of a whole problem, which usually includes the planovalgus foot, equinus ankle, and external tibial torsion. Indications for correction are more than 10° of ankle joint valgus relative to the long axis of the tibia. If the external tibial torsion is being corrected as well, no more than 5° of valgus should be tolerated at the ankle joint. If more valgus is present on the postoperative radiograph, the cast should be wedged to correct the deformity (Case 11.8). The presence of the ankle valgus must be recognized when correcting the hindfoot because it is important to avoid overcorrection of the hindfoot valgus. If no tibial derotation is required, then correction of the ankle valgus can usually be done with a screw epiphyseodesis of the medial malleolars if there is adequate growth remaining. The ankle has to be monitored with radiographs every 4 to 6 months, and when the valgus has corrected, the screw should be removed (Case 11.9). For individuals with a closed growth plate, up to 15° of valgus can be accepted if the foot is corrected close to a neutral position below the ankle. This residual ankle valgus causes the foot to fall into external rotation and valgus with increased dorsiflexion, but tends to be less of a problem in individuals who are dependent on orthotics for ankle stability. Having the ankle valgus corrected is more important in individuals who are high-functioning community ambulators without orthotics or assistive devices.

Outcome of Treatment

There are no reports of the outcome of treating valgus deformity in spastic feet. Our experience has been that it is important not to overcorrect the deformity because a little valgus is better tolerated than a little varus. Also, there does not seem to be much loss of correction, although we have not had enough children corrected by the screw epiphyseodesis who have completed growth to be confident of this fact. A stable correction has been reported in several series with a wide variety of other diagnoses.^{62–64}

Complications of Treatment

Following screw epiphyseodesis, there have been no reports of premature growth arrests after the screws were removed.^{62–64} No significant complications have been reported and our only complication from correction of



Case 11.8 Lindsey

Lindsey, a 10-year-old girl with moderate diplegia, developed a significant internal tibial torsion, which was cosmetically objectionable to her. She and her family desired this to be corrected with a tibial osteotomy. A percutaneous osteotomy was performed with the application of a short-leg cast and a proximal tibial pin. The radiograph in the operating room showed a significant valgus deformity of the ankle (Figure C11.8.1), so the cast was wedged while she was still under anesthesia to get her ankle to neutral alignment (Figure C11.8.2). In general, a little valgus is better than varus because the subtalar joint can accommodate the valgus better; however, significant val-

gus may place an external rotation valgus moment on the foot causing progressive valgus collapse of the foot. The goal should be to have 0° to 5° of valgus at the ankle joint. If after the cast is applied and there is more than 10° of valgus or more than 5° of varus, the cast should be wedged and the angulation corrected. The technique for doing the wedge is to make two lines down the middle of the fragments to be aligned, and this intersection level (Figure C11.8.3A) is the level at which the cast wedge is to be placed. The triangle (Figure C11.8.3B) defines the size of the angular correction that needs to be made. This technique will correct both displacement and angulation. Also, by measuring the width of the cast on the X-ray at level A (Figure C11.8.3A) you can next measure the same distance from the apex on the triangle B (Figure C11.8.3B) and at this location the width of the open wedge can be measured. This method allows precutting of a block to hold open the wedge.

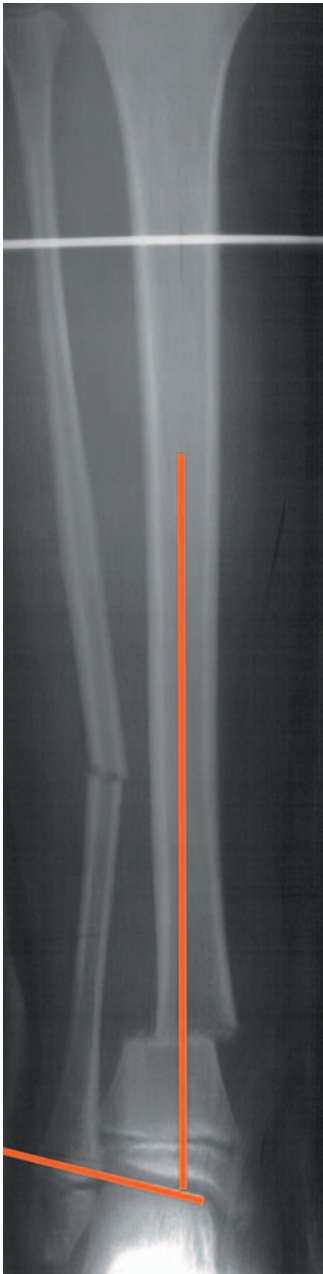

Figure C11.8.1

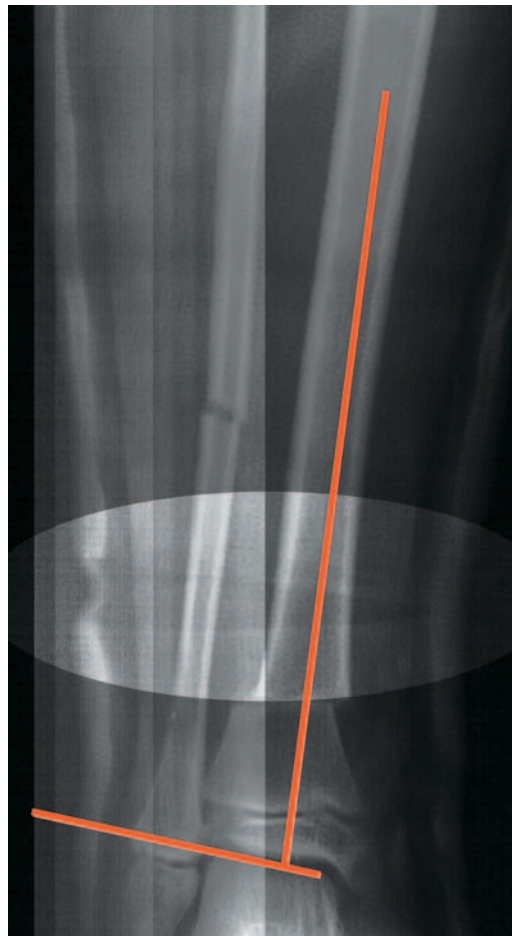

Figure C11.8.2

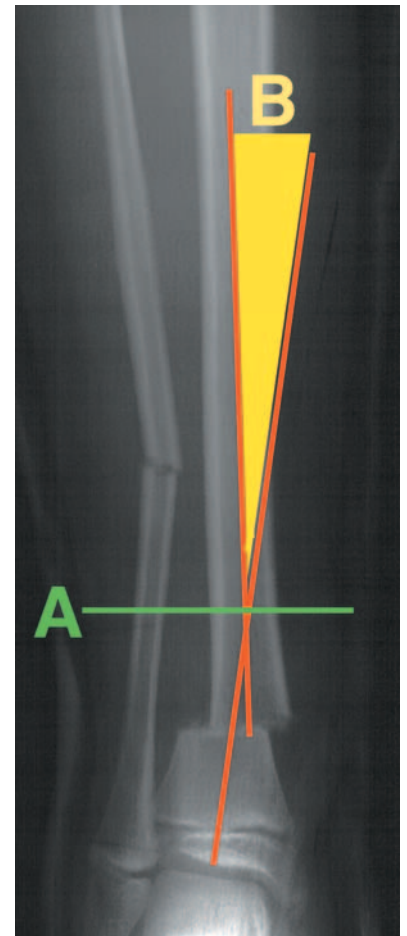


Figure C11.8.3



Case 11.9 Kenneth

Kenneth, a 16-year-old boy with significant growth delay and hypotonia, was evaluated with severe planovalgus foot deformities. He had problems tolerating his AFO. On physical examination, he was hypotonic but could walk without assistance. He had severe planovalgus feet but no muscle contractures. In the operating room his feet were reduced to normal position and fixed with a subtalar fusion, but he still tended to fall into valgus with simulated weight bearing. Under fluoroscopy, he was thought to have mild instability of the ankle joint and approximately

10° to 15° of ankle valgus, but he had no torsional malalignment. He had significant amount of growth remaining so a medial malleolar epiphyseodesis screw was placed (Figure C11.9.1). He was then monitored carefully, and by the 24-month follow-up, he had acquired approximately 20° of correction, (Figure C11.9.2), which could be monitored as well by the presence of a faint growth arrest line (Figure C11.9.3). The screw was then removed when he had slight overcorrection and the foot appeared in a good position.

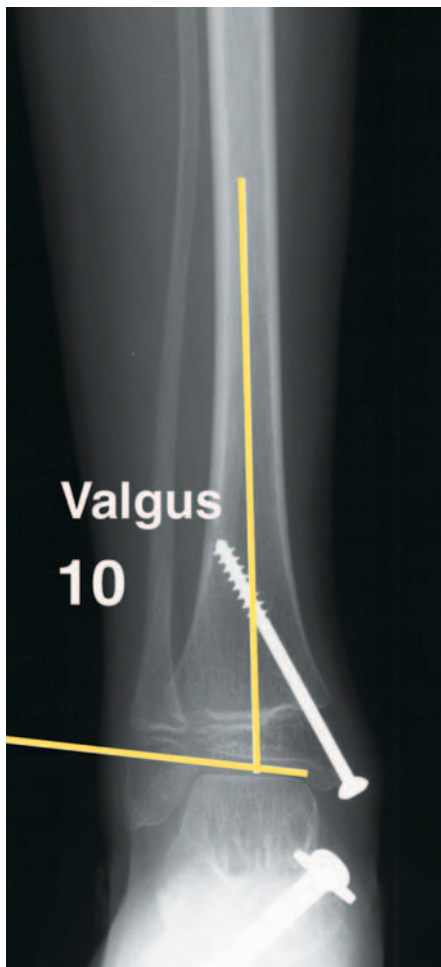


Figure C11.9.1

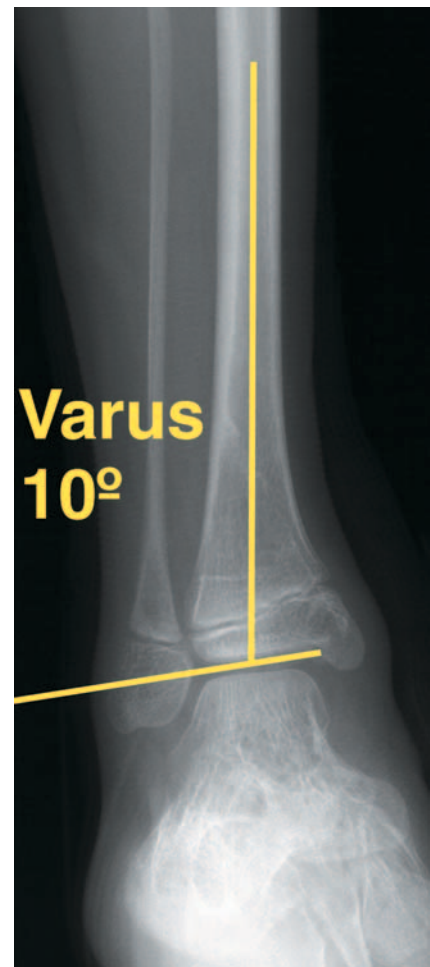

Figure C11.9.2

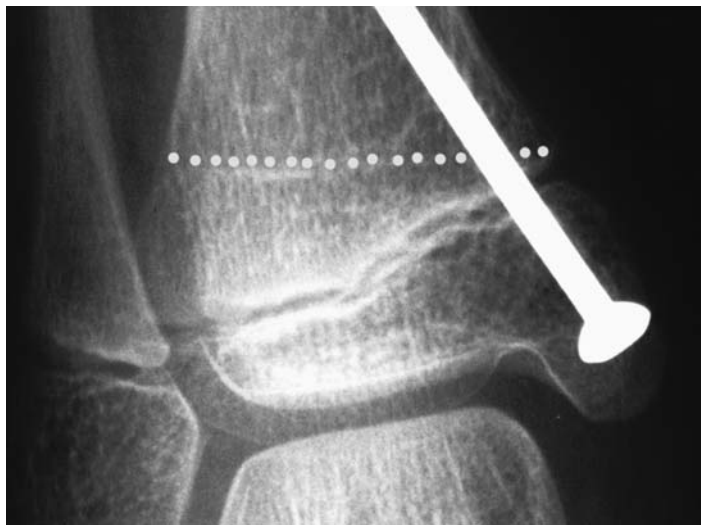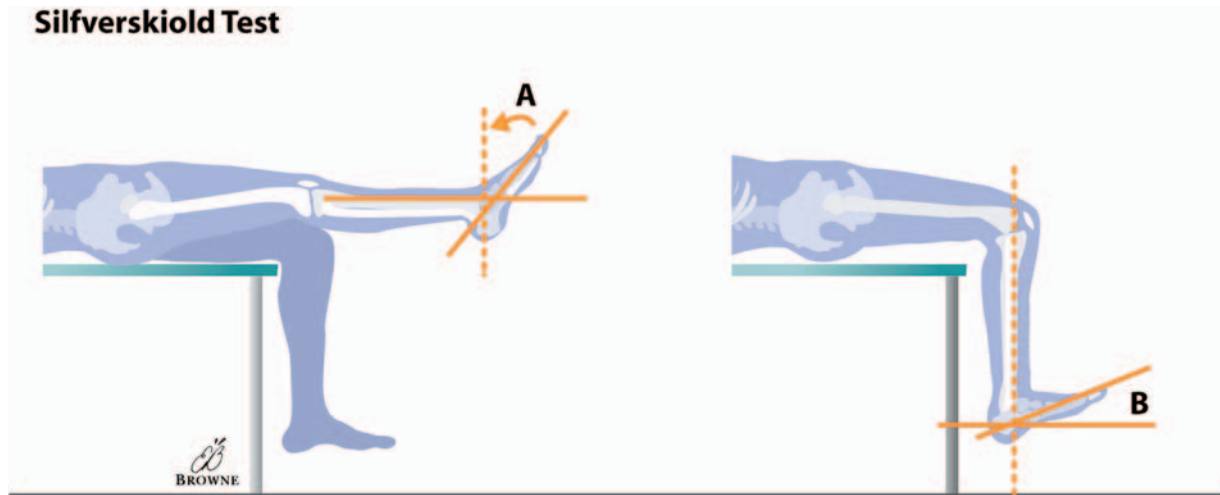


Figure C11.9.3

ankle valgus was mild overcorrection, leaving this individual with a mild varus foot position.

Equinus

As noted previously, ankle equinus was the first deformity of individuals with spastic CP that gained the attention of surgeons, namely Dr. Strohmeyer. Dr. Strohmeyer's tenotomy of the tendon Achilles, and the promotion of this operation by Dr. Little, marked the beginning of modern medical and surgical management of CP.¹ Tenotomy of the Achilles tendon was the primary practice until early in the 1900s when Silfverskiöld⁶⁵ described the test named for him, along with the procedure of proximal gastrocnemius release from the femoral condyles. The concept of the difference between contractures of the gastrocnemius and the soleus was considered very important in the middle half of the 1900s, as defined by the Silfverskiöld test (Figure 11.14). This understanding spawned the development of gastrocnemius neurectomies and many different procedures to differentially lengthen the gastrocnemius versus soleus at the level where the gastrocnemius and soleus tendons join. Procedures were described by Vulpius in 1913 and 1920, by Strayer in 1950 and 1958, and by Baker in 1954 and 1956.²³ As more advanced gait studies were initiated in the 1970s, the initial focus on EMG interpretations to understand gait found very little difference in the activation patterns between the gastrocnemius and soleus; therefore, the focus of the contracture difference between gastrocnemius and soleus was believed to be of little importance.⁶⁶ This belief led to a period in the 1970s and 1980s when the significance of the difference between contractures of the gastrocnemius and soleus, as measured by the Silfverskiöld test on physical examination, was believed to have little importance. However, by the late 1980s and 1990s, with the widespread use of improved kinematics and kinetic measures, the significant difference in the contracture patterns of the gastrocnemius and soleus was again recognized, even though there is minimal difference in the muscle activation times. This historical context is important in interpreting the various discussions at meetings and in published papers of the subject



of equinus ankle contractures in spastic children. This discussion now focuses on the current understanding of the problem of equinus in children with spastic CP.

Etiology

Equinus ankle position in children with CP is caused by spasticity and the secondary and tertiary deformities produced by the spasticity. The primary reason spastic ankles develop equinus is because the plantar flexor of the ankle is five to six times stronger than the dorsiflexor (Figure 11.15). Therefore, if all muscles are equally spastic, the plantar flexors always overpower the dorsiflexors in all positions of the ankle joint. Overpowering of the dorsiflexors by plantar flexors is the predominant cause of equinus in children with total body spasticity. In children with ambulatory ability, the equinus usually is also due to increased stretch reflex as part of the spasticity. During weight acceptance and middle stance, the gastrocnemius normally is an eccentric contraction, which then changes in terminal stance to a strong concentric contraction. During this period in weight acceptance in middle stance, it

Figure 11.14. A very important physical examination test to obtain at the ankle is to determine the difference in the lengths between the gastrocnemius and the soleus muscles using the maneuver described by Silfverskiöld. Gastrocnemius length is assessed by recording the degree of passive dorsiflexion with the knee extended (A), and soleus length is assessed by measuring passive dorsiflexion with the knee flexed (B). In many children with CP there is a substantial difference; however, there is little difference in normal individuals.

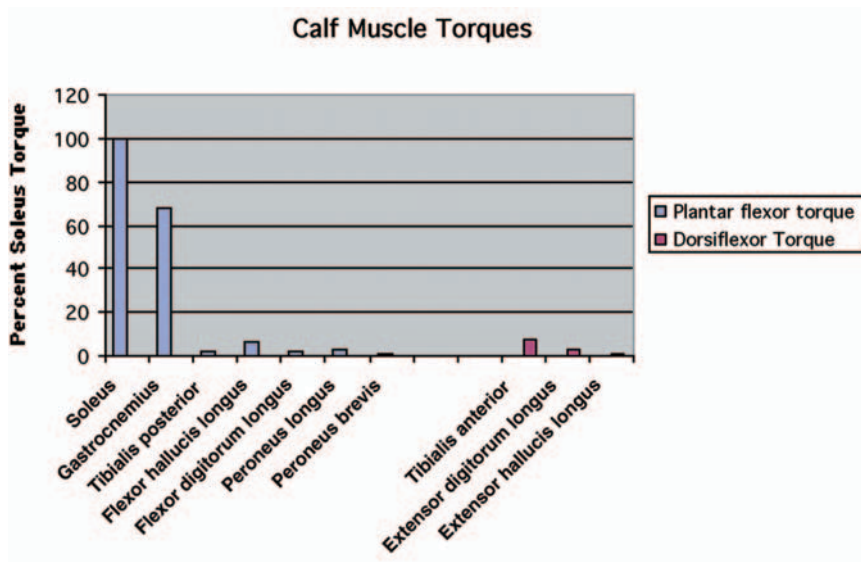


Figure 11.15. By using the cross-sectional area of the muscles, maximum torque can be calculated. By using the soleus, which is the largest muscle, as 100%, all the remaining muscles except the gastrocnemius are very small. There is no way to balance the muscles of the calf.² This also shows why, in the face of spasticity, equinus almost always predominates.

is especially difficult to avoid the stretch reflex, which initiates a premature concentric contraction. For children who have initial contact with toe strike, avoiding the stretch reflex is even more difficult. This toe strike in initial contact serves as an acute stretch reflex response to cause an equinus jerk, which is seen best on the vertical force vector of the ground reaction force.

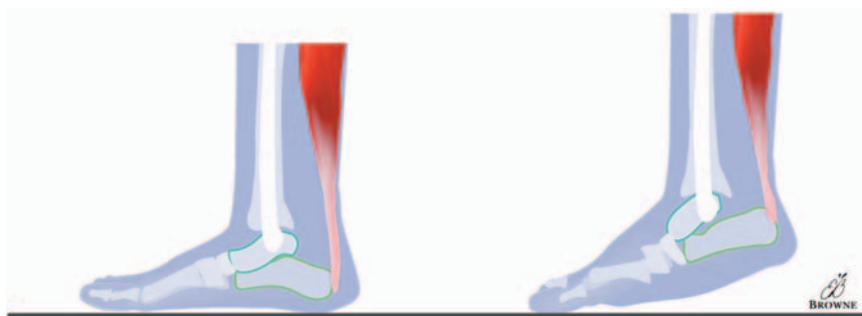
Secondary Pathology

As with all muscles, spasticity prevents normal growth and therefore muscle contractures develop. Secondary causes of equinus positioning are due to these contractures. Using the Silfverskiold test, the difference in the contractures between gastrocnemius and soleus can be measured easily. For reasons that are not well understood, children with diplegia and quadriplegia tend to have large discrepancies with much more contracture developing in the gastrocnemius than the soleus. Children with hemiplegia tend to have much more symmetric contraction patterns between the gastrocnemius and the soleus. These symmetric contraction patterns may be due to diplegia causing more knee flexion when sitting and lying, whereas type 2 hemiplegia allows a more normal position of the knee joint. However, there is significant variation and some children with hemiplegia, especially types 3 and 4, also have a significant discrepancy in contractures between these two muscles. For children who ambulate, the increased equinus brought on by the contracture is often perceived as very strong plantar flexion. This equinus is strong from the mechanical sense of being able to bear a large load; however, the ability of the muscle to input active power in the equinus position is very poor. Another analogy is an ankle fused in equinus, which is also a very strong ankle, but it cannot provide any power input for ambulation or jumping.

Tertiary Changes

When ankle equinus is due to a significant contracture, there is little ability to absorb power or energy, and all the weight is borne on the toes or the forefoot, placing a large stress on the middle and hindfoot. As these children gain weight, especially in late childhood and adolescence, the foot can no longer bear the weight and tends to collapse. The most common collapse pattern is into planovalgus; however, a few children collapse into a varus deformity (Figure 11.16). Again, children with diplegia have a very strong attractor to planovalgus collapse, and children with hemiplegia have a strong attractor to varus collapse. Children with total body involvement may collapse in either direction; however, planovalgus is a stronger attractor, especially for children who do some weight bearing. Another tertiary effect of equinus is increasing knee flexion in stance phase. As children are forced to weight bear on the forefoot or toes, there is either a large knee extension moment created driv-

Figure 11.16. A contracture of the major ankle plantar flexors is commonly associated with planovalgus foot deformity. The planovalgus allows apparent dorsiflexion for several reasons. First, the calcaneus moves posterior, rotates externally, and tilts into valgus. This move allows the insertion of the Achilles tendon to move proximally because it is inserted at the distal end of the calcaneal tuberosity. Second, the calcaneus remains in equinus relative to the tibia although it is in dorsiflexion relative to the talus. Third, the talus falls into severe equinus, causing a decrease in the height of the talus, thereby effectively moving the calcaneus proximally. Fourth, there is usually some break in the midfoot causing dorsiflexion to occur in the midfoot. Even if the plantar flexors do not appear contracted, the gastrocnemius is almost always significantly tighter after a complete correction of the planovalgus. After the planovalgus correction, careful assessment of the length is important intraoperatively to determine if concurrent tendon lengthening may be indicated.



ing the knee into back-kneeing, or the body accommodates by flexing the knee so the moment at the knee is in extension or very mild flexion. The equinus ankle position forces the knee into either the back-knee or the flexed knee position. Diplegia is strongly drawn to the flexed knee attractor and produces the commonly seen crouched gait pattern. Hemiplegia tends to have a stronger attractor to back-kneeing. Another tertiary effect of equinus is progressive external foot progression angle caused by a combination of planovalgus and external tibial torsion. By initiating the external foot progression angle through planovalgus and external tibial torsion, the contracted equinus provides a strong moment arm, which tends to further increase the external foot progression angle.

Natural History

The natural history of equinus is very consistent, being similar in all patterns of involvement. In early childhood, at age 18 to 24 months, children start to have a definite tendency for sitting with equinus and standing with equinus. Until age 4 to 7 years, this equinus tends to be predominantly dynamic with no fixed muscle contractures. As these children approach middle childhood, by 6 to 7 years of age, fixed equinus contractures have developed, predominantly of the gastrocnemius in diplegia and quadriplegia. Hemiplegia more commonly presents with gastrocnemius and soleus contractures. In middle childhood, these fixed muscle contractures usually get worse, and the tertiary deformities start to become the predominating problems. By adolescence, crouched gait is the primary pattern in diplegia; however, in hemiplegia, equinovarus foot position with back-kneeing is more common.

Diagnostic Evaluations

The primary method of monitoring equinus in children with CP is by physical examination. This examination should include a record of the ankle dorsiflexion with knee flexion to measure the length of the soleus and of the ankle dorsiflexion with the knee extended to measure the length of the gastrocnemius. Attempts should be made to measure the length of the soleus and gastrocnemius without initiating the spasticity, which means trying to have the children relaxed and moving the ankle slowly. This test should always be done under anesthesia before any planned surgery so the real difference in muscle length can be easily recognized. For ambulatory children, monitoring the amount and timing of dorsiflexion in stance phase is important. Few children with a significant amount of spasticity will have a first rocker; however, if one is seen, it is a very good sign for gaining excellent ankle function. During second rocker, the dorsiflexion should slowly increase until terminal stance when there is plantar flexion push-off. If the dorsiflexion maximum occurs very early, and the plantar flexion starts in middle stance, or even during weight acceptance, ankle function is very compromised. The gastrocnemius EMG should be bimodal; however, most children with spasticity have a unimodal pattern, which probably means there is a significant decrease in motor control available to transition between the eccentric and the concentric contraction patterns. Also, a high plantar flexion moment in middle stance phase, sometimes of equal magnitude to the push-off burst, usually means that the ankle is very stiff and eccentric contraction is probably not occurring. Power in these ankles usually demonstrates early stance high absorption followed by a midstance generation burst. This midstance generation power burst is the cause of vaulting, or lifting the center of mass of the whole body. The premature plantar flexion almost always reduces push-off

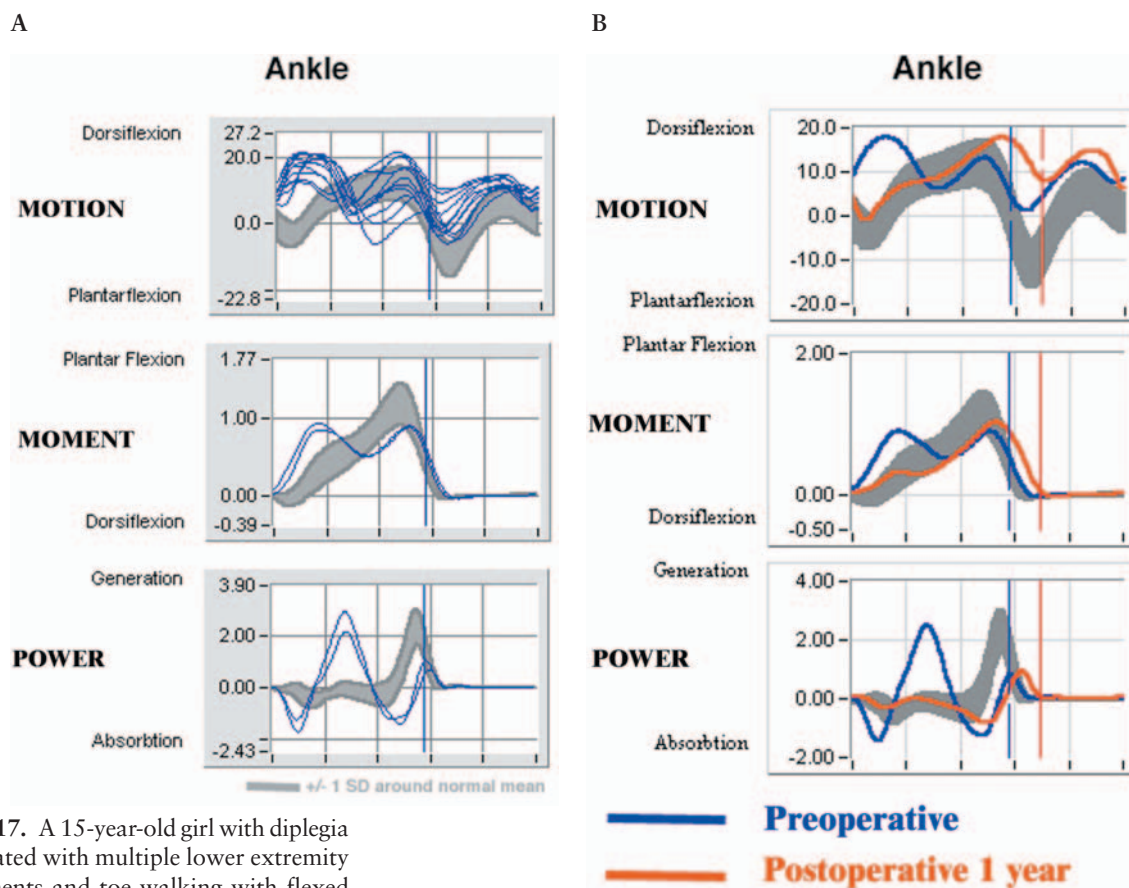


Figure 11.17. A 15-year-old girl with diplegia was evaluated with multiple lower extremity malalignments and toe walking with flexed knees. She had some variability of gait indicating instability in stance; however, she had the same consistent pattern on ankle dorsiflexion early in stance, followed by a premature plantar flexion but a second dorsiflexion cycle before push-off. The ankle moment showed the early plantar flexion movement and the power curve showed the high power generation of the early stance phase vault (A). This girl had a spastic gastrocnemius and had -15° of dorsiflexion with the knee extended but 5° with the knee flexed, indicating a large difference between the gastrocnemius and soleus muscle lengths. After a gastrocnemius lengthening, the early stance phase vault completely disappeared. All the vaulting power generation also disappeared, and the push-off power generation was maintained although no significant increase in push-off power generation developed (B).

power burst because of poor prepositioning of the ankle to generate the power burst for significant additional plantar flexion (Figure 11.17).

Attempts to separate the differences in toe walking by normal children versus children with diplegia have demonstrated only minor kinematic and kinetic differences.⁶⁷ Similarly, comparing toe walking in children with mild diplegia and idiopathic toe walkers found only mild differences.⁶⁸ Electromyographic patterns of idiopathic toe walking are not much different from those of children with diplegic toe walking.⁶⁹ Our unpublished data suggest that the most reliable difference in obligatory toe walking due to either a fixed contracture in CP or idiopathic toe walking is the absolute consistency of the ankle moment. Children with contractures are much more consistent, whereas the compensatory toe walkers, or voluntary toe walkers, demonstrate a significant amount of variation in ankle moment, often in the face of little kinematic variation.

Treatment

The approach to treating ankle equinus must always keep in the forefront that the gastrocnemius and soleus muscles are the most important muscles of ambulation. Individuals with no functioning gastrocnemius or soleus cannot stand without external support and have very little ability to walk. On the other hand, individuals with a contracted, overactive gastrocnemius or soleus have to make many adaptations to walk, but functional ambulation is possible until the tertiary deformities become too severe. Our goal in the treatment of ankle equinus is to optimize function of the whole child for

both standing and walking, with a long-term view of understanding this function throughout a lifetime.

Indications and Treatments

As children start to stand during the development of functional ambulation, or start to stand in a stander, external control of the ankle by the use of a solid-ankle AFO usually assists them by providing a stable base of support. As the children grow and ambulation ability increases, ankle equinus may often be managed with articulating AFOs, which allow dorsiflexion but limit plantar flexion. These orthotics should be custom molded and control the equinus, not cover it up (Figure 11.18). If the children's spasticity is so severe that AFOs cannot be tolerated, and a fixed contracture that prevents ankle dorsiflexion to neutral with both knees extended and knees flexed has not developed, an injection of botulinum toxin is given. The botulinum toxin injection may be repeated in 4 months for several cycles if it produces beneficial effects and the children can tolerate the AFOs. When the gastrocnemius develops a contracture that no longer allows the ankle to dorsiflex to neutral with the knee extended, full analysis of the gait is indicated. This contracture most commonly occurs around age 5 to 7 years, but occasionally occurs as young as age 3 years. Based on the full analysis and determination of all the abnormalities, surgical lengthening is performed. If children have contractures

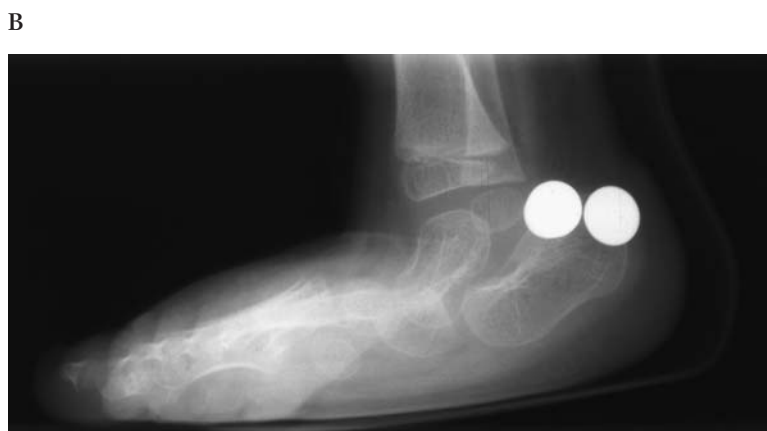
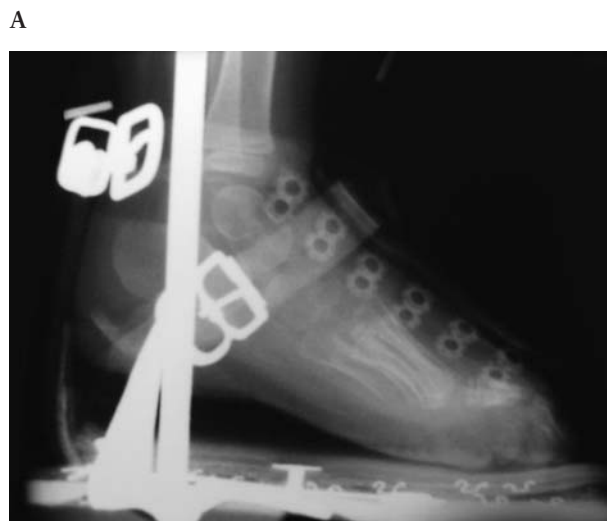
Figure 11.18. The application of orthotics can produce correction of the equinus or cover up the equinus. An example is this 3-year-old boy who was placed in old-style orthopaedic shoes with metal braces because they provided better tolerated correction according to his physical therapist. The radiograph clearly shows that the shoes were better tolerated because they covered up the equinus and did not correct the deformity (A). A radiograph of the foot of a child with severe planovalgus who was believed to be well corrected in the orthotic also shows that the planovalgus had minimal real correction (B, *cal*). Correction can only be expected in very supple deformities. Orthotics may still be of benefit in providing stance stability even if the underlying deformity is not corrected.



Figure 11.19. Lengthening of the gastrocnemius through a short posteromedial incision leaves a scar that has a very low cosmetic concern. Long scars in the middle of the calf should be avoided, especially in girls where the scar will remain very evident.

of both the gastrocnemius and soleus, a tendon Achilles lengthening using an open Z-lengthening is usually performed. If only the gastrocnemius requires lengthening, a recession of the gastrocnemius muscle is performed. This recession is performed by doing a lengthening of the musculotendinous junction (Figure 11.19). If only a small lengthening is required, a more proximal fascial incision is often made. If there is significant contracture of the gastrocnemius, meaning dorsiflexion is less than -10° , the whole tendon of the gastrocnemius is cut free from the soleus. If there is a mild additional soleus contracture, meaning $\pm 5^\circ$ of dorsiflexion, a lengthening is done more distally, where the gastrocnemius and soleus tendons are conjoined.

Postoperative care requires immobilization for 4 weeks in a walking cast, or ankle orthotics worn 24 hours per day. If Z-lengthening was done, a cast is always used with immobilization being in neutral; however, if only the gastrocnemius is lengthened, the ankle is immobilized in 10° of dorsiflexion. Knee immobilizers are used at night to keep the knee extended if children have a tendency to lie in bed with the knees flexed. Walking in a cast fitted with a flat sole is encouraged. After the cast or acute postoperative orthotic is removed, children are encouraged to work with physical therapists to develop a heel-toe gait and work on strengthening the gastrocnemius and soleus muscles. If, after 1 month, the children have a significant foot drop with persistent toe strike, are still toe walking, or are walking with increased knee flexion in midstance, an orthotic is prescribed for weight bearing during the day when most of the ambulation occurs.

Outcome of Treatment

The outcome goal of treatment is to have an ankle that functions in the optimal physiologic range, meaning approximately 10° of dorsiflexion to 20° to 30° of plantar flexion. The midstance phase plantar flexion moment should be reduced to normal, and the midstance phase power burst should be reduced or eliminated. Push-off power at the end of stance should be increased. The kinematics should move toward normalization of dorsiflexion, especially with the dorsiflexion peak being in late stance not early stance, and hopefully the development of a first rocker. This goal should be accomplished by the end of the 6- to 12-month rehabilitation period following tendon lengthening. As children grow, depending on their weight and ambulatory ability, the contracture may recur. These children need to be monitored for recurrence until growth has completed.

There are few good outcome reports, although one study compared gastrocnemius fascial recession with open Z-lengthening of the tendon Achilles and found no definite difference, although the groups were not completely similar.⁷⁰ Excellent improvement was found in both groups. Good response in decreasing midstance plantar flexion moment has been reported secondary to gastrocnemius fascial lengthening.⁷¹ Recurrence rates after gastrocnemius lengthening in young children vary widely in different reports, but based on our current experience, this recurrence is probably 25% to 40% over the children's growth time.

Other Treatment

There are many other techniques described for lengthening the tendon Achilles; however, the only technique that has a confirmed impact on lengthening the muscle tendon unit for at least a moderate time of several years is surgical lengthening. There are many surgical lengthenings described to accomplish this goal, from the Strohmeyer tenotomy to the proximal resection of Silfvers-

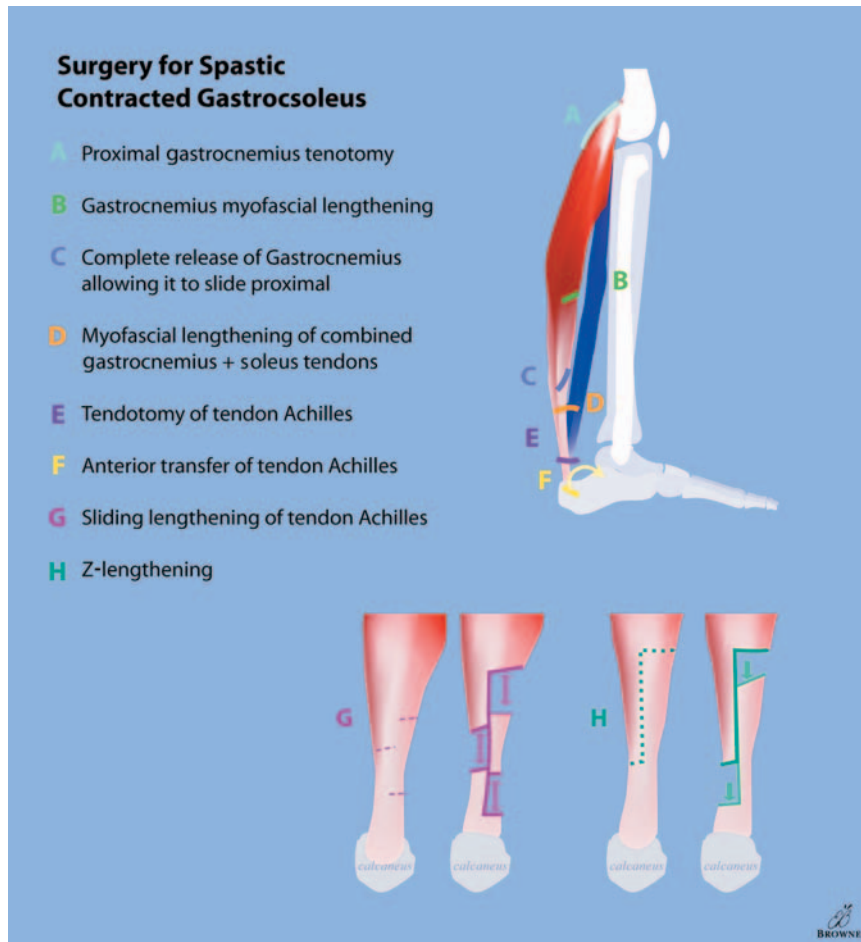


Figure 11.20. Options for addressing equinus contractures include tenotomy or myofascial recession of the proximal gastrocnemius tendons (A), myofascial lengthening of the distal gastrocnemius tendon (B), complete release of the distal gastrocnemius tendon from the underlying soleus tendon and allowing it to retract proximally and reattach itself (C), myofascial lengthening of the combined gastrocnemius tendon (D), tenotomy of the tendon Achilles (E), anterior transfer of the distal insertion of the tendon Achilles (F), percutaneous or open sliding lengthening of the tendon Achilles (G), open Z-lengthening of the tendon Achilles (H), and neurectomy of the gastrocnemius.

kiold, to various percutaneous partial and sliding tenotomies (Figure 11.20). There is very little recent enthusiasm for the complete Achilles tenotomy or proximal recession. There are many papers describing the sliding techniques originally described by White in 1943 and Hoke in 1953.⁷² The original investigators' primary focus was mainly on the recurrence rate.^{73–75} Most papers recognized the problem of overcorrection, but the focus tended to be on reducing recurrence rates. The rates of overlengthening with these procedures were reported as 3% in one series,⁷³ but were largely unreported, probably because most papers were not very concerned with the gait function.

Also, during the midpart of the 1900s, neurectomy of the gastrocnemius was popular as a way of decreasing the spasticity of the muscle. Recently, neurectomy has been reported again and has been found to decrease toe walking when there is no fixed contracture, although no assessment of gait was reported.⁷⁶ The problem with neurectomy is that it will not be permanent because either the muscle fibers that have been denervated will atrophy and there will be further weakening of an already weak muscle, or the muscle fibers will be reinnervated by another motor neuron, thereby increasing the size of the motor unit, further decreasing variable motor control ability. Neither the theoretical advantages nor the historical experience suggests that gastrocnemius neurectomy is a viable modern treatment option.

Another surgical technique is anterior transposition of the Achilles tendon from the calcaneal tuberosity to the area on the calcaneus just posterior to the ankle joint. This procedure was originally described by Murphy

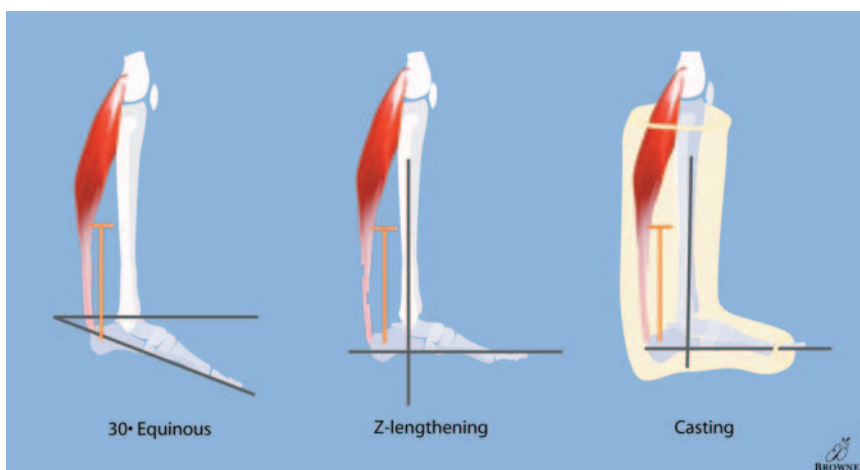
in 1974,⁷⁷ and a report of a large series suggested a good outcome; however, there was no real evaluation of the patients.⁷⁸ These procedures suggest that increased ankle range of motion could be obtained by shortening the moment arm, which is theoretically an accurate mechanical deduction. By shortening the ankle moment arm, the magnitude of the ankle moment is decreased. Because the spastic muscle is already weak, as defined by the decreased cross-sectional area, this anterior transfer of the insertion further weakens the muscle mechanically. Also, by shortening the moment arm and increasing the magnitude of motion at the ankle joint produced by a given increment of muscle contraction, more delicate control of the muscle is required. Because there are no scientific data available from gait studies and the theoretical function of this procedure is suspect, it is not recommended.

Many studies evaluate biofeedback techniques to improve functional dorsiflexion during ambulation on the basis of many children not having fixed contractures but still being toe walkers. Also, the use of neuromuscular stimulation on dorsiflexors has been attempted to improve dorsiflexion. Positive results are reported in a few children in whom biofeedback has been tried⁷⁹; however, there is no long-term carryover after the intervention has ceased. Range-of-motion exercises are routinely used, but there are few or no data to document their effectiveness. For young children, passive range of motion is a reasonable option, but as they get close to adult size, it is no longer possible to do passive range-of-motion stretching effectively because of the strength of the gastrocnemius and soleus and the small lever arm afforded by the foot. One study has reported that stretching is easier if the calf is warmed to 40°C before the passive stretching occurs.⁸⁰

By early treatment of spasticity with procedures such as rhizotomy, some feel the need for surgery on the plantar flexors would be reduced. This concept makes theoretical sense; however, there are no supportive data.⁸¹ Unless there are other substantial benefits from dorsal rhizotomy, justifying rhizotomy to treat ankle equinus is difficult because even two separate surgeries to lengthen the gastrocnemius or soleus would be much simpler, cheaper, and have fewer complications than one dorsal rhizotomy.

There has been widespread use of casting to reduce equinus in children with CP. Casting has had periods of enthusiastic promotion; however, no study has demonstrated any long-term benefit. Because casting is simple and cheap, it is still promoted by some⁸² (Figure 11.21). Recently, there has been an increased interest in combining the use of cast immobilization with botulinum toxin injections because both are recognized to relapse quickly.^{83, 84} There

Figure 11.21. There has been a debate of the relative merits of repeated casting to treat equinus contractures of the ankle. This is often presented as the low-risk approach; however, the impact of casting is significant muscle atrophy and therefore creation of a small muscle mass. The tension of casting has never shown that it adds muscle fiber length, but if it does, it also adds tendon length. The impact of surgical tendon lengthening is a longer tendon and a muscle with no change in fiber length. If casting works, then the trade-off of the effects of casting versus surgery are still not clearly defined, because our goal is to have a strong, meaning large-mass, muscle with a long fiber length giving large active joint range of motion. Neither casting nor surgery can meet these goals.



is a sense that combining these two modalities would provide longer-term benefit. At this time, there is no published evidence to support this concept.

Complications of Treatment

Complications of lengthening the gastrosoleus complex are primarily recurrent contracture or overlengthening. Wound infections are rare, and when they occur, they are easy to treat with local wound care. Spreading scars, which are sensitive to local touch, do occur but are almost completely avoidable by not placing the incision directly posterior, where it is irritated by shoe wear. The incision should always be kept on the medial side, where it is less likely to be irritated and the spreading scar is also less noticeable.

Recurrent contracture is by far the most common problem following equinus contracture surgery. The goal should not be to completely avoid recurrent contractures, although reducing the number and frequency is reasonable. Equinus surgery is very similar to treating an inflamed appendix. There is a well-recognized incidence of removing normal appendices because of misdiagnosis. The accepted incidence of surgically exploring a normal appendix is safer than allowing a much larger number of inflamed appendices to rupture, with some possibly going on to death from general sepsis. A recurrent equinus contracture is like removing a normal appendix; not desired, but a necessary aspect of the current treatment routine. Overlengthening is analogous to allowing individuals to develop severe sepsis with significant risk of death. Rates of recurrent contracture requiring repeat surgery ranging from 9% to 29% have been reported.^{73, 74} Percutaneous tenotomy was reported to have a lower recurrence rate than gastrocnemius fasciotomy. Most studies reviewing the outcome either have short-term follow-up, or the studies are old with very poor evaluations; therefore, it can be concluded that there are currently no good numbers to document an acceptable rate of recurrence. Our current child population is variable, but overall, it is expected that 25% to 40% of children having equinus surgery in childhood will require a second procedure before to full maturity. Of the few children with severe early contractures that require surgery before age 5 years, almost all will need a second surgery. However, at the other end, those children who do not need the equinus surgery until late childhood or adolescence seldom need another surgery. If the second surgery is required, the same indications and procedures are used. Repeat fascial lengthening of the gastrocnemius is possible; however, there is a higher incidence of needing an open lengthening of the Achilles tendon on the second surgery. After a second lengthening, the muscles of the gastrocnemius and soleus are very short. These short muscles are an unavoidable side effect, and they are the reason equinus surgery should be delayed as much as possible, although the need for three equinus surgeries is probably due mostly to factors in individual children and not the surgical technique.

Using orthotics at night or during the day has not been shown to help prevent recurrent contractures.^{74, 85} The disadvantage of the orthotic, especially if it is used during the day, is that it promotes muscle atrophy because the muscle gets less activity and less stress is placed upon the muscle. Therefore, it becomes a balancing act between trying to strengthen the muscle and also giving it stretch. If nighttime orthoses are used to prevent recurrent equinus, these orthoses must include a knee extension splint. Using the nighttime ankle splint will only tend to make the contracture of the gastrocnemius relative to the soleus worse, because the ankle splint will usually encourage the knee to position in flexion so all tension is removed from the gastrocnemius.

The most feared and worst complication of equinus surgery is overlengthening, leading to insufficiency of the plantar flexors (Case 11.10). This



Case 11.10 Carlton



Carlton, a 12-year-old boy with diplegic pattern involvement, had a percutaneous tendon Achilles lengthening at age 4 years. He had used AFOs for most of his childhood but now complained of knee pain and problems tolerating AFO wear, as he had had progressive collapse of his feet. On physical examination he had popliteal angles of 50° , knee flexed ankle dorsiflexion on the left of 40° , and on the right of 30° . There was no difference with extended knee dorsiflexion. Both feet were noted to have a flexible cavovalgus deformity with calluses over the first metatarsal phalangeal joint area and the heel (Figures C11.10.1, C11.10.2). Not only was there a significant medial cavus, he also had a significant increase in the lateral arch, which is typical of the foot whose Achilles tendon has been functionally removed (Figure C11.10.3). No tendon Achilles could be palpated; however, there was some resistance at the end of dorsiflexion. Both tibias had 50° external transmalleolar-to-thigh axis. The foot pressures showed bilateral cavovarus feet (Figure C11.10.4), and the pressure pattern showed especially high force over the medial forefoot on the left (Figure C11.10.5). He had good balance and walked with a normal walking speed of 115 cm/sec and 138 steps per minute cadence. On gait analysis, he was noted to have low variability with normal timing of ankle motion, although it was slightly increased in dorsiflexion. The knee demonstrated increased knee flexion at foot contact with a weight acceptance knee flexion curve in early stance but increased knee flexion in midstance. Knee flexion in swing phase was slightly low and slightly late. Hip motion was normal. Ankle moment was normal; however, the knee moment showed very high

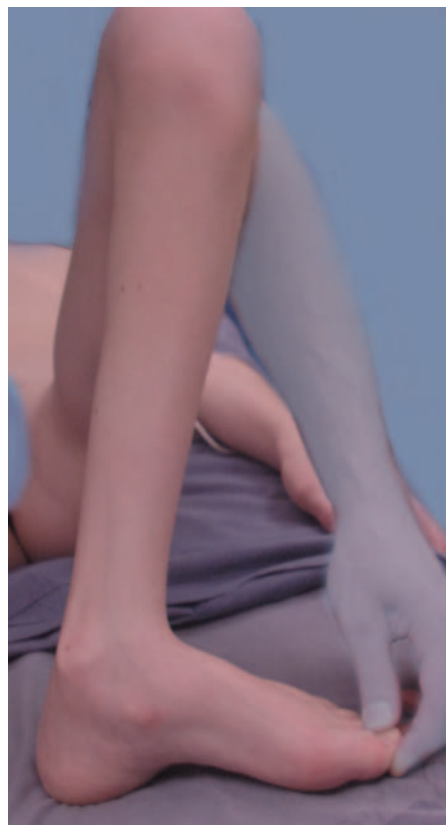

Figure C11.10.1

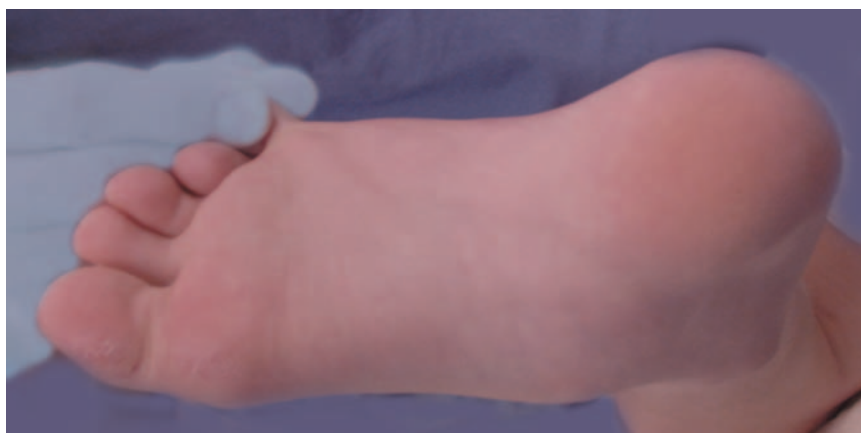

Figure C11.10.2

extension moment in both early and late stance. Hip moments also showed increased extension moment in early stance and increased flexion moments in late stance. Power evaluation showed mild decreased ankle power generation at push-off, increased generation at the knee in early stance, and very high absorption in late stance. The hip showed significant increase in generation in both early and late stance, which indicated that most of his power for ambulation came from the proximal muscles (Figure C11.10.6). This case is an excellent example of the deformity occurring from insufficiency of the gastrocnemius muscle. The foot collapses into cavovalgus because all the plantar flexors are now the long toe flexors, including the tibialis posterior, peroneus longus, and brevis. The force of these muscles allows the calcaneus to dorsiflex but causes plantar flexion of the forefoot. The cavovalgus is never seen with a spastic or contracted gastrocnemius. The ankle has normal motion and moments; however, the moment and motion is at 20° to 40° external to the knee axis causing the ground reaction force vector in the plane of the knee axis to be significantly less. This requires a secondary response at the knee, which is to use knee extensors to control the knee position. The knee tends to stay in an increased flexed position, requiring a high knee extension moment. In midstance, the knee generates power as it helps

with knee extension going into midstance. In terminal stance, the knee absorbs power because it continues with an eccentric contraction of quadriceps to guide knee flexion. The hip, on the other hand, has normal motion but greatly increased demands from its normal moment force and power generation, showing that it is the main power generator in this boy.

This overall pattern of severe insufficiency of the gastrocnemius would, in the past, have been considered a great success of Achilles tendon lengthening. We can now see that this is a far worse outcome than anything caused by a contracted gastrocnemius. The foot deformity and malrotation can be corrected; however, the lack of gastrocnemius power cannot be corrected. Most of the moment generated in this ankle comes from a combination of the out-plane stiffness and the small muscle plantar flexors excluding the gastrocnemius. After correction of these deformities, this boy will have to wear an AFO with plantar flexion resistance for the rest of his life. With even a shortened muscle and a contracture, the gastrocnemius tendon could be lengthened to provide ankle stability so a child with this level of neurologic involvement would not likely need an AFO as an adult. The cavovarus foot deformity, though, is somewhat easier to correct than a severe planovalgus deformity due to a spastic contracture.

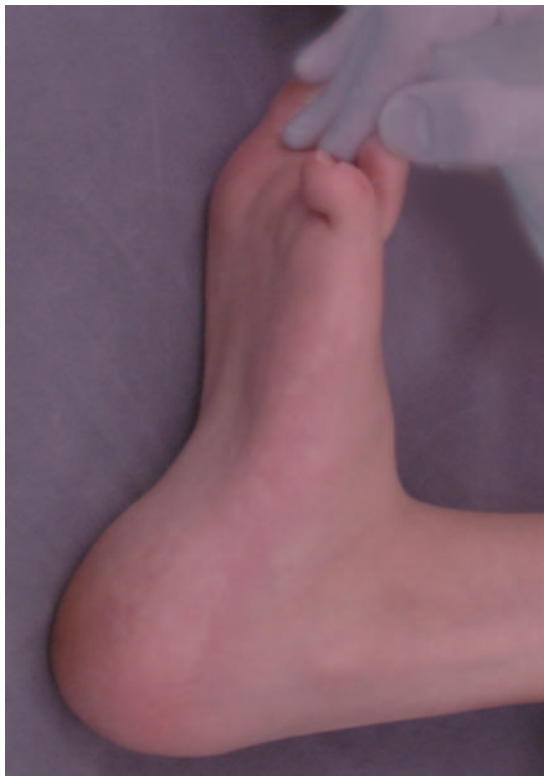

Figure C11.10.3

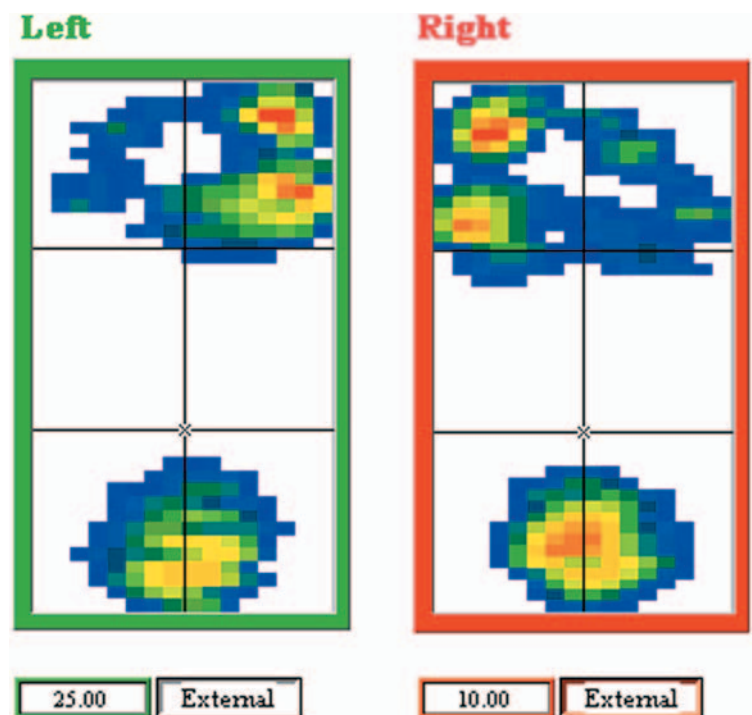


Figure C11.10.4

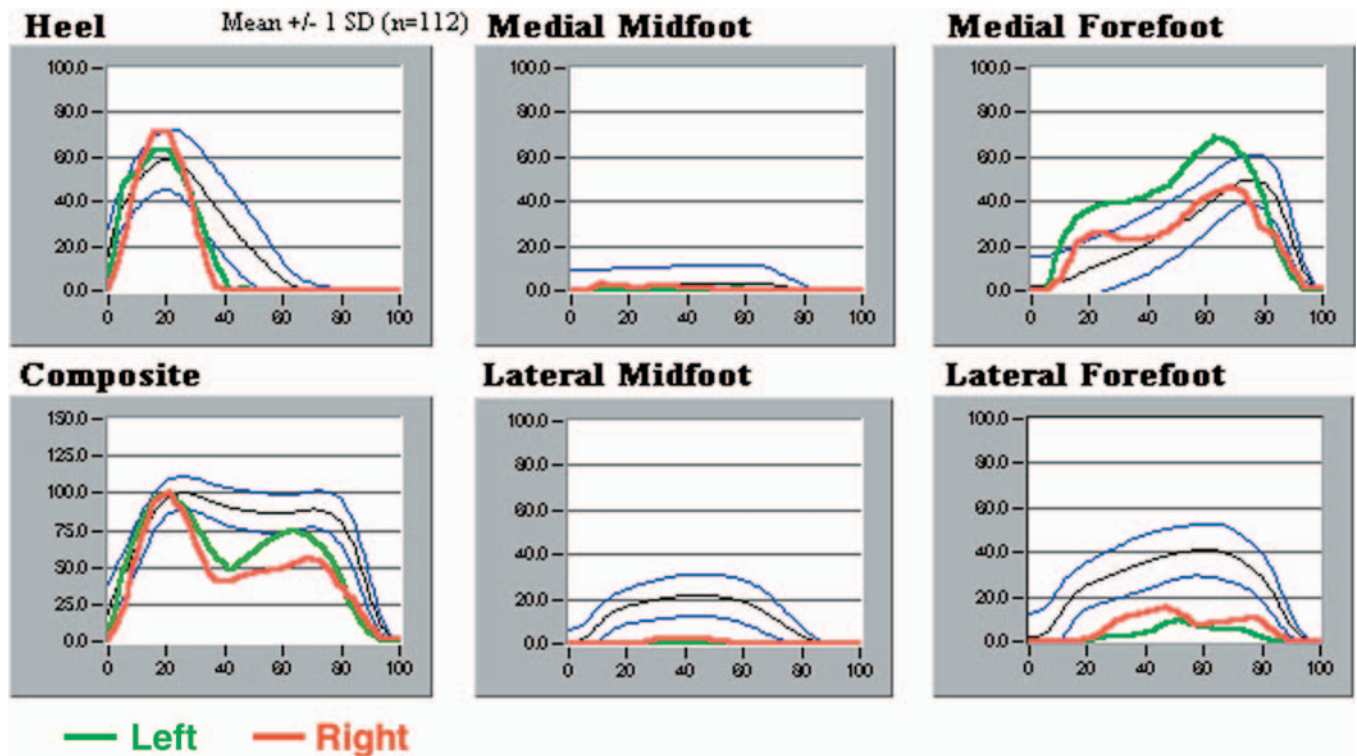


Figure C11.10.5

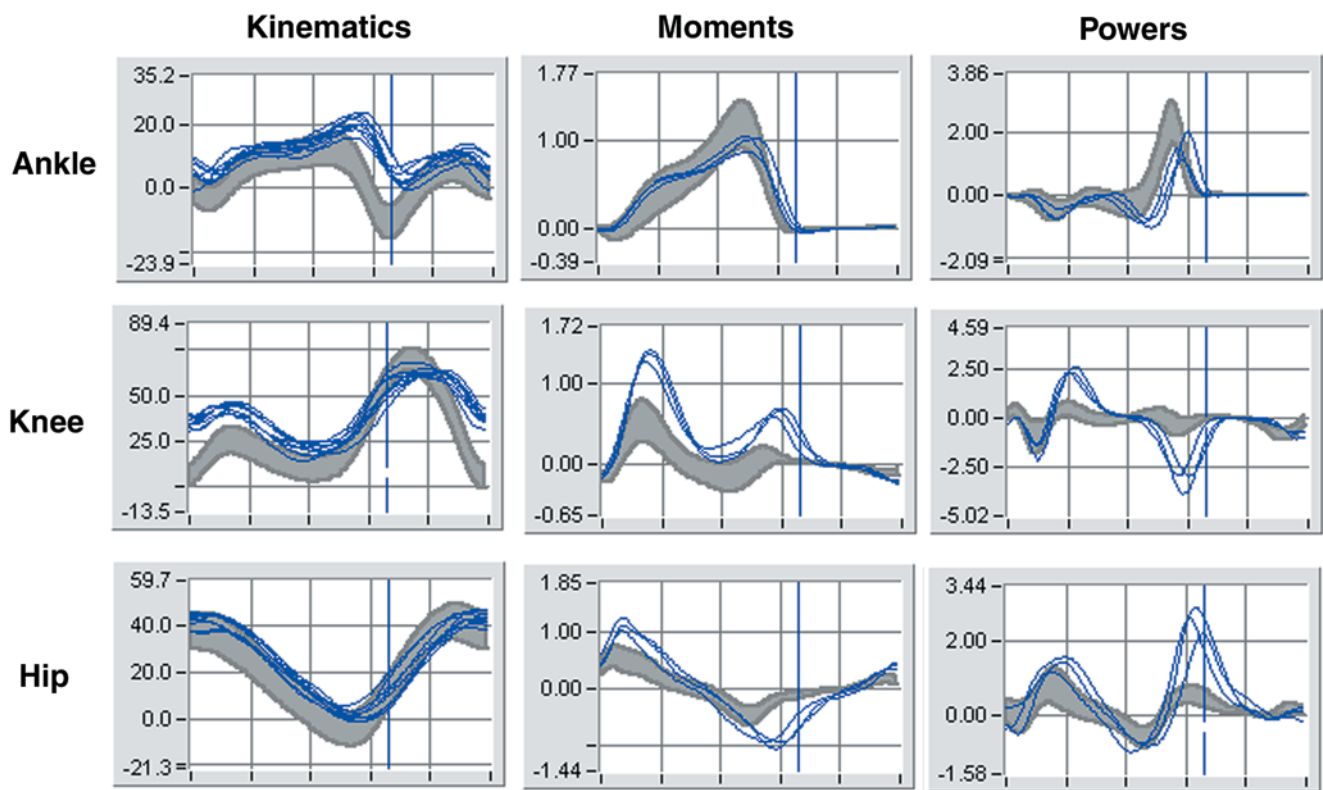


Figure C11.10.6



Figure 11.22. The incompetent ankle plantar flexion–knee extension couple can be treated with ground reaction AFOs. An articulated ground reaction AFO is especially useful in children who have active but weak plantar flexion, active dorsiflexion, and corrected foot deformities. This allows the plantar flexors to strengthen during gait but maintains good knee extension. This orthotic often can be weaned away over 1 to 2 years as the plantar flexors strengthen.

insufficiency ranges from severe fixed calcaneus position to mechanically incompetent plantar flexors, but with the foot resting in the neutral position. Overlengthening based on full evaluations of gait has been defined in as many as 30% of children.⁸⁶ The development of calcaneus position from overlengthening is reported for proximal and myofascial lengthening in 14% to 18% of cases; however, it is highest with percutaneous lengthening, where it was reported as being 38%.⁸⁷ One definition of calcaneus deformity is dorsiflexion in midstance greater than one standard deviation above the mean. This limit is set because almost all children with spasticity have decreased range of motion at the ankle joint; therefore, if more dorsiflexion occurs, more plantar flexion will be lost. Any spastic child with more than 20° to 30° of dorsiflexion on physical examination with the knee extended after equinus surgery has overlengthened plantar flexors. These individuals with overlengthened plantar flexors need to be braced with a solid-ankle AFO with the hope that growth and shortening of the muscle fibers will slowly tighten the plantar flexors (Figure 11.22). This overlengthening is usually, but not always, a direct result of surgical overlengthening of the plantar flexors.⁸⁸ Other causes of this overlengthening are failure to correct knee flexion deformities concurrent with lengthening the equinus contracture. Failure to correct knee flexion deformities will cause an increased moment arm on the plantar flexors, which will stretch them out over time. Although this is not a direct surgical cause of the overlengthening, this too is a surgical complication secondary to a surgical decision-making error. There are rare individuals who develop severe calcaneus without surgery, and these individuals usually have persistent posturing patterning with hip flexion, knee flexion, and ankle dorsiflexion. We have never seen this posturing pattern in individuals who are ambulatory. Also, some individuals with severe hypotonia

and weakness develop an insufficiency of the plantar flexors with calcaneus ankle position. All ambulatory children whom we have seen with spasticity with plantar flexor insufficiency or calcaneus gait are the result of surgical complications.

Plantar flexion insufficiency from overlengthening may also present with back-kneeing in stance as a mechanism that children adapt to gain stability. This back-kneeing is a common adaptive mechanism in poliomyelitis, but we have also seen this as an adaptive change for an incompetent plantar flexor. This pattern should be suspected in any child with increased dorsiflexion on passive examination but back-knee stance posture.

Treatment of calcaneus or plantar flexion insufficiency as a complication of overlengthening of plantar flexors is by the use of a dorsiflexion-limiting AFO (see Figure 11.22). This AFO can be an articulated ground reaction AFO if individuals have some power in the plantar flexors, or a solid-ankle AFO if they have very limited strength. There is no way to repair the overlengthened Achilles tendon, and most individuals need lifelong use of an orthotic after they have developed this insufficiency. Many individuals will develop a collapse of the foot into cavovalgus as growth continues. This cavovalgus usually needs surgical treatment and is discussed in the section on planovalgus. For individuals who do not want to wear or have poor tolerance for wearing AFOs, another very old option that emanates from the poliomyelitis era is to do a pantalar arthrodesis.⁸⁹ This procedure has been recently resurrected by Dr. Kerr Graham to deal with calcaneus caused by iatrogenic overlengthening of the plantar flexors produced by percutaneous tenotomies. This is a major procedure that can be considered to deal with a severe but easily avoidable complication.

The best treatment for calcaneus gait is to avoid this complication by not doing percutaneous Achilles tendon surgery and always making sure to address knee flexion deformities concurrently with equinus contractures. Every calcaneus position defined by more than 20° of dorsiflexion in mid-stance, or more than 20° of dorsiflexion with the knee extended on physical examination, should be evaluated carefully. With appropriate attention to surgical detail, the occurrence of plantar flexor insufficiency should become extremely rare.

Subtalar and Midfoot Deformities

After ankle equinus, subtalar foot deformities have attracted the next most attention from orthopaedists. Initially, as interest shifted from poliomyelitis to CP, equinovarus of the foot was the first deformity to receive significant attention. Almost every imaginable combination of surgeries on the tibialis anterior and tibialis posterior muscles, which were thought to be the primary cause of this deformity, was described. With the advent of EMG gait studies, a more sophisticated approach developed. Attention was directed at the planovalgus as well, although this was conceptually more difficult to understand and did not receive as much attention from the perspective of designing different variations of procedures.

Etiology of Foot Deformities

The interpretation of the etiology of these subtalar deformities was believed to be simple anatomical muscle imbalance driven from the neurologic impairment. These conceptual techniques worked well in understanding poliomyelitis foot deformities.⁹⁰ However, these poliomyelitis concepts have never

worked well in understanding the imbalance and surgical correction of foot deformities in children with CP. Understanding foot deformities continues to be challenging, and the concept of dynamic motor control provides better insight leading to direct implications for clinical management of these deformities. In the theoretical domain of dynamic motor control, equinovarus and planovalgus are seen as two strong attractors at opposite ends in the same plane or same problem. Therefore, trying to balance the foot into a normal position is almost impossible, given the attractor weakness of the normal position as in most children with CP. Understanding some of the factors that go into making varus and valgus such strong attractors makes it clear why there will be a surprisingly small difference between severe varus and severe valgus deformity in the early evolution of these foot impairments. One of the reasons the foot is so vulnerable is that the subtalar joint has very little inherent structural stability, especially in childhood. The stability is strongly determined by the muscles and many different forces affecting the muscles. One impact on the magnitude and direction of deformity is the ankle position. Ankle equinus tends to drive toward subtalar foot varus, and dorsiflexion tends to produce foot valgus. Also, strong muscles with significant dynamic spasticity seem to favor varus, and high mechanical force of walking seems to favor valgus development. Foot progression angle, tibial torsion, and motor control ability are also factors that influence the direction and magnitude of the deformity.

Because these foot deformities are such strong attractors, once varus or valgus deformity is established, it tends to become fixed and is relatively resistant to move away from its attractor. An analogy for these foot deformities is a standing tree. If the tree is perfectly symmetric and is cut at the base, factors such as wind and how the tree is cut determine the direction it will fall. When the strong trunk is cut, the tree has a weak attractor for remaining upright, which is similar to a foot without strong muscles with good motor control. If this tree has large limbs on only one side, and leans to the side with the large limbs because of how it grew, it has a very strong attractor to fall in the direction it is leaning. This is analogous to the foot with established valgus deformity. However, if all the branches are cut off the side to which the tree leans, the tree suddenly will have a strong attractor to fall in the opposite direction. Similarly, if the valgus foot deformity is overbalanced in the varus direction, there will be an attraction in the foot to fall into more varus. Based on this dynamic motor control concept of subtalar foot deformities, the treatment can be planned with an understanding of the direction for progressive deformity that will occur after the treatment. Dynamic motor control can also provide a framework for understanding the natural history of the foot deformity, as there are no reported natural history studies of feet in children with CP.

Equinovarus

Equinovarus foot deformity has received much attention in the published orthopaedic literature of spastic foot deformities; however, in our experience, it represents less than 20% of the subtalar foot problems, with planovalgus being a much more common foot deformity. One study reported that 94% of individuals with hemiplegia develop some varus of the foot and 64% of those with diplegia develop valgus.⁹¹ There is no doubt that some constellation of factors makes varus a strong attractor in hemiplegia. The tibialis anterior and posterior are strong muscles that pull the foot into varus. In addition to causing forefoot and hindfoot varus, the tibialis posterior is also a plantar flexor of the ankle. The directly opposing muscle for the varus force

of the tibialis posterior is the peroneus brevis. The tibialis anterior also causes forefoot varus, and because the varus predominantly occurs through the hindfoot, it also produces hindfoot varus. Tibialis anterior is also the primary ankle dorsiflexor and is the largest anterior compartment muscle. In addition to dorsiflexion and foot varus, the tibialis anterior also causes elevation of the first ray and is the primary cause of dorsal bunions in spastic feet. The primary opposing muscle of the tibialis anterior for dorsiflexion is the gastrosoleus, which is 25 to 30 times stronger. The primary muscle opposing the tibialis anterior for varus and elevation of the first ray is the peroneus longus, which is only half as strong as the tibialis anterior.²

Based on these muscle influences, when there are very strong muscles working against a smaller load, equinovarus positioning will predominate. This equinovarus positioning is seen in the early childhood of most ambulatory children, as they initially start walking up on their toes with varus foot position. In children with hemiplegia, the amount of force the limb has to apply is decreased because the normal limb supplies most of the force input, even as these children get older; therefore, these feet will tend to stay in varus. Also, in some nonambulatory children, the early equinovarus caused by spasticity will strongly predominate because of the stronger muscles on the varus equinus plane. In the early phase in young children, the varus is supple. By age 5 to 7 years, many of the children with diplegia demonstrate a varus foot deformity with toe walking, but when these children are seen standing foot flat, the hindfoot often falls into valgus. These feet in ambulatory children with diplegia will almost all fall into progressive planovalgus as they get older and heavier, when the force balance shifts and the attractor gets progressively stronger. Children with hemiplegia, who on foot flat stance continue with a varus hindfoot or neutral foot alignment, will tend to be drawn to the varus attractor, but this is less predictable.

Secondary Pathology

As the dynamic foot deformity persists and develops fixed muscle contractures, usually of the gastrocnemius and tibialis posterior, overcorrection of the hindfoot varus is no longer possible on physical examination. By the time this level of contracture develops, usually not until adolescence in children with hemiplegia, they will be persistently weight bearing on the lateral border on the foot and will develop overgrowth of the proximal end of the fifth metatarsal. This overgrowth produces a heavy callus, and often pain after walking for long distances. For most children with spasticity, the cavus remains supple in this phase.

Tertiary Changes

The tertiary changes of equinovarus are fixed heel and hindfoot varus, which develop after the muscle contractures have been established for some time, usually requiring years. Also, fixed cavus deformity tends to develop with severe equinus. The foot gradually looks like a severe clubfoot in which more than 90° of hindfoot varus may be present (Case 11.11). We have only seen the most severe expression of this deformity in nonambulatory children with quadriplegic pattern involvement. As the varus deformity increases, ambulatory children have increasing problems walking, and even the most medically neglected cases come to an orthopaedist before they develop these severe fixed clubfoot deformities. Some individuals with moderate equinovarus who are very active and have heavy body weight may develop stress fractures of the lateral metatarsals (Figure 11.23). These fractures tend to be annoying in that they heal well but tend to recur unless the position is improved.



Case 11.11 Edward

Edward was a 12-year-old boy with severe spastic quadriplegia who was fed by a gastrointestinal tube. He was brought in for an orthopaedic evaluation by his foster mother, who had cared for him for the past 6 months. Her primary concern was that she had problems keeping anything on his feet so that he did not get skin breakdown over the lateral side of the foot (Figure C11.11.1). On physical examination, there was a severely fixed equinovarus position to the foot, similar in appearance to a severe club-foot in a newborn. His foster mother was told that this occurred in the past 3 or 4 years, as the natural mother was unable to provide adequate care. After considerable discussion of the various options, a talectomy was performed (Figure C11.11.2), which allowed shoe wear and corrected the care problems for his foster mother.

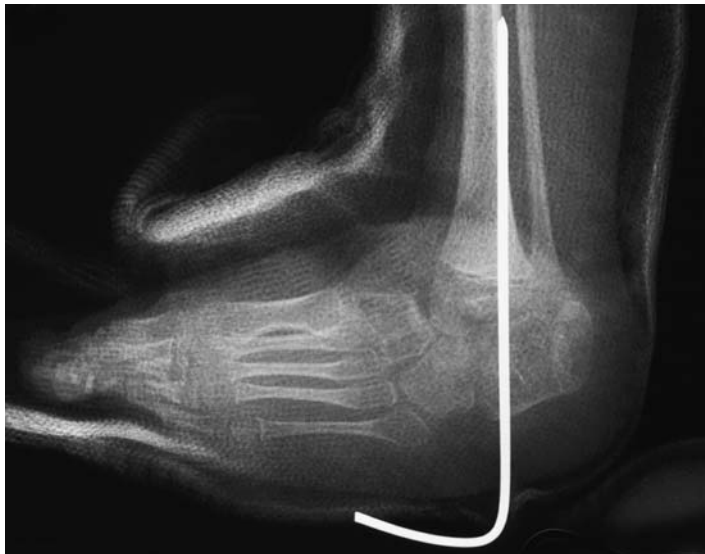

Figure C11.11.2

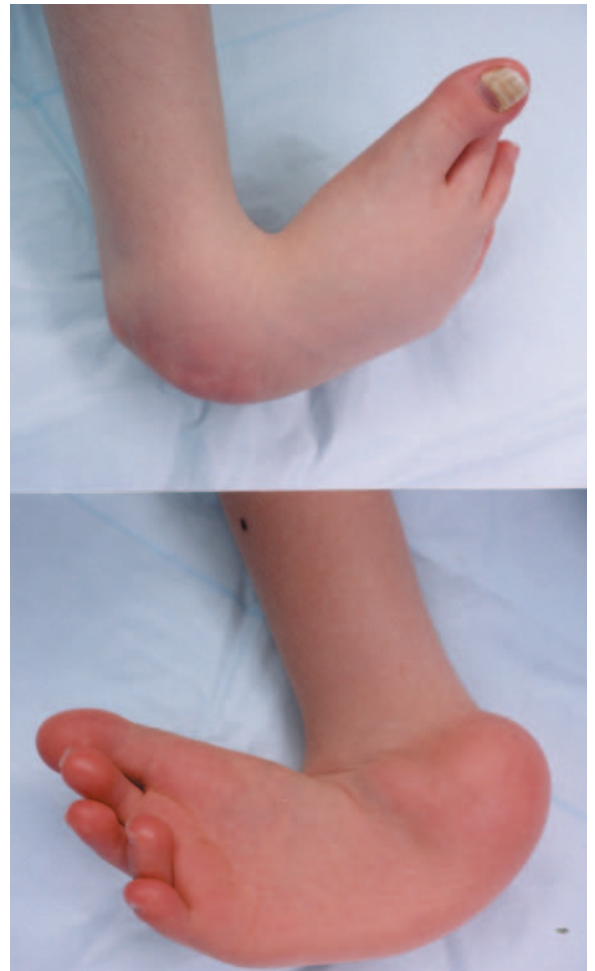
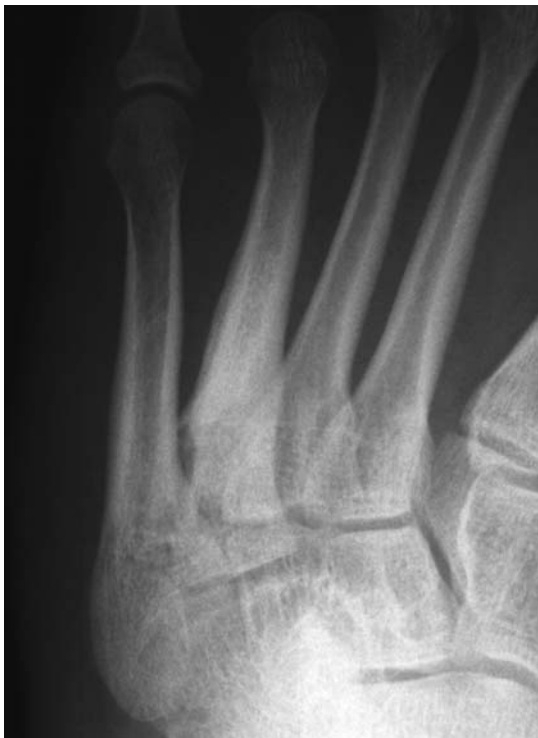
Figure C11.11.1

Natural History

There are no published reports of the natural history of equinovarus foot position. Based on our experience, varus deformities are very common in young children and tend to resolve or get slowly worse in children with hemiplegia. The children with diplegia, on the other hand, will almost always drift slowly into planovalgus during late childhood and adolescence (Case 11.12). Children with quadriplegic pattern involvement have the most unpredictable progression. Except when the deformity is established with fixed contractures, the attractor for the position in which it is set becomes increasingly stronger.

Figure 11.23. This 17-year-old girl with a mild diplegia developed a mild plantar flexor contracture forcing her to a very premature heel rise. After extensive walking during a summer job, she developed a stress fracture of the fourth metatarsal. Treatment of this stress fracture should involve reducing the stress by lengthening the contracture that is increasing the stress, usually the plantar flexors.



Diagnostic Evaluations

One of the most difficult problems in studying foot deformities has been the difficulty of quantifiable diagnostic testing to classify severity levels. Traditionally, radiographs have been the main method; however, radiographic angles provide poor correlation to specific deformity, have poor accuracy, and are very position dependent. The use of anterior radiographic tomography has been reported to show poor specificity for the abnormal deformity.⁹¹ The use of the pedobarograph has become much more common in the past 10 years and has been demonstrated to be useful in assessing foot deformities.⁹² We have evaluated this device for children with CP and have found it provides the best assessment and assignment of a magnitude for varus-valgus foot position. The technique we use assigns a number for the weightbearing symmetry index, ranging from -60 to $+60$, with a number between -15 and $+15$ representing a normal foot. Feet with -40 and greater have severe varus, and feet with $+40$ and greater have severe valgus. The numbers in between demonstrate moderate deformities. The symmetry impulse index is calculated by subtracting the medial forefoot and midfoot impulse of the whole gait cycle from the impulse of the lateral forefoot and midfoot. This number tells which side of the foot bears the most weight and is not influenced by toe walking (Figure 11.24). Although the pedobarograph is good to assess the magnitude of the varus deformity using the impulse index, it is not helpful to assess the cause. The EMG is the primary tool to assess the cause of the varus deformity, meaning the tibialis anterior and gastrocnemius should be recorded with surface electrodes in the tibialis posterior with a fine wire electrode. These EMGs have to be correlated to the gait cycle using foot switches or kinematics. The EMG activity has to be correlated to the kinematic motion of the ankle joint and the foot progression angle. Also, the physical examination should focus on the range of motion of the subtalar joint and the position of the foot in the foot flat stance. The use of the Cole-

man block test to separate a fixed cavus forefoot deformity with a supple hindfoot from a fixed hindfoot deformity with forefoot deformity is occasionally helpful⁹³ (Figure 11.25). The Coleman block test is most useful in children who have had a heel cord lengthening and still have varus. Most children with spastic varus have little pressure on the first ray, which demonstrates that the hindfoot varus is not being caused by a fixed forefoot covo-varus; therefore, the Coleman block test has little significance.

Indications and Treatment

The supple foot deformity commonly seen in early and middle childhood is best treated with an orthotic. If there is a significant component of equinus with the varus, a full calf height AFO is required. For rare children, usually those in whom the gastrocnemius has been lengthened and some residual varus remains in stance phase, the use of a supramalleolar orthotic with a lateral heel post may control the foot. Often, when children are having an



Case 11.12 Dylan



Dylan, a 2-year-old boy with diplegia, was initially seen as he walked with a walker. He made slow gradual progress with his gait until age 7 years when he reached a plateau. At that time, he was wearing half-height AFOs to prevent plantar flexion, but still walked with predominant toe walking. On physical examination he was noted to have 10° of dorsiflexion with knee flexion and -5° of dorsiflexion with the knees extended. Both ankles were similar, although the left seemed to have a more definite end feel. Physical examination also showed bilateral planovalgus feet, definitely worse on the right than the left. Gait analysis showed foot contact dorsiflexion at near neutral, no first rocker, early and decreased dorsiflexion in stance, and a premature plantar flexion in stance. Ankle moment was increased in early stance and then decreased in late stance. The power curve showed high early absorption and a midstance generation burst associated with a vault. There was almost no push-off power generated in late stance (Figure C11.12.1). The foot pressure showed a significantly worse planovalgus on the right, with more external foot progression angle of 28°. Heel contact was decreased and early heel rise was noted. Increased pressure on the medial side of the foot indicated more severe valgus on the right side (Figures C11.12.2, C11.12.3). This was the typical middle childhood mild equinus contracture of the gastrocnemius without a soleus contracture in a child who was developing planovalgus, and this child should be expected to fall into increased crouch as he gained mass through his adolescent growth.

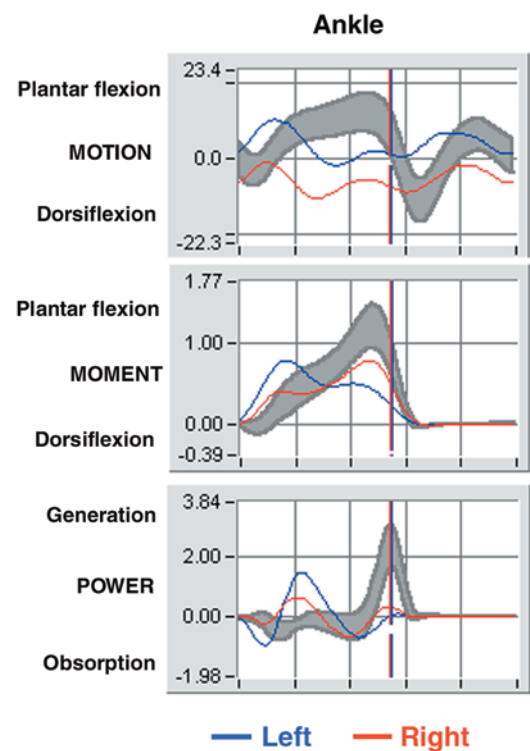


Figure C11.12.1

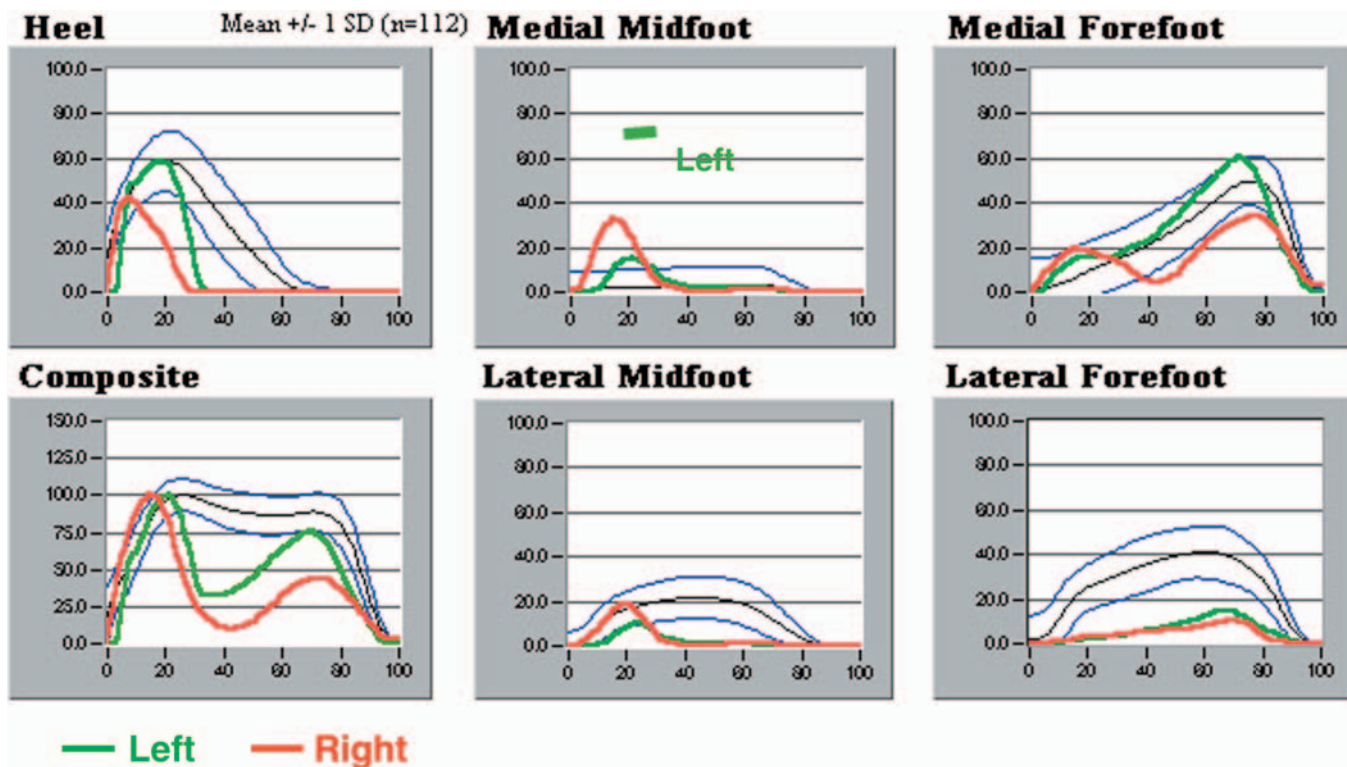


Figure C11.12.2

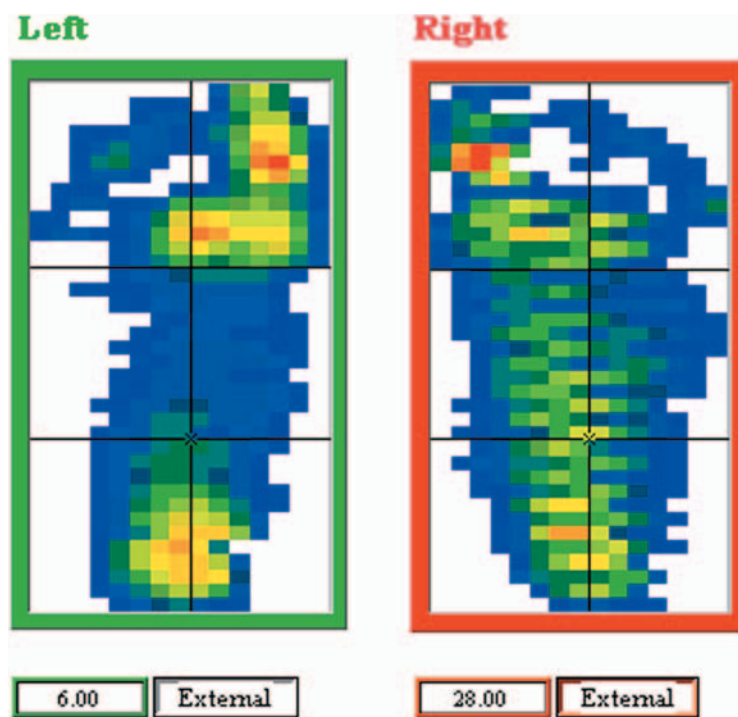


Figure C11.12.3

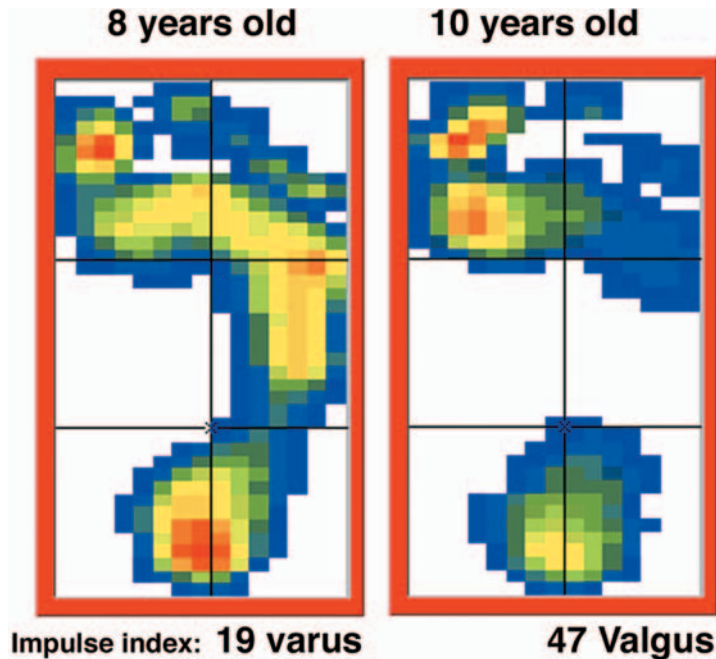


Figure 11.24. At age 8 years, the most common hemiplegic foot position in addition to the equinus is varus position, as seen in this pedobarograph that shows increased lateral forefoot and midfoot weight bearing. Two years after a split transfer of the tibialis posterior to the peroneus brevis, the foot has developed a valgus load bearing patterning with most of the pressure on the medial forefoot. The physical appearance of the foot remains good. This case demonstrates how, even in the ideal case, there is tendency for overcorrection of varus foot position in children.

evaluation for surgical reconstruction to improve gait, usually at 5 to 7 years of age, the foot has an element of varus, especially when they are standing on tip toes. A full examination should include an EMG of the tibialis posterior using a fine wire; however, many children at this age are not able to cooperate to have the wire inserted and then walk with a normal gait pattern. Also, at this age in children with diplegia, usually no surgery should be performed to correct varus deformity unless the varus is severe and there is an already fixed contracture of the tibialis posterior.

An extremely high number of children with supple varus will fall into valgus gradually as adolescence approaches, and any surgery on the tibialis anterior or tibialis posterior will often only exacerbate the natural history. Valgus foot collapse is an extremely strong attractor for ambulatory children with diplegia who enter adolescence, and all early treatment has to consider the strength of this attractor (Case 11.13). For children with hemiplegia who have severe varus foot position with any degree of tibialis posterior contracture, consideration of mild intramuscular lengthening of the tibialis posterior is recommended. In early and middle childhood, varus foot deformities should be left alone unless they are severe with at least some fixed muscle contracture, meaning there is some limitation in hindfoot and forefoot varus when these children are completely relaxed (Case 11.14).

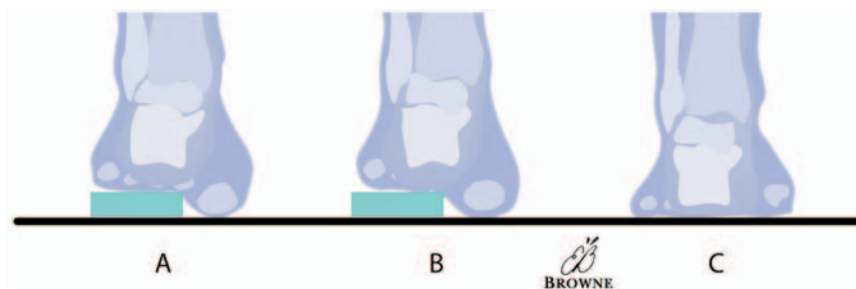


Figure 11.25. A mechanism to separate hindfoot varus from forefoot varus is the lateral block test as described by Coleman and Chestnut.⁹³ The varus foot has a 1-cm-thick block placed under the lateral foot allowing the first and second rays to drop off the edge of the block. If the hindfoot deformity corrects (A), the etiology of the varus is in the forefoot, usually with a cavus component. If the hindfoot does not correct (B), then the etiology is in the hindfoot, either a fixed subtalar deformity or a fixed contracture of the posterior tibialis. The normal alignment is graphic (C).



Case 11.13 Brianna



Brianna, a 3-year-old girl with spastic diplegia, presented with the complaint that she just started to ambulate but she always requires the use of push toys. She ambulated best when toe walking with the knees flexed. On a follow-up visit 1 year later, she walked independently but with poor balance, stiff knees, and high on her toes. At age 5 years, she had bilateral adductor, psoas, distal hamstring, and gastrocnemius lengthening. She also had a rectus transfer at the same time. This improved her stance stability; however, by age 7 years, she developed a planovalgus foot on the right and equinovarus foot on the left. At age 8 years, she had a split tibialis posterior transfer to the peroneus brevis on the left and a calcaneal lengthening on the right. By 1 year following this surgery, the left foot looked good but the right foot had definite residual valgus, which rapidly became worse over the next year. This required a reconstruction with subtalar fusion and medial column reconstruction including advancement of the tibialis posterior after resection of the navicular tuberosity, lateral transfer of the tibialis anterior, and opening wedge osteotomy of the medial cuneiform. At the 1-year follow-up, the foot showed good correction but with some significant residual valgus, and the left foot showed increased valgus (Figure C11.13.1). At skeletal maturity at age 15 years, the left foot continued with some increase in the valgus position and the right foot also had dropped into some valgus. This case demonstrates how difficult it is to predict the progression of foot deformities; however, as children with moderate or severe diplegia go into adolescence, there is a strong attraction to falling into valgus. Thus, in all corrections of the feet, one should be very careful to avoid overcorrection of varus position in middle childhood. It also means that correction of planovalgus requires complete correction, especially in middle childhood, or there is a high risk of developing recurrent valgus.

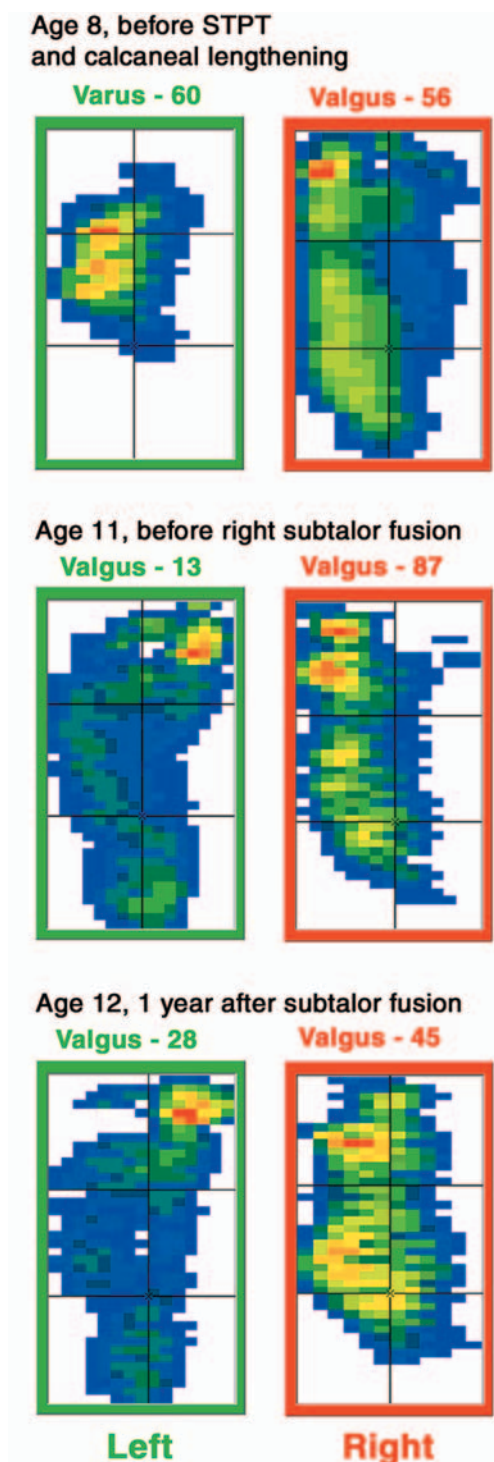


Figure C11.13.1



Case 11.14 Wendell



Wendell, a 9-year-old boy, was evaluated because his mother noticed that he walked over on the side of his foot. On physical examination he was noted to have right hemiplegia; however, he was also thought to have slight increased tone on the left side. He had normal hip and knee examination. The range of motion of the left foot and ankle was normal. The right ankle dorsiflexion was -5° with both flexed and extended. The tibialis posterior was noted to have 2+ spasticity, and heel eversion was to 10° . The pedobarograph demonstrated significant varus of the right foot with a premature heel rise. High pressure was noted in the lateral midfoot segment (Figures C11.14.1, C11.14.2). An EMG demonstrated phasic gastrocnemius

and tibialis anterior muscles. Posterior tibialis EMG was not performed because of his very high anxiety level concerning needles. He had a split transfer of the right tibialis posterior muscle with excellent improvement. By 2 years following the surgery, with a significant growth, he developed a mild planovalgus foot with prolonged heel contact. He was asymptomatic, and this level of mild planovalgus tends to function better than mild varus if it does not progress and get worse. With the recent growth, he has developed some contracture of the gastrocnemius with a premature heel rise and a varus deformity on the left side (Figure C11.14.2).

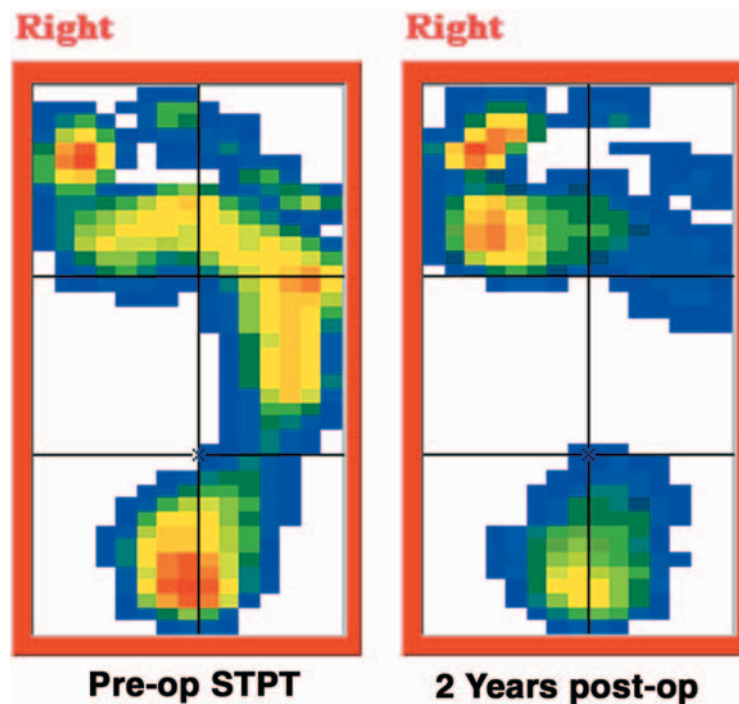


Figure C11.14.1

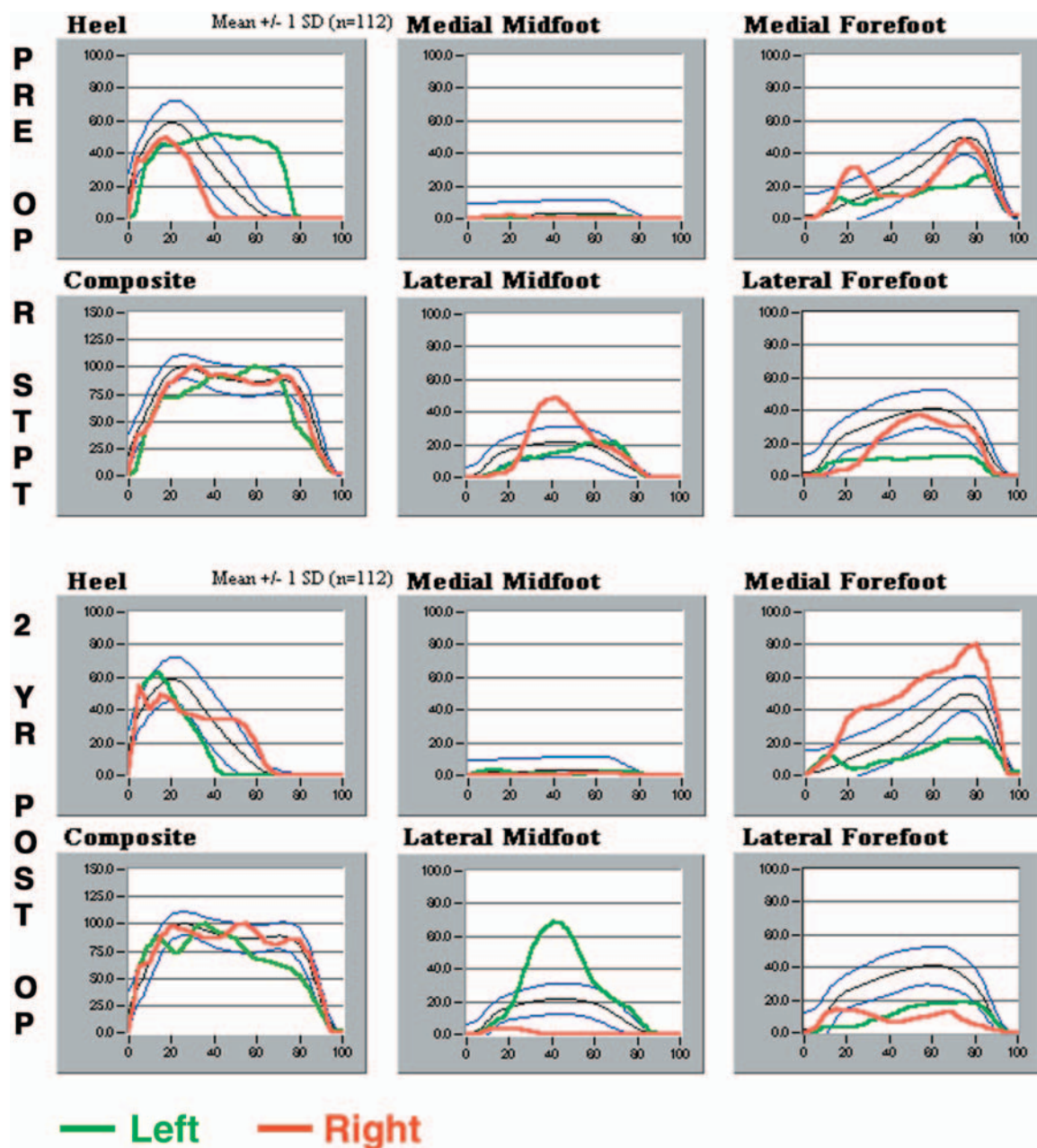


Figure C11.14.2

Adolescents

By the preadolescent or adolescent age of 8 to 12 years, children with a varus foot deformity will develop much more defined deformity, often becoming symptomatic from pain due to high pressure over the lateral fifth metatarsal. By this age, most children will be able to cooperate for a full EMG evaluation, which includes an EMG fine wire of the tibialis posterior. If the tibialis posterior has no contracture, which means easy overcorrection of the hindfoot is possible, and the EMG shows this muscle to be active throughout stance phase or constantly active, a split transfer to the lateral side with attachment

to the peroneus brevis is recommended. Children in this age group with varus foot deformities that can be manually corrected to at least a neutral heel are ideal candidates for correction by tendon surgery. If the varus is most significant during swing phase and the tibialis anterior is on constantly, or on during the majority of stance phase, a split transfer of the tibialis anterior is performed with attachment to the cuboid or a slip of the peroneus longus. If both muscles are constantly active, both can be split-transferred, especially if there is a severe deformity. If the tibialis anterior is constantly active and the tibialis posterior has a contracture, the tibialis posterior may have a myofascial lengthening and the tibialis anterior a split transfer. The equinus must be addressed based on the degree of dorsiflexion on the kinematics and physical examination.

After the surgical correction in the operating room, the foot should rest in neutral to slight valgus. If the foot rests in varus after the tendons are attached in surgery, final correction of the varus is very unlikely. Following the tendon transfer, children are immobilized in a weightbearing cast with slight overcorrection into valgus and at neutral to 5° of dorsiflexion. This cast is maintained for 4 weeks, after which the children are allowed full activity without orthotic control.

Fixed Heel Varus

Children with fixed heel varus, which often cannot be passively corrected, are usually well into adolescence or are young adults, typically ages 15 to 20 years. This group includes failures of tendon transfers and children who were medically neglected and did not receive surgery at an earlier age when tendon surgery would have sufficed. Because of the fixed deformity, the treatment often requires an osteotomy. If the primary problem is a fixed hindfoot varus, correction by Dwyer sliding and closing wedge calcaneal osteotomy is recommended (Case 11.15). If the primary deformity is midfoot, then excision of the calcaneocuboid joint is recommended. This lateral closing wedge osteotomy will improve some hindfoot varus as well; however, in rare severe cases, both the Dwyer calcaneal osteotomy and the lateral calcaneocuboid joint resection fusion may be needed. Along with the bone osteotomy, a Z-lengthening of the tibialis posterior is recommended. Because of severe shortening and the long tendon, it is more difficult to find adequate muscle mass to do a myofascial lengthening in individuals with this level of severity of tibialis posterior contracture. The osteotomy should be fixed with internal fixation, and again, the amount of correction will never be better than that seen in the operating room at the conclusion of the procedure. Many of these individuals also have a very prominent fifth metatarsal from long-time weight bearing. The appearance of the foot and the immediate comfort of the individuals will often be improved if this overgrowth is resected. Immobilization in a cast is usually required for 12 weeks to allow full bone healing. Weight bearing is allowed as soon as tolerated from the perspective of pain.

Severe Fixed Spastic Clubfeet

Individuals with severe varus in feet that have the appearance of severe untreated clubfeet and in whom treatment is desired often require very extensive decompression (Case 11.11). Because of the large magnitude of the surgery, caretakers should be offered the options of making well-padded protective orthotics and using wheelchair protective foot buckets instead of



Case 11.15 Medhi



At age 3.5 years, Mehdi, a boy with diplegia, walked with a posterior walker and his mother came and expressed concern about his flat feet. He had been in solid AFOs but his mother felt his feet were not getting better. The radiographs demonstrated severe planovalgus deformities bilaterally (Figures C11.15.1, C11.15.2). At that time, he had a bilateral Z-lengthening of the peroneus longus and Achilles tendons and a myofascial lengthening of the peroneus brevis. Over the next 2 years, both feet developed gradually increasing varus positioning, so at age 14 years, he had bilateral split tibialis posterior transfers. However, the varus persisted until at age 17, at which time when he ambulated in the community with Lofstrand crutches, he also complained of increased foot pain. He felt he was doing well except for the foot pain. On physical examination he was noted to have a heavy callus over the lateral aspect of the proximal fifth metatarsal. This was also the area of his foot where he noted the pain. Observation of his weight bearing showed the foot in equinovarus with lateral midfoot weight bearing, which was confirmed by observation of his gait (Figure C11.15.3). Range of motion of the subtalar joint demonstrated that the heel could not be brought to neutral but remained in at least 15° of varus. The ankle dorsiflexion in both knee positions was the same at -5°. Radiographs showed severe varus position with a parallel talus and calcaneus (Figure C11.15.4). Because of the fixed deformity, he had a closing wedge and lateral displacement osteotomy of the calcaneus (Figure C11.15.5). After rehabilitation, his foot position in stance was neutral (Figure C11.15.6), with improved

position during gait and complete resolution of the pre-operative pain. This is a typical demonstration of the unpredictable nature of peroneal tendon surgery and the severe consequence of overcorrection.

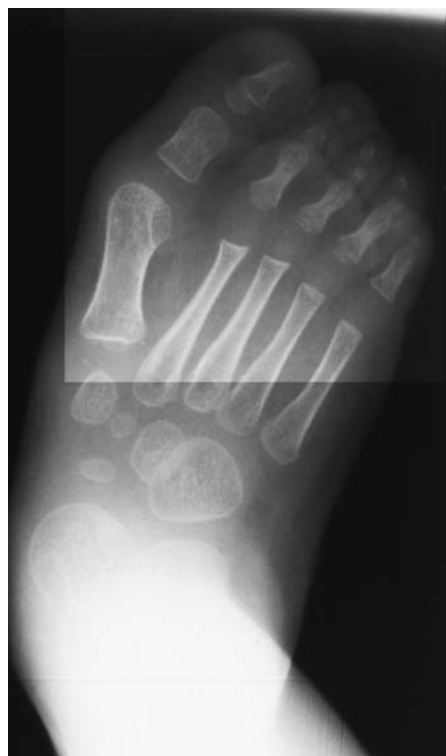

Figure C11.15.1

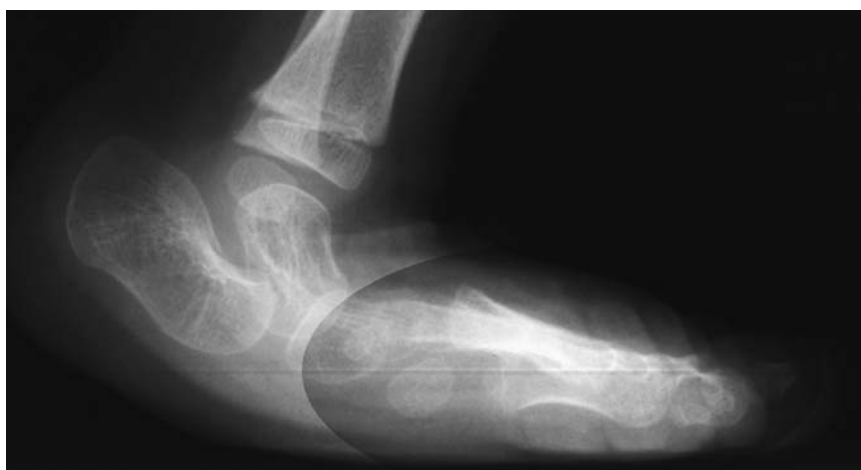

Figure C11.15.2

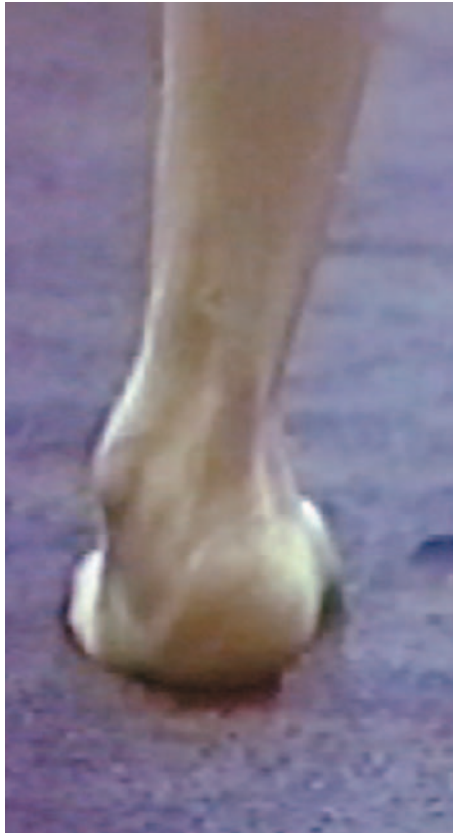

Figure C11.15.3

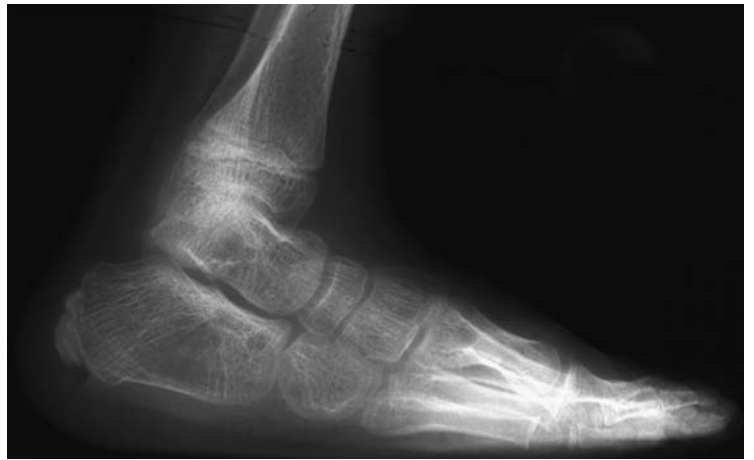

Figure C11.15.4

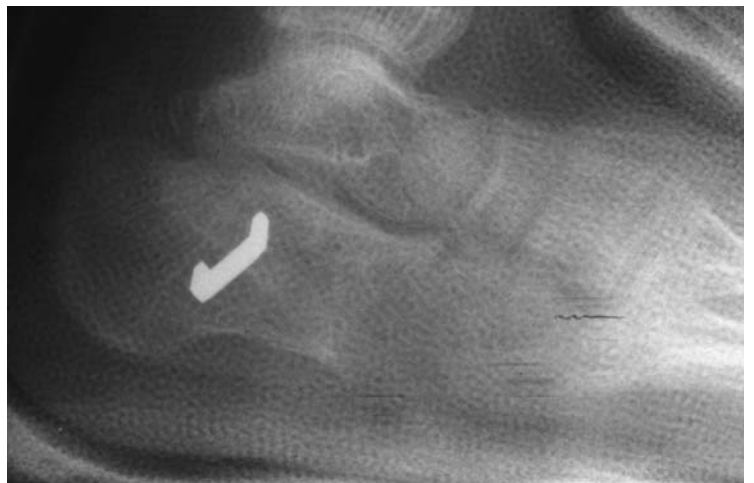


Figure C11.15.5

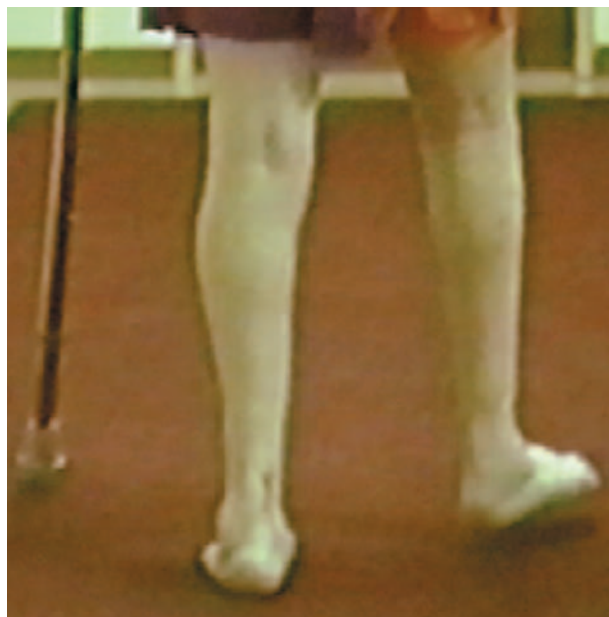

Figure C11.15.6

footrests. However, the main complaint is usually skin breakdown from footrests while individuals are in the wheelchair. If surgical correction is desired, a choice has to be made between a triple arthrodesis and a talectomy. If there is some mobility in the foot that allows substantial correction under anesthesia, a triple arthrodesis can be performed with a tenotomy of the tibialis posterior at the level of the medial malleolus. Most of the severe deformities are very stiff, and a talectomy is a simpler procedure that allows excellent correction. All these deformities that we treated have occurred in nonambulatory children in whom the symptomatic problem was skin breakdown over the feet as they grew to adult size. Along with the talectomy, all the muscles are tenotomized, including the tendon Achilles, tibialis anterior, tibialis posterior, and peroneus brevis and longus. Both talectomy and triple arthrodesis provide stable long-term correction of the deformity in this group of individuals with limited demands on the feet.

Outcome of Treatment

There are no published data to evaluate the outcome of orthotic management of varus foot deformities. It is doubtful that there is a significant effect on the foot with the use of orthotics; however, the orthotics do allow children to be more stable and comfortable. Also, the use of orthotics allows children to grow and age so predicting the final development of the deformity is more clearly defined.

The outcome of evaluating children with EMG, then applying an algorithm similar to that presented, reportedly yields good results in all cases.⁹⁴ An earlier description of the tibialis posterior transfer by Green et al.,⁹⁵ which included mostly individuals with hemiplegia, reported that all did well except two who had fixed deformities and later required calcaneal osteotomy. Reporting good results has been the trend in most other publications⁹⁶⁻⁹⁸ that reported the results of tibialis posterior tendon surgery. Only in one study⁹⁹ was an overcorrection rate of 15% reported with tibialis posterior tendon surgery. The outcome of these studies leads one to conclude that overcorrection from split transfer of the tibialis posterior is exceedingly rare; however, this is not the case (Case 11.16). In our review with an 8-year follow-up, we found a high rate of overcorrection in individuals with diplegia and quadriplegia. Children with ambulatory diplegia had a 52% failure rate with 66% of those failing due to valgus overcorrection. Equinovarus due to quadriplegia had a failure rate of 66%, with 40% of those failing due to valgus overcorrection. Even children with hemiplegia can have overcorrection, but it is much less likely as we found only 2 overcorrections of 39 feet. The endemic problem in this literature is that there is no objective way to evaluate these feet, and it is a well-known fact that mild to moderate planovalgus is better tolerated than mild to moderate varus. Therefore, these investigators probably tend to overlook valgus overcorrection because the children and caretakers are happier with valgus than with varus. However, over the long term, there is a tendency for these feet to fall into progressively worse valgus, some of which was probably caused by the tendon surgery and some of which was due to the natural history, with the tendon surgery just causing it to occur earlier. The optimistic outcome reports published in the literature of tibialis posterior tendon surgery for spastic equinovarus probably reflect the outcome for children with hemiplegia only.

Outcome reports of lengthening the tibialis posterior tendon as promoted by Ruda and Frost suggested an excellent outcome.¹⁰⁰ They recommended no immobilization when doing the surgery before to age 6 years.¹⁰⁰ Again, it is very difficult to tell from this recommendation how many children would



Case 11.16 Lotti



Lottie is a 7-year-old girl with spastic diplegia who was evaluated with the major parental concern being her walking up on her toes and in-toeing. Based on a full evaluation, she was believed to have significant anteversion of the femurs, stiff knees in swing phase due to rectus spasticity, hamstring contracture limiting knee extension in stance, equinovarus feet due to gastrocnemius contracture, and spastic tibialis posterior. Based on this, she had bilateral femoral derotation osteotomies, rectus transfer to the sartorius, distal hamstring lengthening, gastrocne-

mius recession, and split tibialis posterior transfer. One year after surgery, her gait was much improved except she was already developing worsening valgus deformity in the left foot. This was treated with rigid in-shoe supra-malleolar orthotics, which she tolerated well. Her gait and foot deformity stabilized and seemed to improve slightly by the 3-year follow-up; however, when she had significant weight gain with onset of puberty, she developed painful callosities and bunions that made orthotic wear difficult (Figures C11.16.1, C11.16.2). The foot pressure

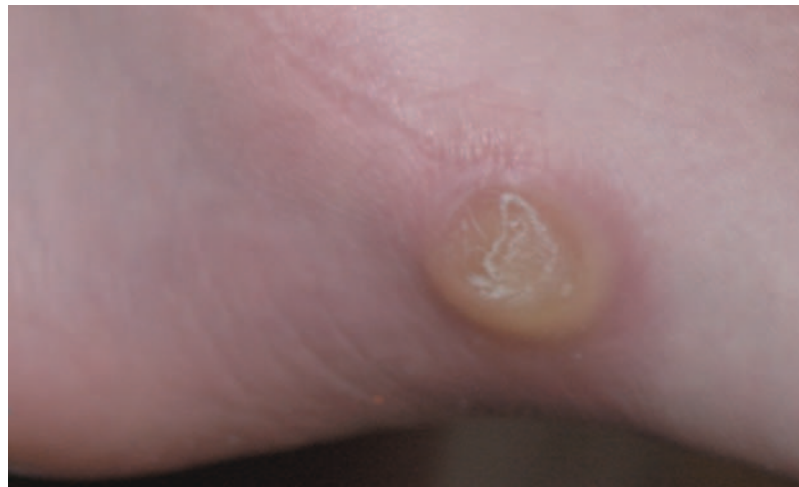

Figure C11.16.1

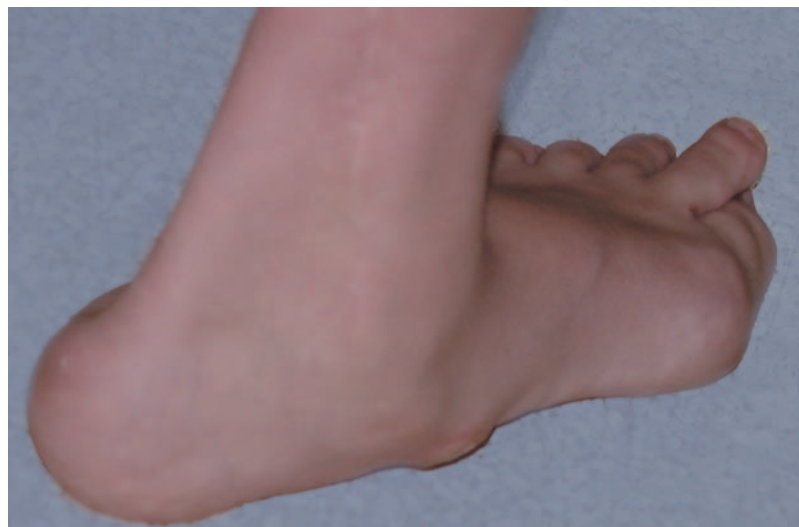

Figure C11.16.2

at this time showed significant bilateral planovalgus with predominant weight bearing on the medial side of the foot (Figures C11.16.3, C11.16.4). Bilateral calcaneal lengthenings were then performed with resection of the navicular tuberosity, advancement of the tibialis posterior, transfer of the tibialis anterior to the medial cuneiform, and correction of the left bunion with a first metatarsal osteotomy and soft-tissue realignment. This provided good cosmetic correction of the foot and excellent correction of the right foot where the deformity was more mild. The left foot had good cosmetic correction; however, weight bearing still tends to be predominantly on the medial border of the foot, suggesting that there was an overcorrection of the forefoot supination (Figures C11.16.5, C11.16.6).

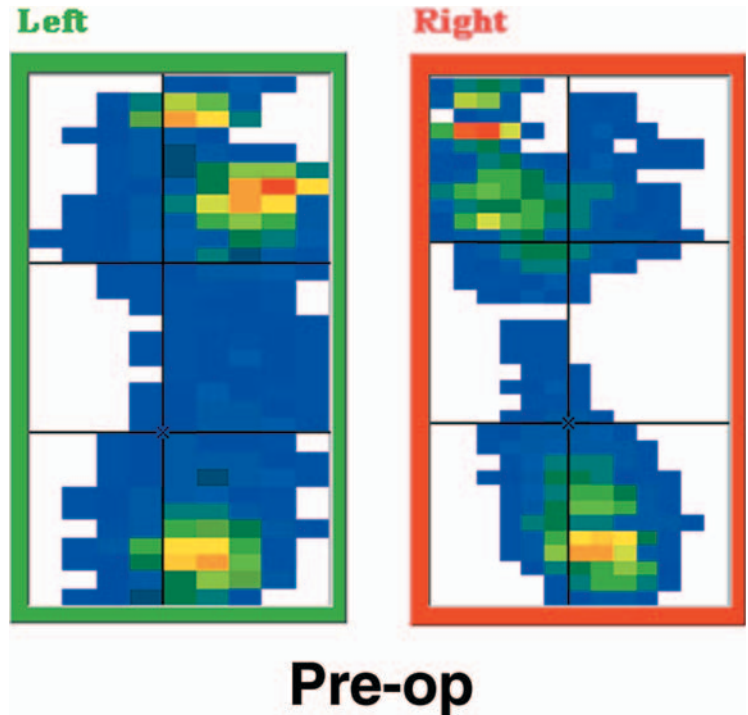


Figure C11.16.3

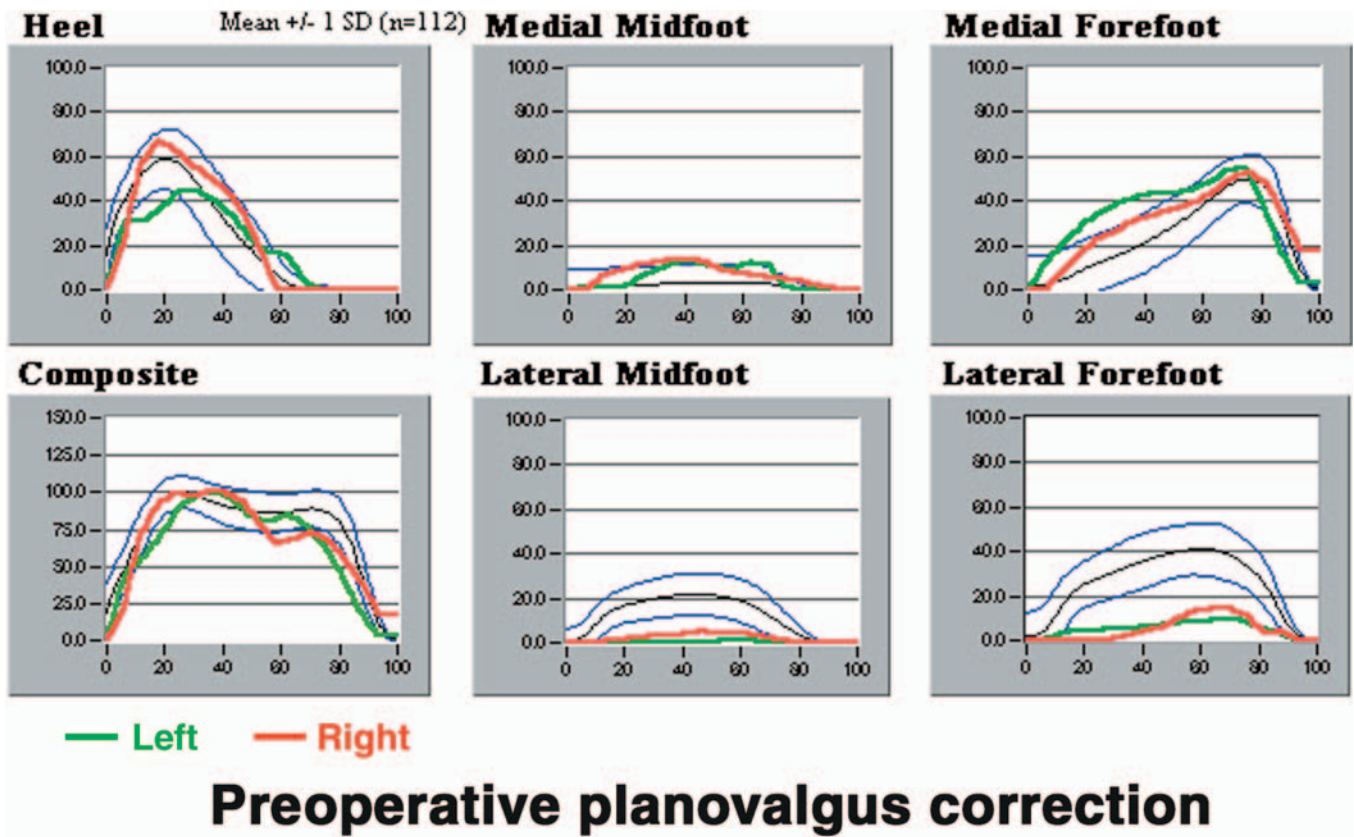


Figure C11.16.4

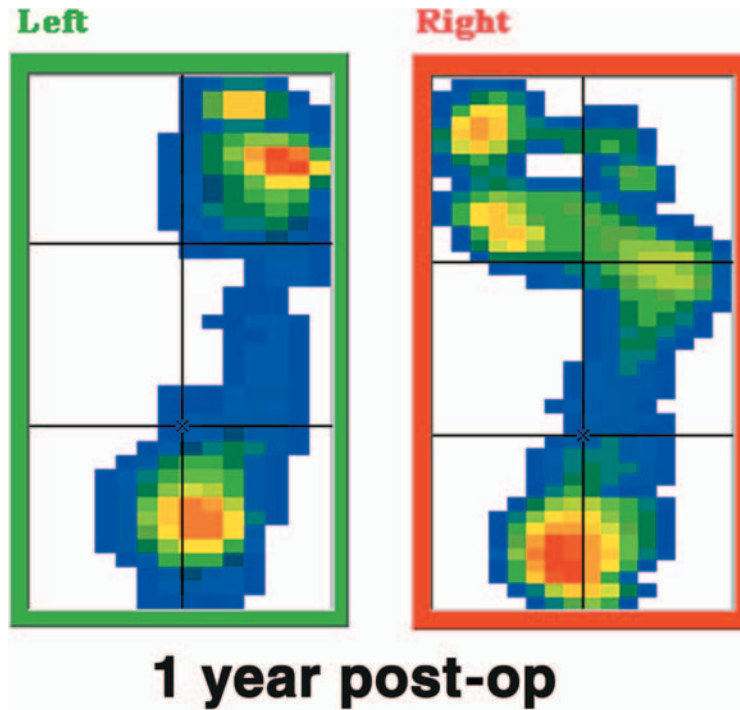
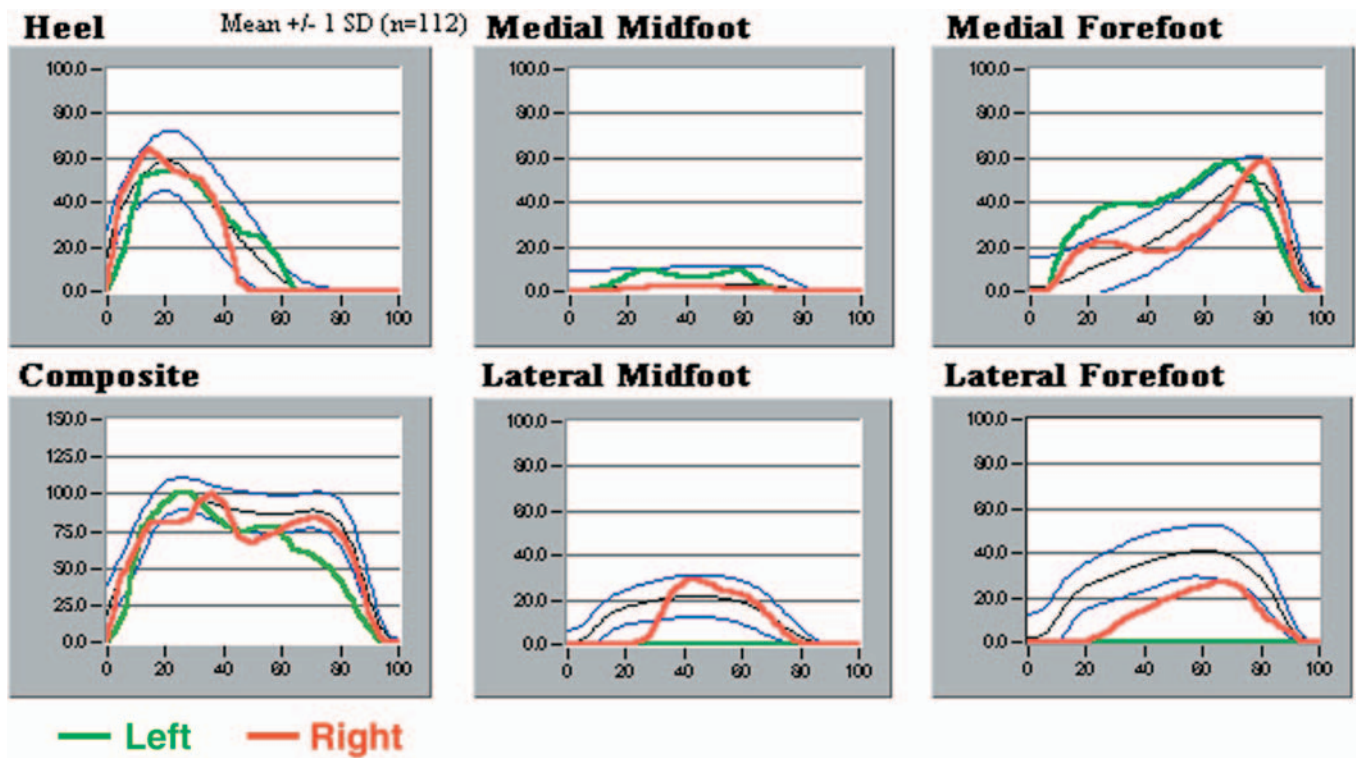


Figure C11.16.5



One year following lateral column lengthening

Figure C11.16.6

have gotten better with no surgery because the natural history is to fall into valgus as they get older. In the one study reporting outcome of combined split tibialis anterior transfer and tibialis posterior lengthening, 22 feet did well when the surgery was done very young, between the ages of 2 and 8 years. No overcorrections were reported.¹⁰¹ Our comparison of myofascial tibialis posterior lengthening with Z-lengthening and split transfer demonstrated no significant difference between the procedures. Although we found no difference, based on our experience, split transfers are preferred in high-functioning children with hemiplegia, myofascial lengthenings in mild contractures of diplegia, and Z-lengthenings in the more severe contractures.

Split transfers of the tibialis anterior were reported to have excellent results with strict criteria defined as dynamic deformities with overactive tibialis anterior on EMGs.^{102, 103} Also, good results were reported with no overcorrections when lengthening the tibialis posterior was added to the split tibialis anterior transfer.¹⁰¹

The outcome of calcaneal osteotomy as recommended by Dwyer⁹⁰ suggested excellent radiographic results with good patient satisfaction.¹⁰⁴ There have been no objective gait evaluation studies, but our experience in a limited number of patients is in agreement with these published data. There have been no reports on talectomy or triple arthrodesis for varus foot deformity, and a review of the results of these procedures is given in the planovalgus section.

Other Treatments

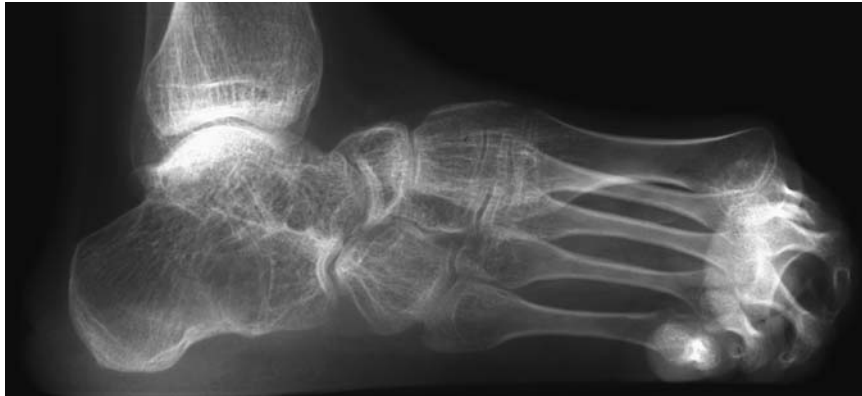There have been other operative procedures reported to treat varus foot deformity in addition to those presented. Complete transfer of the tibialis posterior through the interosseous membrane to the anterior aspect of the foot was recommended in one study.¹⁰⁵ This transfer was suggested to assist with dorsiflexion, similar to its use in feet with paralysis. This transfer should never be used in spastic feet because it causes the worst deformed feet over time that we have ever seen (Figure 11.26). Most of these feet require triple arthrodesis in a very technically demanding procedure. There are a few children in whom the posterior tibialis muscle activity on EMG seems to have completely changed phase to match the tibialis anterior. These feet are theoretically ideal candidates for complete anterior transfer of the tibialis posterior. Although we have no experience with the long-term results with these narrow indications, our experience with the severe deformities noted above makes us hesitant to perform or recommend this procedure.

Transposing the tibialis posterior around the medial side of the tibia by moving it anterior to the medial malleolus has been advocated as well; however, this leads to a high number of severe cavus foot deformities, which again are harder to treat than the initial deformity.¹⁰⁶ This procedure is not recommended in children with varus deformities secondary to spasticity.

Split transfer through the interosseous membrane of half of the tibialis posterior has been recommended for use in children in whom the tibialis posterior is constantly active and for children who have significant varus in swing phase. Based on two studies, good results were reported in children.^{107, 108} We have no experience with this procedure; however, it seems to have a relatively narrow indication and it is not clear that there are real advantages over the standard lateral transfer, which is technically easier.

Anterior transfer of the long toe flexors has been advocated as a way of balancing the foot with spastic varus.^{109, 110} We have no experience with this procedure; however, it seems to be using muscles with extremely small force potential and is not theoretically sound on that basis.

A



B

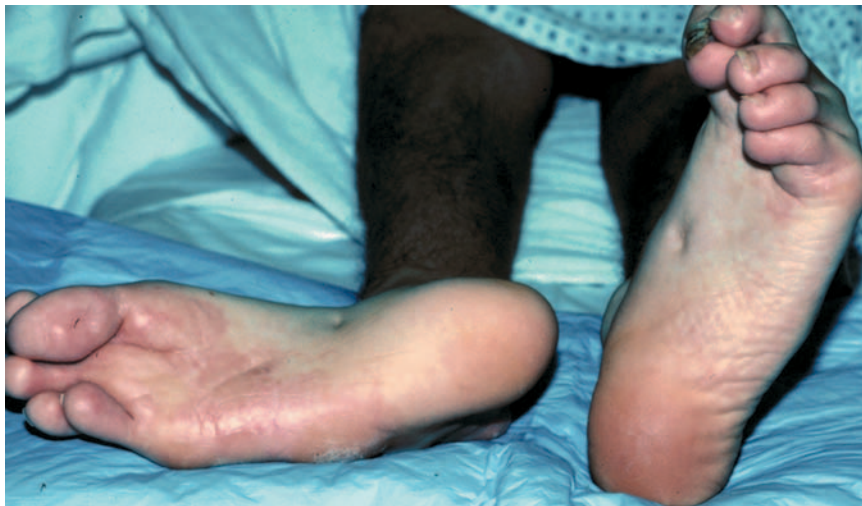

Figure 11.26. This boy with severe diplegia had a complete transfer of the tibialis posterior through the interosseous membrane to correct equinovarus at age 13 years. By age 17 years, he had developed such severe foot and toe deformities that he could no longer walk (A). The feet developed severe supination with claw toes (B). This procedure causes the worst deformed feet seen as a complication of surgery. Complete anterior transfer of the tibialis posterior is rarely indicated in spastic feet.

Complications of Treatment

Complications of varus foot deformity treatment are recurrent deformity and overcorrection. A mild valgus foot deformity is better tolerated than a mild varus foot deformity; therefore, the goal of treatment should be to get mild overcorrection. It is also important to recognize that the valgus attractor is stronger in ambulatory diplegia than the varus attractor; therefore, overcorrection in this population has to be done with extreme caution, especially in younger children.

The most commonly reported complication from tendon surgery to correct varus deformity is recurrent deformity, which is usually identified as a failure to correct the initial deformity completely, most often due to unrecognized hindfoot stiffness.^{95, 97, 111} This failure to recognize stiffness or contracture is a major cause of recurrent deformity, but in our experience, recurrence is more complicated than reported in most papers. Some of these children initially have a satisfactory result, but then are slowly drawn back toward the varus attractor as the varus gets worse with growth. The treatment of recurrent deformity usually requires a calcaneal osteotomy or a calcaneocuboid joint resection and fusion. Another attempt at foot balancing may need to be performed with the osteotomy, including a split tibialis

anterior transfer or lengthening of the residual tibialis posterior. A second split transfer is technically difficult to perform and not recommended because of the significant scar that is present from the initial procedure. This scarring makes splitting of the tendon longitudinally very difficult and runs a high risk of developing tendon ruptures. Other causes of recurrent deformity, such as a tear of the transferred tendon, undoubtedly occur but are very difficult to diagnose. In exploration of one such case, the tendon end was very hard to identify apart from the scar tissue.

Overcorrection is probably the most common complication, but it is largely missed or not perceived as significant. For many children, there is overcorrection into mild to moderate planovalgus; however, no complaints or clinical symptoms occur. Our experience has been that there are at least as many overcorrections needing surgery as there are recurrent deformities with long-term follow-up. The recurrent deformities occur more quickly and the overcorrections tend to come later, sometimes up to 10 years later, which is probably another reason why many short-term follow-up studies miss the overcorrections. Overcorrection into planovalgus requires treatment using the planovalgus treatment algorithm.

Planovalgus

Planovalgus deformity is the most common foot deformity in all ages of children with diplegia and quadriplegia.¹¹² Although planovalgus is commonly recognized, neither the natural history of the evolution of the deformity nor a detailed description of the pathologic anatomy of the deformity is defined in the published literature. The following description is based on our experience; however, there is a definite need for well-defined investigations in this area.

Etiology

The direct cause of planovalgus is multifactorial and includes muscle imbalance, abnormal forces, bony malalignment, genetic predisposition, and ligamentous structure response. In most children, it is impossible to assess each factor in a way that is helpful to predict the outcome. The best way to predict the outcome of the foot is to recognize that planovalgus is a very strong attractor, especially in ambulatory diplegia and in some quadriplegia. Muscle imbalance is much less clearly a major contributor to the etiology than it is in the development of equinovarus deformity. There have been reports of peroneal muscle EMG in children with CP in which no activity during stance phase is found.¹¹² Others have reported increased activity in some children.^{2,3} Some children have definite spastic and overactive peroneal muscles, which are major deforming forces pulling the foot into valgus. These spastic and overactive peroneal muscles are most common in nonambulatory children with quadriplegia but are occasionally recognized in ambulatory children. An abnormal force environment is the major factor in ambulatory children. This abnormal force comes from the stiffness caused by spasticity, in which the knee and ankle do not work as shock absorbers. Also, the poor motor control prevents the muscles in the feet from working as secondary shock absorbers. These repetitive high forces have to be absorbed by the bones, joints, and the connective tissue. The effect of these forces is to collapse the system into a direction in which there are more stable osseous constraints. Also, contractures of the gastrocnemius and soleus increase the force on the subtalar joint with a tendency to drive the joint into a collapsed position. Torsional

malalignments, especially external tibial torsion, add a moment that tends to further drive the planovalgus into a more severe deformity. Children primarily have cartilage in the bones of their feet and these increased forces deform the cartilaginous bones. These abnormally shaped bones with a large component of cartilage have less inherent structural stability.

It is well recognized that there are genetic and racial tendencies toward normal planovalgus foot deformity, and these genetic tendencies probably contribute to the initiation of planovalgus deformity in children with CP as well. Also, when the planovalgus deformity is initiated, there is increased tension on the ligamentous structures, such as the plantar fascia. As the deformity collapses, more force is applied and the plantar fascia stretches out, allowing more collapse. Although there are multiple causes of the initiation of planovalgus, the development of the deformity occurs over a long time frame, which is important in the treatment planning and interpretation of the outcome of the treatment.

Natural History

Children with diplegia usually start standing and cruising around 2 years of age. This standing is predominantly on the toes with an equinovarus foot position. For many of these children, the foot is clearly in hindfoot valgus with a decrease in the medial longitudinal arch when they stand foot flat. Another group of children stand early with severe planovalgus feet, and even when they stand on the toes, they are still in valgus in the hindfoot. From 2 to 6 years of age, there can be a dramatic change in these foot positions, with some of the severe planovalgus feet completely correcting (Case 11.17). This tendency for improvement of planovalgus feet in young children has been previously noted,²³ but the natural history of planovalgus feet has not been studied. In general, by 7 years of age, the planovalgus position will be as good as spontaneous correction can provide. This spontaneous correction probably is due to improving motor control, which starts to make a positive impact in controlling foot position because it occurs most in relatively high-functioning ambulatory children with diplegia. In middle childhood, the planovalgus foot position tends to be stable with little change. By adolescent growth, almost all children with some degree of planovalgus have some progression of the deformity, and this is the time when the foot usually becomes painful. In general, the pain comes from high pressure over the medial bony prominence, which is the talar head and navicular tuberosity. Often, the increased discomfort is associated with rapid weight gain and increased crouching.

Pathologic Deformity in Ambulators

Although it is important to understand the etiology and natural history of planovalgus feet, the treatment also depends on understanding the poorly defined pathologic anatomy. The anatomy of the subtalar joint is complex but well described in many anatomy texts. This anatomical description is based on the acetabulum pedis concept, which defines the talus as the ball structure articulating a cup structure made up of the calcaneus inferiorly and the navicular anteriorly that functions as an acetabulum^{113, 114} (Figure 11.27). In this anatomical concept, the foot articulates through the subtalar joint as a relatively rigid structure. The foot in this definition excludes the talus. The articulation of the talonavicular joint, middle facet, and anterior facet of the calcaneus makes a very elliptical acetabulum. Continuing to the posterior talus though, the posterior facet has an articulation that is out of the plane, with a condyle on the calcaneus that articulates with a plateau on the talus



Case 11.17 Tyler



Tyler, a 2-year-old boy, was noted to have an asymmetric diplegic pattern. He had just started independent ambulation, and his parents' primary concern was related to his severe flat feet. On physical examination the ankle dorsiflexion was to 20° with knee flexion and with knee extension. There was more spasticity on the left, but otherwise there was not much difference between right and left. The feet were clearly in severe planovalgus (Figure C11.17.1). He was placed in articulated AFOs to provide support for the feet. Over the next several years, the feet spontaneously improved, but by age 5 years, he had developed significant in-toeing and equinus on the left side. During this development, the tone and movement limitations on the right almost disappeared, and he developed a clear hemiplegic pattern. There was complete resolution of the planovalgus on the left with a mild residual on the right (Figure C11.17.2). At this time, he had a left-side-only femoral derotation osteotomy, rectus transfer to the sartorius, and lengthening of the hamstrings and gastrocnemius. One year after this surgery his right foot remained completely normal and the left foot had a mild planovalgus (Figure C11.17.3). This case shows the difficulty in predicting the outcome of feet in young children. The severe early planovalgus of the left foot completely resolved without any direct treatment, and the right foot made substantial improvements.



Figure C11.17.1

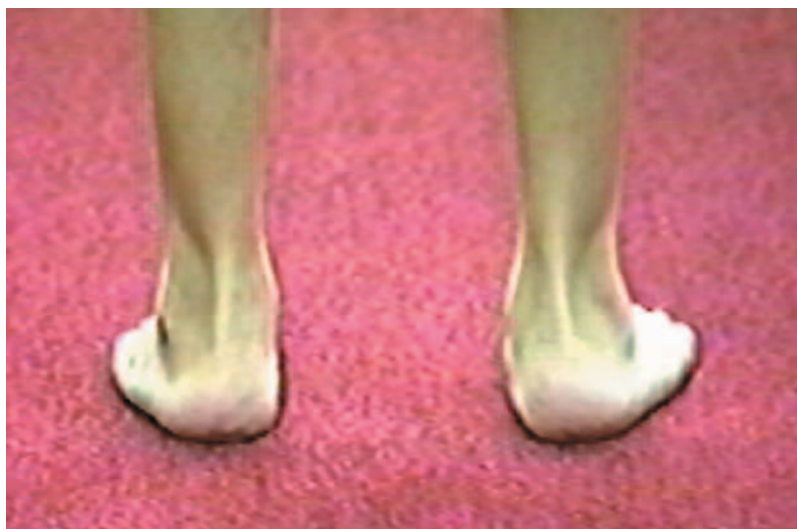

Figure C11.17.2

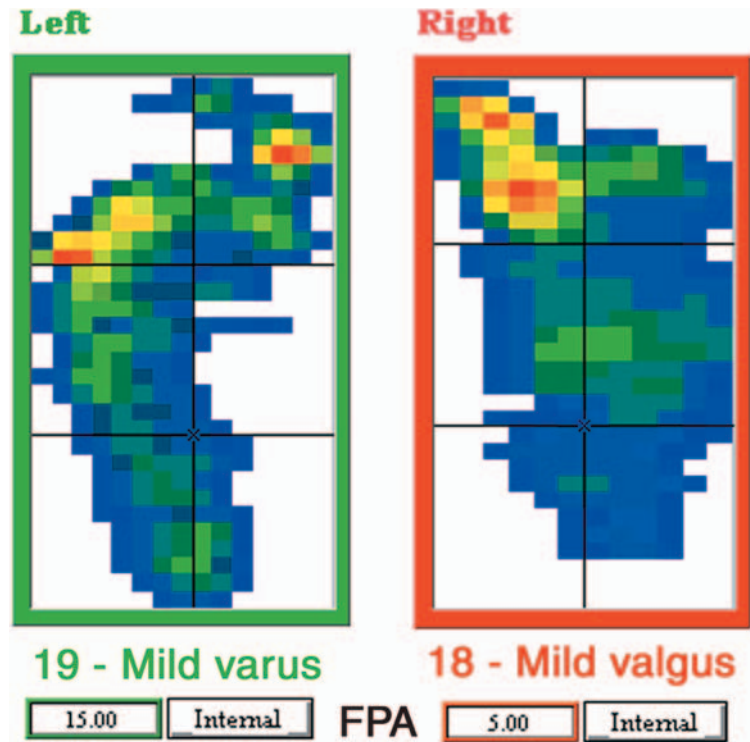


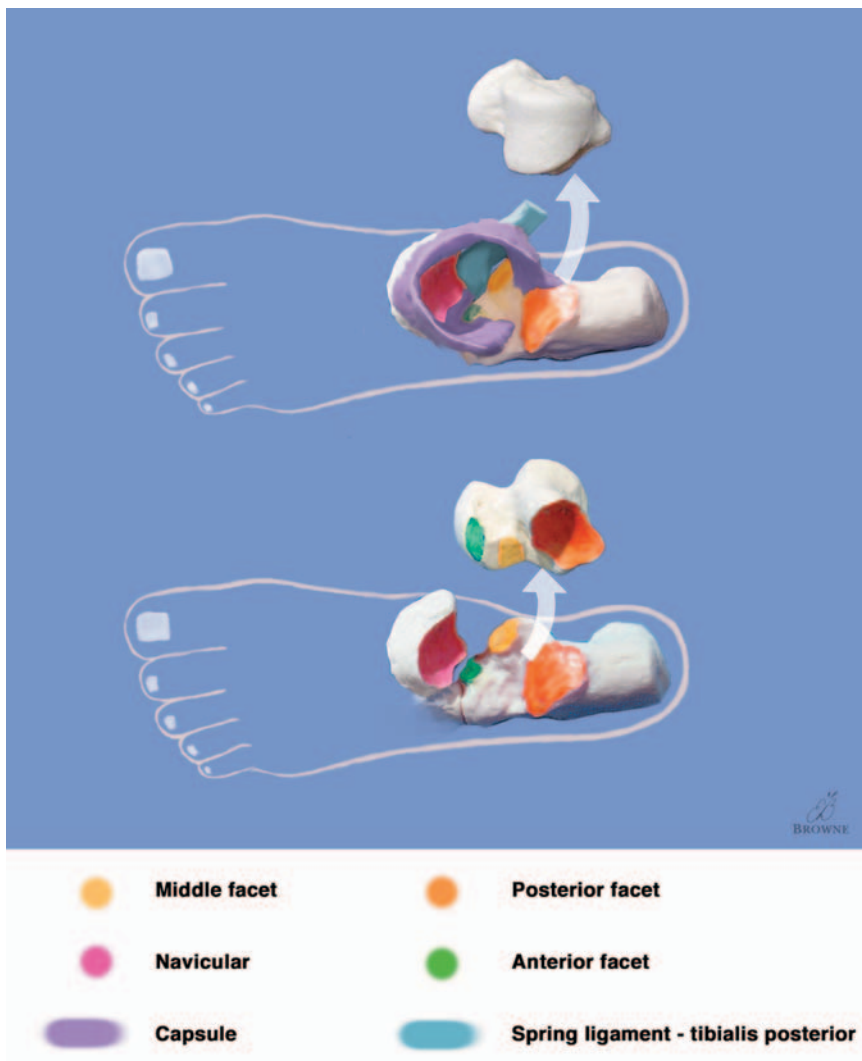
Figure C11.17.3

(Figure 11.28). With normal anatomy, this arrangement allows relatively free and easy movement of the anterior aspect of the foot joint, but is severely restrained by the out-of-plane posterior facet. This complex joint is ideal in providing a limited degree of free motion that can be controlled by the muscles, but has rigid and strong inherent stability created by weight bearing on the posterior facet. Because the posterior facet's arrangement with a condyle on the calcaneus and a plateau on the talus, the joint is stabilized naturally by weight bearing, especially by heel strike at foot contact, which loads the posterior facet. This construct allows much freer movement in nonweight-bearing or low-weightbearing environments such as preswing and swing phase. The freer movement is allowed as the weight bearing shifts to the acetabular-shaped anterior joint with the implication that more varus and valgus motion is possible at toe-off or with weight bearing on the forefoot.

Primary Pathology

In the development of planovalgus pathologic deformity, the foot moves into valgus, external rotation, and dorsiflexion relative to the talus. As this deformity increases, the head of the talus becomes uncovered medially and inferiorly. As dorsiflexion of the foot relative to the talus increases, the condyle of the posterior facet is subluxated out of the plateau of the talus, allowing posterior movement of the calcaneus on the talus, which allows more external rotation and dorsiflexion of the foot. In this process, there is great variation in the relative degree and specific direction of motion. Some feet collapse mainly into valgus, and others have more external rotation and dorsiflexion. This progressive cycle proceeds until the calcaneus has dorsiflexed and moved posterior to the limits allowed by the soft tissues. Subluxation of the anterior talus out of the acetabulum pedis is a primary pathologic motion

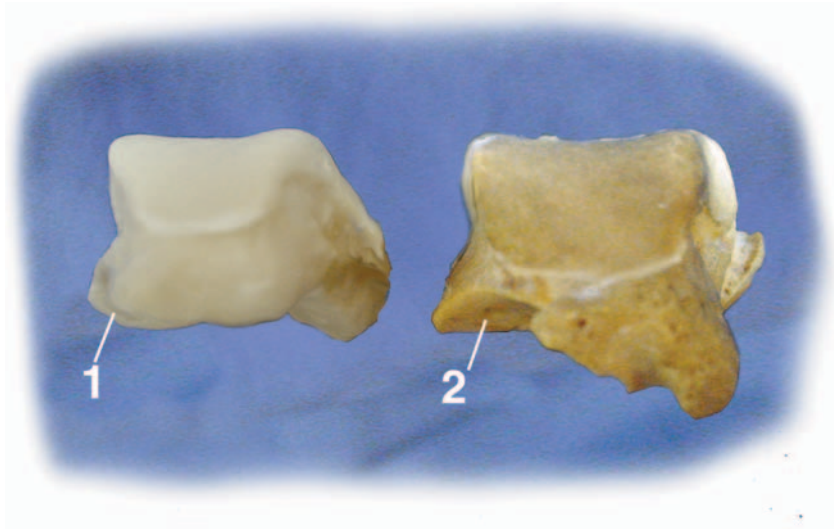
Figure 11.27. The complex shape of the subtalar joint is designed to provide stability in weight bearing and mobility in swing. The anterior aspect is an oblong acetabular type structure that articulates with the head and neck of the talus. This structure is called the acetabulum pedis and is bordered anteriorly by the navicular, medially by the spring ligament, and inferiorly by the anterior and middle facets. The posterior facet has a condyle on the calcaneus and a plateau on the inferior talus. Upon weight bearing, this joint stabilizes especially when the posterior facet is compressed and then locked against the out-of-plane and oblong acetabulum pedis. In swing phase with the posterior facet loose, the mobile acetabulum allows easy and free motion of the hindfoot.



allowed in part because of an acetabular dysplasia pathology created by changes in the articulations between the navicular and calcaneus, and the calcaneocuboid joint; however, there are secondary adaptations that also occur and may become progressive drivers of the pathology of planovalgus.

In acetabular dysplasia of spastic hip disease, the initial abnormal force causes the hip to move laterally out of the joint. However, if there is no alteration of this abnormal force, the acetabulum deforms by opening up as a result of the force on its edge. This same process occurs in the acetabulum pedis in the foot. As the foot moves into planovalgus, the abnormal force in this position continues to drive the deformity into further planovalgus, which then starts to deform to the acetabulum pedis. The initial deformity occurs on the medial side where the head of the talus becomes uncovered and opens up the ligamentous and bony restraints, allowing it to subluxate medially and inferiorly (Figure 11.29). Also, the acetabulum deforms through the articulation of the calcaneocuboid joint, which subluxates with the cuboid moving superiorly and laterally relative to the calcaneus. In the posterior facet, the plateau on the talus tends to open up and become dysplastic on the posterior lateral aspect, allowing the condyle of the calcaneus to subluxate posteriorly and medially.

A



B

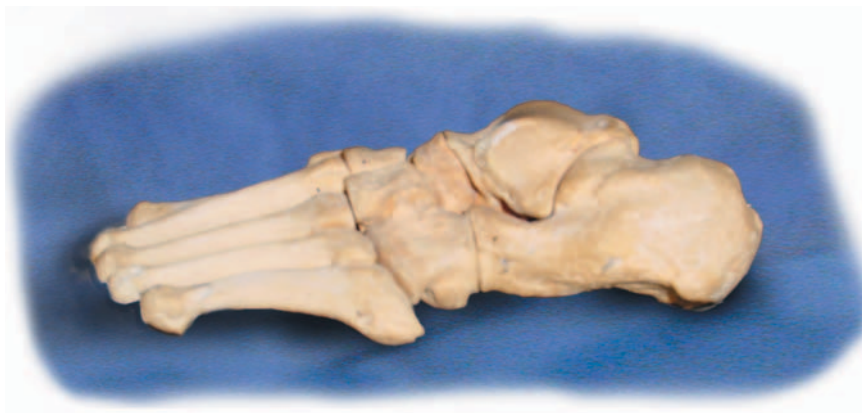

Figure 11.28. As the planovalgus deformity develops, the posterior lateral edge of the talar plateau of the posterior facet becomes dysplastic (A-1) compared to the normal posterior facet (A-2), allowing the calcaneus to subluxate posteriorly. As the calcaneus displaces posteriorly, it becomes more unstable with weight bearing on the posterior facet, which now allows it to rotate into valgus and spin further externally relative to the talus. As the talus spins medial and slips anterior on the calcaneus, the sinus tarsi is obliterated (B).

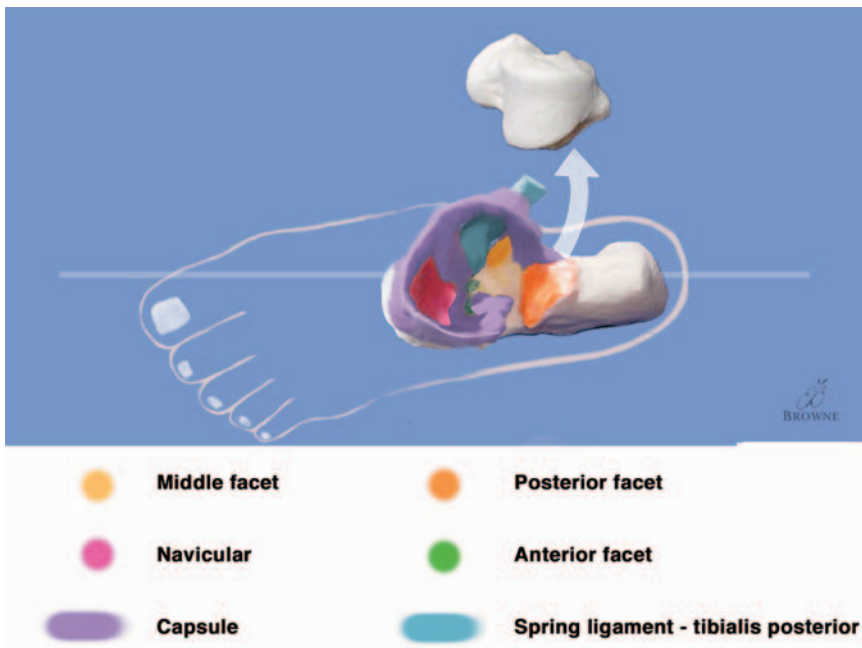


Figure 11.29. Just as the posterior facet becomes dysplastic with increasing planovalgus, the acetabulum pedis also deforms in a process that is very similar to the acetabulum of the hip. The containing cup opens up with stretching of the medial spring ligament, and dysplasia of the middle facet allows the head of the talus to subluxate medially and drop inferiorly. Increased instability in the calcaneocuboid joint can allow the medial aspect to stretch open as the forefoot abducts relative the calcaneus. Therefore, as the posterior facet has become less stable in weight bearing of stance, the dysplasia of the acetabulum pedis makes the hindfoot even less stable and allows more collapse of the foot into valgus, abduction, external rotation, and dorsiflexion.

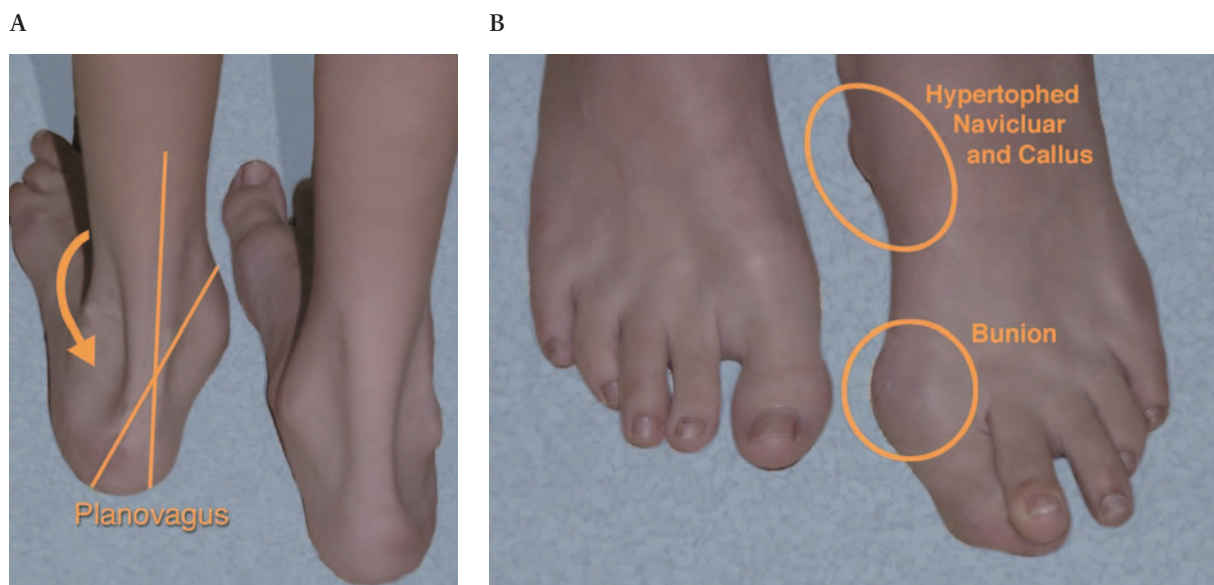


Figure 11.30. A major cause of planovalgus in children with CP is a high force environment. This often starts with the child toe walking, a condition that places high force on the subtalar joint. As the child gets heavier, the force increases and the joints start to collapse into external rotation and valgus, which decreases the plantar flexion ability of the gastrosoleus (A). As the planovalgus collapse proceeds further, the navicular and head of the talus become major weightbearing areas, now decreasing the force to cause further planovalgus deformity. However, these areas do not tolerate the high weightbearing stress and often become painful (B). Another tertiary response of the foot pronating and externally rotating is the development of a bunion from weight bearing on the medial surface of the hallux (B).

Secondary Pathology

As part of these secondary deformities, the calcaneus is almost always in significant dorsiflexion relative to the talus; however, the talus is in a severe equinus relative to the tibia, and the calcaneus is usually in equinus relative to the tibia. These deformities are primarily driven by spasticity or contractures from the gastrocnemius, but sometimes include the soleus as well (Figure 11.30). This process of the talus going into severe equinus with calcaneal dorsiflexion relative to the talus causes the height of the talus to decrease, which makes the degree of gastrocnemius contracture less obvious. It is not clear if the gastrocnemius contracture is a cause of the deformity or is a secondary adaptation to the progressive planovalgus collapse. The gastrocnemius contracture is probably a little bit of both in most children. If the gastrosoleus is not contracted but is incompetent, such as following a tenotomy of the Achilles tendon, a cavovalgus deformity develops as the long toe flexors work against a spastic tibialis anterior. The hindfoot deformities are almost the same; however, the midfoot collapse is in the opposite direction (Case 11.10).

Just as the hip finally develops a complete dislocation that is followed by progressive deformity of the femoral head, there are many tertiary deformities of planovalgus. As the planovalgus gets worse, the collapse of the acetabulum pedis finally becomes stable at some level, with the calcaneus lying up against the talus and completely obliterating the sinus tarsi. By this stage, there are significant secondary deformities, and this is when many of the tertiary deformities develop and progress. Because the foot has developed a stable location, it now bears weight without absorption of the force; however, this drives the force absorption to other locations. Because of the position of the foot in severe planovalgus with external rotation and valgus, the force tends to place a large external valgus moment on the ankle joint.

Tertiary Pathology

A tertiary deformity of planovalgus at the ankle develops as the growth plate of the ankle decreases its growth on the lateral side secondary to high forces, and ankle valgus develops. With longer-standing deformity, the fibula also has retarded growth and more ankle valgus develops. Also, because the hind-

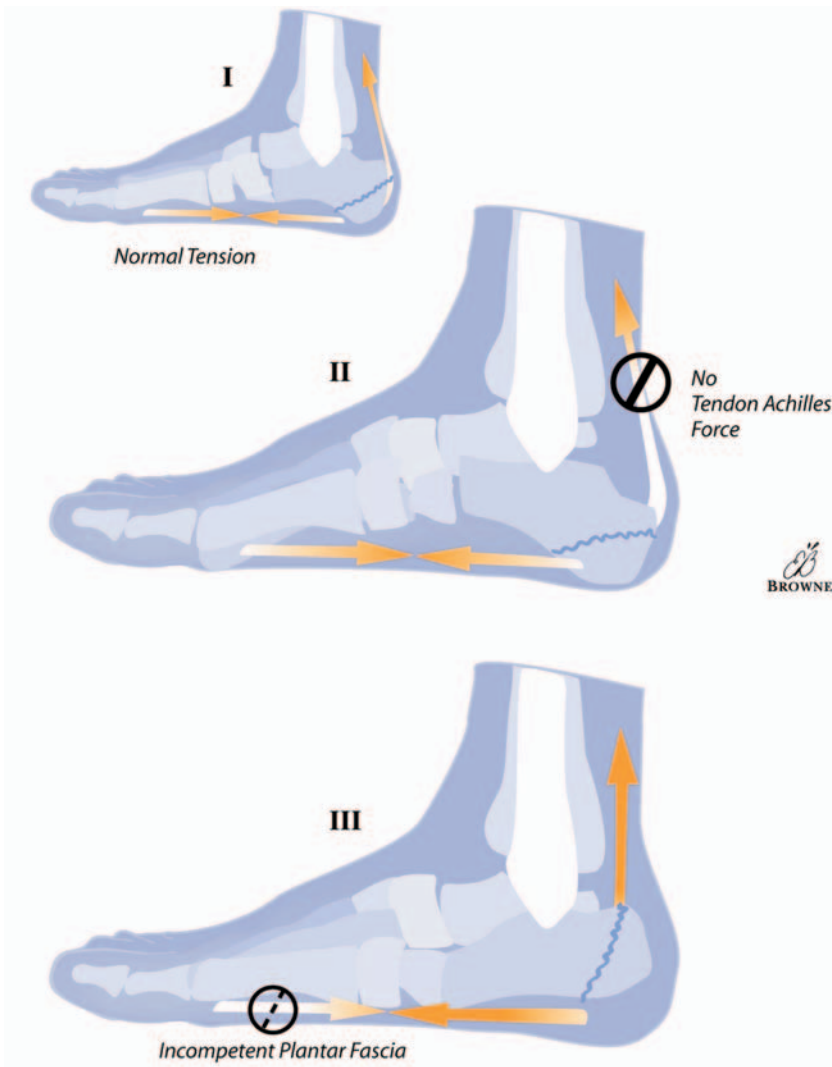


Figure 11.31. Just as the femur develops coxa valga secondary to abnormal muscle force, the calcaneus also changes shape based on the muscular environment. For the normal foot, the combination of tension in the plantar fascia combined with tension, from the tendon Achilles, causes the calcaneal apophysis to elongate. This elongation is in a direction that produces the normal calcaneal tuberosity, directed by the underlying principle that the epiphyseal plate is orienting itself so as to minimize the principle shear stress. By applying this same principle, the foot with severe planovalgus and an incompetent plantar fascia develops an elongated calcaneus because the apophysis grows posterior and proximal. On the other hand, if the child has had the tendon Achilles transected so it is incompetent, all the force on the calcaneal apophysis comes from the plantar fascia; therefore, the calcaneal tuberosity becomes almost vertical as the growth is responding to decrease the summated principal shear stress.

foot is now stable, there is more stress transmitted to the midfoot, where a breakdown tends to develop. The primary site of collapse is the cuneonavicular joint, in which the medial cuneiform subluxates superiorly as the joint rounds out at the edge. Because most of the weight is borne on the medial midfoot with advancing planovalgus deformity, the navicular responds to this weight bearing with hypertrophy of the tuberosity. Also, because the advanced degree of planovalgus causes medial foot weight bearing in terminal stance, this weight bearing tends to be on the medial side of the hallux, which causes a hallux valgus (Figure 11.30). Another tertiary deformity that can be propagated by severe planovalgus is external tibial torsion, which is made worse with external rotation moment produced by the planovalgus in mid- and terminal stance. Often, crouched gait is primarily caused by severe planovalgus deformity, which greatly reduces the effective moment arm at the ankle needed to control the knee and ankle joint motion in stance phase. Growth of the calcaneal tuberosity is another tertiary effect (Figure 11.31).

Pathologic Deformity in Nonambulators

There are children who are nonambulators who nevertheless develop severe planovalgus foot deformities. These children are those with severe spasticity,



Case 11.18 Sierra

Sierra, a 16-year-old girl with severe spastic quadriplegia, presented with her mother who complained of frequent skin breakdown over the prominent medial side of the severe planovalgus foot (Figures C11.18.1, C11.18.2). She was 180 cm tall, which made it almost impossible to get a nonweightbearing foot box. Because of her height, the feet had to rest on the footrest. Her mother was currently using AFOs with a specially molded and padded medial segment; however, she was also getting skin erythema while she was in some bed positions. Because of these

difficulties, she had a correction of the deformity with a triple arthrodesis, which corrected the deformity and alleviated the symptoms.

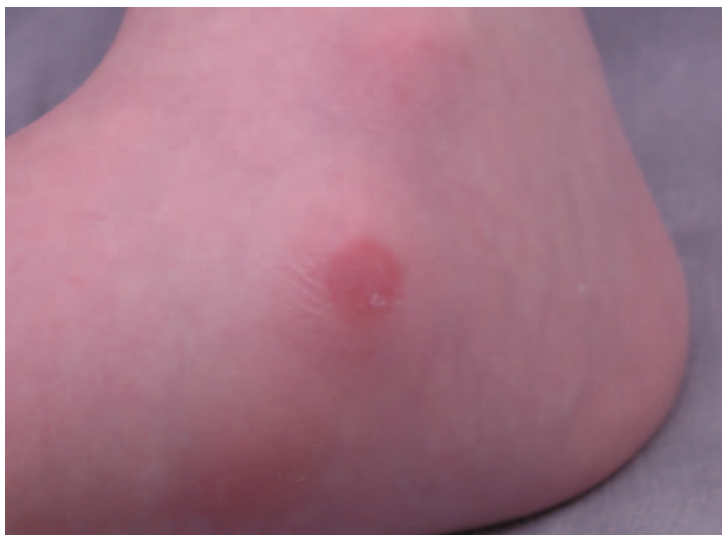

Figure C11.18.1

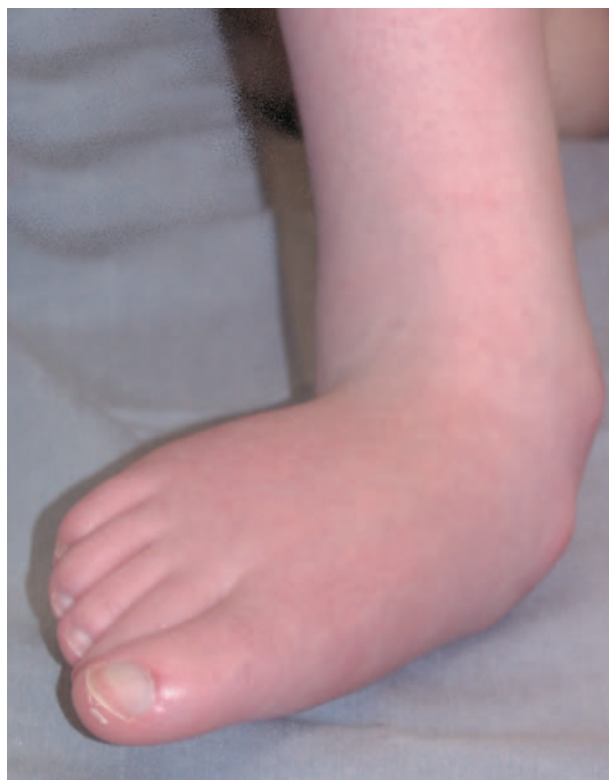

Figure C11.18.2

and the cause of the spasticity is the major etiology of the planovalgus collapse. These children have the same direction of collapse and may develop similar secondary and tertiary changes. The major difference is the severe contractures of the peroneal, gastrocnemius, and tibialis anterior tendons. Often, the only muscle that does not have a severe contracture is the tibialis posterior. As tertiary changes occur, many of these feet develop severe mid-foot breaks so the forefoot is hyperdorsiflexed and the hindfoot is in a severe equinus (Case 11.18).

Diagnostic Evaluations

One of the most difficult problems of planovalgus foot deformities is that there is no definitive imaging study to identify and follow the deformity. Many radiographic angles have been defined^{2,3}; however, the variation of

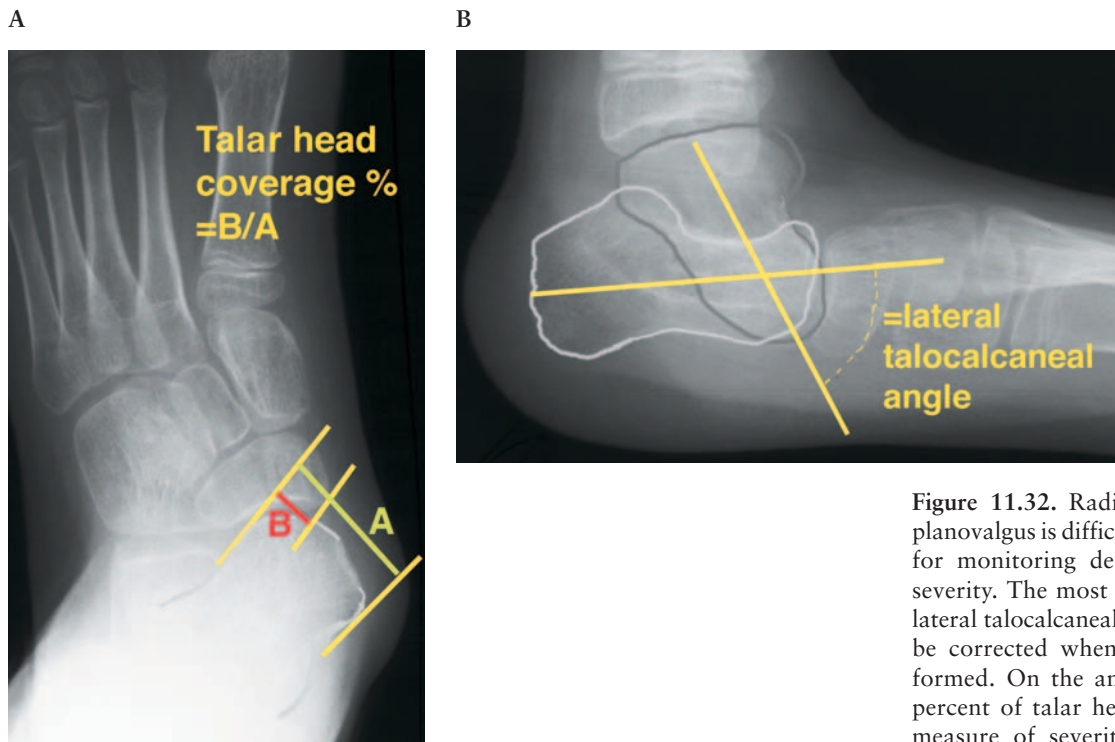


Figure 11.32. Radiographic assessment of planovalgus is difficult and of marginal value for monitoring deformity progression or severity. The most useful measures are the lateral talocalcaneal angle (B), which should be corrected when reconstruction is performed. On the anteroposterior view, the percent of talar head coverage is the best measure of severity (A). Other common radiographic measurements of foot position include tibial-talar angle, talo-first metatarsal angle (B), talocalcaneal angle, and calcaneal-sole angle.

measurements is so large that these have very little use in individual children. One problem is that many of these children have difficulty standing for consistent positioning during radiographic imaging, and nonweightbearing radiographs are so variable as to be of little use. The measurements from weightbearing films that have some merit are the talar head coverage percentage, which is a measure similar to the migration percentage of the hip¹¹⁵ (Figure 11.32), and the calcaneus-to-talus angle measured on the lateral radiograph. These measures are better as evaluations of the degree of correction after surgical procedures than as measures to follow in planning treatments. The goal of treatment is to obtain a talocalcaneal angle in the lateral view of 20° to 30°, and the talar head should show more than 75% covering after an operative correction. Attempts at using computed tomography (CT) scan have not been helpful.

The primary study that yields excellent reproducible data is the pedobarograph. We have developed a quantitative measure based on the amount of weight bearing on the lateral side versus medial midfoot and forefoot called the impulse index. This single measure is highly correlated to physical examination impression of the severity of foot deformity. This diagnostic evaluation is very useful to quantify the severity of the deformity and the response to treatment; however, it does not add much information to define the anatomical pathology.

Treatment

Treatment algorithms of planovalgus feet suffer from a lack of natural history information, and almost no published study clearly defines the reported indications for the procedures. No studies have clear outcome evaluations beyond a few radiographic measures to determine if the procedure succeeded.

Indications

Treatment is based on the severity of the deformity, and it would be nice if the treatment algorithm of prevention, reconstruction, and the palliative treatment approach used in the hip could be used for a planovalgus foot. Although these same concepts will be used, they do not work as well because the natural history is not defined and there is less clear difference between reconstruction and palliation.

The ideal treatment is prevention; however, to know if prevention works, the natural history needs to be known. For instance, how many children have spontaneous resolution of planovalgus feet, which is present at age 2 years, and how old children can be for significant planovalgus deformity to still develop, are all unknown. There have been recommendations that peroneal muscle lengthening should be done in young children with planovalgus to prevent later severe deformity. Results were reported to demonstrate improvement; however, these results have to be interpreted with great caution because they may represent only the natural history.¹¹⁶ On the other hand, others have found a high rate of overcorrection with peroneal muscle lengthening.²³ This high rate suggests that muscle lengthening makes a difference because the valgus attractor is clearly stronger than the varus attractor in diplegia, so converting valgus feet to varus feet would seem to be changing the natural history. However, this change is not completely positive as feet function better in a little valgus than a little varus, so this type of prevention does not produce the desired change (Case 11.15).

The use of orthotics is therefore the only preventative treatment at this time, and there are no objective data on the impact of orthotics on the long-term evolution of planovalgus deformity. One theory suggests that continuous bracing of planovalgus feet will decrease the abnormal deforming forces and prevent the bone deformities, as well as the secondary and tertiary deformities, from developing. This continuous bracing, however, causes atrophy of the muscles, which should control and correct the planovalgus deformity. The second theory suggests that the muscles, especially the tibialis anterior and tibialis posterior, should be strengthened and stimulated to actively correct planovalgus. Bracing, which tends to atrophy the muscles, will only lead to worse long-term collapse as the muscles have no strength to resist the evolving deformity. Because there are no data to back up either theory; clinicians can choose. There is some merit with each approach. Using orthotics is favored during periods of most stressful walking, such as long-distance community ambulating, but children should be out of orthotics for some play time during the day and at home, especially in the evenings.

Reconstruction

Reconstruction of the secondary deformity is indicated when the planovalgus is causing children pain and difficulty with orthotic wear. When the deformity is getting worse, as determined by the pedobarograph or physical examination, surgical correction is also a relative indication. There are two approaches to recommending reconstruction of moderate planovalgus feet. One argument is that the correction should be made early, when the deformity is not so severe, because the correction will be easier and better; however, this often means children have surgery for the planovalgus between the ages of 4 and 7 years. The negative side of this argument is that some of these operative procedures will fail and children will develop planovalgus deformity again, needing a second operation at adolescence or late childhood. The second approach is to wait until the deformity is so severe that children are having symptoms from the deformity, usually at 10 to 14 years of age, then

correct the deformity. By this age, the deformity will almost always be worse, requiring more involved surgery; however, the recurrence will be very low. In our estimation, there is no clear advantage to either of these approaches; however, it is usually unwise to correct the planovalgus in very young children, especially those of less than 5 years of age unless the deformity is exceedingly severe, because many of these children will show natural improvement. After age 5 to 7 years, very little of this natural improvement continues, based on our experience. Therefore, correcting planovalgus in the 5- to 7-year-old age group can be considered; however, unless planovalgus is severe, waiting until at least late childhood or adolescence makes more sense. As tertiary deformities, such as external foot progression, crouch, and hallux valgus increase, correction of the planovalgus is more clearly indicated.

Lateral Column Lengthening

There are many options to correct the primary deformity, which is the hypermobility of the talus in the acetabulum pedis. The options, which are in widespread use, are intraarticular (acetabulum pedis) osteotomy, arthrodesis of the subtalar joint, extraarticular osteotomy, and sinus tarsi motion blockade. The intraarticular osteotomy, meaning it enters the acetabulum pedis although it does not actually go through a synovial joint, is also called the lateral column lengthening calcaneal osteotomy as originally described by Evans.¹¹⁷ This osteotomy is performed across the calcaneus between the middle and anterior facets. The osteotomy is then distracted, which pushes the foot anterior to the osteotomy further anterior, and internally rotates the foot at the same time, driving it into supination and thereby correcting the major primary deformity. By lengthening the calcaneus, the collapse of the calcaneus into dorsiflexion into the sinus tarsi is blocked, and again, locks the condyles of the calcaneus into the talar plateau in the posterior facet. This operative procedure may also push the posterior fragment further into posterior subluxation depending on the degree of dysplasia of the plateau of the talus. The osteotomy is blocked open with a piece of bank bone graft and fixed with a K-wire or small plate. The foot is immobilized in a short-leg walking cast for 10 to 12 weeks until the osteotomy is healed. Postoperatively, if children still have a tendency toward valgus, the foot can be supported with a supra-malleolar orthotic for periods of heavy weight bearing (Case 11.19).

The advantage of this procedure is that mobility of the subtalar joint is preserved, although there is a significant decreased range of motion, especially compared with a normal foot. This operation works best on feet that are supple, with milder deformity. There is no specific age limit; however, the procedure is not indicated for severe deformity in which there is fixed valgus, or severe joint hypermobility as seen in some children with hypotonia. The calcaneal lengthening osteotomy is indicated only in children with reasonable ambulatory skills, meaning at minimum full-time community ambulators with an assistive device. This osteotomy is most reliable in ambulators who are not dependent on walking aids, and it is not indicated in nonambulatory quadriplegic planovalgus deformity. The reason this operation works over time depends on children having some inherent motor control; which is apparently why it is best in feet that have enough motor control to enable individuals to be community ambulators.

Subtalar Fusion

If children have less motor control, especially those who are household ambulators or have lower function, severe hypermobility of the subtalar joint, or a severe planovalgus deformity, a subtalar fusion is the preferred treatment (Case 11.20). This treatment allows the reduction of the calcaneus to



Case 11.19 Katherine



Katherine, 6-year-old girl with spastic diplegia, presented as an independent ambulator with a complaint of having increased foot pain after long-distance walking, and she had increased difficulty with her in-shoe foot orthotics. The other major complaint from her mother was that she tripped frequently and wore out the front of her shoes every 3 months. The physical examination demonstrated a moderate flexible planovalgus bilaterally, which was slightly worse on the left. Observation of her gait demonstrated planovalgus feet with external foot progression angle, forefoot strike, and minimal heel contact with a stiff knee gait in swing phase. Popliteal angles were 60° bilaterally, ankle dorsiflexion was to neutral with knee flexed and to 10° with the knee extended. Kinematic evaluation showed significant rectus activity in the first half of swing phase and delayed and low knee flexion in swing phase. Preoperative radiographs of the feet showed the equinus of the calcaneus and talus relative to the forefoot (Figure C11.19.1) and the uncovering of the head of the talus medially with forefoot abduction (Figure C11.19.2). She had bilateral lateral column lengthening of the calcaneus, distal hamstring lengthening, rectus transfers, and gastrocnemius lengthening. Three months following surgery, she had increased pain on the right side and the radiograph showed a displaced osteotomy with callus

formation (Figure C11.19.3). No activity change was recommended. One year after surgery, her feet were well corrected and free of pain. At age 13 years, 6 years following surgery, excellent correction was maintained even with some slight overcorrection into varus on the right side (Figures C11.19.4, C11.19.5, C11.19.6). She had no pain in her feet. This case demonstrates an excellent result due partially to her high-functioning ambulation and initial moderate degree of deformity. This is the ideal case for calcaneal lengthening.

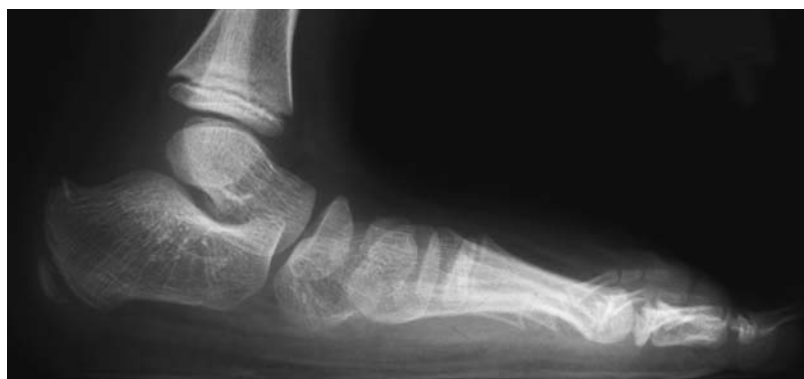

Figure C11.19.1

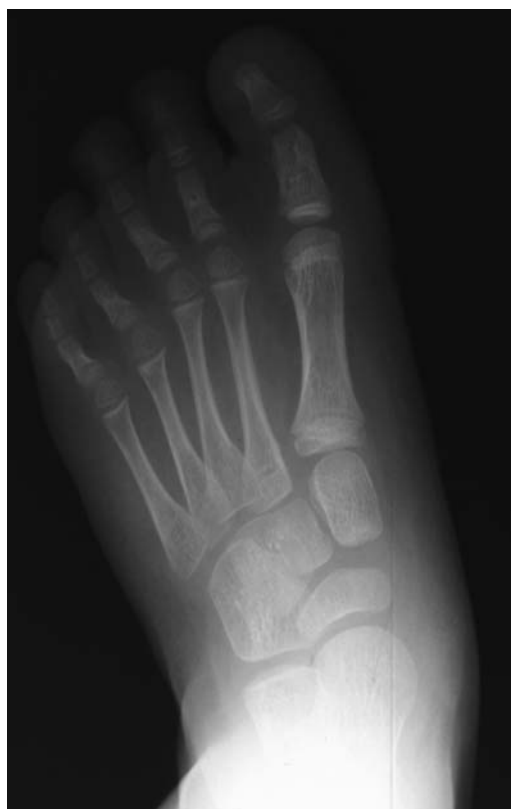

Figure C11.19.2

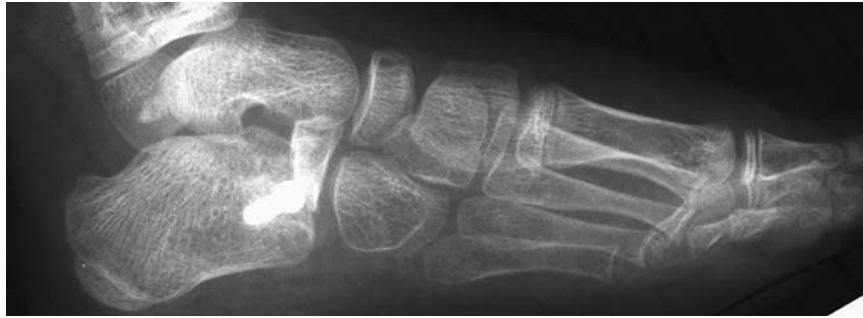

Figure C11.19.3

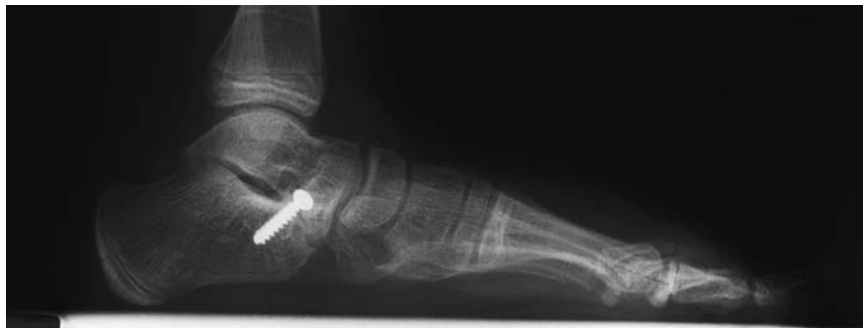

Figure C11.19.4

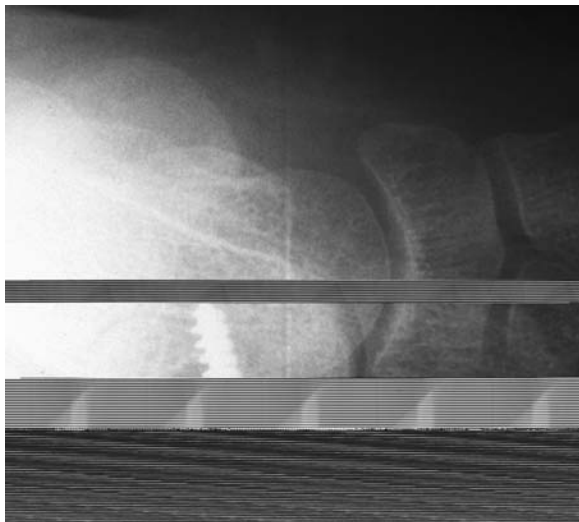


Figure C11.19.5

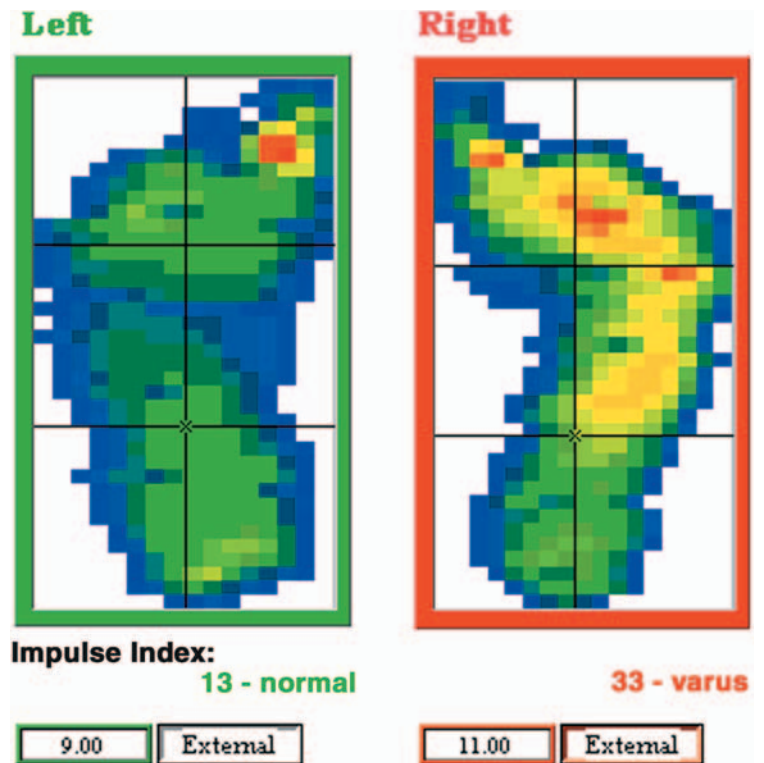


Figure C11.19.6



Case 11.20 Cameron

Cameron, an 8-year-old boy with mild asymmetric diplegia and ataxia, complained of pain in the right foot. His parents noted that he frequently tripped over the right foot. On physical examination he was noted to have mild spasticity in the tibialis posterior, and the gait analysis showed normal timing of the tibialis anterior. Therefore, it was presumed that he had an overactive tibialis posterior as the cause of his varus deformity. A split tibialis posterior was performed with a gastrocnemius lengthening. Six months after the surgery, the foot was in excellent position. However, 4 years later when Cameron was 13 years old, he complained of increased foot discomfort when he walked. He was still a full community ambulator. Observation of his gait demonstrated external progression angle with a planovalgus foot on the right side. On physical examination no contractures were noted, except the ankle dorsiflexion with the knee extended was -7° with the foot in subtalar neutral. With knee flexion the dorsiflexion increased to 10° . The subtalar joint was very mobile and there was a good medial arch without apparent forefoot supination. The right foot radiograph showed the typical hindfoot collapse (Figures C11.20.1, C11.20.2). The foot pressure showed weight bearing on the medial forefoot and heel with an impulse index of 47 valgus and a 10° external foot progression angle. He had a subtalar fusion and gastrocnemius lengthening (Figures C11.20.3, C11.20.4). During the correction of the deformity, the posteriorly displaced calcaneus had been brought anterior so the anterior aspect of the calcaneus and talus were at the same level. On the anteroposterior view, the head of the talus was completely covered by the navicular. One year after surgery, he had a normal foot pressure with an 8° internal foot progression angle (Figure C11.20.5). This example demonstrates the ideal case for a subtalar fusion in that he had a very mobile hindfoot with no midfoot or

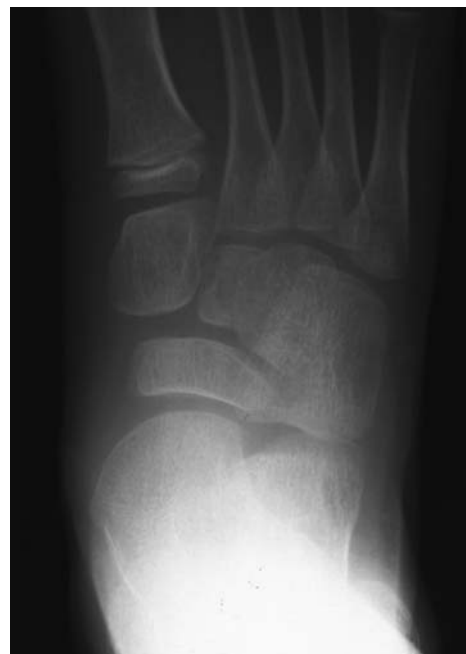

Figure C11.20.1

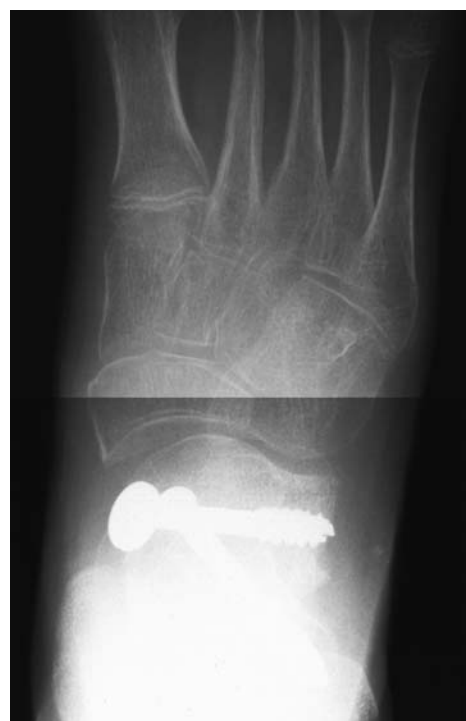

Figure C11.20.3

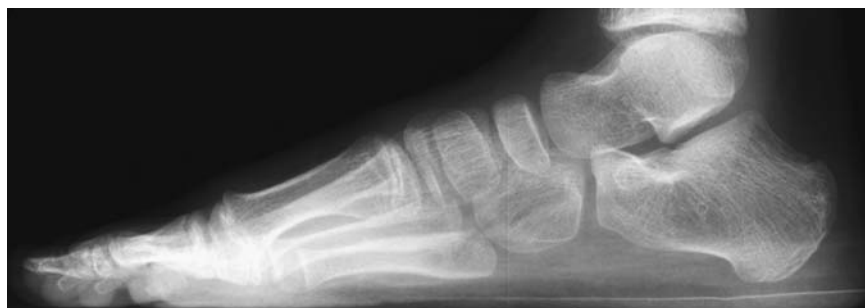

Figure C11.20.2

forefoot deformity. The hypermobile hindfoot does not hold up well after lateral calcaneal lengthening, and this combination of ataxia, hypermobile joints, and diplegia

is at high risk of going from varus deformity to over-correction into valgus.

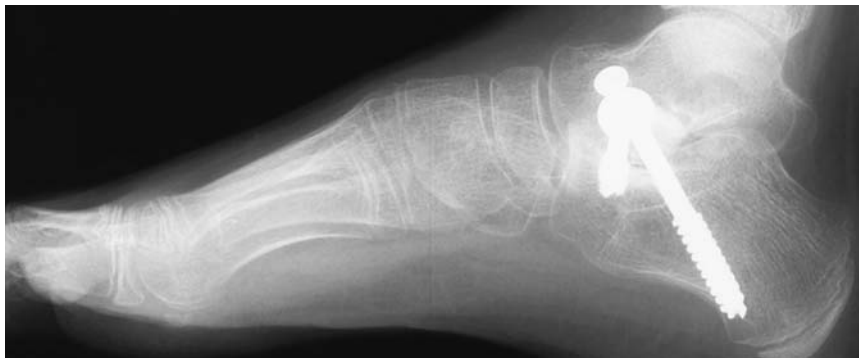

Figure C11.20.4

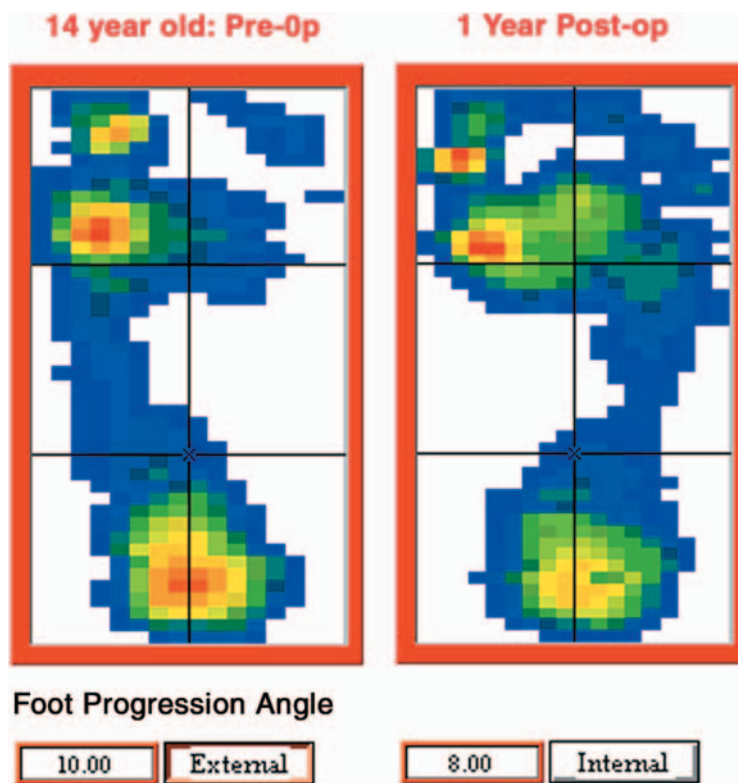


Figure C11.20.5

its normal relationship with the talus and then allows it to be rigidly fixed and fused in this corrected position. This procedure has the advantage of being permanent and removes motion from the subtalar joint. However, this fusion will cause the force to be absorbed in the surrounding joints. For this reason, high-functioning ambulators have the most potential for problems during a lifetime, with increased force concentration in the midfoot and ankle

joint. Before the subtalar joint is fused, the joint must be reduced to an anatomically normal position, meaning the anterior facet has to be reduced with the lateral angle of the calcaneus and talus being between 20° and 30°. The primary fixation should cross the anterior facet, as this is the point farthest from the center of rotation creating the planovalgus deformity. Bone graft is then placed in the sinus tarsi and into a small tunnel in the posterior facet. Usually, the foot is immobilized in a weightbearing cast for 12 weeks. If significant secondary deformities are present, correction of these deformities is required concomitantly with the calcaneal lengthening osteotomy or subtalar fusion. The ankle valgus and tibial torsion must be corrected if they are significant deformities. The midfoot problems with the medial side first ray elevation or forefoot supination must also be corrected concurrently. Hallux valgus is another frequent tertiary problem that should not be overlooked. Each of these deformities is discussed in separate sections. Another very closely related problem is subluxation of the calcaneocuboid joint on the lateral side, causing collapse of the lateral or peroneal arch.

Calcaneocuboid Lengthening Fusion

Calcaneal lengthening can also be accomplished by excision of the calcaneocuboid joint and adding bone graft to do a lengthening fusion at this level (Case 11.21). For more severe deformities, correction of the lateral column or peroneal arch first requires that the calcaneus and talus be reduced and the calcaneus be placed in dorsiflexion relative to the tibia. After this correction is accomplished with a calcaneal lengthening or a subtalar fusion, careful inspection of the calcaneocuboid joint should be done to see if it is subluxating superiorly or laterally. If instability of the joint is noted by direct inspection, the joint capsule should be opened and a visual inspection of the joint performed. If significant subluxation or hypermobility is occurring, either a partial osteotomy of the dorsolateral side of the calcaneus, or excision and fusion of the calcaneocuboid joint, should be performed. This procedure should accomplish the task of creating a peroneal longitudinal arch on the lateral side of the foot.

Triple Arthrodesis

Palliative treatment of severe valgus deformities, usually in children who are nonambulators or are marginal ambulators, requires a major series of fusions. This operation is also indicated in a few ambulators who have developed severe foot deformities after previous surgeries. A severe foot deformity is the indication for a triple arthrodesis, with extensive correction of the medial column supination by distal extension of the fusion, as discussed in the section on forefoot supination. This triple arthrodesis can be a challenging operation, and it requires a careful reduction and fixation of each bone into its anatomically correct location. First, the calcaneus is reduced to the talus and then fixed with a screw across the anterior facet. The cuboid is then reduced to the calcaneus by excision of the calcaneocuboid joint and insertion of a graft, which will lengthen the lateral column and reestablish the peroneal arch. Next, the navicular should be reduced to the talus and an excision of the medial cuneonavicular joint performed with the goal of at least fusing the talonavicular and cuneonavicular joints. Each of these joints has to be rigidly immobilized with either a plate, typically used on the calcaneocuboid joint, or internal fixation with strong K-wires, usually used on the medial column. Tendon Achilles lengthening and other tertiary deformities as indicated are corrected at the same time.



Case 11.21 Austin

Austin, a 14-year-old boy with moderate spastic diplegia, was evaluated because of painful shoe and orthotic wear. Physical examination demonstrated severe but flexible planovalgus deformities of the feet. There were no toe deformities, and torsional alignment was external foot progression of 30°. He was very crutch use dependent and he was a functional community ambulator. Radiographs demonstrated typical planovalgus deformity of the feet (Figures C11.21.1, C11.21.2). He had a subtalar fusion with a lateral column lengthening (Figure C11.21.3). After the surgery, he was left with a significant elevation of

the medial column showing dorsiflexion of the first ray, which was present and overlooked during the procedure. This error caused him to develop high lateral foot weight bearing, as the medial column would not bear weight. Because of poor knee control and tendency for back-kneeing, he used AFOs, which were of some help; however, due to the crutch use, he would still back-knee with the AFOs. This case demonstrates the importance of not overlooking any of the deformities that are present at the time of the reconstruction.

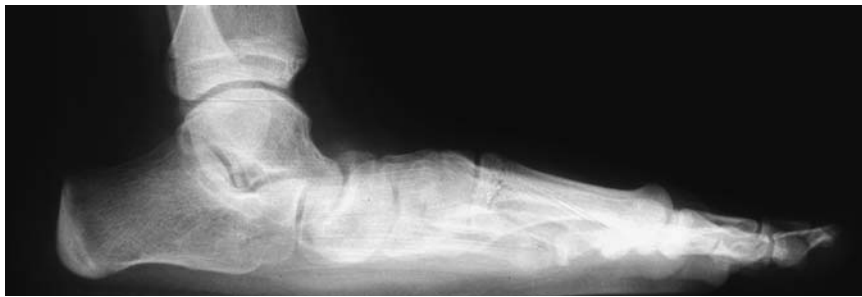

Figure C11.21.1

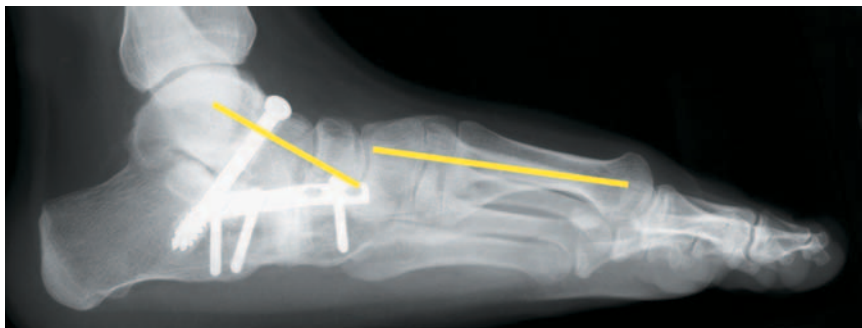

Figure C11.21.3

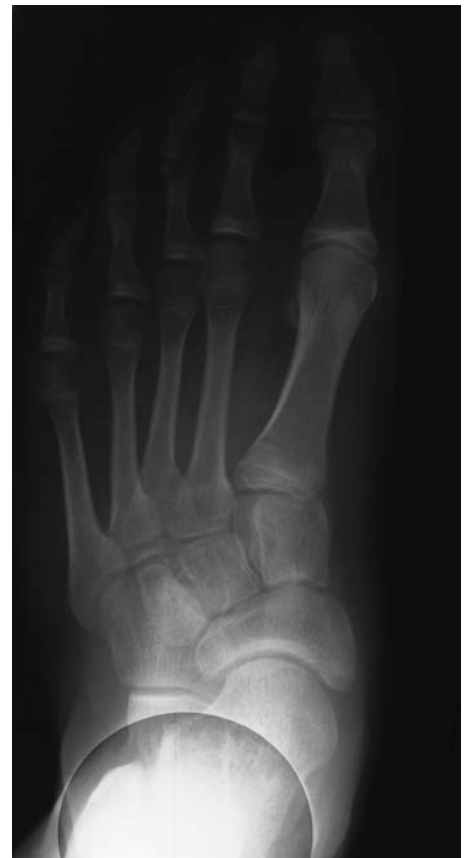

Figure C11.21.2

Outcome of Treatment

Discussing the outcome of surgery to correct planovalgus is difficult. There are many case series reports, especially of subtalar fusion for planovalgus feet in children with CP. Most of these reports focus on nonunion rates, or the need for additional surgery as an outcome assessment. Many publications also report different technical methods for doing the procedure; however, the end result tends to be similar. In general, using different evaluation criteria for subtalar fusions, which are by far the most commonly reviewed procedures for planovalgus feet in children with CP, 70% to 90% of the children with subtalar fusions are reported to do well.^{88, 118–122}

The outcome of lateral column lengthening has received much less review and it was initially recommended as being inappropriate for children with CP by Evans.¹¹⁷ A small series of children were reported to have done well by Mosca.¹²³ We reported our series and noted a failure rate of almost 25%, and by the time these children are fully mature, the failure rate may go as high as 30% to 40%.¹²⁴ The outcome is probably better if only high-functioning ambulators are chosen and there is diligent correction of all secondary and tertiary deformities.

The outcome of triple arthrodesis has shown a high rate of developing degenerative arthritic changes in the ankle joint on long-term follow-up.¹²⁵ The outcome also demonstrated many patients who were basically fused in situ so they still had severe planovalgus deformity. Another short-term study demonstrated that children do better if the triple arthrodesis is done before the deformity is so severe that they stop walking.¹²⁶

Other Treatments

The other operations, many of which are used widely but are not used in our facility, include extraarticular osteotomy and sinus tarsi implants. The extraarticular osteotomy, in which the osteotomy is made at the level of the calcaneal tuberosity, is similar to the Dwyer osteotomy for varus deformity; however, in the planovalgus foot, the osteotomy is displaced medially. This osteotomy shifts the force medially and decreases the pathologic force that tends to cause the planovalgus to progress. This osteotomy has been reported to provide good correction with functional improvement in the foot.¹²⁷ Others have added additional osteotomies to the calcaneal osteotomy in the midfoot to correct midfoot dorsiflexion, supination, and adduction (Case 11.22). This approach leaves the subluxated and dislocated joints in the abnormal positions but creates compensatory deformities. Reasonable correction can be obtained, but there are no long-term data to suggest that this approach is better than correcting the deformity at the location where it occurs through the joint, which also requires fusing the joints. The feet with these extensive osteotomies do not have a large amount of joint motion, and the motion that is present is occurring through subluxated or dislocated joints, which in other parts of the body have a tendency to develop arthritis much quicker and more severely as patients age. Long-term follow-up of these patients has not been reported.

Another popular approach is to insert some device in the sinus tarsi to create a subtalar joint arthroereisis. This technique appears to address the dysplasia that has occurred in the posterior facet by causing a mechanical block of the calcaneus, preventing the posterior subluxation and collapse into dorsiflexion relative to the talus. Reported devices include staples,¹²⁸ plastic plugs,^{129, 130} and screws placed into the calcaneus. The object of all these procedures is to reduce the primary deformity of planovalgus, then introduce



Case 11.22 Benjamin

Benjamin, an 11-year-old boy with diplegia who was a community ambulator, presented with pain in the medial side of the foot with long-distance walking. On physical examination he was noted to have severe planovalgus (Figure C11.22.1). He had correction of the planovalgus with a lateral and inferior calcaneal tuberosity osteotomy and reconstruction of the medial column, including a medial cuneiform osteotomy (Figure C11.22.2). Two years

later, he had a well-positioned foot with no symptoms during activity. The radiograph (Figure C11.22.3) showed an excellent orientation of the calcaneus, good medial arch, and excellent forefoot correction. This good position was present although the subtalar joint was still in the subluxated position with the calcaneus posterior to the talus and the anterior calcaneus filled the sinus tarsi. (Case material from Dr. Henry Chambers.)

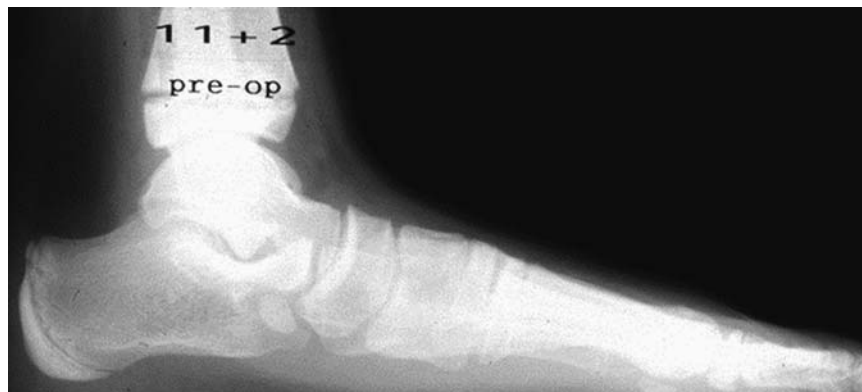

Figure C11.22.1

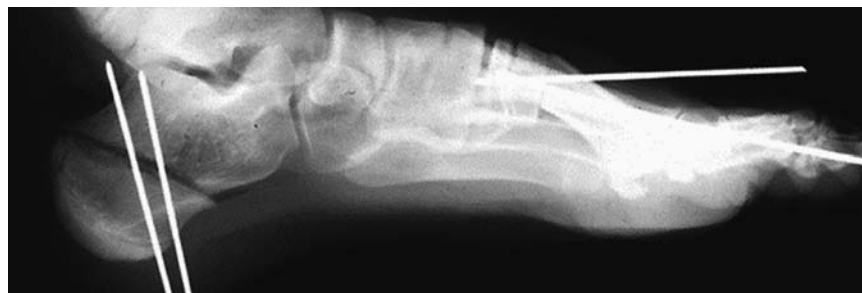

Figure C11.22.2

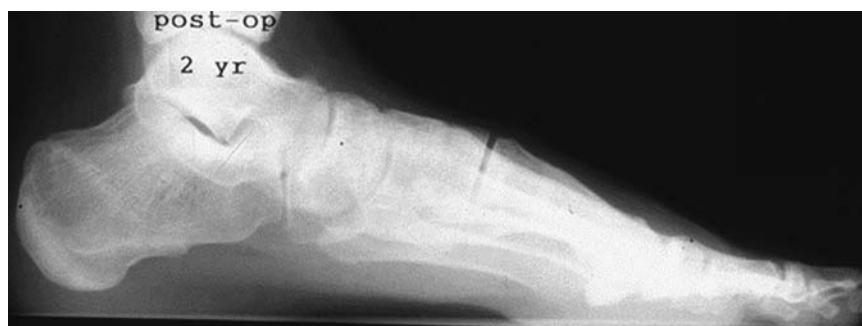

Figure C11.22.3

the object into the subtalar joint as a block to prevent repeat collapse. Most of these procedures are recommended for very young children who are an average age of 4 years and have mild flexible deformities. Some children have the operation performed as young as age 2 years, with good results reported.¹²⁸ Clearly, even with the natural history being undefined, this is the recognized time when children improve their planovalgus, and it is difficult to know how much of this excellent outcome is due to the treatment and how much is simply reporting the natural history. Using the plastic implant, a 5% failure rate was reported, with most of these in children having over-correction into varus deformity.^{129, 130} There are no large reports of the use of screws; however, they seem to have the same benefit, often showing very good correction (Case 11.23). All these devices are recommended primarily for children in whom the natural history is still likely to improve; therefore, the indications and outcomes for these devices are probably similar to lateral column lengthening. Our experience is also somewhat colored because although we have never implanted these devices, we have had an opportunity



Case 11.23 Thomas

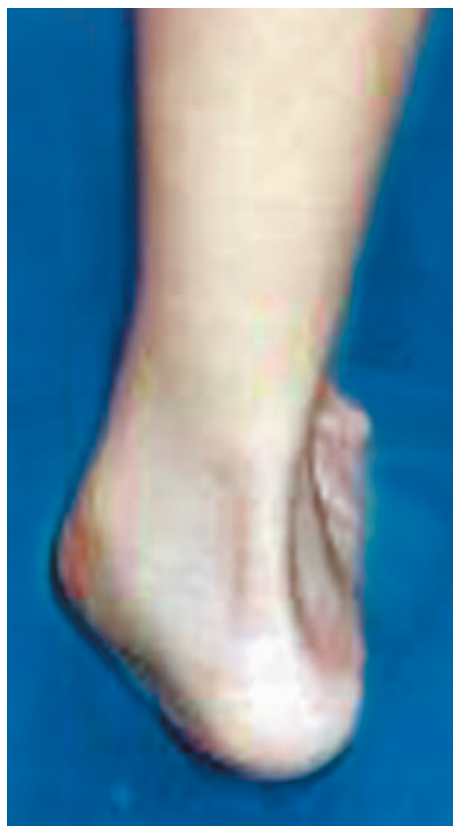

Figure C11.23.1

Thomas, a 5-year-old boy, was an independent community ambulator who had problems with shoe and brace wear because of severe planovalgus feet. On physical examination, the feet were both noted to have severe planovalgus on weight bearing (Figure C11.23.1) but were flexible during the examination. The radiograph demonstrated the typical deformity of a severe planovalgus (Figures C11.23.2, C11.23.3). He had a prominent navicular medially. A reconstruction was performed in which the navicular tuberosity was excised and the posterior tibial tendon advanced. A screw was placed in the sinus tarsi just anterior to the posterior facet with the foot held in the reduced position (Figure C11.23.4). By a 2-year follow-up, his foot had an excellent correction (Figure C11.23.5). (Case material from Dr. Patricia Fucs.)

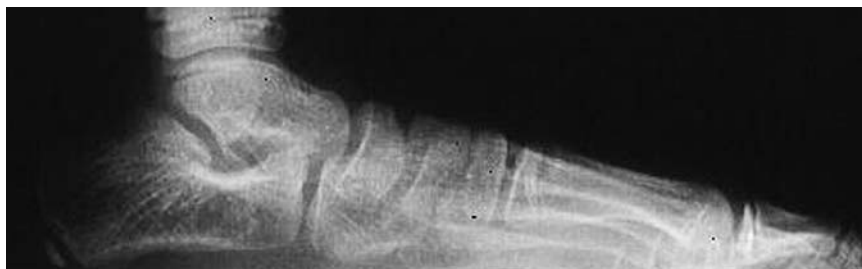

Figure C11.23.2

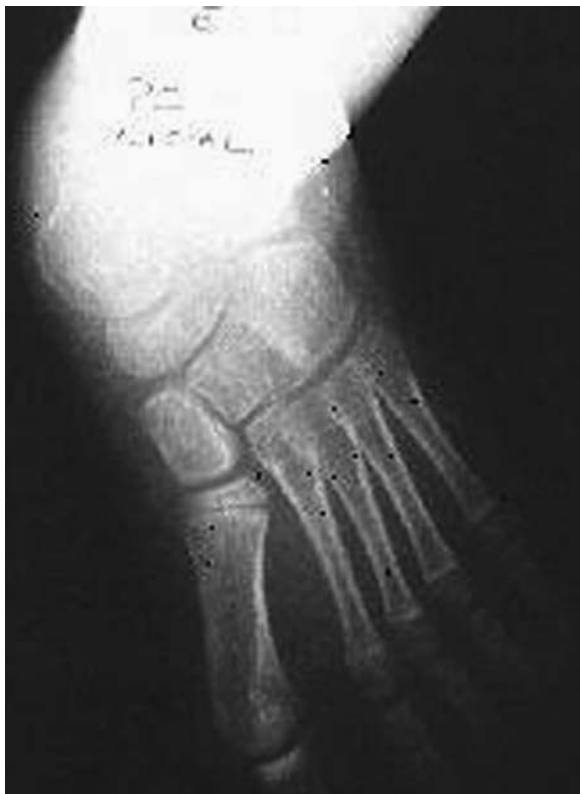

Figure C11.23.3

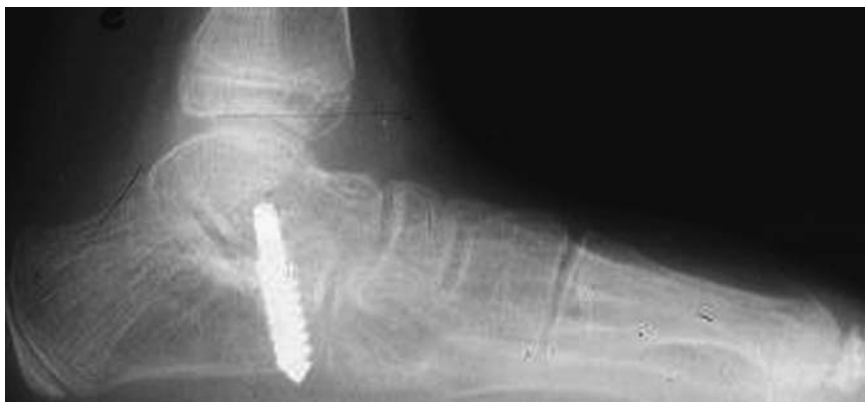


Figure C11.23.4

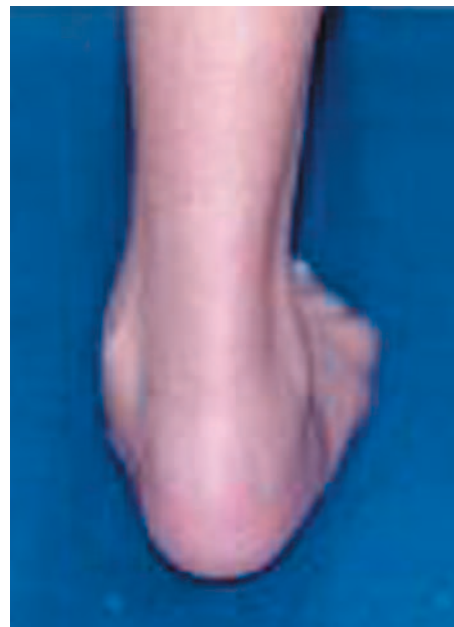

Figure C11.23.5

to remove many plastic plugs and staples (Case 11.24). Usually, the subtalar joint is very stiff, with a significant amount of inflammatory reaction around the implant. If the natural history were clearly understood, these devices would be an appealing option to consider in children with mild deformities who have a very high risk for progression. However, without these natural history data, placing an implant into a very young child's foot that may get better without treatment is questionable.



Case 11.24 Marcel

Marcel, a 12-year-old boy with severe diplegia, was a household ambulator when he presented with a complaint of pain in his foot with weight bearing. He had an operation for planovalgus 5 years previously in which a staple was placed in the sinus tarsi. At that time, he also had an Achilles tendon lengthening. On physical examination he had dorsiflexion to 30° with both flexion and extension of the knee. He used a posterior walker for slow household ambulation. Solid-ankle AFO use was uncomfortable because of pain in the calcaneus and medial aspect of the arch, both places where he had heavy callus from high chronic pressure (Figures C11.24.1, C11.24.2). The radiograph demonstrated a sinus tarsi staple, which appeared to have bone reaction, suggesting that there was some motion. The subtalar joint was in good position (Figure C11.24.3). He had a reconstruction with a subtalar fusion, lateral column lengthening, fusion of the calcaneocuboid joint, and medial column soft-tissue plication. At his 6-month follow-up, his foot was in excellent position with good brace wear tolerance. Because he still had no significant gastrosoleus activity, brace wear was required for all weight bearing (Figure C11.24.4).

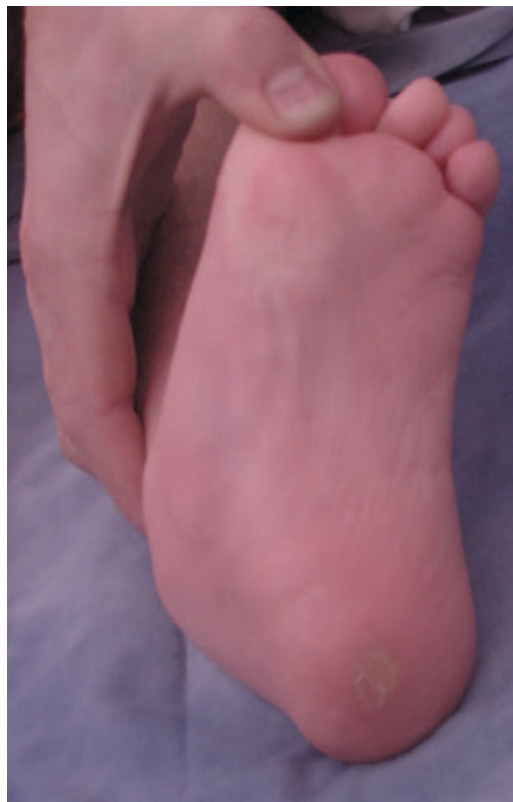

Figure C11.24.1

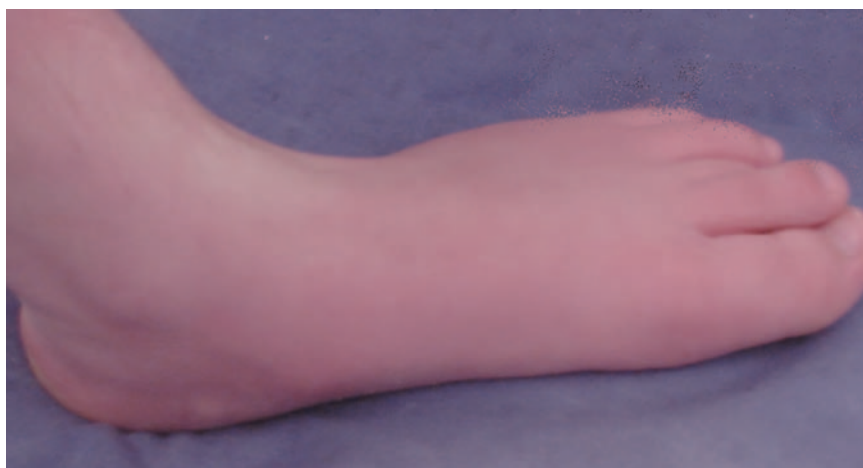

Figure C11.24.2

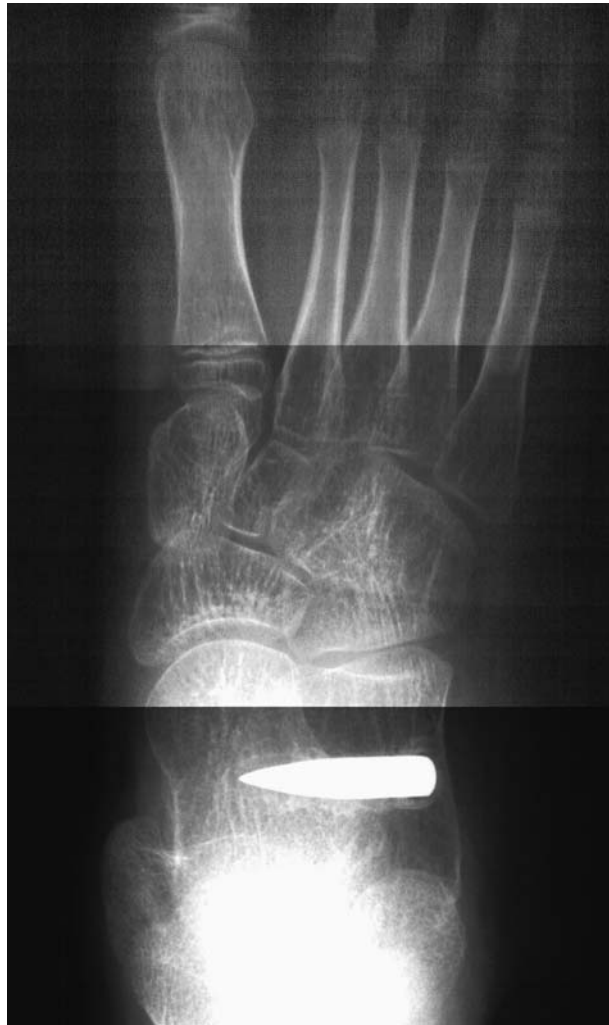

Figure C11.24.3

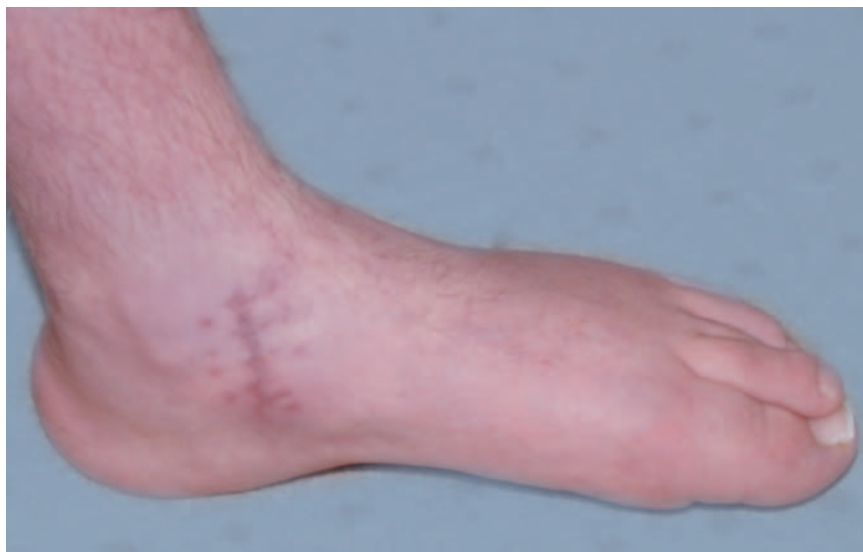


Figure C11.24.4

Complications of Treatment

Orthotics

Complications of treating the planovalgus foot by orthotics are skin breakdown from the medial midfoot pressure and a high risk of progression of the deformity once children reach adolescence. The most common complications of all operative procedures are, first, failure to correct the planovalgus deformity, and second, failure to correct all secondary and tertiary deformities.⁶⁰ The common errors are failing to correct the plantar flexion of the calcaneus relative to the tibia and leaving the calcaneus in equinus. This error causes loss or reversal of the peroneal arch on the lateral side of the foot, which frequently becomes a source of high pressure and pain. Treatment of this problem, which presents with patients complaining of feeling a mass like a small ball on the lateral sole of the foot, is an osteotomy of the calcaneal tuberosity to displace the osteotomy distally. It is not feasible or possible to resect just a small mass where the pain is located because this area should not be a major weightbearing area, which it has become. The calcaneal osteotomy will shift the weight bearing to the heel pad, where it is supposed to be (Case 11.25). Another major or overlooked deformity is forefoot supination with an elevated first ray and a dorsal bunion. If this deformity becomes symptomatic, children have to be returned to the operating room and the deformity corrected as outlined below.

Surgical Procedures

Complications of lateral calcaneal lengthening include dorsal displacement of the distal fragment. If the distal fragment completely displaces and is recognized in the early postoperative period, meaning the first 4 weeks, children should be returned to the operating room and the osteotomy reduced and fixed. If significant healing has occurred, the osteotomy should be allowed to heal and only addressed if problems are noted. Clearly, the most common problem with a lateral column lengthening is recurrent deformity, which should be fixed with a subtalar fusion when the deformity becomes so severe as to again require surgery in all instances. There is little role for repeat lateral column lengthening after it has initially failed. Overcorrection into varus can occur with a lateral column lengthening, although this has not occurred in our experience. We had two feet in which overcorrection has occurred, but the lateral column lengthening had occurred through the calcaneocuboid joint.

The most widely reported complication of fusions is nonunions. Nonunion rates of 5% to 10% are common. Many times, nonunions are asymptomatic and do not need treatment (Figure 11.33). Nonunions are mainly a problem if no internal fixation is used and the deformity recurs. There is no role today for doing a subtalar fusion without using rigid internal fixation; this is especially true for feet with spastic muscles, where it is almost impossible to hold the reduction in an ideal position without internal fixation. Also, historical papers have shown that the rate nonunion and loss of correction are very high when no internal fixation is used in children with CP, although this type of surgery worked well for children with poliomyelitis. Westin in 1977²³ and McCall et al. in 1985⁵⁹ reported failures of subtalar fusions of 36% and 46%, respectively. The early polio surgeons used tibial struts²³; however, they incorporated slowly and caused many tibial fractures at the graft site. Fibular struts were then advocated¹³¹; however, these led to proximal migration of the fibula and worsening ankle valgus²³ and should never be used. Other bone graft harvesting sites include ribs,²³ calcaneal dowel grafts,²³ and iliac crest.¹¹⁸ Internal fixation was introduced by Cahuzac et



Case 11.25 Hayley

Hayley, a 16-year-old girl with mild spastic diplegia, presented with a complaint of pain in her feet with long-distance ambulation. She was a full community ambulator whose only problems were a mild crouch with 15° to 25° of knee flexion in midstance and planovalgus feet (Figure C11.25.1). The radiograph showed typical changes with the calcaneus in equinus and loss of medial and peroneal arches. A triple arthrodesis was performed without using internal fixation, and by 18 months after surgery, she had the same complaint, although she then described the problem as feeling like there was a stone in her shoe.

The radiograph (Figure C11.25.2) showed a solid fusion, but the calcaneus was still in equinus with complete loss of the peroneal arch. Shoe orthotics that built up under the heel and had a relief area over the prominent lateral calcaneocuboid joint were made. However, the orthotics failed to provide relief. She was returned to the operating room where a plantar displacement osteotomy of the calcaneal tuberosity was performed (Figure C11.25.3). Following recovery from the surgery, the pain was completely resolved.

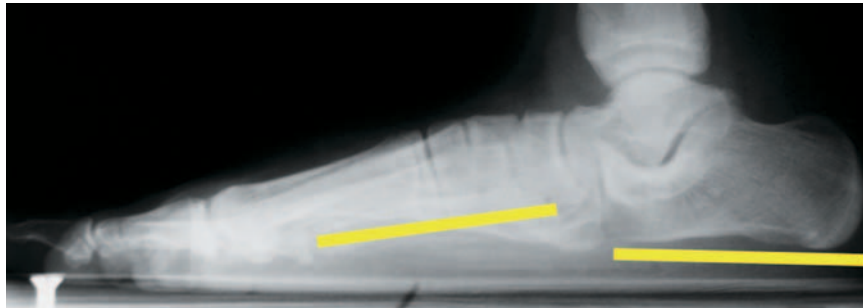

Figure C11.25.1

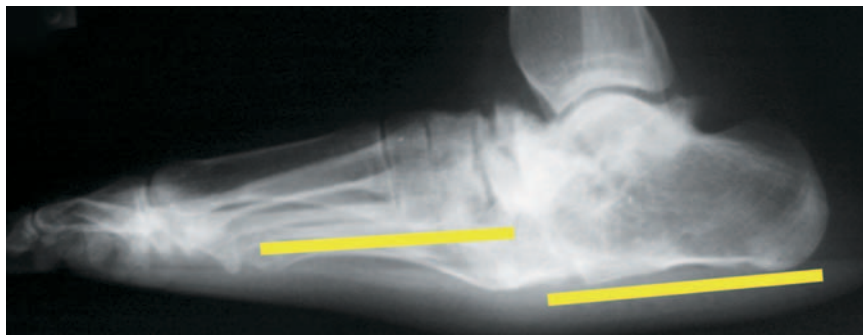

Figure C11.25.2

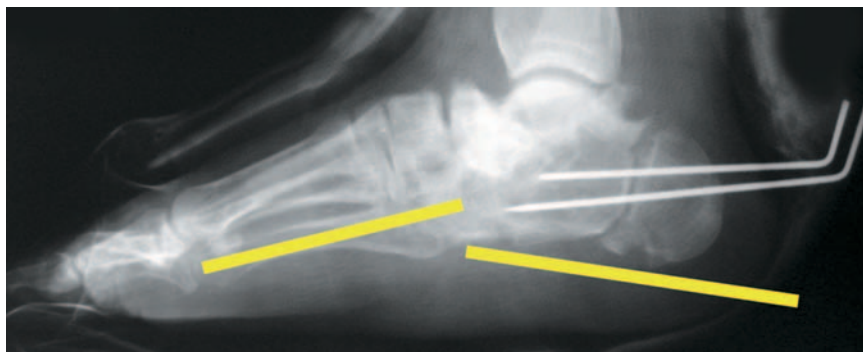
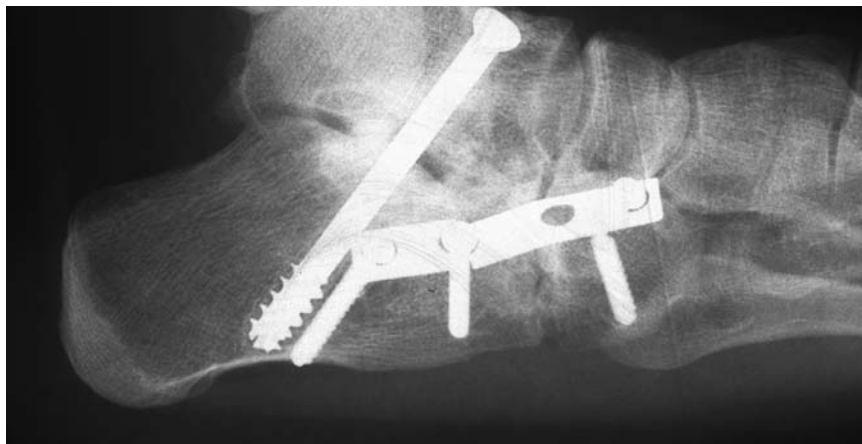


Figure C11.25.3

Figure 11.33. This 15-year-old boy with spastic diplegia had severe planovalgus corrected by subtalar fusion and lateral column lengthening through the calcaneocuboid joint. A radiograph at his 1-year follow-up visit demonstrated an established nonunion of the calcaneocuboid joint. He had no pain or other complaints and was followed until he was age 21 years with no complaints. Although these are rarely symptomatic in the short term, better attention to bone grafting greatly improves fusion rates. Long-term consequences of these nonunions are unknown.



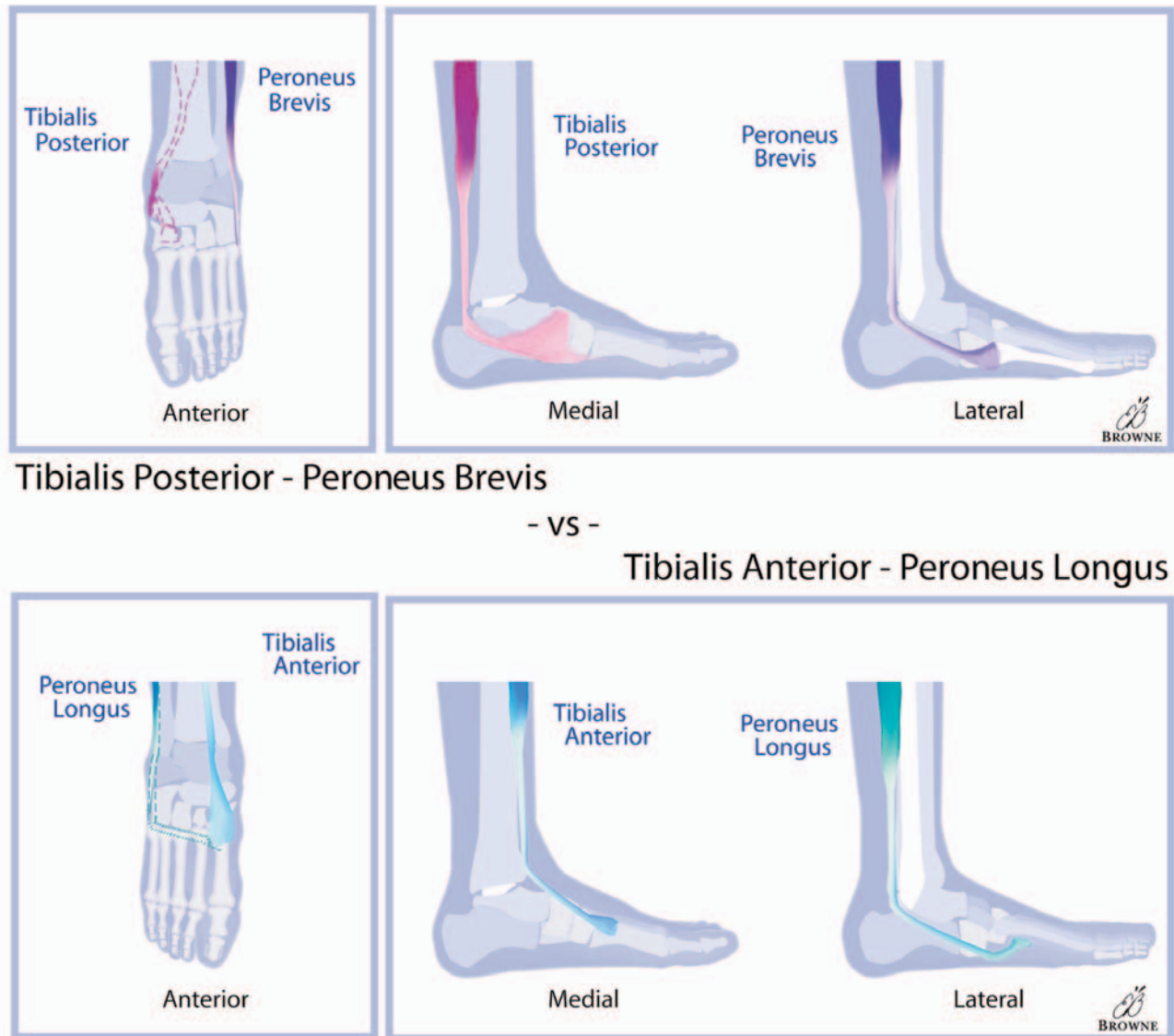
al.¹³² and popularized by Dennyson and Fulford.¹³³ Currently, nonunions are rarely a problem with the excellent internal fixation that is available, and we prefer to use bank bone graft, although the calcaneal dowel or iliac crest graft are reasonable options. Tibial struts and fibular struts have unacceptably high complications and should not be used.

Another complication of subtalar fusion is the development of ankle valgus over time. If this valgus gets to the point of being symptomatic, an osteotomy of the tibia or a screw medial ankle epiphyseodesis should be performed. This problem is usually concurrent with midfoot collapse, especially at the calcaneocuboid joint, and medial column collapse, mainly at the cuneonavicular joint. These problems all need to be addressed in the same procedure, because if only one is addressed the force will concentrate on the area where the repair was made and the repair will fail. There is no good long-term follow-up to adulthood; however, approximately 5% to 10% of children who have subtalar fusions between 7 and 10 years of age are likely to need more surgery by full maturity.

One of the long-term complications of all fusions is increased joint stiffness of the feet, which increases the risk of arthritis at the ankle joints and at the joints not fused. This arthritis risk was evident on our long-term follow-up study¹²⁵; however, there was remarkably little pain associated with these radiographic degenerative arthritic changes. Most of the people were still in middle age, and the operative procedures were not of modern quality with respect to reduction of deformity. We have no idea how the modern operations will fare over the lifetime of these individuals, but having the foot normally aligned should improve the force milieu.

Midfoot Supinations and Dorsal Bunion

Forefoot supination has received very little attention relating to planovalgus deformity in spastic children. The association of forefoot supination has been noted previously^{123, 134}; however, this is in relation to planovalgus deformity in general. All children with severe planovalgus and many with moderate planovalgus have forefoot supination that is very obvious after the hindfoot deformity is corrected. The supination is due to overpull of the tibialis anterior and insufficiency of the peroneus longus, which occurred with the foot in the planovalgus position (Figure 11.34). In younger children and more mild deformities, this supination corrects as the hindfoot corrects because now the peroneus longus is again put under stretch, and lengthening



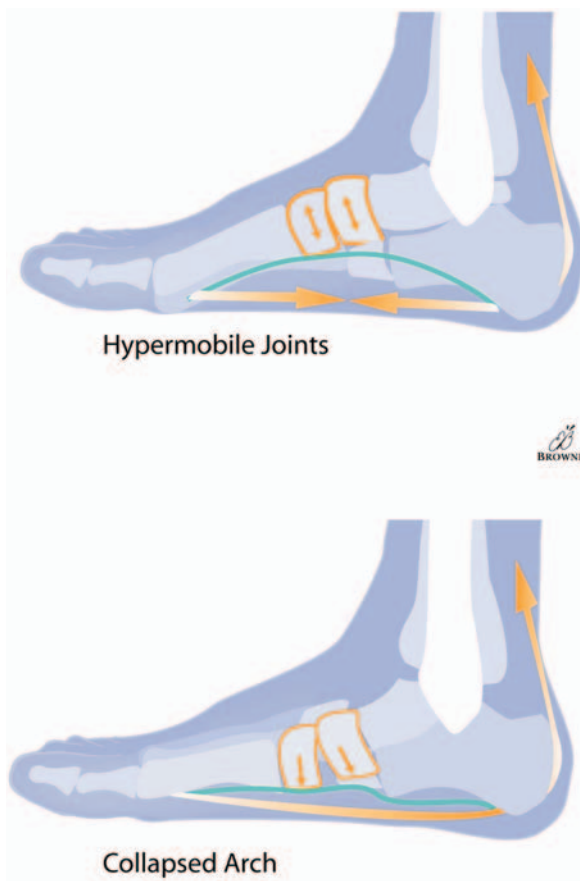
Tibialis Posterior - Peroneus Brevis

- VS -

Tibialis Anterior - Peroneus Longus

Figure 11.34. Foot stability is provided by the inherent bone stability and is primarily controlled by two pairs of extrinsic muscles. First, the tibialis anterior produces dorsiflexion, forefoot varus, supination, and first ray elevation, and it is counterbalanced by the peroneus longus, which causes plantar flexion, forefoot valgus, pronation, and depression of the first ray. The second pair is the tibialis posterior, which produces hindfoot varus, forefoot adduction, and supination. It is directly counterbalanced by the peroneus brevis, which produces hindfoot valgus, forefoot abduction, and pronation. Lengthening and transfers of these muscles must always take these balances into account.

Figure 11.35. The medial arch of the foot is maintained by the tension of the plantar fascia supported by the tibialis anterior and peroneus longus muscles. The bones form an arch, with a capstone joint at the top of this arch being the medial cuneonavicular joint. When high force produced by strong plantar flexion against a heavy body mass causes collapse of the medial arch, the predominant failure point is subluxation and hypermobility in the medial cuneonavicular joint.



of the gastrocnemius gives the tibialis anterior a better excursion range. However, in more severe cases, the supination deformity, which is secondary, has become fixed and requires correction.

The deformity of supination occurs at the cuneonavicular joint, with the cuneiform being displaced dorsally and having severe hypermobility allowing increased dorsiflexion. After correction of the hindfoot, especially with calcaneal lengthening osteotomy, the plantar fascia tightens somewhat and may partially protect the supination if it is mild. However, the plantar fascia only works if the capstone joints, namely the talonavicular and cuneonavicular joints, are stable (Figure 11.35). The instability of the cuneonavicular joint allows the first ray to dorsiflex, and as a secondary response to the supination, the flexor hallucis longus has increased tension and the hallux drops into severe plantar flexion. This elevation of the first ray with midfoot supination and flexion of the hallux causes the dorsal bunion. After hindfoot correction in children with severe planovalgus, the tibialis anterior is often found to be very contracted, preventing even passive correction of the supination.

Indications and Treatment

There are three levels of this supination deformity. First is a mild deformity, usually in younger children, in which forefoot supination is corrected almost completely by hindfoot correction. Intraoperative dorsiflexion pressure on the plantar surface of the first ray causes primarily ankle dorsiflexion with only minimal elevation of the first ray. This level of supination usually needs no treatment.

With a moderate degree of severity, the foot looks well corrected; however, with pressure on the plantar surface of the first ray, elevation of the first ray occurs before any significant ankle dorsiflexion occurs. This deformity requires correction by exposure of the cuneonavicular joint, and if the joint is allowing increased mobility and has some superior rounding, an opening osteotomy of the first cuneiform should be performed with transfer of the whole tibialis anterior to the lateral cuneiform (Case 11.26). Advancement of the tibialis posterior is also performed to increase soft-tissue restraint in the medial arch. The position of the osteotomy is maintained with a heavy K-wire inserted into the first metatarsal and across the osteotomy site into the talus. The foot is immobilized in a cast. An opening wedge osteotomy is performed, so bone graft has to be inserted using bank bone if there is no autogenous bone freely available.

If the deformity is severe as described by a foot that rests in supination after correction of the hindfoot, the supination must be surgically corrected. The same approach is used as for a moderate deformity, but the cuneonavicular joint is almost always dorsally subluxated as well, and in this situation, the joint is resected and a dorsal opening wedge of bone graft is inserted to fuse the joint or a plantar closing fusion is performed. Also, tibialis anterior transfer to the lateral cuneiform and tibialis posterior advancement are performed. If the opening wedge osteotomy does not fully correct the medial arch, there may need to be additional correction through the talonavicular joint and the first metatarsal cuneiform joint. In this situation, in which all the medial column needs to be fused, this correction is best fixed with a plantar-based plate, which extends from the first metatarsal onto the talus (Case 11.27). This level of fusion is only required in very severe deformities, usually for children who are marginal ambulators or nonambulators.



Case 11.26 Kelly

Kelly, a 13-year-old girl with spastic diplegia, was an independent ambulator who complained of increased pain in her feet, and she was very unhappy about the appearance of her feet, especially the bunions. On physical examination she was noted to have no significant fixed contractures except for the planovalgus feet with severe bunions. They appeared to cause her decreased stability in stance phase and the forefoot was very wide, making shoe fitting difficult. The pedobarograph showed a severe planovalgus deformity with predominant weight bearing on the medial forefoot (Figure C11.26.1). The radiographs (Figures C11.26.2, C11.26.3) showed a typical posterior planovalgus deformity of the calcaneus equinus relative to the tibia, but more equinus of the talus. The calcaneus was in dorsiflexion relative to the talus. The navicular and talus are in relatively normal alignment on the lateral view, but the navicular is laterally displaced on the anteroposterior view. On the lateral view, the first ray and

medial cuneiform are in dorsiflexion relative to the hindfoot, with the deformity occurring through the naviculocuneiform joint. Because of the advanced degree of the deformity, a subtalar fusion was performed. Medial column reconstruction was performed with a dorsal opening wedge osteotomy of the medial cuneiform, because the cuneonavicular joint was not deformed and appeared stable when inspected intraoperatively. The medial tuberosity of the navicular was resected and the insertion of the tibialis posterior was advanced. The tibialis anterior was moved from the insertion on the first ray to the medial cuneiform (Figure C11.26.4). The bunion was corrected with a proximal phalangeal osteotomy and soft-tissue realignment of the metatarsal phalangeal joint (Figure C11.26.5). After 8 weeks of immobilization in a cast and K-wire in the medial column, she had an uneventful recovery and she was happy with the result, both the cosmetic appearance and the comfort of her feet.

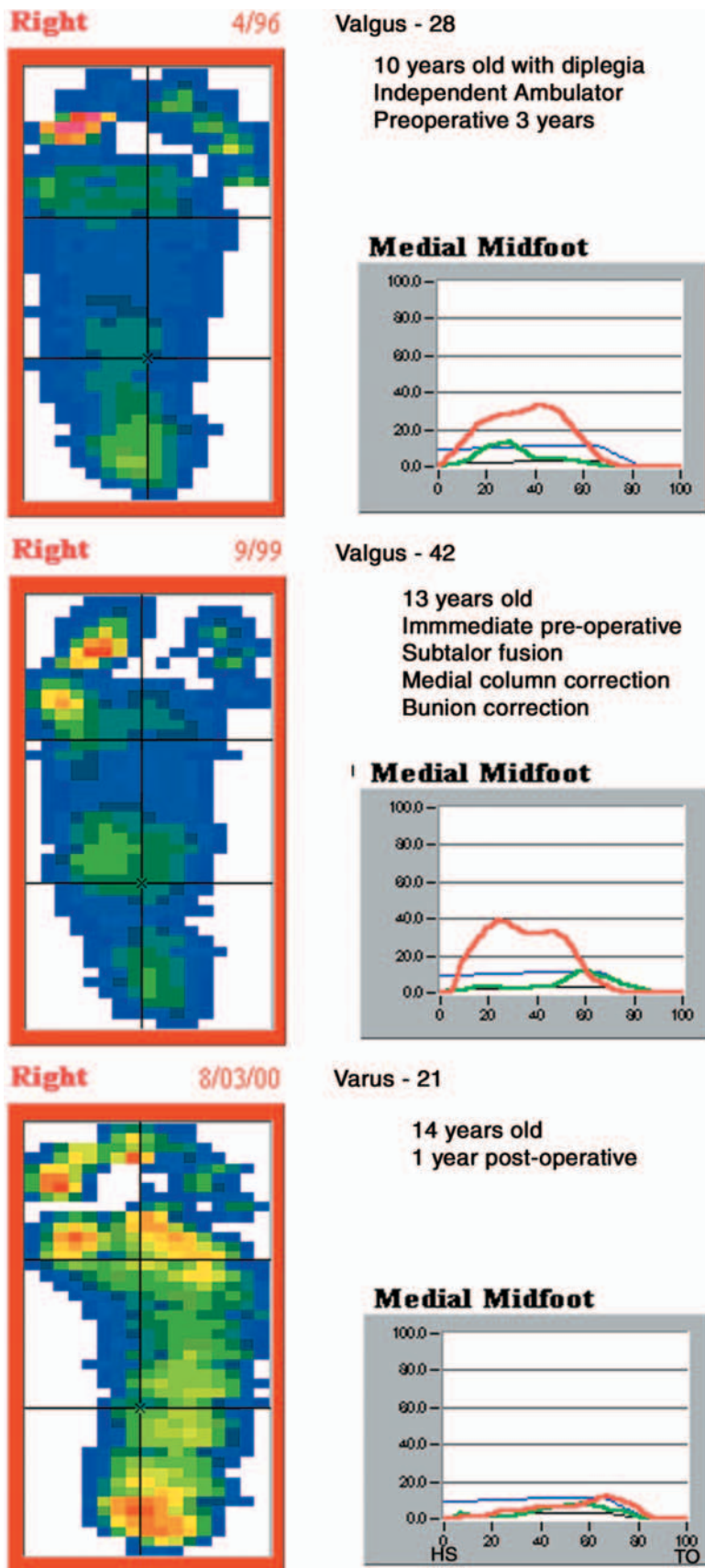


Figure C11.26.1

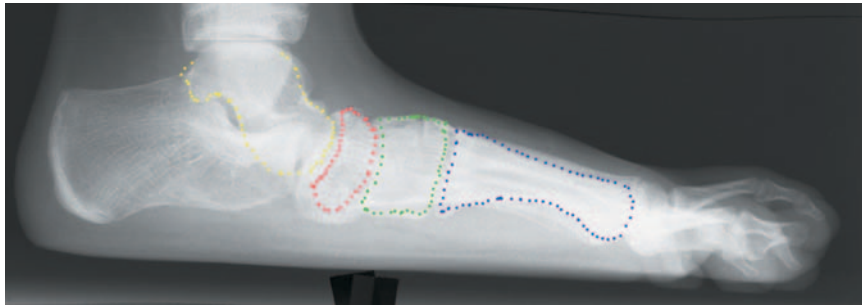


Figure C11.26.2

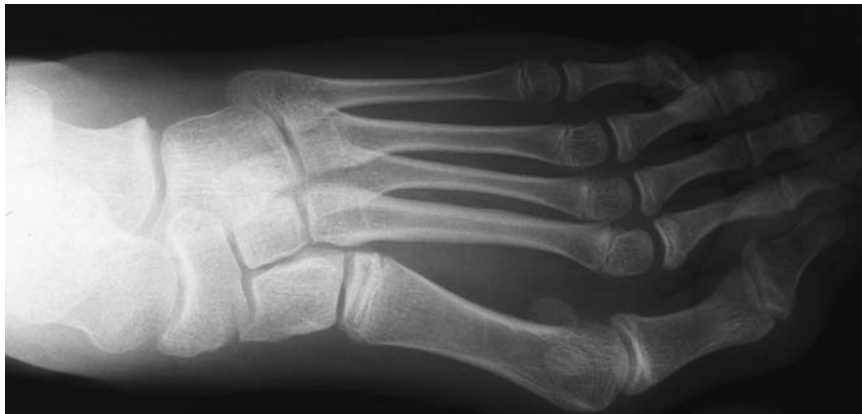

Figure C11.26.3

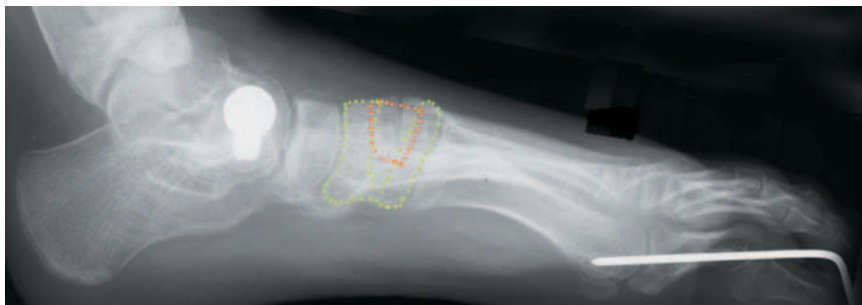

Figure C11.26.4

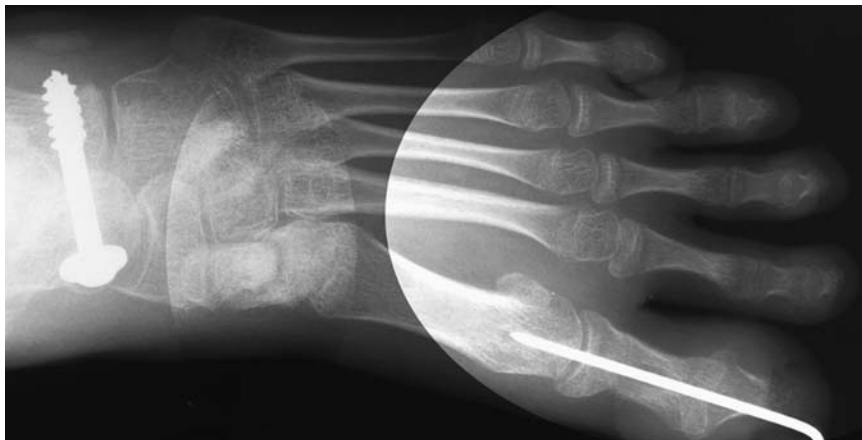

Figure C11.26.5



Case 11.27 Lionel

Lionel, a 17-year-old boy with a severe spastic diplegia, presented with a complaint of pain and skin breakdown over a dorsal bunion and over the medial arch of his foot (Figure C11.27.1). He was a limited household ambulator with a walker but relatively independent in transfers. The foot was extremely stiff and the deformity could not be corrected passively. His only prior surgery was a tendon Achilles lengthening many years previously. He had very limited ankle motion in addition to the fixed foot deformity. Radiographs showed a severe forefoot supination with a flexed first metatarsal phalangeal joint and

hindfoot planovalgus (Figure C11.27.2). A reconstruction was performed with correction and fusion of the hindfoot by standard subtalar fusion. The calcaneocuboid joint was then resected and the medial column was still noted to be very stiff. At the time, the decision was made to fuse the whole medial column and fix it with a plantar-based plate (Figure C11.27.3). The lateral column was fused by adding bone graft after fixation of the medial column. After it healed, he had a well-corrected foot, which provided good support and was pain free (Figure C11.27.4).

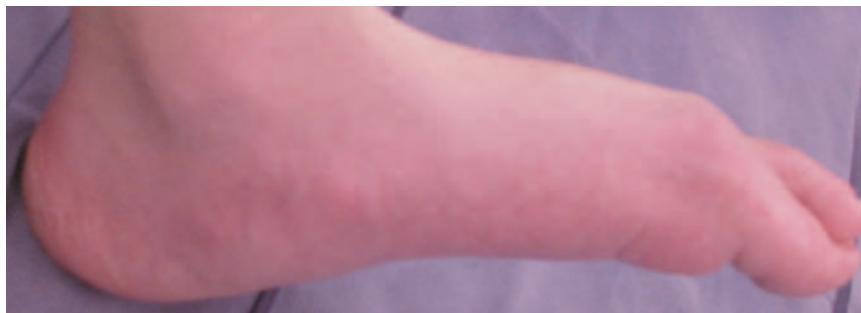

Figure C11.27.1

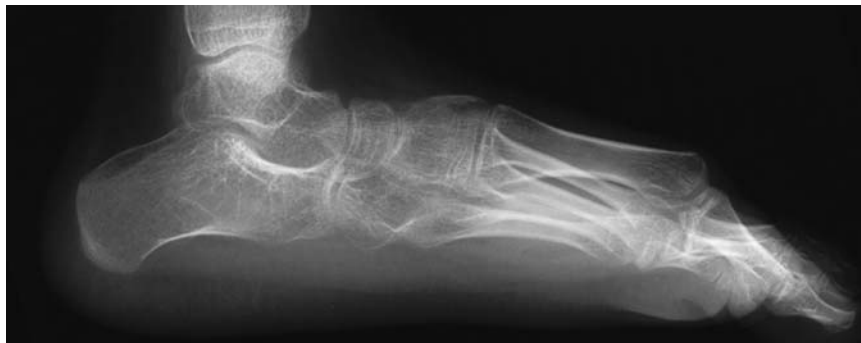

Figure C11.27.2

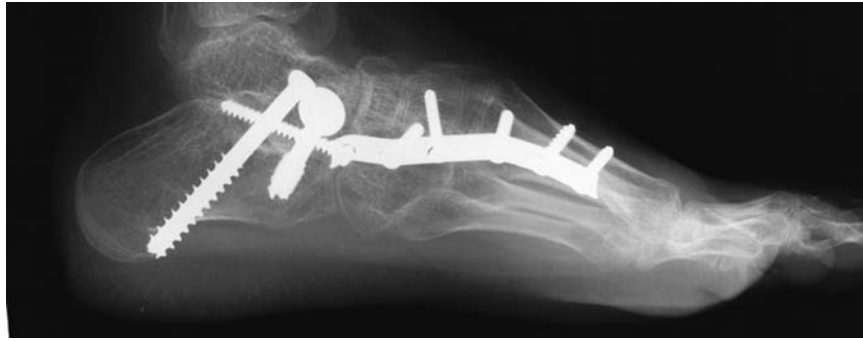

Figure C11.27.3

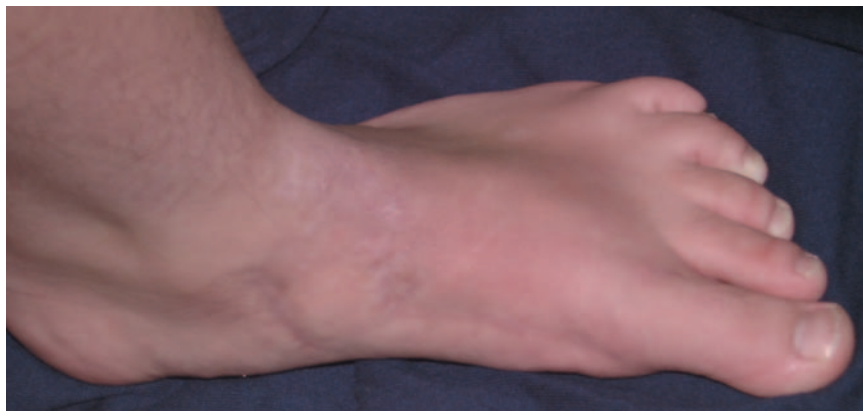

Figure C11.27.4

For most feet in children, when the medial first ray elevation is corrected, the dorsal bunion will usually resolve as the hallux again extends. In some adolescents, a dorsal exostosis has already developed, blocking extension of the hallux. This exostosis should be excised. In some adolescents and young adults, especially those who are nonambulatory, there often is very significant cartilage degeneration, and the first metatarsal phalangeal joint should be fused to keep the hallux in 15° to 20° of extension relative to the first metatarsal. Isolated treatment of the dorsal bunion is seldom indicated, and then only in rare individuals who have no associated hindfoot or forefoot deformity.

A few children with severe deformities from spasticity also develop a clawed hallux with increased flexion of the interphalangeal joint in addition to the dorsal bunion, which is directly related to first ray elevation. If this deformity is noted after supination correction, tenotomy of the flexor hallucis is indicated. If the interphalangeal joint is severely flexed and stiff, an interphalangeal joint fusion is recommended.

Outcome of Treatment

The outcome of treatment of the supination and dorsal bunion is good if complete correction is obtained. Unless children or adolescents have motor

control to allow good ambulation, there is a tendency for the medial column supination to recur. After the transfer of the tibialis anterior, the long toe extensors often become more prominent; however, we have not found a need to treat these. The acute attention to correction of the medial column deformity is a relatively new treatment, having evolved over the past 8 years, and as such, there is still no long-term follow-up. It will take another 10 years to get a better feel of how these children respond to this treatment over time; however, these feet are clearly better than those in which no attention was paid to the forefoot supination.

Other Treatment

There are no other treatment options that have been proposed to deal with this problem. The use of orthotics and shoe modifications are of very little help with forefoot supination and severe dorsal bunions.

Complications of Treatment

The most common complication has been collapse of the medial arch over 3- to 5-year follow-up times. Collapse is more of a problem in individuals who are nonambulatory and who had severe deformities that were not completely corrected. Overcorrection has been a minor problem only in individuals in whom the whole medial column was fused in slight increased forefoot varus and cavus. No additional change occurs over time when the whole medial column is fused.

Cavus

Cavus in children with spastic CP is rare as a major component of the foot deformity. A small group of children with severe hypotonia and ataxia develop a mild to moderate calcaneal cavovalgus deformity. In most of these children, the deformity is asymptomatic and requires no treatment. If severe valgus develops, the cavus tends not to be severe enough to treat and only the valgus needs treatment, usually with a subtalar fusion. When children with spasticity develop cavus, it may be a cavovarus or a calcaneal cavovalgus.

As the typical equinovarus becomes worse, the forefoot adduction and cavus also increase. In very severe cavovarus, the forefoot adduction and forefoot cavus may become so severe that they require treatment as well.

The most common situation where spasticity causes symptomatic cavus is in combination with valgus. Usually, both the valgus and the cavus are a significant problem, but for most individuals, the calcaneal valgus is more disabling than the cavus. Calcaneal cavovalgus occurs only when there is a very weak or incompetent gastrosoleus muscle, and we have seen this only in children who have had overlengthening of the tendon Achilles. With an incompetent tendon Achilles, the remaining plantar flexors, which include the toe flexors, peroneals, and tibialis posterior, all insert far enough distally that as they pull against the now remaining largest muscle in the calf, the tibialis anterior, the foot is drawn into cavus, with the calcaneus going into dorsiflexion and the forefoot dropping into plantar flexion relative to the hindfoot. Usually, there is an increased dorsiflexion range and limited plantar flexion relative to the tibia (Case 11.10). Also, in rare, neglected severe equinus deformities the foot can lead to a fixed cavus that may require treatment as part of correcting the cavus (Case 11.28).

Indications and Treatment

If there is a mild cavus associated with equinovarus, treatment of the equinovarus only is usually sufficient in young children because the tendency is to fall into planovalgus as they get older. If the cavus is moderate in teenagers or young adults, a plantar release can be performed as part of the procedure. However, the tendon Achilles or gastrocnemius is usually lengthened as part of the equinovarus treatment, which makes it difficult to put these children in a stretching cast for the cavus. Several authors have recommended doing the plantar fascia release and placing children in a cast for 6 weeks and then coming back and lengthening the plantar flexors.¹³⁵ For feet with severe equinovarus with severe cavus, the only reasonable correction is by triple arthrodesis with adequate bone resection to allow correction of the cavus, sometimes with the addition of a plantar fascial release.⁹⁰

Usually, the cavus of the calcaneal cavovalgus is the tertiary deformity of the collapse due to an incompetent tendon Achilles. There is no procedure to reconstruct the major plantar flexors. The calcaneal valgus is best treated by subtalar fusion, which usually allows good fit into an orthosis. These individuals have to plan to use an orthosis for the rest of their lives. As was noted previously, in severe cases in which children cannot or will not tolerate orthotic wear, a pantalar arthrodesis is another option. This fusion corrects the deformity and provides stability, but places all the force onto the mid-foot joints.



Case 11.28 Stacy



Stacy, a 16-year-old girl, was brought to CP clinic for her first visit with a complaint that she was having pain in her feet and was not able to walk as far as she once did because of this pain. She was in high school, had never had an orthopaedic evaluation, but was seen by a family doctor. Observation of her gait demonstrated severe equinus with ballerina-type toe walking. Physical examination demonstrated maximum dorsiflexion to only -35° , fixed cavus of the feet, internal hip rotation of 60° , and external rotation of -5° . Kinematics demonstrated 20° of internal rotation of the hips, knee flexion of 25° to 30° in stance and minimal additional knee flexion in swing phase, and ankle equinus of 60° with little motion. A detailed social history was obtained to determine the cause of this severe medical neglect. It was determined to be due to neglect by the primary care physician and family neglect. Social services determined that there was a good chance for follow-through, so she had Achilles tendon lengthening, plantar fascia release, rectus transfers, and femoral derotation osteotomies. Over a year-long aggressive post-operative rehabilitation program in which she worked very hard, she had an excellent result with normal rotational alignment, greatly improved knee flexion in swing phase,

and plantigrade feet (Figure C11.28.1). The cavus deformity of these feet occurs from long-term severe neglected spastic equinus. The equinus can still be corrected with only a tendon Achilles lengthening. Posterior ankle capsulotomies are almost never needed even in adults. The cavus does become progressively more fixed; however, in teenagers such as this case represents, the cavus can be relatively easily reduced with only a plantar fascia release. Lengthening of toe flexors may be needed; however, the toes are often in severe hyperextension at the metatarsal phalangeal joints and therefore are not so severely shortened. The open Z-type tendon Achilles lengthening allowed her to develop normal dorsiflexion; however, because of limited muscle exertion she is still limited in the amount of plantarflexion. However, this improved ankle motion has completely normalized her ankle moments and improved ankle power generation. This aspect of the procedure also allowed for decreased hip moments and decreased her hip power generation. All these improvements toward a normal gait pattern can be attributed to corrected ankle position. Improvement in knee flexion in swing phase is attributed to the rectus transfers (Figure C11.28.1).

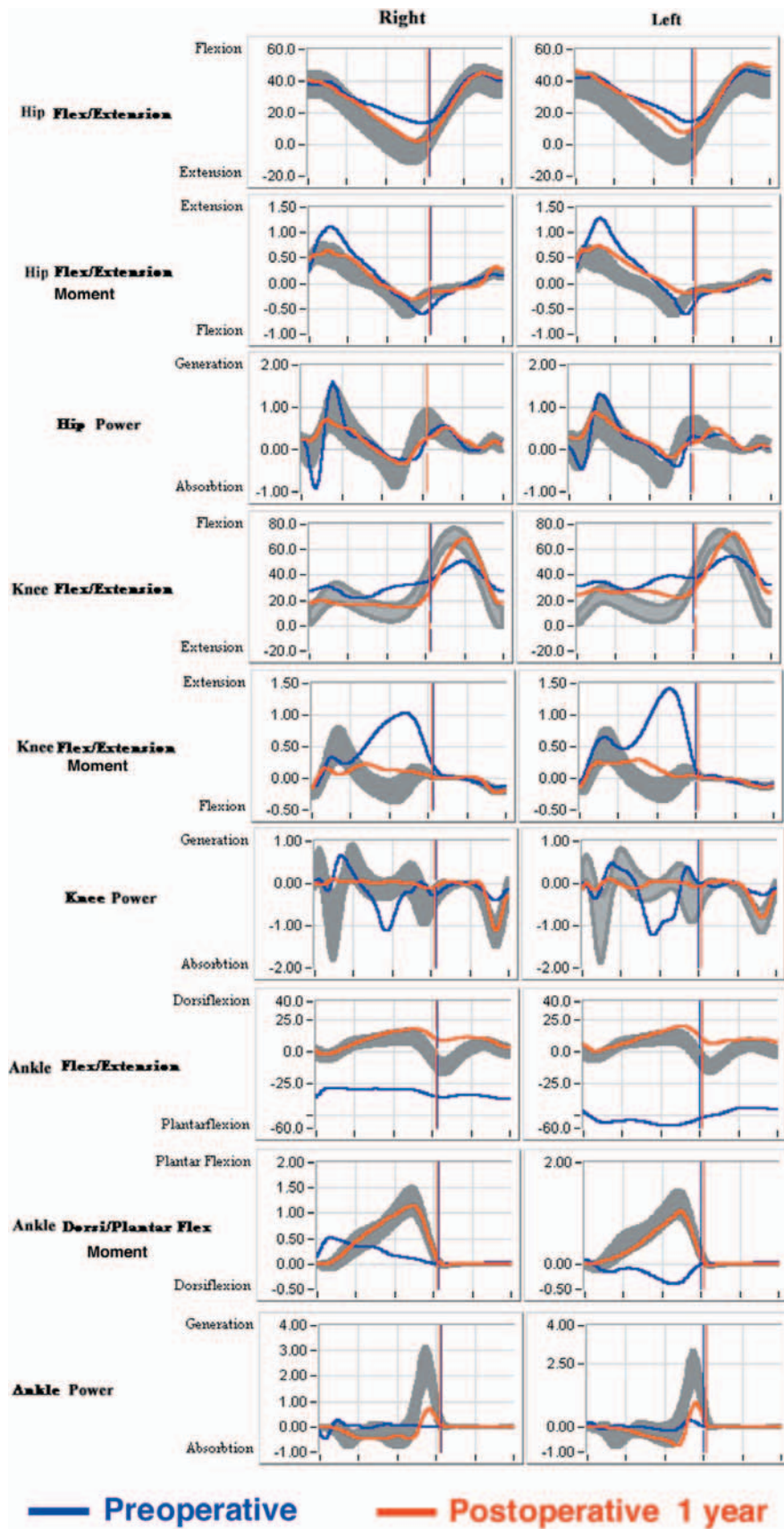


Figure C11.28.1

Forefoot and Toe Deformities

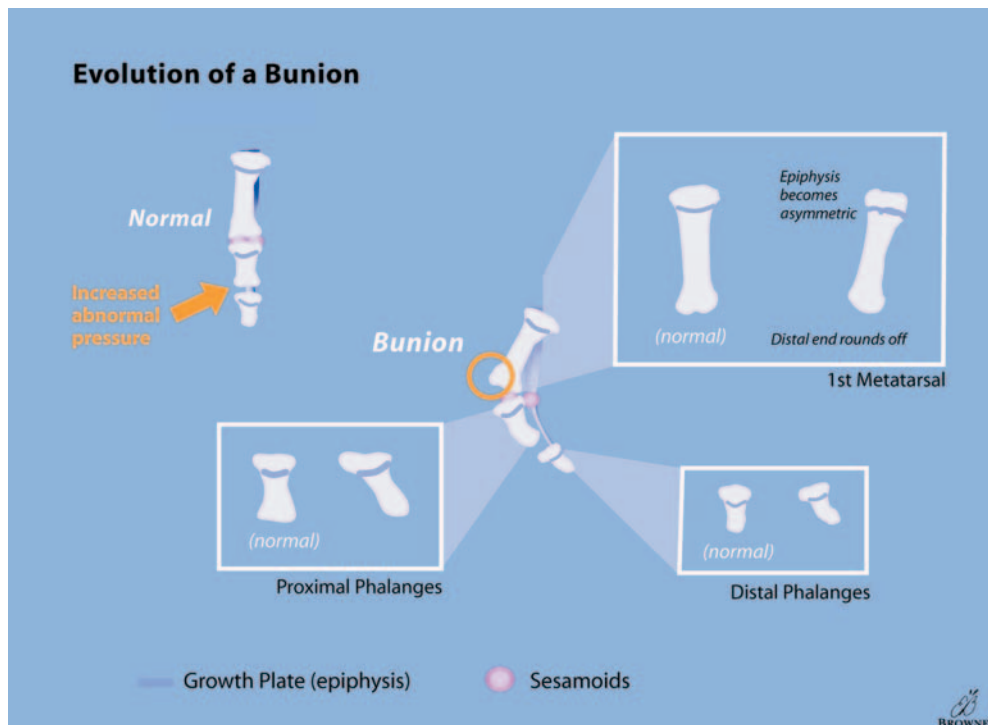
Most of the forefoot and toe deformities in spastic feet are still related to hindfoot and midfoot deformities. Often, these deformities become most symptomatic after the correction of the hindfoot and midfoot problems.

Hallux Valgus

The cause of almost all bunions in children and adolescents with CP is hindfoot valgus, which positions the foot such that the pressure of weight bearing is taken on the medial side of the hallux, especially in terminal stance.¹³⁶ This external moment drives the hallux towards the second toe, causing it to overlap or underlap the second toe. As children get older, the deformity tends to get worse in almost every case.¹³⁷ As the hallux moves over or under the second toe, the first metatarsal experiences a moment that drives it medially and opens an angle between the first and second metatarsal. This process continues to get progressively worse as the hindfoot valgus increases, increasing the force on the hallux. As subluxation of the metatarsal phalangeal joint occurs, medial subluxation of the sesamoids also occurs. As the hallux moves laterally, more force is reflected to the distal end of the first metatarsal, thereby driving the distal end of the first metatarsal medially (Figure 11.36). In children with equinus, the weight bearing may be on the medial side and distal end of the hallux, placing a large force across the growth plate of the proximal phalanx, causing it to grow into valgus as well.

Adolescent bunions are well recognized in the general population, and there are a few high-functioning community ambulatory children with CP who develop bunions with minimal hindfoot deformity. It has been our interpretation that this rare deformity is most likely adolescent bunions occurring in children who also have CP; therefore, these bunions can be treated the same as adolescent bunions.

Figure 11.36. The evolution of spastic bunion deformity is almost always associated with planovalgus foot deformity. As the foot pronates and abducts, the pressure of weight bearing starts to shift from the plantar surface of the first metatarsal phalangeal joint to the lateral side of the first ray and hallux. This pressure causes the hallux to develop increased valgus at the first metatarsal phalangeal joint. Often, there is an associated equinus causing weight bearing to shift distally; this causes the weight bearing to shift to the middle and distal phalanx. As the force is applied to the medial side and toward the distal end of the hallux, the first metatarsal is forced into varus through the medial cuneiform-first metatarsal joint. Also, pressure on the distal phalanx causes it to deform and develop distal valgus in the toe.



Pathology

The deformity includes a metatarsus primus varus of varying degrees with hallux valgus produced by subluxation of the metatarsal phalangeal joint. As the metatarsal phalangeal joint subluxates, the medial capsule becomes contracted and the abductor hallucis and flexor hallucis brevis also become contracted, which tends to make the deformity worse. Over time, chondromalacia develops over the medial side of the distal end of the metatarsal and a prominent bunion also develops. The bunion is primarily hypertrophic bursa and thickened skin. There is very little actual bone or cartilage overgrowth in children or adolescents. Another very significant area of valgus occurs at the proximal phalanx of the hallux. For a significant number of individuals, this is the major source of the bone deformity. Valgus deformity of the proximal phalanx is much more common as a significant aspect of the bunion deformity in spastic feet than it is in adolescent or regular childhood bunions (see Figure 11.36).

Natural History

The only report of natural history is a relatively subjective report in which it was noted that all untreated bunions continued to get worse in children and adolescents with CP.¹³⁷ Also, it has been our experience that these deformities get worse over time. We have never seen a bunion or hallux valgus spontaneously resolve. However, there is wide variation, as some mild to moderate bunions do not seem to bother the individuals much and surgically treating these milder deformities if they are asymptomatic is probably not indicated; however, the long-term effects into middle and older adulthood are unknown.

Diagnostic Evaluations

The primary investigation should be a standing anteroposterior radiograph of the forefoot to evaluate the degree of the metatarsus primus varus and the degree of hallux valgus (Figure 11.37). Attention has to be paid to the amount of valgus in the proximal phalanx in planning the treatment. In some feet, especially those with more severe deformities, the hallux can rotate laterally on its long axis, which will then cause the proximal phalanx to be out of plane on the standard anteroposterior view of the forefoot. If the radiographic measurement does not agree with the visual examination of the toe, another radiograph should be made focusing only on the hallux with the toe positioned so the radiograph is parallel to the nail bed.

Indications and Treatment

Bunions present as mild, moderate, or severe deformities. Mild bunions are those that are very supple, occur often in early and middle childhood, cause no pain, and are not fixed deformities when the children are nonweight bearing. The treatment of mild bunions usually is to use an AFO with a toe plate that extends to slightly past the front tip of the hallux with correction of the supple planovalgus, which is the cause of the deformity. The toe plate may be slightly elevated to assist in rollover at toe-off. If the planovalgus is so severe that orthotics are not tolerated, or a decision is otherwise made to correct a hindfoot deformity, mild bunions and hallux valgus need no surgical treatment. With correction of the hindfoot, the toe deformity is expected to remain stable or may improve.

Moderate bunions have a fixed deformity (even when children are not weight bearing), a toe that is passively correctable, minimal pain, and less than 30° of hallux valgus, or less than 20° of metatarsus primus varus on the

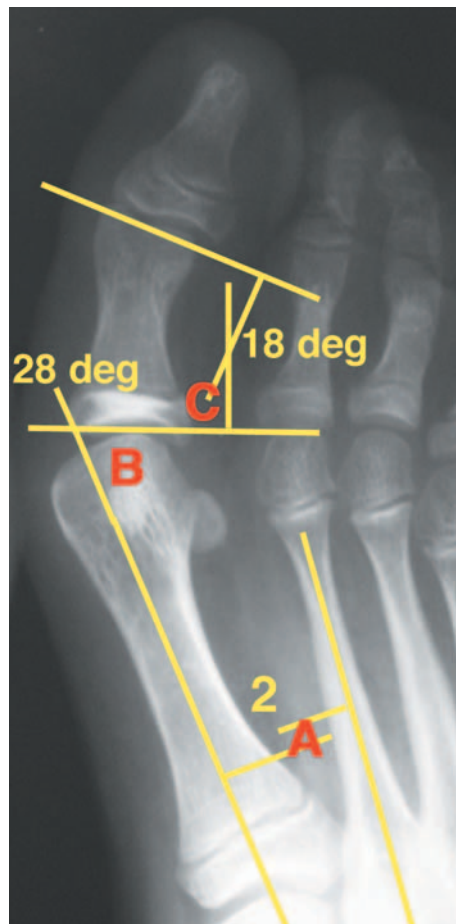

Figure 11.37. Radiographic assessment of the spastic bunion should pay attention to the intermetatarsal angle (A), the metatarsal proximal phalangeal angle (B), and the interphalangeal angle (C). Correction of the bunion deformity requires addressing the angular deformities in each of these areas if they are significant.

weightbearing radiograph. This deformity is most commonly seen in middle childhood and adolescence. The indication to treat this deformity is if hindfoot correction is required or if the bunion is becoming painful. These moderate bunions frequently have a primary bone deformity at the proximal phalanx often with mild metatarsus primus varus. After correction of the hindfoot, if the foot is very supple and children are good community ambulators, soft-tissue correction of the bunion by lateral capsulotomy, which releases the adductor hallucis and flexor hallucis brevis with plication of the medial capsule, may be sufficient (Case 11.29). It is important to not excise much bone in the process of doing a bunionectomy, as enough material can almost always be excised using only a knife. Proximal phalangeal osteotomy should usually be added if a significant deformity is present. If metatarsus primus varus is over 10° and children are good ambulators, then an osteotomy of the first metatarsal should be added. Sometimes the interphalangeal joints of the hallux are flexed, and Goldner described adding a transfer of the flexor hallucis longus to the extensor hallucis longus proximal to the metatarsal phalangeal joint.¹³⁷ We have not found this necessary; however, we have had several children who have developed severe interphalangeal joint flexion requiring interphalangeal joint fusion. If children are minimal ambulators or nonambulators, the most reliable procedure is fusion of the metatarsal phalangeal joint.

Severe bunions and hallux valgus are those defined as being stiff, not passively correctable, with more than 30° of hallux valgus and more than 20° of metatarsus primus varus. These feet are often hard to shoe and cause pain with shoe wear and long-distance ambulation. Even if the symptoms for patients or caretakers are all related to the toes, the hindfoot deformity has to be corrected first, or a reasonable correction of the bunion is not possible. In adolescents who are high-functioning community ambulators, most of these bunions can usually be reconstructed with a combination of metatarsal osteotomy, medial release, and lateral bunion excision with capsular plication. Some bunion reconstructions will need the addition of a first phalangeal osteotomy (Case 11.30). There are a few children in whom all the bunion deformity occurs in the phalangeal region and can be corrected with an osteotomy of the proximal phalanx (Figure 11.38). For all other individuals, especially those who are nonambulators, fusion of the metatarsal phalangeal joint is the best option (Case 11.31).

Outcome of Treatment

Soft-tissue reconstructions have been reported to hold up if all deformities are corrected.^{137, 138} However, there is a higher rate of recurrent bunion deformity and decreased patient satisfaction with the realignment procedures than with the fusion of the metatarsal phalangeal joint. The theoretical long-term advantage in high-functioning ambulators is that the mobile hallux joint will place less stress on the more proximal joints and thereby decrease the risks of developing degenerative arthritis. Because of the superior outcome of fusion and the high recurrence rates in nonambulators, there is little justification for doing realignment in this group.

Complications of Treatment

The main complication in the realignment procedure is recurrent deformity.¹³⁸ Loss of correction was such that only 36% to 55% correction was found in the hallux valgus angle after the realignment, compared with 89% correction after a fusion.¹³⁸ Another series reported excellent long-term maintenance of correction after the alignment.¹³⁷ We have had one patient who became severe enough to require a metatarsal phalangeal joint fusion. The

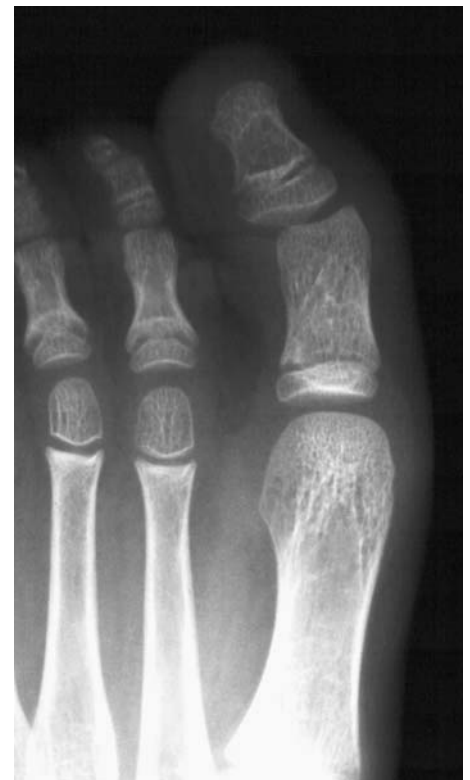

Figure 11.38. Correction of bunions requires careful attention to the radiograph, as demonstrated by this radiograph where the entire deformity is clearly in the interphalangeal region. Correction of this deformity requires only an osteotomy of the proximal phalanx.



Case 11.29 Kasia

Kasia, a 10-year-old girl with spastic diplegia who was a full independent community ambulator, complained of foot pain and poor shoe wear. On physical examination she had a moderate left planovalgus foot deformity with a bunion and hallux valgus (Figure C11.29.1). The planovalgus was corrected with a subtalar fusion and a soft-tissue correction of the bunion, including release of the adductor hallucis tendon, recentering the sesamoids under the first metatarsal, minimal bunion excision, and plication of the lateral capsule. By 1 year following surgery, she had some overcorrection of the bunion (Figure C11.29.2); however, over the following 3 years until she reached maturity, this stabilized and did not become a symptomatic problem (Figure C11.29.3). This case demonstrates that soft-tissue realignment is effective in the correction of bunions, especially when combined with hindfoot correction; however, care must be taken to do very little physical bunion resection. Bone resection is almost never an indication; only the cartilaginous apophyseal cap is resected. Also, care should be taken not to overcorrect the soft-tissue realignment.

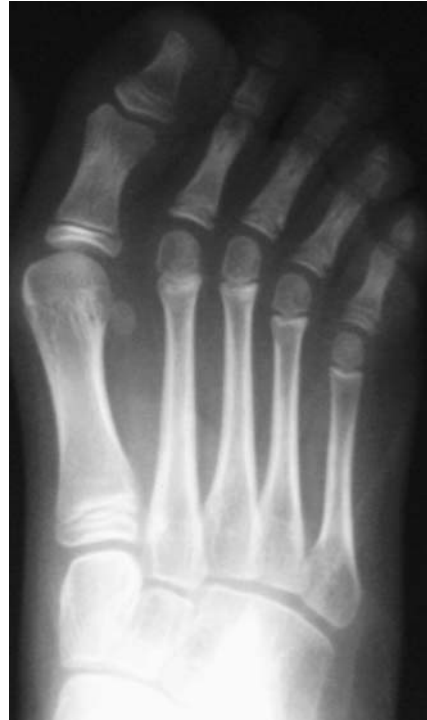

Figure C11.29.1

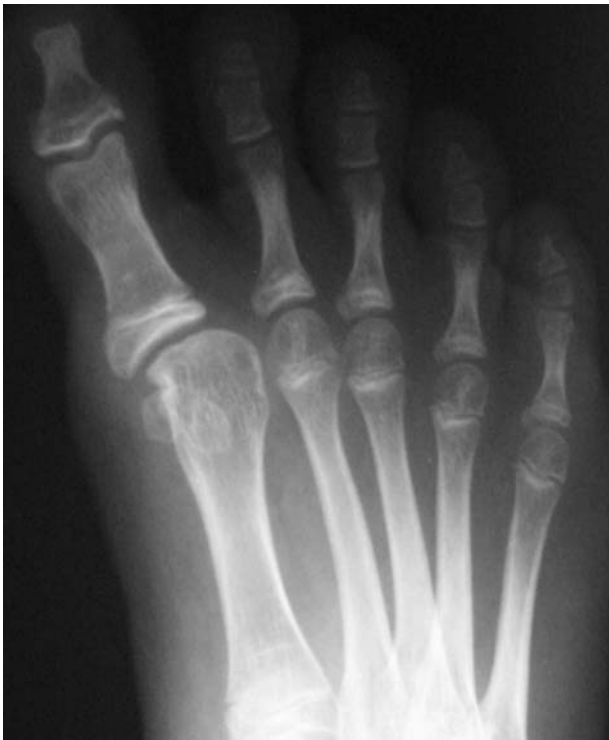

Figure C11.29.2

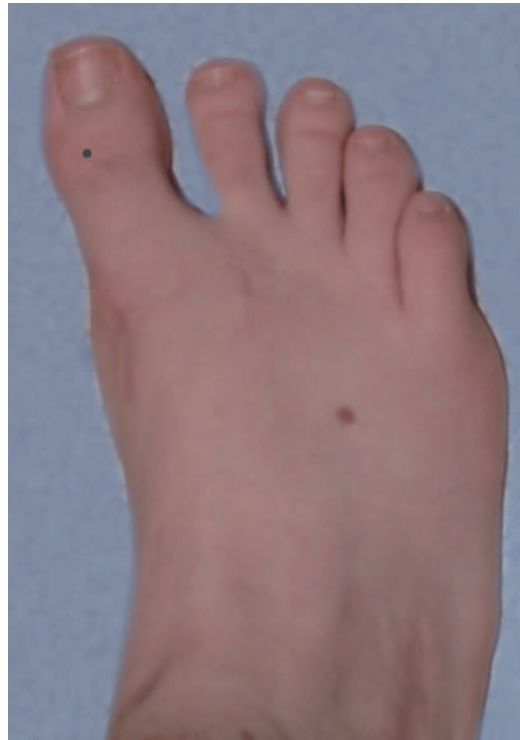

Figure C11.29.3



Case 11.30 Shaline

Shaline, a 15-year-old girl with diplegia who was a community ambulator with Lofstrand crutches, presented with the major complaint of pain in her foot with shoe wear. She was also concerned about the appearance of her foot, especially with the bunion (Figure C11.30.1). On physical examination she was noted to have a fixed bunion deformity with metatarsus primus varus and a mild to moderate planovalgus foot deformity. Ankle dorsiflexion was to neutral with the knees extended and to 13° with knee flexion. The radiograph showed no evidence of arthritic change in the bunion joint (Figure C11.30.2). A reconstruction, including lateral column lengthening through the calcaneus for correction of planovalgus, gastrocnemius lengthening, first metatarsal osteotomy, bunionectomy, and adductor hallucis release, was performed. One year after surgery, she was happy with the cosmetic appearance (Figure C11.30.3), and the alignment was maintained 2 years later (Figure C11.30.4).

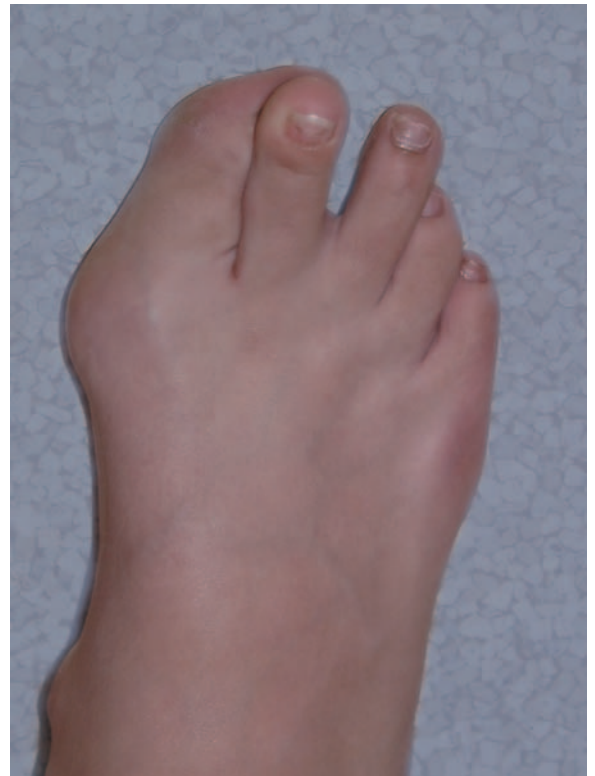

Figure C11.30.1

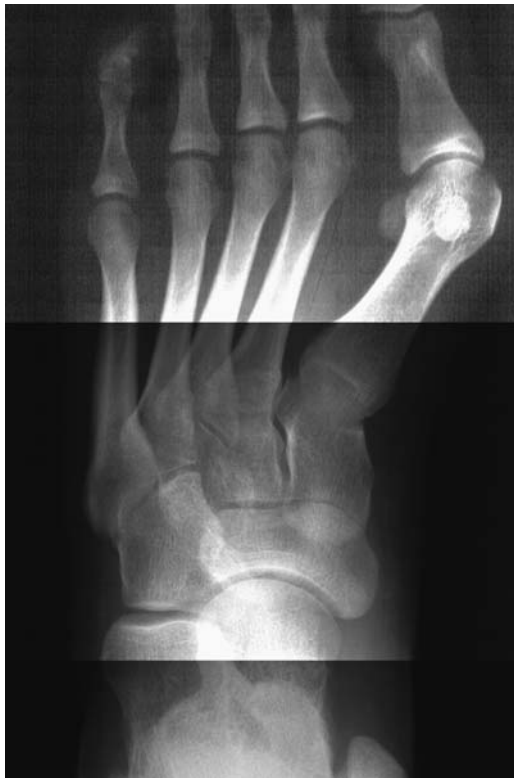

Figure C11.30.2

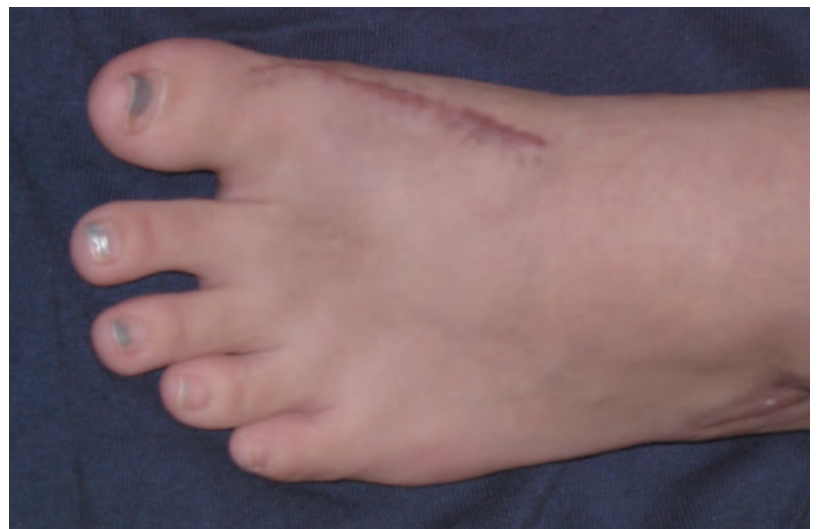

Figure C11.30.3

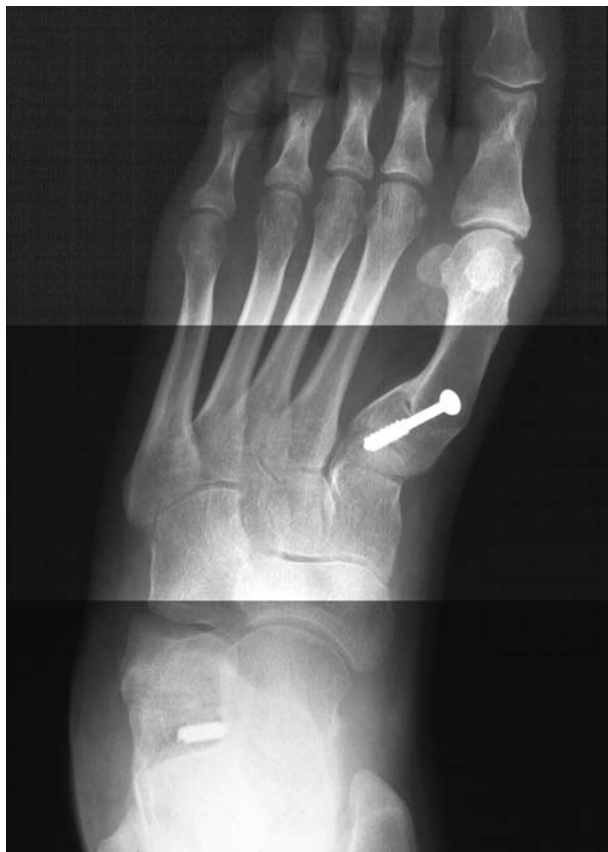

Figure C11.30.4

major problem with metatarsal phalangeal joint fusions is nonunions. The rate of nonunion in one report was 1 of 26 fusions.¹³⁹ Rigid fixation with screws or small plates may decrease the risk of nonunions, but in individuals with small and osteoporotic bones, these internal fixation devices are difficult to use. Another complication of fusion is malalignment of the arthrodesis, which is directly due to error in the operative technique. Too much extension, usually more than 20°, can lead to the hallux rubbing on the dorsum of the shoes. The exact amount of extension depends on the angle of the first ray in the weightbearing position after correction of the hindfoot deformity. If there is insufficient extension, there will be increased weight bearing on the distal end of the hallux, causing tenderness.

Extended Hallux

The most common situation where the extended hallux is encountered is in ambulatory children in whom the extensor hallucis longus is substituting for the tibialis anterior, either to augment the tibialis anterior or for a tibialis anterior that is firing out of phase. Some children have continuous active extensor hallucis longus so the hallux is also extended throughout stance phase. This extension is most commonly encountered with ankle equinus, without other significant foot deformity. The complaints from parents or children are pain in the hallux from rubbing on the dorsum of the shoe, and several have complained that the hallux rubs a hole in the shoe upper after several months



Case 11.31 Humberto

Humberto, a 10-year-old boy with moderate spastic diplegia who walked with crutches, presented with foot pain due to planovalgus deformities. He had a subtalar fusion with a lateral column lengthening with an excellent outcome (Figures C11.31.1, C11.31.2). There was a mild residual forefoot supination, which was not addressed at this initial procedure. Over the next 6 years, he went through adolescence and developed a very muscular body build with a weight of 90 kg. At age 16 years, he was a very active community ambulator with crutches, but complained of pain in his bunion joint on the right side only. The forefoot supination was noted to be slightly worse radiographically, and he had a metatarsus primus varus, hallux valgus, dorsal bunion, and a flexion contracture of the first metatarsal phalangeal joint (Figures C11.31.3, C11.31.4). The hindfoot correction, which had been excellent, had also lost some correction in that the fused calcaneocuboid-talar segment was now in more equinus compared with the forefoot. This midfoot break was as apparent on the physical examination as it was on the radiograph. Because the pain was thought to be coming from degenerative changes in the bunion joint and not from rubbing against a shoe, he had a fusion of the bunion joint with correction of the first ray elevation with an opening wedge fusion of the cuneonavicular joint (Figures C11.31.5, C11.31.6). This intervention provided excellent relief. In retrospect, this might have been avoided with appropriate correction of the medial column at the time of the first procedure. However, it also shows the vulnerability of the midfoot joints when the hindfoot has a solid fusion, especially in an individual who is a heavy mechanical user of his foot, as this boy is, and will be for the rest of his life.

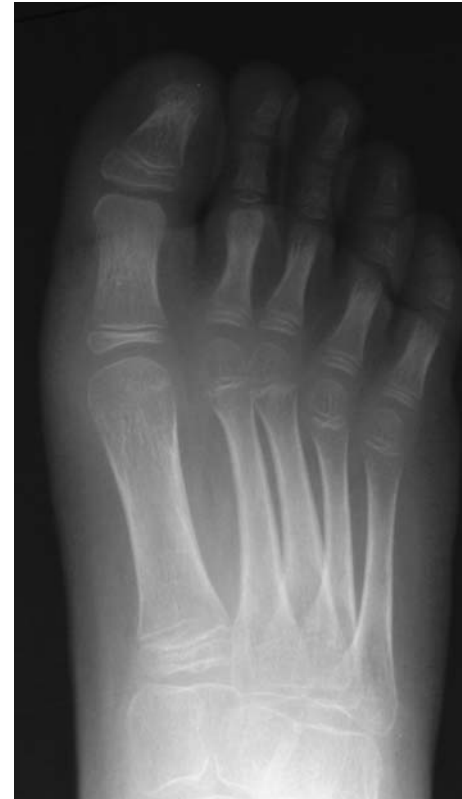

Figure C11.31.1

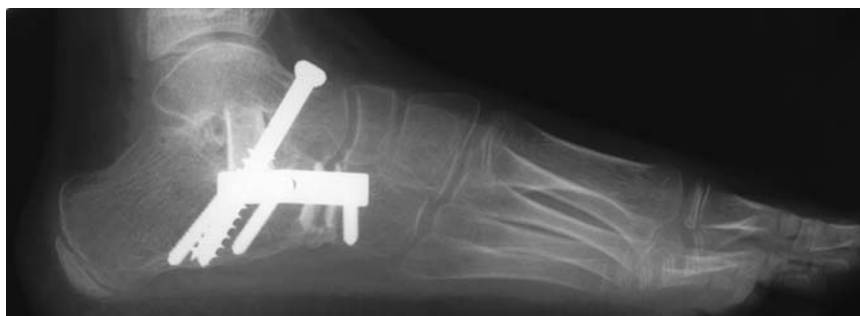

Figure C11.31.2

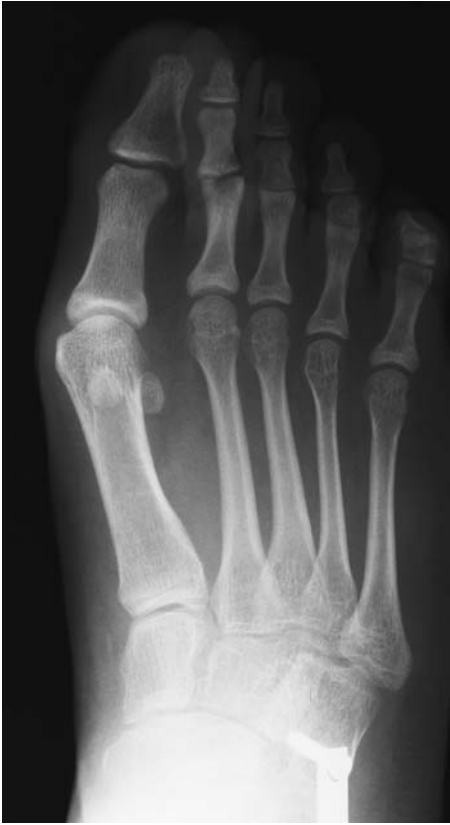

Figure C11.31.3

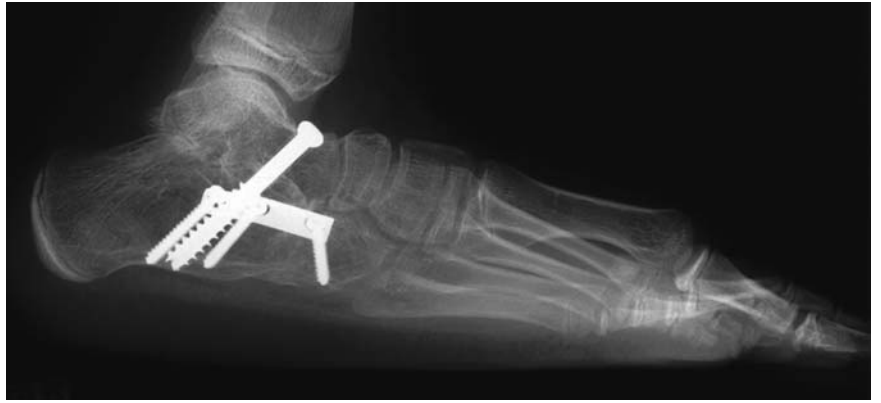

Figure C11.31.4

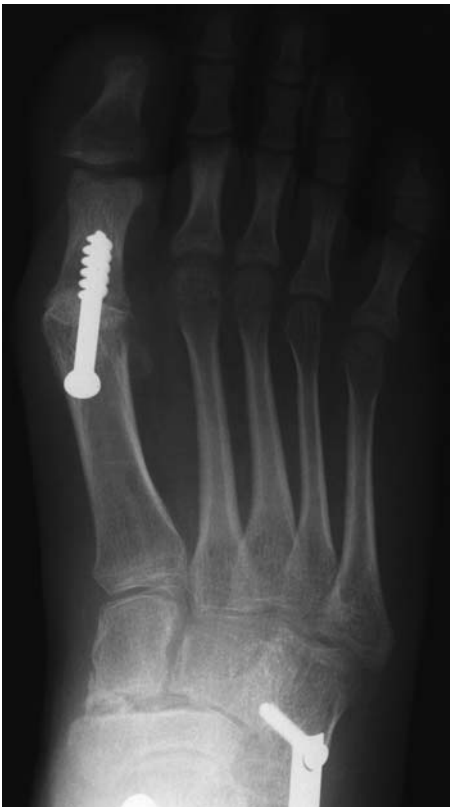

Figure C11.31.5

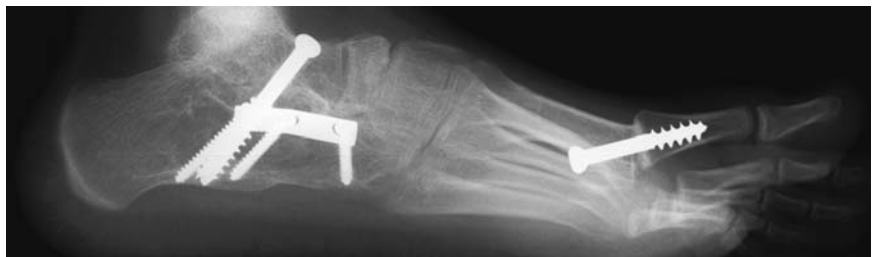

Figure C11.31.6

of wearing new shoes. In most patients, the interphalangeal joint is extended as well, which may cause distal irritation to become severe, often causing nail bed irritation. A few individuals present with flexion at the interphalangeal joint. This flexion is due to a spastic flexor hallucis longus in addition to the overpull of the extensor hallucis longus. These children complain of pain in the dorsum of the interphalangeal joint of the hallux.

Treatment

For children with extended toes in whom there is no other foot deformity and the interphalangeal joint is extended or neutral, the extensor hallucis longus is tenodesed to the tibialis anterior or to the proximal end of the first metatarsal. The tendon of the extensor hallucis longus is left intact and attached distally, which will prevent the hallux from dropping into flexion, but now the active component of the extensor hallucis longus can function as an ankle dorsiflexor.

If the extended metatarsal phalangeal joint is associated with a flexed interphalangeal joint, tenotomy of the flexor tendon at the metatarsal phalangeal joint level with fusion of the interphalangeal joint is recommended. The classic Jones transfer of the flexor hallucis longus to the dorsum of the hallux is not routinely recommended because this muscle has to be very spastic to cause the deformity initially; therefore, after a transfer, it may cause more flexion of the hallux than desired.

Minor Toes

The most common minor toe problem in children with CP is clawing of the toes. This clawing is a direct effect of the spasticity, and sometimes after transfer of the tibialis anterior or lengthening of the tibialis anterior with gastrocnemius lengthening, the overactive toe flexors and toe extensors become more evident. The clawing is especially severe in children or adolescents who have correction of severe equinus because the toe flexors will also be contracted in these situations. Most of these children have a clawing that involves flexion of the metatarsal phalangeal joint and interphalangeal joint; however, some individuals develop cock-up toes with extension of the metatarsal phalangeal joint and flexion of the interphalangeal joints. This cock-up toe is a toe collapse caused by overpull of both the flexor and the extensor muscles, which most commonly is seen in ambulators.

Natural History

Most of the minor toe deformities cause few problems in children; however, by adolescence, these fixed deformities may start causing irritation by rubbing on the inside of shoes.

Treatment

No treatment is required if mild toe contractures are easily corrected passively after lengthening of the gastrocnemius or tendon Achilles. However, care should be taken in cast immobilization to make sure there is a good supportive toe plate past the tips of the toes, and that some stretch is placed on the toe flexors by elevating the toe plate slightly. Ankle-foot orthotics should always have toe plates to prevent the clawing response, which is especially strong if the brace ends in the middle of the toes. We have seen casts applied that ended with a short toe plate in which the children clawed over the end of the cast until deep ulcers developed on the plantar surface of the toes.

If the toe cannot be easily brought to neutral after lengthening of the tendon Achilles, an intramuscular lengthening of the flexor hallucis longus and

the flexor digitorum longus should be performed. This lengthening can be done through the same posterior incision through which the tendon Achilles lengthening was performed. An intramuscular lengthening is almost never needed when only a gastrocnemius lengthening is performed.

If the clawing continues after posterior intramuscular lengthening, or develops when no posterior lengthening is needed, flexor tenotomies can be performed at the level just distal to the metatarsal phalangeal joint. These flexor tenotomies can be performed percutaneously, and can even be done under local anesthesia in the outpatient clinic if patients are not too anxious. Immobilization with a soft dressing for 10 to 14 days is usually all that is required.

The cock-up toes develop more stiffness, and the indication for treatment is usually irritation on the dorsum of the toes during shoe wear. If these toes are very supple, transfer of the flexor tendons to the dorsum of the toes at the proximal phalangeal level can be considered. However, by the time most of the clawed toes become sufficiently symptomatic to require treatment, they are usually stiff and often involve only one or two of the minor toes, usually a long third, or sometimes a long fourth, toe. For these isolated toes, and for toes that are stiff in the clawing position, treatment is a tenotomy of the flexor tendon and resection of the interphalangeal joint. If the metatarsal phalangeal joint is stiff, which seldom occurs in adolescence, a resection of the proximal half of the phalanx is preferred. Following the resection, the toes are immobilized with a K-wire for 4 weeks.

Ingrown Toenails

The increased pressure caused by the abnormal force of spasticity can lead to ingrown toenails. Ingrown toenails seem to be more common in children with spasticity than normal children, but there are no data available to document this fact. The ingrown nail usually occurs on the medial side of the hallux nail bed, but it may involve either or both sides. Also, there is a familial tendency, as many parents also have had problems with ingrown toenails. Another cause of the symptomatic nails are trimming of the nails too far proximally at the borders, especially on the medial side. Some parents reason that the cause of the soreness is due to the nail corner causing an inflammation and, therefore, they try to trim the nail back even further. All this trimming does is cause more irritation, as the sharp nail corner only irritates the skin further and causes granulation tissue hypertrophy.

Treatment

When the nail has an acute infection and inflammation, the foot should be soaked in salt water or Betadine solution for 20 minutes daily, then well dried. If cellulitis is present, broad-spectrum oral antibiotics for 5 days are indicated. If this acute inflammation does not respond in 2 weeks, an acute lateral nail bed and nail matrix resection is required. It is usually best not to do the resection when acute inflammation with purulent drainage is present; however, in a few situations, it is very difficult to clear these inflammatory symptoms, and the operative procedure can be safely done in the acute phase.

If children have several bouts of acute inflammation of the nail bed, the lateral nail, nail bed, and nail matrix should be resected as a wedge to the depth of the distal phalanx. One or two loose sutures are used to close the area of the wedge resection. Both the medial and lateral border of the nail should be done at the same time if indicated by the presence of a history of inflammatory changes or nail deformity.

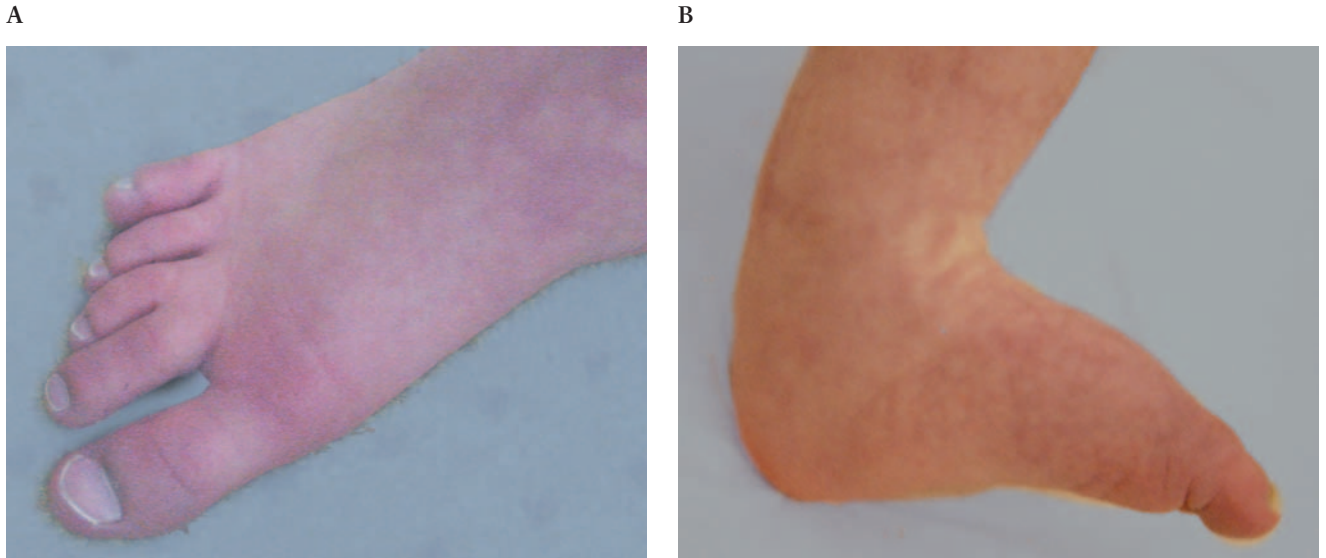


Figure 11.39. A very common problem in children with CP is decreased control of blood flow, which is seen when the limb becomes very cold and cyanotic appearing (A). Some feet may be very mottled in appearance (B). Although this causes great anxiety among parents, school personnel, family doctors, and other concerned individuals, it is a completely benign condition. We have seen hundreds of such feet and do not know of any problems caused by this condition. This is an indication of decreased temperature control, so children need to be protected from very high and very low temperature environments.

Blue Feet: Sympathetic Vascular Dysfunction

A very common problem in children and adolescents with CP, especially in nonambulatory individuals, is the presence of cold and discolored feet (Figure 11.39). Typically, the feet are very cold during the day, especially when exposed to room temperatures. Caretakers often feel that the feet have no pulse and that they look very similar to feet with severe vascular dysfunction, often seen in diabetes or peripheral vascular disease in adults. The cause of these cold and blue feet is sympathetic overactivity, or it can be thought of as spasticity of the sympathetic nervous system. These changes cause no pain to patients, and when the feet are warmed by placing them in warm water or having them well covered at night, the color and blood flow is excellent. These cold and discolored feet are a benign condition causing no known problems to the feet.

Treatment

Treatment of this sympathetic overactivity is to keep the feet covered with socks, but no other treatment or investigation is needed. Weight bearing in standers or gait trainers should be encouraged. There is no need for special vascular checks by the caretakers, as this will only cause worry about a situation for which there is no need for concern.

Treating Complications

Sciatic Nerve Palsy

Sciatic nerve palsy primarily occurs during treatment of knee flexion contractures. Almost all these nerve palsies resolve over time; therefore, the treatment is focused on avoiding further nerve injury, but continuing to work on gaining knee extension. This means splinting the knee into extension as far as individuals will comfortably tolerate and doing gentle passive knee range of motion daily, pushing to the limits of knee extension, always with the hip extended to avoid nerve stretch. Children should avoid sitting with

the knee in extension and the hip flexed to prevent further stretch on the sciatic nerve. The use of antiinflammatory medications and, occasionally, antidepressants may help control the pain during the rehabilitation phase. Full functional recovery should be expected, although occasional children will develop some decreased sensation and chronic intermittent swelling of the foot.

Fractures

The most common sites of low-energy bone insufficiency fractures are the distal metaphysis of the femur and the proximal metaphysis of the tibia. These fractures can be diagnosed with a careful physical examination and are easy to treat with soft, bulky dressings or very heavily padded casts. These fractures may occur during stretching exercises for knee flexion contractures, but seldom cause any residual problems.

Wound Infections and Scar Formation

Wound infections in the knee are a minimal problem, and most of the concern is related to the spreading and widened scar, which is left after the wound has healed. These scars tend to initially be red, thick, and very apparent. Use of gentle circular massage and vitamin A oil may gradually cause the scar to decrease. Individuals should seldom consider any scar revision for 1 to 2 years postoperatively. By that time, most of the concerns have dissipated as the scar thins and develops relatively normal skin color. For the first year or two, caretakers and patients should be warned against getting a sunburn on the operative scar, which tends to cause it to become inflamed and thicken more. Sunburn is of most concern for scars on the anterior thigh from rectus femoris transfers. These scars seem to be especially sensitive to inflammation and thickening and are in a location where the scar is readily apparent.

Treating General Complications of Foot Deformities

The most common complication of foot surgery in individuals with CP is recurrent deformity. Recurrent planovalgus is especially common, as are recurrent bunions and hallux valgus after realignment procedures. The rate of recurring deformity has to always be weighed against the advantage of doing a procedure that preserves the joint. Recurrent deformity is primarily a problem when joint fusions are avoided. This balance requires a difficult choice, but saving the subtalar joint, even with a 25% recurrence rate, may be acceptable in high-functioning ambulatory individuals. This recurrence rate would be much more difficult to justify in nonambulatory individuals because they presumably will not place the same stress on their feet over a lifetime; therefore, saving the subtalar joint is of less benefit. Treatment of recurrent deformities follows the algorithm of the standard treatment, except it is seldom wise to repeat the same operation. If the procedure failed once, there is probably something about the anatomy and milieu that suggests this is not the ideal operation for the foot. There is a tendency for surgeons to understand this concept when treating their own failures, but they too quickly blame poor technique or technical errors with the original procedure when they are treating someone else's failures. In general, surgeons should resist the temptation to think that they can do a better job than the original surgeon.

Vascular Infarction After Foot Surgery or Tibial Osteotomy

Vascular compromise can occur from derotation osteotomies, especially when they are combined with correction of severe foot deformities. If one side of the foot seems to have less blood flow in the acute postoperative period, the cast should be removed and the whole foot inspected. Some of the correction may have to be compromised to improve the circulation. If there is an exceptionally great amount of pain, inspection of the whole foot is indicated as well. The risk of this vascular compromise is highest when more than 30° of tibial derotation is required. Fibular osteotomy, which seems to decrease the risk, should be added to the tibial osteotomy. We have seen one partial infarction of the lateral border of the foot. The area was allowed to demarcate and then granulated closed without any other treatment required. The use of epidural anesthesia in the postoperative period may make the diagnosis more difficult as well.

Ulcers on the Sole of the Foot After Surgery

Ulcers develop on the sole of the foot from inappropriate cast techniques. Plantar surface ulcers are especially high risk if gastrocnemius lengthening is performed and then a cast is applied with some stretch on the gastrocsoleus. This cast has to be well molded on the sole of the foot. Flat plates used to apply pressure on the plantar surface of the foot must be avoided. We had one individual use a flat plate in a cast of a child, and a 2-cm-diameter, full-thickness ulcer developed over the third metatarsal head. This ulcer required 3 months to heal, and even 6 years after the operative procedure, this young adult continues to have intermittent problems with recurrent callus formation from the residual scar over this ulcer. Ulcers can be avoided with careful molding of the medial longitudinal arch and not placing direct pressure under the prominent metatarsal heads. After the initial cast has set, the exterior cast sole needs to be flattened so individuals can bear weight, but this must not be done with the application of the initial layer of plaster material. If skin breakdown occurs from cast pressure, it is usually localized and will granulate over time. It is usually better to allow the wound to heal and the scar to mature before any formal revision is attempted. If a thick scar develops, a revision can then be performed. The risk of developing skin breakdown inside a cast is definitely higher when epidural anesthesia is used during the postoperative period because it is more difficult to determine when there is an abnormal pain pattern present.

Postoperative Hypersensitivity

Hypersensitivity of the foot after major foot surgery is very common. After the cast is removed, individuals are encouraged to soak the foot, and caretakers are instructed to gently massage the foot. Socks should not be worn to bed, and children are encouraged to get into standers using orthotics as needed. Most of these hypersensitivities resolve by 2 to 3 months after surgery. If hypersensitivity does not resolve, it was often present preoperatively, or the caretakers are excessively protecting the foot using socks at night and avoiding touching or even bathing the foot. At this stage, physical therapists have to get actively involved with a desensitization program, which includes weight bearing, stimulation of the foot with different textures, massage, and water therapy. Sympathetic reflex dystrophy has never been reported in individuals with CP and we know of no cases, although it is relatively common in adults with hemiplegia secondary to strokes.¹⁴⁰

Wound Infection

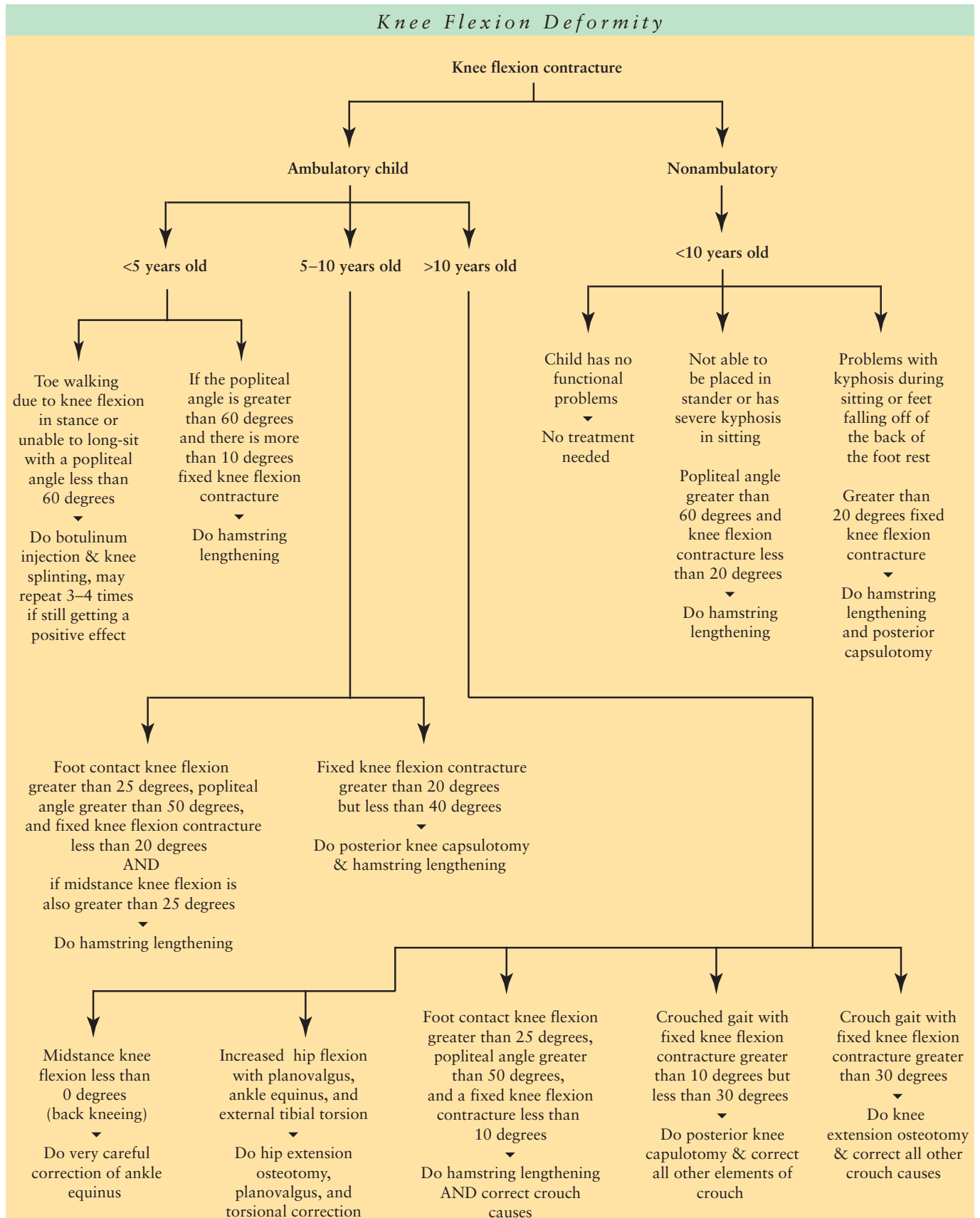
Wound infections following surgery on the feet are rare. Lateral wounds from the surgical exposure for correction of severe planovalgus deformity can be under very strong tension when closed. Closure of these wounds using the near-far, far-near trauma stitch with no subcutaneous closure often works best. A rapidly resorbing suture material, such as plain gut, should be used and then there is no need to remove the sutures, as the sutures will be completely resorbed by the time the cast is removed.

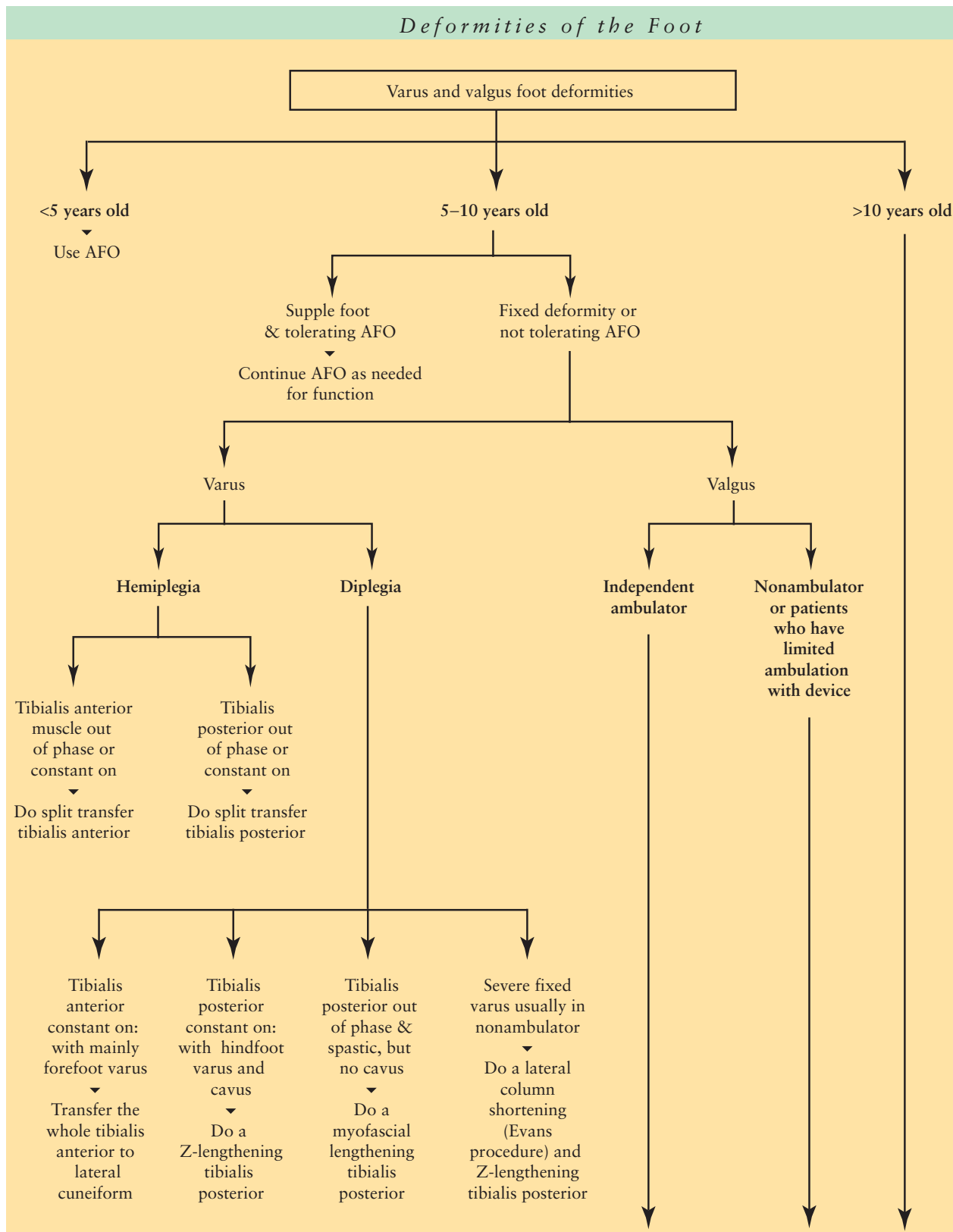
Compartment Syndrome After Tibial Osteotomy

Compartment syndrome can occur after surgery, especially for tibial osteotomy. We have never seen a compartment syndrome after tibial osteotomy and have seen it only once following release of a severe knee flexion contracture with a knee capsulotomy and concurrent correction of severe planovalgus deformity. Monitoring of the limb for decreased vascular flow and sensory changes is required. Also, increased pain above the expected amount should make surgeons suspicious. Cast removal and measuring intercompartment pressures are indicated if there is ongoing concern. If high compartment pressure is found, acute compartment decompression is required.

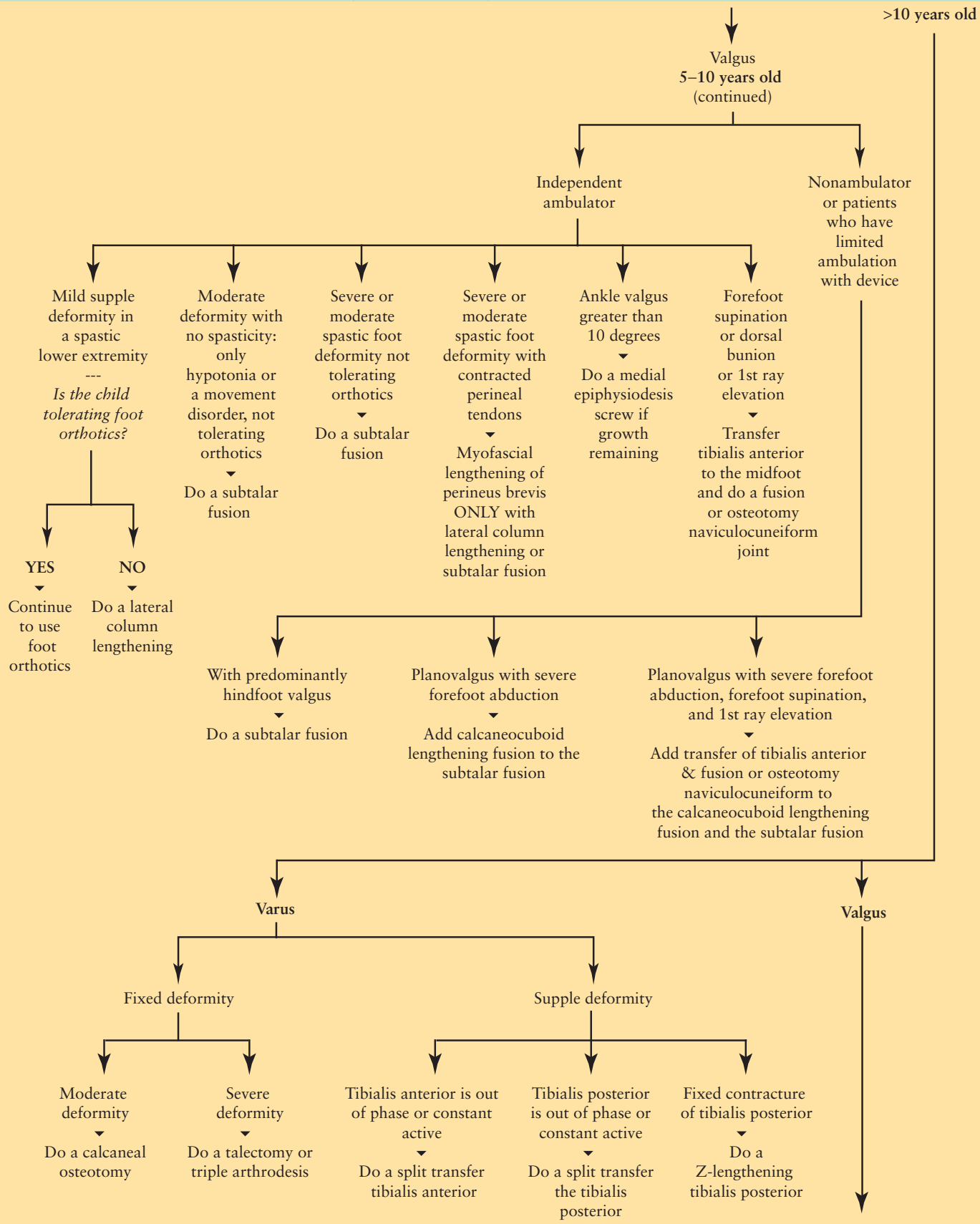
Peroneal Nerve Palsy

Peroneal nerve palsy can occur with tibial osteotomy, although it is rare with distal tibial osteotomies. We have not encountered peroneal nerve palsy. It is also important during the application of short-leg casts to make sure that the cast is not tight and does not have pressure points over the neck of the fibula.





Deformities of the Foot



Varus

Valgus

Fixed deformity

Supple deformity

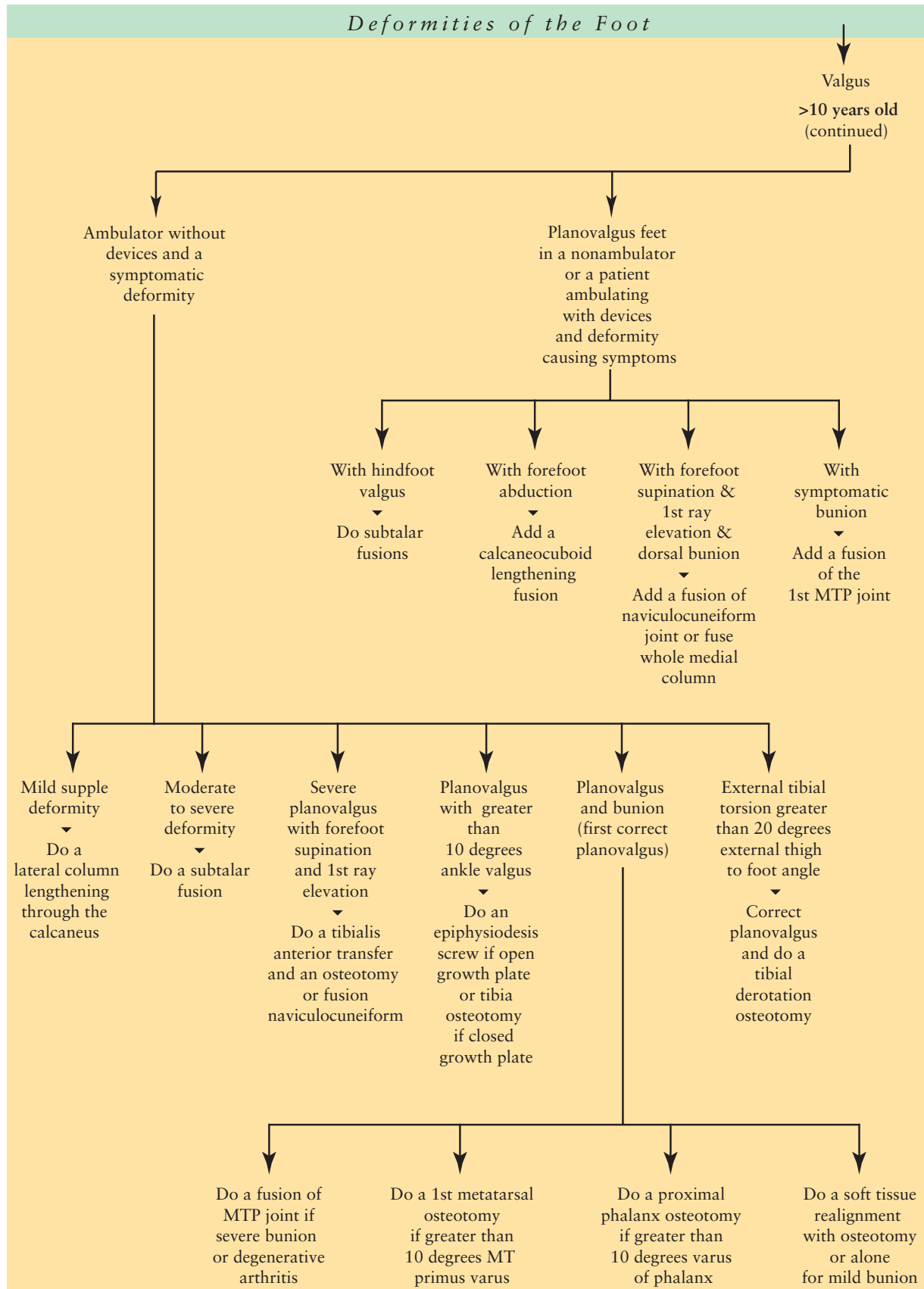
Moderate deformity
Do a calcaneal osteotomy

Severe deformity
Do a talectomy or triple arthrodesis

Tibialis anterior is out of phase or constant active
Do a split transfer tibialis anterior

Tibialis posterior is out of phase or constant active
Do a split transfer the tibialis posterior

Fixed contracture of tibialis posterior
Do a Z-lengthening tibialis posterior



References

1. Siegel IM. Historical vignette #9. Little big man: the life and genius of William John Little (1810–1894). *Orthop Rev* 1988;17:1156, 1161–6.
2. Perry J. *Gait Analysis: Normal and Pathologic Function*. Thorofare, NJ: Slack, 1992.
3. Katz K, Rosenthal A, Yosipovitch Z. Normal ranges of popliteal angle in children. *J Pediatr Orthop* 1992;12:229–31.
4. Delp SL, Arnold AS, Speers RA, Moore CA. Hamstrings and psoas lengths during normal and crouch gait: implications for muscle-tendon surgery. *J Orthop Res* 1996;14:144–51.
5. Hennrikus WL, Rosenthal RK, Kasser JR. Incidence of spondylolisthesis in ambulatory cerebral palsy patients. *J Pediatr Orthop* 1993;13:37–40.
6. Hoffinger SA, Rab GT, Abou-Ghaida H. Hamstrings in cerebral palsy crouch gait. *J Pediatr Orthop* 1993;13:722–6.
7. Thompson NS, Baker RJ, Cosgrove AP, Corry IS, Graham HK. Musculoskeletal modeling in determining the effect of botulinum toxin on the hamstrings of patients with crouch gait. *Dev Med Child Neurol* 1998;40:622–5.
8. Anderson JP, Snow B, Dorey FJ, Kabo JM. Efficacy of soft splints in reducing severe knee-flexion contractures. *Dev Med Child Neurol* 1988;30:502–8.
9. Pascual-Pascual SI, Sanchez de Muniaín P, Roche MC, Pascual-Castroviejo I. Botulinum toxin as a treatment for infantile cerebral palsy. *Rev Neurol* 1997;25:1369–75.
10. Granata KP, Abel MF, Damiano DL. Joint angular velocity in spastic gait and the influence of muscle-tendon lengthening. *J Bone Joint Surg [Am]* 2000;82:174–86.
11. Thometz J, Simon S, Rosenthal R. The effect on gait of lengthening of the medial hamstrings in cerebral palsy. *J Bone Joint Surg [Am]* 1989;71:345–53.
12. Gage JR. Surgical treatment of knee dysfunction in cerebral palsy. *Clin Orthop* 1990;45–54.
13. Nene AV, Evans GA, Patrick JH. Simultaneous multiple operations for spastic diplegia. Outcome and functional assessment of walking in 18 patients. *J Bone Joint Surg [Br]* 1993;75:488–94.
14. DeLuca PA, Ounpuu S, Davis RB, Walsh JH. Effect of hamstring and psoas lengthening on pelvic tilt in patients with spastic diplegic cerebral palsy. *J Pediatr Orthop* 1998;18:712–8.
15. Damiano DL, Abel MF, Pannunzio M, Romano JP. Interrelationships of strength and gait before and after hamstrings lengthening. *J Pediatr Orthop* 1999;19:352–8.
16. Rethlefsen S, Tolo VT, Reynolds RA, Kay R. Outcome of hamstring lengthening and distal rectus femoris transfer surgery. *J Pediatr Orthop B* 1999;8:75–9.
17. Damron T, Breed AL, Roecker E. Hamstring tenotomies in cerebral palsy: long-term retrospective analysis. *J Pediatr Orthop* 1991;11:514–9.
18. Sharps CH, Clancy M, Steel HH. A long-term retrospective study of proximal hamstring release for hamstring contracture in cerebral palsy. *J Pediatr Orthop* 1984;4:443–7.
19. de Windt FH, Spoor CW, Huson A, Duijffes F. A model for the study of hip dysplasia in the spastic child. *Acta Orthop Belg* 1984;50:143–7.
20. Drummond DS, Rogala E, Templeton J, Cruess R. Proximal hamstring release for knee flexion and crouched posture in cerebral palsy. *J Bone Joint Surg [Am]* 1974;56:1598–602.
21. Elmer EB, Wenger DR, Mubarak SJ, Sutherland DH. Proximal hamstring lengthening in the sitting cerebral palsy patient. *J Pediatr Orthop* 1992;12:329–36.
22. Eggers G. Transplantation of the hamstring tendons to femoral condyles in order to improve hip extension and to decrease knee flexion in cerebral spastic paralysis. *J Bone Joint Surg [Am]* 1952;34A:827–830.
23. Bleck E. *Orthopedic Management in Cerebral Palsy*. Oxford: Mac Keith Press, 1987:497.
24. Atar D, Zilberberg L, Votenberg M, Norsy M, Galil A. Effect of distal hamstring release on cerebral palsy patients. *Bull Hosp Jt Dis* 1993;53:34–6.

25. DeVries WH, Kruse RW. Is there a relationship between hypertension and lower-extremity contracture release in cerebral palsy? *Am J Orthop* 1998;27:421–2.
26. Shah A, Asirvatham R. Hypertension after surgical release for flexion contractures of the knee. *J Bone Joint Surg [Br]* 1994;76:274–7.
27. Atar D, Grant AD, Lehman WB. New approach to limb deformities in neuromuscular patients. *Bull Hosp Jt Dis Orthop Inst* 1990;50:99–106.
28. Gage J. *Gait Analysis in Cerebral Palsy*. London: Mac Keith Press, 1991.
29. Feldkamp M. Patella fragmentation in cerebral palsy. *Z Orthop Ihre Grenzgeb* 1990;128:160–4.
30. Rosenthal RK, Levine DB. Fragmentation of the distal pole of the patella in spastic cerebral palsy. *J Bone Joint Surg [Am]* 1977;59:934–9.
31. Lloyd-Roberts GC, Jackson AM, Albert JS. Avulsion of the distal pole of the patella in cerebral palsy. A cause of deteriorating gait. *J Bone Joint Surg [Br]* 1985;67:252–4.
32. Ounpuu S, Muik E, Davis RB III, Gage JR, DeLuca PA. Rectus femoris surgery in children with cerebral palsy. Part I: The effect of rectus femoris transfer location on knee motion. *J Pediatr Orthop* 1993;13:325–30.
33. Ounpuu S, Muik E, Davis RB III, Gage JR, DeLuca PA. Rectus femoris surgery in children with cerebral palsy. Part II: A comparison between the effect of transfer and release of the distal rectus femoris on knee motion. *J Pediatr Orthop* 1993;13:331–5.
34. Sutherland DH, Santi M, Abel MF. Treatment of stiff-knee gait in cerebral palsy: a comparison by gait analysis of distal rectus femoris transfer versus proximal rectus release. *J Pediatr Orthop* 1990;10:433–41.
35. Gage JR, Perry J, Hicks RR, Koop S, Wertz JR. Rectus femoris transfer to improve knee function of children with cerebral palsy. *Dev Med Child Neurol* 1987;29:159–66.
36. Miller F, Cardoso Dias R, Lipton GE, Albarracin JP, Dabney KW, Castagno P. The effect of rectus EMG patterns on the outcome of rectus femoris transfers. *J Pediatr Orthop* 1997;17:603–7.
37. Chambers H, Lauer A, Kaufman K, Cardelia JM, Sutherland D. Prediction of outcome after rectus femoris surgery in cerebral palsy: the role of cocontraction of the rectus femoris and vastus lateralis. *J Pediatr Orthop* 1998;18:703–11.
38. Damiano DL, Abel MF. Functional outcomes of strength training in spastic cerebral palsy. *Arch Phys Med Rehabil* 1998;79:119–25.
39. Damiano DL, Kelly LE, Vaughn CL. Effects of quadriceps femoris muscle strengthening on crouch gait in children with spastic diplegia. *Phys Ther* 1995;75:658–67; discussion 668–71.
40. Mann M. Fatigue fractures of the lower patellar pole in adolescents with cerebral movement disorders. *Z Orthop Ihre Grenzgeb* 1984;122:167–70.
41. Topoleski TA, Kurtz CA, Grogan DP. Radiographic abnormalities and clinical symptoms associated with patella alta in ambulatory children with cerebral palsy. *J Pediatr Orthop* 2000;20:636–9.
42. Feldkamp M, Katthagen EW. Results of surgical correction of flexion contractures of the knee joint in CP children (author's transl.). *Z Orthop Ihre Grenzgeb* 1975;113:181–8.
43. Normand X, Dubouset J. Reinforcement of the tension of the knee extensor apparatus in triple-flexion gait in children with motor disorders. *Rev Chir Orthop Reparatrice Appar Mot* 1985;71:301–10.
44. Michele AA, Nielsen PM. Tibiotalar torsion: bioengineering paradigm. *Orthop Clin North Am* 1976;7:929–47.
45. Staheli LT. Torsion: treatment indications. *Clin Orthop* 1989:61–6.
46. Delgado ED, Schoenecker PL, Rich MM, Capelli AM. Treatment of severe torsional malalignment syndrome. *J Pediatr Orthop* 1996;16:484–8.
47. Villani C, Billi A, Morico G, Calvisi V, Romanini L. Considerations on deformity of the foot and suprasegmental pathology in infantile cerebral palsy. *Ital J Orthop Traumatol* 1989;15:197–207.
48. Joseph B, Carver RA, Bell MJ, et al. Measurement of tibial torsion by ultrasound. *J Pediatr Orthop* 1987;7:317–23.

49. Stefko RM, de Swart RJ, Dodgin DA, et al. Kinematic and kinetic analysis of distal derotational osteotomy of the leg in children with cerebral palsy. *J Pediatr Orthop* 1998;18:81–7.
50. Vankoski SJ, Michaud S, Dias L. External tibial torsion and the effectiveness of the solid ankle-foot orthoses. *J Pediatr Orthop* 2000;20:349–55.
51. Bennett JT, Bunnell WP, MacEwen GD. Rotational osteotomy of the distal tibia and fibula. *J Pediatr Orthop* 1985;5:294–8.
52. Dodgin DA, De Swart RJ, Stefko RM, Wenger DR, Ko JY. Distal tibial/fibular derotation osteotomy for correction of tibial torsion: review of technique and results in 63 cases. *J Pediatr Orthop* 1998;18:95–101.
53. McNicol D, Leong JC, Hsu LC. Supramalleolar derotation osteotomy for lateral tibial torsion and associated equinovarus deformity of the foot. *J Bone Joint Surg [Br]* 1983;65:166–70.
54. Krenzel WF, 3rd, Staheli LT. Tibial rotational osteotomy for idiopathic torsion. A comparison of the proximal and distal osteotomy levels. *Clin Orthop* 1992;285–9.
55. Lee LW, Kerrigan DC, Della Croce U. Dynamic implications of hip flexion contractures. *Am J Phys Med Rehabil* 1997;76:502–8.
56. Liggio F, Kruse R. Split tibialis posterior tendon transfer with concomitant distal tibial derotation osteotomy in children with cerebral palsy. *J Pediatr Orthop* 2001;21:95–101.
57. Rattey T, Hyndman J. Rotational osteotomies of the leg: tibia alone versus both tibia and fibula. *J Pediatr Orthop* 1994;14:615–8.
58. Dias LS. Valgus deformity of the ankle joint: pathogenesis of fibular shortening. *J Pediatr Orthop* 1985;5:176–80.
59. McCall RE, Lillich JS, Harris JR, Johnston FA. The Grice extraarticular subtalar arthrodesis: a clinical review. *J Pediatr Orthop* 1985;5:442–5.
60. Scott SM, Janes PC, Stevens PM. Grice subtalar arthrodesis followed to skeletal maturity. *J Pediatr Orthop* 1988;8:176–83.
61. Hsu LC, Yau AC, O'Brien JP, Hodgson AR. Valgus deformity of the ankle resulting from fibular resection for a graft in subtalar fusion in children. *J Bone Joint Surg [Am]* 1972;54:585–94.
62. Beals RK. The treatment of ankle valgus by surface epiphyseodesis. *Clin Orthop* 1991;162–9.
63. Davids JR, Valadie AL, Ferguson RL, Bray EW III, Allen BL Jr. Surgical management of ankle valgus in children: use of a transphyseal medial malleolar screw. *J Pediatr Orthop* 1997;17:3–8.
64. Stevens PM, Belle RM. Screw epiphyseodesis for ankle valgus. *J Pediatr Orthop* 1997;17:9–12.
65. Silfverskiold N. Reduction of the uncrossed two joint muscles of the leg to one-joint muscles in spastic conditions. *Acta Chir Scand (1923–1924)* 1923;56:315–30.
66. Perry J, Hoffer MM, Giovan P, Antonelli D, Greenberg R. Gait analysis of the triceps surae in cerebral palsy. A preoperative and postoperative clinical and electromyographic study. *J Bone Joint Surg [Am]* 1974;56:511–20.
67. Davids JR, Foti T, Dabelstein J, Bagley A. Voluntary (normal) versus obligatory (cerebral palsy) toe-walking in children: a kinematic, kinetic, and electromyographic analysis. *J Pediatr Orthop* 1999;19:461–9.
68. Kelly IP, Jenkinson A, Stephens M, O'Brien T. The kinematic patterns of toe-walkers. *J Pediatr Orthop* 1997;17:478–80.
69. Kalen V, Adler N, Bleck EE. Electromyography of idiopathic toe walking. *J Pediatr Orthop* 1986;6:31–3.
70. Yngve DA, Chambers C. Vulpius and Z-lengthening. *J Pediatr Orthop* 1996;16:759–64.
71. Saraph V, Zwick EB, Uitz C, Linhart W, Steinwender G. The Baumann procedure for fixed contracture of the gastrocsoleus in cerebral palsy. Evaluation of function of the ankle after multilevel surgery. *J Bone Joint Surg [Br]* 2000;82:535–40.
72. Novacheck TF, Stout JL, Tervo R. Reliability and validity of the Gillette Functional Assessment Questionnaire as an outcome measure in children with walking disabilities. *J Pediatr Orthop* 2000;20:75–81.

73. Craig JJ, van Vuren J. The importance of gastrocnemius recession in the correction of equinus deformity in cerebral palsy. *J Bone Joint Surg [Br]* 1976;58:84–7.
74. Lee CL, Bleck EE. Surgical correction of equinus deformity in cerebral palsy. *Dev Med Child Neurol* 1980;22:287–92.
75. Sharrard WJ, Bernstein S. Equinus deformity in cerebral palsy. A comparison between elongation of the tendo calcaneus and gastrocnemius recession. *J Bone Joint Surg [Br]* 1972;54:272–6.
76. Doute DA, Sponseller PD, Tolo VT, Atkins E, Silberstein CE. Soleus neurectomy for dynamic ankle equinus in children with cerebral palsy. *Am J Orthop* 1997;26:613–6.
77. Pierrot AH, Murphy OB. Albert E. Klinkicht Award, 1972. Heel cord advancement. A new approach to the spastic equinus deformity. *Orthop Clin North Am* 1974;5:117–26.
78. Strecker WB, Via MW, Oliver SK, Schoenecker PL. Heel cord advancement for treatment of equinus deformity in cerebral palsy. *J Pediatr Orthop* 1990;10:105–8.
79. Carmick J. Managing equinus in children with cerebral palsy: electrical stimulation to strengthen the triceps surae muscle. *Dev Med Child Neurol* 1995;37:965–75.
80. Lespargot A, Robert M, Khouri N. Stretching the triceps surae muscle after 40 degrees C warming in patients with cerebral palsy. *Rev Chir Orthop Reparatrice Appar Mot* 2000;86:712–17.
81. Chicoine MR, Park TS, Kaufman BA. Selective dorsal rhizotomy and rates of orthopedic surgery in children with spastic cerebral palsy. *J Neurosurg* 1997;86:34–9.
82. Cottalorda J, Gautheron V, Charmet E, Chavier Y. Muscular lengthening of the triceps by successive casts in children with cerebral palsy. *Rev Chir Orthop Reparatrice Appar Mot* 1997;83:368–71.
83. Corry IS, Cosgrove AP, Duffy CM, McNeill S, Taylor TC, Graham HK. Botulinum toxin A compared with stretching casts in the treatment of spastic equinus: a randomized prospective trial. *J Pediatr Orthop* 1998;18:304–11.
84. Koman LA, Mooney JF III, Smith BP, Walker F, Leon JM. Botulinum toxin type A neuromuscular blockade in the treatment of lower extremity spasticity in cerebral palsy: a randomized, double-blind, placebo-controlled trial. BOTOX Study Group. *J Pediatr Orthop* 2000;20:108–15.
85. Grant AD, Feldman R, Lehman WB. Equinus deformity in cerebral palsy: a retrospective analysis of treatment and function in 39 cases. *J Pediatr Orthop* 1985;5:678–81.
86. Segal LS, Thomas SE, Mazur JM, Mauterer M. Calcaneal gait in spastic diplegia after heel cord lengthening: a study with gait analysis. *J Pediatr Orthop* 1989;9:697–701.
87. Borton DC, Walker K, Pirpiris M, Natrass GR, Graham HK. Isolated calf lengthening in cerebral palsy. Outcome analysis of risk factors. *J Bone Joint Surg [Br]* 2001;83:364–70.
88. Dillin W, Samilson RL. Calcaneus deformity in cerebral palsy. *Foot Ankle* 1983;4:167–70.
89. Waugh TR, Wagner J, Stinchfield FE. An evaluation of pantalar arthrodesis. A follow-up study of one hundred and sixteen operations. *J Bone Joint Surg [Am]* 1965;47:1315–22.
90. Dwyer FC. The present status of the problem of pes cavus. *Clin Orthop* 1975:254–75.
91. Minagawa A. Study of weight-bearing changes of normal and abnormal feet by frontal tomography (author's transl.). *Nippon Seikeigeka Gakkai Zasshi* 1979;53:181–98.
92. Walker M, Fan HJ. Relationship between foot pressure pattern and foot type. *Foot Ankle Int* 1998;19:379–83.
93. Coleman SS, Chesnut WJ. A simple test for hindfoot flexibility in the cavovarus foot. *Clin Orthop* 1977:60–2.
94. Renders A, Detrembleur C, Rossillon R, Lejeune T, Rombouts JJ. Contribution of electromyographic analysis of the walking habits of children with spastic foot

- in cerebral palsy: a preliminary study. *Rev Chir Orthop Reparatrice Appar Mot* 1997;83:259–64.
95. Green NE, Griffin PP, Shiavi R. Split posterior tibial-tendon transfer in spastic cerebral palsy. *J Bone Joint Surg [Am]* 1983;65:748–54.
 96. Detrembleur C, Willems P, Plaghki L. Does walking speed influence the time pattern of muscle activation in normal children? *Dev Med Child Neurol* 1997;39:803–7.
 97. Kagaya H, Yamada S, Nagasawa T, Ishihara Y, Kodama H, Endoh H. Split posterior tibial tendon transfer for varus deformity of hindfoot. *Clin Orthop* 1996:254–60.
 98. Vogt JC. Split anterior tibial transfer for spastic equinovarus foot deformity: retrospective study of 73 operated feet. *J Foot Ankle Surg* 1998;37:2–7; discussion 78.
 99. Taussig G, Aufaure P, Pilliard D. Tendon surgery in equinovarus deformity of the foot in children and adolescents with cerebral palsy. *Rev Chir Orthop Reparatrice Appar Mot* 1990;76:128–36.
 100. Ruda R, Frost HM. Cerebral palsy. Spastic varus and forefoot adductus, treated by intramuscular posterior tibial tendon lengthening. *Clin Orthop* 1971;79:61–70.
 101. Barnes MJ, Herring JA. Combined split anterior tibial-tendon transfer and intramuscular lengthening of the posterior tibial tendon. Results in patients who have a varus deformity of the foot due to spastic cerebral palsy. *J Bone Joint Surg [Am]* 1991;73:734–8.
 102. Hoffer MM, Reiswig JA, Garrett AM, Perry J. The split anterior tibial tendon transfer in the treatment of spastic varus hindfoot of childhood. *Orthop Clin North Am* 1974;5:31–8.
 103. Hoffer MM, Barakat G, Koffman M. 10-year follow-up of split anterior tibial tendon transfer in cerebral palsied patients with spastic equinovarus deformity. *J Pediatr Orthop* 1985;5:432–4.
 104. Hehne HJ, Baumann JU. Dwyer's calcaneal osteotomy for varus deformity of the foot. A follow-up study including gait analysis (author's transl.). *Z Orthop Ihre Grenzgeb* 1979;117:202–11.
 105. Root L, Miller SR, Kirz P. Posterior tibial-tendon transfer in patients with cerebral palsy. *J Bone Joint Surg [Am]* 1987;69:1133–9.
 106. Johnson WL, Lester EL. Transposition of the posterior tibial tendon. *Clin Orthop* 1989:223–7.
 107. Mulier T, Moens P, Molenaers G, Spaepen D, Dereymaeker G, Fabry G. Split posterior tibial tendon transfer through the interosseus membrane in spastic equinovarus deformity. *Foot Ankle Int* 1995;16:754–9.
 108. Saji MJ, Upadhyay SS, Hsu LC, Leong JC. Split tibialis posterior transfer for equinovarus deformity in cerebral palsy. Long-term results of a new surgical procedure [published erratum appears in *J Bone Joint Surg [Br]* 1994;76(4):683]. *J Bone Joint Surg [Br]* 1993;75:498–501.
 109. Hiroshima K, Hamada S, Shimizu N, Ohshita S, Ono K. Anterior transfer of the long toe flexors for the treatment of spastic equinovarus and equinus foot in cerebral palsy. *J Pediatr Orthop* 1988;8:164–8.
 110. Ono K, Hiroshima K, Tada K, Inoue A. Anterior transfer of the toe flexors for equinovarus deformity of the foot. *Int Orthop* 1980;4:225–9.
 111. Kling TF Jr, Kaufer H, Hensinger RN. Split posterior tibial-tendon transfers in children with cerebral spastic paralysis and equinovarus deformity. *J Bone Joint Surg [Am]* 1985;67:186–94.
 112. Bennet GC, Rang M, Jones D. Varus and valgus deformities of the foot in cerebral palsy. *Dev Med Child Neurol* 1982;24:499–503.
 113. Epeldegui T, Delgado E. Acetabulum pedis. Part I: Talocalcaneonavicular joint socket in normal foot. *J Pediatr Orthop B* 1995;4:1–10.
 114. Sarrafian SK. Biomechanics of the subtalar joint complex. *Clin Orthop* 1993:17–26.
 115. Alman BA, Craig CL, Zimble S. Subtalar arthrodesis for stabilization of valgus hindfoot in patients with cerebral palsy. *J Pediatr Orthop* 1993;13:634–41.

116. Nather A, Fulford GE, Stewart K. Treatment of valgus hindfoot in cerebral palsy by peroneus brevis lengthening. *Dev Med Child Neurol* 1984;26:335–40.
117. Evans D. Calcaneo-valgus deformity. *J Bone Joint Surg [Br]* 1975;57:270–8.
118. Barrasso JA, Wile PB, Gage JR. Extraarticular subtalar arthrodesis with internal fixation. *J Pediatr Orthop* 1984;4:555–9.
119. Bhan S, Malhotra R. Subtalar arthrodesis for flexible hindfoot deformities in children. *Arch Orthop Trauma Surg* 1998;117:312–5.
120. Guttmann GG. Subtalar arthrodesis in children with cerebral palsy: results using iliac bone plug. *Foot Ankle* 1990;10:206–10.
121. Keats S, Kouten J. Early surgical correction of the planovalgus foot in cerebral palsy. Extra-articular arthrodesis of the subtalar joint. *Clin Orthop* 1968;61:223–33.
122. Romanini L, Carfagni A, Amorese V. Grice's operation for spastic flat foot. *Ital J Orthop Traumatol* 1983;9:439–49.
123. Mosca VS. Calcaneal lengthening for valgus deformity of the hindfoot. Results in children who had severe, symptomatic flatfoot and skewfoot. *J Bone Joint Surg [Am]* 1995;77:500–12.
124. Andreacchio A, Orellana CA, Miller F, Bowen TR. Lateral column lengthening as treatment for planovalgus foot deformity in ambulatory children with spastic cerebral palsy. *J Pediatr Orthop* 2000;20:501–5.
125. Tenuta J, Shelton YA, Miller F. Long-term follow-up of triple arthrodesis in patients with cerebral palsy. *J Pediatr Orthop* 1993;13:713–6.
126. Ireland ML, Hoffer M. Triple arthrodesis for children with spastic cerebral palsy. *Dev Med Child Neurol* 1985;27:623–7.
127. Koman LA, Mooney JF III, Goodman A. Management of valgus hindfoot deformity in pediatric cerebral palsy patients by medial displacement osteotomy. *J Pediatr Orthop* 1993;13:180–3.
128. Crawford AH, Kucharzyk D, Roy DR, Bilbo J. Subtalar stabilization of the planovalgus foot by staple arthroereisis in young children who have neuromuscular problems. *J Bone Joint Surg [Am]* 1990;72:840–5.
129. Smith PA, Millar EA, Sullivan RC. Sta-Peg arthroereisis for treatment of the planovalgus foot in cerebral palsy. *Clin Podiatr Med Surg* 2000;17:459–69.
130. Vedantam R, Capelli AM, Schoenecker PL. Subtalar arthroereisis for the correction of planovalgus foot in children with neuromuscular disorders. *J Pediatr Orthop* 1998;18:294–8.
131. Seymour N, Evans DK. A modification of the Grice subtalar arthrodesis. *J Bone Joint Surg [Br]* 1968; 50:372–5.
132. Cahuzac M, Claverie P, Nichil J, Caranobe J. Results and limitations of rehabilitation in cerebral palsy. *Rev Chir Orthop Reparatrice Appar Mot* 1977;63:609–22.
133. Dennyson WG, Fulford GE. Subtalar arthrodesis by cancellous grafts and metallic internal fixation. *J Bone Joint Surg [Br]* 1976;58B:507–10.
134. Fulford GE. Surgical management of ankle and foot deformities in cerebral palsy. *Clin Orthop* 1990:55–61.
135. Eilert RE. Cavus foot in cerebral palsy. *Foot Ankle* 1984;4:185–7.
136. Holstein A. Hallux valgus: an acquired deformity of the foot in cerebral palsy. *Foot Ankle* 1980;1:33–8.
137. Goldner JL. Hallux valgus and hallux flexus associated with cerebral palsy: analysis and treatment. *Clin Orthop* 1981:98–104.
138. Jenter M, Lipton GE, Miller F. Operative treatment for hallux valgus in children with cerebral palsy. *Foot Ankle Int* 1998;19:830–5.
139. Davids JR, Mason TA, Danko A, Banks D, Blackhurst D. Surgical management of hallux valgus deformity in children with cerebral palsy. *J Pediatr Orthop* 2001;21:89–94.
140. Wang YL, Tsau JC, Huang MH, Lee BF, Li CH. Reflex sympathetic dystrophy syndrome in stroke patients with hemiplegia—three phase bone scintigraphy and clinical characteristics. *Kao Hsiung I Hsueh Ko Hsueh Tsa Chih* 1998;14:40–7.



SECTION II

Rehabilitation
Techniques

Many interventions have been applied to treat cerebral palsy, but when all is said and done we are still dealing with a nervous system that is impaired in many different ways. Some of the interventions that we are applying to children with cerebral palsy (CP) are really attempts at remediation of the consequences of weakness or abnormal tone. The interventions we apply have their own side effects and limitations. As a consequence, we can fall into a trap and apply these interventions with an intensity that sends an unfair signal to the child and family. That signal is that we can make the child normal. We do not make damaged nervous systems normal. In many cases, we simply teach and/or trick the child's nervous system to cope and provide strategies that alter some of the side effects and, in some cases, simply delude ourselves.

1. Neurodevelopmental Therapy

Elizabeth Jeanson, PT

In the 1960s and early 1970s, pediatric therapists for CP appeared distinct from therapists who trained on poliomyelitis cases and from there quickly developed a cadre of therapists who practiced neurodevelopmental therapy (NDT). Neurodevelopmental treatment has gone through a long evolution over the years. Time has forced it to become more eclectic and become one of the most commonly used intervention strategies for children from infancy through adulthood with CP.¹ Since the conception of NDT by Dr. Karl and Mrs. Berta Bobath in the 1940s, the scientific community's understanding of the brain and the conceptual framework of NDT has evolved. As our understanding of how the brain inspires and controls movement evolves, so does the theory of NDT into what is currently accepted as the Dynamic Systems Theory. In this way NDT is a "living concept."² It adapts and grows as knowledge of the brain's function is revealed.

Using the Dynamic Systems Theory, NDT-trained therapists are able to use a variety of handling techniques. These specialized techniques encourage active use of appropriate muscles and diminish involvement of muscles not necessary for the completion of a task. Child-directed and -initiated movement tasks are critical to the success of neurodevelopmental treatment.² Therapists practicing NDT set functional individual session goals, which build upon each other to facilitate new motor skills or improve the efficiency of learned motor tasks. Improvements in efficiency can include decreased energy used during a task, decreased work required of the muscles during a task, and habituation of new patterns of movement. These tasks are specific to and driven by the functional needs of the child. In NDT the child takes an active role in treatment design. The therapist must be constantly evaluating their input into the child's movement with the goal of active, habituated, independent movement.

NDT is a problem-solving approach focusing on the individual's current needs while aiming for the long-term goal of function across the lifespan.² Occupational, speech, and physical therapists as well as educators can use NDT. The benefits of utilizing NDT include improved ability to perform functional activities appropriate to the needs of the individual, active participation of the child, improved strength, flexibility, and alignment, and improved function over a lifespan. NDT is not an exclusive treatment for individuals with CP.

NDT-trained therapists have completed an 8-week pediatric or a 3-week adult course, and some, an additional 3-week infant postgraduate course.

Practicing therapists can be found in every community. Therapists can learn about the theory and techniques at a variety of continuing education courses offered throughout the year and over the course of many years.

2. Strengthening Exercises

Diane Damiano, PhD

In past years, several clinical myths existed about what one should never provide to patients with CP, such as “no plastic for spastics” when prescribing orthoses or “never strengthen spasticity.” Recent research has provided evidence to dispel these myths and bring a new level of awareness of how children with CP can be helped. It has always been known that increased tone is not the only or even the most significant impairment of CP, but that there is poor recruitment of muscle unit activity and inconsistent maintenance of maximum efforts. Research that investigates muscle strengthening has contributed to this understanding.

More than 50 years ago, Phelps proposed that resisted exercise “to develop strength or skill in a weakened muscle or an impaired muscle group” was an integral part of treatment in CP.³ Shortly thereafter, physical therapists denounced strengthening for their patients with upper motor neuron syndromes based primarily on the clinical concern that such strong physical effort would exacerbate spasticity. However, scientific evidence has been accumulating in recent years that dispels this contention and supports the effectiveness of strength training for improving motor function in CP as well as in other neuromotor disorders. Muscle strength is related to motor performance and should be an integral part of a rehabilitation program that addresses other impairments which inhibit motor performance in this population, such as muscle–tendon shortening, spasticity, and coordination deficits.

It has been shown that even highly functional children with spastic CP are likely to have considerable weakness in their involved extremities compared to age-related peers, with the degree of weakness increasing with the level of neurologic involvement.^{4,5} If a child has at least some voluntary control in a muscle group, the capacity for strengthening exists. In the absence of voluntary control, strength training is more problematic, but may be facilitated by the use of electrical stimulation or by strengthening within synergistic movement patterns. However, strengthening is only justifiable if the ultimate goal is to improve a specific motor skill or function. Therefore, a child with little or no capacity for voluntary muscle control is unlikely to experience substantial functional benefits from a strength-training program. Most ambulatory children with CP have the capacity to strengthen their muscles, although poor isolated control or inadequate length in the ankle dorsiflexor or the hamstring muscles may limit progress in some patients. Nonambulatory children may also experience improvements in their ability to use their upper extremities, transfer more effectively, or engage more actively in recreational and fitness activities. Invasive procedures such as muscle–tendon lengthening, selective dorsal rhizotomy, intrathecal baclofen pump implantation, or botulinum toxin injections may improve muscle length and/or control so that muscles can then be strengthened more effectively. In turn, strength training may serve to augment or prolong the outcomes of these procedures.

To participate in a strength-training program, the child must be able to comprehend and to consistently produce a maximal or near-maximal effort. Children as young as 3 years of age may be capable of this, but waiting to augment the program until the child is age 4 or 5 years is more realistic.

Motivational and attentional factors can also affect a program's success. Family compliance with the treatment schedule and protocol is also critical.

The same physiologic principles that underlie the development of muscle strength apply whether or not a person has CP. Load is the stimulus for increasing strength and it should be close to an individual's maximum to achieve measurable gains. In practical terms, this would mean that a person should be able to lift a specified load two to three times before experiencing fatigue or a decrement in performance. Data on the specific treatment regimens to differentially train for strength, endurance, or power in this population, or which muscles can and should be strengthened to impart the greatest functional benefits, are not yet available specifically for CP, although useful guidelines may be found in the literature.^{6,7} The number of repetitions and how these are grouped in a session will vary depending on the desired functional goals. For example, if the focus were on strengthening, an optimal program would be to use high loads with a low number of repetitions (3 to 8) arranged in multiple sets with a rest between each set. In contrast, if the therapist is more interested in improving muscle endurance, the load does not need to be quite so high, but repetitions should be greater (8 to 20) before resting. As the patient improves, the load and/or the number of repetitions can be increased depending again on the therapist's goal. If the goal is to try to increase strength, the recommended frequency of sessions is three times a week.

It seems logical that muscles across the joint from those that tend to be spastic are good candidates for strengthening. In spastic CP, for example, one might consider strengthening any or all of the following: elbow extensors, forearm pronators, wrist extensors, hip extensors and abductors, knee extensors, and ankle dorsiflexors. However, weakness can be present in other muscles that may also disrupt performance, such as the ankle plantar flexors or hip flexors, which are important power producers in gait. Both absolute and relative strength across a joint should be considered when designing protocols to avoid exacerbating muscle imbalance and contractures. Sample isotonic and isokinetic training programs are shown in Tables R1 and R2. Strengthening does not necessarily require weights, or devices, but can be achieved through multiple activities so long as the intensity of the load is sufficiently high to stress the muscle. Some other options for strength training include treadmill training, aquatic resistive exercise, and many different sports and recreational activities.

Weight training is deemed to be safe for children of all ages when performed properly.⁸ Before the completion of physical growth, training loads should not exceed maximum to avoid damaging developing musculoskeletal structures. Other safety considerations include a more gradual buildup in the amount of resistance for children who are particularly weak or inactive, not allowing a child to lift weights without adult supervision, and not letting

Table R1. Sample isotonic program.

<p>GOAL: Increase hip flexor and knee extensor strength for faster, more upright gait pattern</p> <p>LOAD: Use free ankle weights at 80% maximum</p> <p>FREQUENCY/DURATION: 3 times per week for 8 weeks</p> <p>SESSION: 4 sets of 5 repetitions each (total = 20) for both muscle groups on right and left legs</p> <p>POSITION: Hip: Supported standing while lifting leg as in high "marching"; knee: sitting on chair with feet off the ground while extending knee slowly</p> <p>PROGRESS: Strength measured and load increased every 2 weeks throughout program</p>

Table R2. Sample isokinetic program.

<p>GOAL: Increase torque and rate of torque production in knee extensor and ankle dorsiflexor muscles on a hemiplegic extremity to improve gait</p> <p>LOAD: Accommodating resistance with “window” set at 80%–90% of maximum effort</p> <p>FREQUENCY/DURATION: Three times per week for 8 weeks</p> <p>SESSION: Ten repetitions (concentric) at 2 speeds (30, 60/sec) with rests as needed; 10 repetitions (eccentric) at 30°/sec for each muscle group</p> <p>POSITION: Semireclining sitting position on device using standard knee and ankle attachments and protocols</p> <p>PROGRESS: Increased to higher speed by 30 as soon as person can exert force to match speed of machine throughout the range (concentric only)</p>
--

a weight dangle on a limb in the absence of muscle effort or external support. Children should not exercise the same muscle group on consecutive days. If excessive soreness is present or persists, or if muscle tightness worsens as a result of the strengthening program, the protocol should be modified. The presence of a seizure disorder may also preclude participation for some patients if these are poorly controlled by medication and are exacerbated by increased physical effort. Physician approval should be obtained before initiating a weight-training program with any child.

Both isotonic and isokinetic training programs have been shown to increase strength and motor function in CP, as quantified by the Gross Motor Function Measure.^{9–14} Gait improvements that have been reported include increased velocity at free and fastest speed, primarily through increased cadence, increased active motion in the muscles trained, and greater stability in stance.^{9,11,14–16} Improved self-perception has also been noted,¹⁰ but more research is needed to examine these and other effects from specific programs and activities.

Weakness limits functional performance in CP, but can be improved through training. Therapists should also be more proactively involved in prevention of secondary impairments and promotion of wellness and fitness in their patients. Strength and endurance training are important components of fitness, and may promote more optimal health across the lifespan and increase participation in recreational, social, and occupational activities in children and adults with CP.

3. Balance Interventions

Betsy Mullan, PT, PCS

The impairments of motor control and tone in and of themselves can present a balance problem to patients, or there can even be further impairments of the vestibular and sensory system, which affect balance and equilibrium, thus creating an even more complicated picture.

Balance cannot be separated from the action of which it is an integral component or from the environment in which it is performed.¹⁷ Normal balance development involves three systems: the vestibular, visual, and somatosensory. Initially, vision is critical to postural control development, peaking during times when major gross motor development skill transitions occur in sitting to crawling, crawling to standing, and standing to walking.¹⁸ Postural responses, such as those of children on a moving platform, vary with the age of the child. The apparent integration of the visual, vestibular, and somatosensory inputs appears to occur by 4 to 6 years of age, with the responses of the 7- to 10-year-old group being similar to adults.¹⁹

Cerebral palsy is a disorder with multisystem impairments, which may affect the visual, vestibular, and/or somatosensory systems. Nasher et al. found inappropriate sequencing of muscle activity, poor anticipatory regulation of muscle sequencing during postural control, and postural stability that was frequently interrupted by destabilizing synergistic or antagonistic muscle activity in individuals with CP.²⁰ It is evident that physical therapists working with individuals with CP need to assess as well as address these balance issues, keeping in mind the action that is required and the environment in which it is being performed.

Balance is a component of most, if not all, developmental assessments including the Gross Motor Function Measure, the Bruininks–Osterestky Test of Motor Proficiency, the Peabody Developmental Motor Scales, and the WeeFIM. These tests can be useful in helping the therapist ascertain whether the balance issue is visual (eyes open or closed), vestibular, or somatosensory (is the surface moving or not). It is also important to evaluate the child's balance needs and deficits relative to their task demands (sitting independently for dressing versus going to school and navigating the busy hallways), as well as the child's and parents' concerns and goals. This information can then be utilized to customize a treatment program.

Interventions should include various handling and treatment techniques mentioned elsewhere in this volume to help the child achieve success. Environments must be structured and tasks created in both open and closed situations to allow the greatest carryover to functional life skills. Closed tasks²¹ are those whose characteristics do not change from one trial to the next; these require less information processing with practice. Open tasks²¹ require more information processing. In closed environments²¹ in which surroundings are fixed, children do not need to fit their balance into external timing, but can manage the situation at their own speed. Open environments require more attention and information processing.

Clinicians should keep in mind the action requiring balance, as well as the environment in which the child needs to function,¹⁷ to appropriately assess and plan interactions to maximize a child's function in their environment.

4. Electrical Stimulation Techniques

Adam J. Rush, MD

An area that has received a great deal of press and a great deal of anecdotal experience is the role of electrical stimulation in CP. A review of the literature is very confusing, and there is great inconsistency from one medical center to the next as to what they are referring. Dr. L.J. Michaud probably has the most lucid discussion of electrical stimulation in CP.²²

Making recommendations regarding which children should receive neuromuscular electrical stimulation (NMES) or transcutaneous electrical stimulation (TES) is a problem. Although there is no literature indicating that any particular group of children were likely to be harmed by it, or less likely to benefit, most children studied were mild to moderately affected by CP and seemed to have fairly good cognition. Furthermore, the worst side effect reported was a local skin reaction from the stimulating pads. Therefore, one could say that this is a harmless intervention that might be attempted in any child with CP. However, studies have not been performed comparing various regimens with each other.

We appear to have a recurring theme of therapists applying NMES and choosing their stimulation parameters based on personal experience, rather than based on good science. Dr. Michaud's article suggests the following,

which strikes one as a reasonable place to begin: stimulus frequency, 45 to 50 Hz; stimulus intensity, maximum tolerated; on/off times, 10/50 seconds, or triggered; ramps, 1 to 5 seconds, or to comfort; treatment duration, 10 to 15 repetitions; frequency, 3 to 5 days per week.²²

There are a number of studies regarding the relative utility of resistance exercise, NMES, or both.²³ Results vary, but they could be summarized to say that NMES is better than nothing, and not quite as good as resistance exercise alone, but that doing both is redundant.

5. Hippotherapy

Stacey Travis, MPT

Children benefit from movement and novelty. There have been some improvements in limb placement and balance and equilibrium seen in children who worked on the Bobath balls during neurodevelopment therapy. Hippotherapy gives them, if you will, a hairy, olfactory-stimulating, warm, four-legged Bobath ball platform on which a trained therapist can capitalize on motor control, stretching, and equilibrium as the therapist works with the child.^{24–33} The North American Riding for the Handicapped Association (NARHA) has defined hippotherapy as “The use of the movement of a horse as a tool by physical therapists, occupational therapists, and speech-language pathologists to address impairments, functional limitations and disabilities in patients with neuromusculoskeletal dysfunction. This tool is used as part of an integrated treatment program to achieve functional outcomes.”³³

Years of traditional, clinic-based therapy can become tedious and ineffective for both the therapist and the child. Hippotherapy provides therapists and their patients with a novel and effective treatment modality that can spark new interest and enthusiasm. Hippotherapy is used for rehabilitation and is not to be confused with therapeutic riding. Therapeutic riding is not a formal treatment and focuses on recreation or riding skills for disabled riders.²⁷ Hippotherapy subjects must have an initial evaluation, progress notes, and a discharge note, just as any therapy patients.²⁵ It is important to note that this treatment may not be suitable or safe for children with spinal instability, severe osteoporosis, hip dislocation, uncontrolled seizures, spinal fusion, poor static sitting balance (in children >70 pounds), or increased tone after riding.³³ Individuals with CP have little experience with rhythmic movements because of impairments that limit their ability to reverse the direction of movement.²⁶ Researchers postulate that a walking horse simulates the triplanar movement of the human pelvis during gait, while the warmth and rhythm of the horse decrease tone and promote relaxation.^{24,29} Theoretically, hippotherapy enables a child with CP to experience rhythmic movement by decreasing impairments and allowing for the self-organization of the movement patterns into functional movement strategies.²⁹ Researchers have supported this theory by reporting a number of observable benefits of hippotherapy^{24–31,33} (Table R3).

The majority of the existing research on hippotherapy consists of subjective studies.^{24,27,28} Results of hippotherapy are difficult to measure objectively due to a lack of valid and reliable instruments. Poor methodology and small sample sizes in the current research cause the results to be insignificant or inconclusive. Fortunately, despite this lack of objectivity, third-party reimbursement has been commonly received for hippotherapy sessions from a wide variety of insurance companies since 1982.³⁰

A typical hippotherapy session lasts from 45 minutes to an hour. Current research is lacking a consensus on a definitive frequency or duration for this

Table R3. Benefits of hippotherapy.

Improves joint co-contraction	Increases attention span
Decreases tone	Mobilizes pelvis, hips, and spine
Decreases energy expenditure with movement	Increases muscle ROM, flexibility, and strength
Improves stability	Increases body awareness
Facilitates weight-shifting	Improves balance
Facilitates postural and equilibrium responses	Improves posture/alignment
Increases visual perception	Increases listening and vestibular skills
Increases self-confidence	Improves gait
Improves respiration	Improves speech and language
Increases coordination	Improves relationships

treatment, but preliminary studies recommend at least 30-minute sessions, two times per week, for at least 10 weeks.³³ Depending on the child, preparation activities may be necessary before mounting the horse.³³ These activities may include stretching or relaxation techniques to prepare the child's body to be ready for the horse. Hippotherapy does not typically use a saddle, but rather a sheepskin or soft pad.^{24,30} This pad allows the child to be treated in almost any position on the horse's back (e.g., supine, prone, quadruped, sitting, side sitting, kneeling) (Figure R1). On the horse, the child wears a helmet and is accompanied by three adults: a therapist, a side walker, and a lead.^{32,33} The therapist may ride along with the child or handle the child from beside the horse. The lead's main responsibility is guiding the horse. He/she walks alongside the horse, even with its eye. The side walker helps the therapist position and focus the child. He/she walks beside the rider's knee using an arm-over-thigh hold. The therapist can use toys or games (rings, balls, slinky) to work on various activities in different positions, or vary the terrain the horse is walking on to further challenge the child. Following the treatment on the horse, the session should end with similar activities on land to promote functional carryover.³⁰

The American Hippotherapy Association has set specific guidelines, qualifications and responsibilities for the therapist using this modality.^{25,33} It is recommended that only a properly trained therapist perform this type of treatment.

6. Aquatic Therapy

*Jesse Hanlon, BS, COTA,
and Mozghan Hines, LPTA*

The therapeutic use of water lies in the art of careful selection to use the many physical properties of water in the most appropriate way to produce a sensible result. Misuse or careless application can mean that well-intended therapy fades into merely tender loving care. Aquatic therapy provides countless opportunities to experience, learn, and enjoy new movement skills, which leads to increase functional skills, mobility and builds self-confidence.

The relief of hypertonus in the spastic type of CP is one of the major advantages of aquatic therapy. When a body is immersed in warm water (92° to 96°F), its core temperature increases, causing reduction in gamma fiber activity, which in turn reduces muscle spindle activity, facilitating muscle

Figure R1. Hippotherapy is performed on horseback with a thin soft saddle. Work on balance and motor coordination is often performed with the child seated backward on the horse (A). Upright sitting stresses balance reactions. Performing hippotherapy requires three staff people. One individual leads the horse while the therapist works with the child, standing alongside the horse. A third assistant is required on the side opposite the therapist to prevent the child from falling and to assist the child in changing positions (B).

A



B



relaxation and reducing spasticity, thus resulting in increased joint range of motion and consequently creating better postural alignment.

Buoyancy, viscosity, turbulence, and hydrostatic pressure are properties of water that can provide assistance or resistance to a body. The property of buoyancy can be utilized in many different ways. Buoyancy can simply be defined as an upward force that counteracts the effect of gravity, providing weight relief. When a body is submerged up to the seventh cervical vertebra, or just below the chin, a person weighs 10% of their body weight on land; at chest level, 30% of body weight on land; and at just below waist, 50% of




Figure R2. A great way to start gait training, especially after surgical procedures, is pool walking. This means the pool needs to have handles available in the water at the correct height.

body weight on land. For a gradual increase in weightbearing activities, the individual can be progressively moved to shallower water, starting in deep water using flotation devices. In addition to providing weight relief from gravitational forces, buoyancy can support movements, which facilitates learning functional skills such as sitting, standing, rolling, or walking before their achievement on land (Figure R2). The buoyant affect of immersion in water is a useful tool after orthopaedic surgery to treat weakness, painful joints, or decreased weight bearing through the lower extremities.

Due to its hydrostatic pressure, water is a natural brace to the trunk and a compression garment for lower extremities. This makes it possible for patients with postoperative edema to exercise in the water without wearing a pressure garment, and assists the therapist when working toward the goal of weaning an individual from a trunk brace, such as a thoracic lumbar spine orthosis (TLSO), after spinal surgery. Hydrostatic pressure also challenges breath control and voice projection while strengthening the respiratory muscles.

The viscosity of water acts as resistance to movement, meaning the faster the motion, the greater the resistance. This isokinetic trait of water is helpful in smoothing out ataxic movements and improving balance reactions by allowing increased response time. Hand paddles, walking boots, fins, and flotation devices can be added to maximize water's resistance in a progressive resistive strengthening program. Sensory and vestibular issues can also be addressed in an aquatics environment. Underwater swimming, splashing, water play, and pouring are examples of sensory exercises. The vestibular system can be challenged through activities such as spinning in an innertube, flips underwater, the game of Marco Polo, and diving for rings (see Table R3).

Research findings were presented by D.E. Thorpe et al. of the University of North Carolina at Chapel Hill on the effects of aquatic resistive exercises

on a variety of factors in persons with CP at the American Physical Therapy Association's annual conference held in Texas in 2001.³⁴ Strength, balance, energy expenditure, functional mobility, and perceived competence of individuals were measured using standardized testing performed before, after, and 1 week after an aquatic progressive resistive exercise program. The nine subjects between 7 and 31 years of age with spastic diplegic CP performed stretching, resistive exercises with equipment, swimming skills, and lower extremity strengthening three times per week for 10 weeks. The study results demonstrated that the subjects had a significant increase in strength of their knee and hip extensors with retained hip extension, but not knee extension, at 1 week posttherapy. Gait velocity significantly improved immediately and at 1 week posttherapy CP. An example of a typical patient who can benefit from aquatic therapy is Heather who is status postmultiple orthopaedic procedures performed to correct severe progression of her bilateral foot deformities. The surgical procedures included bilateral tibial osteotomies, lateral column lengthenings, first metatarsal osteotomies and gastrocnemius recessions. Heather wore bilateral short-leg casts for 8 weeks. Her primary mode of locomotion was a power wheelchair. Physical therapy three times per week was initiated 5 days after surgery with focus on transfer training, increasing range of motion, strengthening, and ambulation training.

Clinical findings after land therapy and before pool therapy included that Heather was nonambulatory, transferred from a wheelchair to a mat with the maximum assistance of one, and her standing tolerance with a walker and contact guard was for 30 seconds. Her short-leg casts were removed 8 weeks after surgery. Aquatic therapy was initiated 2 days later with focus on walking in chest-deep water with the assistance of one for 30 feet. Strengthening exercises included wall squats, marching, biking, supine recover, and abdominal exercises. During land therapy 5 days after the start of aquatic therapy, Heather reported improved ease in weight bearing with two-person assistance. She was able to ambulate in parallel bars while wearing bilateral knee immobilizers for 6 feet times two with the moderate assistance of two. Heather continued land therapy one time per week and aquatic therapy two times per week for an additional 20 weeks. Presently she is able to ambulate 80 feet with a Kaye walker with minimal assistance. She is also able to take three to four backward steps. This is a skill she was never able to perform. In the pool she is able to walk backward 30 feet with minimal assistance. She currently transfers independently using a sliding transfer technique.

Table R4. Aquatic therapy: contraindications and precautions.

Contraindications	Precautions
Open wounds	Seizure disorder: controlled with medication
Communicable rashes (pseudomonas, streptococcus)	Respiratory compromise: vital capacity of 1.5 liters or less
Infections (respiratory, urinary, ear, blood)	Osteotomies, ileostomies, urostomies, "G" and "J" tubes, suprapubic appliances
Fever	External fixator
Uncontrolled seizure activity	Behavior problems (children, head injuries, uncontrolled fear)
Tracheotomies	Hypersensitivity
Cardiac failure	Autonomic dysreflexia
Active joint disease (rheumatoid arthritis, hemophilia)	Uncontrolled high or low blood pressure
Menstruation without internal protection	

Table R5. Recommended swimming strokes based on neurodevelopmental approach.

Severe Quadriplegia (spastic, athetoid, mixed)
Finning
Sculling
Child attempts these strokes while being pulled through water. Instructor may stand behind child's head and resist backward propulsion to aid in co-contraction.
Moderate Spastic Quadriplegia and Diplegia
Finning/sculling
Elementary backstroke
Breaststroke
Moderate Athetosis
Finning/sculling
Elementary backstroke
Hemiplegia
Finning/sculling
Child should be encouraged to use only the involved arm initially.
Sidestroke
Involved side should be on top of the water. Child may use inverted scissors kick. (Note that flutter kicks can increase extensor tone, which can result in scissoring gait in the ambulatory child.)

There are a number of contra-indications for aquatic therapy which basically include either issues which may place the child in a dangerous situation in the water such as frequent seizure activity, or issues in which the child may contaminate the water for other swimmers such as having large open infected wounds. There are also a number of situations, which call for extra precautions by the therapist to avoid injury to the patient or the therapist, such as children with severe unpredictable behavior problems.

Each of the different patterns of neurologic involvement require a specific consideration of the swimming strokes the therapist should focus on teaching the child. As an example, the child with hemiplegia and little use of one arm will have little success with a crawling stroke. However, focusing on using the involved arm is an excellent therapy modality and is often stressed during therapeutic sessions. For most of these children the side-stroke will be much more effective as a recreational swimming pattern.

Other Aquatic Treatment Approaches

There are several therapy methods that can be integrated into one practice as the need arises. Watsu, the water-based version of Shiatsu, was developed by a shiatsu master from northern California. The provider always performs Watsu in a hands-on manner. The patient is usually held or cradled in warm water while the provider stabilizes or moves one segment of the body, resulting in a stretch of another segment due to the drag affect. The client remains passive while the provider combines the unique qualities of the water with rhythmic flow. This combination of meridian therapy and massage can calm and relax the patient who is overly excited or experiencing pain.

The Halliwick Method was developed by James McMillan while teaching swimming to handicapped children and is based upon hydrodynamics and body mechanics. It teaches cognitive skills, breath control, and understanding of body movements in the water. The Halliwick Method combines the unique qualities of the water with rotational control patterns.

The Bad Ragaz Ring Method is a form of active or passive aquatic therapy molded after the principles and movement patterns of Knupfer exercises

and proprioceptive neuromuscular facilitation (PNF). The patient is verbally, visually, and/or tactilely instructed in a series of movement or relaxation patterns while positioned horizontally and supported by optional floats around the head, neck, hip, wrists, and ankles. The patterns may be performed passively for relaxation/flexibility or actively with assistance or resistance for strengthening.

Berta and Karl Bobath originated the Neurodevelopmental Treatment Approach to treat individuals with pathophysiology of the central nervous system, specifically children with CP and adults with hemiplegia. Treatment involves active participation of the patients and direct handling to optimize function with gradual withdrawal of direct input by the therapist

Pool Design/Accessibility

Ideal pool design requires consideration of multiple factors to accommodate for various disabilities and therapies (Table R6). It is especially important for the pool facility to be accessible to wheelchairs (Figure R3). It is also important to have an accessible changing area, which is not usually available for adult-sized individuals unless there are special adaptations (Figure R4).

Multidisciplinary Approach

Every team member plays a part in addressing patient's needs. Oral hygiene, toilet hygiene, dressing/undressing skills, and showering before or after pool sessions can be incorporated in an aquatics program provided by occupational therapists. Speech therapists can take advantage of water resistance to promote increased voice projection and verbalization while physical therapists are working on functional mobility.

In conclusion, aquatic therapy is an entertaining and efficient way to enhance the quality of life for children with CP. Children are naturally drawn to the aquatic environment, enabling the practitioner to use this pleasant

Table R6. Pool design/accessibility.

Decks
Skid-resistant flooring in the pool area and locker rooms
Depth of water
Zero depth entries to 3 feet is ideal for toddlers and infants. Depending on pool size and therapeutic program, the water depth should meet the needs of the treatment plan. Four and one-half feet of water works well with school age children. Ten feet of water is needed if diving is part of the program.
Air and water temperature
Water temperature for a therapeutic pool should be between 92° and 96°F. Recreation pool water should be between 86° and 88°F. The air temperature should be within 5° of the water to prevent condensation. Too high or low temperatures can affect both the equipment and the participants. Maintaining the ideal water temperature plays an important role in balancing water chemistry.
Pool entries and exits
Zero entry ramps, steps with railing(s), ladders, and hydraulic lifts can benefit patients with different functional levels.
Locker rooms/showers
Wheelchair-accessible locker rooms with mat tables
Safety equipment
All safety equipment required by the state and providing facility to prevent accidents and to meet any medical emergencies
Staffing
Pool lifeguard on duty at all times when program in operation
Qualified licensed therapist to perform aquatic sessions




Figure R3. As children grow to adult size, the ability to get a child into and out of the pool for hydrotherapy is an important element of the facility. The wheelchair ramp as is shown here is a very safe, simple, and efficient mechanism to make the pool accessible.



Figure R4. One problem in doing hydrotherapy for large individuals who are totally dependent for dressing and movement is finding changing rooms or tables. Low-cost solutions can easily be developed using construction and plumbing supplies. A volunteer for the school constructed this changing table.

Table R7. Community resources.

American Red Cross
17th and D Streets, NW
Washington, DC 20006
<http://www.redcross.org>

National Recreation and Park Association
3101 Park Center Drive
Alexandria, VA 22302
<http://www.nrpa.org>

Boys and Girls Club of America
National Headquarters
1230 W. Peachtree Street, NW
Atlanta, GA 30309
<http://www.bgca.org>

Table R8. Recommended reading.

Campion MR. *Hydrotherapy in Pediatrics*, 2nd Ed. Oxford: Butterworth-Heinemann, 1991.

Harris SR, Thompson M. Water as learning environment for facilitating gross motor skills in deaf-blind children. *Phys Occup Ther Pediatr* 1983;3:1:75–82.

Langendorfer S, Bruya LD. *Aquatic Readiness: Developing Water Competence in Young Children*. Champion, IL: Human Kinetics. 1995.

Routi RG, Morris DM, Cole AJ. *Aquatic rehabilitation*. Philadelphia: Lippincott-Raven, 1997.

Martin K. Therapeutic pool activities for young children in a community facility. *Phys Occup Ther Pediatr* 1983;3:1:59–74.

atmosphere to carry out therapeutic goals along with building confidence and having fun. Aquatic therapy is a great adjunct to traditional land-based therapy, improving such goals as range of motion, coordination, functional mobility, and a lifelong opportunity for fitness. There are many methods to use water for therapy and recreation with many different people developing recommendations and reporting what works and does not work (Tables R7 and R8).

7. Assistive Devices

Mary Bolton, PT

Most children with CP will need assistive devices for standing and walking during their lifetime. There are many assistive device styles, accessories, and options in the durable medical equipment market. Choosing the walker that offers the appropriate support but allows the greatest degree of mobility is of utmost importance. Therefore, it is crucial to have several of these devices available for trial when evaluating a child for the use of assistive equipment.

When a child is being assessed for a walker, the initial evaluation is very extensive. The key factor is the child's ability to weight bear on her lower extremities. When evaluating younger children, hold them upright with their feet in contact with the ground and note their ability to support themselves. Noting the ability to take weight with transfers is key when evaluating older children. Information from the parents, therapists, teachers, and other caregivers will increase your understanding of the child's needs and potential. The ability to dissociate the lower extremities from each other is essential for walking, but is difficult for children with extensor tone. Stepping reactions should occur with the drive to stand and move. A thorough evaluation of the child's range of motion is needed. Contractures of the lower extremity will have a significant effect on the child's ability to stand upright. Evaluate the ability and strength used to hold the body upright with her arms. The arms may function in a variety of positions for weight bearing, such as extended elbows, or flexed with the arms supported on platforms.

The child's functional mobility should also be assessed. Their usage of floor or upright movement enables the therapist to view weightbearing control, weight-shifting ability, cognitive motivation, and problem-solving skills. Observation of transfers from sit to stand, stand to pivot, and floor to stand is of value. The child's use of a wheelchair, the style and maneuvering skills, provides further information about vision, strength, endurance, and cognitive and environmental awareness. Any durable medical equipment that is used to help the child's positioning or ability to stand upright should also be used and evaluated.

With their knowledge of the child's equipment use at home and school, the parents are often able to provide additional background information for the assistive device evaluation. A history of the type of equipment the child has tried and how well she performed with it is helpful. You also will need to know what equipment is currently in use. Parents may have ideas about their child's current needs and desires. In addition, determine if any surgeries or medical interventions (bracing, Botox injections, etc.) are proposed in the future, which may influence the recommendations for walking aids.

Many times the school or home therapists involved with the child's care have important information regarding the assessment of the child's walking needs, but they are limited by equipment availability and options. Access to the Internet often increases information about equipment, although it may not always be available to try with the child. Working with local durable medical equipment vendors and/or contacting the equipment manufacturers directly is always an option.

Standers are helpful for children who need significant postural support, lack ability or understanding of how to support themselves on their arms, and have limited cognitive understanding (by developmental age or actual limited cognitive development) of how to use a walking device. The first step is to determine if a supine, prone, or upright stander is most appropriate for the position desired. Children who need more extension strength including head control, arm weightbearing facilitation, and can actively engage in standing would benefit from a prone stander (Figure R5). Children with increased extension posturing or decreased postural control due to weakness or low tone generally benefit from initiating upright standing at a slower rate. A supine stander allows for a slower progression into the upright posture and ease with blood pressure and circulation problems. The upright stander has many varieties from full trunk support to lower lumbar control. They are often used with children who can move to standing with a stand



Figure R5. Prone standers such as this are very useful but require measuring to fit the individual child. It is also ideal to have the equipment at the evaluation site so the parent can see how big it is and see how the child responds to the device.

transfer and need to increase their overall standing tolerance, whether it is due to limited range of motion, strength, or overall endurance. This type of stander with additional bracing can be used for lower extremity weakness. All these different stander styles have a variety of options, accessories and special features. There are boundless possibilities limited only by the manufacturer's creativity.

When a child begins to show the ability to bear weight on her legs and attempts to weight shift as she steps, she is usually ready for a walking aid. These walking devices vary from maximum assistance control, as in a gait trainer, to walkers, canes, and crutches.

A gait trainer is usually most appropriate for a child with increased postural tone, limited pelvic and lower extremity dissociation, and the inability to weight shift with caregiver support. Such children have a desire to move and interact with their environment but are limited by their ability to do so independently. Gait trainers align the body's center of gravity over the feet, prevent trunk lateral flexion, and offer weightbearing support through a seat. The gait trainer helps to stabilize the trunk and pelvis so the legs can move independently for stepping. For the child that adducts her legs, stepping straps can assist in abducting the legs. Arm supports are optional. The child is able to propel the device by stepping. The trunk is aligned with trunk/hip guides, straps, or pads. Gait trainers are like ring walkers or baby walkers that offer more support, have variable sizes, and the capability for limited wheel direction. For safety of the older and more mature child, the gait trainer's base of support is much larger, but this is often found to be large and cumbersome in a home setting. Also, the large child needs to be lifted or moved into the trainer making it difficult for a single caretaker to manage safely. Although not functional for the older child, the trainer is ideal for the younger one who needs stabilization and is beginning to demonstrate ambulation skills.

A walker is usually beneficial when a child shows potential for weight bearing, is initiating stepping, but has limited weight shift, balance, muscle endurance, or coordination. There are a variety of walkers to use for assessment. Forward and posterior walkers are available and include many accessories and options. The most important determinant in choosing a walker is how the child actually functions with it. It is valuable, as with all equipment, to have a large selection of walker styles, sizes, and upper extremity support devices to try. Additional items such as wheels, brakes, seats, and pelvic guides can be added or interchanged later. Generally, watching the child's emotional reaction and movement ability will guide the therapist in narrowing down the style of walker that is most appropriate for that child. Some children need multiple sessions or extended periods to adjust to the equipment, especially if it is their first time using it. The younger child may be more accustomed to walking with their arms in a variety of positions including hands held high, leaning on furniture, or pushing walking toys. A child with this experience may accept the posterior walker easier than an older child who has become accustomed to using a front walker. The larger child also has an easier time with maneuvering the forward walker, because the base of support on the large-size posterior walkers becomes too cumbersome. A posterior walker is most suitable for a child who advances the supportive device too far forward or has excessive trunk flexion. A forward walker is appropriate for children who need less upper extremity support for postural alignment and have more fluent weight shift patterns. These walkers generally are lighter and more compact.

Children who need relatively little assistance for balance, fall occasionally, and have difficulty with longer community distances or unlevelled sur-

faces may benefit from the assistance of a cane or crutches. The child is usually 6 years or older, and reports using their walker less often, leans on furniture for assistance, or prefers to be mildly supported by another person. Canes and crutches come in a variety of styles and designs. Canes are beneficial for children who have occasional falls, and are gradually getting slower than their peers and entering their teenage years. The therapist will need an array of sizes, base options, and grip styles to determine the most appropriate equipment for the child's comfort level and need. Some individuals use canes for safety in larger school settings and community outings; however, forearm crutches are by far the most useful assistive devices for individuals with CP.

Determining the best assistive equipment should not be a rushed decision. It will impact on the child's continued development and ability to interact and move in her world. Sometimes more than one device is necessary, perhaps a walker for school distances and a cane for the smaller crowded home. Selecting the best equipment for the child should not be limited by evaluation time. Remember, the goal is walking with the best postural alignment, convenience for usage, efficiency, and walking speed. The parent and child should be satisfied and confident with the recommendation.

8. Seating Systems

*Denise Peischl, BSE, Liz Koczur, MPT,
and Carrie Strine, OTR/L*

No other area of technology for children with CP has shown any greater growth than that in mobility systems and seating components. There is no facility where you will not find consensus among the caregivers that an appropriate prescription for a seating device needs to include the family, the treating therapist, the physician, the equipment vendor, and, for the complex cases, a rehabilitation engineer. Guidelines for seating systems are outlined in Tables R9 through R17. Because wheelchairs are always large devices

Table R9. Seating systems.

<p>Laterals (trunk supports mounted on the backrest)</p> <ul style="list-style-type: none"> (+) Support patient in an upright posture (+) Lateral support for safety in transport (+) Proximal stability to enhance distal mobility (-) Decreases amount of lateral mobility patient has <p>Curved laterals</p> <ul style="list-style-type: none"> (+) Curve around patient's trunk to help decrease forward flexion of the trunk (-) May make transfers difficult (-) Requires swing-away hardware for transfers <p>Straight laterals</p> <ul style="list-style-type: none"> (+) Easier for patient to move in and out (+) Easier for transfers (-) Does not block forward flexion of the trunk <p>Summer/Winter Bracket Hardware (Slide adjustment on back of chair allows caregiver to move lateral in and out for heavier clothing); user is unable to access</p> <ul style="list-style-type: none"> (+) Easy to use: no tools required (+) Allows width adjustability for changes in season (i.e., winter coat) (+) Allows for growth adjustability without tools (-) Extra parts to chair that could be removed and lost <p>Swing-away hardware (Push lever on side of lateral, allows it to open at an angle)</p> <ul style="list-style-type: none"> (+) Moves lateral out of the way for ease of transfers (-) Additional hinge; creates a weak spot for potential break (-) Not considered heavy duty for aggressive support
--

Table R10. Seating systems.

Hip guides (Pads usually mounted to frame of chair or underneath cushion cover to keep hips in alignment. Hip guides mounted to chair can come in any length, usually full, three-quarter length, or just around the pelvis.)

- (+) Keep hips centered in middle of chair
- (+) Able to maintain hip position with accommodating for growth
- (+) Narrows in width for midline alignment
- (-) Adds to overall weight of chair
- (-) Cumbersome when folding chair
- (-) Makes transfers difficult

Table R11. Seating systems.

Knee adductors (Pads usually mounted to footrest hangers that assist in keeping knees from frog-leg position. Point of contact is on lateral femoral epicondyle.)

- (+) Assists to maintain neutral alignment of lower extremities
- (-) May come out of alignment due to moving parts (multiaxis joints)
- (-) Makes transfers difficult
- (-) Cumbersome

Knee block (Positioned in front of the knee to prevent sliding out of wheelchair in conjunction with seatbelt)

- (+) Prevents sliding out
- (-) Cannot be used when knee or hip integrity is in question
- (-) Difficult for transfers

Abductor (Also called a pommel – used to abduct knees)

- (+) Decreases adduction, maintaining good lower extremity alignment
- (+) Can flip down to get out of the way for transfers
- (-) If positioned incorrectly can cause groin problems
- (-) Cumbersome
- (-) Difficult for independent function

Table R12. Seating systems.

Shoulder retractor pads (Aggressive positioning option to retract the shoulders. Mounted off backrest padded brackets to hold shoulders against backrest.)

- (+) Retract shoulders
- (-) Difficult to position
- (-) Cumbersome
- (-) Adds weight to wheelchair
- (-) Not intended for a user who uses trunk flexion/extension for functional reach

Sub-ASIS bar (aggressive positioning option to immobilize the pelvis)

- (+) Controls pelvic thrusting usually caused by high tone
- (+) Maintains constant position of individual while seated in wheelchair
- (+) Controls pelvic rotation
- (-) Could cause skin breakdown in ASIS joint if incorrectly set
- (-) Difficult to assess tolerance of patient who is cognitively impaired
- (-) Cannot be easily adjusted

Trunk positioners

Chest harness (Nylon or Neoprene vest-like apparatus)

- (+) Assists to keep client's trunk upright
- (+) Used for safety in transport (along with conventional lock downs)
- (-) Does not have a good line of pull to promote shoulder retraction

Chest strap (Velcro strap with or without D-ring positioned across trunk)

- (+) Assists client to keep from flexing trunk forward
- (+) Safety in transport
- (+) Easy to put on/off
- (-) Not an aggressive trunk positioner

Shoulder straps (Neoprene or nylon padded straps with line of pull on trunk proximal to the shoulder complex)

- (+) Aggressive positioner to promote shoulder retraction
- (+) Improves clients trunk stability
- (+) Safety in transport
- (-) Needs to be snug to work correctly
- (-) Does not allow client much freedom of trunk movement

Hemi-harness (Upside-down Y-shaped shoulder harness)

- (+) Aggressive positioner to promote unilateral shoulder retraction
- (+) Allows client to use unaffected limb and trunk for functional reach
- (-) Gives stability to only one side
- (-) Client may be able to move out of it

Table R13. Seating systems.

Pelvic Positioners
<p>Pushbutton seatbelt</p> <ul style="list-style-type: none"> (+) Simple, easy to operate (+) Some manufacturers produce varieties that require less pressure to undo (+) Durable (-) Sometimes too hard for users without fine motor control
<p>Airplane seatbelt (Flip-up seatbelt)</p> <ul style="list-style-type: none"> (+) Simple, easy to operate (+) Easy to undo with gross hand movement (+) Durable (-) Big metal buckle can be cumbersome
<p>Fastex buckle seatbelt</p> <ul style="list-style-type: none"> (+) Difficult to unlatch, user attempt to remove may create safety issue (-) Not durable
<p>Padded seatbelt</p> <ul style="list-style-type: none"> (+) Comfort (+) Allows user/caregiver to make snug without “cutting into” user
<p>Single-pull padded seatbelt (One D-ring on seatbelt makes for a better line of pull for user/caregiver to make snug.)</p> <ul style="list-style-type: none"> (+) Easy to get snug fit (+) Assists to reduce tone (+) Durable (-) Bulky
<p>Double-pull padded seatbelt (Two D-rings on seatbelt allows user/caregiver to pull equally on both sides of pelvis to make snug.)</p> <ul style="list-style-type: none"> (+) Easy to get a snug fit (+) Easily adjustable (+) Good for extensor tone reduction (+) Assists with decreasing pelvic rotation (-) Bulky
<p>Reverse seatbelt (Seatbelt attaches behind user so they are unable to remove themselves.)</p> <ul style="list-style-type: none"> (+) Safety (-) Difficult for caregivers to reach (-) Not good for tone reduction or pelvic positioning
<p>Seatbelt rigidizer (Hard plastic cover over one or both sides of seatbelt)</p> <ul style="list-style-type: none"> (+) Puts seatbelt in a good position for user to easily retrieve and buckle (-) May get in the way for transfers
<p>Pelvis Positioning Strap (Y-type strap coming up between legs for abduction)</p> <ul style="list-style-type: none"> (+) Alternative pelvic positioning to hip belt or sub-ASIS bar (+) May work well with children under 2 years of age (-) Not effective in reducing tone (-) Does not control pelvic rotation (-) Requires constant skin monitoring for irritation and abrasion

compared with the child’s size, when determining the functional use of the device one must very carefully consider the patient, the family environment and family goals, and the community environment where the device will be used (Figure R6). Many of the specific indications and contraindications are not well defined or widely agreed upon in the rehabilitation community. As with all interventions, there are pluses and minuses and these are included for consideration (see Tables R9–R17).

After the team evaluation and all the specific components for the wheelchair are agreed upon, excellent documentation qualifying the need for each component must be generated. This thorough documentation can then be formulated into prescription form and a detailed letter of medical necessity to qualify the medical need for the wheelchair. Failure to provide the documentation of medical necessity often leads to the denial of key components of the seating system. An example letter of medical necessity is as follows:

Table R14. Seating systems.

Backrests
<p>Flat backrest</p> <ul style="list-style-type: none"> (+) Solid support for pelvis and spine (+) Easy to mount hardware to it (+) Compliments other positioning devices (i.e., laterals, headrest, etc.) (+) Allows use of growth-oriented hardware (-) No accommodation for spinal deformity (-) Adds weight to wheelchair (-) Prevent folding of wheelchair unless removed
<p>I backrest (Flat back made in the shape of the capital letter I)</p> <ul style="list-style-type: none"> (+) Allow laterals to be moved in close to trunk without significant offset hardware (+, -) All positive and negative components of a flat backrest (-) Need to measure correctly for adequate support (-) If moving back between posts, posts may interfere with lateral maneuverability
<p>Curved backrest (Slightly concave, made of wood and foam)</p> <ul style="list-style-type: none"> (+) Minimal contour for lateral stability (-) More difficult to mount lateral hardware than to a flat backrest
<p>Premolded contoured backrest (Commercially available contoured back, i.e., Jay)</p> <ul style="list-style-type: none"> (+) May come with pressure relief areas along spine (+) Minimal contour for lateral stability (-) Sometimes difficult to fit for pediatric population
<p>Custom-molded contoured backrest (Practitioner uses foam to mold backrest for individual patients. Foam in place can be completed at appointment, however, some molds must be sent to manufacturer to be completed.)</p> <ul style="list-style-type: none"> (+) Accommodation for spinal deformity (+) Individual for user (+) Foam in place may be changed easily (-) User may have to wait for custom mold (-) Requires knowledgeable practitioner to measure for or produce an accurate mold of the child's spine
<p>Bi-angular backrest (Flat backrest with hinge in lumbar area to give patient increased spinal extension)</p> <ul style="list-style-type: none"> (+) Assists with upright positioning (-) Difficult to get correct specifications (-) Not adjustable
<p>Sling backrest (Nylon padded backrest)</p> <ul style="list-style-type: none"> (+) Easy to fold (-) Promotes kyphotic posture (-) No adjustability
<p>Adjustable tension backrest (Six to eight hook-and-loop straps positioned horizontally on sling back)</p> <ul style="list-style-type: none"> (+) Maintains constant tension on backrest (+) Promotes upright posture (+) Easy to fold chair (+) Allows minimal concavity for minimal lateral stability (-) Unable to mount any hardware on it for laterals or headrest (-) Maintains minimal amount of sling

Date

To Whom It May Concern:

Kevin Jones is an 11-year-old male with a primary diagnosis of quadriplegic CP. Kevin was seen in the Seating Clinic at the duPont Hospital for Children on August 15, 2003 for evaluation and prescription of a new seating system, which is necessary to meet his seating and mobility needs.

Kevin presents with the following: he is on a bowel and bladder program; his hearing and vision are within normal limits; he has increased tone in his upper extremities, and increased tone in his lower extremities; his head control is fair; his trunk control is poor; his spine is flexible. Kevin has knee flexion

Table R15. Seating systems.

Foot Positioners

- Calf strap (Hook-and-loop strap positioned in front or behind calf)
 (+) Minimal positioning for knee flexion/extension
 (+) Easily removable
 (-) Not an aggressive positioner
 (-) Usually used with another type of foot positioner
- Heel loop (Strap mounted to posterior part of footplate)
 (+) Assists in keeping foot from sliding posteriorly off footplate
 (-) Not an aggressive positioner
 (-) Sometimes in the way to flip up footplate
- Ankle strap (Hook-and-loop or D-ring strap mounted to footplate, positioned across ankle)
 (+) Assists in keeping foot on footplate
 (-) Not aggressive, many users are able to pull feet out
- Toe loop (Hook-and-loop or D-ring strap mounted on footplate, positioned across metatarsals)
 (+) Assists to keep foot on footplate
 (+) Used in conjunction with ankle strap can help to prevent forefoot rotation
 (-) Bulky
- Ankle hugger (Neoprene strap mounted to footplate, encompasses entire circumference of ankle)
 (+) Padded, comfortable
 (+) Allows minimal movement
 (+) Difficult for user to pull out of it
 (-) Bulky
 (-) Does not control forefoot movement
- Shoe holder (Heavy-duty plastic piece that shoe sits in and is strapped into)
 (+) Aggressive positioning
 (+) Difficult for user to pull out of it
 (+) Controls forefoot and rear foot motion
 (-) Bulky
 (-) Must get correct size

Table R16. Seating systems.

Cushions

- Flat cushion (Minimal cushioning on a firm surface)
 (+) Supports client's pelvis and limbs
 (+) Easy to transfer into and out of
 (+) Inexpensive
 (+) Requires minimal maintenance
 (-) No positioning for orthopaedic deformities
- Pre-molded contour foam cushion
 (+) Gives minimal – moderate contour to accommodate for orthopaedic deformities
 (+) Supports patient's pelvis and limbs
 (+) Requires minimal maintenance
 (-) Increased contour may make it difficult to transfer into and out of
- Gel cushion (Cushions using foam and a pressure-relieving fluid)
 (+) Pressure relieving gel positioned under bony prominences
 (+) May come with different contours to accommodate for orthopaedic deformities
 (+) Firm – good for pelvic stability
 (-) Requires caregiver/patient maintenance
 (-) Increased contour may make it difficult for patient to move into and out of
- Air cushion (Pressure-relieving cushions using air regulation to maintain cushion firmness)
 (+) Great for pressure relief under bony prominences
 (-) High level of patient/caregiver maintenance
 (-) Minimal pelvic stability
 (-) Difficult for patient to transfer on/off of
- Incontinent cover (One type of removable cover, prevents urine from soaking cushion)
 (+) Maintains integrity of cushion
 (-) Positions urine under patient

Table R17. Seating systems.

Trays

Full lap tray

- (+) Supports individual's upper body
- (+) Good for cognitive stimulation and feeding issues
- (-) Needs to be removed for transport

Clear tray

- (+) Allows client to see lower half of body
- (+) Pictures can be placed under the tray
- (-) More expensive than wood

Wood tray

- (+) Durable
- (+) Supports individual's upper body
- (-) Individual unable to see through

Half-lap tray (Fits on one armrest; used for patients with hemiplegia)

- (+) Supports affected side of patient
- (+) Allows patient to freely use unaffected side to propel wheelchair
- (+) Firm surface for work, etc.
- (+) Patient can independently remove
- (-) Difficult for patient to independently put on
- (-) Sometimes desk space is too small for patient to work effectively

Easel tray

- (+) Supports book/objects in a better line of vision for patient
- (-) Takes up a lot of space on tray
- (-) Not for a patient with aggressive behavior
- (-) Cumbersome

Figure R6. The process of making an assessment and writing the prescription for a wheelchair requires evaluating many elements. This is ideally done in a multidisciplinary team with therapist, rehabilitation engineer, parent, and physician. This process is especially true for very sophisticated power chairs with multiple features, which may cost as much as \$30,000.



contractures; he is independent in power wheelchair mobility; he is dependent for transfers; he is verbal in communication; and cognitively he is age appropriate.

His current wheelchair is a Quickie P200 power wheelchair, which is three years old. Due to growth and weight gain, this system no longer accommodates Kevin's seating and mobility needs. His P200 is a 17-inch wheelchair and currently Kevin's hip measurement is 19 inches. It is evident that this wheelchair no longer accommodates his needs.

The seating goals for Kevin are to increase mobility, increase efficiency, enhance function, maintain posture, increase independence, protect skin, provide comfort, and provide safety.

Upon evaluation, the seating team recommends the following be prescribed for Kevin: Action Arrow wheelchair with 4-pole motors and weight-shifting power tilt-in-space; 14-inch wheels with flat free fillers and rubber knobby tires; Q-tronics electronics – joystick with 1/8 inch jacks; swing-away mount on right side; 24 NF gel batteries; low seat-to-floor height; 70 degree hangers with angle-adjustable footplates; height-adjustable desk length on right and full length on left; clear tray with top drop hardware and tray support extension and joystick cutout; Cloud cushion; AEL flat swing-away laterals 5×6; solid curved I-back; small curved OttoBock headrest with hardware; TRCM with mounting bracket; TASH C5 adapter; TASH microlite switch; color: black with twilight.

Specific components and indications:

Basic Motorized Wheelchair	<ul style="list-style-type: none"> • Unable to ambulate or propel a manual wheelchair • Has functional use of one UE
Motorized W/C with adjustable electronics	<ul style="list-style-type: none"> • Low/decreasing endurance • Special switch configuration necessary due to upper extremity weakness • Increased sensitivity adjustability to decrease spasms of client and/or allow use of ECU with w/c
TRCM w/TASH switch	<ul style="list-style-type: none"> • Capability to adjust speed, excel; to allow better control and safety in use • Alternate switch for tilting due to limited strength, especially when in tilt and working against gravity • Maintains constant access to tilt regardless of degree of tilt
High strength	<ul style="list-style-type: none"> • Strong base of support for tilt
Power tilt	<ul style="list-style-type: none"> • Outdoor terrain • Independent weight shift for position change • Pressure relief • Reduce/eliminate shear • Reduce spasms • Personal hygiene
Adjustable height arm	<ul style="list-style-type: none"> • Support to tray at right height • Upper body support and balance • Ease of transfer
Angle-adjustable footplates	<ul style="list-style-type: none"> • Ankle contractures • Ankle braces • Reduce extensor thrust in LEs • Knee contractures – prevent feet from resting on standard footplate
Solid seat	<ul style="list-style-type: none"> • Pelvic stability • Avoid sling effect, adduction of knees

Cloud cushion	<ul style="list-style-type: none"> • Pressure relief for bony prominences
Jay back	<ul style="list-style-type: none"> • Contour for pelvic stability • Pressure relief along spine • Min/mod lateral and lumbar support and contour
Solid back	<ul style="list-style-type: none"> • Built-in capability for growth • Upright posture • Prevent/minimize kyphosis • Trunk stability
Laterals	<ul style="list-style-type: none"> • Encourage midline trunk position and correct/delay scoliosis • Compensate for lack of trunk control • Safety
Headrest	<ul style="list-style-type: none"> • Assist with transfer, locks for strength • Poor head control due to low tone • Active flexion/hyperextension of head • Posterior and/or lateral support • ATNR • Safety in transport
Tray (clear)	<ul style="list-style-type: none"> • Facilitate breathing • Upper arm and trunk support • Functional surface for schoolwork • Inability to access desks, tables, etc. • Base for augmentative communication device, computer
Seat belt	<ul style="list-style-type: none"> • Pelvic positioning – prevent sliding out • Safety
Anti-tippers	<ul style="list-style-type: none"> • Safety
Large casters	<ul style="list-style-type: none"> • Rugged terrain, smoother ride
Flat-free fillers	<ul style="list-style-type: none"> • Prevent flat tires • Reduce maintenance

Should you have any questions regarding these recommendations for Kevin, do not hesitate to call us at (302) 999-9999. We hope that you will be able to accommodate these needs in an expedient manner. Thank you for your cooperation and assistance in this matter.

Sincerely,

Freeman Miller, MD

9. M.O.V.E.TM (Mobility Opportunities Via Education) Curriculum

Kristin Capone, PT, MEd, Diana Hoopes, PT, Deborah Kiser, MS, PT, and Beth Rolph, MPT

The M.O.V.E.TM Curriculum is an activity-based curriculum designed to teach individuals basic functional motor skills needed for adult life. These skills allow them to enjoy a more inclusive lifestyle because movement is an integral part of everyday life. People with physical disabilities often require assistance to participate in these everyday activities, such as moving to the bed or bathroom, to school, or to their place of work. The MOVE curriculum provides a framework for teaching the skills necessary for individuals with disabilities to gain greater physical independence. It combines functional body movements with an instructional process designed to help people acquire increasing amounts of independence in sitting, standing, and walking.

Linda Bidabe, founder and author of the MOVE curriculum, realized the need for a functional mobility curriculum when she observed that 21-year-old students were graduating from her school with fewer skills than they had when they entered school. She believed that the “developmental model” was not meeting the needs of students with severe disabilities because these students learned skills at a very slow rate and would take years to develop some of the early developmental skills such as rolling or prone propping on elbows. Therefore, the students would never accomplish functional mobility skills in sitting, standing, and walking.³⁵

This program is for any child or adult who is not independently sitting, standing, or walking. This includes those with both significant motor disabilities and mental retardation. Whether in a special school or a regular classroom setting, MOVE provides the student increased opportunities to participate in life activities with their peers without disabilities. Progress in the program can help reduce the time needed for custodial care, increase the child’s self esteem, and promote acceptance by peers.

Contraindications to consider before starting the MOVE curriculum include circulatory disease, respiratory distress, brittle bones, muscle contractures, curvature of the spine, hip dislocation, foot and ankle abnormalities, pain or discomfort, or a head that is too large to be supported by the neck. Medical or physical therapy consultation is recommended for any student with possible contraindications to obtain clearance for the exercise and weight-bearing activities. Exclusion from the program is limited to those individuals whose medical needs contraindicate the need to sit, stand, or walk.

The MOVE program is based upon the teaming of special education instruction with therapeutic methods and includes ecologic inventory, prioritization of goals, chronologically age-appropriate skills, task analysis, prompts for partial participation, prompt reduction, and the four different stages of learning: acquisition, fluency, maintenance, and generalization. It is divided into six steps. In step one, the student participates in the Top-Down Motor Milestone(TM) Test that evaluates his or her ability in 16 basic motor skills that are necessary for functioning in the home and community. The motor skills are age appropriate and based on a top-down model of needs rather than the traditional developmental programs based on sequential motor skills acquisition of infants.

Following the test, the student, parents, and/or caregivers are briefly interviewed in step two, to determine activities important to the family at the present time and in the future. An activity is defined as a specific event such as, “I want to be able to walk across the stage to get my diploma.” Step three analyzes the activities to determine the motor skills (from the Top-Down Motor Milestone™ Test) necessary to perform the activity, for example, walking forward or maintaining standing.

In step four, the amount of assistance needed by the student to perform the selected activities at the time of testing is recorded on the Prompt Reduction Plan Sheets provided in the assessment booklet. A plan is then formulated in step five to systematically reduce assistance over the instructional period. In the final step, step six, the skills are taught using the teaching sections of the curriculum to provide suggestions based on individual student needs.

To teach certain skills the MOVE curriculum utilizes equipment such as regular classroom chairs, adapted chairs, mobile standers, and gait trainers that are designed to support the student while they are practicing a skill (Figures R7 and R8). The equipment is not a substitute for teaching but rather a support to make instruction possible. Dependence upon equipment is continually reduced until the individual achieves as much independence as possible.

Figure R7. The development of gait trainers with a high degree of modularity has been driven in part by the philosophy of the MOVE program to have children up weight bearing and moving in the device, which gives the amount of support the child needs. The goal is then to gradually reduce the amount of support as the child develops strength and motor skills.



Figure R8. An important aspect of the MOVE program is the ability to get individuals into weightbearing positions, which is difficult for adult-sized adolescents. The development of mechanical lift walkers makes this process much easier for the caregivers.



MOVE is designed to embed mobility skill practice into functional everyday routines. As a result, MOVE can occur at school, in a facility, at home, or in the community, thus providing opportunities for multiple repetitions. MOVE is successfully implemented by therapists, educators, paraprofessionals, parents, and anyone who interacts with the individual.

The structured teaching approach used in the MOVE curriculum is validated in the article, *Mobility Opportunities Via Education (MOVE): Theoretical Foundations*, by Barnes and Whinnery,³⁶ which describes its use of natural environments, functional activities, scaffolding, partial participation, and use of contemporary motor theories related to teaching functional mobility skills.

The John G. Leach School, the nation's first MOVE model site, completed a pilot study in 1998 to evaluate the effectiveness of the MOVE curriculum. Eleven students (ages 4 to 18 years) with a variety of severe disabilities participated in the six steps of the MOVE program. After a 5-month period of instruction, improvements in sitting, standing, and walking were achieved. Improvements were also noted in the areas of communication, alertness, and overall health. Because of the success of the pilot program the MOVE curriculum was adopted for schoolwide use.

For example, a 5-year-old boy with a diagnosis of Cornelia–DeLang syndrome began the MOVE program at Leach School because he was nonweight bearing and intolerant of positions other than supine, as well as unable to communicate or play with his peers and siblings. Following daily practice in a mobile stander, he increased his tolerance for weight bearing. As support from the equipment was reduced, the student was able to practice standing as part of his classroom routines such as diaper changes and getting in and out of his classroom chair. Over a 3-year period he progressed from walking with full support in a gait trainer to walking with one hand held or pushing a forward rolling walker. This gain has led to increased social interaction and independent exploration of his environment.

10. Occupational Therapy Extremity Evaluation

Marilyn Marnie King, OTR/L

Individuals with CP may present with spasticity that causes dynamic or fixed contractures. Typical orthopaedic deformities include shoulder excessive external rotation, elbow flexion, pronation, ulnar deviation, wrist flexion, thumb adduction, tight finger flexion, and swan neck fingers. Surgery should improve these areas, but some children use their limits for function and may not do better. Examples are children who use augmentative communication aids and need a pronated arm or whose ability to point requires wrist flexion (tight tenodesis).

Brief Description of Surgeries to Treat the Upper Extremity

Surgeries to lengthen tendons or to transfer muscles to balance power and tone are frequently performed on the child with spastic CP, although never on children with dystonia, nor those with undulating fanning of fingers, nor those with rigid extension of the arm and flexion of the wrist. The Green transfer is the transfer of the flexor carpi ulnaris (FCU) to the extensor carpi radialis brevis (ECRB). There are variations that include tying flexors into the finger extensors and the palmaris longus (PL) into the extensor pollicis longus (EPL) thumb extensors. Prognosis is progressively improved with the following skills of the patient: good intelligence and motivation to follow through

with splinting and treatment exercises, good sensation and proprioception, patience versus poor attention span, realistic expectations, the ability to isolate wrist flexion from finger extension, and good volitional release.

Goals to achieve through surgery usually include two of the following, which are listed in order of certainty: improved cosmesis, meaning the wrist is placed in neutral, improved ability to keep the hand clean and odor free, improved ease of dressing, improved ability to see where the fingers are grasping, which further improves the potential for eye–hand coordination, and improved function of the hand, which is the least successfully achieved. A realistic order of achievement relative to improved function of the hand includes mass grasp, mass release, helper limb, tip pinch to index to middle fingers, lateral key pinch, grasp and turn object, cylindrical fist lacking 1 inch from palm, mass finger abduction/adduction, and finally, but rarely, individual isolated finger positions (such as sign language alphabet), finger magic tricks, shadow pictures with hands, rotating isospheres in palm, and fast activities such as spinning a top, snapping fingers, clapping, stirring, and shaking.

The surgeon's evaluation includes the effect the patient's body motions have on the increased wrist flexion, the patient's timing in throwing, and the posture of the arm with the use of the body during reaching, grasping, and running. If the child uses synkinesis or mirroring motions from the sounder side, the functional use will not be as good. Families' coping skills and unrealistic anticipated use of the extremity after surgery often present a dichotomy of expectation that the surgery will cure the functional deficit as compared to the more realistic prospect that the appearance of the arm will improve. The surgeon's recommendations to therapists are to keep splints small, compact, and simple (no outriggers) with focus on assisting function over cosmetic splinting. The dorsal wrist cock-up splint is recommended for functional protection. It provides extension support with the palmar arch preserved, as well as providing lateral borders to control the ulnar drift. By being on the dorsum, the splint does not rest against the trunk and is easier for the child to self-apply with the wrist strap being easier to handle. A night resting splint may be indicated if the fingers cannot extend (tight tenodesis) with the wrist, which following surgery is now in greater extension. The appropriate time for surgery is after the child is 6 years old; the ideal time is between 8 and 12 years old because of the child's greater understanding, cooperation, and ability to participate in the decision. There is a common range of problems of the upper extremity observed in children with CP for which a specific treatment is usually defined based on the identified deformity (Table R18).

Splinting

Usually following muscle transfer surgery the patient is casted for 4 to 6 weeks. Upon cast removal, the surgeon recommends that the patient wear a wrist cock-up splint at 20° to 30° extension for protection to prevent forceful wrist flexion (transfers) for 1 month with an hour or two off each day while sitting and bathing. After that period the child wears the splint at nighttime only. By 4 to 6 months the splint is worn only as protection as ambulation balance/roughness requires. The night resting splint is recommended for 6 months to a year, depending on severity of tone.

Upper extremity splinting for children who are not postoperative may pose some challenges. If a child is totally uncooperative and noncompliant about using splints, the family should not fight the child so as to lose sleep or create psychologic barriers. Generally, the following splinting is recommended for children with contractures caused by CP. The child between 1 and 4 years old who is not yet a candidate for surgery may benefit from a soft

Table R18. Typical problems and surgical intervention.**Shoulder**

P: Instability, dislocation

D: Joint laxity, athetosis

Tx: Decrease ROM to shoulder, increase strength around shoulder, tie/tether elbow to belt or wheelchair, avoid surgery if possible

Shoulder

P: Axilla hygiene, difficulty with dressing, getting through doors

D: External rotation of “high guard” or “flying bird” deformity

Tx: Release pectorals, tighten internal rotators or do a rotation osteotomy of humerus

Elbow

P: Dress, hygiene, cosmesis

D: Flexion contracture (surgery will weaken biceps strength)

Tx: Elbow extension splint, surgery to lengthen biceps, brachialis, elbow extension splint at night, AROM

Forearm

P: Palm out of sight, unable to see object pinched

D: Pronated arm

Tx: Reroute pronator teres to supinate, cast to above elbow to hold supination

Wrist

P: Poor appearance of flexed wrist, difficulty dressing or being dressed, unable to see what is in pinch, unable to easily touch thumb to index tip

D: Wrist flexed, ulnar deviated, forearm pronated, fingers flexed

Tx: If AROM of finger extension occurs with wrist flexion, then Green transfer (flexi carpi ulnaris to extensor carpi radialis brevis). If AROM is only wrist extension, then flexi carpi ulnaris may be transferred to finger extensors. If there is ulnar drift, plicate extensor carpi radialis longus. Lengthen flexor digitorum sublimis if strength is less than “poor” or 2/5. A wrist cock-up splint (in 20° extension) is needed for 3 months to prevent overstretch of flexor carpi ulnaris if wrist is flexed accidentally. A wrist/resting hand splint in progressive finger and wrist extension to increase the tenodesis excursion is needed if the child cannot open his fingers with the wrist in extension.

Fingers

P: Child cannot grasp, joints lock, swan neck deformity

D: Joint laxity, intrinsic – function

Tx: Tighten tenodesis with flexor digitorum sublimis

Thumb

P: Hygiene

D: Cortical position

Tx: “Rules of Thumb” – Lengthen a short muscle; shorten a long muscle; fuse an unstable thumb; augment a weak muscle (transferring from site of more power)

Thumb

P: Poor grasp, hygiene, cosmesis, web space contraction (House Type 1)

D: Contracted abductor pollicis, active interphalangeal joint extension and abduction of thumb

Tx: Abductor pollicis release (Matev) to increase web space

Thumb

P: Poor grasp, hygiene and cosmesis (House type 2)

D: Flexed metacarpal phalangeal of thumb but some variable function of IP flexion and extension

Tx: Shorten or augment EPL with PL/BR/FDS; augment abductor pollicis with BR/PL or lengthen adductor longus

Thumb

P: Poor grasp, hygiene, cosmesis (House type 3)

D: MCP extension contraction (hyperextension)

Tx: Adductor pollicis release, MCP fusion or plication; augment abductor pollicis longus with BR/FPL; lengthen extensor pollicis longus/EPB

P= Problem, D=Deformity, Tx= Treatment

Benik thumb abductor splint with wrist extension stabilized with integrated thermoplastic (molded by microwaving the splint to fit the thumb) during the day. At night, a dorsal resting splint is required if there is thumb abductor tightness and tight tenodesis. The splint should hold the thumb, fingers, and wrist in extension to stretch the tenodesis (no outriggers). If the resting position of the elbow is approximately 90° and passive range of motion (ROM)

of elbow extension is approximately -50° , a long resting splint that incorporates the elbow may be used at night, or an elbow extension splint may be used as well. Air splints may be used for elbow extension for 10 minutes during crawling, keyboard use, and arm-reaching play. Soft neoprene supinator “twister” splints may also be used during activity. These may be constructed with a Benik splint and a long neoprene strip spiraling up the forearm, or may be obtained readymade from an orthotics manufacturer. The child 4 to 9 years old should wear the same night splints as above, but not wear the splints as much during the day and only for function. Unfortunately, the adolescent splinting program is often futile due to dissatisfaction with cosmesis and lack of compliance.

Cerebral Palsy Functional Scoring Levels: Scoring Scales

There are many ways to classify the levels of function of the child with CP. Reasons for a classification system include being able to compare outcomes of similar children, noticing trends in abilities of these similar children to be able to help predict the type of care the child will need, and the effectiveness of hand surgery. Table R25 includes scoring scales that help quantify the use of the hand and upper extremity so that there can be a presurgery and post-surgery comparison with objectivity. Functional limitations are influenced by a variety of issues each child faces. There are many different assessment tools based on the goals of the measurement. Many of these are commercially available (see Table R25).

Green’s Scale is a quick progressive description of use of the upper extremity by the child with CP and reflects cognitive, sensory, reflexive, and orthopaedic limits in a concise list that families can understand. This scale permits the child, family, physician, therapist, etc. to rate the following function for both upper extremities and can be used before and after surgery. The expectation of improving one level after surgery is realistic. The Green’s Scale categorizes use of the upper extremities as poor, fair, good, and excellent. The term POOR is applied to describe the function of the upper extremity capable of lifting paper weight only, having poor or absent grasp and release, and poor control. FAIR is used to describe the upper extremity having a helping hand without effectual use in dressing, has fair control, and slow, not effective grasp/release. The term GOOD describes the upper extremity with a good helping hand, good grasp/release, and good control. EXCELLENT is used to explain the upper extremity having good use in dressing, eating, and general activities, effective grasp/release, and excellent control.

The A.I. duPont Hospital for Children’s (AIDHC) Clinic Scale was designed to classify the upper extremity functional ability of children with CP. This orthopaedist’s scale is used in a busy clinic and requires no equipment to administer. By assessing the child’s movement both actively and passively and with parent report on use of the limb, the examiner can use the data to assist in treatment planning. Level of function is categorized in a series of types from 0 through V (Table R19). Parents of children with CP are asked to assess the use their child makes of her hands by way of an upper extremity questionnaire (Table R20). A correlation is being studied between the parents’ assessments and the functional types as determined by the surgeons, as well as the outcomes after surgery. Generally, after surgical intervention functional type is increased by one level, thereby improving the collective functional activities of most children.

The Quality of Upper Extremity Skills Test (QUEST) is used to measure hand function by evaluating four domains: dissociated movement, grasp, protective extension, and weight bearing. It is designed for use with children

Table R19. Functional report: Upper extremity (UE) functional classification for CP (AIDHC).

_____ R	_____ L	Type 0 (No function, position interferes)
_____		No contractures
_____		With dynamic contractures
_____		With fixed contractures
_____ R	_____ L	Type I (Uses hand as paperweight or swipe only, poor or absent grasp and release, poor control)
_____		No contractures
_____		With dynamic contractures
_____		With fixed contractures
_____ R	_____ L	Type II (Mass grasp, poor active control)
_____		No contractures
_____		With dynamic contractures
_____		With fixed contractures
_____ R	_____ L	Type III (Can actively grasp/release slow and place object with some accuracy)
_____		No contractures
_____		With dynamic contractures
_____		With fixed contractures
_____ R	_____ L	Type IV (Shows some fine pinch such as holding pen, some key pinch with thumb)
_____		No contractures
_____		With dynamic contractures
_____		With Fixed contractures
_____ R	_____ L	Type V (Normal to near-normal function; fine opposition of thumb; can do buttons and tie shoes)
_____		No contractures
_____		With dynamic contractures
_____		With fixed contractures

who have neuromotor dysfunction with spasticity and has been validated for use in children from 18 months to 8 years of age and correlates strongly with the Peabody Developmental Fine Motor Scales. The House Scale describes the thumb position in progressive degrees of contracture.

The Shriner's Hospital (South Carolina) Upper Extremity Test (SHUE) is currently under development and evaluation. It is a series of activities to permit observation of function that the child with hemiplegic CP demonstrates. The therapist observes joint positions for the following contractures while performing a variety of functional activities. Joint position during elbow extension is viewed while the child throws a large therapy ball, bounces a ball, places a sticker on a ball, and ties shoelaces. Having the child place a sticker on a large ball, open a wallet, use a knife and fork with Theraputty, hold a wallet, and throw and bounce a large therapy ball allows joint position during wrist extension to be viewed. Observation of joint position during supination can be observed by having the child place her palm on the opposite-side cheek and during the palm-up hand-slap activity "give me five" and receive five. The joint position of thumb (open web, neutral web, thumb in palm) function can be viewed during activities such as removing paper money from a wallet, removing a sticker from a sheet, holding paper when cutting it with scissors, and opening the top of a large-mouth thermos.

Table R20. Upper extremity questionnaire.

Instructions: Please answer questions 1 through 5. When answering yes to a question, please circle any and all comments (a through d) that apply.

My child uses the involved arm very little. Yes _____ No _____

I find it difficult to adequately cleanse the elbow of my child.

I find it difficult to adequately cleanse the wrist of my child.

My child's arm (s) make it difficult to dress because of the positions.

My child can use the involved arm somewhat. Yes _____ No _____

My child can position the arm/hand on his/her own.

My child tends to use the involved hand/arm as a paperweight or post while the opposite extremity performs a task.

My child can use the involved arm to turn switches on and off.

My child has some ability to hold large objects in the affected hand. Yes _____ No _____

My child seems to have difficulty managing small objects (i.e. pick up a pen).

If my child uses a walker, he/she can use the involved arm to hold the walker.

My child has the ability to place objects (i.e. blocks) into my hand or a container when asked.

My child has some ability to dress alone. Yes _____ No _____

My child can use the involved hand to pull up his/her pants

My child can use the involved hand to zip a zipper (holds the tab end).

My child can use the involved hand to do buttons.

My child can use the involved hand to turn doorknobs.

My child can use the involved hand fairly well. Yes _____ No _____

My child can tie his/her own shoes (not velcro straps)

My child can draw with the involved hand (i.e. make stick figures).

My child's thumb tends to get in the way during tasks.

The results of this questionnaire are compared to an answer key. A perfect score adds up to 21 points. Each item is worth one point if the item is not a problem for the child to perform.

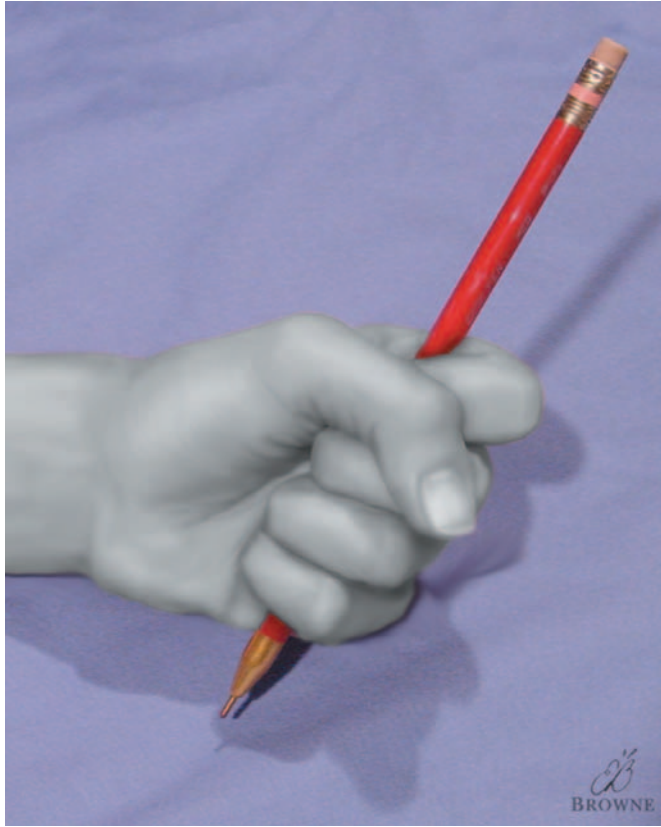Tenodesis effect is assessed by holding the finger straight and measuring the range of passive wrist extension. Spontaneous use of the limb can be determined by observing the child's use of both hands during activities such as ball catch, stabilizing objects, and tying shoelaces. For information about SHUE, contact the Occupational Therapy Department of the Shriners' Hospital of South Carolina in Greenville, SC at (864)240-6277.

Overall Evaluation of CP in Occupational Therapy


For an overall perspective of CP, one may use some general scoring scales for CP from an occupational therapy point of view to evaluate tone, trunk, and neck control as well as fine motor control of the upper extremities.³⁷ To achieve this perspective one must assess the following: type of CP, therapy issues as indicated, associated problems, sensory integration, cognitive integration, and psychosocial skills. Young children with CP also are having neurologic development, therefore maintaining a developmental perspective of function especially functional development of hand use is important (Figure R9).

The types of CP include those with motor cortex lesions (hemiplegia, quadriplegia, spastic, diplegia), basal ganglia lesions (fluctuating tone, dystonia, diakinesis athetosis), and cerebellar lesions (ataxia).

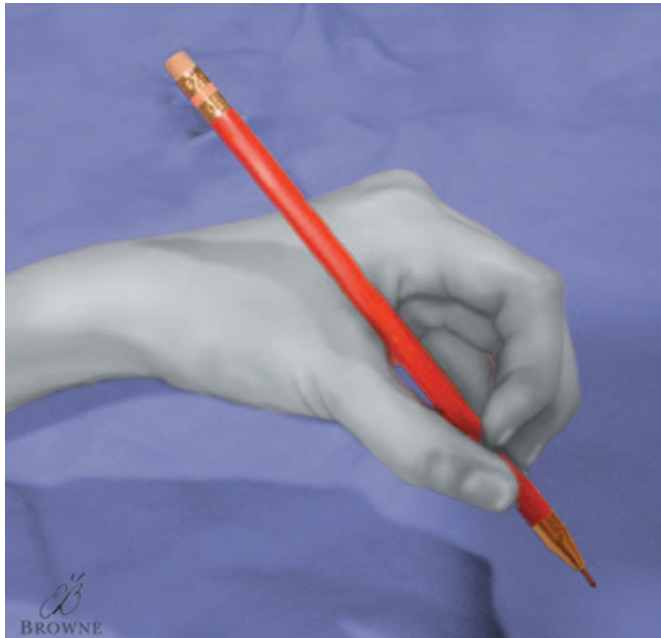A



B



C



D



Figure R9. Hand grasp and position can be classified by developmental stage. Palmar-supinated grasp predominates from age 1 to 2 years (A). When the hand is used it is usually fisted, wrist slightly flexed, and supinated with movement being produced by motion of the whole arm. Between 2 and 3 years of age, digital-pronated grasp predominates with finger grasp, straight pronated ulnar deviated wrist in which movement mainly occurs in the forearm (B). From age 3 to 4 years, static tripod posture predominates in which there is rather crude finger grasp and most motion occurs in the wrist (C). Between 4 and 6 years of age, dynamic tripod postures becomes the norm in which there is better fine grasp with the fingers and motion is occurring in the fingers (D).

Issues to address in therapy as indicated are varied and first include the neuromuscular components and how they affect self-care.³⁸ In that category, the quality and distribution of tone (spasticity, athetosis, both, athetosis with tonic spasms, choreoathetosis, flaccid, ataxia) is considered using a spasticity scale such as Ashworth's Scale³⁹ or a general description of the spasticity.⁴⁰ Next, range of motion is assessed for patterns that may lead to scoliosis, kyphosis, forearm pronation, wrist flexion, swan neck finger deformities, hip subluxation, contractures of elbow/hip adduction, knee flexion, and ankle plantarflexion, etc. Focus is then directed toward quality of movement and includes evaluation of position and the need for hand/wrist splints, and of posture and the need for equipment for seating, wheelchair, bath and toilet supports, etc. Finally, reflexes and reactions such as symmetric tonic neck reflex (STNR), asymmetric tonic neck reflex (ATNR), positive supporting obligatory, and slow protective balance are considered. There are many additional and detailed upper extremity reflexes⁴¹ (Table R21).

Associated problems include seizures, hearing difficulties, eye muscle imbalance, vision problems, mental retardation, obesity, urinary tract infection, and malnutrition/failure to thrive.

Sensory integration assessment includes the evaluation of sensory awareness and sensorimotor processing components and how they affect occupations of work, leisure, and self-care:³⁸ tactile, proprioceptive, vestibular, visual, auditory, gustatory, and olfactory. Also, through perceptual components and how they affect occupations of work, leisure and self-care:³⁸ stereognosis, kinesthesia, body scheme, right-left discrimination, form constancy, position in space, visual closure, figure ground, depth perception, and topographic orientation.

Cognitive integration is determined by assessing arousal, attention, orientation, memory, problem solving, and generalization of learning.

Assessment of psychosocial skills and psychologic components incorporates the evaluation of personality characteristics such as lability, passivity and dependence, resistance to change, and frustration.

Occupational Therapy Evaluation Before Proposed Surgery

Because the surgical procedure(s) produce a biomechanical change, the occupational therapy evaluation encompasses both orthopaedic and functional components. To obtain active/passive ROM (A/PROM) measurement of both upper extremities, a standard goniometry of the upper extremities is performed as well as the passive stretch of the tenodesis and spasticity interference. Evaluation of active ROM includes joint measurement as well as observation of patterns and synergistic motions. If the angle of ulnar deviation is severe, it will make it difficult for the child to see what is being grasped. Severe wrist flexion decreases the ability of the index pad to touch the thumb and mechanical advantage is lost, although it may make opening the fingers easier for pointer use. Swan neck deformities frequently occur with the child's overall finger and wrist extension effort. Synergistic movements that indicate primitive reflexes or spasticity influences are noted. These motions will decrease the ease or ability for large improvements from surgery. Primitive reflexes include Moro or startle reflex, ATNR, STNR, or extensor thrust used to flex the shoulders for arm positioning. Associated reactions may include synkinesis demonstrated by mirroring motions of the stronger extremity, overflow, and oral grimace or tongue use during activities. Basic reflexes that may still persist will decrease the effectiveness of coordinated smooth movement and subsequent function.

Table R21. Upper extremity reflexes.

Hoffmann's sign	A finger flick of the index finger produces clawing of fingers and thumb.
Klippel and Weil thumb sign	Quick extension of fingers causes flexion and adduction of thumb.
Chaddock's wrist sign	Stroking the ulnar side of the forearm near the wrist causes flexion of the wrist with extension fanning of the fingers.
Gordon's finger sign	Pressure exerted over the pisiform bone results in flexion of the fingers or the thumb and index finger.
Tromner's sign	The finger flexion reflex is sharp tap on the palmar surface or the tips of the middle three fingers producing prompt flexion of the fingers.
Babinski's pronation sign	The patient places his hands in approximation with the palms upward and the examiner jars them several times with his own hands from below. The affected hand will fall in pronation, the sound limb remaining horizontal.
Bechterew's sign	The patient flexes and then relaxes both forearms. The paralyzed forearm falls back more slowly and in a jerky manner, even when contractures are mild.
Leri's sign	Upon forceful passive flexion of the wrist and fingers, there is absence of normal flexion of the elbow
Mayer's sign	Absence of normal adduction and opposition of the thumb upon passive forceful flexion of the proximal phalanges (MP joint), especially of the third and fourth fingers of the supinated hand. This procedure may be painful and will decrease cooperation of the patient.
Souque's sign	In attempting to raise the paralyzed arm, the fingers spread out and remain separated.
Sterling's sign	Adduction of a paretic arm occurs upon forceful active adduction, against resistance of the unaffected normal arm.
Strumpell's pronation sign	Upon flexing the forearm, the dorsum of the hand instead of the palm approaches the shoulder.
Forced grasping	Firm radial directed stroking by the examiner's fingers across the subject's palm causes a grasp reaction of the hand.
Kleist's hooking sign	Reactive flexion of the fingers of the affected hand upon pressure exerted by the examiner's hand against the flexor surface of the finger tips
Oral motor	Decreased chest mobility, decreased lip closure, tongue thrust affecting feeding, swallowing, drooling, articulation, dysarthria
Palmo-mental	A vertical stroke along the radial border of the child's thumb will produce a contraction of the chin (mental muscles) if abnormal.

Evaluation of passive ROM is impacted by muscle tone, which can be assessed by Hoffman's sign, finger flick elicits thumb flexion clonus; Klippel–Weil sign, flexed fingers quickly extended elicits thumb flexion/adduction or clonus; and Ashworth's spasticity scale using the elbow extension test.⁴⁰ There are many associated reflexes⁴¹ (see Table R21).

How the range interferes with function, such as difficulty dressing when placing flexed wrists into sleeves, or externally rotated arms getting caught when rolling wheelchairs through doors, is also evaluated. Tenodesis tightness will require a resting hand splint with the wrist placed in the best extension/finger extension after surgery because the FCU to ECRB procedure will increase the tenodesis tightness when the wrist is extended. Skin maceration may be due to a deep wrist crease, fisted hand, and/or antecubital fossa.

A significant aspect of upper extremity function is grasp and the functional use of both arms. Many of the children evaluated are functionally and/or cognitively very limited; thus, selecting the best evaluation test is challenging. A simple observation of how the child is able to stabilize objects, such as wrist as a weight on paper, holding a jar to open with the other hand, or perform a grasp–release task will give a pre- and postassessment measure for each child. Unilateral tests will also give more specific details in actual prehension. Doing functional activities of daily living (ADL) such as dressing, buttoning, and toileting will also give a degree of integrated use of the hands. Basic control is observed for extrinsic and intrinsic hand muscle skill: supination and pronation, wrist flexion, extension, ulnar and radial deviation, finger flexion, extension, ability to abduct and adduct fingers, make an opposed pinch, and form the sign language alphabet characters (which tests isolation of fingers). Grasp strength (Dynamometer or bulbs) and pinch strength⁴¹ is tested by how the child can perform as well as noting the angle of the wrist (usually flexion) during the grasp.

Basic grasp–release is required for the next screening. Some abnormal grasp patterns work well (Figure R10) whereas other patterns are not effective (Figure R11); for example, grasping a 1-inch cube and then releasing it into a coffee can, or stacking 1-inch cubes. The wrist angle (flexion and ulnar drift) is measured while the child is picking up and releasing large objects such as a soda bottle/can, medium-sized objects such as a 1-inch block or checker, and small-sized objects such as a pencil or Cheerio. These dexterity tests require good control of the hand and are frequently not possible with children having involved CP.

The Jebsen Hand Test is composed of seven short timed subtests that assess writing, turning cards, picking up small objects, simulated feeding, stacking checkers, lifting empty 3-inch cans, and lifting 1-pound, 3-inch cans (weight) and is normed for individuals age 6 and up.⁴³ Each subtest is normalized so one subtest may be useful. Thumb abduction is particularly examined with the can pick-up test. The Physical Capacities Evaluation (PCE) includes both unilateral and bilateral subtests but are normed for ages 18 through 68. The Purdue Pegboard, Crawford Small Parts, and Minnesota Rate of Manipulation (MMRT) Tests are more prevocational with endurance being one of the parameters tested.

For children with more advanced physical and cognitive skills, it is helpful to use a bilateral functional test. Observe how the child is able to stabilize objects such as paper against the wrist, holding a jar to open with the other hand, opening a wallet (take money out), unscrewing 3-inch and smaller jars, buttoning, putting on socks, taking off a sticker from a sheet, and taking a cap off a pen or marker. Doing functional ADLs such as dressing, buttoning, and toileting will also give a degree of integrated use of the hands, but will not give a numerical score or norm. Standardized tests may be too long for the attention or cognitive level of the child, too advanced, or have a prevocational focus. Therapists should consider the Peabody Developmental Scales of Fine Motor Skills for children age 4 to 14, or the Bruininks–Oseretski Test of Motor Proficiency for ages 4 to 14, and the Pennsylvania Bi-Manual for children age 17 and up. Clinical observations must be made as to the altered grasp patterns and other postural compensations, etc. Commenting about the child's ability to follow directions and the use of arms and whether the limb interferes with being dressed all give measures to compare after surgery.

After surgery, the child will need a protective wrist cock-up splint with the wrist in about 20° extension to wear continuously with brief breaks during

A

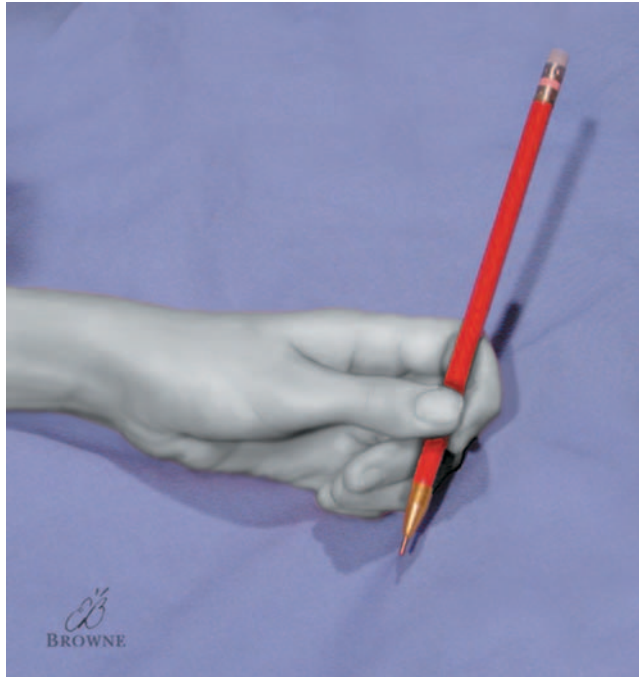
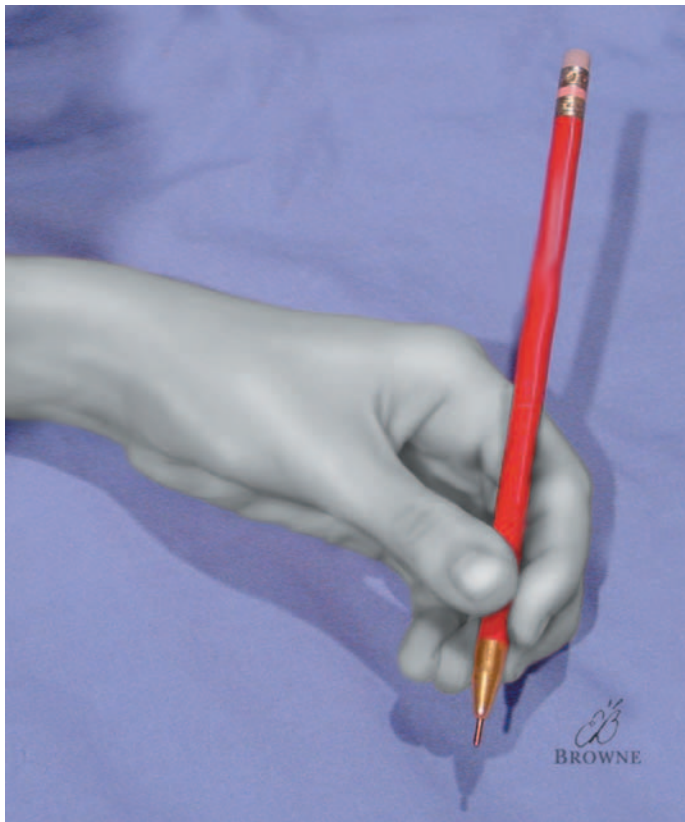
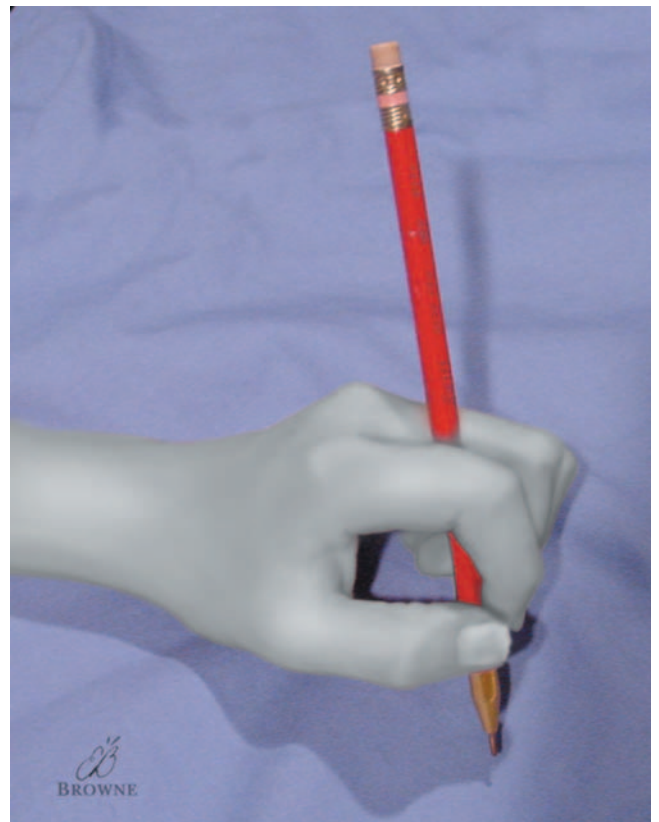


Figure R10. Some individuals develop abnormal but relatively efficient grasps with the tripod grasp being common (A). Also, the quadruped grasp (B) and the adapted tripod grasp are relatively efficient. Stabilizing the pencil between the index and long fingers may look clumsy, but it is an efficient grasp for individuals (C).

B



C



A

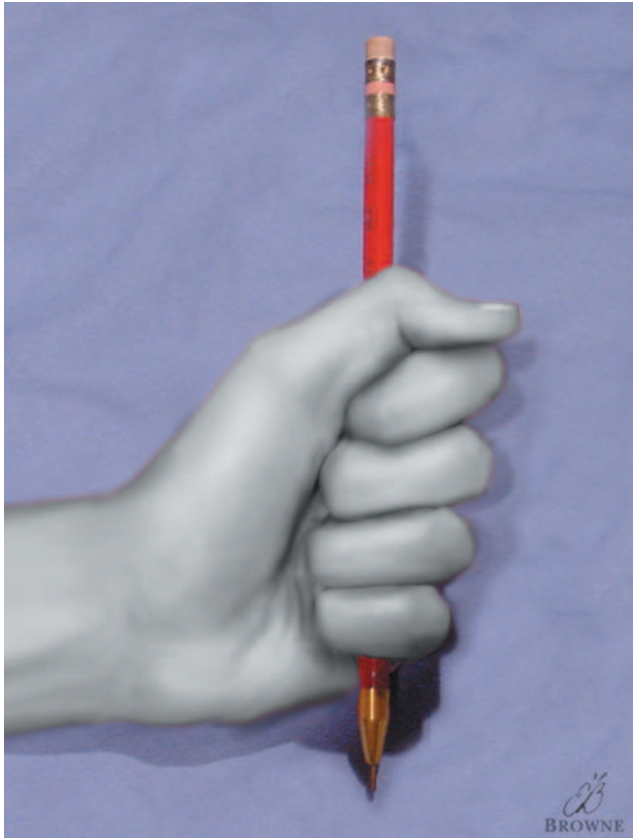


Figure R11. Inefficient grasps that develop in children with cerebral palsy include the transpalmar grasp, which is similar to the very immature grasp (A). Other more abnormal inefficient patterns include the supinated grasp (B), interdigital brace grasp (C), thumb tuck grasp (D), index curl grasp (E,F,G,), and the thumb wrap grasp (H).

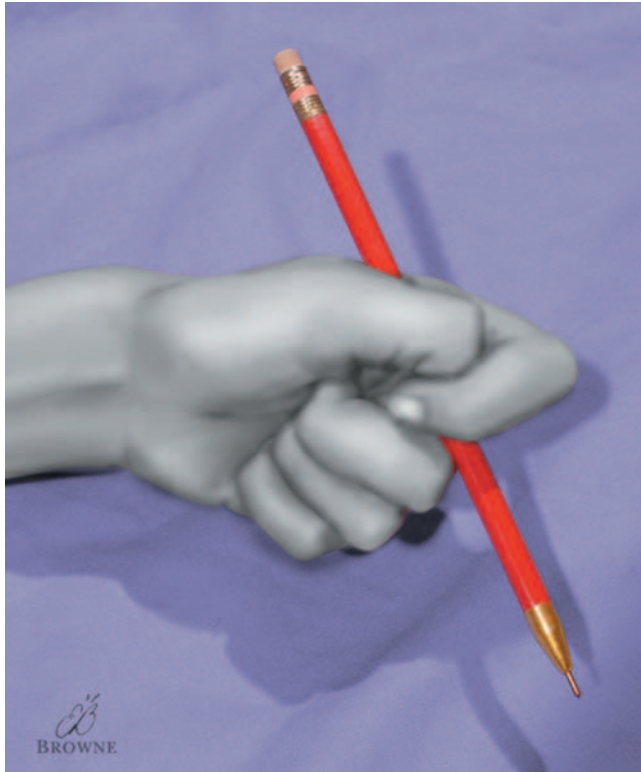
B




C



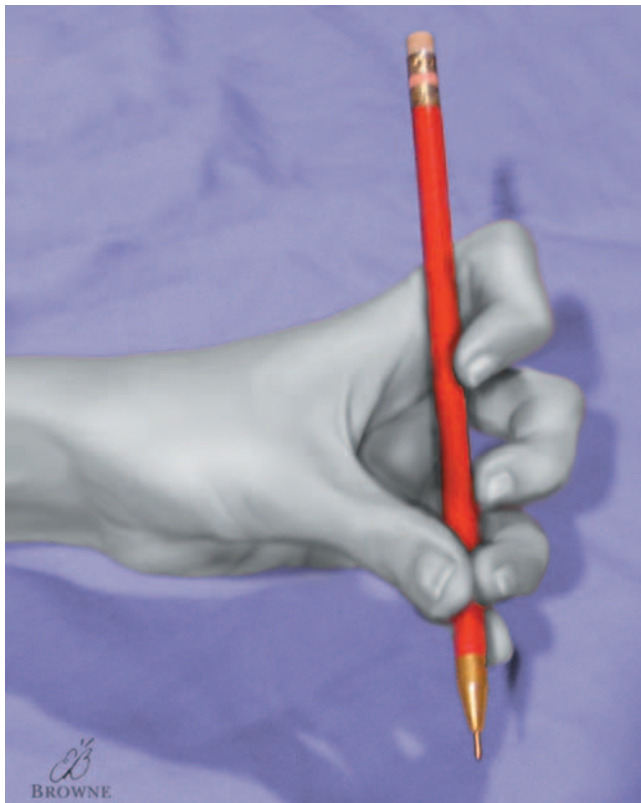
D



E



F



G

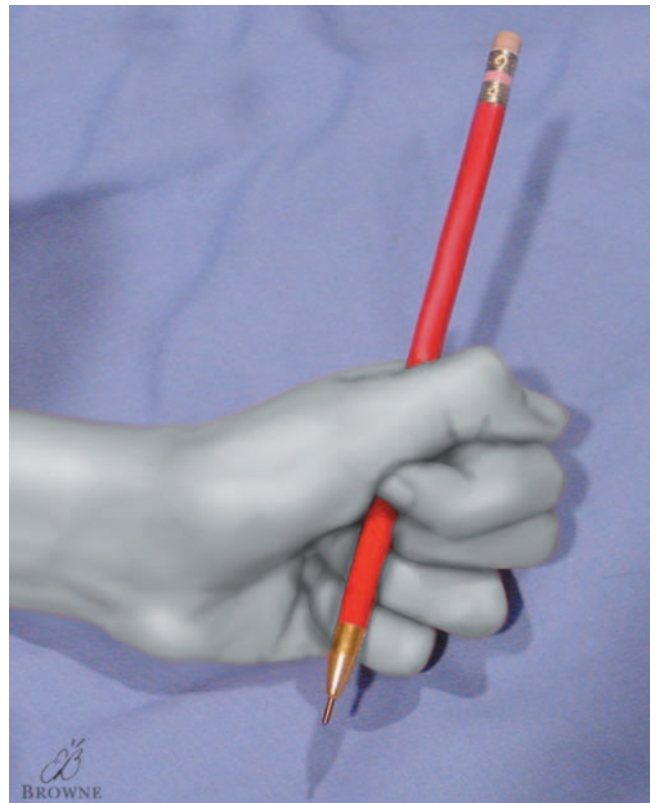
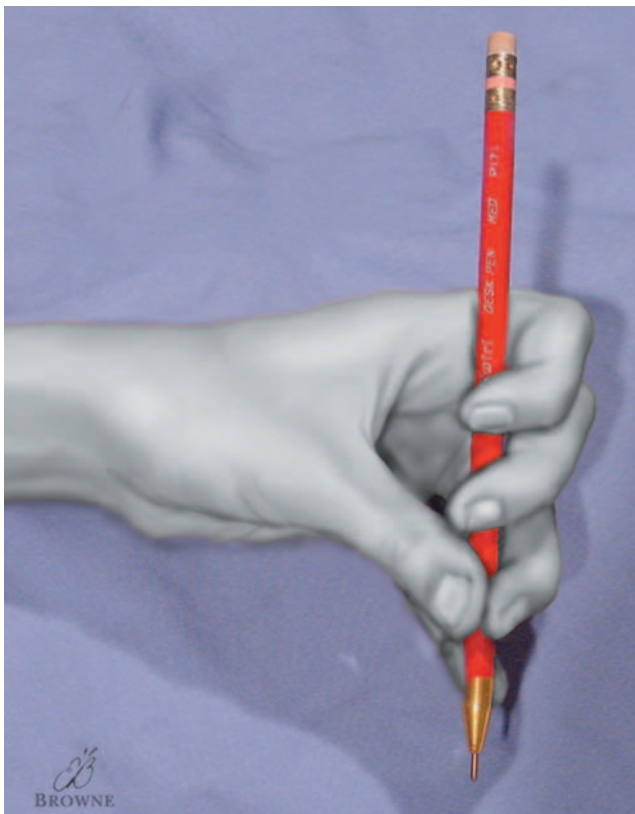

Figure R11 (continued).

Figure R11 (continued).

H



bathing and at meal times for 2 to 3 months, and for 4 to 6 months during ambulation to prevent sudden wrist flexion that may strain or injure the muscle transfers. A night resting splint with the wrist in progressively more extension to stretch the tenodesis may be indicated. Synergy or Aquaplast is used due to the strength and ease of moldability. A dorsal wrist cock-up splint is used because it is easier for the child to put on herself, controls simultaneously the wrist extension and the ulnar drift, places less splint material in the palm, and does not rely on the straps to keep the wrist stable.

Sensory testing is done to help determine if the hand has enough sensation to encourage spontaneous use of the limb. A quick screen is testing the stereognosis differentiation of a 1-inch foam block or wood block. Texture discrimination is tested in the 2- to 3-year-old, object identification in the 4- to 5-year-old, graphesthesia in the 6- to 9-year-old, and two-point discrimination in the older child. Sharp/dull sensation is tested with a paper clip and is done on all the children. The collected clinical data are recorded on a standardized worksheet (Table R22). These published evaluation instruments are available from a number of resources (see Table R25).

Treatment Precautions Following Surgery

If a FCU to ECRB transfer was performed, one should avoid forceful passive wrist flexion and resistive wrist flexion or extension during the first 2 months after cast removal. This precaution is recommended to assure that the muscle transfers are not ruptured.

Table R22. AIDHC occupational therapy clinic evaluation worksheet.

CP Hand/Pre- and Post-surgery

NAME: _____

ID#: _____ DOB: _____

DATE: _____

Referred by: _____ OTR Initials: _____

Dx: CP (Circle type) SPASTIC FLACCID ATHETOID QUAD HEMIPLEGIC – R ___ L ___

Proposed procedure & which extremity: _____

Purpose for surgery: (Circle) Increase wrist extension, supination, thumb abduction, elbow extension, other: _____

Pre-op ___ / ___ / ___ Surgery ___ / ___ / ___ Post-op ___ Post-op (4–6 wks.) ___ Post-op (6 mos.) ___

Dominance: R ___ L ___ Ambulation: (Circle) W/C W/Aids Walks

Resting position of limb:

	SITTING R / L	STAND R / L	WALK R / L	RUN R / L	(Circle)
SHOULDER	/	/	/	/	PROTRACTED/RETRACTED/ABDUC
ELBOW	/	/	/	/	FLEXED/EXTENDED
FOREARM	/	/	/	/	SUPINATED/PRONATED
WRIST	/	/	/	/	FLEXED/EXTENDED
Wrist Deviation	/	/	/	/	RADIAL/ULNAR
HAND	/	/	/	/	FISTED/OPEN
THUMB	/	/	/	/	CORTICAL/ADDucted/ABDucted

Deformities: (List digits/joints) Swan-neck Y ___ N ___ Boutonniere’s Y ___ N ___

Strength/ROM	R A/PROM	L A/PROM	MMT 0-5 R/L
SHOULDER			
SHOULDER /			
SHOULDER ABD			
SHOULDER ADD			
SHOULDER INT ROT			
SHOULDER EXT ROT			
ELBOW V			
ELBOW/			
SUPINATION			
PRONATION			
WRIST V			
WRIST/			
ULNAR DEVIATION			
FINGERS (GROSS)			

(continued)

Table R22. Continued

PROM: TENODESIS ON STRETCH: WITH FINGERS HELD IN EXTENSION,
WHAT IS PASSIVE EXTENSION OF WRIST? R ____ L ____

ABILITY TO FOLLOW DIRECTIONS: (Circle) GOOD FAIR UNABLE

COMMUNICATION EFFECTIVENESS: (Circle)

CLEAR MILDLY UNCLEAR SPECIAL SYSTEM: _____

Comments _____

STRENGTH OF GRASP and WRIST ANGLE: R ____ # ____
L ____ # ____

TIP PINCH: R ____ # ____
L ____ # ____

LATERAL PINCH: R ____ # ____
L ____ # ____

OPPOSITION: R: THUMB to Index Y/N, to 3 Y/N, to 4 Y/N, to 5 Y/N
L: THUMB to Index Y/N, to 3 Y/N, to 4 Y/N, to 5 Y/N

GRASP/RELEASE AND TENODESIS INFLUENCE (Indicate R or L):

TIP PINCH: R ____ # ____
L ____ # ____

LATERAL PINCH: R ____ # ____
L ____ # ____

OPPOSITION: R: THUMB to Index Y/N, to 3 Y/N, to 4 Y/N, to 5 Y/N
L: THUMB to Index Y/N, to 3 Y/N, to 4 Y/N, to 5 Y/N

GRASP/RELEASE AND TENODESIS INFLUENCE (Indicate R or L):

0 1 2 3 0 = UNABLE, NO RELEASE

CUBE _____ 1 = RELEASE C WRIST FLEXED >40 DEG

PENCIL _____ 2 = RELEASE C WRIST NEUTRAL

SPOON/FORK _____ 3 = RELEASE C WRIST EXT. >20 DEG

CUP _____

CHEERIO PICK UP _____ Uses mirroring of other hand (Synkinesis)
Yes = Abnormal No = Normal

CHEERIO TO MOUTH _____ Y/N

UNSCREW A 3" LID _____ Y/N

JEBSEN HAND TEST (If possible): (Seconds) R ____ L ____ Standard Deviation ____

Comments _____

Write 30 letter sentence _____

Turn over 5 cards _____

Pick up 6 small objects _____

Use spoon—5 beans _____

Stack 4 checkers _____

Pick up 5 empty cans _____

Pick up 5 1# cans _____

(continued)

Table R22. Continued

REFLEX OVERFLOW: (Circle)

STARTLE - Y/N

HOFFMAN'S (finger claw with index flick) - Y/N

KLIPPEL+WEL (quick flexed fingers are extended, thumb flexes and adducts) - Y/N

SENSATION SCREEN:

STEREOGNOSIS (Distinguish 1" cube of foam from 1" block of wood) - R=Y/N L=Y/N

SHARP/DULL - R=Y/N L=Y/N

2PT DISCRIMIN (Thumb and index tips 1/4") - R=Y/N L=Y/N

FUNCTIONAL REPORT: (AIDHC) UE Functional Classification for CP (Circle)

R/L Type 0 (No function)

No contractures ____ With dynamic contractures ____ With fixed contractures ____

R/L Type I (Uses hand as paperweight or swipe only, poor or absent grasp and release, poor control)

No contractures ____ With dynamic contractures ____ With fixed contractures ____

R/L Type II (Mass grasp, poor active control)

No contractures ____ With dynamic contractures ____ With fixed contractures ____

R/L Type III (Can actively grasp/release slow and place object with some accuracy)

No contractures ____ With dynamic contractures ____ With fixed contractures ____

R/L Type IV (Shows some fine pinch such as holding pen, some key pinch with thumb)

No contractures ____ With dynamic contractures ____ With fixed contractures ____

R/L Type V (Normal to near normal function; fine opposition of thumb; can do buttons and tie shoes)

No contractures ____ With dynamic contractures ____ With fixed contractures ____

PARENTAL REPORT: Limb interferes with dressing self (Circle) R=Y/N L=Y/N

SPLINTS:

PRIOR to surgery _____

AFTER surgery _____

NIGHT RESTING with hand at maximum tenodesis stretch _____

WRIST COCK-UP (For protection during ambulation) _____

SUPINATION _____

OTHER _____

VIDEO/PHOTO OF HAND GRASPING OBJECT: (Circle)

Start position Grasp block Pick up Cheerio Other _____

TREATMENT RECOMMENDATIONS: _____

SURGERY EXPECTATIONS: (Review post-surgery home program and show types of splints)

Therapist

Occupational Therapy Treatment Goals Following Surgery

Occupational therapy goals are to improve scar formation, avoid swelling, maintain normal position of the wrist, and prevent muscle transfers from being avulsed. Gentle restoration of grasp is also a goal, but does not include resistive strengthening or passive stretching of wrist flexion for several months. Therapy goals are progressive and begin with improving the coordination of grasp (mass grasp, and then refined grasp if feasible). Next is coordination of grasp–release accuracy and grasp with supination/pronation. Focus is then directed at improving the tripod pinch accuracy. Finally, isolated finger control (if feasible) is improved, using many in-hand manipulation activities. Examples are sign language or hand gestures, rotation of two isospheres in the palm, performing peg activities with progressively finer pegs and using resistive tools to strengthen grasp while working with the pegs, and bilateral/bimanual hobbies such as hand sewing, leather lacing, cooking, working with dough/clay, and erector set assembly.

Generally, use of the new arm and hand positions shows favorable results of improving appearance (cosmesis) and advances one functional type (AIDCH orthopaedic score) or progresses one level of the Green's scale in about 2 months; results are best at 6 months, and grip strength recovers in about 6 months.

Photography: Position with Grasp/Release Effort

Photographs obtained before and after surgery will assist documentation to help quantify the outcome. Typically the following activities are photographed if the child can perform them: resting position of the limb (elbow, wrist, and fingers), also called the “attitude” of the limb, best opening of the hand (finger extension and thumb abduction) in combination with the wrist (flexion, ulnar deviation), supination/pronation, elbow flexion/extension, shoulder position (internal or external rotation), and functional grasp and release (thumb/wrist position), which includes the child's attempts at grasping a pen on table, releasing a 1-inch cube into a coffee can, and lifting and placing a 3-inch can (from the Jebsen test). Some grasp or pen-holding patterns have a high risk for developing fatigue or writer's cramp if these postures are used over long periods of time (Figure R12).

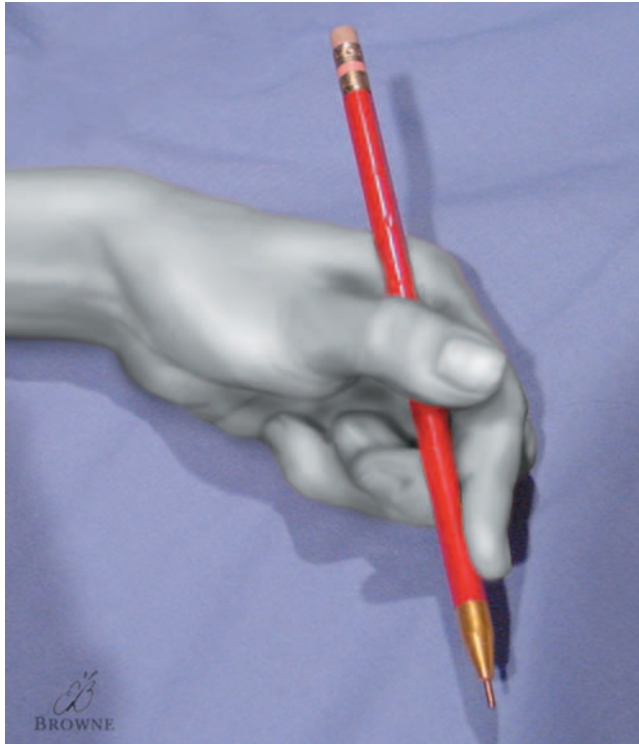
Informational/Instructional Handouts for Families and Home Therapist

Families require written instructions and instructional handouts can be standardized. Examples include information pertaining to splint care (completed for the family when the splints are made), and postsurgery guidelines for the family and home therapist (Tables R23 and R24).

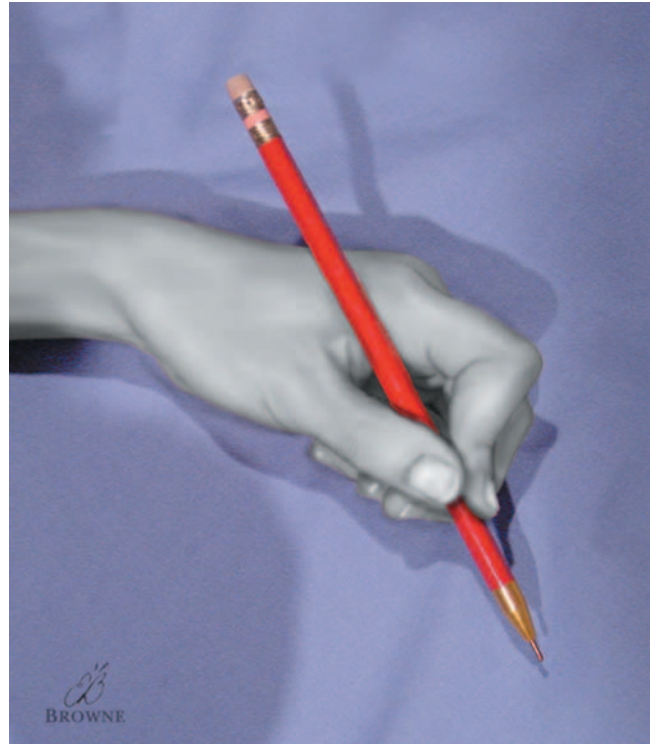Prediction of Functional Outcomes

The more abnormal the reflexes and sensory awareness, the less function even after surgery. A combination of more than one of these systems will decrease use of the limb. Surgery will improve the position of the limb but not improve the sensory control of the limb. If influence of grasp–release skill is present before surgery, it should be better following surgery performed to improve wrist extension because the fingers and thumb will be in a better

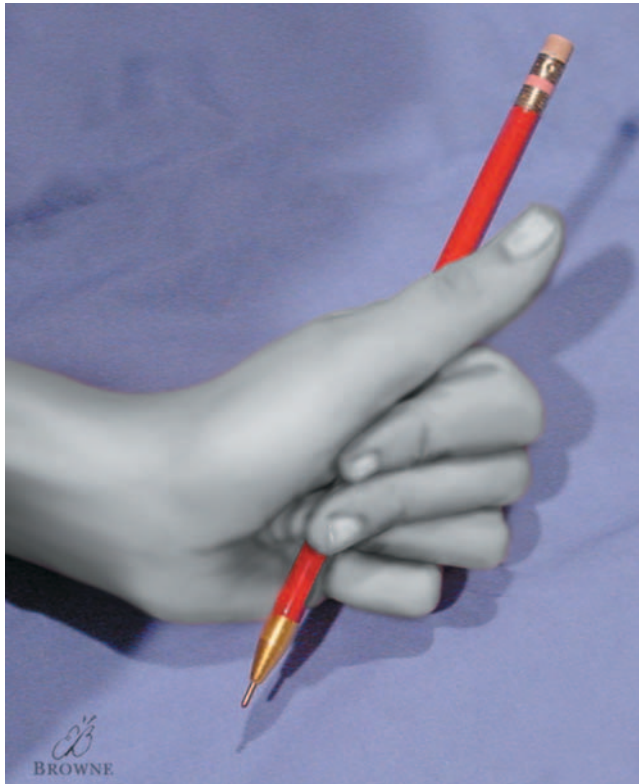A



B



C



D

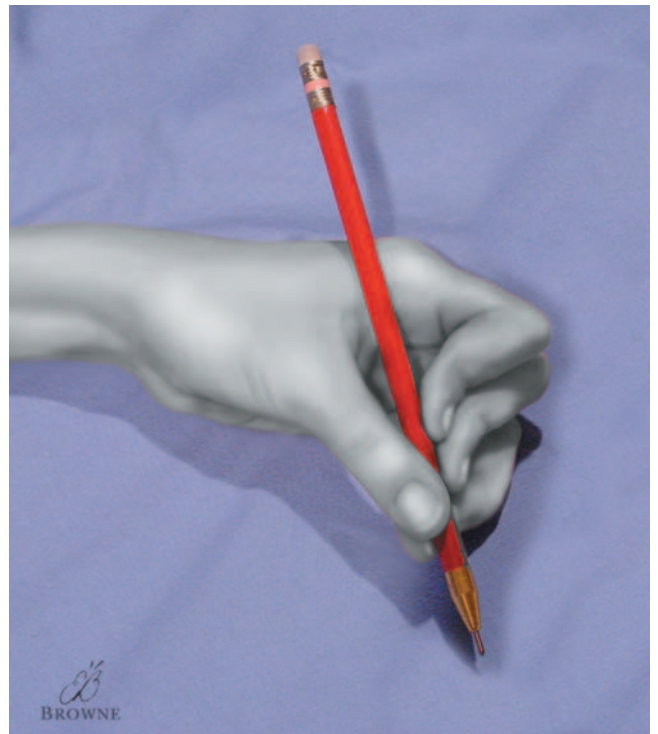


Figure R12. Some grasp patterns that develop have a high risk of leading the writers cramp if the individual does a significant amount of writing. The adducted thumb posture (A) and combinations of digit hyperextension grasps (B–D) are at-risk positions.

Table R23. Therapy services: splint care.

Purpose of Splint: This splint was prescribed by your doctor for:

- preventing deformity
- proper positioning to correct deformity
- increasing range of motion (gentle stretching)
- permitting exercise of specific muscles
- stabilizing for better use of involved limb
- protecting weak muscles, bones and/or joints
- permitting complete rest or healing of the limb, joints, or muscle transfers
- preventing the child from removing tubes, bandages, or interfering with healing

Wearing Instructions:

First, build up the length of time using the splint by wearing it about an hour and then remove it, and examine the skin for red marks. If these marks disappear within one-half hour, then wear the splint for ____ hours.

Usage:

- Night use Build up the length of time wearing the splint by 1 hour until reaching 5 hours; then wear all night.
- Day use Wear ____ hour(s) on, and ____ hour(s) off

Instructions:

If there is pain or redness that does not resolve in one hour, contact the therapist. If sweating occurs, try sprinkling powder (without talc), cornstarch, or placing thin absorbent cotton such as a sock or stockinette between the skin and splint. Dampening the splint, shaking baking soda on the splint and rising it off can eliminate odor from body perspiration.

Be sure the splint straps are not so tight that circulation is cut off. One way to test this is to pinch the nails of the limb in the splint. The toe or finger should turn white, and then pink. If the toe or finger does NOT become pink again or develops a darker color, Recheck the fit of the splint and loosen the strap slightly.

Care of Splint:

The materials in the splint are affected by heat, so take care that it is not left near heat producing areas such as the television and radiator, or left in an enclosed car, or on a sunlit windowsill. Store the splint in a safe area away from pets and where dogs cannot get them; dogs will chew them! The splint should be washed in lukewarm water and mild soap or alcohol. Acetone (fingernail polish remover) and other chemicals should not be used near the splint.

Follow-Up:

Therapists prefer to periodically examine the splint to ensure proper fit if it is used to progressively correct deformity. Please obtain your insurance referral and then call for an appointment if you are not regularly in therapy.

Material Used: _____

Therapist Constructing Splint

Phone Number

Date Constructed

Splint Care Home Program

AIDHC/MK, 1989

AIDHC 2001 Home Therapy Program

biomechanical position to grasp items on a table. If skill with influence of sensation is diminished, the use of the limb in dynamic, quick situations will be diminished. Automatic or spontaneous use of the limb will also be reduced. Influence of primitive reflexes will hinder good control or speed of control. These changes may cause a child to avoid the use of the limb.

Table R24. CP surgery: FCU to ECRB and other surgeries.

Guidelines for Family & Occupational Therapist

The main goals of surgery for the arm of a child with cerebral palsy or spasticity of the flexors are: (Check applicable)

- ___ less skin maceration from tight position (thumb, wrist, elbow creases, even axilla)
- ___ easier cleaning of these creases
- ___ a better appearance of the limb at rest
- ___ a better position of the wrist to permit easier dressing, for care-giver or individual improved ability to see what is in the hand or pinch
- ___ to improve a cylindrical helping-grasp
- ___ to improve the grasp-release but not with the expectation of a faster, normal fine
- ___ pincer grasp or controlled release combined with supination (enhanced dexterity)

The most common surgery is the FCU>ECRL/B which is to transfer the muscle that causes the wrist to flex and ulnarly deviate (the flexor carpi ulnaris or FCU) and transfer it to the insertion of the wrist extensor tendon (the extensor carpi radialis longus and brevis also called ECRL+B or extensor digitorum communis EDC). Associated surgeries usually performed at the same time include biceps release or lengthening, thumb abductor augmentation or thumb adductor release, pronator teres release or rerouting. Following the surgery, the arm is casted for 1 month in a position that stretches the muscles out of the deforming posture. This cast position is typically with the elbow held at 60 degrees of flexion, forearm supinated (palm toward face), and wrist extended (hand away from palm) to about 50 degrees. ROM during cast wear should occur to the shoulder and fingers several times daily to prevent stiffness.

About 1 month after surgery, the surgical dressing/cast is removed and a wrist cock-up splint for protection during ambulation or at school is made the same day as the cast removal. This splint permits grasp but prevents wrist flexion, protecting the transfer while it heals and is to be worn continuously for a period of one to two months. A night resting splint with the wrist, fingers and thumb in full extension is frequently ordered to stretch the tenodesis so that grasp-release is more effective during the day. A supination splint or elbow extension splint may also be ordered.

Home exercises include stretching the joints that were released. Elbow extension, wrist extension and thumb abduction should be done. There should be no active or passive wrist flexion for two months.

Early therapy includes gentle scar massage after the scabs are gone, monitoring swelling, monitoring scar maturation (absorbable sutures), and general wound management. Stretching should be done for the thumb into abduction and extension, the wrist into extension only, the forearm into supination and the elbow into extension. These should be done two to three times per day. The wrist splint should be worn continuously and only removed during the day for therapy or for bathing once the patient is transferred into the tub. The splint is worn all night for the next six weeks, and possibly up to six months. If the child is walking, the splint must be worn to protect the wrist from forceful flexion, which could tear the FCU transfer to the ECRB during the two to three month healing period.

For the therapist at home or school: There is a need to clarify confusion between typical hand therapy for peripheral injuries versus therapy following hand surgery for CNS involvement and spasticity such as CP. These outcome expectations differ greatly. For children with CP who have muscle transfers to balance the power of wrist flexors, the wrist cock-up splint is not intended to create a thumb post, which could cause rubbing due to spasticity, would not permit passive stretching out of the thumb-in-palm tendencies, would limit the thumb to only a pincer thumb post and would interfere with healing of palmar incisions. Instead the use of the wrist cock-up splint is to afford protection for the tendon transfers during healing by preventing fast forceful wrist flexion. The surgery together with the cock-up splint allows some mass cylindrical grasp and pinch early. If the child has a pincer grasp, it is encouraged. A pincer grasp can be assisted with a soft stretchy neoprene strap attached to the wrist cock-up splint to hold the thumb in the necessary abduction and extension and may be removed when walking, holding crutches, doing thumb stretches, etc. A firm functional thumb-post splint is only provided later if there is functional ability to pinch and use the pinch, and if the child has the ability to follow directions for that pinch. If there is some grasp and release, the family can gather a bowl of 1-inch to 3-inch sized items to pick up and move as part of games (hard, soft, fuzzy, rough, i.e., dice, cans, cubes/blocks, Legos, bristle blocks, etc.). Start with picking up and putting down of items. If successful and not frustrating, have the child pick up and put the items into slots, stack, or place on a target like a checkerboard, Tic-Tac-Toe, etc. If the child has better grasp control, try picking up coins, paperclips, buttons, playing cards, etc. Combining grasp with turning the wrist can be tried next, for example buttoning clothes, wind-up toys etc., but these are not usually possible for children with CP.

If there are further questions, please call your therapist at _____ .

11. Intrathecal Baclofen Pumps

Maura McManus, MD, FAAPMR, FAAP

Neurosurgical interventions have been brought into wide use during the past 10 to 15 years. The first is that of dorsal root rhizotomies, which has met with mixed reviews. Recent meta-analysis of affected patients demonstrates that if there is any benefit it is only in a few points of improvement and not dramatic functional improvements. Use of intrathecal baclofen in the pediatric patient having CP has yielded as good a reduction in tone as dorsal rhizotomy and does not represent an ablative procedure. This is important because, unlike rhizotomies, it is entirely reversible.

Table R25. Evaluation sources.

<p>Crawford Small Parts from Psychological Corp, 1-800-872-1726</p> <p>DeMatteo C, Law M, Russell D, Pollock N, Rosenbaum P, Walter S. The reliability and validity of the Quality of Upper Extremity Skills Test (QUEST). <i>Phys Occup Ther Pediatr</i> 1993;13(2):1-18.</p> <p>Bruinink RH. "Bruinink-Oseretsky Test of Motor Proficiency." Circle Pines MN: American Guidance Service, 1978.</p> <p>Jebsen RH. An objective and standardized test of hand function. <i>Arch Phys Med Rehab</i> 1969; 50:311, 1969. (Unilateral hand dexterity test made from household objects)</p> <p>Mathiowitz V, Rogers SL, Dowe-Keval M, Donohoe L, Rennells C. The Purdue Pegboard: norms for 14- to 19-year olds. <i>Am J Occup Ther</i> 1986;40(3):174-179.</p> <p>Minnesota Rate of Manipulation Test. Published by American Guidance Service, Inc., Publishers Building, Circle Pines, MN 55014</p> <p>Peabody Developmental Motor Scales (PDMS-2) by M. Rhonda Folio, Rebecca R. Fewell, Austin, TX: Pro-ed. Order Number 9281 from Pro-ed, 8700 Shoal Creek Boulevard, Austin TX, 78757-6897, 1-800-897-3202</p> <p>Physical Capacities Evaluation of Hand Skill (PCE). In: Bell E, Jurek K, Wilson T. Hand skill: a gauge for treatment. <i>Am J Occup Ther</i> 1976;30(2):80-86.</p> <p>Schmidt R, Toews J. Grip strength as a measured by Jaymar dynamometer. <i>Arch Phys Med Rehab</i> 1970; 51:321.</p> <p>Shriners Hospital, Greenville, SC. "SHUE" Evaluation. Contact the Occupational Therapy Dept. at 864-240-6277.</p> <p>Taylor N, Sand PL, Jebsen RH. Evaluation of hand function in children. <i>Arch Phys Med Rehab</i> Mar 1973;54:129-135 (Jebsen Hand Test: Pediatric Norms).</p> <p>Tiffin J, Asher E. Purdue Pegboard: norms and studies of reliability and validity. <i>J Appl Psychol</i> 1948;32:234. (Purdue Pegboard is available from Lafayette Instrument, 1-800-428-7545.)</p>

Spasticity is the most common motor disorder in CP and is seen in approximately two thirds of the population.^{45,56,84} It is a component of the upper motor neuron syndrome and is described as a velocity-dependent increase in resistance to passive stretch associated with increased deep tendon reflexes (DTR). Spasticity is probably due to an imbalance between inhibitory and excitatory impulses that terminate on or near the alpha motor neurons in the spinal cord.^{56,63,64} In CP, there is believed to be a deficiency of descending impulses that typically stimulate the release of the inhibitory neurotransmitter gamma-aminobutyric acid (GABA). GABA acts presynaptically to inhibit the release of excitatory neurotransmitters such as glutamate and aspartate, resulting in relative excess of excitatory impulses and resultant hypertonia.^{45,59,64}

Although some spasticity may be necessary for function in children with neurologic impairment, it is often a problem that can be difficult to treat. Spasticity may cause pain, limit sleep, lead to joint deformity, and interfere with function. It may also interfere with care including transfers, toileting, bathing, and dressing.^{59,68,71}

Multiple approaches are available for treatment of spasticity in patients with CP. These include physical and occupational therapy for stretching, positioning, and bracing. Oral medications have been used as well as local treatments such as Botox injections and phenol motor point block injections.^{56,59,68} Orthopaedic surgery may be necessary, and this may include soft-tissue releases and/or osteotomies.⁸⁴ Neurosurgical procedures such as selective dorsal rhizotomy are also available.^{44,79} The goals for treatment should be realistic and individualized and they need to be agreed upon by patient, family/caregiver, and medical team. Ideally, a multidisciplinary team should be involved in the decision making. Such a team may include physi-

cal and occupational therapists, nurse, physiatrist, neurologist, orthopaedist, neurosurgeon, patient, and family.

Several oral medications have been used to reduce tone, including diazepam, baclofen, dantrolene, tizanidine, and clonidine. Although they can decrease spasticity, their sedating side effects are not well tolerated in children.^{59,68,90}

Baclofen has been noted to be moderately helpful when taken orally for spasticity of spinal origin in adults. It has been relatively unhelpful in treating spasticity of cerebral origin, especially in children with CP. It is lipophilic and crosses the blood–brain barrier poorly. Intrathecal baclofen has been shown to reduce spasticity with fewer side effects.⁶⁸

Pharmacology of Baclofen

Baclofen (lioresal) is an analogue of GABA, which is the main inhibitory neurotransmitter in the central nervous system (CNS). Intrathecal baclofen diffuses into the superficial layers of the dorsal gray matter of the spinal cord (layers II–III) where GABA_B receptors are believed to be located.^{70,82} These receptors have been noted in the brainstem as well. Muller et al. noted the concentration of baclofen in the cerebrospinal fluid (CSF) is 10 times higher than levels achieved by oral administration.⁷⁶ Also, there is a concentration gradient from the lumbar to cervical region of 4 to 1.⁷⁰

History

In 1984 Penn and Kroin pioneered the use of intrathecal baclofen for spasticity in patients with multiple sclerosis and spinal cord injury.⁷⁰ Albright et al. did their first study in 1991 and a follow-up study in 1993 noting successful decrease in spasticity in patients with spasticity of cerebral origin.^{45,46} In 1992 the Federal Drug Administration (FDA) approved the use of intrathecal baclofen in the form of the Medtronic SyncroMed implantable infusion system for treatment of spasticity of spinal origin. This same treatment was approved by the FDA for treatment of spasticity of cerebral origin in adults in 1992, but it was not approved for use in children until 1997.⁴⁶

Criteria

For the success of intrathecal baclofen, careful patient selection is critical. Patients with moderately severe spasticity of spinal and cerebral origin (i.e., CP, traumatic or anoxic brain injury) have been successfully treated with intrathecal baclofen.^{46,73,88} Patients with dystonia have also responded to this treatment, often at higher doses.⁴⁷ Patients with athetosis, ataxia, and myoclonus have not noted improvement. Spasticity is considered severe with Ashworth scores of greater than 3.⁵¹ Spasticity and dystonia are believed to be problematic when they are generalized and significantly interfere with movement, positioning, or care. Patients may also experience spasticity-related pain during the day and at night, and this sometimes limits sleep. Many patients are at risk of severe joint deformity.⁸⁴ Other important issues to consider include the following⁶²: the patient must have significant body mass to maintain the pump, the patient and family need to understand and accept the cosmesis of the pump, the entire team must agree upon appropriate goals, and the patient and family must be motivated to achieve these goals

and be committed to the follow-up required to maintain the pump's function. Ideally, the previous assessments should be made with a multidisciplinary team in a spasticity management clinic where families can have access to adequate information. Gait analysis should be part of the evaluation in ambulatory patients.⁷⁴

The following are additional clinical considerations, not contraindications, for intrathecal baclofen pump implantation.⁶² A trial of oral baclofen is not a prerequisite for patients with spasticity of cerebral origin. Patients who have had a spinal fusion cannot undergo a trial, but this not a contraindication for pump implantation. A history of seizures is not a contraindication to intrathecal baclofen therapy. The presence of a ventriculoperitoneal (VP) shunt is not a contraindication. Patients with VP shunts may require less baclofen. Prior soft-tissue lengthenings, tendon releases, and selective dorsal rhizotomy are not contraindications. For patients with cervical or trunk weakness, the benefits of baclofen in reducing extremity spasticity must be weighed against the potential for loss of the patient's function if trunk and cervical tone is reduced. Some patients and families may be reluctant to undergo the destructive invasive procedure. The reversible nature of intrathecal baclofen may be especially important.

Screening Trial and Pump Implantation

Once a patient is felt to be a potential candidate, a screening trial is scheduled. Because of the risk of respiratory depression during the trial, it is probably most appropriately performed in a hospital on a general nursing floor.⁸³ Early on the day of the trial, a baseline physical exam is completed, and a lumbar puncture is performed. The test dose of either 50, 75, or 100 µg is injected into the intrathecal space. If conscious sedation is used, a short-acting sedative such as midazolam may be used in conjunction.⁶⁵ After the lumbar puncture is performed and intrathecal baclofen is injected, patients should remain flat for at least 1 hour to avoid spinal headache. Spasticity scores/Ashworth or modified Ashworth scores are recorded preinjection and at 2-hour intervals postinjection as patients are followed for 6 to 8 hours. It takes 1 to 2 hours for the baclofen to penetrate the spinal cord to produce clinical effect. Peak effect is believed to be at 4 hours.⁷⁵ Aside from noting Ashworth scores, it is important to assess patients out of bed in their seating/wheelchair system.⁵² It is often difficult to obtain a functional assessment during the screening trial. Evaluation of mobility in an ambulator may be challenging as underlying weakness may limit function during the trial. Such a patient may still be a candidate for the pump because a lower dose of intrathecal baclofen can be programmed through the pump than can be achieved during the trial.⁵⁸ Although bolus injections are preferred for screening trial, continuous infusion trials using an externally placed catheter can be performed; this is important in patients in whom dystonia is being evaluated.^{47,53} If the patient had a clinically significant response to intrathecal baclofen (i.e., Ashworth or modified Ashworth scores decreasing by 1 or more), the pump implantation is scheduled.

The intrathecal baclofen delivery system consists of a programmable subcutaneously implanted pump with a reservoir attached to an intraspinal catheter (Medtronic, Inc., Minneapolis, MN). The adult-sized pump with an 18-ml reservoir is 7.5 cm by 2.8 cm (similar to the size of a hockey puck). A pediatric-sized pump with a 10-ml reservoir is available. It is one third thinner, but has the same diameter as the adult-sized pump.⁶² Because they are close in size, it might be difficult to justify using the pediatric-sized pump, which will need to be refilled much more frequently.

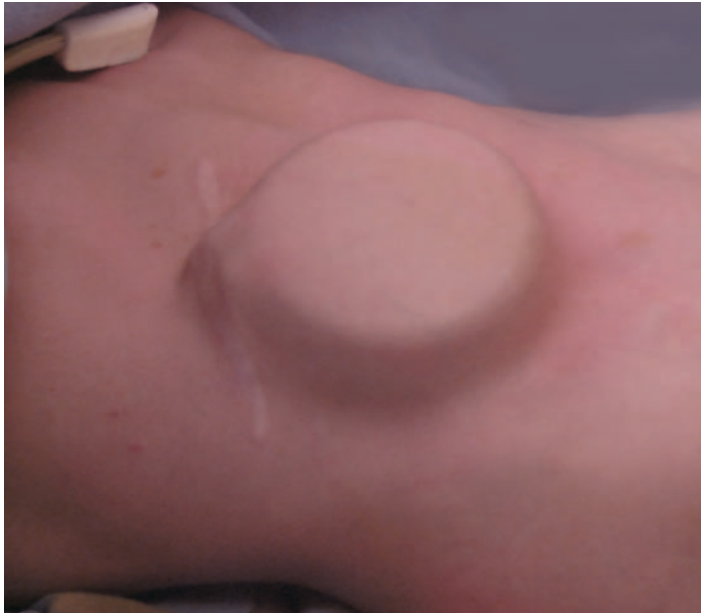

Figure R13. Baclofen pumps may be very prominent in thin children. Implanting the pump under the fascia makes it less prominent, and it is very important to implant the pump so the scar is not overlying the implant, as this has a higher risk of breaking down than normal skin

The pump is inserted under general anesthesia into a lateral abdominal subcutaneous location or under the external oblique and rectus fascia (Figure R13). A catheter is tunneled subcutaneously and connected to an intrathecal catheter. The catheter enters the subarachnoid space of the spinal canal at the lumbar spinal level.^{46,62} The catheter can be placed at various heights depending on whether upper extremity relaxation is also a goal. To increase the effect of intrathecal baclofen on the upper extremities, the catheter can be placed at midthoracic level (T6–T7) rather than T11–T12.⁶⁰ The mean dosing may also be lower. The pump is programmed to deliver a continuous infusion, which assists with diffusion of baclofen into the spinal cord.

Postoperatively the patient remains supine for 48 hours to limit spinal leak and headache. For nonambulators, postoperative dose adjustments can be made daily even during bed rest. For ambulators, it may be necessary to wait until they are cleared to be out of bed to ambulate before adjusting the dose.^{60,65} Adjustments should be made once daily while in the hospital postoperatively. The first follow-up visit should be at 7 to 10 days and then monthly for the first 6 months. It may take 6 to 9 months to gradually titrate the dose to the desired clinical response. In some cases, the dose may need adjustment for the first 2 years after implantation.^{46,73} Typically, the dose of intrathecal baclofen is not related to age or weight. As noted above, patients with VP shunt may require a lower dose.

The pump reservoir is refilled by percutaneous puncture through a septum in the pump at intervals of 1 to 3 months. Dosage adjustments are made via an external computer/programmer and transmitted to the pump by a handheld radiofrequency wand. The pump can be programmed to deliver the baclofen in several modes including simple continuous infusion, complex continuous infusion (i.e., rate changes at set times during the day), and bolus infusion mode.⁶²

Complications

Complications seen with the intrathecal baclofen infusion system may be related to the medication, the pump, the catheter, or the surgical procedure.

Complications related to the medication may be seen during the trial, immediately postoperatively, or during maintenance therapy especially at the time of dose adjustments. Common adverse effects of the medication include somnolence, headache, nausea, vomiting, hypotonia, dizziness, and increased constipation. Transient urinary retention/hesitation has been noted after dose adjustment, and this appears to respond to decreasing the dose.^{66,77} The most serious side effects of medication overdose include respiratory depression and loss of consciousness progressing to coma. There is no specific antidote for treating overdose, but reports suggest that intravenous (IV) physostigmine may reverse the central effects, most notably drowsiness and respiratory depression.⁷⁶ Pediatric dosage of physostigmine is 0.02 mg/kg IV, with no more than 0.5 mg/min. This dose may be repeated at 5- to 10-minute intervals if necessary, with a maximum dose of 2 mg.⁶²

Complications of intrathecal baclofen withdrawal have been well documented in the literature; they include rapid increase in spasticity, irritability, hallucinations, seizures, and pruritus without rash. Muscle rigidity, rhabdomyolysis, multiorgan system failure, and death have been reported but are quite rare.⁸⁷

Other complications are more easily divided into immediate postoperative and late complications. Immediate postoperative complications include infection at pump or catheter site, meningitis, wound dehiscence, seroma, or cerebrospinal fluid (CSF) leak.^{46,72,73} Infections have led to pump removal, but the overall number of postoperative infections has decreased with use of prophylactic antibiotics. CSF leak may be suspected if postoperative spinal headache persists. Fluid collection and/or leakage at the catheter site in the lumbar region may also present as a CSF leak. Such a leak usually seals off within 1 to 2 days but may take as long as 2 to 3 weeks. If the spinal leak persists, a blood patch may be considered.⁶⁵

Late complications can involve pump and catheter problems and skin breakdown, as well as human error. Skin breakdown over the pump site has been seen under braces or seatbelts. Close monitoring of pump site and adjustments to wheelchairs and braces can limit this problem. Human error can lead to programming errors, improper filling of the reservoir, and errors in dosing concentration. The highest probability of seeing these problems is within 48 hours after refill.⁸³

Pump problems may include positional and mechanical problems. Pumps have been reported to flip over, especially in obese patients, and more secure suturing may limit this. Mechanical problems include battery failure and rotor lock problems. Low battery level can be detected by interrogating the pump. Current batteries, placed since 1999, have a longer lifespan of 7 years, rather than 4 years as observed in the original pumps. With a low reservoir volume, less than 2 ml, the pump will slow the rate automatically, and this can lead to an underinfusion of programmed dose. If a rotor lock problem develops, this may also present with the patient receiving less medication than was programmed. This can be evaluated by obtaining an X-ray of the pump to identify the roller and repeat X-ray in 24 hours should reveal roller-changing position.⁶²

Catheter problems can include a kink, fracture, blockage, migration, and disconnection. Patients can present with signs of limited clinical response or even clinical withdrawal. After interrogating the pump, a radiologic examination with anteroposterior and lateral views of the pump and catheter system should be obtained. If an X-ray provides minimal information, a check of the catheter patency to the site of delivery with either contrast media or radiolabeled indium is indicated.⁶² Follow-up X-rays are reviewed after radio-

paque solution is injected. After radiolabeled indium is used, serial nuclear medicine scans over 12 to 24 hours are reviewed.⁸⁵ After the cause of intrathecal baclofen interruption is determined, either surgical repair, revision, or replacement of system components is carried out. Catheter problems overall have been reduced since catheters have been made more flexible and since the one-catheter system has replaced the two-catheter system.

Outcomes

The benefits of intrathecal baclofen have been published in the spinal cord injury literature and more recently in the CP literature.^{46,49,50,81} Functional improvements and improved quality of life have been reported in the treatment of both spasticity and dystonia. These benefits include increased comfort and ease of positioning, with increased seating tolerance and decreased caregiver burden; this has been reported in areas of bathing, toileting, and dressing. Decreased pain and improved sleep have also been noted.^{46,50,52} Many families have reported increased smiling, engaging, and socializing at home and at school. Functional improvement has been noted in upper extremities as well as lower extremities.⁴⁸

Although the benefits of intrathecal baclofen in the spastic quadriplegic population are well documented, the role of intrathecal baclofen in ambulatory patients is not as clear.^{50,72,73} One study by Albright et al. investigated functional improvement in ambulators, marginal ambulators, and non-ambulators. Of 24 patients, clinicians noted functional improvement in 9, no change in 12, and worsening function in 3. Subjectively, 20 of 24 of these families felt gait had improved.⁵⁸ This is a promising study even without formal gait analysis. Pre- and postintrathecal baclofen gait analysis will likely add significant information.⁷⁴ Intrathecal baclofen treatment in CP may reduce the need for subsequent orthopaedic surgery related to spasticity and may decrease the need for multiple orthopaedic procedures.⁵⁷

Some challenges to outcome include the fact that there is more effect from intrathecal baclofen on lower extremities than upper extremities. If patients and families feel strongly about optimizing upper extremity function, they need to be aware that standing, transfers, and ambulation may be lost.

One great advantage of intrathecal baclofen compared to selective dorsal rhizotomy is that the dose of intrathecal baclofen can be titrated to carefully reduce tone while not completely eliminating it.⁴⁸ This has been demonstrated to be very helpful in children who have significant spasticity with lower extremity weakness who inherently use some of the spasticity in their lower extremities to ambulate. Another advantage is if patients and families are not completely satisfied with the intrathecal baclofen therapy, the system may be removed.

Summary

Intrathecal baclofen treatment has been shown to successfully decrease generalized spasticity in patients with CP. The benefits in spastic quadriplegic patients have been demonstrated. While there does seem to be a functional benefit in ambulatory patients, the role of intrathecal baclofen in this group is not as clear. This continues to need further study, particularly with gait analysis.

Success of the intrathecal baclofen therapy does seem to be related to appropriate patient selection, setting of achievable goals, patient and family motivation and compliance, and dedicated multidisciplinary team.

References

1. DeGangi, GA, Royeen C. Current practice among neurodevelopmental treatment association members. *Am J Occup Ther* 1994;48(9):803–9.
2. Bly L. A historical and current view of the basis of NDT. *Pediatr Phys Ther* 1991; 131–5.
3. Slominski AH. Winthrop Phelps and the Children's Rehabilitation Institute. Management of motor disorders of children with cerebral palsy. In: Scrutton D, ed. *Management of the Motor Disorders of Children with Cerebral Palsy*. London: Spastics International Medical Publications, 1984:59–74.
4. Damiano DL, Vaughan CL, Abel MF. Muscle response to heavy resistance exercise in children with spastic cerebral palsy. *Dev Med Child Neurol* 1995;37:731–9.
5. Wiley ME, Damiano DL. Lower-extremity strength profiles in spastic cerebral palsy. *Dev Med Child Neurol* 1998;40:100–7.
6. Faigenbaum AD, Westcott WL, Loud RL, Long C. The effects of different resistance training protocols on muscular strength and endurance development in children. *Pediatrics* 1999;104:e5.
7. Lockwood RJ, Keyes AM. *Conditioning with Physical Disabilities*. Champaign, IL: Human Kinetics, 1994.
8. American Academy of Pediatrics. 1990. Strength training, weight and power lifting by children and adolescents (RE9196). Committee on Sports Medicine 1989–1990. <http://www.aap.org/policy/03327>
9. MacPhail HEA, Kramer JF. Effect of isokinetic strength training on functional ability and walking efficiency in adolescents with cerebral palsy. *Dev Med Child Neurol* 1995;37:763–75.
10. Darrah J, Wessel J, Nearingburg P, O'Connor M. Evaluation of a community fitness program for adolescents with cerebral palsy. *Pediatr Phys Ther* 1999;11: 18–23.
11. Darrah J, Fan JSW, Chen LC, Nunweiler J, Watkins B. Review of the effects of progressive resisted muscle strengthening in children with cerebral palsy: a clinical consensus exercise. *Pediatr Phys Ther* 1997;9:12–7.
12. Horvat M. Effects of a progressive resistance-training program on an individual with spastic cerebral palsy. *Am Correct Ther J* 1987;41:7–11.
13. McCubbin JA, Shasby GB. Effects of isokinetic exercise on adolescents with cerebral palsy. *Adapted Physical Activity Quarterly* 1985;2:56–64.
14. Johnson LM, Nelson MJ, McCormack CM, Mulligan HF. The effect of plantarflexor muscle strengthening on the gait and range of motion at the ankle in ambulant children with cerebral palsy: a pilot study. *N Z J Physiother* 1998;26: 8–14.
15. Damiano DL, Kelly LE, Vaughan CL. Effects of a quadriceps femoris strengthening program on crouch gait in children with cerebral palsy. *Phys Ther* 1995; 75:658–67.
16. Damiano DL, Abel MF. Functional outcomes of strength training in spastic cerebral palsy. *Arch Phys Med Rehabil* 1998;79:119–125.
17. Carr JH, Shepherd R. Neurological rehabilitation: optimizing motor performance. Theoretical consideration in balance assessment. *Aust J Physiother* 2001; 47:89–100.
18. Long C. *Handbook of Pediatric Physical Therapy*. Baltimore: Williams & Wilkins, 1995:198–200.
19. Woolacott, MH, Shumway-Cook A. Development of posture and gait across the lifespan. In: Long C. *Handbook of Pediatric Physical Therapy*. Baltimore: Williams & Wilkins, 1995:198–200.
20. Nasher LM, Shumway-Cook A, Marin O. Stance posture control in select groups of children with cerebral palsy: deficits in sensory organization and muscular coordination. *Exp Brain Res* 1983;49:393–409.
21. Gentile AM. Skill acquisition. *Aust J Physiotherapy* 2001;47:89–100.
22. Michaud LJ. Electrical stimulation in children. In: *Pediatric Rehabilitation State of the Art Reviews. Physical Medical Rehabilitation*, Vol. 14, No. 2. Philadelphia: Hanley and Belfus, year:347–362.

23. Reed B. The physiology of neuromuscular electrical stimulation. *Pediatr Phys Ther* 1997;9:100. As adapted from Baker LL, McNeal DR, Benton LA. *Neuromuscular Electrical Stimulation: A Practical Guide*, 3rd ed. Downey, CA: Los Amigos Research and Education Institute, 1993.
24. Bertoti DB. Effect of therapeutic horseback riding on posture in children with cerebral palsy. *Phys Ther* 1988;68:1505–1512.
25. Heine B, Benjamin J. Introduction to hippotherapy. *Adv Phys Ther PT Assist* 2000;June:11–13.
26. Haehl V, C Giulina, C Lewis. Influence of hippotherapy on the kinematics and functional performance of two children with cerebral palsy. *Pediatr Phys Ther* 1999;11:89–101.
27. MacKinnon JR. Therapeutic horseback riding: a review of the literature. *Phys Occup Ther Pediatr* 1995;15:1–15.
28. MacKinnon JRA. Study of therapeutic effects of horseback riding for children with cerebral palsy. *Phys Occup Ther Pediatr* 1995;15:17–30.
29. MacPhail HEA, J Edwards, J Golding, et al. Trunk postural reactions in children with and without cerebral palsy during therapeutic horseback riding. *Pediatr Phys Ther* 1998;10:143–7.
30. McCloskey S. The effects of hippotherapy on gait in children with neuromuscular disorders. *AHA News Summer* 2000;10–14.
31. McGibbon NH, Andrade CK, Widener G, Cintas H, et al. Effect of an equine-movement program on gait, energy expenditure, and motor function in children with spastic cerebral palsy: a pilot study. *Dev Med Child Neurol* 1998;40:754–62.
32. Quest Therapeutic Services, Inc. Hippotherapy volunteer information packet. 461 Cann Rd., West Chester, PA 19382. (610) 692-0350. e-mail: SandraMcCloskey@msn.com
33. North American Riding for the Handicapped Association (www.narha.org/PDFFiles/tr_cp.pdf).
34. Thorpe DE, Reilly MA. The effects of aquatic resistive exercise on lower extremity strength, energy expenditure, function mobility, balance and self-perception in an adult with cerebral palsy: a retrospective case report. *Aquat Phys Ther* 2000;8(2):18–24.
35. Bidabe L. M.O.V.E.: (Mobility Opportunities Via Education) Curriculum. Bakersfield, CA: Kern County Superintendent of Schools, 1990.
36. Barnes SB, Whinnery KW. Mobility opportunities via education (MOVE): theoretical foundations. *Phys Disab* 1997;16(1):33–46.
37. Case-Smith J, Allen A, Pratt PN. *Occupational Therapy for Children*, Vol. 3. St. Louis: Mosby, 1996.
38. Dunn W, ed. *Pediatric Occupational Therapy*. Thorofare, NJ: Slack, 1991.
39. Damiano DL, Quinlivan JM, Owen BF, Payne P, Nelson KC, Abel MF. What does the Ashworth scale really measure and are instrumented measures more valid and precise? *Dev Med Child Psychol* 2002;44(2):112–118.
40. Pedretti L. *Occupational Therapy, Practice Skills for Physical Dysfunction*. St. Louis: Mosby, 1985:89.
41. Chusid JG, McDonald JJ. Correlative Neuroanatomy and Functional Neurology. Los Altos, CA: Lange, 1964:212 (persistent reflexes in the UE and hand).
42. Mathiowitz V. Grip and pinch strength: norms for 6-19 year olds. *Am J Occup Ther* 1986; 40:705–711.
43. Jebsen RH. An objective and standardized test of hand function. *Arch Phys Med Rehabil* 1969;50:311.
44. Abbott R. Selective rhizotomy for treatment of childhood spasticity. *J Child Neurol* 1996;11:S36–42.
45. Albright AL, Cervi A, Singletary J. Intrathecal baclofen for spasticity in cerebral palsy. *JAMA* 1991;265:1418–22.
46. Albright AL, Barron WB, Fasick MP, Polinko P, Janosky J. Continuous intrathecal baclofen infusion for spasticity of cerebral origin. *JAMA* 1993; 270:2475–7.
47. Albright AL, Barry MJ, Fasick P, Barron W, Schultz B. Continuous intrathecal baclofen for symptomatic generalized dystonia. *Neurosurgery* 1996;38:934–9.

48. Albright AL, Barry MJ, Fasick MP, Janosky J. Effects of continuous intrathecal baclofen infusion and selective dorsal rhizotomy on upper extremity spasticity. *Pediatr Neurosurg* 1995;23:82–85.
49. Armstrong RW. Intrathecal baclofen and spasticity: what do we know and what do we need to know? *Dev Med Child Neurol* 1992;34:739–745.
50. Armstrong RW, Steinbok P, Cochrane DD, Kube S, Fife SE, Farrell K. Intrathecally administered baclofen for the treatment of children with spasticity of cerebral palsy. *J Neurosurg* 1997;87:409–14.
51. Ashworth B. Preliminary trial of carisoprodol in multiple sclerosis. *Practitioner* 1964;192:540–2.
52. Barry MJ, Albright AL, Shultz BL. Intrathecal baclofen therapy and the role of the physical therapist. *Pediatr Phys Ther* 2000;12:77–86.
53. Butler C, Cambell S. Evidence of the effects of intrathecal baclofen for spastic and dystonic cerebral palsy. AACPDM Treatment Outcomes Committee Review Panel. *Dev Med Child Neurol* 2000;42:634–45.
54. Campbell SK, Almeida GL, Penn RD, Corcos DM. The effects of intrathecally administered baclofen on function in patients with spasticity. *Phys Therapy* 1995;75:352–62.
55. Frost F, Nanninga J, Penn R. Intrathecal baclofen infusion: effects on bladder management programs in patients with myelopathy. *Am J Phys Med Rehabil* 1989;68:112–5.
56. Gans B, Glenn M. In Glenn M, Whyte J, eds. *The Practical Management of Spasticity in Children and Adults*. Philadelphia: Lea & Febiger, 1990:1–7.
57. Geszten PC, Albright AL, Johnstone GF. Intrathecal baclofen infusion and subsequent orthopedic surgery in patients with cerebral palsy. *J Neurosurg* 1998;88:1009–13.
58. Gerszten PC, Albright AL, Barry MJ. Effect on ambulation of continuous intrathecal baclofen infusion. *Pediatr Neurosurg* 1997;27:40–4.
59. Gormley ME Jr. Management of spasticity in children. Part 2: Oral and intrathecal baclofen. *J Head Trauma Rehabil* 1999;2:207–9.
60. Grabb PA, Guin-Renfroe S, Meythaler JM. Midthoracic catheter placement for intrathecal baclofen administration in children with quadriplegic spasticity. *Neurosurgery* 1999;45:833–7.
61. ITB technical note. The effects of magnetic resonance imaging (MRI) on Medtronic drug infusion systems. Minneapolis: Medtronic Inc., 2000.
62. ITB product monograph. Minneapolis: Medtronic Inc., 1998.
63. Katz R. Management of spasticity. *Am J Phys Med Rehabil* 1988; 67:108–116.
64. Katz RT, Campagnolo DI. Pharmacologic management of spasticity. *Phys Med Rehabil State Art Rev* 1994;8:473–80.
65. Keenan C, Alexander M, Sung I, Miller F, Dabney K. Intrathecal baclofen for treatment of spasticity in children. *Phys Med Rehabil State Art Rev* 2000;12:275–83.
66. Keisswetter H, Schober W. Lioresal in the treatment of neurogenic bladder dysfunction. *Urol Int* 1975;30:63–71.
67. Kofler M, Kronenberg MF, Rifici C, Saltuari L, Bauer G. Epileptic seizures associated with intrathecal baclofen application. *Neurology* 1994; 44:25–7.
68. Krach LE. Pharmacotherapy of spasticity: Oral medications and intrathecal baclofen. *J Child Neurol* 2001;16:31–36.
69. Kroin JS. Intrathecal drug administration, present use and future trends. *Clin Pharmacokinet* 1992;22:319–26.
70. Kroin JS, Ali A, York M, Penn RD. The distribution of medication along the spinal cord after chronic intrathecal administration. *Neurosurgery* 1993;33:226–30.
71. Massagli TL. Spasticity and its management in children. *Phys Med Rehabil Clin N Am* 1991;2:867–89.
72. Meythaler JM, Guin-Renfroe S, Law C, Grabb P, Hadley MN. Continuously infused intrathecal baclofen over 12 months for spastic hypertonia in adolescents and adults with cerebral palsy. *Arch Phys Med Rehabil* 2001;82:155–61.
73. Meythaler JM, Guin-Renfroe S, Grabb P, Hadley MN. Long-term continuously infused intrathecal baclofen for spastic-dystonic hypertonia in traumatic brain injury: 1-year experience. *Arch Phys Med Rehabil* 1999;80:13–9.

74. Miller F. Gait analysis in cerebral palsy. In: Dormans JP, Pellegrino L, eds. *Caring for the Child with Cerebral Palsy*. Need publisher information, 1998:169–191.
75. Muller H, Zierski J, Dralle D. Pharmacokinetics of intrathecal baclofen in spasticity. In: Muller X, Zierski J, Penn RD, eds. *Local-Spinal Therapy of Spasticity*. Berlin: Springer, 1988:223–6.
76. Muller-Schwefe G, Penn RD. Physostigmine in the treatment of intrathecal baclofen overdose. Report of three cases. *J Neurosurg* 1989;71:273–5.
77. Nanninga JB, Frost F, Penn R. Effect of intrathecal baclofen on bladder and sphincter control. *J Urol* 1989;142:101–5.
78. Parise M, Garcia-Larrea L, Sindou M, Mauguiere F. Clinical use of polysynaptic flexion reflexes in the management of spasticity with intrathecal baclofen. *Electroencephalogr Clin Neurophysiol* 1997;105:141–8.
79. Peacock W, Straudt L. Functional outcomes following selective posterior rhizotomy in children with cerebral palsy. *J Neurosurg* 1991;74:380–5.
80. Penn R, Savoy SM, Corcos D, et al. Intrathecal baclofen for severe spinal spasticity. *N Engl J Med* 1989;320:1517–21.
81. Penn RD, Kroin JS. Intrathecal baclofen alleviates spinal cord spasticity. *Lancet* 1984;1:1078.
82. Price GW, Wilkins GP, Turnbull MJ, Bowery NG. Are baclofen-sensitive GABAB receptors present on primary afferent terminals of the spinal cord? *Nature* 1984;307:71–4.
83. Rawlins P. Patient management of cerebral origin spasticity with intrathecal baclofen. *J Neurosci Nurs* 1998;30:32–46.
84. Ried S, Pellegrino L, Albinson-Scull S, Dormans JP. The management of spasticity. In: Dormans JP, Pellegrino L, eds. *Caring for the Child with Cerebral Palsy*. Baltimore: Brookes, 1998:99–123.
85. Rosenson AS, Ali A, Fordham EW, Penn RD. Indium-111 DTPA flow study to evaluate surgically implanted drug pump delivery system. *Clin Nucl Med* 1990;15:154–6.
86. Rymer WZ, Katz RT. Mechanisms of spastic hypertonia. *Phys Med Rehabil State Art Rev* 1994;8:441–54.
87. Sampathkumar P, Scanlon PD, Plevak DJ. Baclofen withdrawal presenting as multi-organ system failure. *J Neurosurg* 1998;88:562–3.
88. Tilton A, Nadell J, Massirer B, Miller M. Intrathecal baclofen therapy for treating severe spasticity in pediatric patient with anoxic brain injury. *Clinical Case Study*. Medtronic Inc., Minneapolis, 1999.
89. Young RR, Delwaide PJ. Drug therapy spasticity (first of two parts). *N Engl J Med* 1981;304(1):28–33.
90. Young RR, Delwaide PJ. Drug therapy spasticity (second of two parts). *New Engl J Med* 1981;304(2):96–9.



SECTION III

Surgical Techniques

Upper Extremity Procedures

1. Shoulder Adductor, Extension, and External Rotator Lengthening

Indication

The indications for shoulder adductor lengthening are usually in a child with a quadriplegic pattern involvement who has a severe shoulder adduction contracture making axillary care and dressing difficult. The primary contracture is usually with internal rotation and adduction coming from the pectoralis. Some children develop shoulder abduction extension and elbow extension during ambulation or while sitting in a wheelchair. Improved cosmesis and fewer problems with injury of the hand can occur with lengthening of the triceps and external rotators.

Procedure

1. An incision is made over the anterior deltopectoral groove. The inferior border of the pectoralis major is identified (Figure S1.1.1).
2. The superior and inferior borders of the pectoralis minor and major are identified and a hemostat is passed underneath these two muscles.
3. Cautery is used and the muscles are transected completely. Abduction then should increase 20° to 30°, sufficient to allow easy access to the axillary region (Figure S1.1.2).
4. If the latissimus dorsi and teres minor are very contracted, a separate posterior incision can be made (Figure S1.1.3) and these can be released as well (Figure S1.1.4).
5. The teres major and minor can also be transected medial to the long head of the triceps. Care has to be taken to avoid injury of the axillary nerve coming up through the quadrilateral space (Figure 1.1.5).
6. The long head of the triceps is then identified distal to the axillary nerve and transected (Figure 1.1.6).
7. The lateral head of the triceps is next defined and transected (Figure 1.1.7).
8. The wounds are closed and no immobilization is utilized.

Postoperative Care

Immediate passive range of motion is started postoperatively.

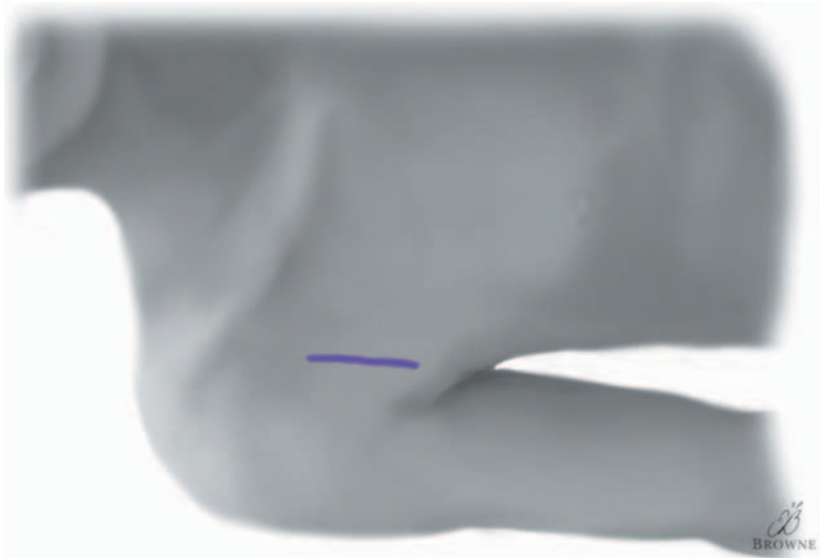


Figure S1.1.1

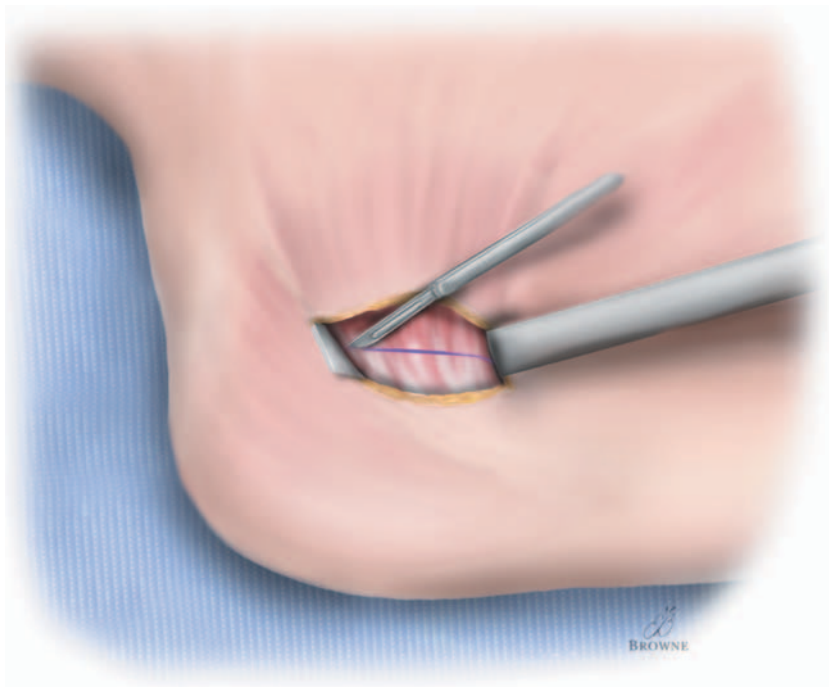


Figure S1.1.2

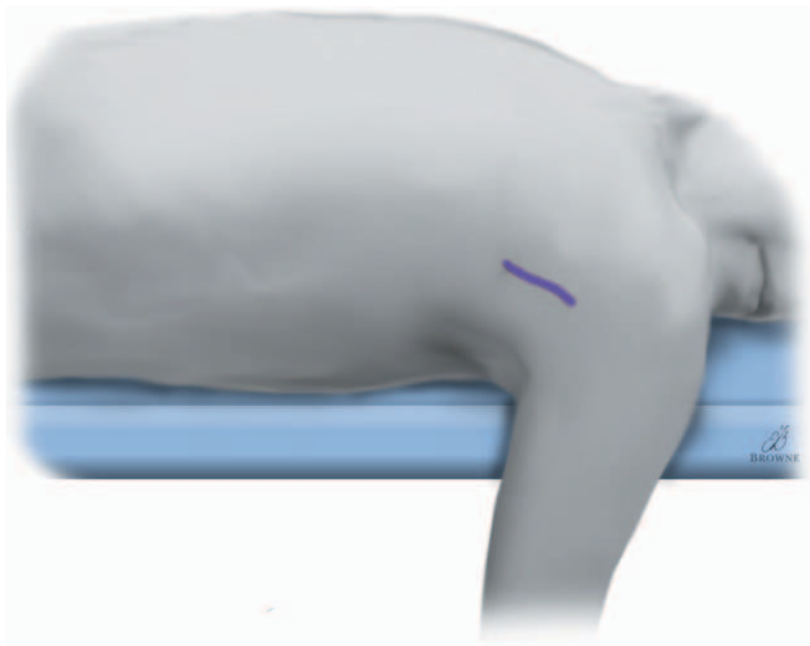


Figure S1.1.3

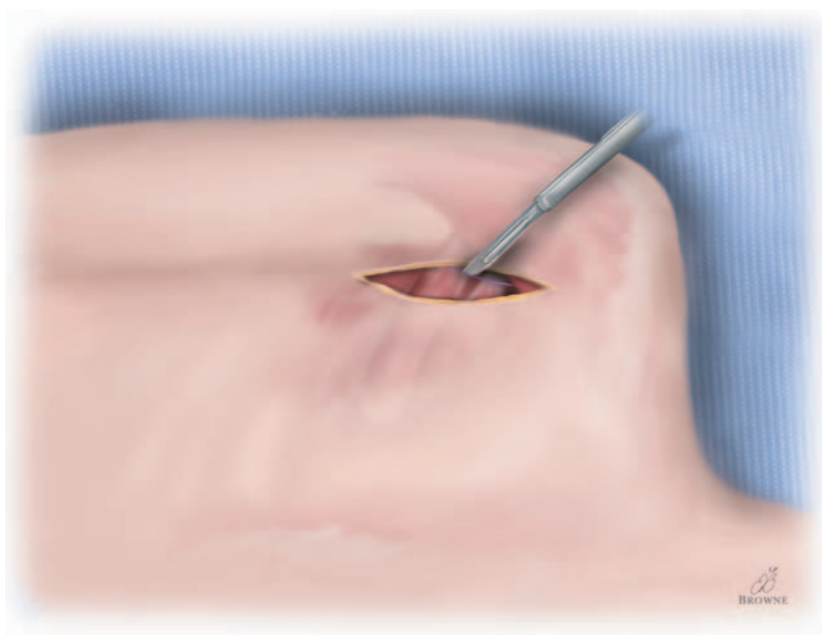


Figure S1.1.4

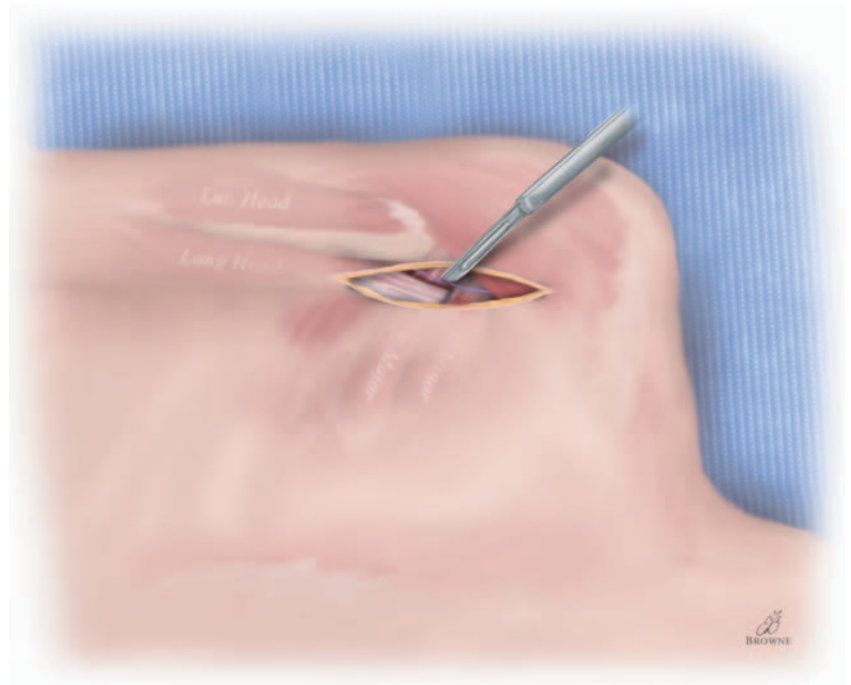


Figure S1.1.5

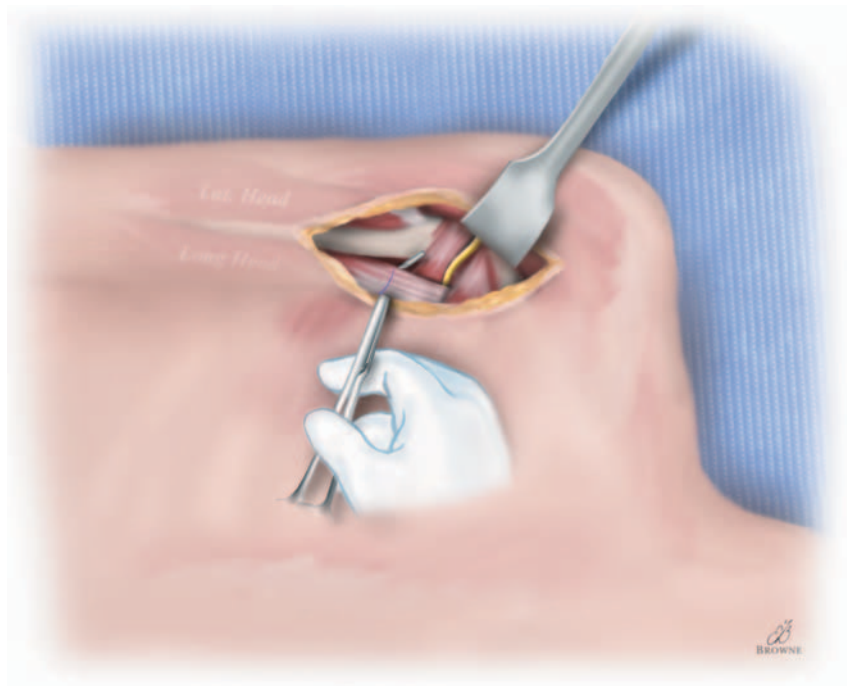


Figure S1.1.6

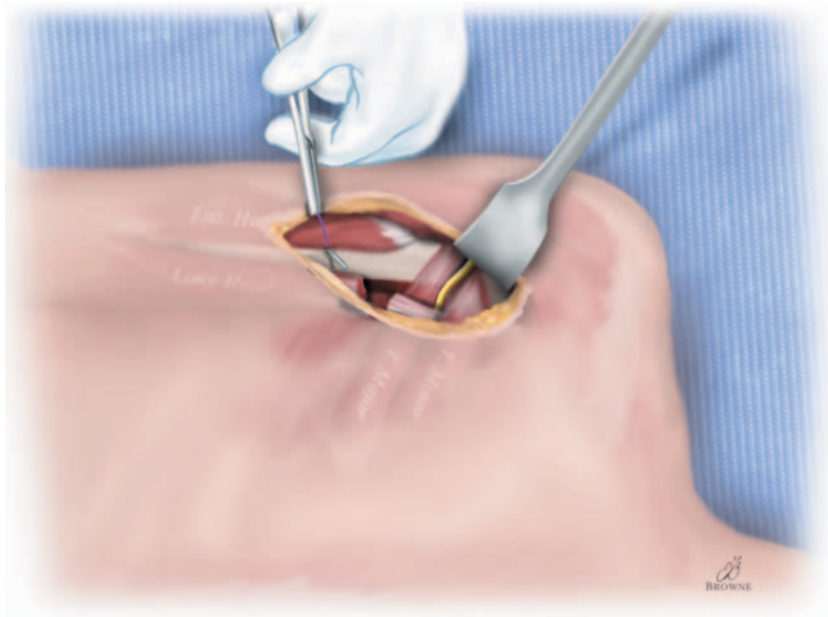


Figure S1.1.7

2. Humeral Derotation Osteotomy

Indication

The indication is usually severe external humeral rotation or severe internal rotation. The most common patterns are children with severe abduction external rotation contractures, which make seating difficult, or the high-functioning child with hemiplegia who has a severe internal rotation contracture.

Procedure

1. Incision is made along the anterior border of the deltoid and carried down to the midarm (Figure S1.2.1). The interval is opened to the humerus with subperiosteal dissection distally but not with elevation of the deltoid insertion into the humerus.
2. An osteotomy with an oscillating saw is made at the level just proximal to the humeral insertion of the deltoid (Figure S1.2.2). If the humerus is to be rotated externally, the plate is placed on the medial surface with a minimum of two holes proximally and three holes distally and, if possible, a six-hole plate should be utilized (Figure S1.2.3). Good compression of the osteotomy is performed (Figure S1.2.4).

Postoperative Care

Immediate postoperative passive range of motion is allowed; however, when the limb is not being ranged, it should be immobilized in a sling for 4 weeks to allow healing to begin.

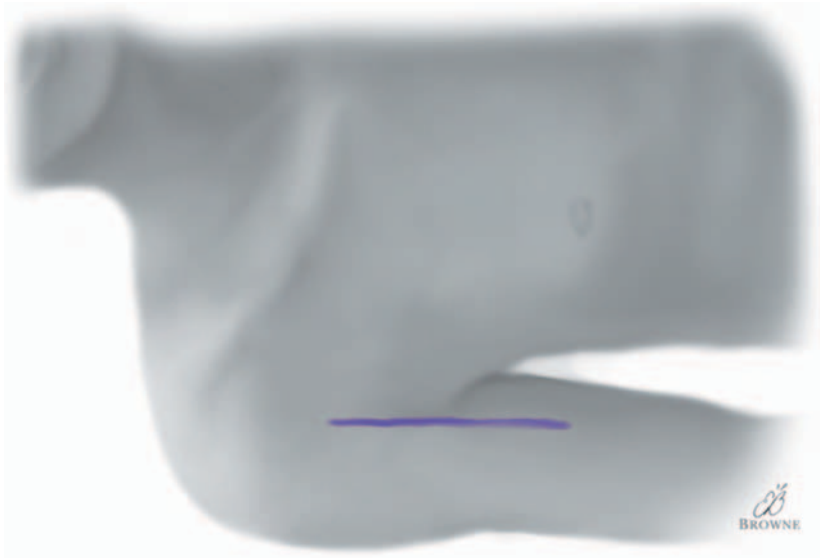


Figure S1.2.1

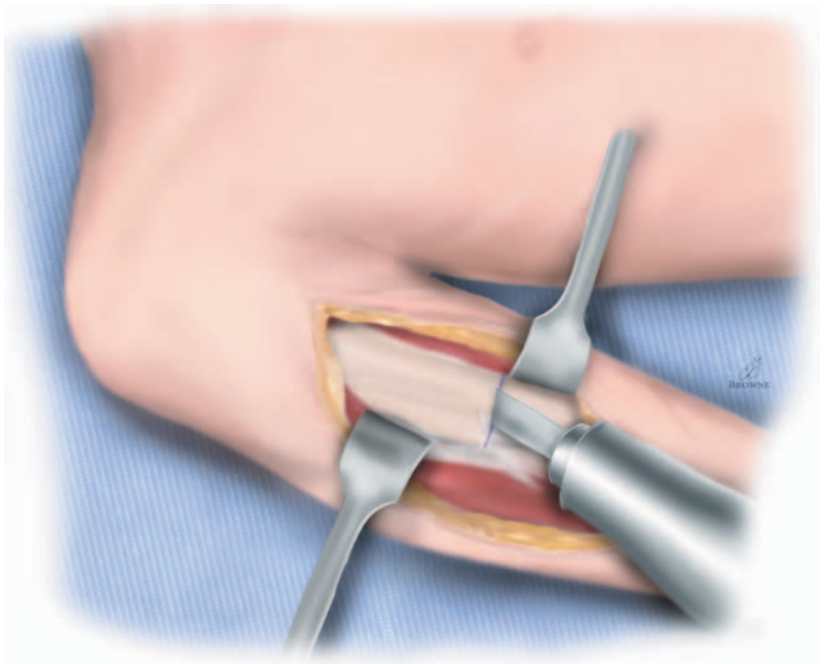


Figure S1.2.2

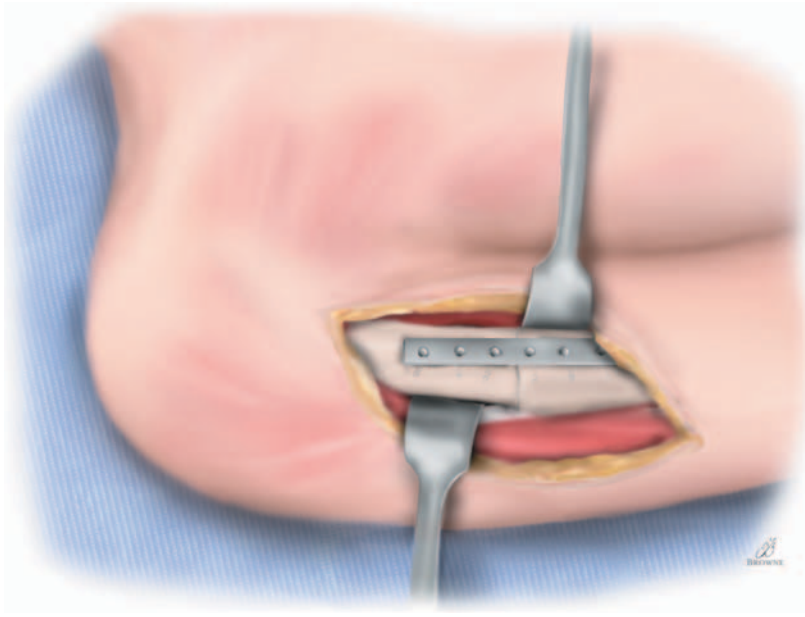


Figure S1.2.3

3. Elbow Flexion Contracture Release

Indication

Elbow flexion contractures are common in both children with hemiplegia and those with quadriplegia. For the child with hemiplegia and a mild contracture, only the biceps is released. If the child has a very functional upper extremity, a Z-lengthening of the biceps tendon may be performed. For the quadriplegic child with a severe contracture, complete transection of the biceps and brachialis is performed with some myofascial lengthening of the brachioradialis.

Procedure

1. Incision is made anterior transverse just proximal to the elbow crease (purple line, Figure S1.3.1). It is carried down to the subcutaneous tissue with spreading and retraction of the subcutaneous veins. If more proximal or distal exposure is needed the incision can be extended in Z-plasty fashion (Figure S1.3.1, blue lines).
2. The tendon of the biceps is palpated and extensively cleaned. Retractors are placed on each side and the tendon is transected (Figure S1.3.2, purple lines). At this point, if it is felt that the arm is extremely functional requiring heavy strength, a Z-lengthening of the tendon can be performed (Figure S1.3.2, green line).
3. For the quadriplegic child with a severe contracture, complete release of the biceps and the majority of the brachialis fascia beneath the biceps is performed as well (Figure S1.3.3). If a significant lateral contracture of the flexor still remains, myofascial lengthening of the lateral mass also can be performed.

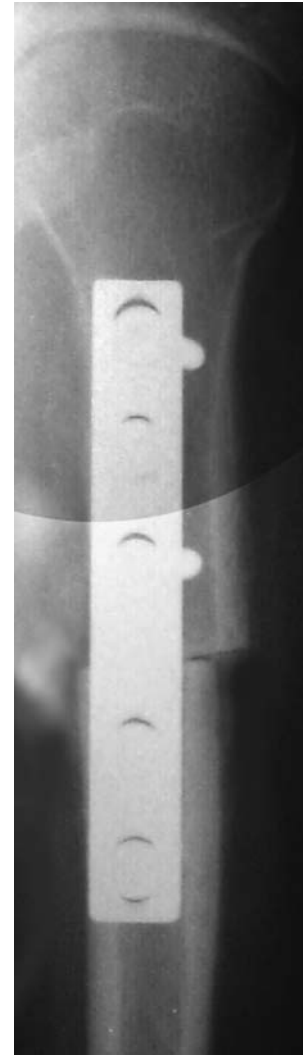


Figure S1.2.4



Figure S1.3.1

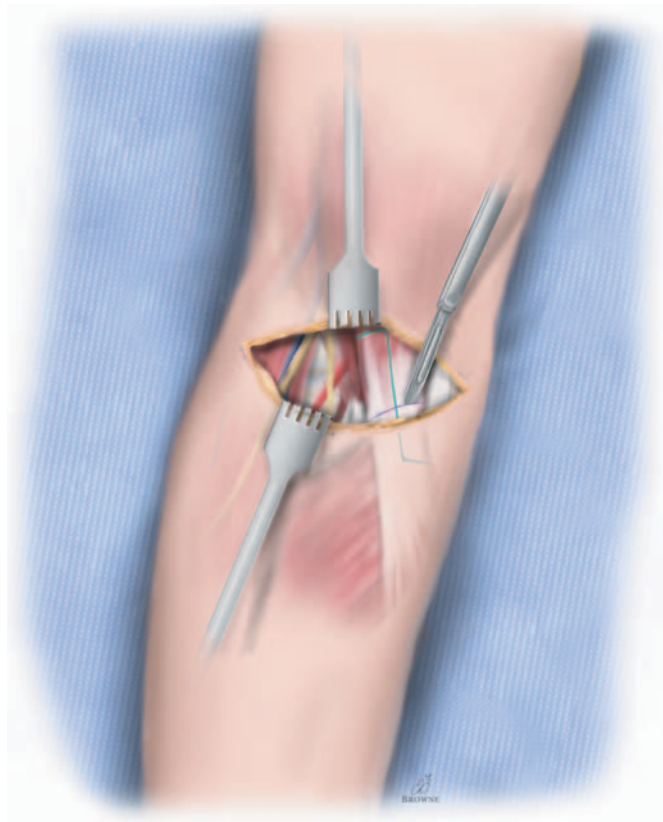


Figure S1.3.2

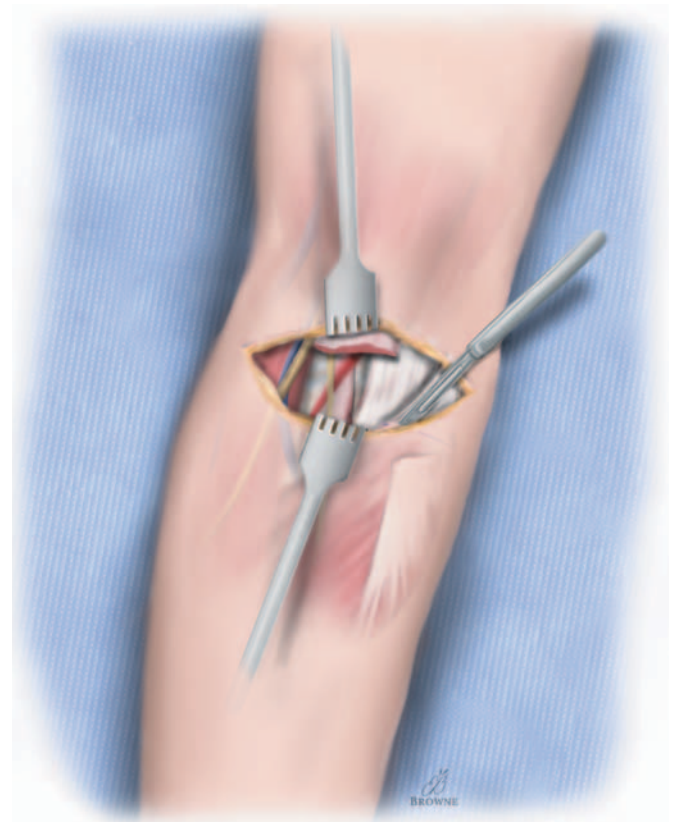


Figure S1.3.3

Postoperative Care

Immediate active range of motion is begun if there is no other indication for the utilization of a cast. If the child also undergoes forearm procedures, the elbow may be immobilized in a cast in approximately 70° to 80° of flexion. Casting is utilized based on the requirements of other procedures, not the elbow tendon lengthening.

4. Pronator Release or Transfer

Indication

Release or transfer of the pronator teres is indicated if there is a significant pronator contracture, usually in the child with a hemiplegic upper extremity. Some children with a quadriplegic pattern with functional forearms also may need a pronator release.

Procedure

1. The incision is made in the midforearm between the brachioradialis and the extensor carpi radialis longus muscles (Figure S1.4.1). The incision is carried through the subcutaneous tissue and the interval between brachioradialis and extensor carpi radialis longus is opened.
2. The radius is identified and the fascia overlying the radius is opened.
3. The pronator teres tendon will be identified, and proximal dissection is extended until the full tendon of the pronator teres can be identified. The pronator teres has a very broad insertion onto the radius.
4. A right-angle clamp is placed around the pronator teres (Figure S1.4.2).
5. If a release is planned, especially for individuals with quadriplegia and for many children with hemiplegia, the tendon is transected and care is taken to make sure that no remnants of the tendon remain attached.
6. If a transfer is indicated, the tendon is released with its underlying periosteum to the distal third–middle third junction of the radius.
7. The tendon of the pronator teres then is passed through the interosseous membrane, wrapped around the radius distally in the opposite direction (Figure S1.4.3), and sutured into the periosteum or a single drillhole placed in the distal radius with a stay suture tied to a suture anchor (Figure S1.4.4).
8. Care should be taken to avoid major bicortical drillholes because of the risk of fracture.

Postoperative Care

The forearm is immobilized in full supination in a long-arm cast for 4 weeks. Postoperative treatment includes range of motion after cast removal, which can occur as early as 2 weeks if no other procedures were performed.

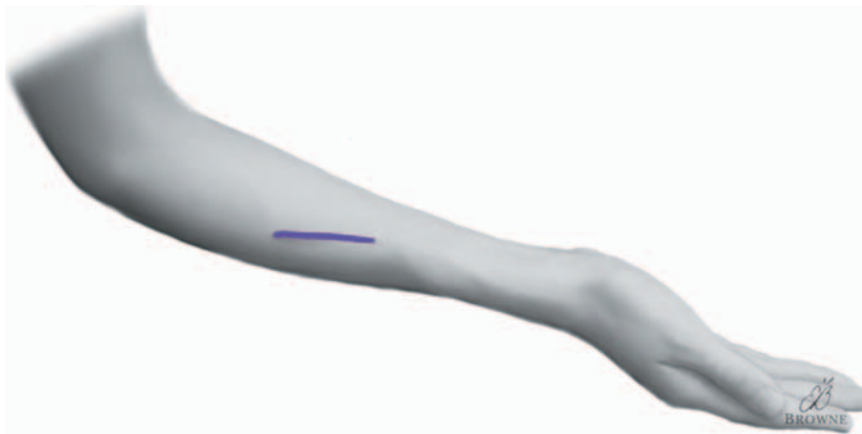


Figure S1.4.1

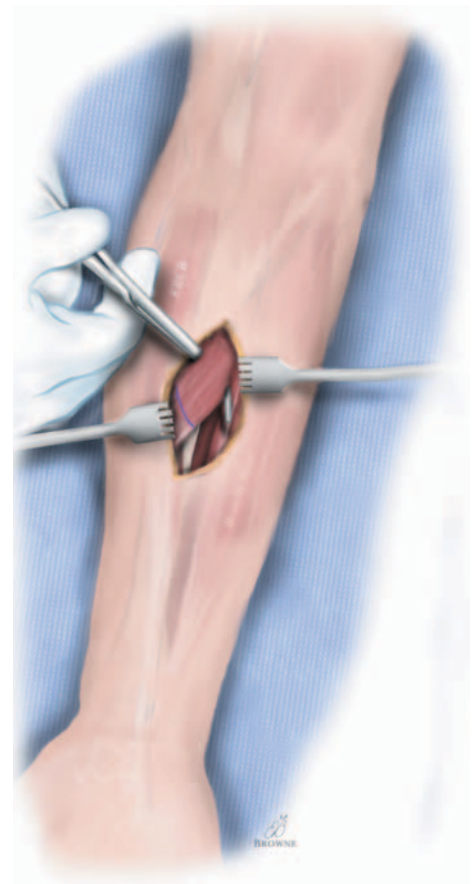


Figure S1.4.2

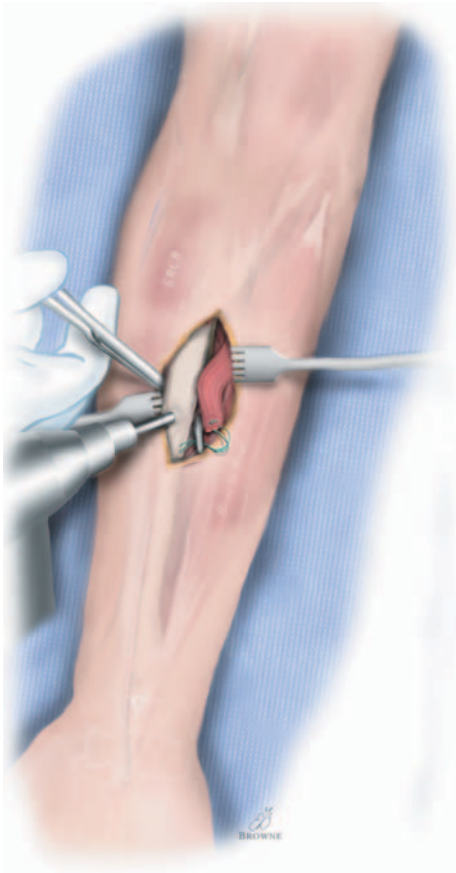


Figure S1.4.3

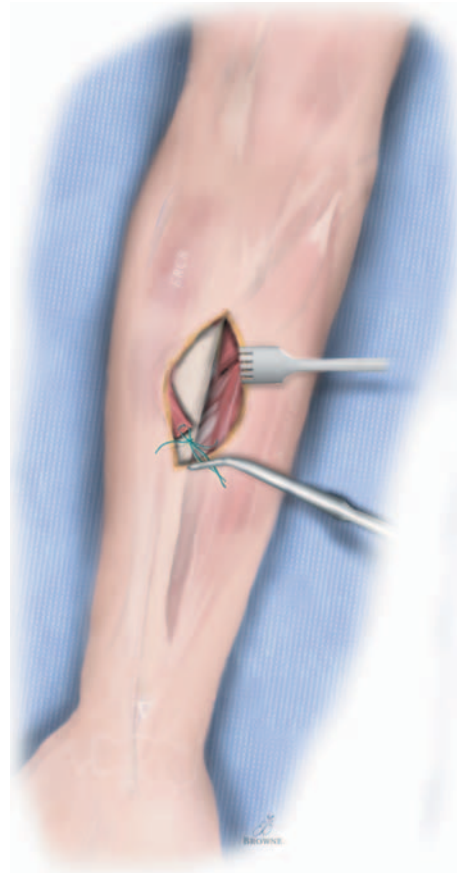


Figure S1.4.4

5. Flexor Carpi Ulnaris Transfer for Wrist Flexion Deformity

Indication

Wrist flexion, often combined with ulnar deviation, is a common contracture. Flexion of the fingers may be present as well. Transfer of the flexor carpi ulnaris is indicated when there is dynamic wrist flexion contracture and when there is a wrist flexion contracture with a fixed contracture on the ulnar side. This procedure may be combined with lengthenings of the extensor carpi ulnaris if there is significant ulnar deviation, or lengthening of the flexor carpi radialis if there is significant fixed wrist flexion contracture after detachment.

Procedure

1. The incision is made across the wrist crease along the flexor carpi ulnaris (Figure S1.5.1) and then may be extended across the forearm in a lazy S fashion, dependent on whether finger flexor lengthenings are indicated (Figure S1.5.2). The tendon border of the flexor carpi ulnaris is identified and freed of its fascial and muscle attachments in the distal 6-cm segment. The tendon is detached as far distally as possible off the carpal bones, being careful to protect the ulnar nerve

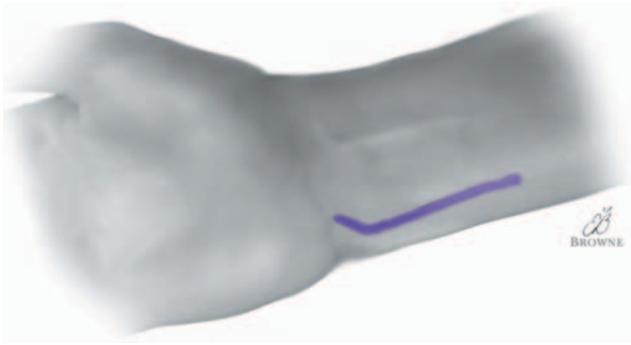


Figure S1.5.1

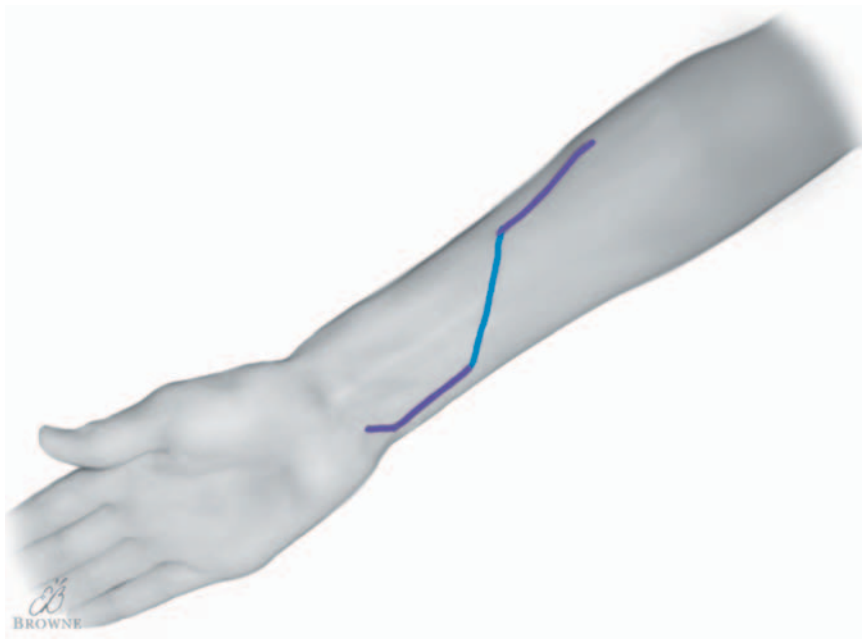


Figure S1.5.2

on the deep and thenar side of the tendon (Figure S1.5.3). It is next stripped using a surgical finger or another instrument so its fascia is stripped at least to midforearm. A suture is placed in the end of the tendon.

2. At this time, the wrist should easily dorsiflex passively to 20° or 30°, and if this is not possible, the flexor carpi radialis is identified and a myofascial or Z-lengthening is performed based on how much dorsiflexion is needed. Usually, a Z-lengthening is required because the muscle often is very short and the tendon very long. Flexor carpi radialis lengthening is only required in wrists with severe flexion contractures (Figure S1.5.4).
3. An incision is made in the dorsum of the wrist from distal on the radial side to slightly proximal on the ulnar side (Figure S1.5.5).
4. If the goal is to transfer the tendon into the extensor carpi radialis longus or brevis, these tendons are exposed to their insertion distally, freeing the extensor hallucis longus. If the goal is to transfer the FCU into the finger extensors, the finger extensors are identified at their common dorsal wrist compartment.

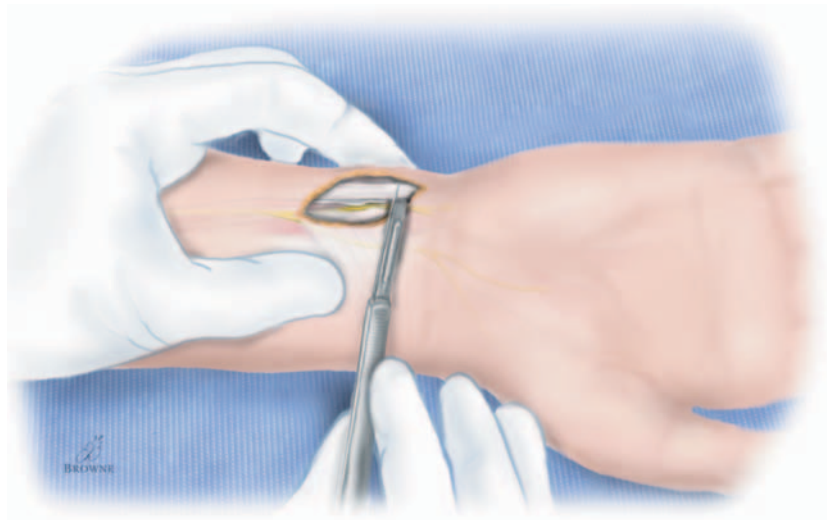


Figure S1.5.3

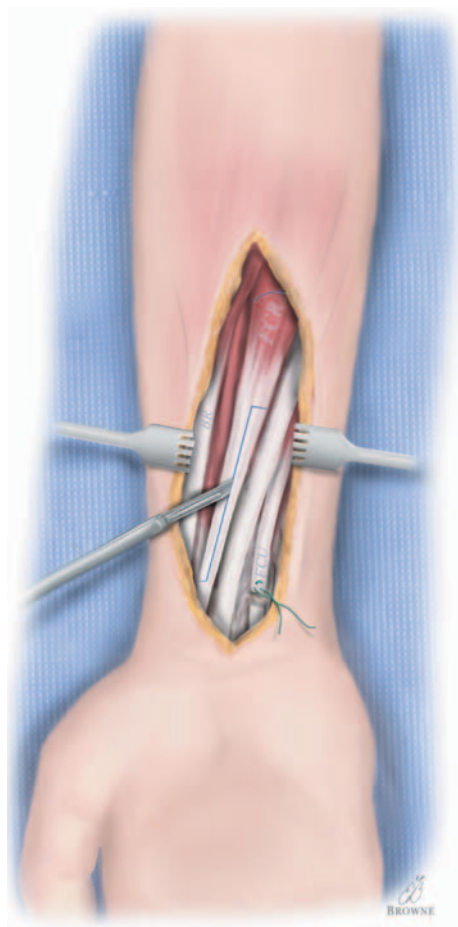


Figure S1.5.4

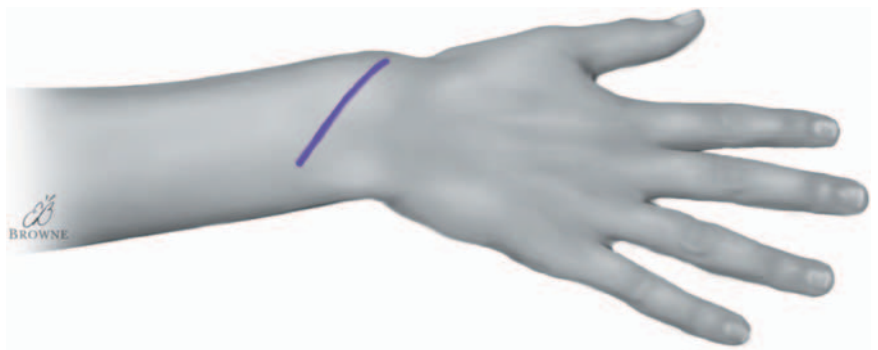


Figure S1.5.5

5. A tendon passer is passed through the subcutaneous tissue from dorsal to volar, and the tendon is grasped and pulled into the dorsal wound, which should provide easy and sufficient tendon length. Care should be taken to make sure that the muscle is pulled in a gentle curve and a sharp bend is not made in the subcutaneous tissue at midforearm (Figure S1.5.6). Attention then is directed back to the volar area where further lengthenings are performed if indicated.
6. With the wrist in 20° to 30° of dorsiflexion, if there is full passive finger extension, no finger flexor lengthenings are indicated. If the fingers are unable to extend with the wrist in 20° of dorsiflexion, especially if they lack more than 40° or 50° coming to extension, lengthenings of the finger flexors should be performed.
7. Usually, the primary contracted finger flexor is the flexor digitorum superficialis, which then is exposed by extending the incision across the muscle belly in the midforearm, aiming toward the incision of the pronator release. The flexor muscles are identified and, if good muscle mass is present and the finger flexion contractures are not severe, myofascial lengthenings are performed. Myofascial lengthenings of all the flexor digitorum superficialis muscles usually are required (Figure S1.5.7).

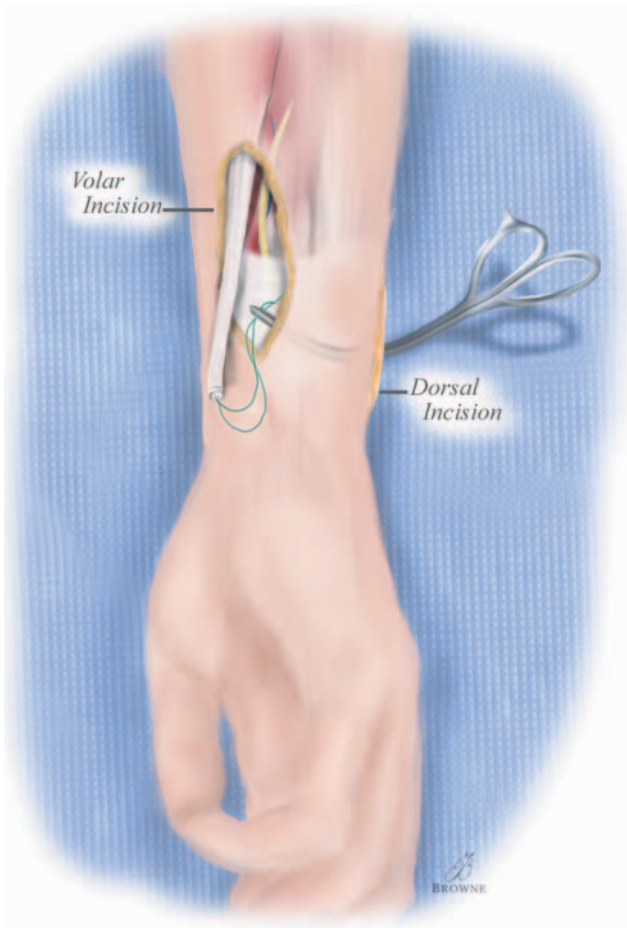


Figure S1.5.6

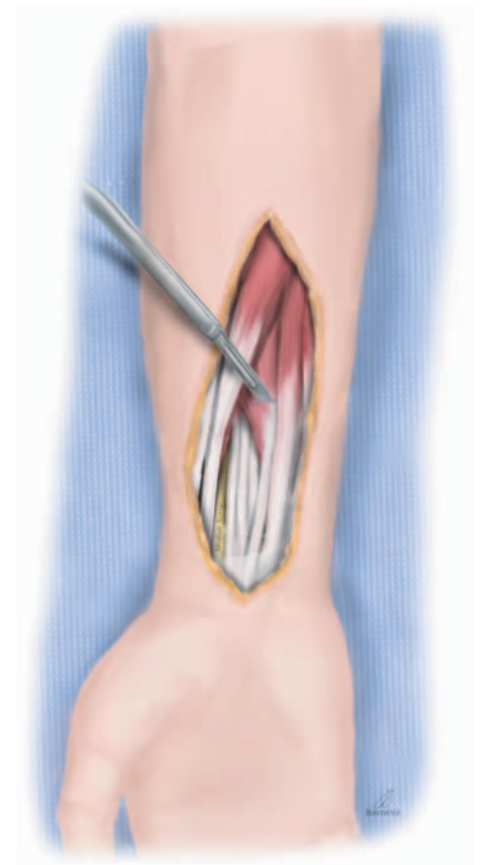


Figure S1.5.7

8. If the finger flexion contractures are quite severe, then the tendons of the flexor digitorum superficialis are identified and the tendons of the index and long finger (Figure S1.5.8, group A) are sutured together as far distally as possible and proximally at the level of their muscle bellies. The tendons of the ring finger and little finger (Figure S1.5.8, group B) similarly are sutured together. The tendons then are transected, one distal and one proximal, which allows a Z-lengthening of the combined motor units to the index and long finger and the ring and little fingers. Sufficient lengthening is provided to allow finger extension (Figure S1.5.9).
9. Following flexor digitorum superficialis lengthening, if there is still significant contracture present, the flexor digitorum profundus tendon and muscle are identified and, for moderate contractures, a myofascial lengthening can be performed. If a severe lengthening is required, a similar combined Z-lengthening is performed.
10. With the wrist extended 20°, the thumb should be extended, and if it is unable to fully extend at neutral abduction and the flexor pollicis longus is very tight, a myofascial lengthening of the flexor pollicis longus usually is sufficient and can be performed through the same incision. For severe contractures in which the muscle belly is short, a Z-lengthening should be performed (Figure S1.5.10).

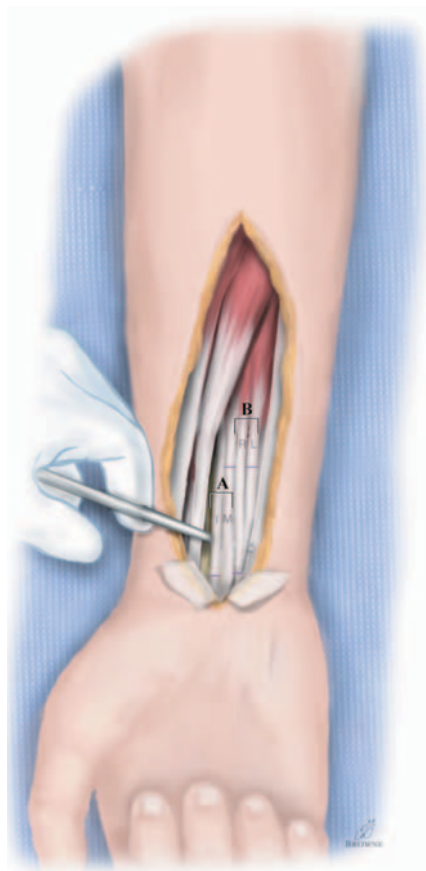


Figure S1.5.8

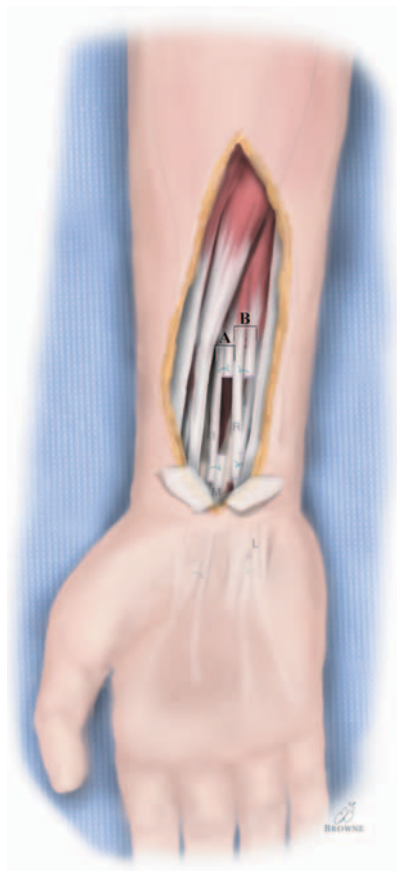


Figure S1.5.9

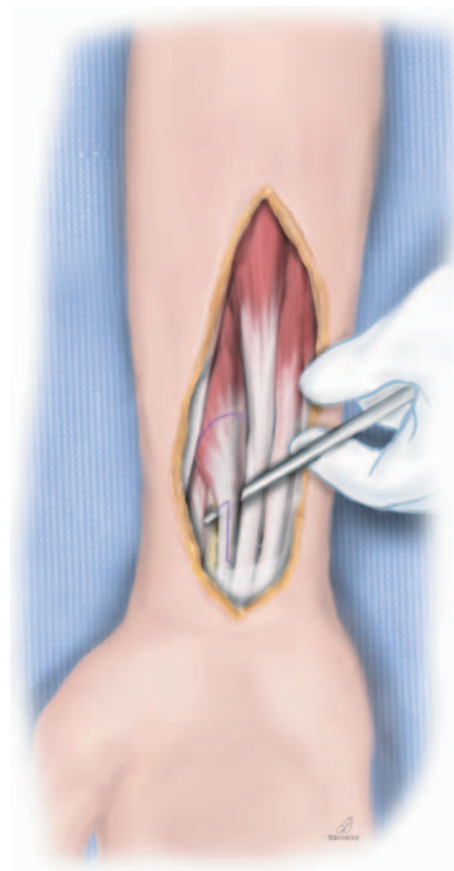


Figure S1.5.10

11. If additional procedures of the thumb or fingers are required, these next should be performed before the tendon transfer is completed. However, the description of this procedure will presume that this has been done or is not needed. The volar wounds are all closed in the appropriate fashion. Attention is directed to the dorsum, where the tendon has had a Kessler suture placed through its end and can be drawn into the wound (Figure S1.5.11). The tendon is woven with a Pulvertaft weave through the tendon to which it is intended to be transferred (Figure S1.5.12). The tension is increased until the wrist is at 20° to a maximum of 30° of extension and the tendons are sutured together (Figure S1.5.13). Following a provisional fixation with one or two sutures, tension is relaxed and the wrist should stay in dorsiflexion of 10° to 30° when the wrist is not supported. If the wrist drops into flexion, the tendon repair has to be taken down, the wrist further dorsiflexed, and the tension of the tendon transfer increased. If the dorsiflexion is more than 30° , the tendon should be relaxed to prevent a hyperdorsiflexion deformity. Suturing of the tendon is completed. The wound is closed.

Postoperative Care

A forearm cast is applied with the wrist in 30° of dorsiflexion and the finger metacarpal phalangeal joints extended to neutral and interphalangeal joints flexed to 45° . The fingers should be incorporated in the cast to the fingertips

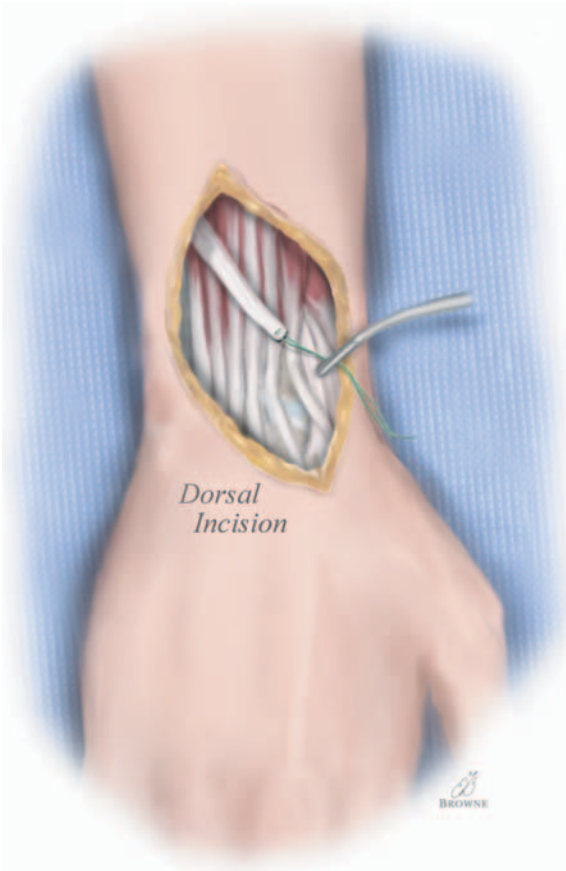


Figure S1.5.11

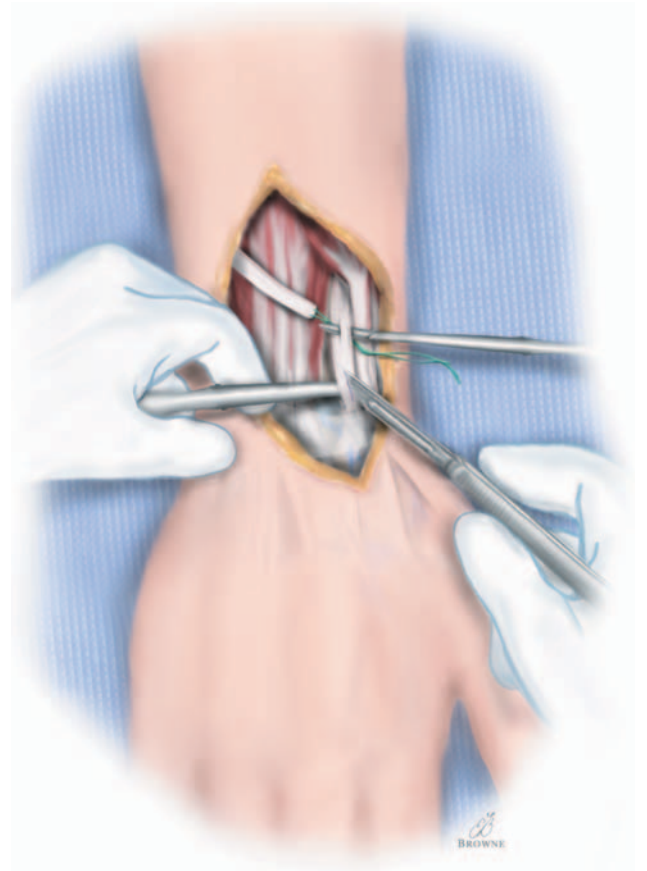


Figure S1.5.12

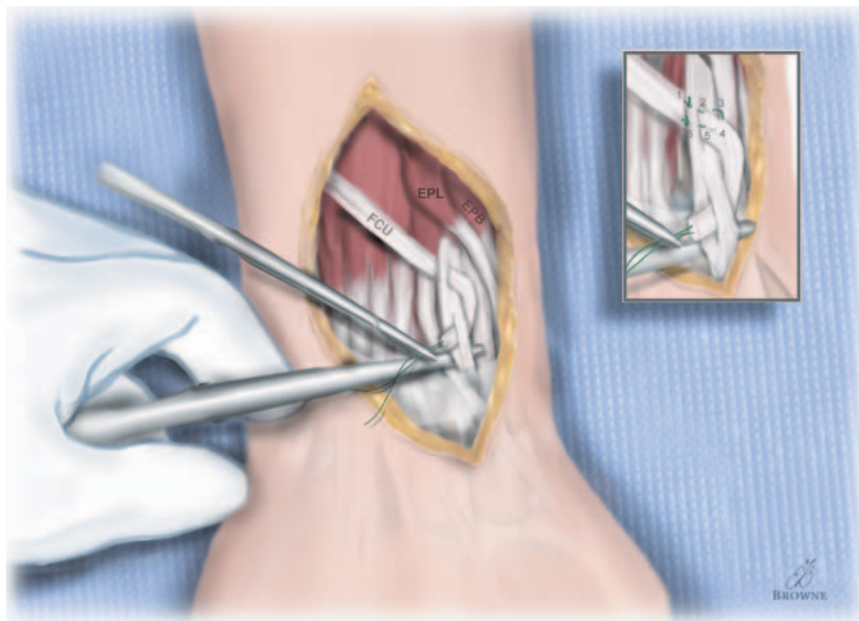


Figure S1.5.13

with the appropriate flexion as noted. The thumb should be in abduction and slightly flexed, especially avoiding hyperextension of the metacarpal phalangeal joint of the thumb and fingers. Four weeks of immobilization in a cast is required, then the cast is removed and a dorsal or volar wrist extension splint is worn 24 hours per day for an additional 4 to 8 weeks, with the splint being removed for gentle active range of motion and bathing only. Following this, the splint is gradually removed as strength is increased.

6. Proximal Row Carpectomy and/or Wrist Fusion

Indication

The indication is primarily in individuals with nonfunctional upper extremities and severe flexion deformities. Wrist fusion is to be avoided in any extremity with substantial function, especially in hemiplegics; however, wrist carpectomy or fusion should be considered only in older individuals or those with no function.

Procedure

1. The incision is made over the dorsum of the wrist extended to the metacarpal base and proximally 2 to 3 cm past the wrist joint. All tendon sheaths are opened on the dorsum of the wrist and all extensor tendons are transected (Figure S1.6.1).
2. The proximal row of the carpus is removed, including the whole of the lunate and the proximal half of the navicular. Attempts at wrist dorsiflexion then are performed, and if more bone removal is needed, the bone should continue to be removed from the capitate and navicular, as well as some removal of cartilage and subchondral bone from the distal radius, but do not remove excessive distal radial bone or there will be very little fusion area (Figure S1.6.2).
3. Once the wrist can be extended to 10° to 20°, there should be only minimal finger flexor tightness and little to no wrist flexor tightness. Bone is removed until at least the wrist flexor tightness is mostly removed. The wrist then is fixed with either a dorsally based plate from the third metacarpal to the radius (Figures S1.6.3, S1.6.4) or, which is usually easier to use, two Steinmann pins through the base of the third

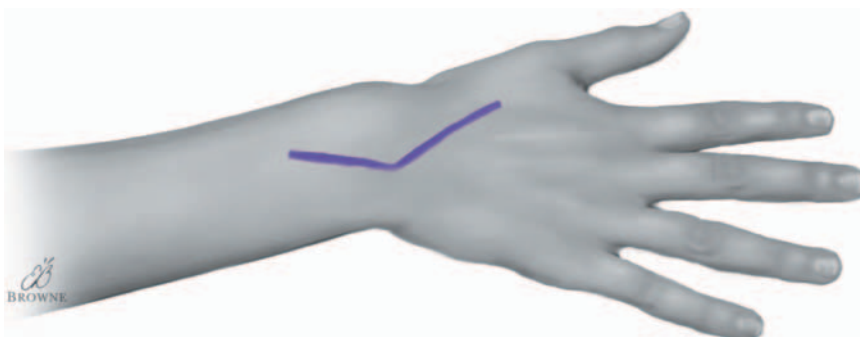


Figure S1.6.1

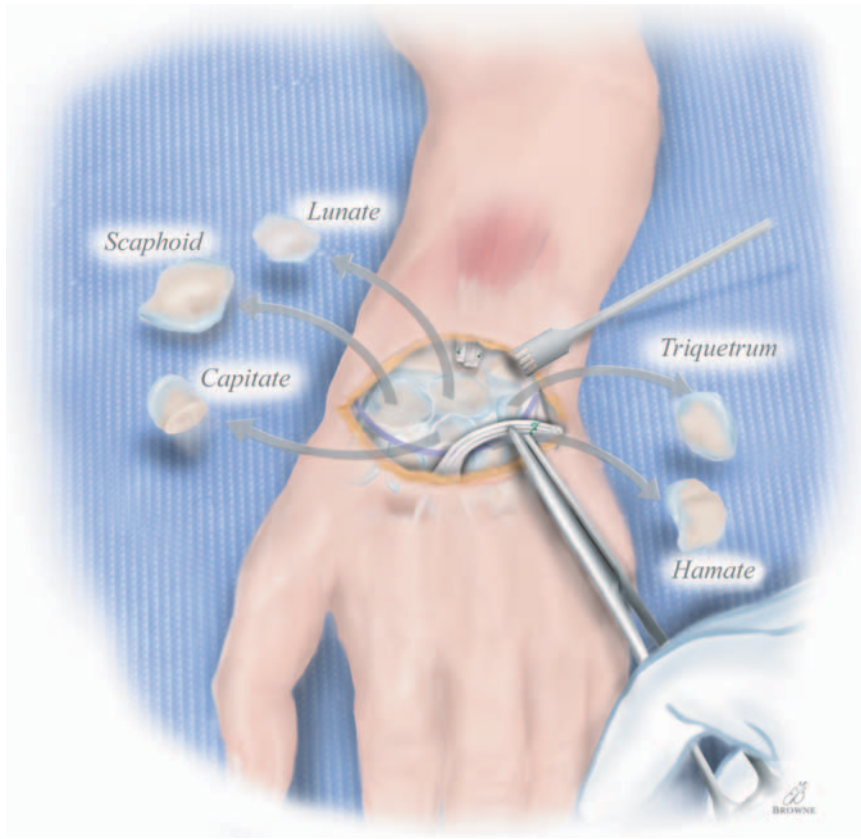


Figure S1.6.2

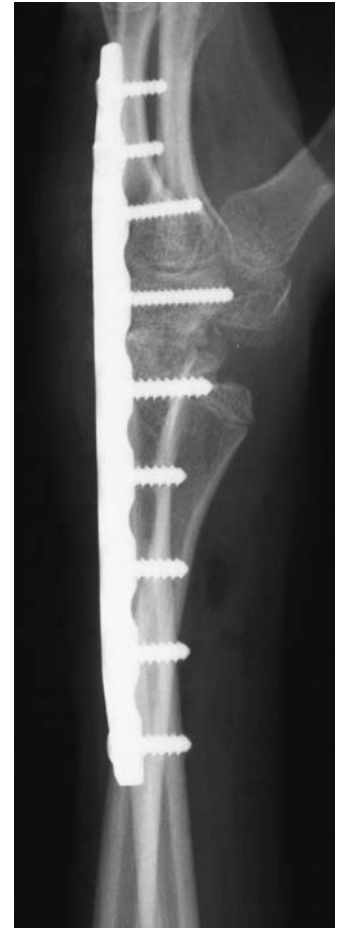

Figure S1.6.3

metacarpal and then one transversely across the wrist joint (Figures S1.6.5, S1.6.6). The dorsal extensor tendons are plicated and repaired as a group (Figure S1.6.7). Because of limited function in the individuals who are indicated to have wrist fusion, individual repairs of the tendons are not indicated. The wrist is immobilized in a short-arm cast for 8 to 10 weeks.

4. After the wrist has been reduced and fixed, if the finger flexors are still substantially tight, it is very important that a volar incision is made and a myofascial lengthening or fascial Z-lengthening of the finger flexors is performed. If these finger flexor lengthenings are overlooked, there will be increasing finger flexion contractures with the fingers ending up severely clawed into the palm, preventing proper bathing.

Postoperative Care

After postoperative rehabilitation and cast removal, little therapy is indicated as these are by definition nonfunctional upper extremities in which the operation was done for comfort care, improved ability for dressing, and personal hygiene. Arthrodesis may or may not occur, but the fibrous arthrosis is stable if the finger flexors do not contract and claw the fingers into the palm.

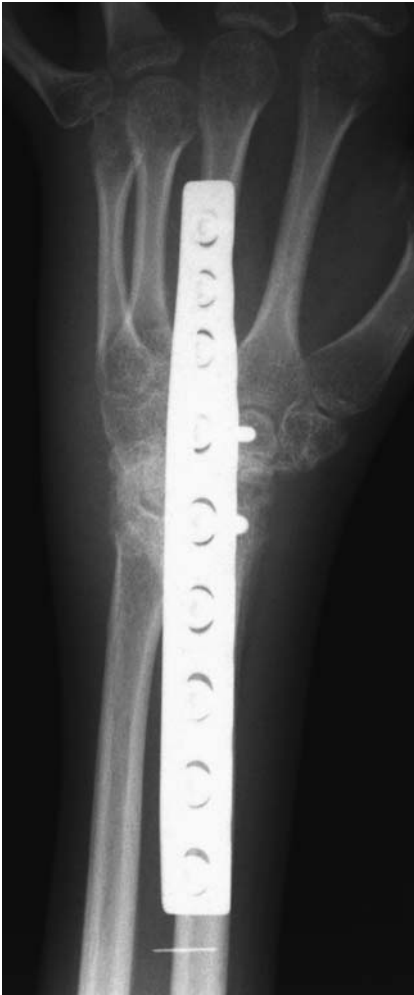

Figure S1.6.4

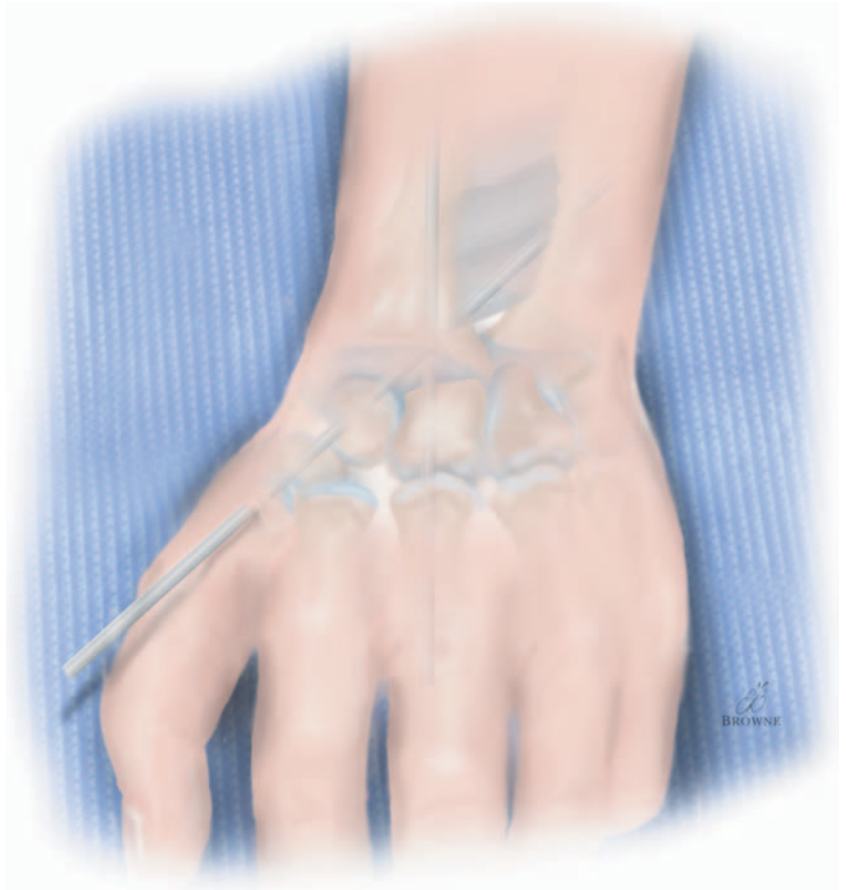

Figure S1.6.5

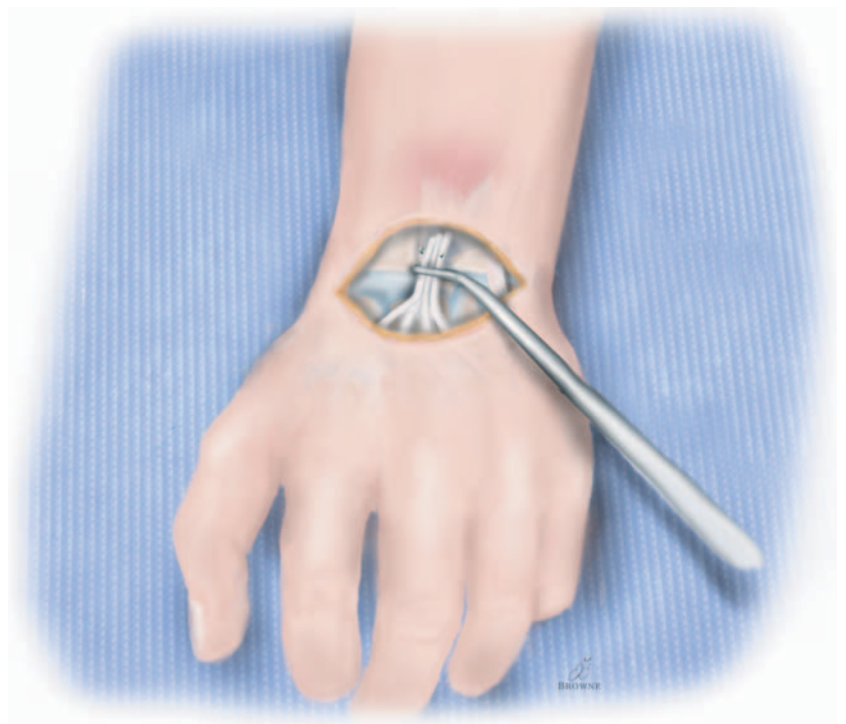

Figure S1.6.7

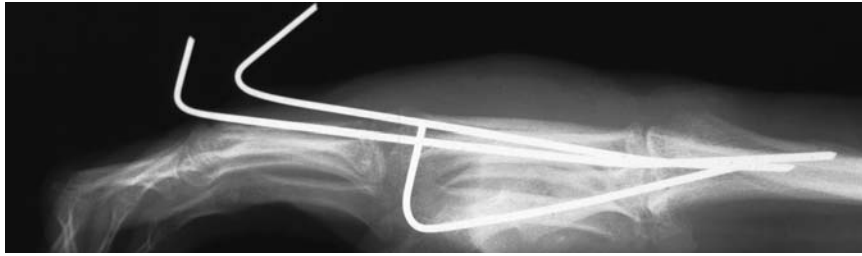


Figure S1.6.6

7. Thumb Adductor Lengthening

Indication

Thumb adductor lengthening, by release of the muscle in midsubstance, is indicated for mild to moderate thumb adduction contractures.

Procedure

1. The incision is made along the distal end of the thenar eminence crease to the transverse palmar crease (Figure S1.7.1).
2. The wound is extended through the palmar fascia between the index and middle finger flexor tendons.
3. Retractors are placed and the transverse muscle fibers of the adductor pollicis origin on the third metacarpal are identified.

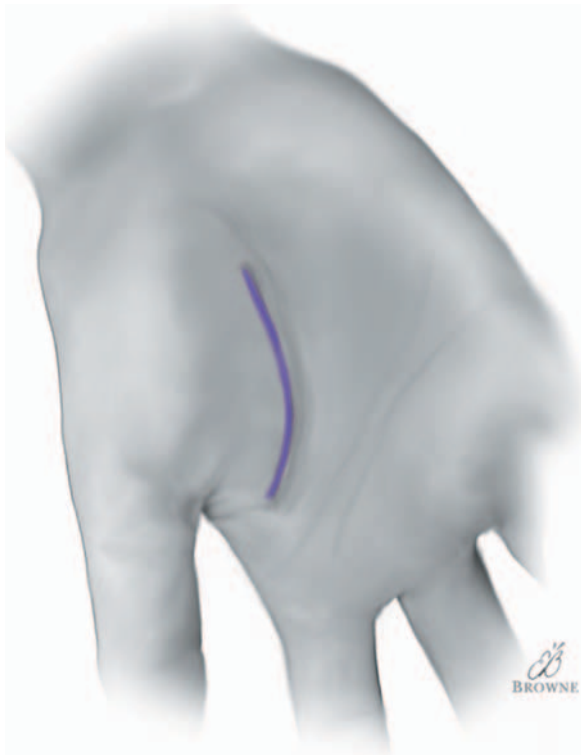

Figure S1.7.1

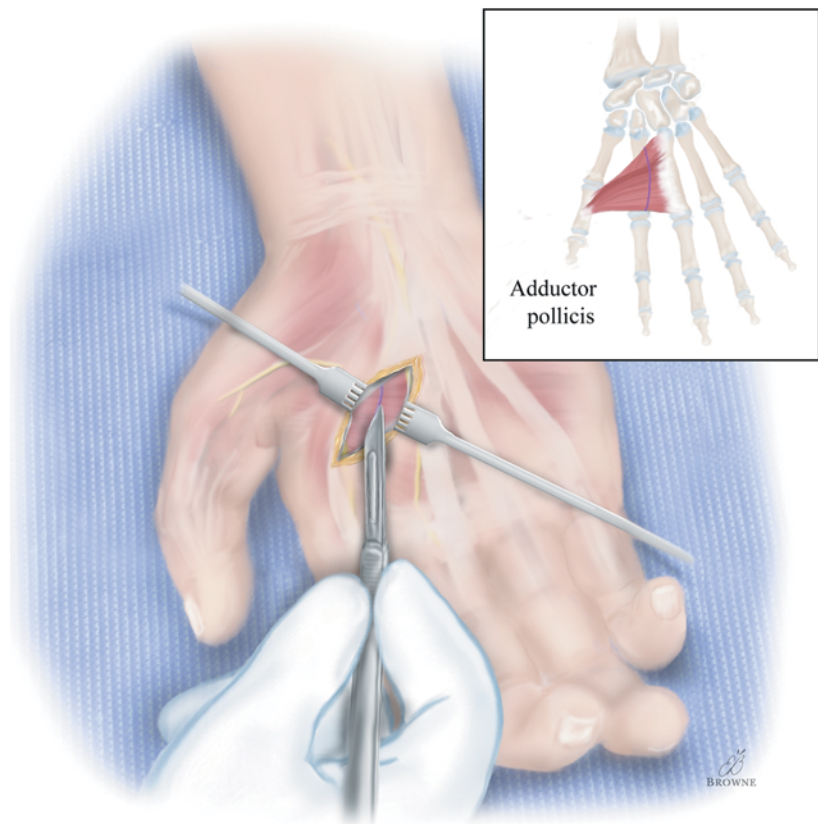


Figure S1.7.2

4. All the transverse muscle fibers of the adductor pollicis are transected, leaving a clean fascial layer below. Care should be taken not to perforate the underlying fascia because the deep palmar arch is located beneath this fascia (Figure S1.7.2).

Postoperative Care

Postoperative management is with the thumb in abduction in the cast for 3 or 4 weeks. Make sure the cast is not producing thumb hyperextension at the MTP joint. After cast removal, thumb abduction splinting at nighttime is usually used for at least 3 weeks. No other treatment is indicated.

8. Webspace Lengthening and Z-Plasty

Indication

Webspace lengthening and Z-plasty are used for severe adduction contractures of the thumb, especially those in which the goal is to get the thumb out of the palm and around large objects. A thumb webspace lengthening with a more aggressive adductor lengthening is indicated. Care has to be taken to avoid excessive lengthening because this will greatly improve thumb abduction at the expense of adduction. If the thumb is abducted enough to hold a drinking glass, almost always lateral key pinch is lost. The relative importance of these functions needs to be individually considered in each child.

Procedure

1. When a moderate amount of length is desired, the simple two-flap Z-plasty is made by making the initial incision along the web of the webspace between thumb and index fingers. The volar incision then is extended 30° to 40° from the distal end proximally, and the dorsal incision is extended from distally to laterally. These flaps are opened (Figure S1.8.1).
2. For more severe contractures in which more length is desired the four-flap Z-plasty should be used. With the four-flap design the incisions are made at 90° at each end then each corner flap is again divided (Figure S1.8.2).
3. The thumb webspace is opened, and the adductor muscle is released from the thumb. The first dorsal interosseous muscle also is released to allow sufficient abduction.
4. The Z-plasty then is reduced and sutured into place.

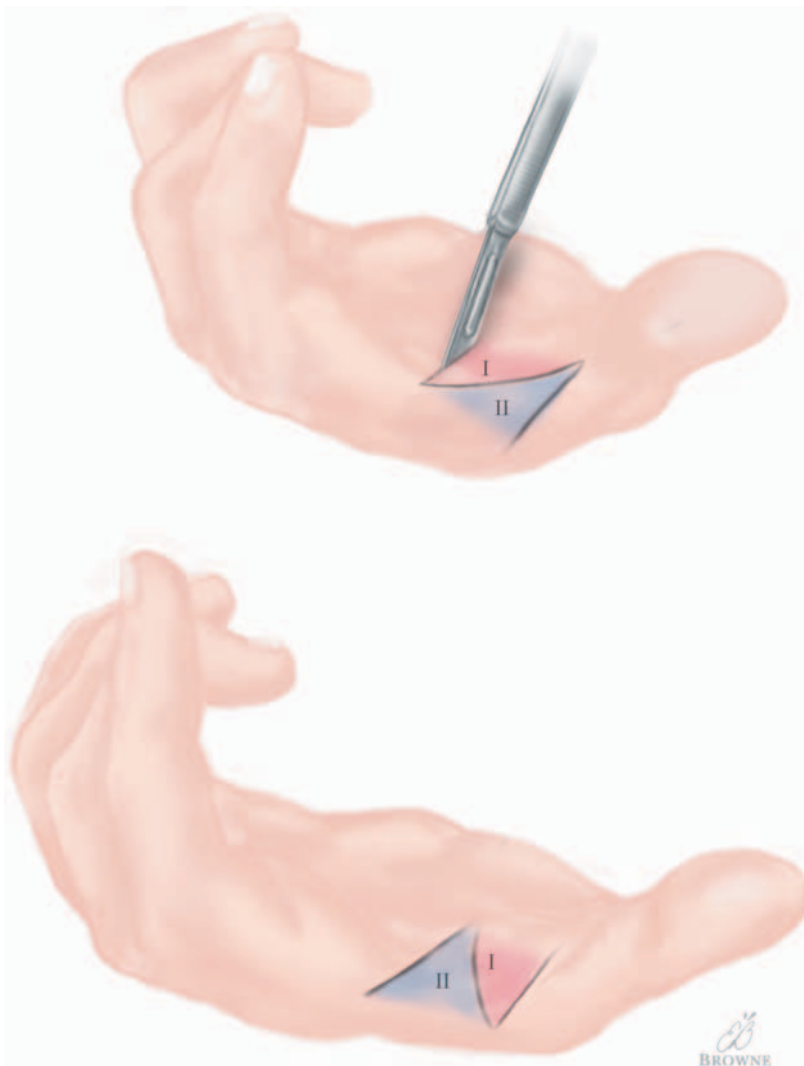


Figure S1.8.1

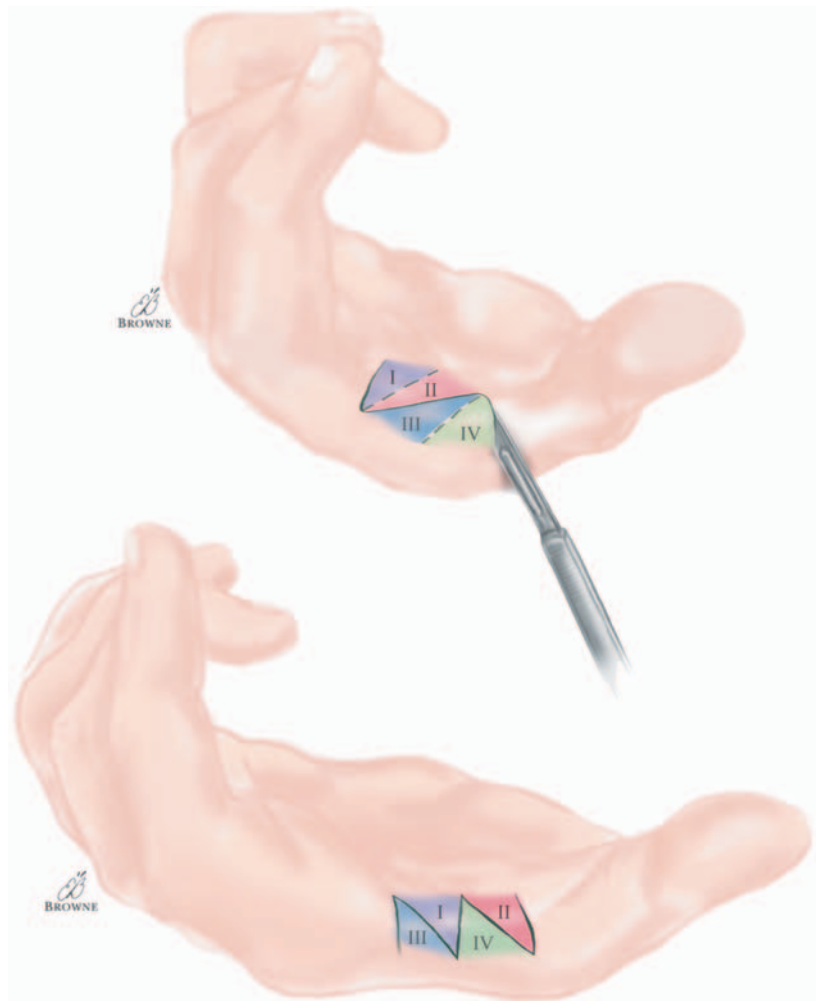


Figure S1.8.2

Postoperative Care

A soft bulky dressing is used for 3 weeks until the wounds are well healed. Therapy is then started, focusing on the functional gains that the child hopes to attain.

9. Metacarpal Phalangeal Joint Fusion of the Thumb

Indication

The indication for the metacarpal phalangeal joint fusion is severe flexion of the metacarpal phalangeal joint or severe extension hypermobility. The most common indication is a House type 4 thumb deformity, also known as a cortical thumb, in which the caretakers have difficulty in keeping the hand clean. This posture leads to sweating in the hand and the development of a very foul odor. Children with functional use of the thumb, but severe MTP hyperextension, are the other indication.




Figure S1.9.1

Procedure

1. The incision is carried in a diagonal fashion across the dorsum of the thumb metacarpal phalangeal joint, transecting the extensor tendon (Figure S1.9.1).
2. The joint is opened and the cartilage is denuded using rongeurs. Crossed K-wires then are used and the thumb is fixed in position (Figure S1.9.2). The position should have approximately 10° to 15° of flexion. Cast immobilization is used usually for 4 to 6 weeks, with the pins left in for the entire time until fusion is demonstrated.

Postoperative Care

Pin removal and cast removal can be performed when the X-ray demonstrates some bridging callus. No splinting or therapy is further required.

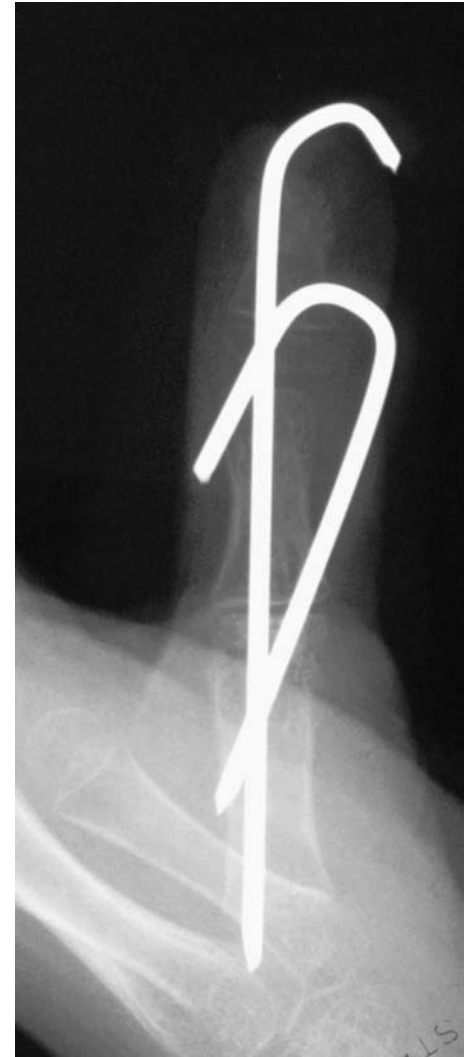


Figure S1.9.2

10. Extensor Pollicis Longus Rerouting

Indication

Rerouting is indicated for active thumb adduction contractures, or those in which there is a lack of thumb abduction and extension; rerouting of the extensor pollicis longus is indicated for moderate deformities.

Procedure

1. The incision is made along the brachial radialis to the base of the metacarpal phalangeal joint of the thumb. The incision is curved over toward the dorsum of the wrist (Figure S1.10.1). If this procedure is combined with the flexor carpi-ulnaris transfer, it can be performed through the dorsal incision with only a slight radial extension on the incision.
2. The extensor pollicis longus tendon is identified and it is removed from its sheath (Figure S1.10.2, POS1) and from the third dorsal wrist

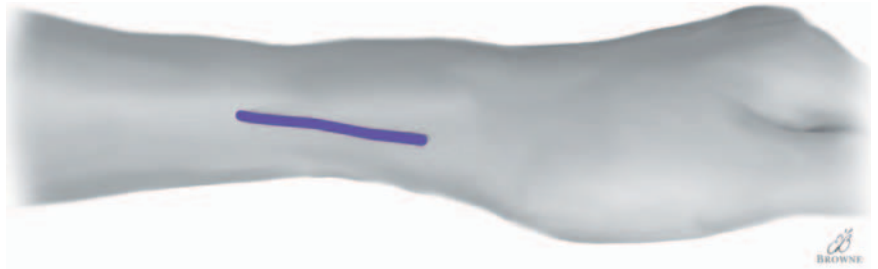


Figure S1.10.1

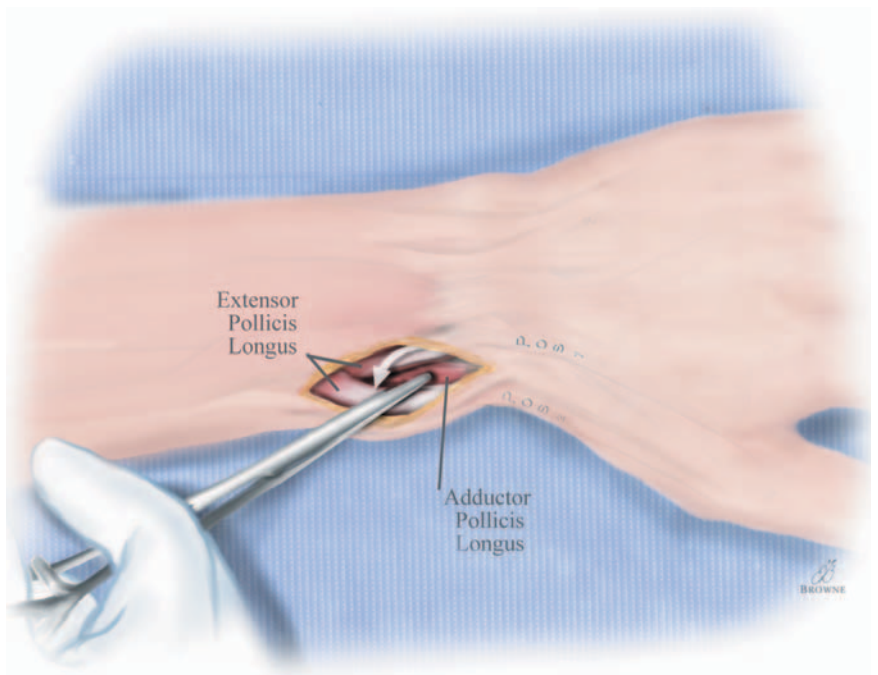


Figure S1.10.2

- compartment. This tendon has to be released into the distal third of the forearm, and so it can be displaced over toward the radial border to be more in line with the adductor pollicis (Figure S1.10.2, POS2).
3. A slip of one half of the adductor pollicis tendon is freed distally (Figure S1.10.3) and used as a pulley by pulling it under the extensor pollicis longus (Figure S1.10.4).
 4. The excised slip is now sutured back on itself around the intact tendon of the extensor pollicis longus, which brings the extensor pollicis longus along a course in parallel with the adductor pollicis (Figure S1.10.5).

Postoperative Care

The thumb is held in an abduction cast for 4 weeks and then is allowed to have full active range of motion.

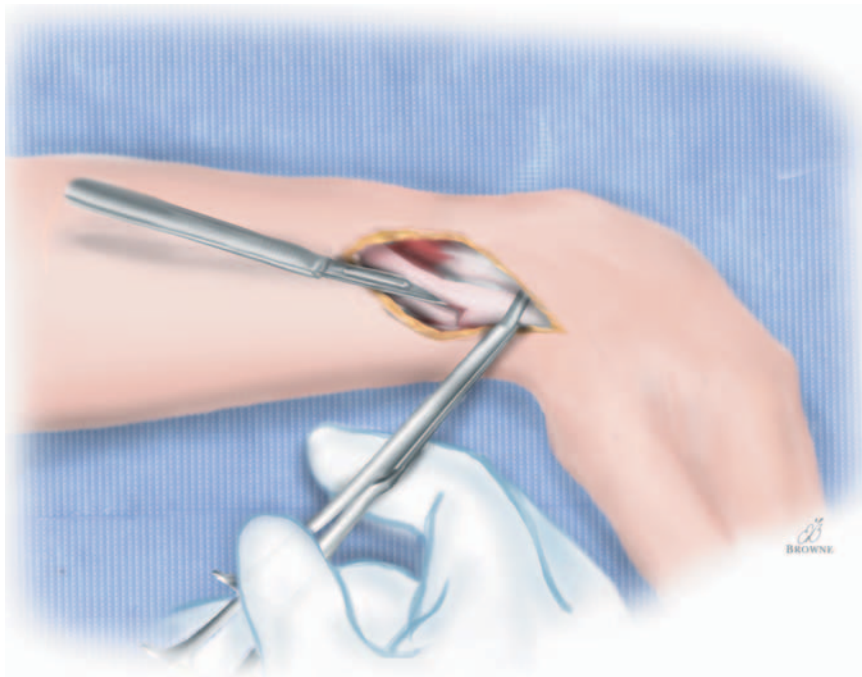


Figure S1.10.3

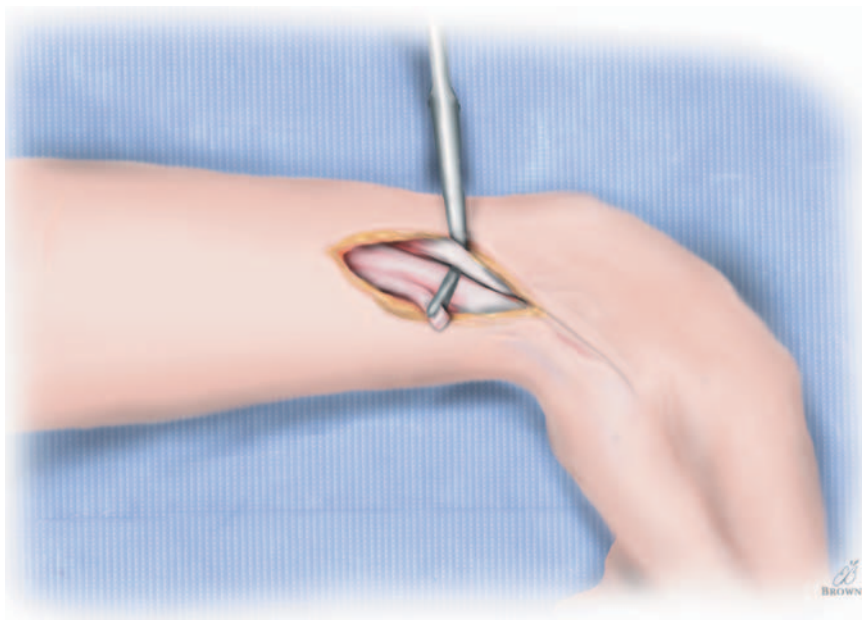


Figure S1.10.4

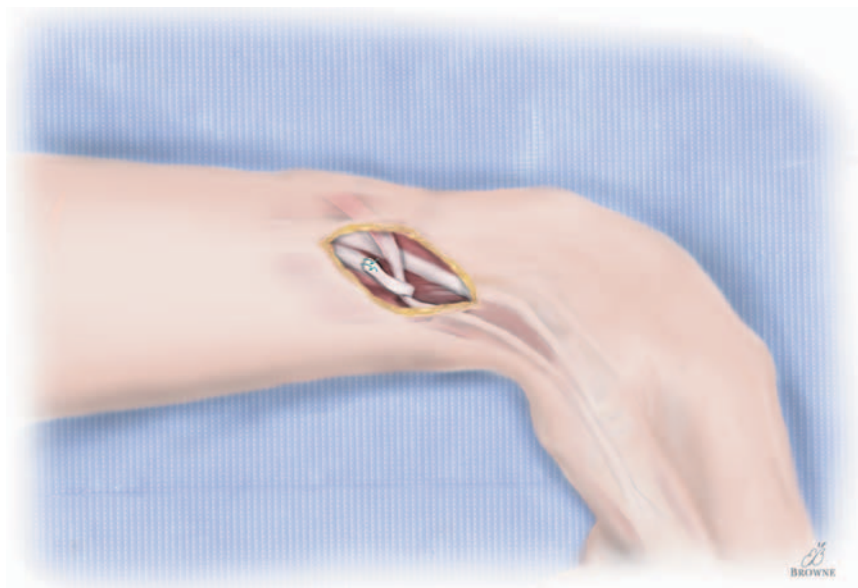


Figure S1.10.5

11. Palmaris Longus or Brachioradialis Transfer to the Abductor Pollicis

Indication

The indication to transfer the palmaris longus or brachioradialis to the abductor pollicis is to augment thumb abduction due to inactive power of a moderate to severe degree.

Procedure

1. If palmaris longus is present, it is released through a superficial wound distal to the palmar crease. The palmaris longus tendon is pulled out through a proximal incision at the midforearm. An incision is made over the distal 2 cm of the abductor pollicis.
2. A tendon passer is utilized and the palmaris longus is passed into the distal wound over the abductor pollicis (Figure S1.11.1).
3. The palmaris longus tendon is woven with a Pulvertaft weave onto the abductor pollicis under maximum tolerable tension (Figure S1.11.2). Alternatively, the brachioradialis may be freed distally from its insertion on the radius, but requires fascial release for at least the distal half of the forearm. Then the brachioradialis is moved over and sutured under tension to the abductor pollicis muscles.
4. Neither the palmaris longus nor the brachioradialis can be transferred easily in such a position that they create too much thumb abduction. However, it is important not to have hyperabduction, but this is more related to doing too aggressive a release of the webspace and the thumb adductors.

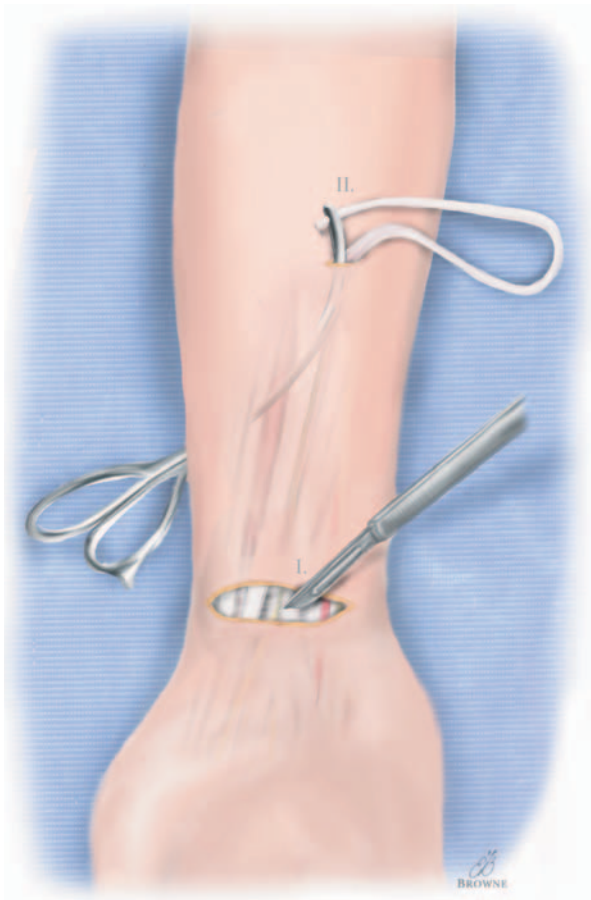


Figure S1.11.1

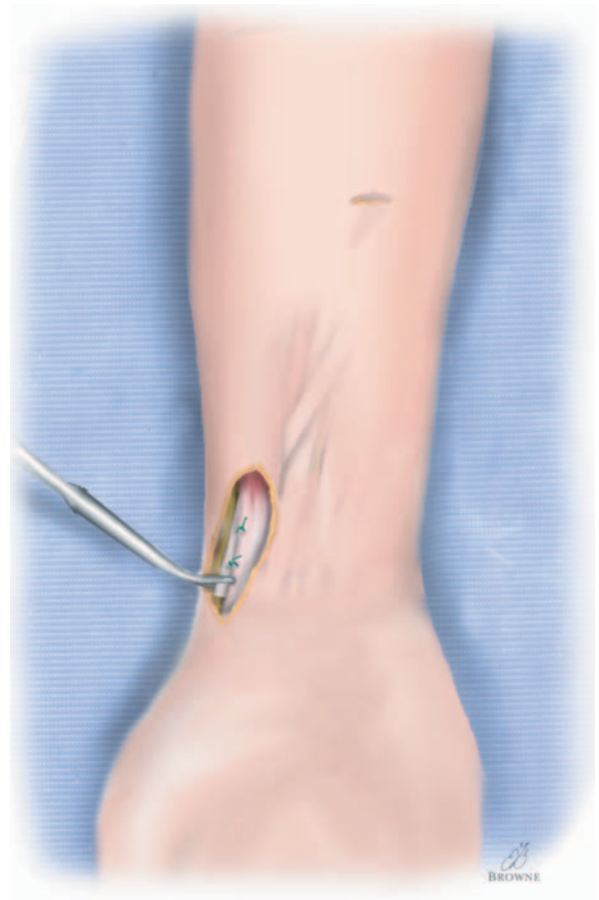


Figure S1.11.2

Postoperative Care

The hand is immobilized in a thumb spica with maximum thumb abduction but avoiding MSP hyperextension. The cast is removed after 4 weeks, and a thumb abduction splint is worn at nighttime for an additional 2 to 4 months.

12. Volar Plate Advancement and Sublimis Slip Reinforcement for Swan Neck Deformity

Indication

Contracted finger flexors with wrist flexion deformity and contracted intrinsic muscles result in hyperextension of the proximal interphalangeal (PIP) joint and flexion of the distal interphalangeal joint to cause a stretching out of the volar capsule at the proximal interphalangeal joint. When the deformities are severe, finger PIP joints get locked in extension and surgical treatment may be indicated. Pain from hyperextension or inability to flex the PIP joint causing functional limitation is the typical direct indication for surgical treatment.

Procedure

1. For moderate deformities, volar capsulodesis and volar plate advancement are the primary treatment. A flexor superficialis tenodesis may be added to this procedure.
2. A midlateral incision is used in the finger, usually extending from the interphalangeal joint to almost the webspace. The incision is carried down dorsally to the neurovascular bundle until the joint and flexor tendon sheath are identified (Figure S1.12.1).
3. A lateral incision is made just anterior to the collateral ligaments; the volar plate is detached from its proximal insertion and the ipsilateral slip of the flexor superficialis muscle is also detached from the distal insertion (Figure S1.12.2).
4. A small hole is drilled through the middle part of the proximal phalanx.
5. A suture is placed through the volar capsule and then passed through a hole drilled in the bone and tied over a button on the dorsal aspect of the finger to advance the volar plate (Figure S1.12.3).
6. This freed half of the flexor digitorum superficialis then is sutured down to the tendon sheath under tension with the finger's proximal interphalangeal joint flexed approximately 30° to 40° (Figure S1.12.3).
7. A single K-wire is driven across the proximal interphalangeal joint to stabilize the joint. It is left in place for 4 weeks.

Postoperative Care

At 4 weeks postoperatively the pins are removed. A splint is made to prevent dorsiflexion and should be worn for another 2 to 4 weeks. Once the splint is removed, there should be no attempt at forceful extension stretching; however, range of motion into PIP joint flexion of the fingers is encouraged.

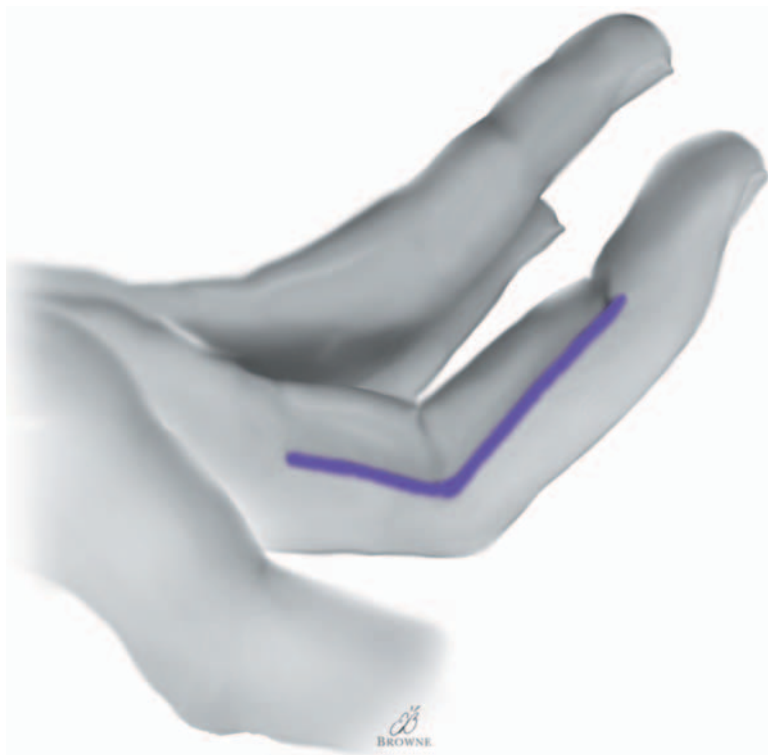

Figure S1.12.1

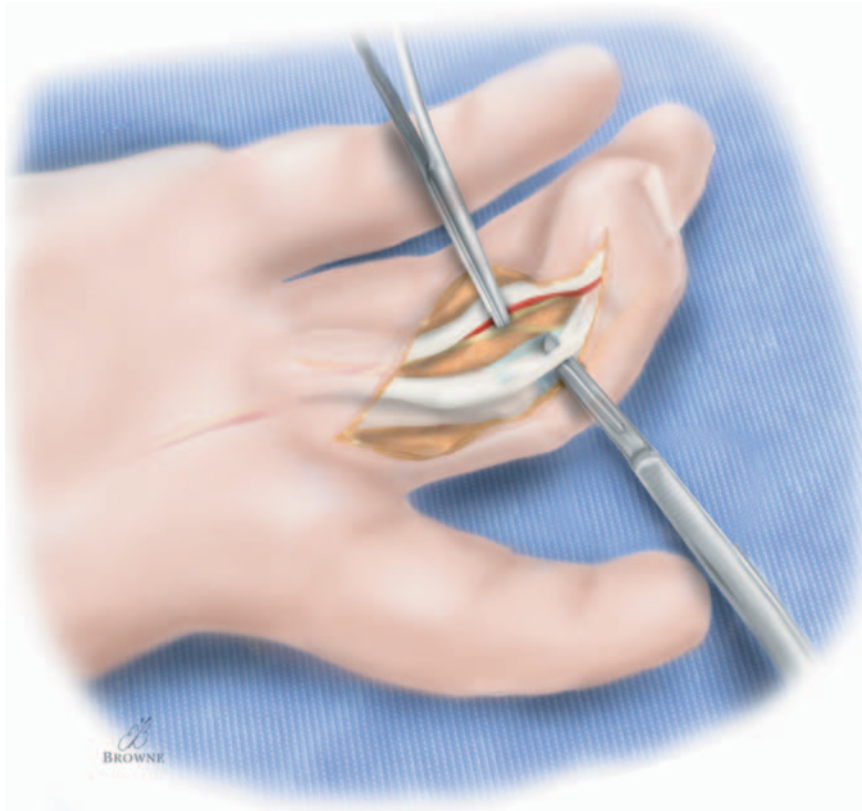


Figure S1.12.2

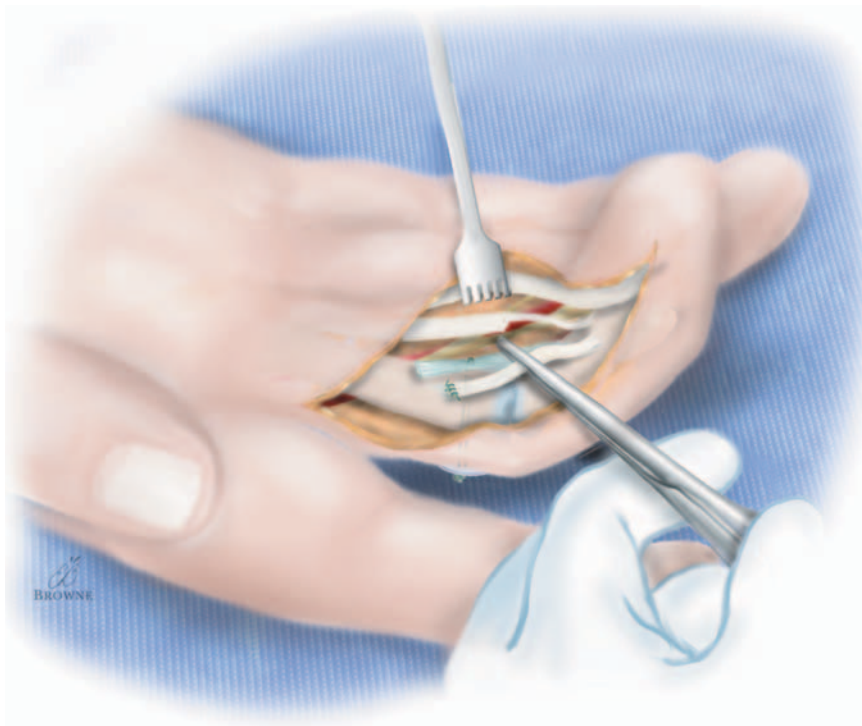


Figure S1.12.3

Spinal Procedures

1. Posterior Spinal Fusion with Unit Rod

Indication

The primary instrumentation for fusion of cerebral palsy scoliosis is posterior spinal fusion using a Unit rod. The indications for fusion in the growing child are a curve approaching 90° when sitting, or a curve that is becoming stiff such that side bending to the midline is difficult. The same instrumentation is indicated for kyphosis in the adolescent when the kyphosis is becoming stiff or is a significant impairment to sitting. Surgical correction of lordosis is indicated when sitting is difficult or if there is pain with sitting from the severe lordosis.

Procedure

1. Preparation of the child should start with insertion of two large-bore peripheral intravenous lines if possible. The child then is intubated with careful attention to having the endotracheal tube well secured.
2. An arterial line is inserted, usually in the radial artery by percutaneous insertion. If it is impossible to obtain a percutaneous peripheral arterial line, cutdown of the radial artery is indicated with insertion of a line. If this is not possible, a cutdown onto the posterior tibial artery at the posterior aspect of the proximal medial malleolus is recommended.
3. A large-bore central line is inserted, typically using a tunneled central line, which will be used postoperatively as a feeding line. Usually, this line is inserted via the subclavian approach with the catheter exiting on the lateral inframammary line or at the medial midline.
4. A Foley catheter is inserted to monitor urinary output, and a nasogastric tube is inserted to continuously keep the stomach decompressed to decrease venous bleeding.
5. The patient is turned prone on the spine frame, making sure that the abdomen is fully dependent to decrease bleeding from increased abdominal venous pressure, and the hips are flexed sufficiently to maximally reduce lumbar lordosis (Figure S2.1.1).
6. After prepping and draping, a posterior incision is made from T1 to the middle of the sacrum. The longitudinal direction of the line is chosen to be halfway between a straight line from T1 to the sacrum and a line that follows the curve of the spinous process (Figure S2.1.2).

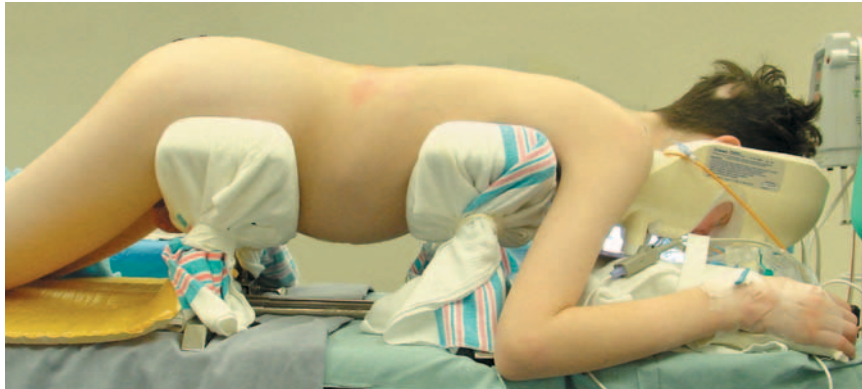

Figure S2.1.1

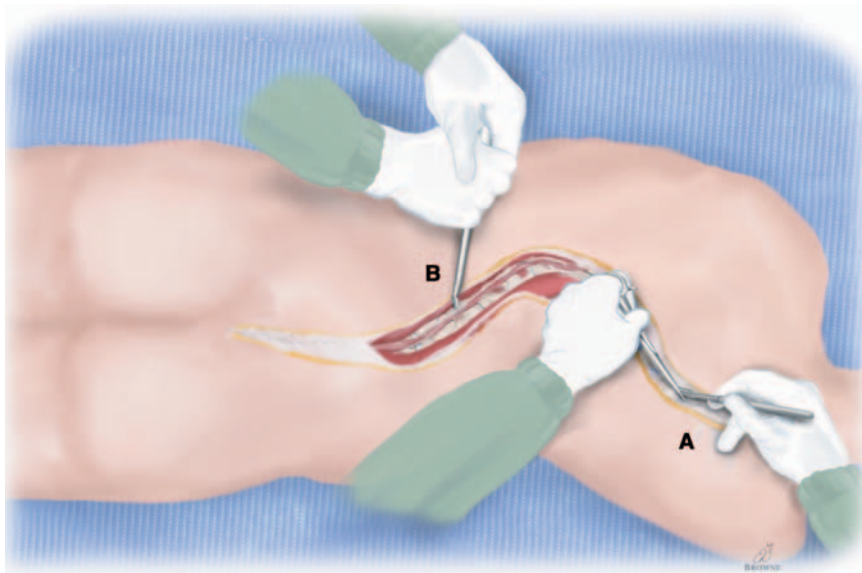


Figure S2.1.2

7. A small superficial dermal incision is made, and then the subcutaneous tissue is infiltrated with a large volume, up to 500 ml, of normal saline diluted 1 to 500,000 with epinephrine. An alternative is to use electrocautery to cut through the subcutaneous tissue and dermis.
8. Utilizing lateral pressure from a clamp and a knife, the interspinous ligaments and spinous process apophysis are transected. By staying exactly in the midline where there are few crossing blood vessels, little bleeding is encountered (Figure S2.1.2, A).
9. Subperiosteal dissection is performed over each lamina with packing of a sponge at each level (Figure S2.1.2, B).
10. After all the laminae are subperiosteally exposed and packed from T1 to L5, attention is directed to the sacrum, where the sacrum is stripped with exposure of the paraspinal muscles until the posterosuperior iliac crest can be palpated. This stripping and elevation need to occur from L5 to the distal end of the sacrum.
11. While doing periosteal elevation over the sacrum and L5, care should be taken to avoid opening the sacroiliac joints or violating the posterior sacroiliac ligaments, as these will have significant bleeding.

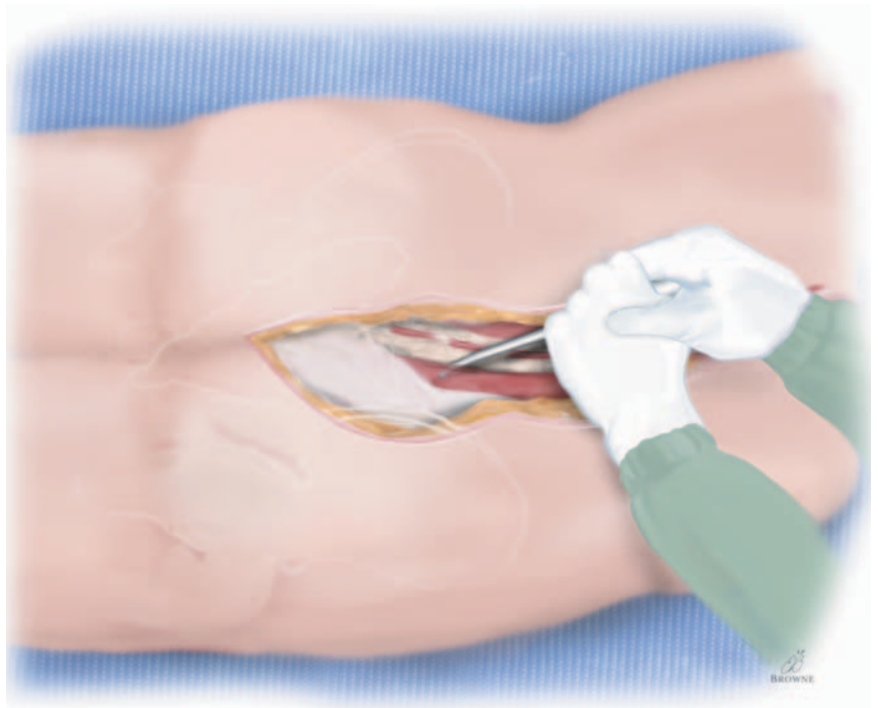


Figure S2.1.3

12. Identify the crest of the posterosuperior iliac spine and then make a longitudinal incision down the midline of the crest to the inferior aspect of the posterosuperior iliac spine (Figure S2.1.3).
13. Subperiosteally strip the lateral aspect of the ilium anterior and inferior.
14. Use a packing sponge; dissect inferior toward the sciatic notch and the posterosuperior iliac spine.
15. Clean the inferior two-thirds of the posterosuperior iliac spine so its medial and lateral border and caudal edge are visible clearly.
16. Insert the drill guide hook into the sciatic notch and align the drill insertion point at the inferior aspect of the posterosuperior iliac spine. Do not get too close to the inferior border. Before drilling, make sure that the drill guide is held into the apex of the sciatic notch with its lateral border being flat against the ilium. Also, before drilling, mark the drill bit so that it will protrude 1 to 2 cm past the distal end of the drill guide (Figure S2.1.4).
17. Drill the hole into the pelvis to, or just past, the mark on the drill bit. Always be careful to stabilize the drill guide in the proper position (Figure S2.1.4).
18. Using a wire or a thin probe, document that the drillhole is entirely within bone.
19. Repeat the same procedure on the iliac crest on the opposite side.
20. Pack Gelfoam into the drillholes to prevent bone bleeding.
21. Pack the lateral side of the iliac crest with a sponge to prevent bleeding. These sponges have to be inserted completely over the edge of the iliac crest or they will become entangled in the rod or wires. These sponges will be removed just before wound closure.
22. Remove the sponge packs from the prior exposure of the spine, and clean each vertebra so that all the soft tissue is removed from the tips

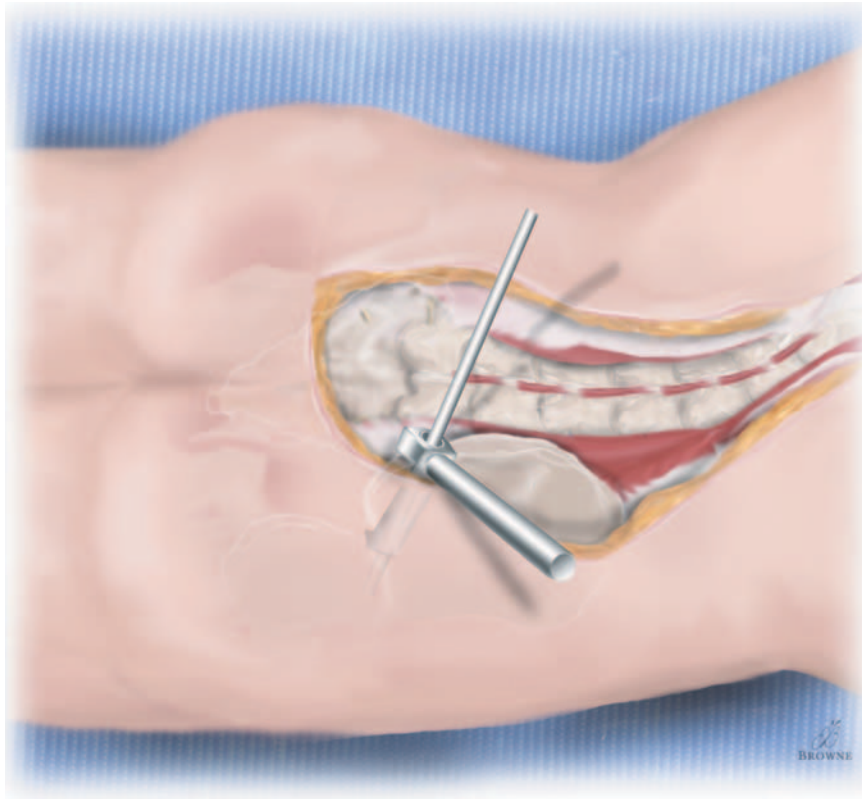


Figure S2.1.4

- of the transverse process over all the laminae and the spinous processes. Make a good clean exposure of the facet joints.
23. Remove the spinous processes by using a bone biter. In the thoracic spine, cut vertically approximately 1 cm distal to the superior aspect of the lamina. By proper removal of the spinous processes, the spinal interspace is opened. It is important never to violate the superior border of the posterior elements, as this is where the strength for wire fixation occurs. In the lumbar spine, the spinous processes should be transected transversely at their base (Figure S2.1.6). In the lumbar area, the spinous process is cut horizontally; then at the thoracolumbar junction they are cut at 45°, and in the thoracic area the process are cut off vertically (Figure S2.1.6).
 24. Use a rongeur with a serrated end to remove the ligamentum flavum (Figure S2.1.5, A). If more bone removal is indicated, remove the bone from the inferior aspect of the spinous process base and lamina only. Never remove bone from the superior aspect of the lamina because this is the aspect of the lamina that provides strength for the wire (Figure S2.1.5, B).
 25. Complete the spinal interspace opening with a curette, making sure that the ligamentum flavum is cut a sufficient distance on either side so wire can be passed (Figure S2.1.5, C). If epidural bleeding occurs during this time, the interspace should be packed gently with Gelfoam and a neural sponge. There may be substantial bleeding from these epidural veins; however, it is almost impossible to cauterize them without an extremely large exposure that destroys the lamina. The bleeding can be controlled with gentle pressure, and

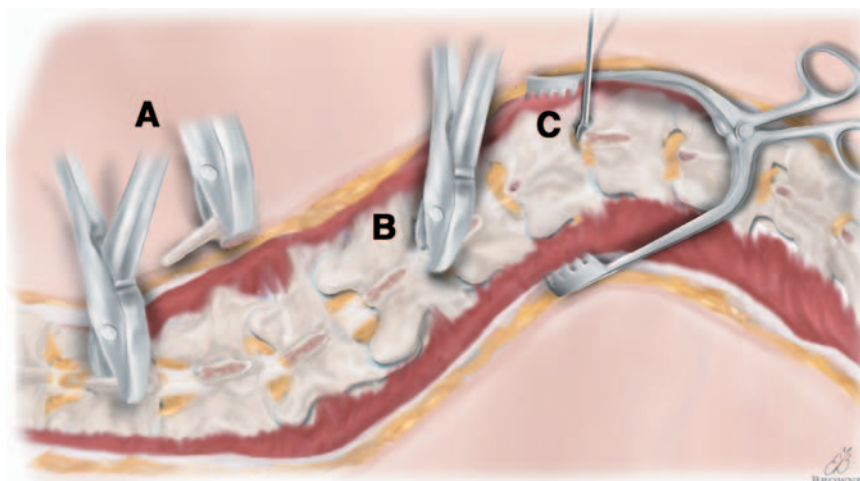


Figure S2.1.5

occasionally wire passing has to be done in the face of some of the epidural bleeding.

26. Wires are inserted starting at the distal end at L5. Usually, two double wires are inserted at L5 and T1 and only a single double wire at each other level (Figure S2.1.7, A). The wires are bent over the

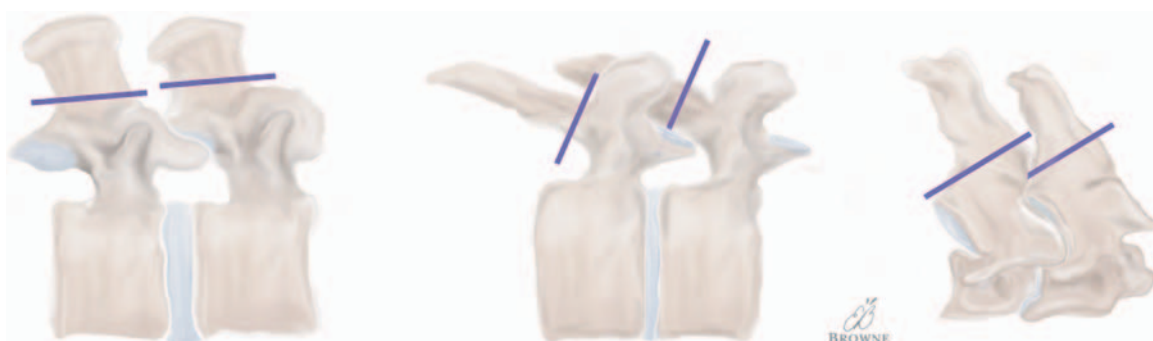

Figure S2.1.6

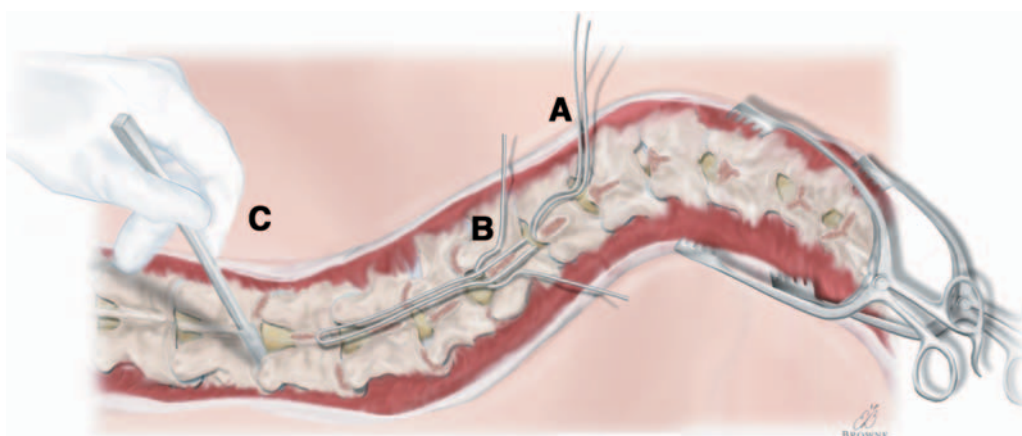


Figure S2.1.7

laminae so that the double end of the wire is bent into the midline pointing caudally, and each beaded lateral single wire is brought out laterally and cross-cranially over the laminae. This double crossing of the wires provides extra protection to prevent the inadvertent protrusion of the wires into the neural canal (Figure S2.1.7, B). When passing wires it is important to roll the wires under the lamina, being especially careful not to roll the wire with the tip caught under the lamina, as this will cause high pressure on the spinal cord (Figure S2.1.8).

27. Utilizing gouges or rongeurs, all facet joints are removed from T1 to the sacrum (Figure S2.1.7, C). The transverse processes and far

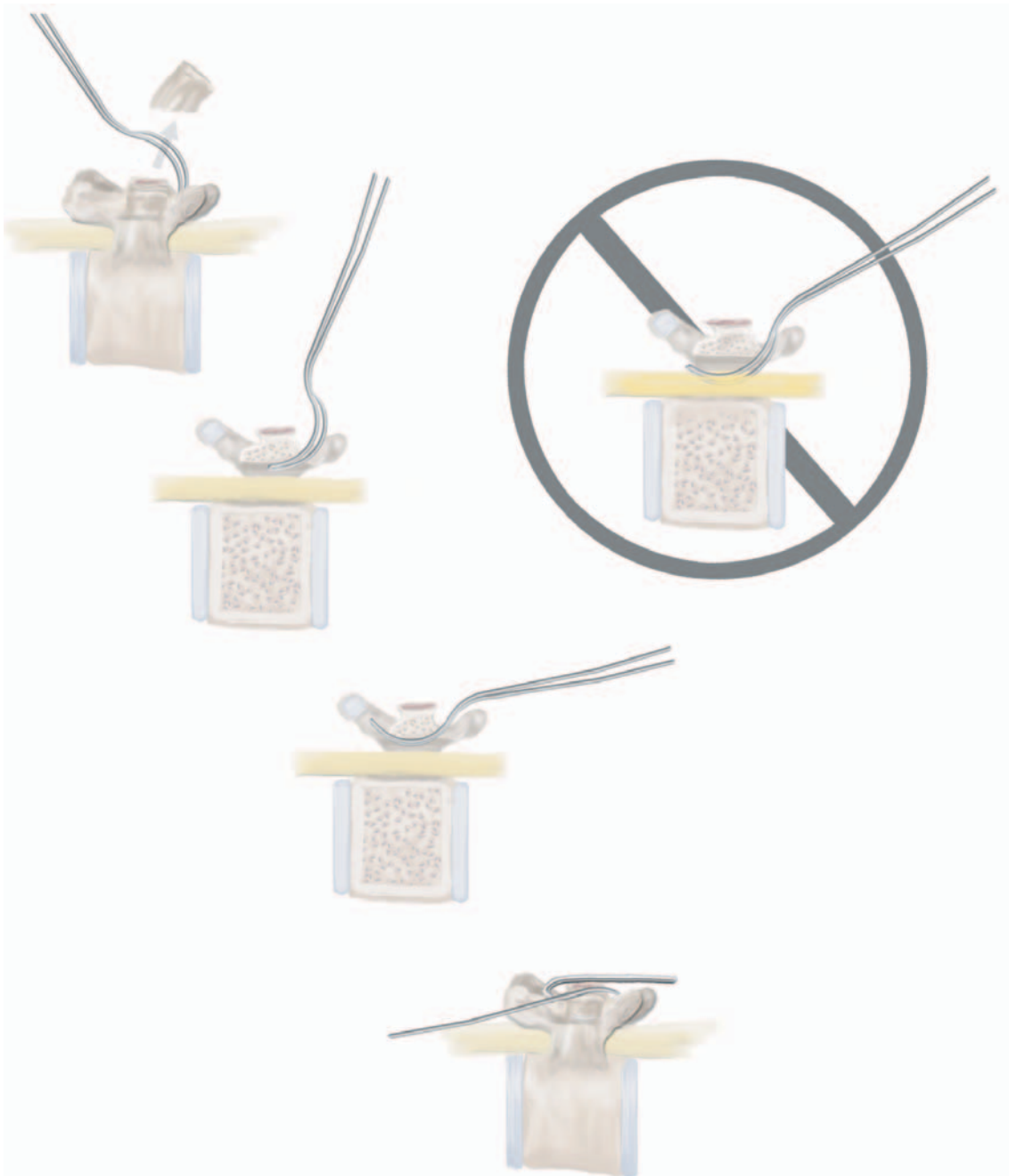

Figure S2.1.8

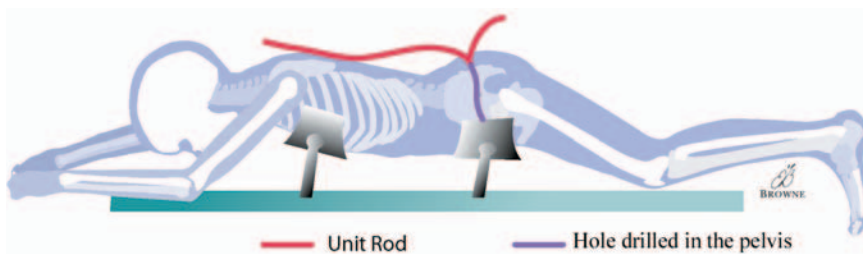


Figure S2.1.9

lateral borders of the laminae are decorticated. Bone graft then is packed into this decorticated bone. Bleeding that cannot be controlled with electrocautery will occur during this period as the bone is opened, and it should be controlled by packing the wound with bone graft soaked with thrombin and Gelfoam. Pressure from additional sponge packing also will help control the bleeding. If severe bleeding is encountered, this portion of the procedure can be done after insertion of the rod, but it is more difficult, and decortication and facetectomy performed after rod insertion will be much less adequate.

28. Choose the correct rod length by estimating the rod and laying it upside down with the legs pointing posteriorly. The most caudal end of the rod is now aligned with the holes drilled in the pelvis. If significant pelvic obliquity is present, choose a midway point between the right and left holes. The cranial end of the rod then is aligned to lie at the level of T1. If there is severe lumbar lordosis or severe scoliosis, one size longer rod may be chosen. If severe kyphosis is present, one size shorter rod should be chosen (Figure S2.1.9).
29. The caudal end of the rod legs then is crossed over for insertion. The holes drilled in the pelvis should be palpated with a probe and their orientation carefully memorized. The hole that is most vertical is inserted first, with that leg of the Unit rod having to be anterior to the leg of the Unit rod to be inserted last. By memorizing the direction, the leg of the Unit rod is inserted for approximately half its length. Attention then is directed to the opposite hole, where it is again probed and its direction carefully memorized, and then the leg is directed into the proper direction. Each of the legs is impacted sequentially until they are driven down completely below the level of the bone of the superior iliac spine. In small children, or those with severe osteoporosis, it is extremely important to very carefully monitor the direction in which the legs of the rod are being impacted, which often requires holding onto the rod with a device and helping direct the rod into the correct direction. With weak bones, the rod may cut its own hole if impaction is not performed carefully. The distal end of the rod then is impacted fully into the pelvis until it is below the level of the posterosuperior iliac spine, and should be lying in the gutter between the iliac spine and the lateral sacrum.
30. The rod is pushed to L5 using a rod pusher and the wires are twisted and tightened (Figure S2.1.10). **It is extremely important to not try to push the rod down to the spine to see if the spine can be corrected and the rod is the right length at this time.** This maneuver may cause the pelvis to fracture and the rod to lose its distal fixation.
31. The rod is pushed using a rod pusher to each sequential vertebral level and the wire is tightened to the rod sequentially (Figure S2.1.11). **Do not use the wires to pull the rod to the bone.**

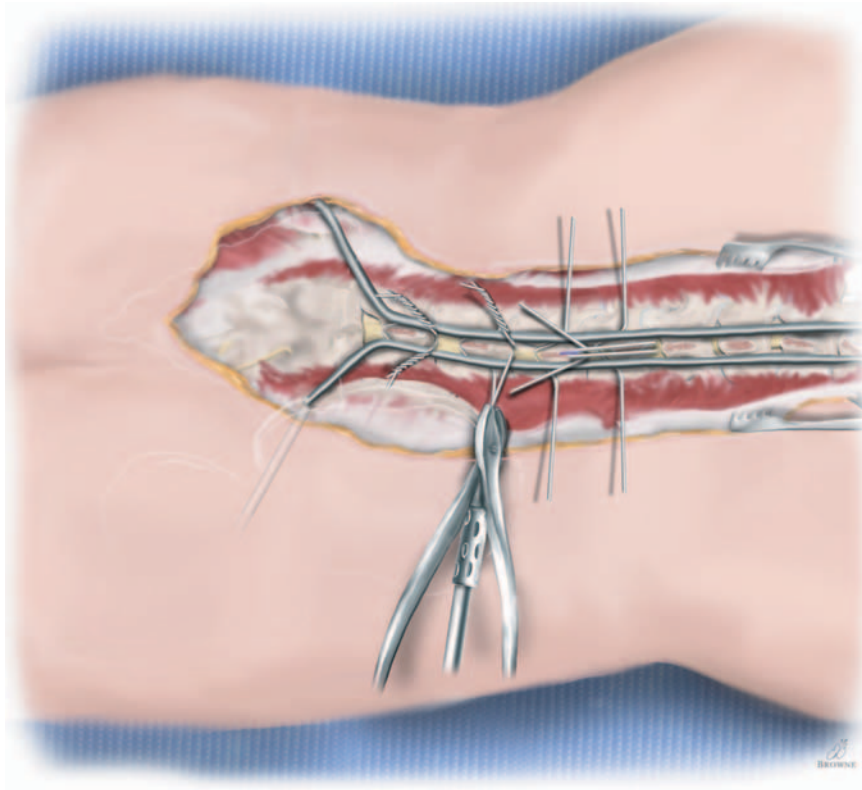


Figure S2.1.10

32. The cut wires that protrude laterally (Figure S2.1.12, A) are now bent to the midline (Figure S2.1.12, B), and additional bone graft is added with bank bone until the rod is covered almost completely (Figure S2.1.12, C). By digital palpation of the rod, make sure there are no laterally protruding wires. A single wire may easily be missed if there is substantial bleeding before wound closure.
33. Closure of the spinal fascia requires suturing so that the closure is watertight and no leaking or bleeding can occur from the deep hematoma. This leaking leads to a high likelihood of developing a subcutaneous hematoma, which causes wound leakage and then developing an infection from the outside in.
34. The subcutaneous tissue is closed to obliterate all dead space. No wound drains are needed.
35. The skin is subsequently closed.
36. After dressing is applied, the child is turned into the supine position and there is careful palpation of the abdomen, especially in the suprapubic region and just to the medial side of the ilium. The anterior tip of the rod can be palpated if it has inadvertently cut a new track and is in the lower abdomen and has not stayed in the drilled holes.
37. An anteroposterior pelvic radiograph is obtained, and if there is any question about the position of the rod, additional 30° to 40° right and left oblique radiographs of the pelvis are obtained to document that the rod is within the pelvis.
38. A chest radiograph is obtained to document that there is no pneumothorax, and also to document the position of the rod postoperatively.

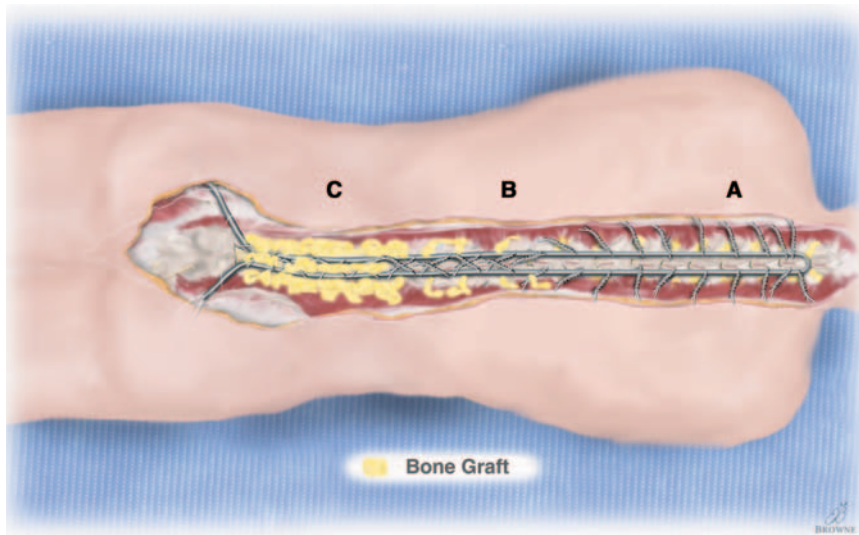


Figure S2.1.12

39. If the radiographs demonstrate adequate position, the child then is transferred to the intensive care unit. It is very important to continue with diligent, continuous monitoring throughout the whole postoperative period, especially the period of transfer to the intensive care unit. When the child is sitting well, full-length postoperative radiographs are obtained (Figures S2.1.13, S2.1.14).
40. If the pelvic legs are felt in the abdomen and the child is hemodynamically stable, he is again turned prone, and the inferior one third of the wound should be opened. The wires on the side of the protruded rod are untwisted from L3, L4, and L5. The rod then is cut at the L3 level. The protruded end of the rod is removed. Its correct hole in the ilium is identified, and the rod is reinserted into this hole. Then, the rod is connected using a tube connector for an end-to-end connection, but it is very important to add an additional side-to-side connection distal to the tube connector because of poor fixation provided only with the tube connector.
41. If there were problems with insertion into the pelvis initially because of hyperlordosis, the Unit rod may be bent into further hyperlordosis, inserted, and then the lordosis decreased, or alternatively, the rod could have been cut prior and then reattached as was described above.

Postoperative Care

The child is kept in the intensive care unit, usually intubated on a ventilator for 24 hours, then extubated and mobilized as tolerated. Almost all children are started on central venous hyperalimentation on the second postoperative day. Oral feeding is initiated as soon as the bowels are functioning. No postoperative orthotic immobilization is required and no special handling is necessary. Wheelchairs must be adjusted before the child uses them postoperatively because the significant change in body shape will cause high skin pressure areas with a risk of skin breakdown, which can then lead to deep infection.

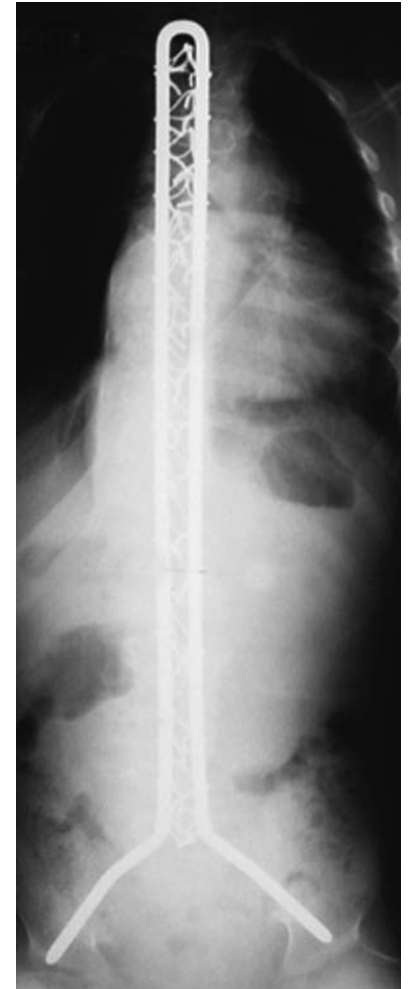


Figure S2.1.13

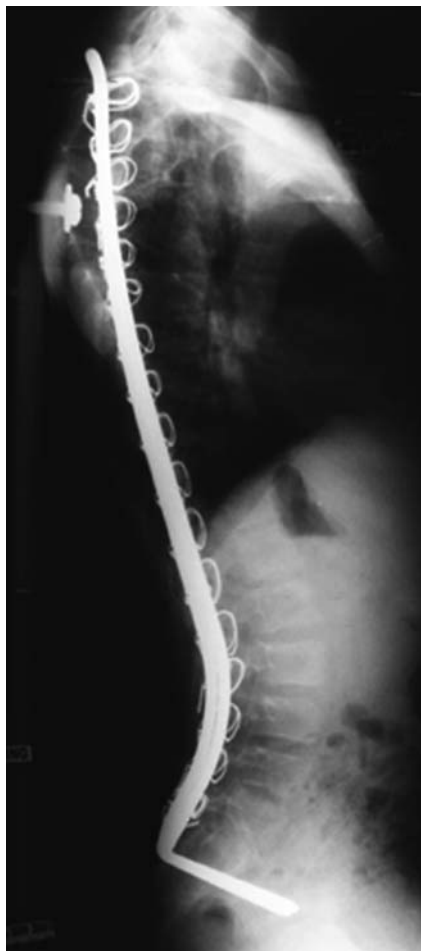


Figure S2.1.14

2. Anterior Spinal Release

Indication

Anterior spinal release is indicated for spinal curves that are excessively large, usually greater than 100° , and for release of severe lumbar lordosis or kyphosis. Very stiff curves of more than 50° , as defined by those in children who cannot side bend to bring the spinous processes to the midline, also require anterior release. With the use of the Unit rod, anterior release is not required because of a concern about crankshaft deformity with growth. No anterior instrumentation is used, as this procedure always is done in combination with a posterior spinal fusion using a Unit rod. Both the anterior and posterior procedures may be done on the same day if the child is very healthy and the surgeon feels comfortable with this much surgery in 1 day. Our experience suggests that it is safer in very compromised children to separate the procedures by 1 week. Typically the anterior procedure is done first and then 1 week later the posterior procedure is performed.

Procedure

1. The exposure is determined by the length of the release to be performed. A thoracic exposure is adequate for a release that will extend from the T10–T11 disk space up to the T3–T4 disks. A lumbar exposure is adequate for release from L1–T12 disks to the L4–L5 disks. Thoracolumbar exposures are required for releases crossing from T11–T12 disks. The side of the exposure is always toward the apex of the scoliosis, or if there is no scoliosis, left-side exposure is easier to avoid the vena cava.
2. If thoracic exposure is sufficient, then the exposure should be made through the rib, which are two ribs cranial to the apex of the curve.
3. Thoracolumbar exposure is made through the 10th rib bed (Figure S2.2.1).
4. A lumbar exposure typically is made through the bed of the 12th rib.
5. After the level is chosen, an incision is made along the rib and carried anteriorly to the border of the rectus abdominus muscle, and then longitudinally along the rectus abdominus muscle to the level.

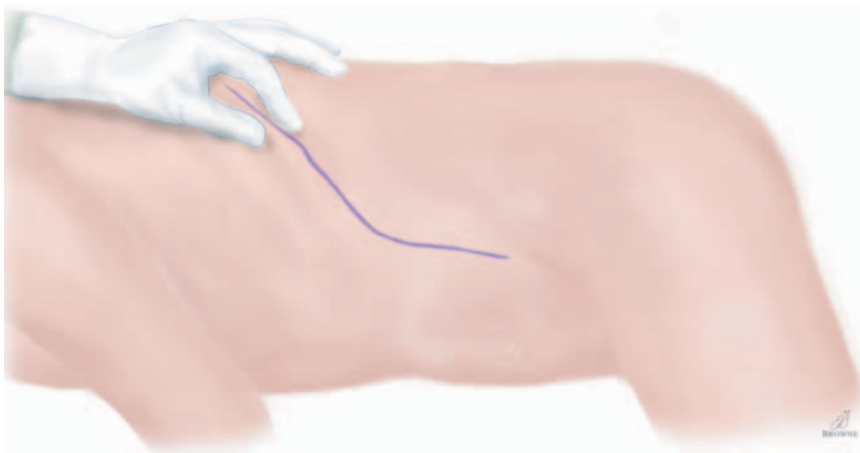


Figure S2.2.1

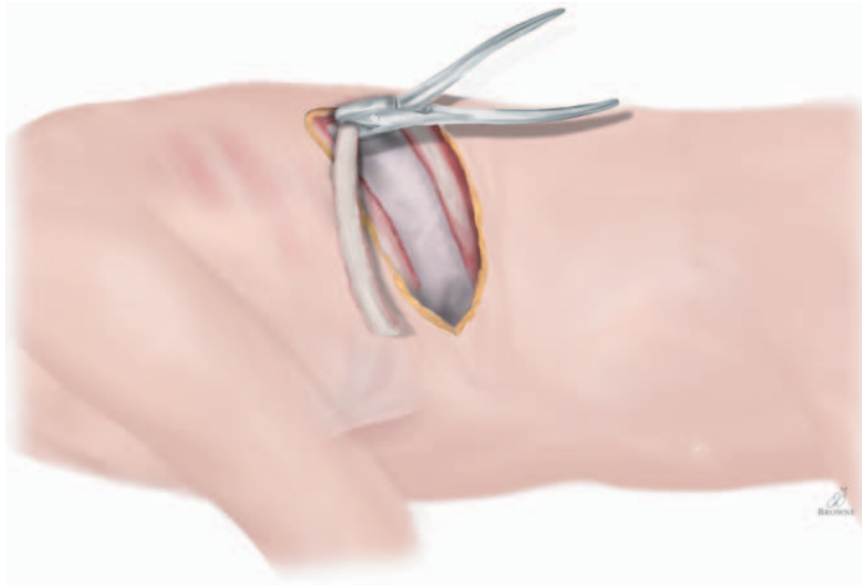


Figure S2.2.2

6. The ribs are exposed and subperiosteally dissected free (Figure S2.2.2). The anterior osteocartilaginous junction is separated, and the rib is subperiosteally dissected leaving it attached posteriorly and then stripped as far posteriorly as possible and transected. The thoracic cavity is entered by opening the periosteum and pleura in the middle of the rib bed and extending it anteriorly. The incision is extended posteriorly to the area of the resection of the rib.
7. If this is a thoracolumbar exposure, the chondral cartilage then is sharply transected longitudinally to where it ends, and it is gently opened using a blunt instrument for dissection at its caudal end. This, then, will enter the abdominal cavity, and the peritoneum should be dissected off the undersurface of the abdominal muscles. At the distal end of the 10th rib the anterior insertion of the diaphragm is encountered beneath the split cartilage.
8. The anterior dissection then is carried down through the abdominal muscles in line with the incision to the lateral border of the abdominus rectus, and can be carried along parallel to the abdominus rectus as far caudally as is needed.
9. The peritoneum then is dissected by blunt dissection off of the lateral and posterior abdominal cavity to enter the retroperitoneal space.
10. The retroperitoneal space is entered posterior to the kidneys and spleen on the left and posterior to the liver on the right side. At this time the anterior aspect of the spine can be palpated.
11. The retroperitoneal fat then is incised over the vertebrae, and using a blunt dissection, all the anterior longitudinal ligaments of the vertebrae are cleanly exposed. Segmental vessels are identified, hemoclips are applied, and the vessels are transected.
12. In the thoracic cavity, the pleura is incised over the spine and the retropleural space is opened with gentle dissection over the anterior longitudinal ligament. Segmental vessels are identified, hemoclips are applied, and the vessels are transected (Figure S2.2.3).

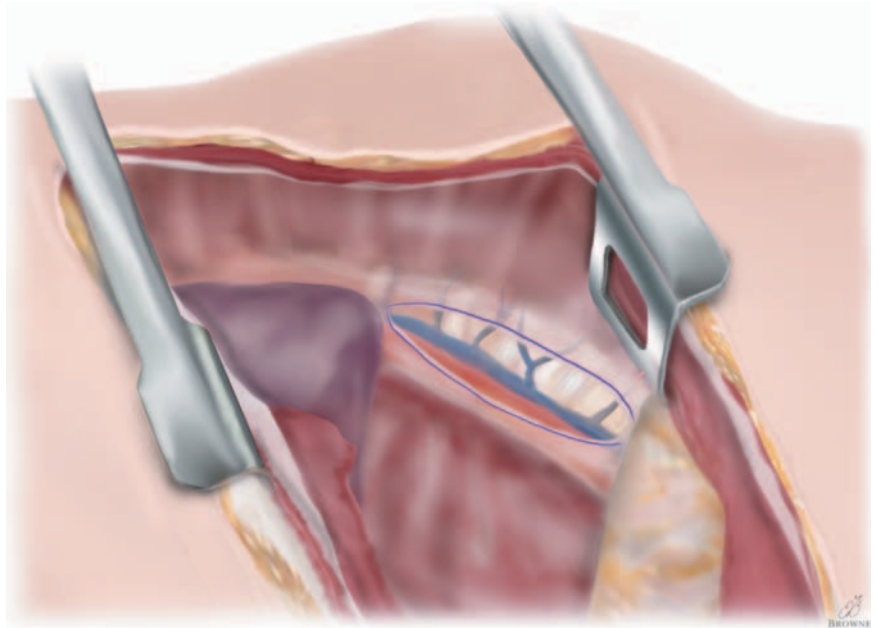


Figure S2.2.3

13. If a thoracolumbar exposure is required, the anterior origin of the diaphragm is identified under the split anterior cartilage of the 10th rib and incised at the border between the lateral third and medial two thirds. Marker sutures are placed on each side of the diaphragmatic incision every 2 cm, and cut in such a way that they can be identified as markers for repair. Usually a pair of sutures are cut short and the next pair is cut long. The diaphragm is cut through its whole circumference, aiming to the middle of the spine so that the separation between the medial and lateral crus of the diaphragm will be opened (Figure S2.2.4).
14. The spine now can be exposed with the anterior longitudinal ligament for the intended length. Utilizing Cobb elevators, the iliopsoas muscle can be elevated off the insertion on the bone, although care should be taken not to do subperiosteal dissection, which increases the bleeding.
15. Segmental vessels are ligated or clipped at each level.
16. The disk spaces are identified as the large, thicker areas on the spine and are incised anteriorly using a sharp knife (Figure S2.2.5).
17. All the disk material is eliminated with removal of a large wedge of all the end plate and some of the bone on the convex side of the scoliosis (Figure S2.2.6, B). Alternatively, if this is a severe lordosis, the anterior-based wedge is resected to allow the spine to close anteriorly. The posterior longitudinal ligament is left intact. For kyphotic deformities, there occasionally is a very thin disk in the front, sometimes even with a bony fusion, so bone burrs or rongeurs are necessary to make an osteotomy of the bone.
18. The disk spaces are packed with Gelfoam material for hemostasis and very thin pieces of bone are applied at the borders. No attempt is made to pack the disk spaces with bone graft (Figure S2.2.6, C).

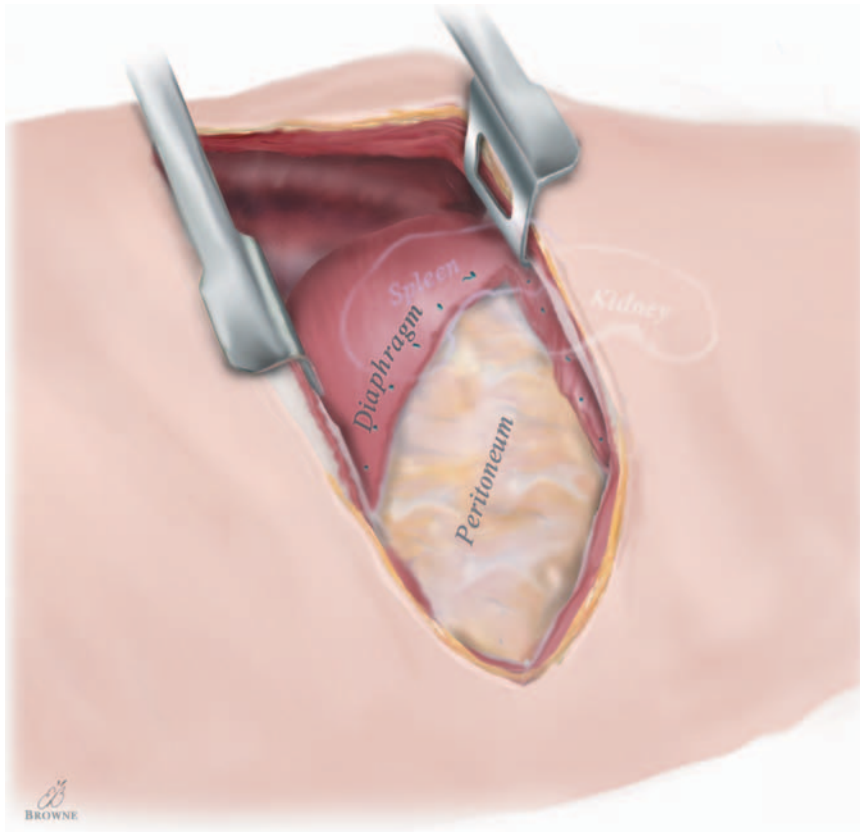


Figure S2.2.4

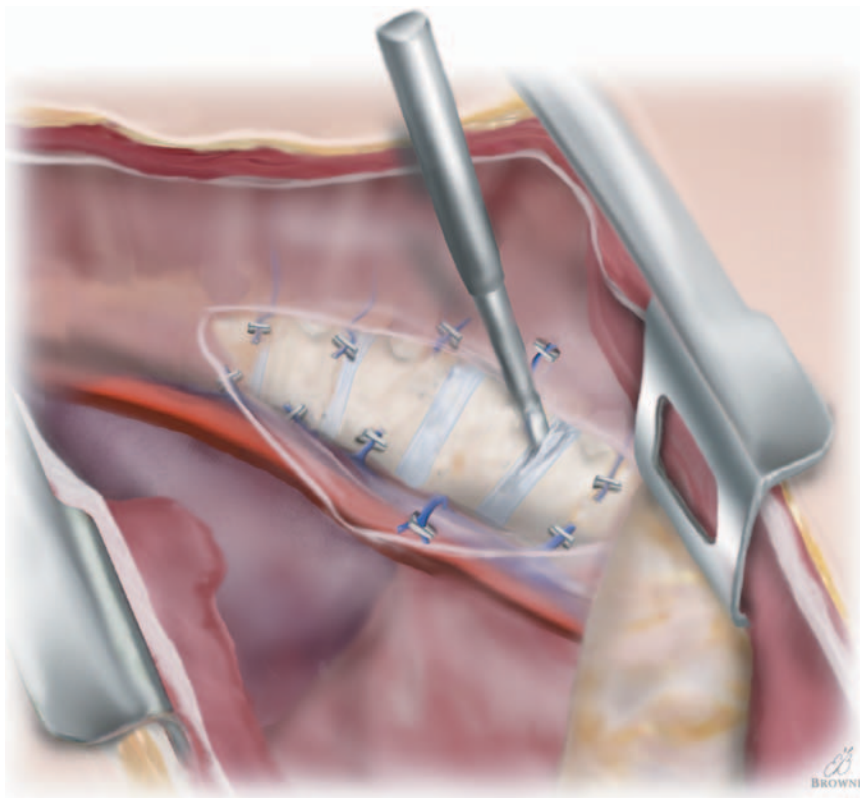


Figure S2.2.5

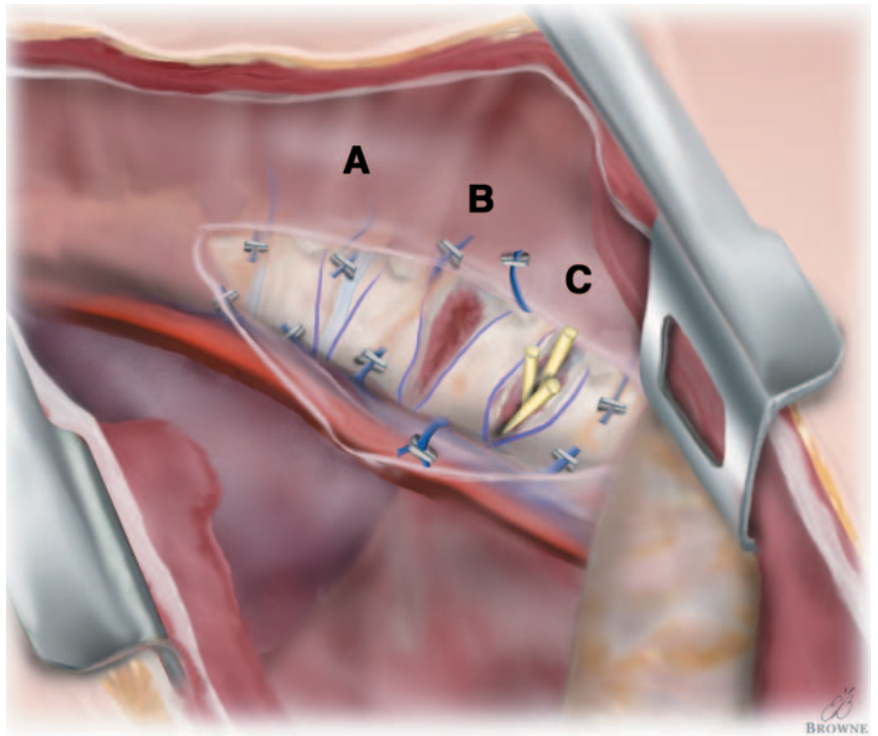


Figure S2.2.6

19. The wound is closed starting by using a running suture to close the posterior pleura over the spine. A suture is utilized and the posterior aspect of the diaphragm is closed with a running suture to close the incision in the diaphragm to its anterior aspect.
20. Sutures are placed around the superior and inferior ribs and used to approximate the thoracotomy wound. Muscle, subcutaneous, and skin closure follows. A chest tube is inserted into the thoracotomy wound before closure. Then, the patient is turned into the supine position for the posterior fusion.

Postoperative Care

The chest tube is left in place for 2 or 3 days until the chest tube drainage is less than 50 ml per 8 hours. There is no special attention except as one manages the posterior fusion, which is the major aspect of this procedure.

3. Baclofen Pump Implant

Indication

Intrathecal baclofen is indicated for individuals with spasticity or dystonia that causes discomfort or significant functional disability. Usually a trial with a single-dose injection is performed to evaluate the effectiveness of the intrathecal baclofen. The child has to have adequate body mass to tolerate the pump, usually 15 to 20 kg body weight.

Procedure

1. The child is placed in the side lying position, usually right side up because many children with cerebral palsy have gastrostomy tubes or may in the future need a gastrostomy tube. By placing the pump on the right side, interference with the gastrostomy tube is reduced.
2. The interspaces between L3–L4 or L2–L3 are palpated and the needle is inserted through the midline until free flow of cerebrospinal fluid (CSF) is identified (Figure S2.3.1). Inserting the needle through paraspinous muscles with the paramedian approach may stabilize the catheter better, but it is a more difficult approach. The catheter is inserted through the needle with placement of the tip at the midthoracic level if reduction of spasticity is to occur only in the legs. If the upper extremities also require a reduction in spasticity, the catheter is placed in the upper thoracic level. If the child has significant generalized spasticity or dystonia, placement to the midcervical region is acceptable. After the catheter has been placed and its position verified with fluoroscopy, an incision is made along the shaft of the needle before it is withdrawn (Figure S2.3.2). Removing the needle before making the skin incision risks damage to the catheter. Making the incision before insertion of the needle risks making additional incisions if a good puncture cannot be obtained at the initial location.
3. If the child has had a spine fusion, use the fluoroscope and identify the space between the rods and between sets of wires. Make an open incision down to the fusion mass and then use a dental burr or other bone cutter and drill through the fusion mass into the spinal canal.
4. An incision is made 8 cm long at the border of the lowest rib on the right upper quadrant of the abdomen. Subcutaneous fat and fascia are

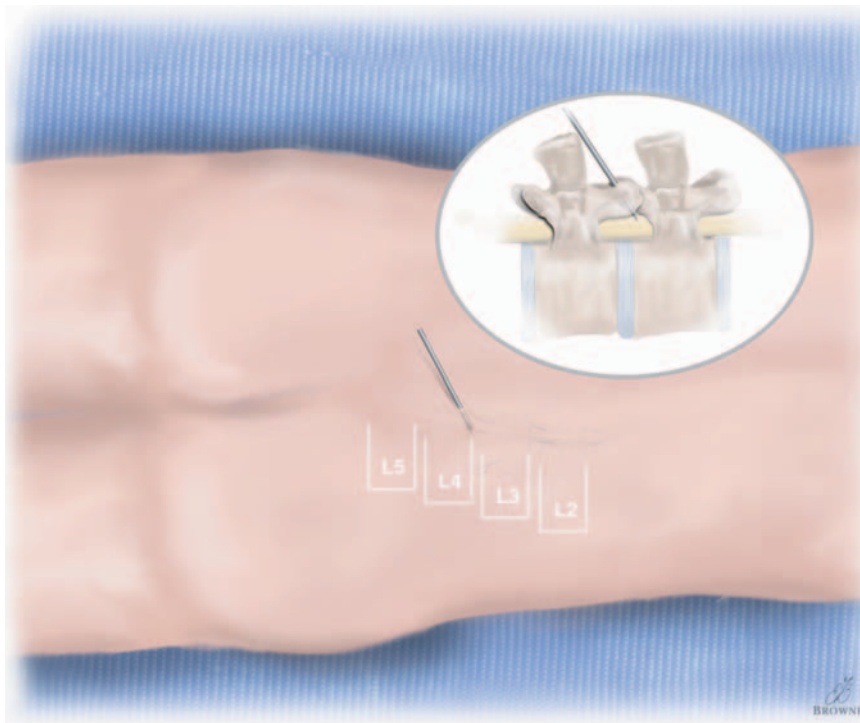


Figure S2.3.1

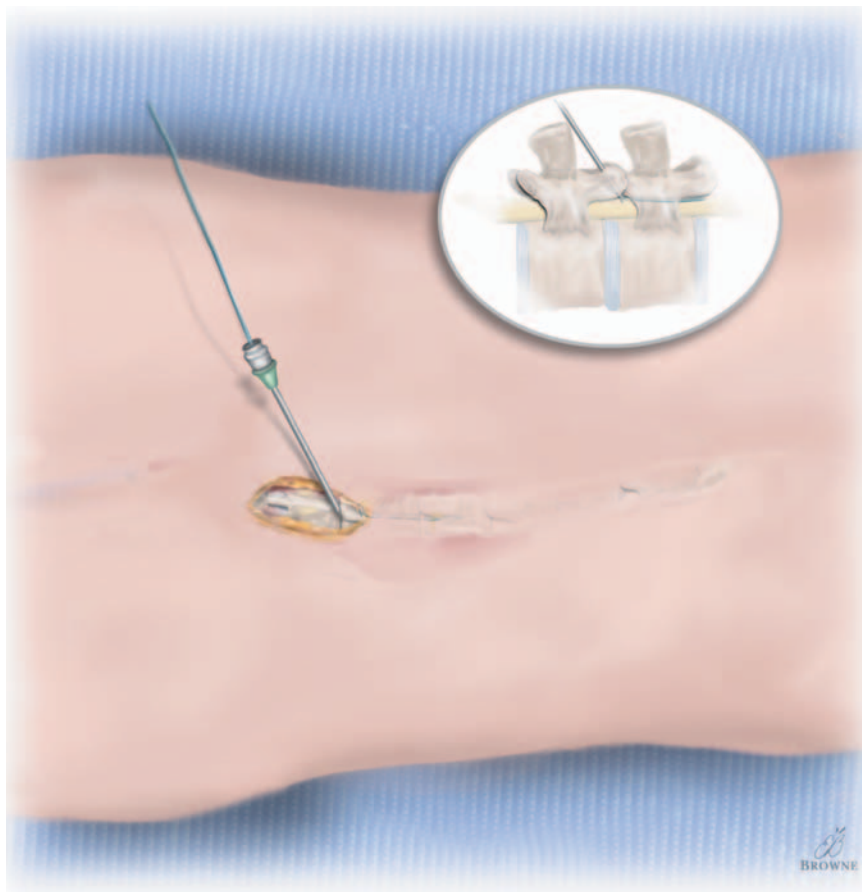


Figure S2.3.2

incised until the abdominal fascia is identified. For individuals with good body fat the fascia is clear inferiorly well below the umbilicus. Dissection of this pocket is best performed with fingers. For small children of less than 30 kg or very slender individuals, the fascia of the external oblique muscle is opened and the pocket is created inside the muscle fascia. A sharp opening to the fascia of the rectus muscle may also be required.

5. A tendon or catheter passer is then passed between the anterior incision and the posterior incision (Figure S2.3.3, A). Usually a heavy suture is pulled into the anterior wound that is then tied to the catheter to pull it into the anterior wound (Figure S2.3.3). Usually pulling the catheter with a suture gives better control and decreases the risk of catheter damage, although directly pulling the catheter with the catheter passer is also acceptable. There should be good outflow of spinal fluid from the catheter after it has been brought into the anterior wound. If there is not good flow, using a very small syringe and 27-gauge needle the catheter can be aspirated and flushed. If flow cannot be demonstrated the catheter should be removed and reinserted at another interspace.
6. The pump is now inserted into the previous created pocket, making sure the injection port is toward the skin. The catheter is cut off, leaving a little redundant catheter, and the catheter is attached to the pump. The pump is pushed well down into the pelvis, making sure that it

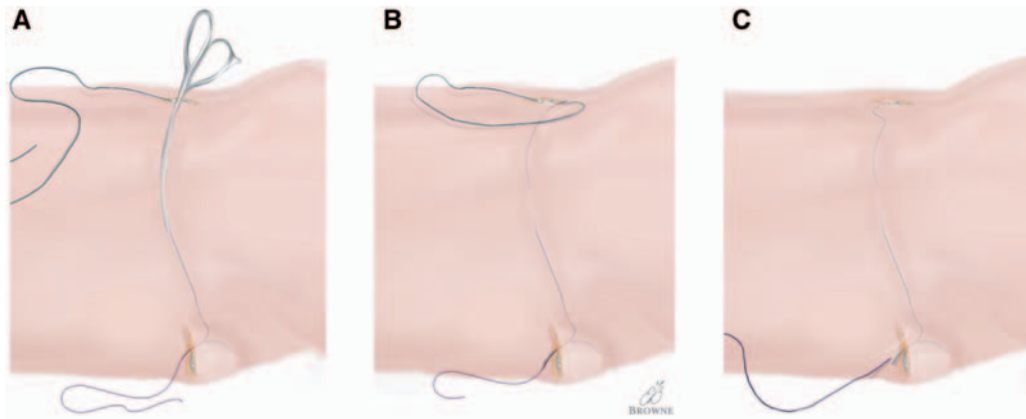


Figure S2.3.3

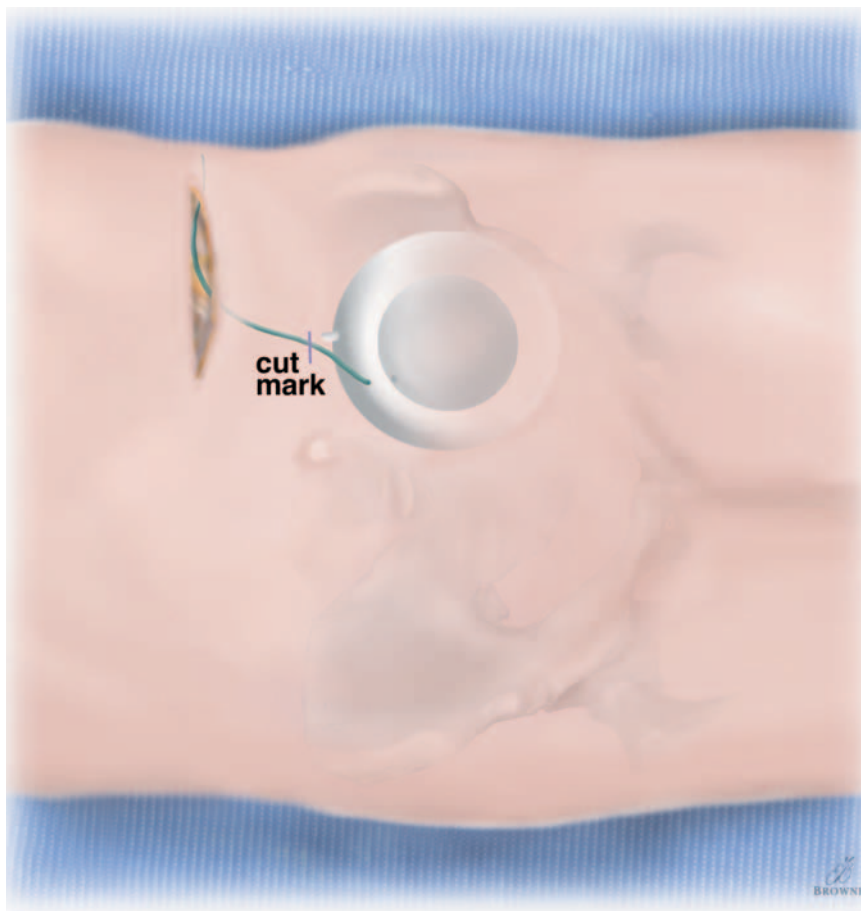


Figure S2.3.4

- does not rest on the iliac crest, and the incision should not cross over any part of the pump when the wound is closed (Figure S2.3.4).
7. Attention is then directed back to the posterior wound where the catheter is locally secured to the fascia with a connector (Figure S2.3.5).
 8. Wounds are closed carefully and an occlusive dressing is applied. If the spine had to be opened with a burr, the bone defect should be

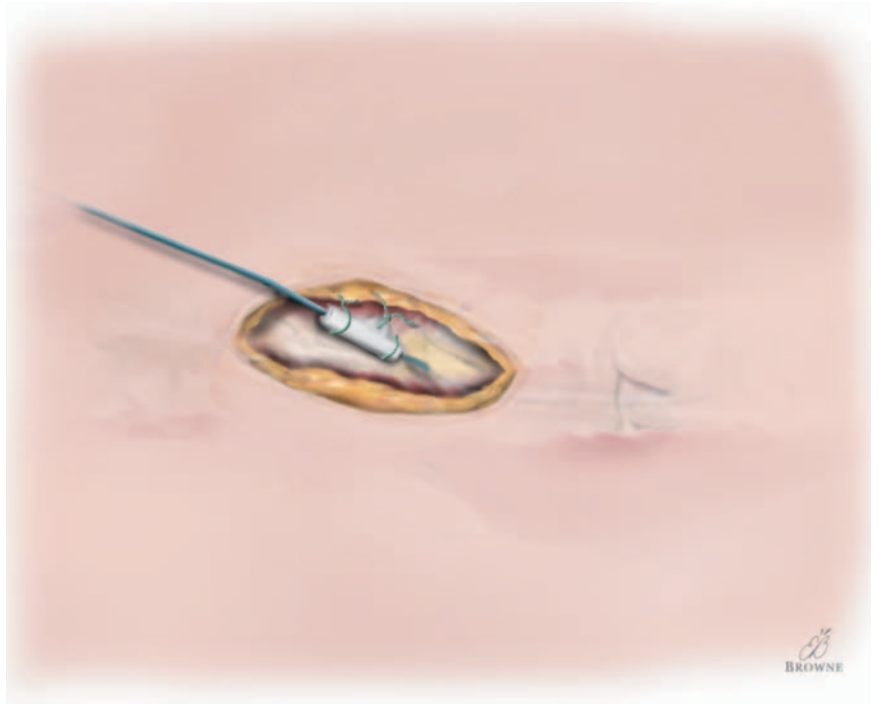


Figure S2.3.5

closed with craneoplast or some other occlusive plug in the bone defect to prevent the development of a spinal fluid leak.

9. The pump has to be filled before insertion and programmed according to the manufacturer's instructions. At the end of the procedure, the pump is programmed to start usually using the daily dose of the effective test dose.

Postoperative Care

Children are maintained in the supine position for 48 hours to try to prevent a spinal fluid leak. After that period they are allowed to ambulate and returned to normal activity but with limited forceful hip flexion. By 4 weeks after the implantation, full unrestricted activity is allowed.

Hip Procedures

1. Adductor and Iliopsoas Lengthening with Proximal Hamstring Lengthening

Indication

Proximal hip soft-tissue lengthenings will be described as one procedure; however, components of this procedure may be selected based on the exact indication. The primary indication is to treat spastic hip disease in children ages 2 to 8 years old with migratory percentage (MP) 25% to 60%. This procedure is also indicated for improving hip abduction to allow for perineal care. Limited lengthenings are also used to improve scissoring gait patterns.

Procedure

1. The incision is made 1 to 2 cm distal to the groin crease starting at the level of the adductor longus and extending posteriorly for 2 cm. The transverse incision is parallel to the groin crease (Figure S3.1.1).
2. Subcutaneous tissue is divided to the fascia overlying the adductor longus.
3. The fascia overlying the adductor longus is opened longitudinally in line with the adductor longus muscle and tendon. A retractor is placed into the compartment and retracted proximally so the tendon of the adductor longus is seen clearly (Figure S3.1.2).
4. A curved hemostat is passed from medial to lateral underneath the tendon of the adductor longus, being careful to avoid perforating the fascia overlying the adductor brevis and thereby risking injury to the anterior branch of the obturator nerve.
5. Electrocautery is utilized and the full tendon and muscle fibers of the adductor longus are divided. The divided end is retracted distally and through the translucent fascia, which is overlying the adductor brevis, and then the anterior branch of the obturator nerve can be clearly identified.
6. With medial retraction, the muscle compartment surrounding the gracilis is opened, and a retractor is placed into this muscle compartment and retracted medially. A hemostat is then passed around the body of the gracilis, which is a very wide muscle going posteriorly, and lifted up onto the medial retractor (Figure S3.1.3). The child's knee is flexed and extended to document that this muscle is gracilis and not adductor brevis or magnus, which occasionally can be confused. The gracilis is the only muscle in the adductor region

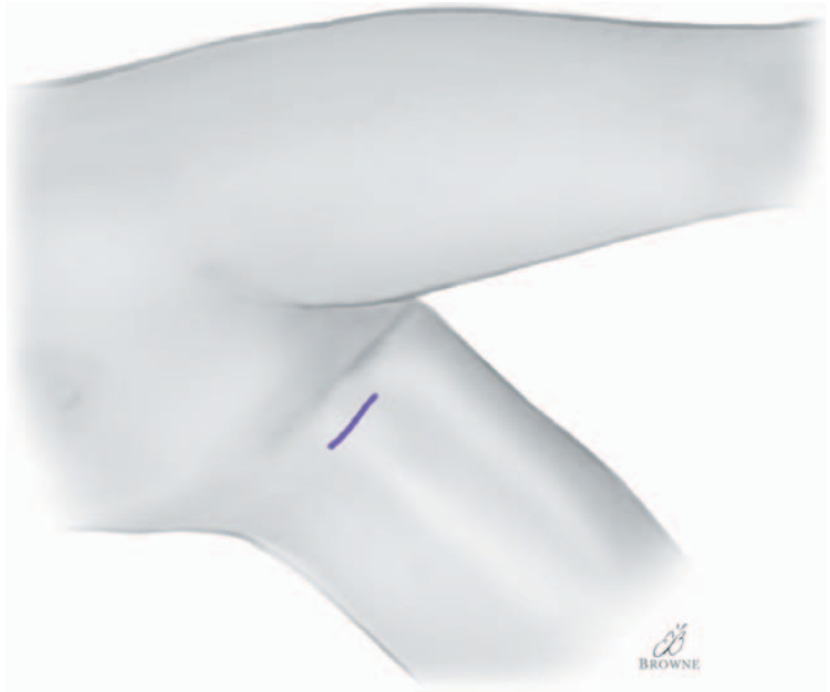


Figure S3.1.1

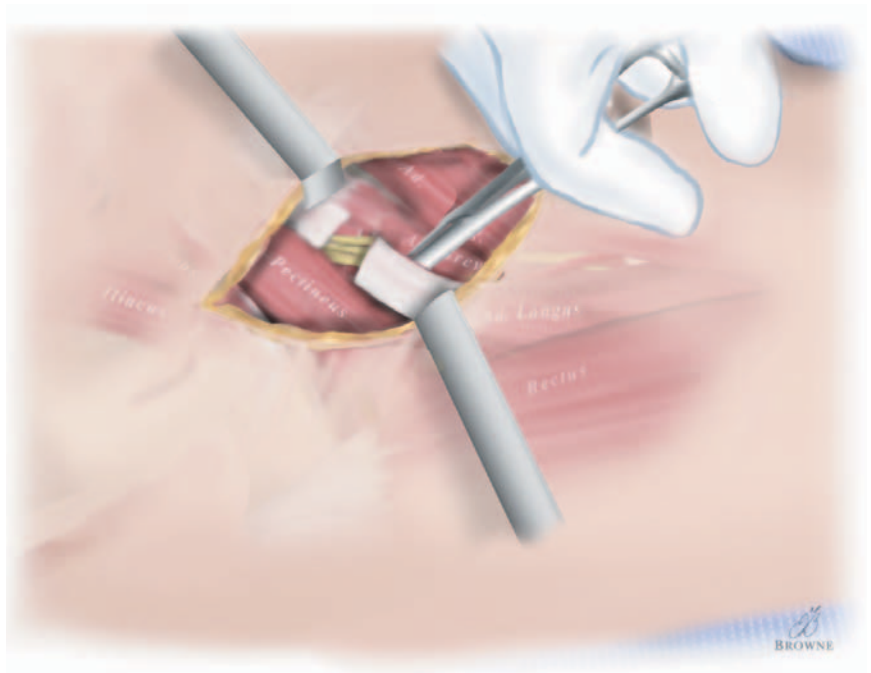


Figure S3.1.2

that crosses the knee joint; therefore, it is the only muscle that will move with knee flexion extension. Electrocautery is utilized and the muscle is transected. All the muscle fibers of the gracilis should be transected so that the muscle compartment is completely clean at the end of this procedure.

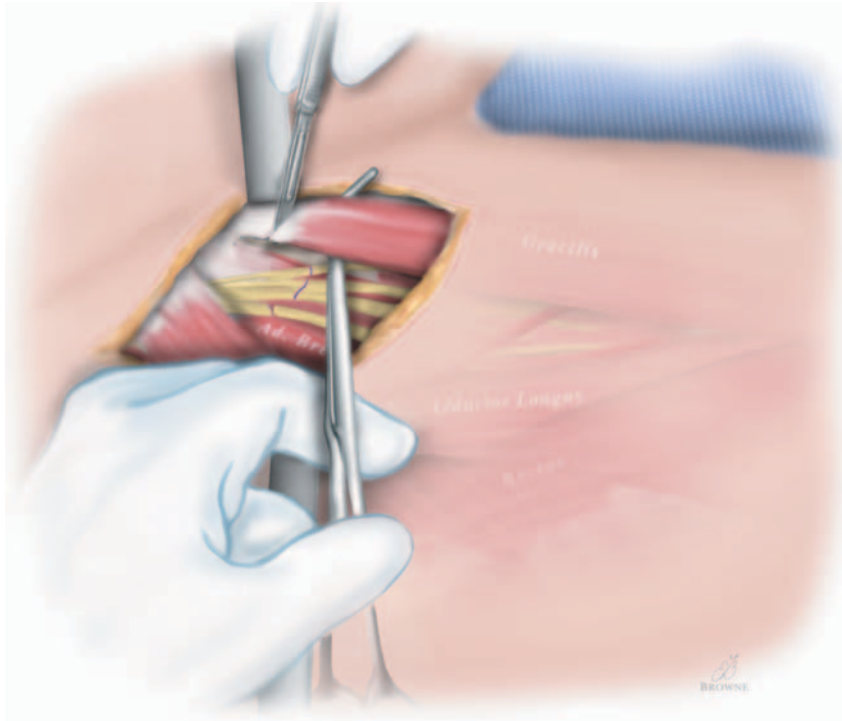


Figure S3.1.3

7. Hip abduction with the hip and knee in extension is now performed, and if it is less than 45° , attention is directed to the adductor brevis. If the child is definitely a nonambulator, and severe hip subluxation with an MP greater than 60% is present, the anterior branch of the obturator nerve can be transected. This transection is performed by identifying all four branches of the obturator nerve (Figure S3.1.3). The nerve is clamped with a hemostat, and electrocautery is utilized to remove a 1-cm section of the nerve.
8. If only the adductor brevis is to be lengthened to gain additional abduction range, then a retractor is placed underneath the anterior branch of the obturator nerve and is retracted laterally. The interval between the adductor brevis and magnus is identified, and a hemostat is placed parallel to the floor along the interval, making sure to stay superior to the fascia because the posterior branch of the obturator nerve lies under this fascia (Figure S3.1.4). Myotomy of the adductor brevis is performed until at least 45° of abduction is obtained, or until all the adductor brevis has been transected. The direction of the myotomy is toward the hip joint at right angles to the muscle fibers of the adductor brevis. Care is taken at the deep end of the adductor brevis to avoid the branches of the recurrent femoral vein and artery.
9. Attention is now directed toward exposure of the iliopsoas, which can be performed through the interval between the pectineus and adductor brevis with the anterior branch of the obturator nerve always staying with the adductor brevis. This interval is opened and the femur is identified. Note that the pectineus will be in line with the iliopsoas so a retractor has to be placed between the pectineus and the iliopsoas. A second option to expose the iliopsoas is to go on the lateral side of the pectineus between the pectineus and the neurovascular bundle (Figure S3.1.5). In this circumstance, the iliopsoas is found

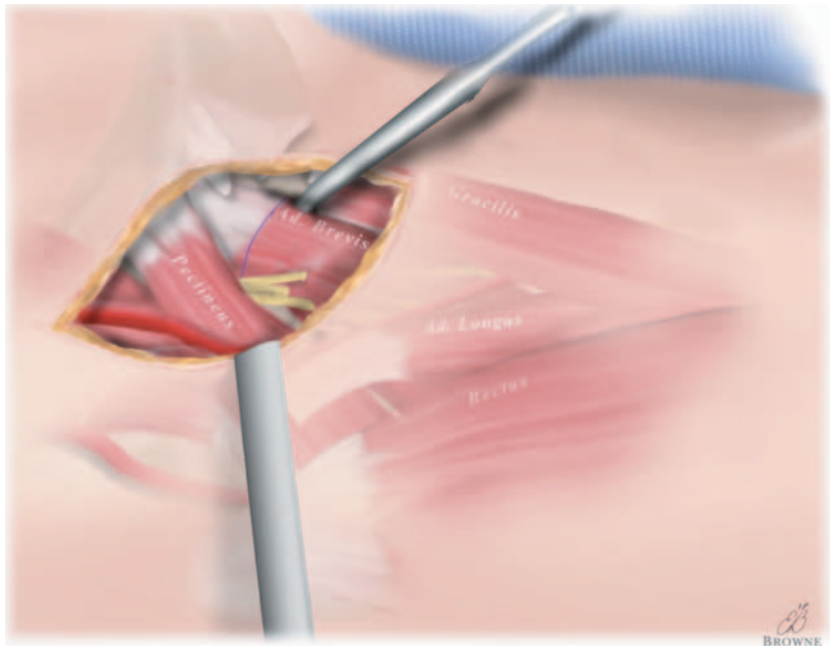


Figure S3.1.4

directly beneath the medially retracted pectineus. With two retractors in place, the iliopsoas bursa is opened with a hemostat and retracted in the direction of the umbilicus, which is the direction that the iliopsoas will be running.

10. A small dissecting hemostat with a small sponge then is used to clean off all the bursa and soft tissue from the iliopsoas tendon, leaving a nice, clean, white, shiny tendon. With retractors in place, a clear view of the iliopsoas now is visible and a small right-angle clamp is placed under the whole tendon of the iliopsoas, entering on the medial side of the tendon where there is no muscle attachment and then lifting up

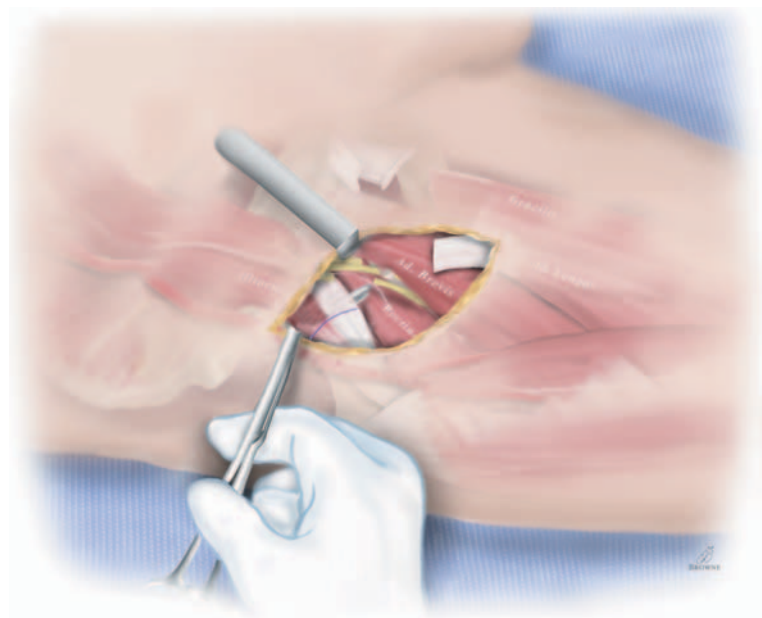


Figure S3.1.5

- the iliopsoas. Iliacus muscle fibers will be coming in on the lateral side of the tendon (Figure S3.1.5).
11. In the ambulatory child in whom performing a complete tenotomy is not recommended, it is very important to lift up the iliopsoas as far proximal as possible and leave all the muscle fibers of the iliacus intact. A regular scalpel is used to divide the tendon of the psoas, cutting from lateral to medial to avoid pointing the blade toward the neurovascular bundle. A good amount of muscle fiber should be left so the iliacus muscle remains intact.
 12. Alternatively, if the child is a severe quadriplegic and the goal is to do a complete release, the tendon and all its muscle fibers should be released at least a centimeter above the cartilaginous tip of the lesser trochanter.
 13. Attention is directed to proximal hamstring lengthening. The muscle compartment of the gracilis, which was opened when gracilis myotomy was performed previously, is again opened. The base of the gracilis muscle compartment is opened using a hemostat or digital palpation (Figure S3.1.6).
 14. The posterior compartment enveloping the hamstring muscles is now palpated and the fascia is lifted off the muscles, palpating around to the ischium. Using digital palpation, the interval between the adductor magnus and the semitendinosus and semimembranosus is identified by slightly flexing the hip and slowly moving the knee into flexion and extension. The muscles that are tightening with the flexion extension movement of the knee are the semimembranosus and semitendinosus, whereas the muscle belly that does not tighten with this maneuver is the adductor magnus. The adductor magnus is pulled medially.
 15. The interval is opened between these two muscles until the femur is palpated. As soon as the femur is palpated, the finger should be turned around and the space between the linea aspera inserting into the femur and the femoral shaft carefully palpated to identify the sciatic nerve. When the sciatic nerve has been identified definitely, it feels like an overcooked, soft noodle and does not tighten like the hard tendon superficial to it (Figure S3.1.7).

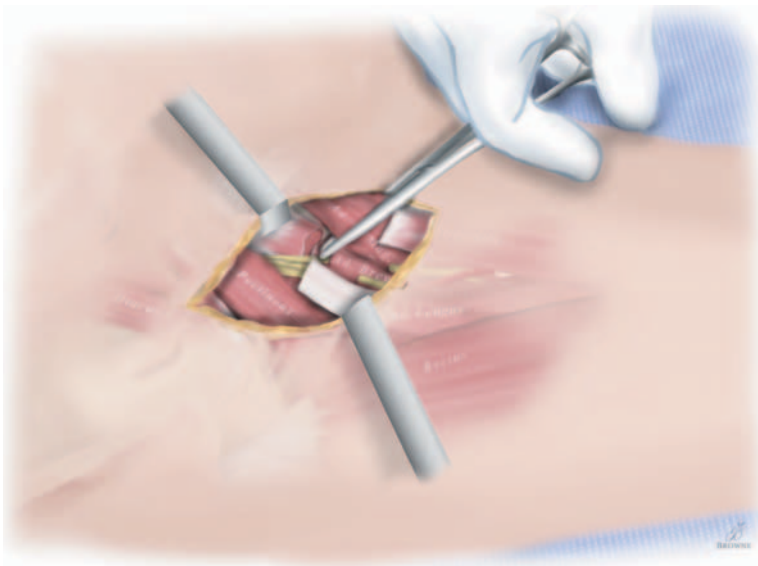


Figure S3.1.6

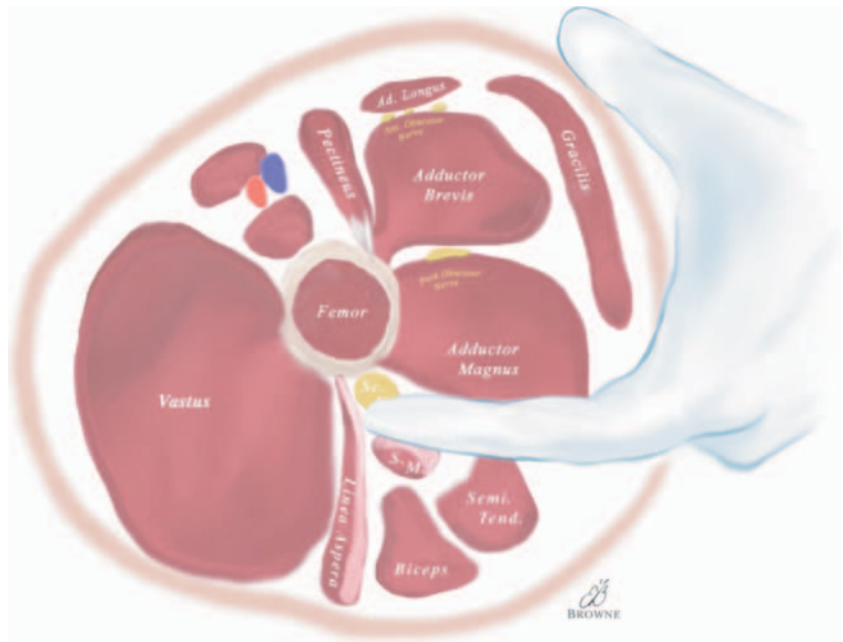


Figure S3.1.7

16. The finger is placed past the nerve, turned 180°, and all the muscles superficial to the nerve are swept up. These muscles should include the semitendinosus, semimembranosus, and long head of the biceps (Figure S3.1.8). A right-angle clamp is then placed around this muscle mass and the finger is removed (Figure S3.1.9).

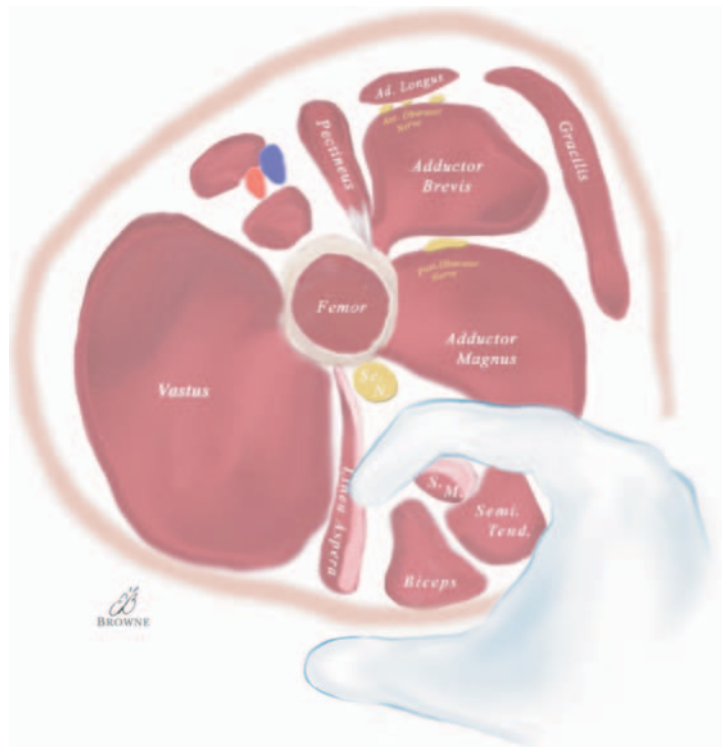


Figure S3.1.8

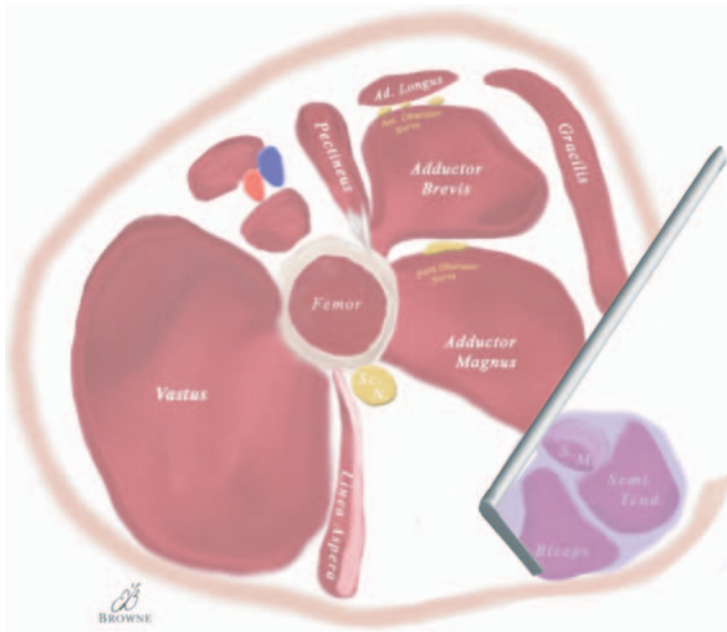


Figure S3.1.9

17. A retractor is placed along the medial wound and another right-angle retractor is used to pull up bunches of this muscle. Care is taken to ensure that it is red muscle that is being transected with electrocautery. All white structures should be checked with a battery-powered nerve stimulator and the child must be nonparalyzed to make sure that there is no damage to the sciatic nerve or inadvertent cutting of the sciatic nerve. In general, the biceps femoris muscle comes up first, followed by the semitendinosus, and then the hard, white tendon that remains is the semimembranosus, which is most easily confused with the sciatic nerve. There will be some muscle fibers attached to the semimembranosus and it does have the appearance of a tendon. However, it is absolutely mandatory to make sure that it is tendon by both stimulation and visual inspection before it is transected.
18. Closing the longitudinal incision in the fascia over the adductor longus with a running tight suture closes the wound. The transverse wound is closed by a subcutaneous running closure and then the skin is closed with a subcuticular suture. It is very important to do a watertight closure of this wound to avoid any leaking of the deep hematoma. The wound should be covered with a watertight plastic dressing to prevent any soiling from the groin.

Postoperative Care

No postoperative immobilization is used; however if the child has a tendency to lie with the knees flexed, knee immobilizers are provided and used for 6 to 12 weeks during sleep time. Pillows are to be placed between the legs when the child side lies, and prone lying is encouraged. The majority of the postoperative pain is resolved by 4 weeks. If proximal hamstring lengthening was performed the physical therapist should be instructed to avoid straight leg raising stretches and long sitting unless the child is completely comfortable because postoperative sciatic nerve palsy can occur.

2. Iliopsoas Lengthening: Over the Pelvic Brim Approach

Indication

This approach is another alternative to perform a myofascial lengthening of the psoas tendon. The advantage is less difficult exposure of the muscle tendon junction in children with significant contractures; however, the difficulty is that the tendon of the psoas is on the deep and most medial aspect of the iliacus muscle. There are no specific indications to using this approach compared to the medial approach. The surgeon's comfort with the specific anatomy is usually the determining factor.

Procedure

1. The incision is along the iliac crest for 5 cm extending slightly medial to the anterior superior iliac spine (Figure S3.2.1). The incision is carried down through the subcutaneous tissue, the fascia is opened just medial to the iliac crest, and the muscle compartment of the iliacus muscle is entered in the iliac fossa.
2. The dissection is carried medially and posterior to the deep border of the iliacus muscle. A right-angle clamp is then passed around the deep border and the psoas tendon is delivered laterally and anteriorly. This is easiest to perform if the hip is flexed so the psoas is relaxed. Often muscle fibers of the iliacus have to be spread to locate the psoas tendon, because the psoas tendon is covered by iliacus muscle except for the far posterior medial edge, which cannot be visualized with this approach (Figure 3.2.2).
3. After the tendon is visualized, it is transected leaving all the surrounding muscle fibers intact. This is a very large tendon and the entire tendon has to be transected or no lengthening will occur.
4. Closing the fascia, subcutaneous tissue and skin closes the wound.

Caution: When doing the medial dissection to find the psoas tendon, it is important to stay within the iliacus muscle compartment because the femoral nerve and artery are immediately on the anterior and medial surface of the

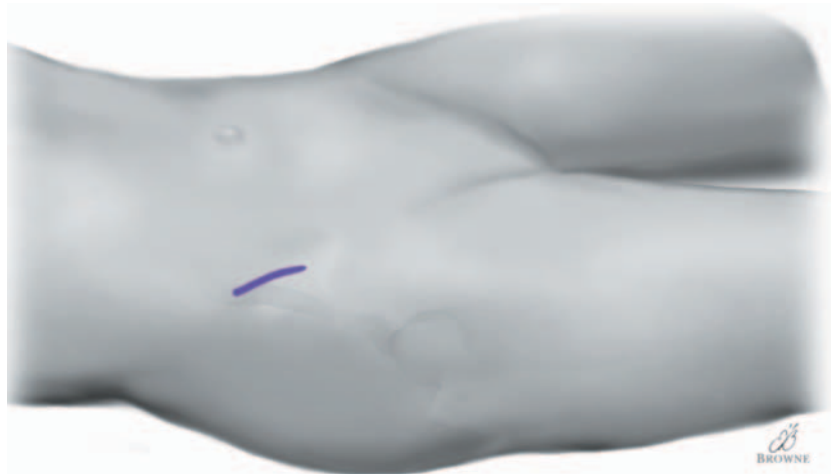


Figure S3.2.1

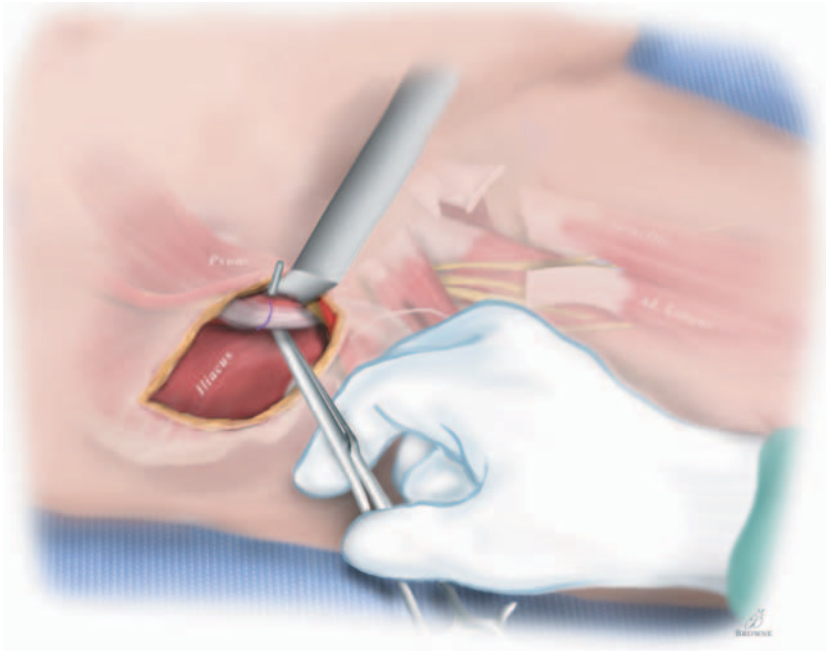


Figure S3.2.2

fascia enveloping the iliacus muscle. It is easier to retract the femoral nerve if the hip is flexed during the dissection.

Postoperative Care

No immobilization is required. Strengthening exercises and aggressive extension stretching should be avoided for 6 weeks.

3. Proximal Femoral Osteotomy

Indication

The proximal femoral osteotomy may be utilized for femoral shortening, providing varus, derotation, or flexion extension correction. Each of these indications for proximal femoral osteotomy is discussed in this procedure, which is all based on the placement of the chisel into the proximal femur.

Procedure

1. The incision is made longitudinally from the flare of the greater trochanter approximately 6 cm distal, with the larger child needing a slightly longer incision and a smaller child needing a smaller incision. Subcutaneous tissue is divided to the fascia latae. The fascia latae is divided in line with the incision, extending both proximally and distally longer than the incision (Figure S3.3.1).
2. A self-retaining retractor is placed, and the vastus lateralis muscle is identified with its insertion point into the proximal femur just distal to the trochanteric apophysis. This retractor also identifies the proximal origin of the apophysis of the femur. The trochanteric bursa should be cleaned off so that good visualization is obtained of this proximal end.



Figure S3.3.1

3. Electrocautery is utilized and the origin of the vastus lateralis is incised transversely from anterior, curved across the lateral aspect of the femur to posterior, and slightly curving distally. Care is taken to make a sharp cut with the electrocautery in this transverse cut all the way to the bone. In the midlateral aspect of the femur, the fascia of the vastus lateralis is incised from the transverse cut proximally to as far distal as possible (Figure S3.3.2).
4. Using Cobb elevators at the distal end of this opening, subperiosteal dissection of the femur is undertaken and retractors are placed.
5. Subperiosteal dissection of the proximal femur is continued, lifting the anterior half of the vastus lateralis anteriorly so a clear definition of the anterior flat surface (Figure S3.3.3) of the extraarticular femoral neck can be visualized. This flat surface on the proximal femur often has several veins entering the bone that should be cauterized to avoid blood loss. The posterior aspect of the vastus lateralis is stripped off the proximal femur as well, making sure that under the posterior proximal end of the femur can be palpated.
6. Using fluoroscopic control, the blade plate insertion site on the lateral aspect of the femur is identified based on the goal of angular correction. Planning should be from a true anteroposterior radiograph, which will allow the definition of the true neck shaft angle (Figure

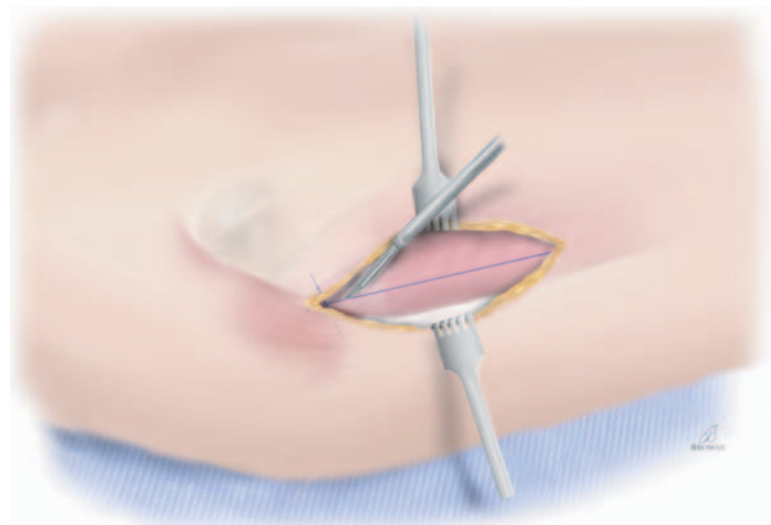


Figure S3.3.2

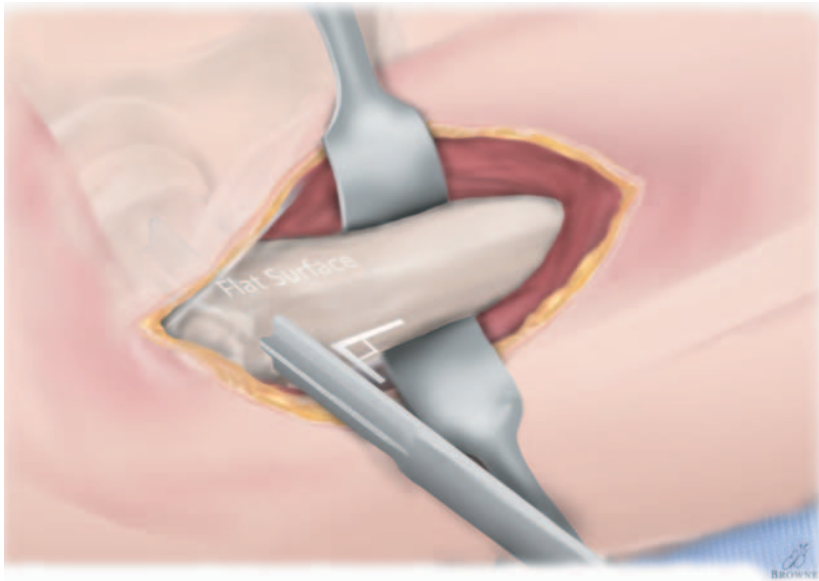


Figure S3.3.3

S3.3.4, line A, angle B). The desired degree of femoral neck shaft varus is chosen (Figure S3.3.4, line A1, angle B1). The angle of insertion of the chisel into the femoral neck is the amount of correction to be created (Figure S3.3.4, angle B minus B1) plus the angle of the plate that will be used (usually a 90° or 100° angle plate is used) (Figure S3.3.4, angle C). To measure this insertion angle from the lateral femoral cortex, this insertion angle has to be subtracted from 180° (Figure S3.3.4, angle F).

7. The size of the chosen blade plate should be between 50% and 75% of the width of the femoral neck, which can be determined by placing the hip into a lateral position, using the plate on the lateral side

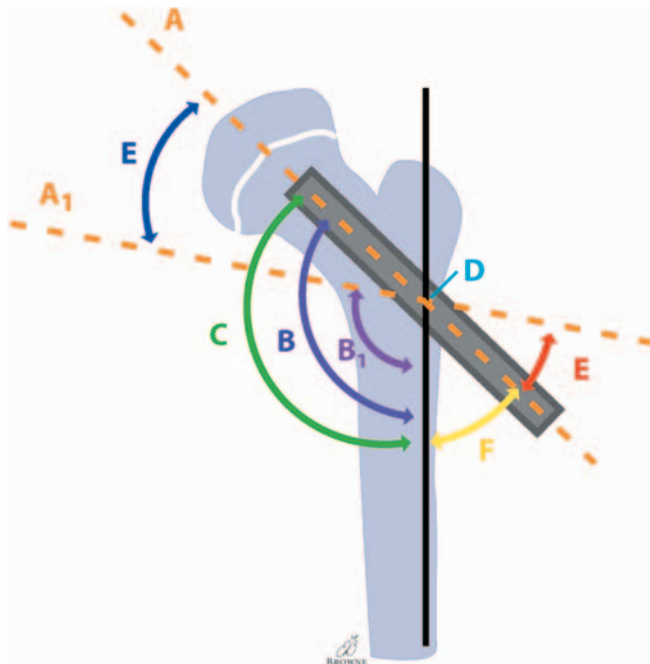


Figure S3.3.4

of the femur, and then determining whether the plate will meet this criterion. Also, looking at the lateral side of the femur, the plate should take up 50% to 75% of the width of the femur as well.

8. The insertion site into the femur is determined by whether there should be a varus osteotomy or whether there is no attempt made for a varus osteotomy. If the child is having only derotation, then the entrance point for the blade plate should be just distal to the apophysis of the greater trochanter, avoiding entering into the greater trochanteric apophysis, but being close to the apophysis. If only derotation is to be performed and a 90° angle plate is to be used, then the blade plate should be entered at 90° to the femoral shaft (Figure S3.3.3). If a 100° blade plate is to be used, then the angle with the blade insertion to the femoral shaft should be 80° (Figure S3.3.4, Angle F). If varus osteotomy is to be performed, the angle in which the blade plate chisel is entered into the femoral neck determines the degree of varus osteotomy that will be obtained (Figure S3.3.4, Angle F). Therefore, if the blade plate chisel is inserted parallel to the femoral neck, there will be a 90° neck shaft angle at the conclusion of the procedure. In most children, the goal is to have a neck shaft angle of 110° to 120°; therefore, the chisel should enter angled 20° to 30° inferior to the axis of the femoral neck. If the goal is obtaining flexion extension correction, then the blade plate chisel should be rotated away from parallel with the long axis of the femur to either flexion or extension, depending on the deformity to be corrected (Figure S3.3.5).
9. After determining the goal for varus, valgus, and flexion extension correction, the blade plate chisel is inserted up the femoral neck under direct visualization using the anterior flat plane to direct the anterior posterior angulation. It is not necessary to use fluoroscopy for this part of the procedure; however, surgeons who are less familiar with the procedure may want to monitor the progression of the chisel with fluoroscopy.
10. For surgeons who have no experience using this device, it is wise to use a guide pin into the femoral neck. This guide pin should be placed

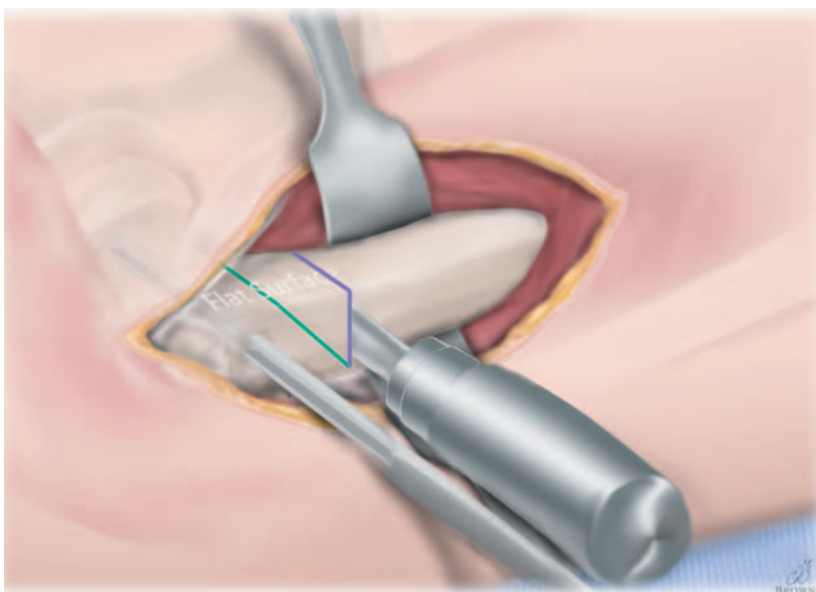


Figure S3.3.5

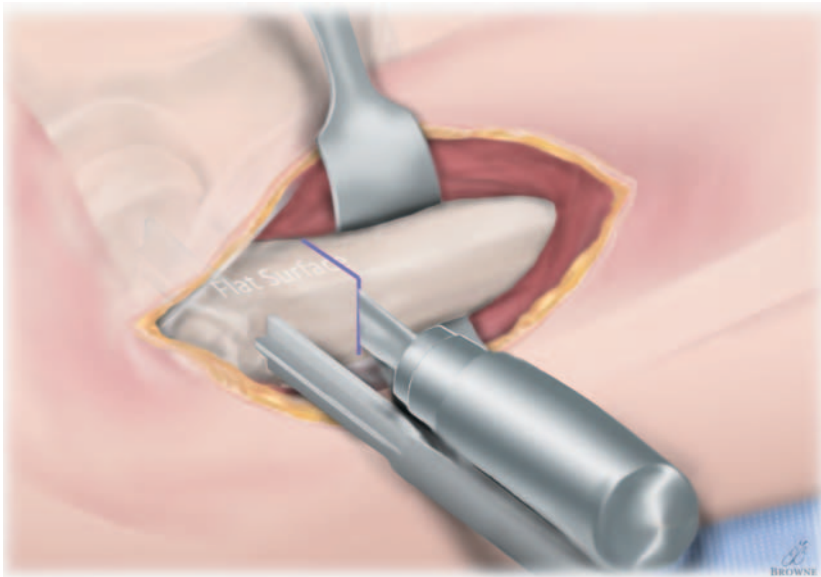


Figure S3.3.6

across the anterior flat plane through the hip capsule and slightly tapped into the femoral head. On the anteroposterior image of the fluoroscope, this pin placement should be exactly where you intend to place the chisel. On the lateral image the pin should be seen lying immediately anterior and completely parallel to the femoral neck. This pin is then used as the guide to insert the chisel.

11. After chisel insertion, the pin is removed and another pin is drilled in directly anterior to the inserted chisel. The chisel can then be removed and this pin is used as the guide to insert the blade plate. For experienced surgeons these pins are not needed; however, it is important to remember that after the blade plate chisel is inserted, you must not remove and reposition the chisel because it likely will cause a complete cutting or osteotomy of the proximal femur, making fixation extremely difficult. For this reason, it is very important that the chisel be placed one time and in the correct position.
12. After the chisel has been placed, the decision of where the osteotomy should be performed is made. If the goal is performing a substantial varus osteotomy, ensure that an intertrochanteric cut is made along with resection of the lesser trochanter. In this circumstance, the minimum amount of cut should be chosen with respect to the distal direction of the osteotomy. The minimum distance from the chisel insertion site is determined from the size of the plate to be used. The distance to the first distal bend in the side plate (Figure S3.3.7, A) is the minimum distance allowed for strong stable fixation. Again, it is very important to make sure that the measurement is not along the hypotenuse of the triangle but along its short right-angle leg. The five different sizes of blade plates each have minimum and maximum lateral displacement distances to make the osteotomy, and these can be measured off the plate to be chosen.
13. The first cut of the osteotomy should be made transverse to the long axis of the femur. After this transverse cut is completed, the second cut starts inside the lateral cortex of the femur, and is made in all planes parallel to the inserted chisel (Figure S3.3.8). This bone wedge, which ideally should include the majority of the lesser trochanter in

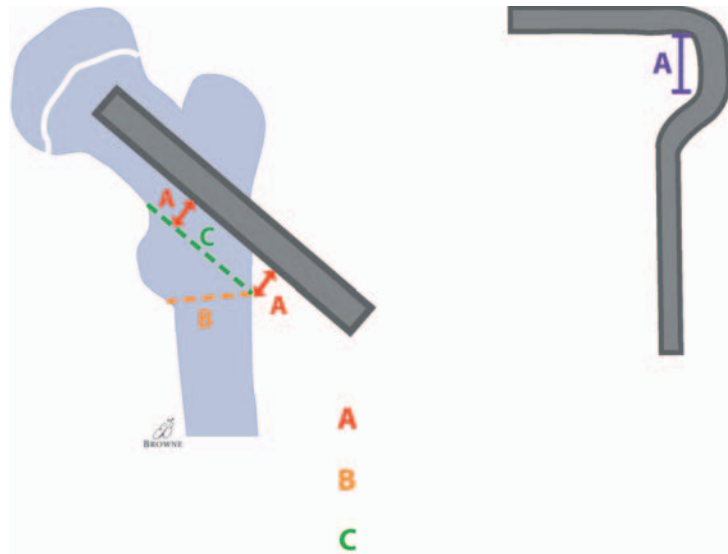


Figure S3.3.7

a nonambulatory child whose hip is being reconstructed, then is removed (Figure S3.3.9).

14. Make sure that the tendon of the iliopsoas, if it is still intact, is transected in the tendinous portion to avoid the development of a long, thin piece of heterotopic ossification or an extremely elongated lesser trochanter. An extremely elongated lesser trochanter occasionally is seen after reconstruction when the apophysis of the lesser trochanter was left intact. If only derotation is being performed, there will be no bone wedge to remove (Figure S3.3.6).
15. If this child is having a reconstruction for hip dislocation and is not able to achieve at least 20° to 30° of abduction of the hip with the hip completely located by fluoroscopic imaging, then a medial capsulotomy should be performed.
16. The medial capsulotomy is performed by abducting the proximal segment and placing deep right-angle retractors to retract the soft tissue,

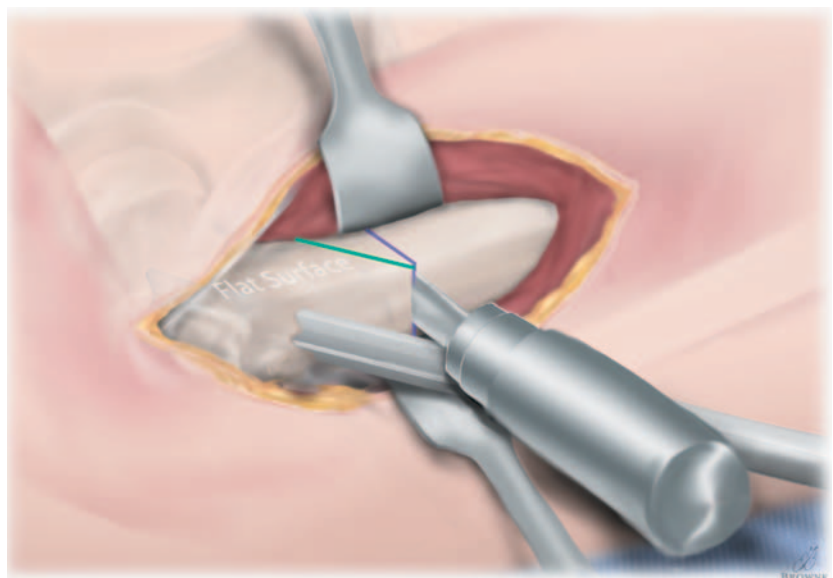


Figure S3.3.8

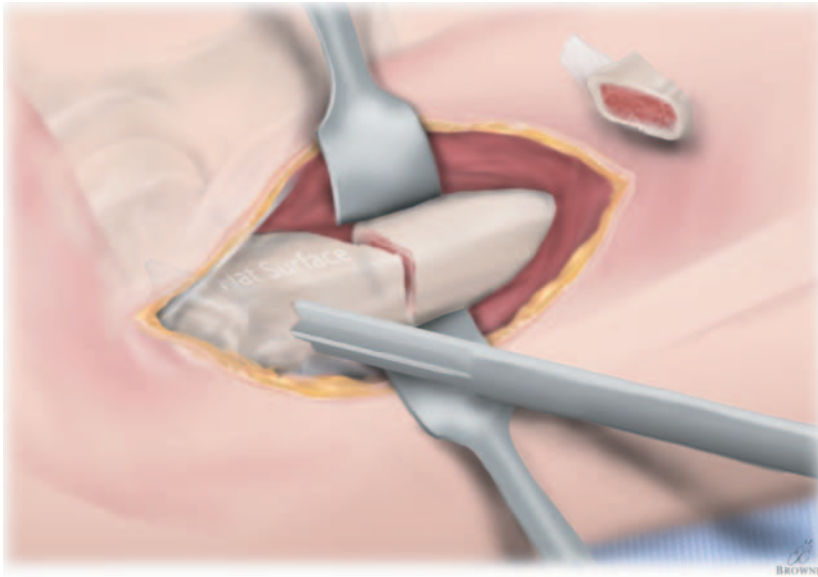


Figure S3.3.9

including the neurovascular structure, superiorly. By palpating up the femoral neck and cleaning off the soft tissues, the femoral neck and the hip joint capsule is readily apparent. This should be incised longitudinally in line with the femoral neck, and then as the hip joint capsule is entered, a transverse incision is made in the hip joint capsule to provide anterior and posterior extension of this opening (Figure S3.3.10). There usually needs to be more posterior medial release than anterior medial release. However, this medial release has to be done in sections and enough lengthening performed until there is adequate abduction and the hip is well reduced into the acetabulum.

17. If the child is to have a pelvic osteotomy, the wound is now packed, and attention is directed to the pelvic osteotomy.
18. If no pelvic osteotomy is to be performed at this stage, the bone clamp is placed on the proximal fragment of the femur to make sure that there is continued proximal control.

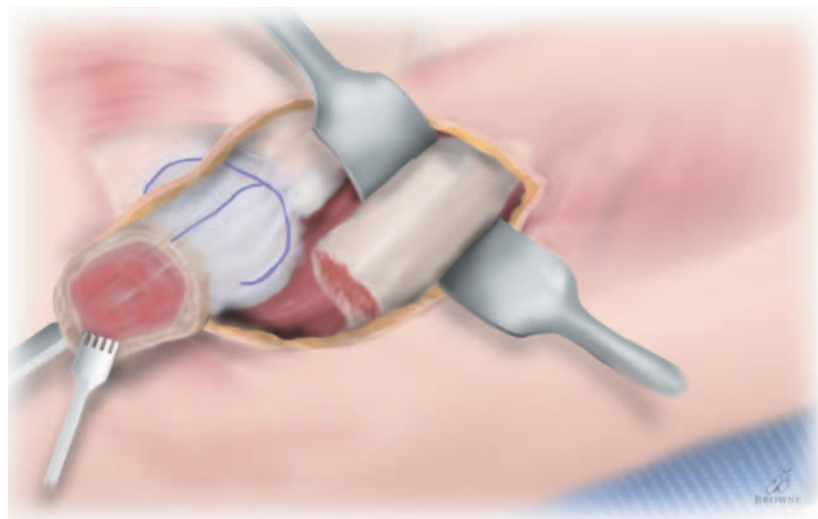


Figure S3.3.10

19. The blade plate chisel is then removed from the femur and the properly sized blade plate is chosen and placed into the exact chisel cut. Continuous careful conscious direction is very important when placing the blade plate. This can be accomplished by monitoring the anterior flat plane to get the correct anterior posterior direction, and by making sure that the blade continues to be parallel to the osteotomy cut on the proximal femur. This cut was made parallel to the blade plate originally. The plate is completely impacted.
20. If the cut was made such that the bone protrudes distally on the lateral surface past the first bend in the lateral protrusion, a saw should be utilized to trim off a corner so it fits well into this rounded contour. The blade plate is impacted until it is in contact on the lateral side. **Do not saw or remove the lateral bone spike beyond that needed for the plate to contact the inferior bend in the lateral offset of the plate. Removing more of this bone greatly weakens the construct by removing lateral cortex, which provides the strength for the tension band effect that is required for this system to be strong.**
21. Verbrugge clamps then are utilized to clamp the distal fragment of the bone to the distal end of the plate.
22. At this point, use great care to ensure that the rotational alignment is correct because the derotation is corrected in this part of the procedure. First, make sure that the femoral neck is roughly parallel to the knee joint axis. Then, check that internal rotation is present to at least neutral. Make sure that the child has external rotation and at least internal rotation to neutral in the sitting position (Figure S3.3.11). In the ambulatory child, the goal is to have approximately equal internal and external rotation with the hip extended (Figure S3.3.12) and preferably about twice as much external as internal rotation with the hip flexed. The anterior flat surface can be compared with the flat surface on the distal fragment to evaluate how much derotation was performed, which typically ends up somewhere between 20° and

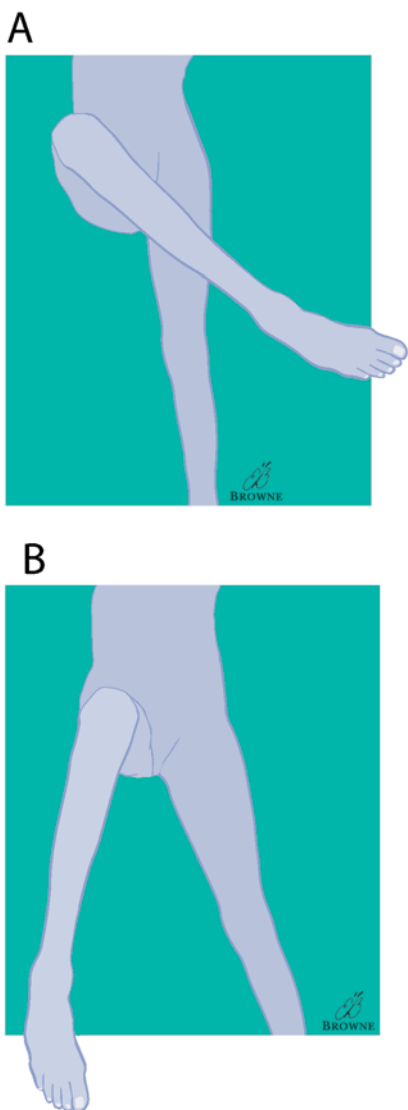


Figure S3.3.11

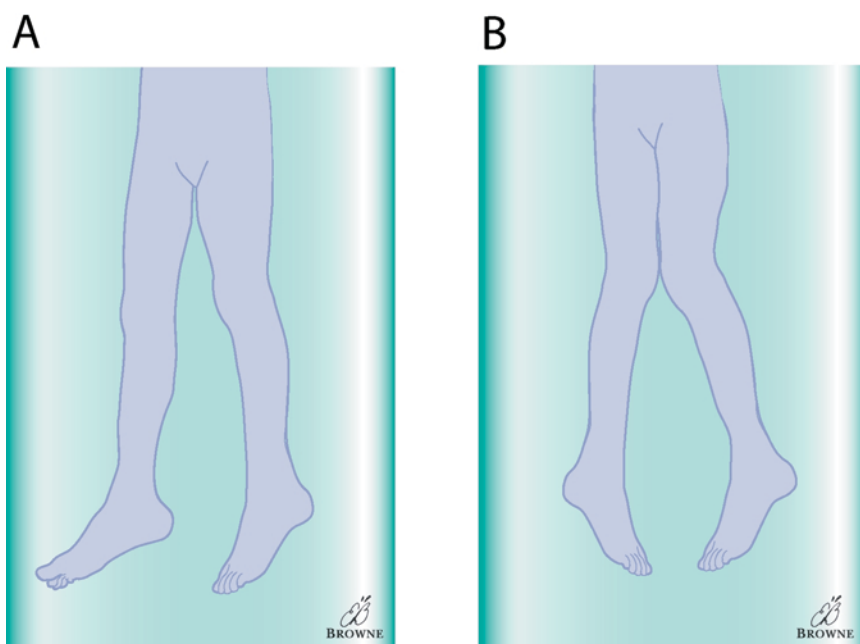


Figure S3.3.12

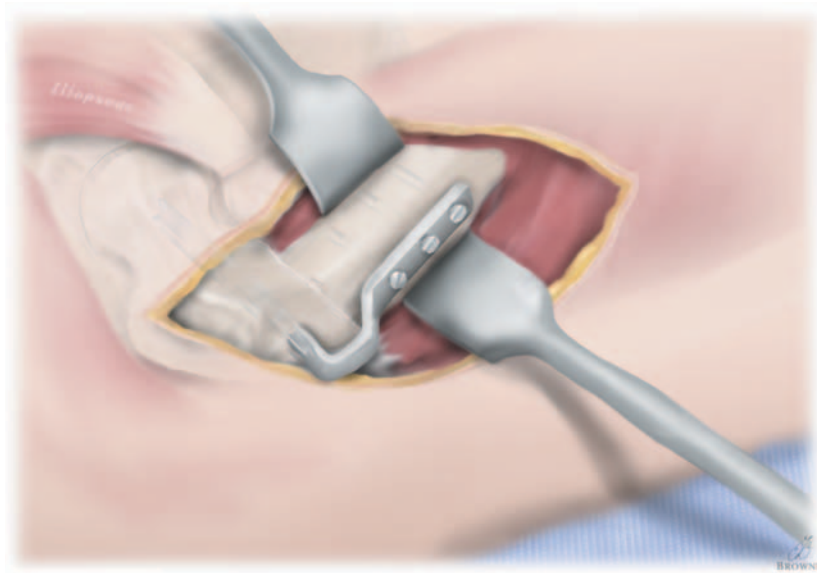


Figure S3.3.13

Ed:
This is the revised figure file from Jays
named S3.3.13. Is it correct?

- 40° (Figure S3.3.13). If this angle is 70° or 80°, use caution to ensure that not too much derotation was performed. There is never an indication to leave the hip in significant retroversion because it might cause a posterior dislocation.
23. A compression screw then is placed in the second hole of the side plate. The rotation is again checked after placement of this screw and removal of the Verbrugge clamps. Another compression screw then is placed, followed by a neutralization screw (Figure S3.3.13). Following the reduction, the medial cortex of the femur should be in complete contact and under compression, often with a little opening of the lateral aspect of the osteotomy (Figure S3.3.14).
 24. The vastus lateralis is closed over the lateral aspect of the plate to provide some soft-tissue coverage. Closure of the fascia latae provides additional coverage of the plate, which then is followed by closure of the subcutaneous tissue and skin closure.

Postoperative Care

Except for rare cases of extreme osteoporosis, no external cast immobilization is required. Anterior/posterior and frog lateral pelvis radiographs with good positioning should be made in the operating room before the child awakens from the anesthesia (Figures S3.3.15 and S3.3.16). These radiographs provide a good baseline should there be later concerns about the position of the osteotomy or the hardware. Physical therapy is initiated on the first or second postoperative day with passive range of motion and mobilizing the child out of bed to the wheelchair. Activity is advanced with full weight bearing, usually with the goal of assisted ambulation before discharge from the hospital on day 4 to 7 after surgery. The first radiograph is obtained 4 weeks after surgery and should show some callus formation. Most children have very minor pain by this time and are making progress toward better ambulation. Independent ambulation to the child's preoperative level is not expected until 3 months after surgery. Improvement in the child's gait pattern should be expected up to 1 whole year after surgery.

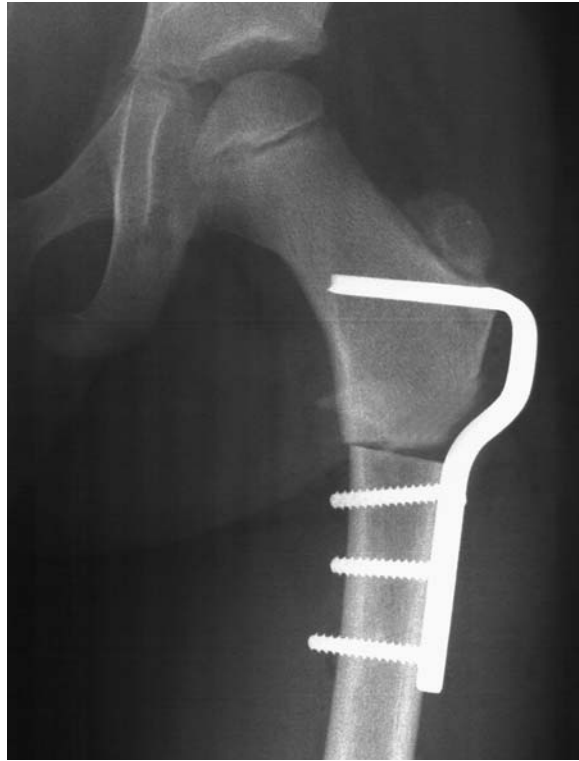

Figure S3.3.14

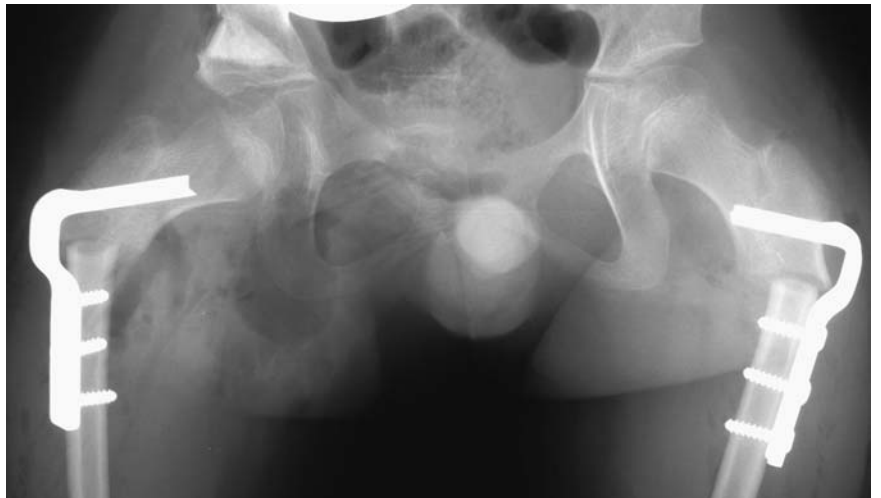

Figure S3.3.15

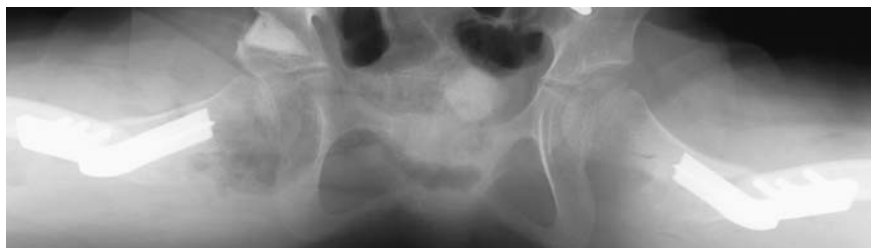

Figure S3.3.16

4. Peri-iliac Pelvic Osteotomy

Indication

The peri-iliac pelvic osteotomy almost always is performed in conjunction with a femoral varus and shortening osteotomy. It is indicated to correct the posterior superior acetabular dysplasia caused by the most common spastic hip disease.

Procedure

1. An incision is made in the bikini line approximately 1 cm medial to the anterior superior iliac spine and extended laterally for approximately 4 cm (Figure S3.4.1). The incision is carried down to the subcutaneous tissue until the fascia is identified.
2. The subcutaneous tissue then is elevated off the fascia until the iliac crest is identified (Figure S3.4.2).
3. A sharp incision is made in the iliac crest halfway between the medial and lateral sides, directly through the apophysis of the iliac crest from as far posterior lateral to the anterior superior iliac spine.
4. Subperiosteal dissection of the lateral wall of the ilium then is performed, using care to bring the whole iliac apophysis off starting posteriorly. This dissection is packed with a 4 × 4 sponge (Figure S3.4.3).
5. Subcutaneous dissection is performed distal to the anterior superior iliac spine in the anterior medial aspect of the wound.
6. The interval between the sartorius and fascia latae is opened, being careful to preserve the lateral femoral cutaneous nerve. The interval between the sartorius and fascia latae is opened down to the anterior inferior iliac spine at the insertion of the direct head of the rectus femoris.
7. Retractors are placed to hold this interval open, and the iliac crest between the anterior inferior iliac spine to the anterior superior spine is palpated.

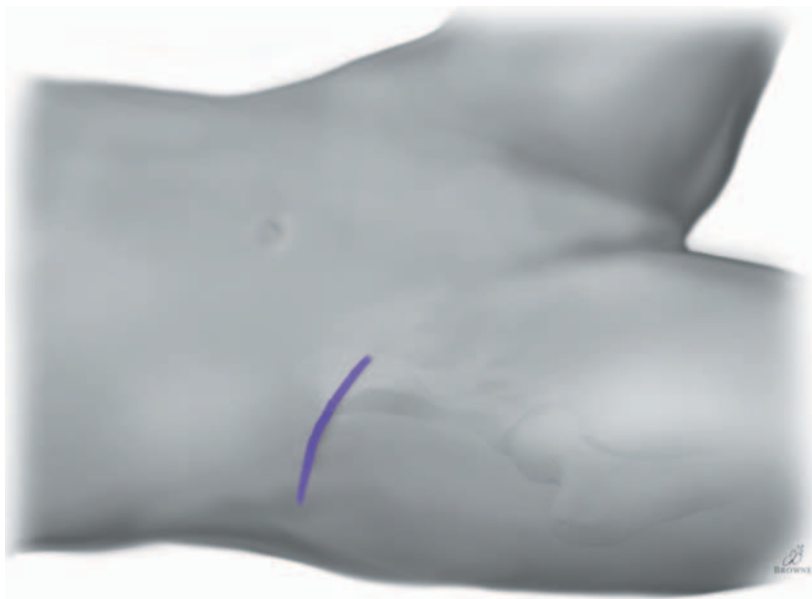


Figure S3.4.1

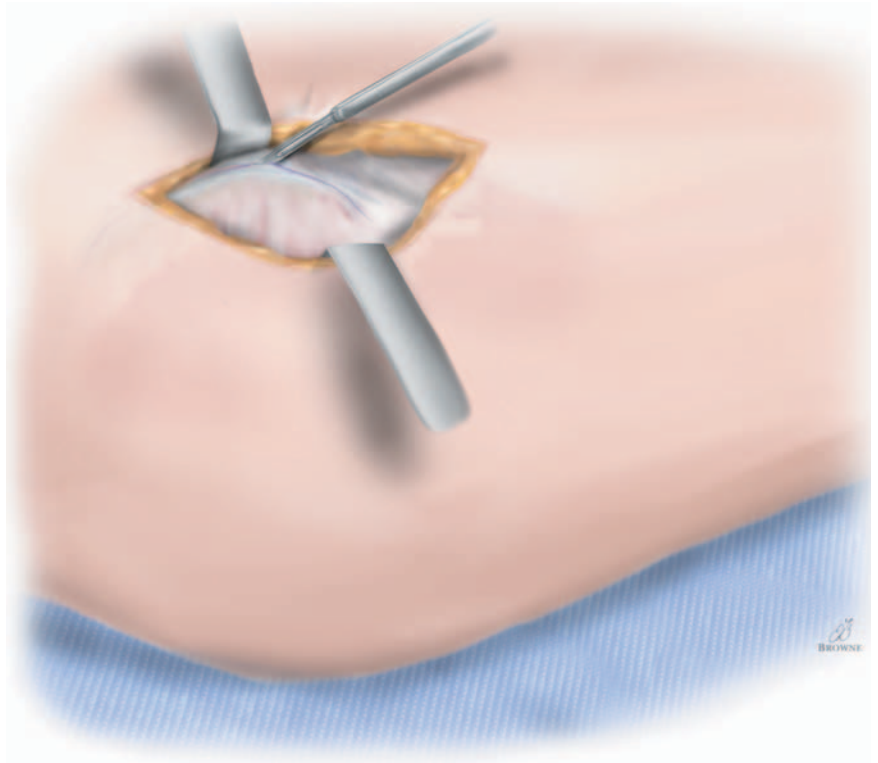


Figure S3.4.2

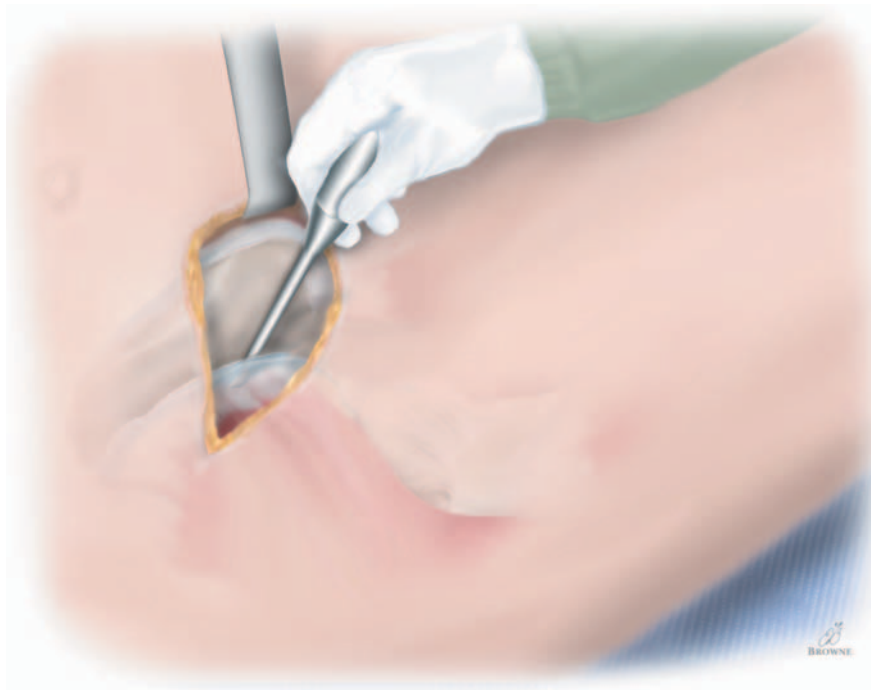

Figure S3.4.3

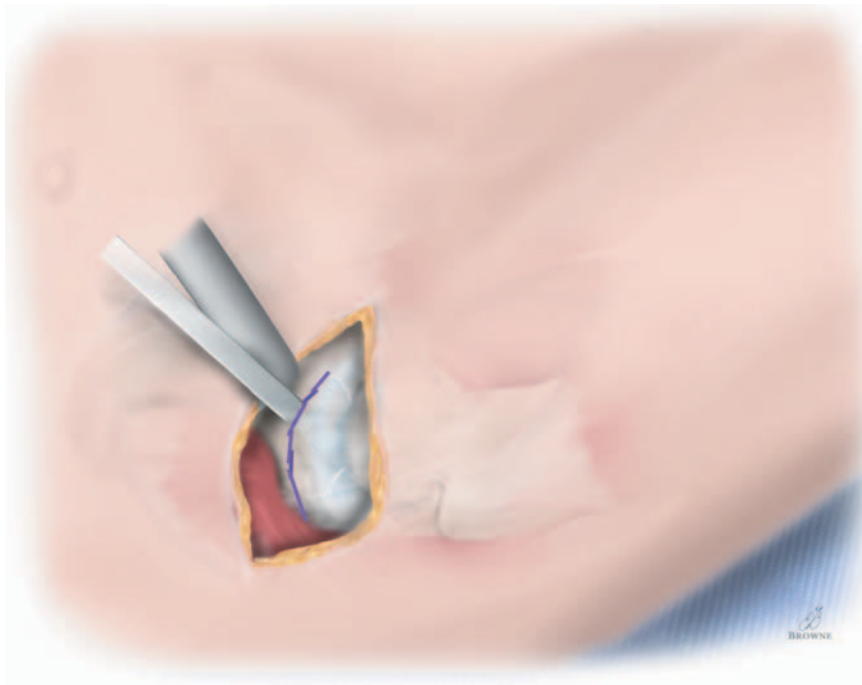


Figure S3.4.4

8. Using a sharp scalpel, the anterior inferior iliac spine is incised along the anterior ridge to the anterior superior spine.
9. Subperiosteal dissection of the lateral aspect of the ilium then is performed. This dissection allows subperiosteal exposure right down to the origin of the hip joint capsule (Figure S3.4.3).
10. At the area where the origin of hip joint capsule is identified, subperiosteal dissection is extended posteriorly and inferiorly to the level of the triradiate cartilage.
11. Fluoroscopic control then is utilized, and a straight 1-cm wide osteotomy is inserted midway between the medial and posterior aspect of the acetabulum, making sure to keep the osteotomy in direct lateral profile (Figure S3.4.4). The osteotomy is entered into the pelvis approximately 5 mm above the hip joint capsule, and then carried down in a straight line to the triradiate cartilage midway anterior to posterior. This insertion usually requires an approximately 30° to 40° anterior to posterior angulation in this cut.
12. The chisel is removed and extended anteriorly, making the next cut parallel to the first cut, but just one chisel width anteriorly. The subsequent anterior cut then is made transversely to detach the anterior inferior iliac spine, leaving it on the distal or acetabular fragment. This most anterior cut goes through both medial and lateral cortices of the ilium, but all the remaining cuts are through only the lateral cortex and remain within the body of the ilium (Figure S3.4.5).
13. Attention then is directed to the posterior aspect where the chisel is again entered and another cut is made parallel, angling posteriorly approximately 40° and again aiming for the center of the triradiate cartilage.
14. A Cobb periosteal elevator is placed posteriorly to the triradiate cartilage, and the chisel is placed to make sure that all the cortical bone in this posterior area is cut parallel to the previous cuts.

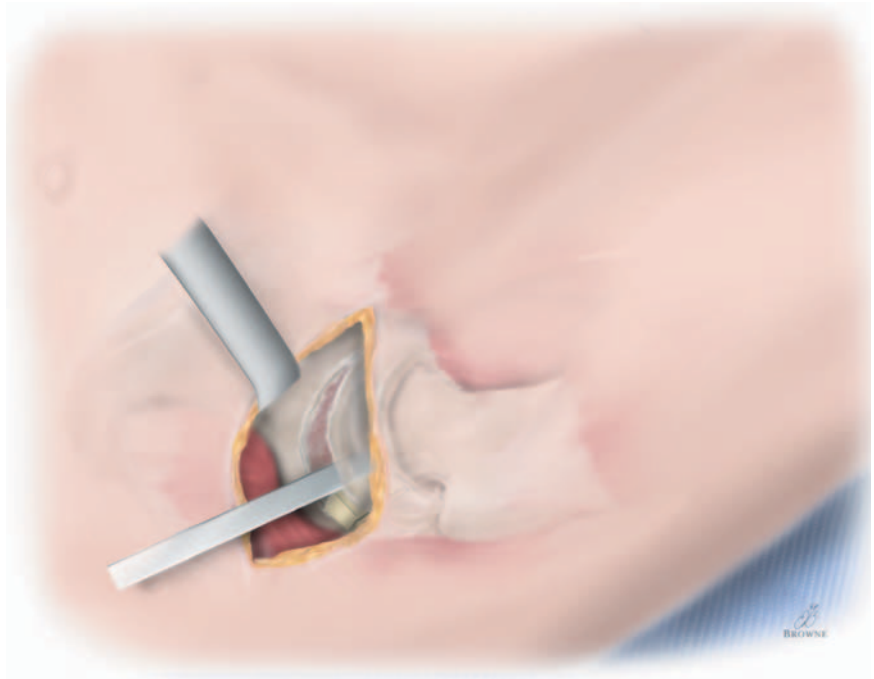


Figure S3.4.5

15. After all this bone has been cut, the osteotomy should be wedged forward and will have a good opening of the acetabular osteotomy. Wedging the osteotomy forward will be much easier to perform if the anterior cut has gone through both cortices.
16. At this point in the procedure, a tricortical iliac crest bone graft specimen from the bone bank is obtained. This bone graft specimen should be at least 1 cm in height and should have at least a 3- to 5-mm thickness of cortical bone surrounding the whole block. In most children, a height of 8 to 10 mm is chosen for the triangular cut, but again the height is not measured along the hypotenuse or any of the right-angle legs but rather along the maximum height of this triangle.
17. With the osteotome in place, the osteotomy is opened, the triangular-shaped bone graft is inserted as far posteriorly as possible, and a long-handled bone impactor is placed against it, lightly tapping on the bone impactor as the osteotome is withdrawn (Figure S3.4.5). As the osteotomy is withdrawn, it is pulled straight lateral and is not pried out because this will remove the bone graft.
18. The tricortical iliac crest bone graft is then gradually impacted into the osteotomy site until the superior edge is just underneath the cortical bone of the ilium.
19. This impacted bone graft wedges under the superior aspect of the ilium, fixing it so it will not displace and no internal fixation is needed (Figure S3.4.6).
20. An additional anterior or midlateral wedge can be placed if there is room. No attempt should be made to place an excessively large anterior lateral wedge because the first graft should have obtained sufficient coverage.
21. Fluoroscopy is utilized with the blade plate chisel in the proximal fragment. Under active fluoroscopy, the hip joint should be much more stable, only subluxating in extreme positions.

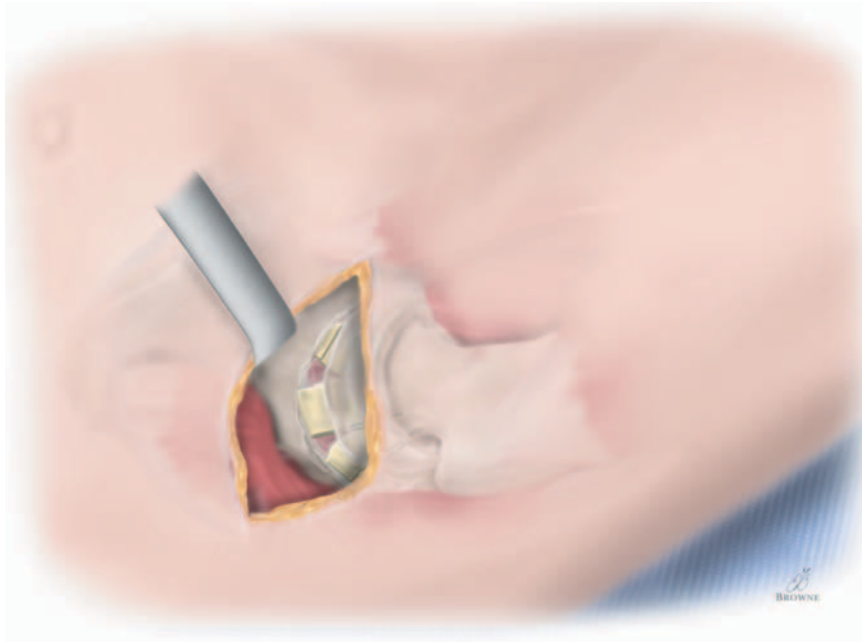


Figure S3.4.6

22. The apophysis of the iliac crest is closed with a running suture using care to reapproximate the apophysis so that growth will not be affected. Tight closure of the fascia anteriorly will prevent any leaking of the iliac crest hematoma as well.
23. Attention again is directed to the femoral osteotomy site where the procedure is continued as described in the femoral osteotomy section. The preoperative X-ray (Figure S3.4.7) should then be compared with the intraoperative X-ray to confirm the reduction and demonstrate good acetabular coverage (Figure S3.4.8).

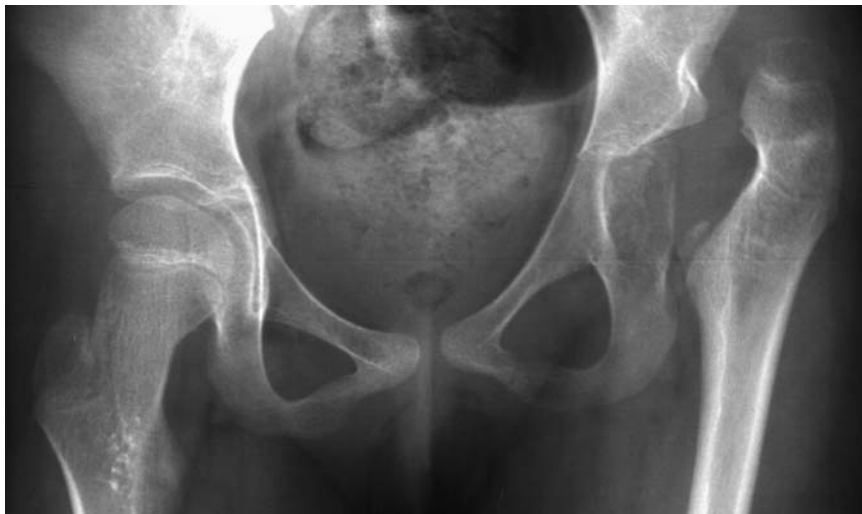

Figure S3.4.7

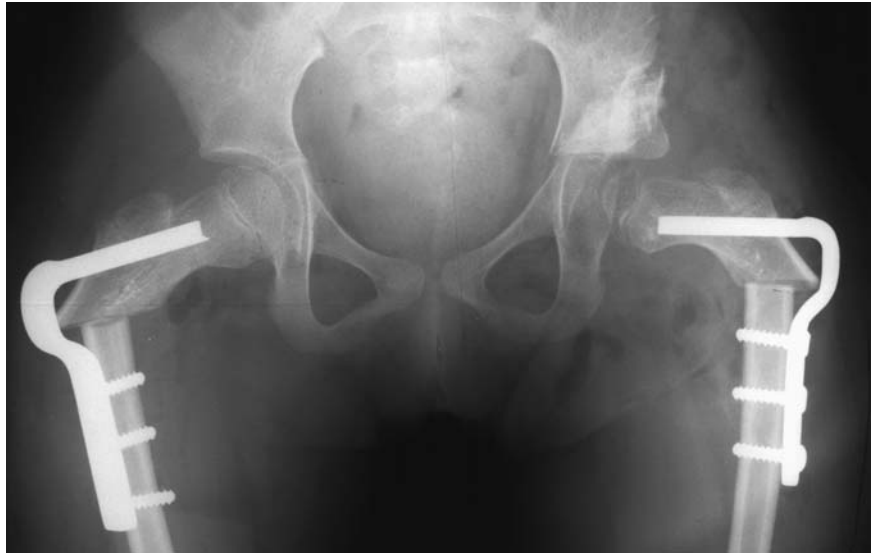

Figure S3.4.8

Postoperative Care

The care is the same as for those who have undergone femoral osteotomy only. No specific care is required for the pelvic osteotomy. Postoperative radiographs should be obtained to provide good baselines for monitoring changes in the implants during the healing phase.

5. Pemberton-Type Pelvic Osteotomy for Anterior Dislocation

Indication

Pemberton osteotomy is only indicated if the direction of the hip dislocation is anterior as documented by a CT scan of the hip.

Procedure

1. An incision in the bikini line or the skin fold of the hip flexion crease is made. This incision is carried 2 to 3 cm medial to the anterior superior iliac spine, and it also should extend 2 to 3 cm lateral to the anterior superior iliac spine (Figure S3.5.1).
2. This incision is carried down through the subcutaneous tissue and then subcutaneous dissection is performed up to the iliac crest (Figure S3.5.2).
3. A sharp incision is made in the iliac crest where it is split in half anteriorly to the anterosuperior iliac spine. Distal subcutaneous dissection then is performed until the interval between the fascia latae and sartorius is identified. The lateral femoral cutaneous nerve should be protected by leaving it with the sartorius (Figure S3.5.3).
4. This interval is opened to the anteroinferior iliac spine, and a sharp incision is made from the anteroinferior iliac spine to the anterosuperior iliac spine.

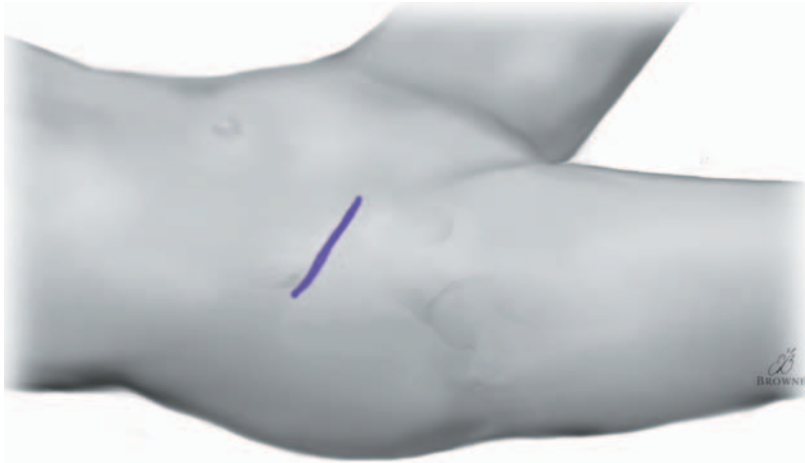


Figure S3.5.1

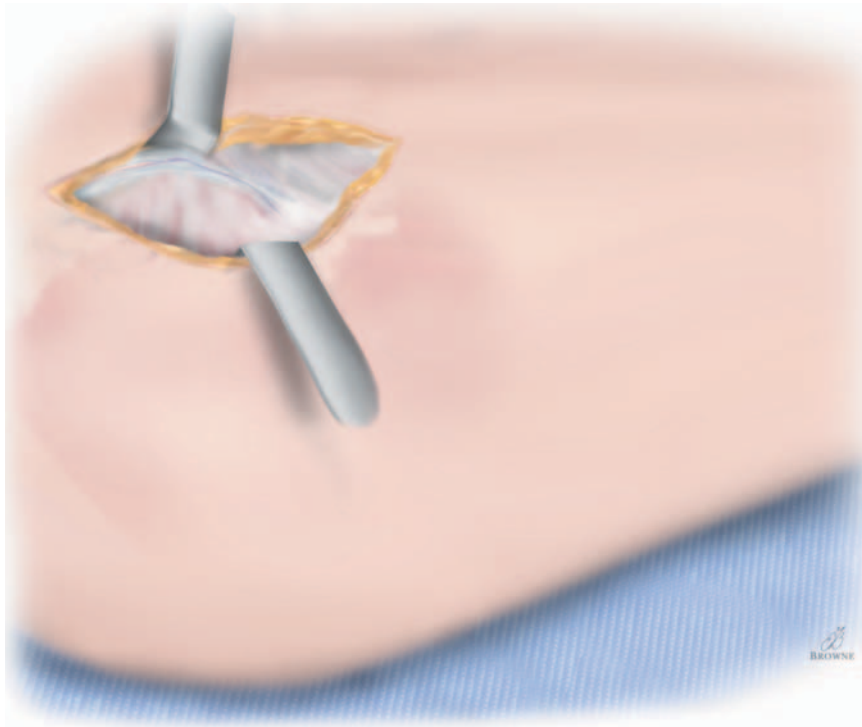


Figure S3.5.2

5. Subperiosteal dissection by spreading of the apophysis then is performed with both medial and lateral walls of the ilium exposed. The incision can be carried medially, stripping the direct head of the rectus with the anteroinferior iliac spine off so the anterior hip capsule can be identified (Figure S3.5.3).
6. With finger palpation the anterior dislocation of the femoral head is readily apparent. This anterior dislocation should have easily reduced after a varus femoral shortening osteotomy; however, if there is any question, the anterior hip capsule can be opened and visual inspection of the hip joint can be performed. This inspection usually is not necessary.

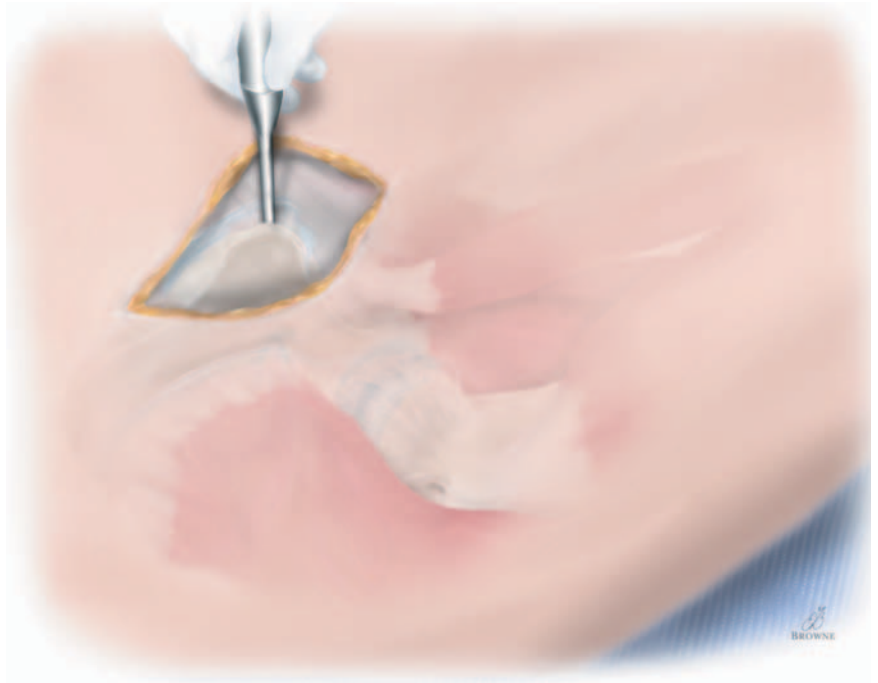

Figure S3.5.3

7. The dissection should extend medially onto the pubic extension of the acetabulum because this is often very deficient in anterior dislocations.
8. Under fluoroscopic control, an anterior to posterior osteotomy is directed toward the transverse limb of the triradiate cartilage through both cortical surfaces of the ilium (Figure S3.5.4).

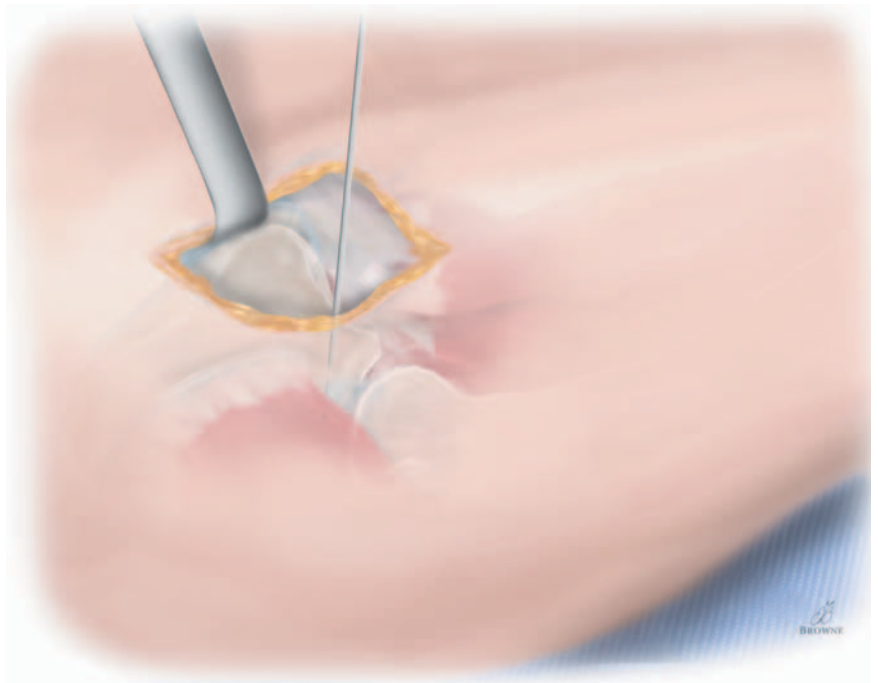


Figure S3.5.4

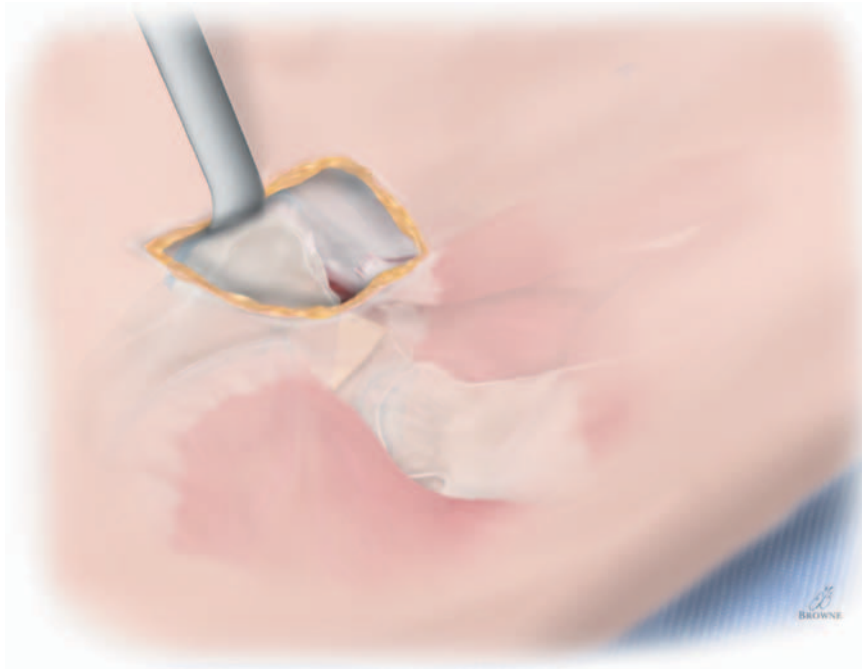

Figure S3.5.5

9. This osteotomy is wedged inferiorly in an attempt to contain the femoral head in the acetabulum. Often, as much as 2 or 3 cm of opening is required to gain stability of the femoral head (Figure S3.5.5).
10. Large tricortical iliac crest bone bank grafts or fibular struts are required to hold this large wedge open, and it is important to extend the osteotomy across into the pubis if there is a hope of gaining sufficient stability (Figures S3.5.6, S3.5.7). The osteotomy has to extend to the transverse arm of the triradiate cartilage, and the opening wedge has to hinge at this point for there to be enough opening (Figure S3.5.8).
11. If the acetabulum cannot be opened sufficiently to gain stability, an inferior capsulotomy may be required to allow the femoral head to drop further down into the acetabulum. This inferior capsulotomy is performed through the lateral femoral osteotomy incision site. However, be very careful to avoid opening the posterior capsule, because many of these hips have global acetabular deficiency and an anterior dislocation can be converted into a posterior dislocation.
12. After femoral head stability is obtained, the apophyses of the iliac crest are again closed, being careful to place sutures midway through the apophyses so the apophyses are not disrupted. Subcutaneous and subcuticular closure follows.

Postoperative Care

Encourage hip flexion, especially sitting with 90° of hip flexion. Passive range of motion is initiated by Physical Therapy on the second day after surgery. No cast immobilization is required.

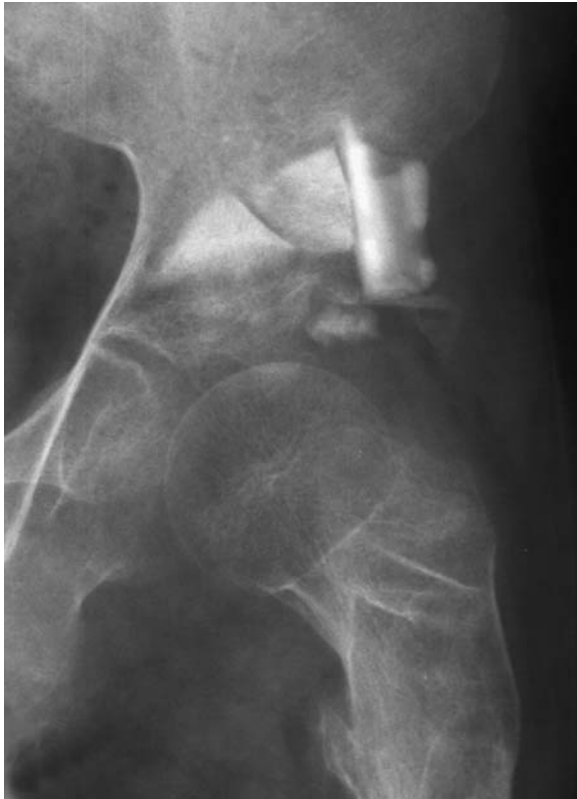

Figure S3.5.6

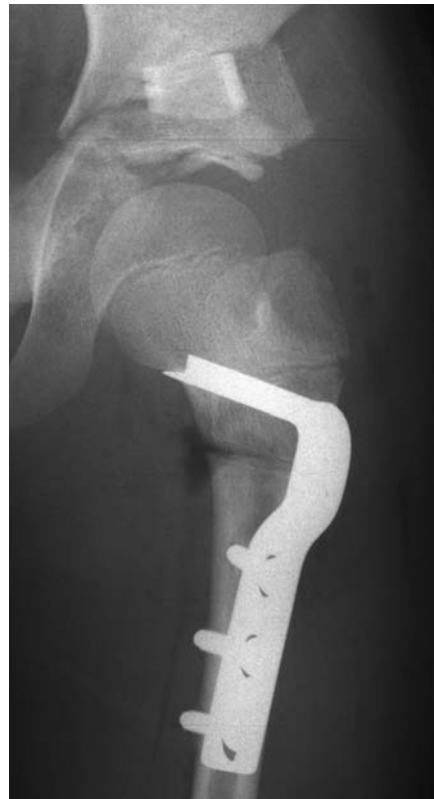

Figure S3.5.7

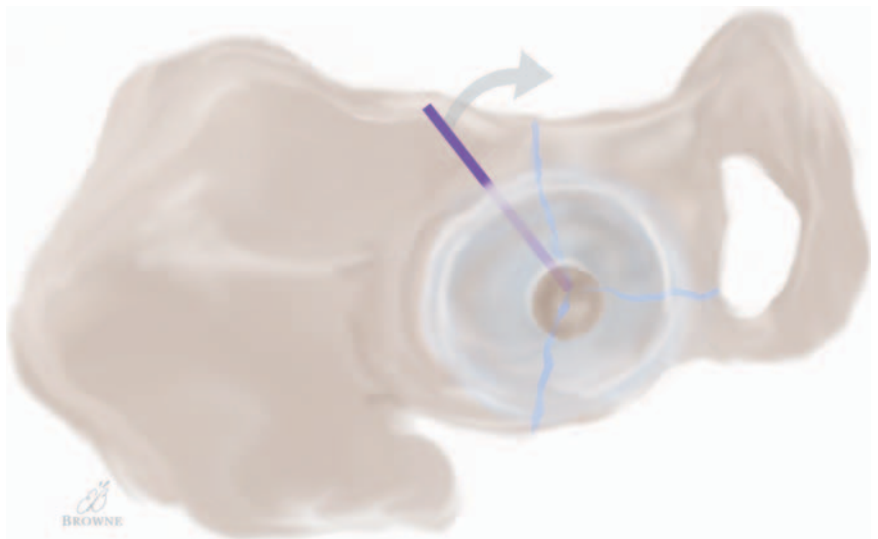


Figure S3.5.8

6. Abductor Lengthening

Indication

Abductor lengthening is indicated for the abduction contracture of a wind-blown deformity or the external rotation abduction contracture associated with the abduction-contracted hip.

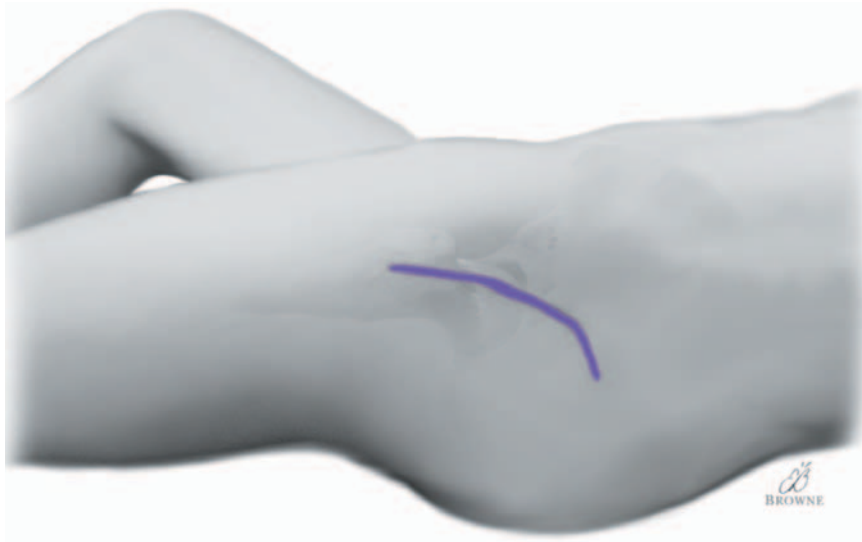


Figure S3.6.1

Procedure

1. The incision should be over the midlateral aspect of the femur, extending proximally over the greater trochanter, and then curved very slightly posteriorly (Figure S3.6.1).
2. The fascia latae is longitudinally incised, but then a dissection using a transverse incision of especially the posterior half of the fascia latae is performed. The anterior half of the fascia latae, if it continues to be tight, also is incised transversely (Figure S3.6.2).
3. The greater trochanter is palpated, and the soft-tissue attachments of the gluteus medius 1 cm proximal to the bony tip of the greater trochanter are incised using electrocautery. These soft-tissue attachments extend posteriorly along the posterior border of the femur (Figure S3.6.3).

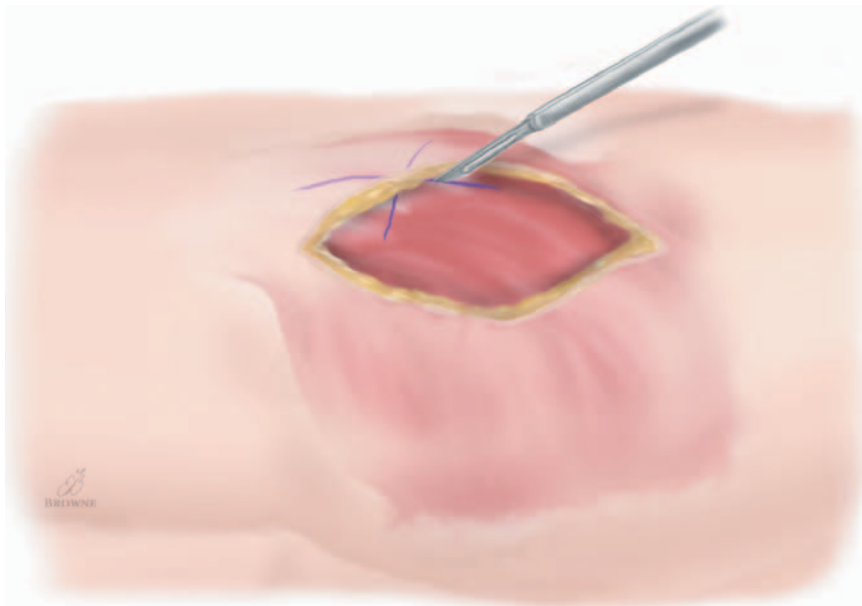


Figure S3.6.2

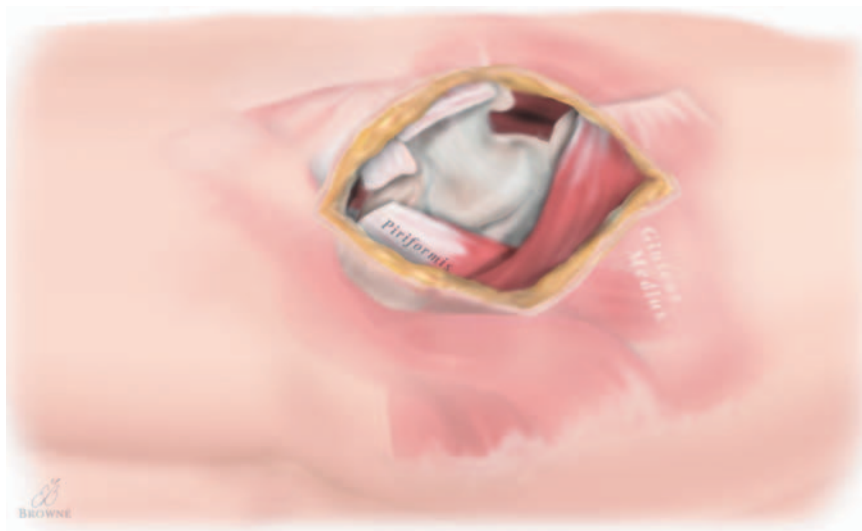


Figure S3.6.3

4. The anterior third of the gluteus medius on the anterior aspect of the greater trochanter usually can be left in place because it typically is not contracted in external rotation abduction contractures. The release must be almost completely along the posterior aspect.
5. Going posterior is very important, especially to identify and transect the piriformis tendon and going further inferior to transect the gemelli (Figure S3.6.3).
6. Next, if more release is needed, the hip joint capsule is exposed, and if the capsule is very tight limiting internal rotation, an incision in the posterior capsule midway between the acetabulum and the femur can be performed safely (Figure S3.6.3).
7. Bleeding points are cauterized, and only the subcutaneous tissue and skin should be closed.
8. This same procedure can be modified for an internal rotation contracture, but the incision should be curved slightly anteriorly. In this circumstance, only the anterior third to anterior half of the abductor is removed. If this procedure is being performed in a child who is non-ambulatory, the whole muscle mass is removed to decrease the amount of internal rotator force (Figure S3.6.4).
9. In an ambulatory child, the anterior part of the muscle is incised; then, with careful retraction, the fascia underlying the abductor is identified and only the fascia is incised to effect a myofascial lengthening of the anterior half of the abductor muscle (Figure S3.6.5).

Postoperative Care

Immediate active and passive range of motion is started on the first postoperative day. Parents are instructed to try to keep the child's hips adducted, or if the release was for internal rotation, to keep the hips externally rotated during sleep at night. This should be accomplished with positioning, not with rigid braces.

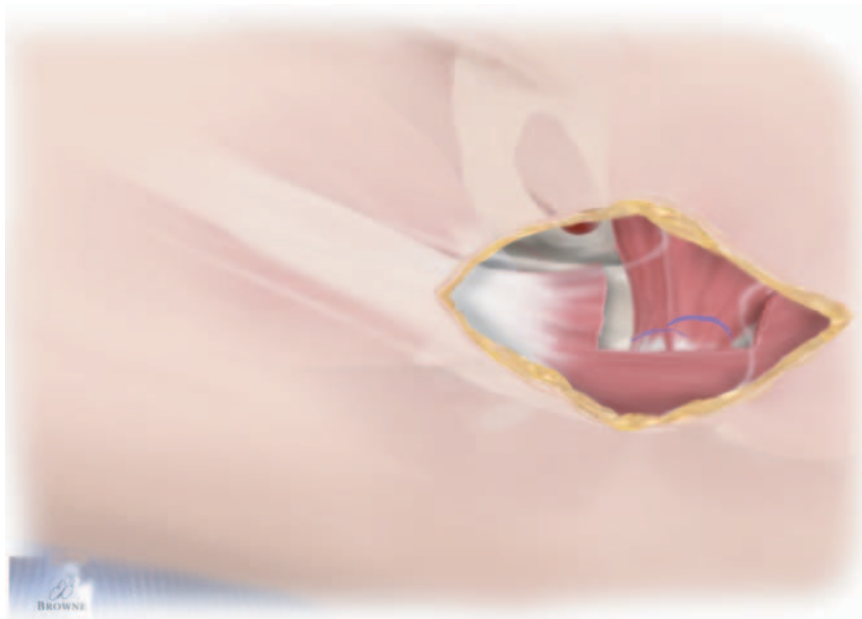


Figure S3.6.4

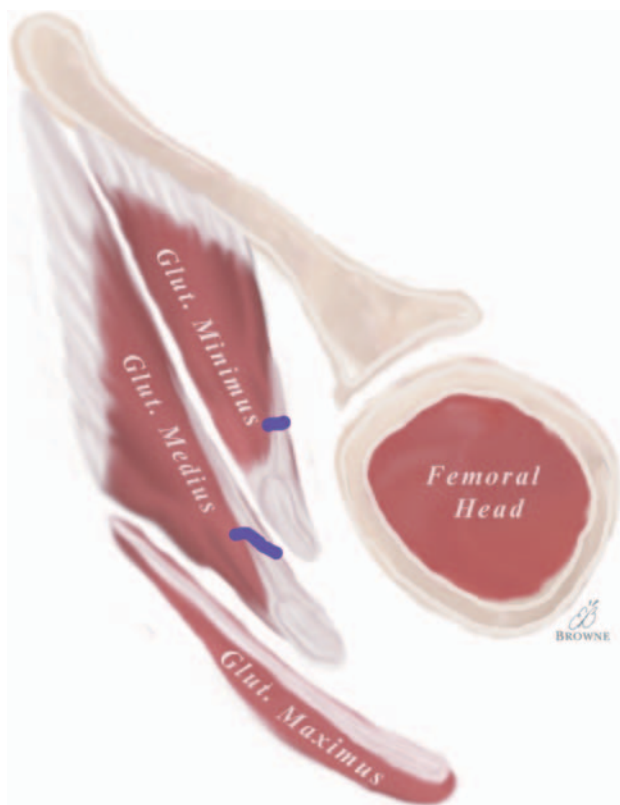


Figure S3.6.5

7. Resection Arthroplasty

Indication

This procedure is indicated as a palliative treatment to decrease the hip pain in nonambulatory children and adults with painful dislocated hips in which there is severe degenerative arthritis and deformity of the femoral head and acetabulum. It is the primary procedure in cases where there is skin breakdown.

Procedure

1. The incision is made over the lateral border of the femur carried down the subcutaneous tissue. The incision should extend distally from the tip of the palpable greater trochanter to approximately 6 or 8 cm (Figure S3.7.1).
2. The fascia latae is incised longitudinally and then the vastus lateralis is identified. The fascia of the vastus lateralis is opened longitudinally; however, subperiosteal dissection of the femur should not be obtained.
3. Using fluoroscopic control, the interval between the muscle and periosteum is identified at the inferior aspect of the ischium.
4. Using an oscillating saw, the femur is transected at this level (Figure S3.7.2).
5. After the femur has been transected, the proximal femur is resected using electrocautery to avoid any subperiosteal dissection because leaving the periosteum tends to cause heterotopic ossification. All of the periosteum and proximal femur are resected with a slight sleeve of soft tissue with extensive use of electrocautery to help minimize bleeding.
6. The hip joint capsule usually is resected right at the border of the femoral neck, leaving a sleeve of hip joint capsule associated with the residual acetabulum.
7. The abductor muscle also is resected well off the tip of the greater trochanter so that no apophysis that might form bone is remaining.
8. After the proximal fragment is removed, sutures are placed in an attempt to cover the rough and open bone on the ilium by suturing hip joint capsule and muscle over this area (Figure S3.7.3).
9. The sleeve of vastus lateralis, which had been freed off the proximal fragment, is sutured over the top of the exposed bone on the distal fragment (Figure S3.7.3).



Figure S3.7.1

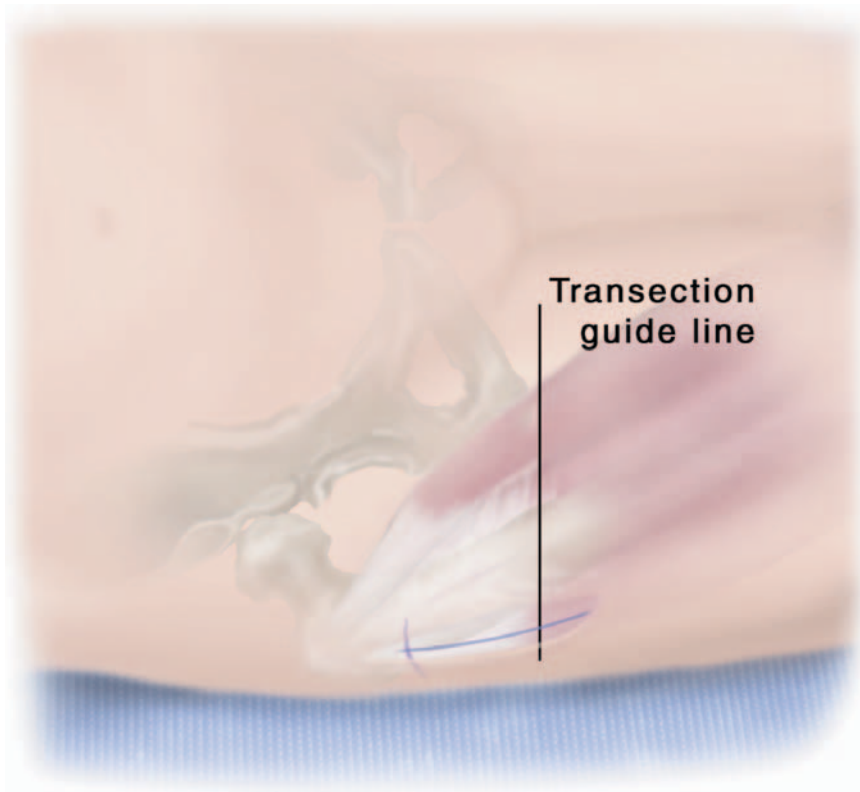


Figure S3.7.2

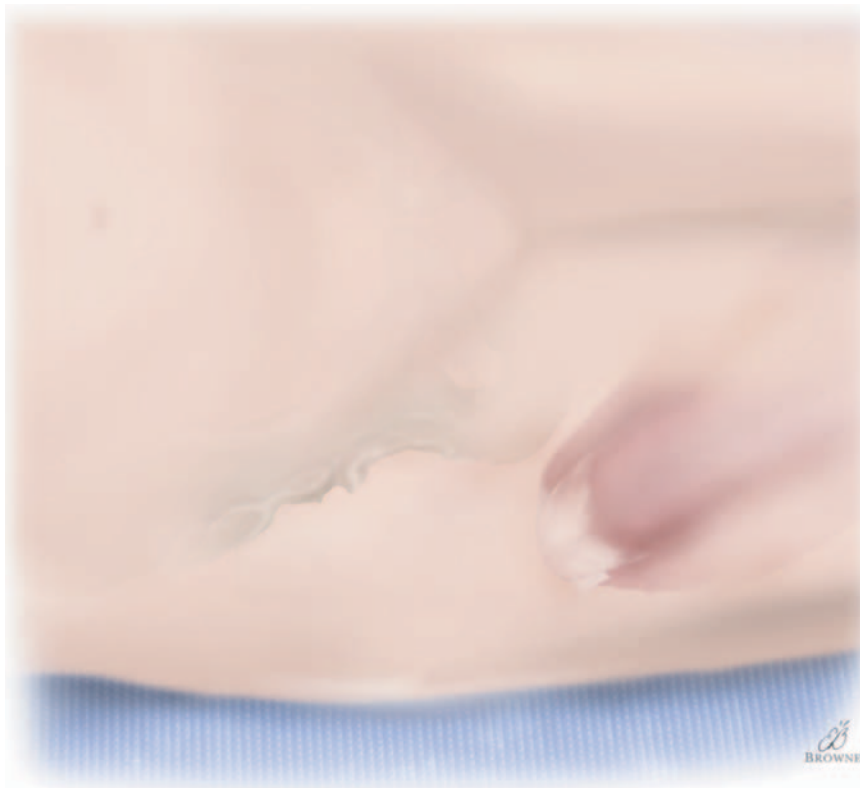

Figure S3.7.3

10. The vastus lateralis then is closed tightly, subcutaneous tissue and skin are closed, and the child is placed in skeletal traction or a well leg cast with broomsticks between the legs to provide some traction and positioning. Well leg traction is a technique in which bilateral short-leg casts are applied and then are rigidly cross-connected with two strong broomsticks. This makes a rectangle so the leg that had the femoral resection is prevented from migrating proximal by the healthy leg.

Postoperative Care

The minimal postoperative care requires the use of the broomstick well leg casts or skeletal traction with distal femoral traction for 6 to 8 weeks. Some surgeons have recommended using external fixation but this seems to be an extreme method of applying traction in these severely compromised individuals. Pain relief typically requires a minimum of 6 months, with many children requiring as long as 12 to 18 months to reach maximum pain relief. No effort is made to increase range of motion by therapy. Children should not be doing any weight bearing until there is maximum pain relief and then only minimal weight bearing is recommended.

8. Interposition Arthroplasty

Indication

The interposition arthroplasty is another salvage procedure that can be used for the painful severely degenerated hip in nonambulatory children and adults. The goal is to implant a humeral component, which acts as a spacer so the individual gets immediate pain relief and does not have to wait 12 to 18 months as is typical for the resection arthroplasty.

Procedure

1. The incision is made on the lateral aspect of the femur from the tip of the greater trochanter to 10 cm distal (Figure S3.8.1).
2. Subcutaneous tissue is opened in line with the skin incision. Fascia latae is longitudinally incised in the same line.



Figure S3.8.1

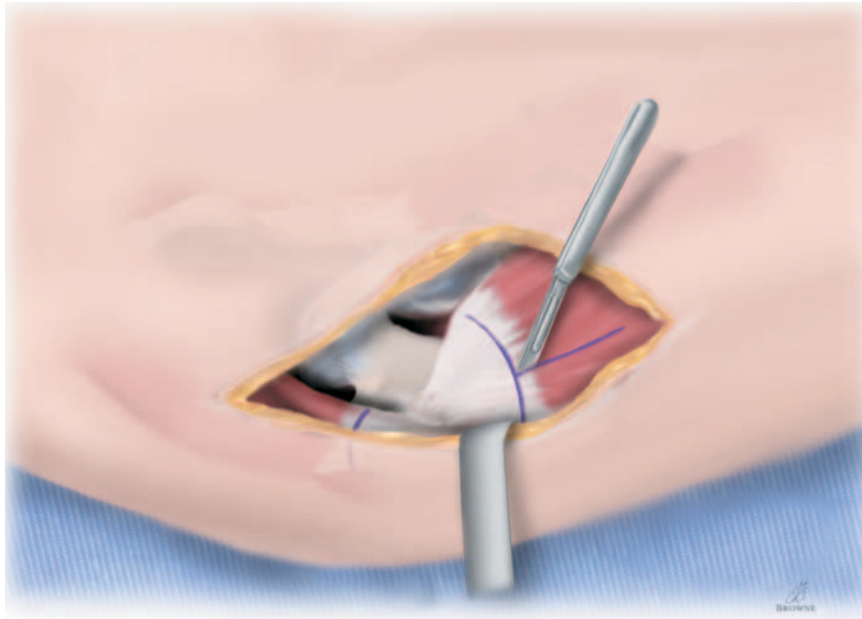


Figure S3.8.2

3. The greater trochanter and proximal femur are identified, and anterior dissection across the proximal femur is performed until the femoral neck is identified (Figure S3.8.2).
4. The lesser trochanter is identified as well, and an incision is made on the anterior femur starting medially in the center of the lesser trochanter and extending laterally in a line parallel with the neck of the humeral prosthesis.
5. This incision should be marked with electrocautery, and using an oscillating saw, the osteotomy is made in line with this mark (Figure S3.8.3).

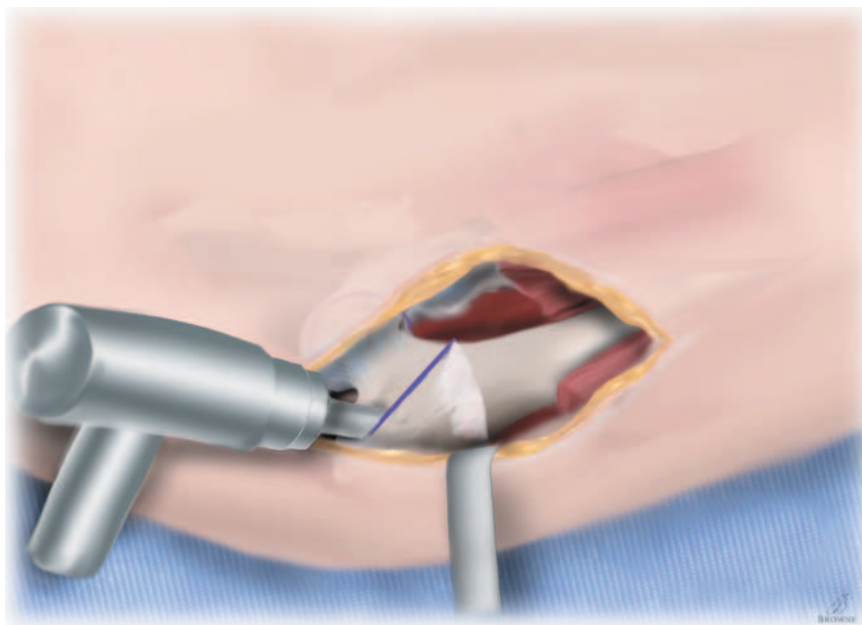


Figure S3.8.3

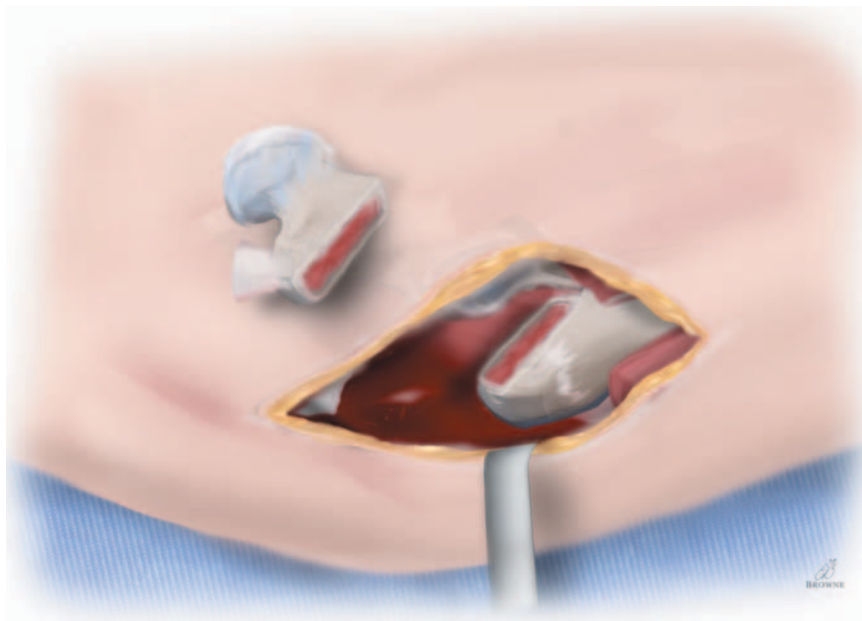


Figure S3.8.4

6. The proximal femur then is completely resected, leaving as much capsule attached to the acetabulum as possible. The abductor muscle is released off of the greater trochanter as well, and all the greater trochanter and the femoral head and neck then are removed (Figure S3.8.4).
7. An inspection of the acetabulum is performed, and if there is an open or raw area of bone either in the true acetabulum or in a false acetabulum, this area is cleaned and exposed, and the template for the glenoid component is used to open an area into the ilium.
8. A temporary reduction of a glenoid component is placed and seated so that it is at the same level of the surrounding bone and does not sit above the edge of the bone.
9. The humeral component then is placed into the distal fragment by opening the intramedullary canal, and the smallest available humeral component usually will fit best.
10. High-speed burs with carbon tips should be available because the medial and lateral flanges of the humeral component often do not fit and will need to be cut back.
11. A dental burr is helpful also to cut some notches into the bone and to burr out the femoral canal so that the prosthesis will make contact and sit as deeply as possible. Usually the distal fragment is not cemented and has a stable press fit. The glenoid component, if used, usually requires a small amount of cement placed into the ilium to hold it in place.
12. After a trial reduction, the hip should have a good range of motion; however, no great attempt needs to be made to make this a stable joint. If the joint wants to dislocate, no problem exists so long as there is good range of motion without a significant amount of force against these joints.
13. The glenoid component then is cemented into place. The distal fragment is cleaned and its humeral component is impacted (Figure S3.8.5).

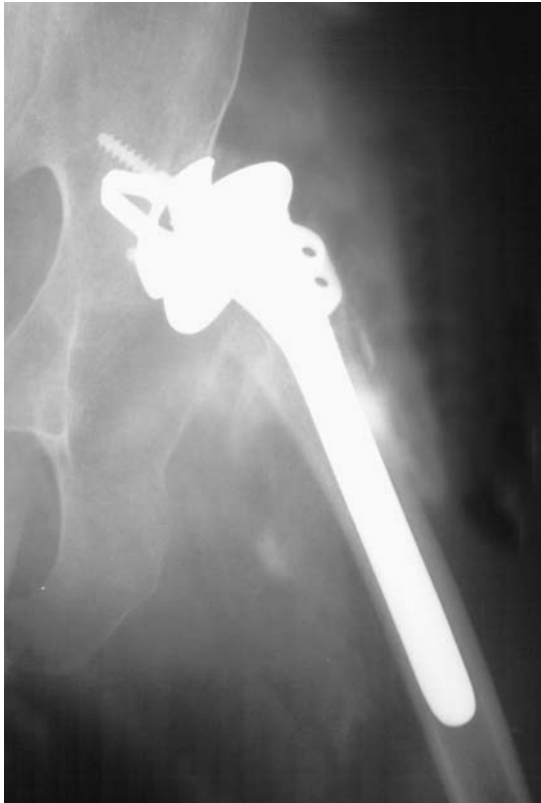

Figure S3.8.5

14. A tight soft-tissue closure of hip capsule and muscle fascia over this area is performed. Deep Hemovac wound suction drains may be placed to drain the hematoma, the fascia latae is tightly closed, and subcutaneous tissue and skin are closed in typical fashion.
15. Usually the children are placed in bilateral short-leg casts, or if the hip feels quite stable, they may utilize an abduction pillow only to help maintain the position while the soft tissues heal.

Postoperative Care

The hip abduction pillow or short-leg abduction casts are used for 6 weeks until the pain has resolved. The child is placed into a wheelchair, which is reclined to the child's level of comfort. Usually there is immediate postoperative pain relief similar to that seen in total hip replacement in adult degenerative hip joint disease. As this is an unstable reconstruction, weight bearing is not recommended.

9. Femoral Derotation with an Intramedullary Nail

Indication

This procedure is indicated in young adults after the growth plates have closed. Various techniques using the intramedullary saw have been described; however, we do not have the intramedullary saw available and have used this technique of closed osteoclasis equally as effectively.

Procedure

1. The procedure includes exposure of the proximal insertion site of the femur with the child in the supine position. The insertion site in the piriformis fossa is identified, and the medial aspect of the tip of the greater trochanter at the level of the piriformis fossa is opened with an awl.
2. The guidewire is placed into the medullary canal.
3. At the flare of the diaphysis and where the bone is starting to widen slightly into the metaphysis, a drillhole is made transversely across the femur to vent the femur.
4. Next the femur is reamed sequentially until at least a 10-mm nail can be placed.
5. The drill guide then is removed, and the chosen nail of the correct length is driven into place to the level where the transverse vent hole was placed (Figure S3.9.1).
6. A 3.2-mm drill again is placed through a drill guide and multiple holes are drilled into the femur, perforating the femur in one plane until only a small bridge of bone remains.
7. Using an angular force, the fracture is completed. There is usually no need to use any osteotomies if enough holes are drilled.
8. Following completion of the fracture, the intramedullary nail is driven on across the osteotomy site until the nail is placed far enough distally so that it is not protruding above the greater trochanter (Figure S3.9.2).
9. The proximal screw is placed using a guide (Figure S3.9.2).
10. At this point, the intramedullary wires and proximal jig on the screw are all removed and great care is taken to derotate the femur so that the correct amount of rotation is obtained.
11. Using a standard fluoroscopic spotting device, one distal transverse screw is placed into the rod to maintain this rotational control (Figures S3.9.3, S3.9.4).

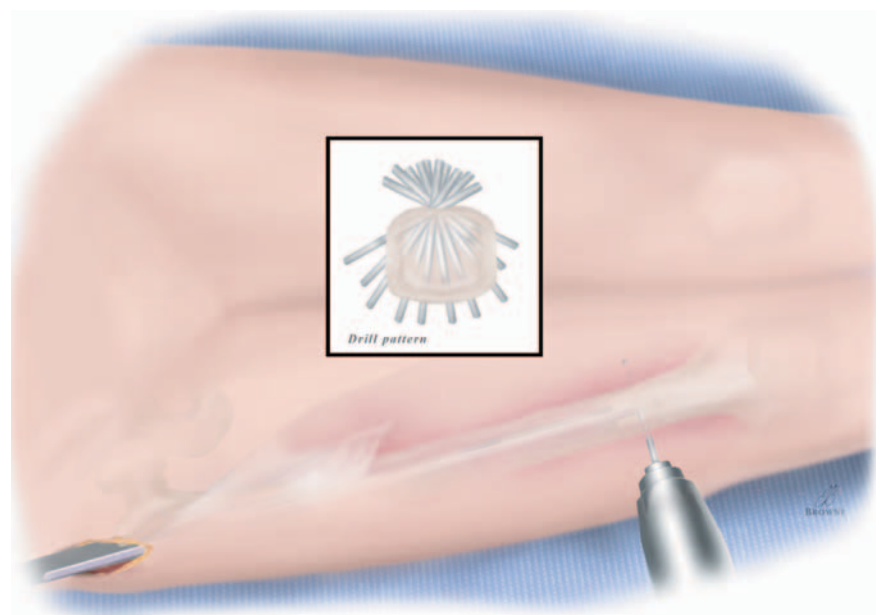


Figure S3.9.1

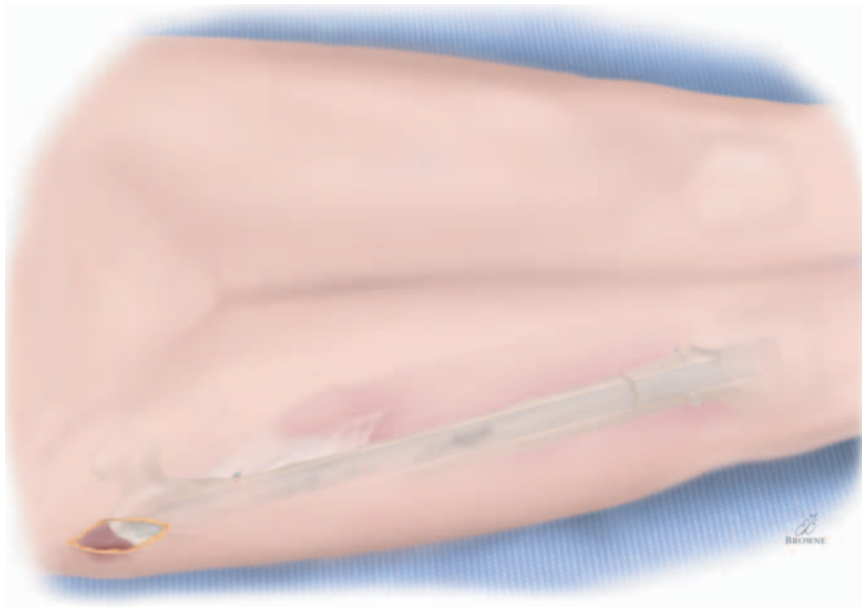


Figure S3.9.2

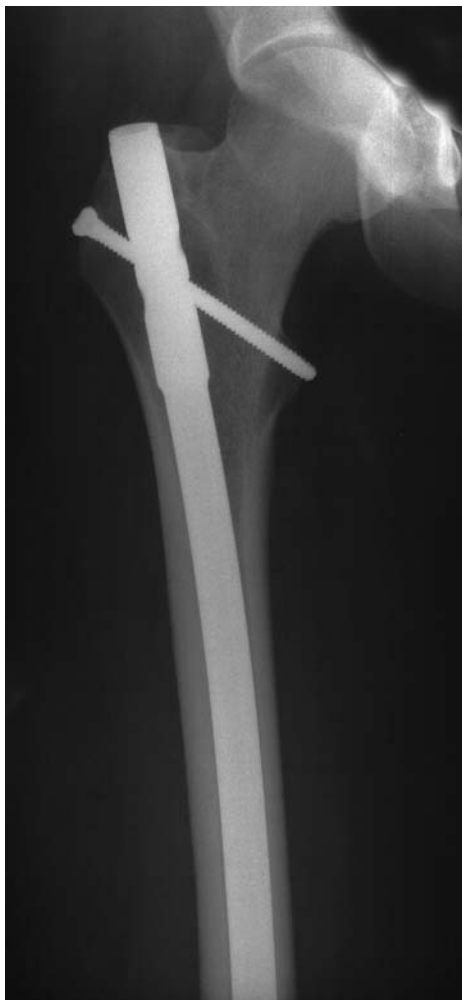

Figure S3.9.3

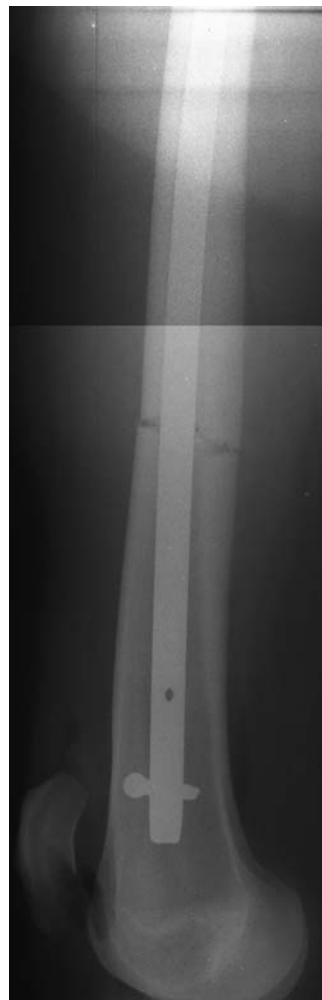

Figure S3.9.4

Postoperative Care

This procedure allows the young adult to ambulate full weight bearing immediately after surgery and shortens the rehabilitation phase versus a proximal femoral osteotomy using a blade plate. An intense period of gait training, usually in the second and third month after surgery, is indicated.

10. Revision Adductor Lengthening

Indication

Revision adductor lengthening is a procedure that unfortunately is relatively common in children with cerebral palsy, as they often will need to have a second adductor lengthening performed, typically at adolescence. This procedure is considerably more difficult, and it is very important that it be done safely and yet extensively with proper landmarks identified.

Procedure

1. The incision should be made in line or directly over the previous incision and carried down through the subcutaneous tissue.
2. There usually is no fascia that can be opened separately, only a mass of scar tissue, so a subcutaneous dissection is undertaken medially until the muscle interval can be identified (Figure S3.10.1).
3. This anterior muscle dissection interval will be either the interval between pectineus and adductor brevis or more typically the interval between pectineus and the neurovascular bundle. Clearly understanding which interval has been located is necessary, and this interval is opened down until the femur is encountered.
4. Once the appropriate interval has been identified, there is a great margin of safety because the location of the major neurovascular struc-

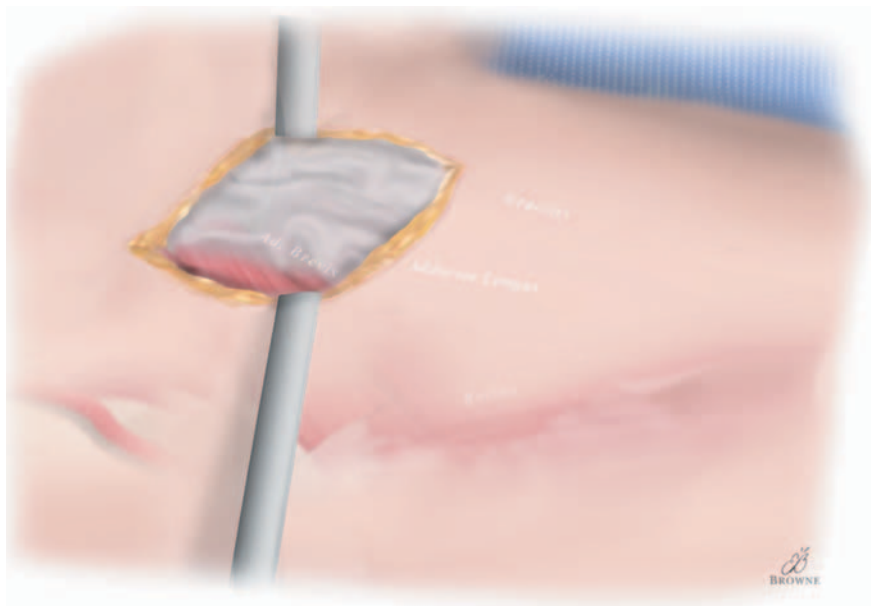


Figure S3.10.1

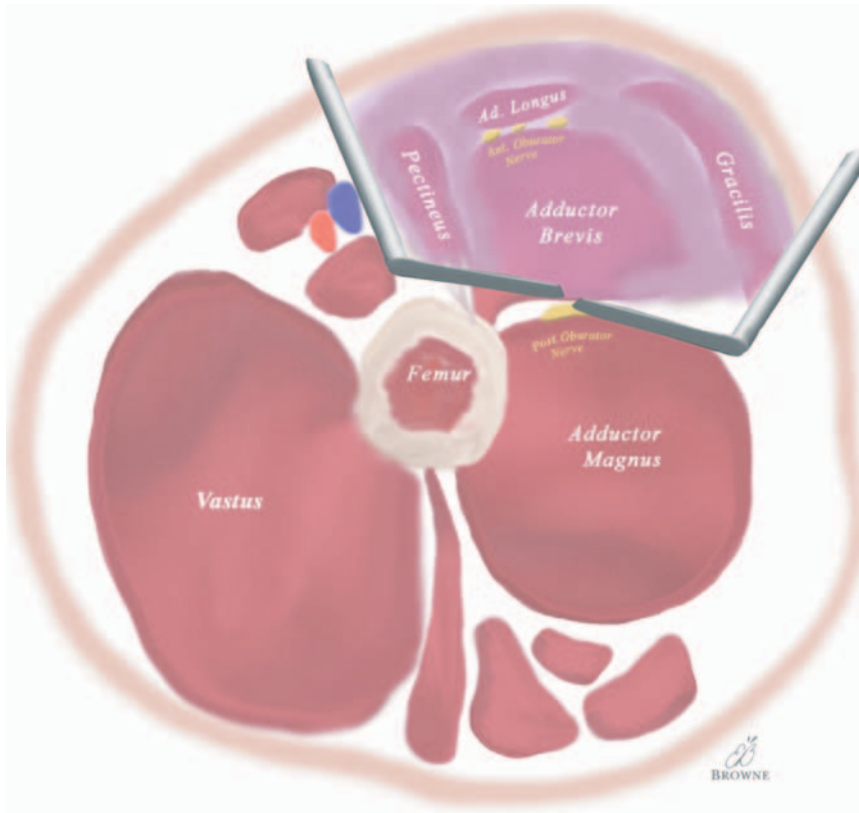


Figure S3.10.2

tures are known and they will always be protected by keeping them lateral with a retractor (Figure S3.10.2).

5. The dissection in the subcutaneous area then is carried medially, and the fascia opened in the midmedial region and carried toward the midline of the thigh until the plane between the adductor brevis and the adductor magnus is identified. This plane is almost always maintained because, even if some adductor brevis lengthening has been performed, the plane usually can still be identified so long as the whole adductor brevis was not resected.
6. By identifying this plane between the adductor brevis and magnus, the posterior branch of the obturator nerve still can be protected.
7. All the muscle mass between the anterior lateral retractor, which retracts the neurovascular bundle and the posterior medial retractor, which in turn retracts the adductor magnus and posterior branch of the obturator nerve, can be transected now (Figure S3.10.2).
8. When getting deep toward the capsule of the hip joint, large branches of the recurrent femoral artery and vein may appear. By staying in the muscle planes, however, these vessels can be avoided. If these vessels are inadvertently damaged, the bleeding can be controlled without too much difficulty with careful packing and the use of vascular clamps.
9. Following transection of all this adductor mass, there usually is sufficient abduction present. However, the medial hip capsule is now clearly in view and the medial hip capsule as well as some remnants of the iliopsoas can be transected as well if necessary. This transection

may provide some contracture release across the anterior medial part of the hip capsule.

10. For adolescents who have very severe contractures, it may be reasonable to transect the posterior branch of the obturator nerve and continue transecting the adductor magnus, and then even transecting some of the medial hamstring.
11. The sciatic nerve is seldom inadvertently visible so long as the transection remains medial to the femur; however, when transecting posterior to the femur, care must be taken that the sciatic nerve does not become injured.
12. Following this extensive adductor lengthening, performing a careful, tight subcutaneous closure followed by a good subcuticular closure of the skin is important because leakage from these deep hematomas can lead to deep wound infections.

Postoperative Care

Use of soft pillows and positioning is required to maintain hip abduction. No solid casting is recommended because there is a high incidence of causing windblown hip deformities or causing abduction contractures. Passive range of motion is performed by a physical therapist starting on the first postoperative day.

Knee Operative Procedures

1. Hamstring Lengthening

Indication

Hamstring lengthening is best performed with the child in the supine position, having an assistant elevate the leg through hip flexion. This position allows easy testing of the length of the hamstring with the traditional clinical popliteal angle test. Although the exposure is easier when the child is prone, it is impossible to check the amount of hamstring length, which has occurred with the operative procedure. The goal of hamstring lengthening should be to have a popliteal angle between 20° and 40° with only enough force to lift the leg, which causes no rotation of the pelvis. The usual indication for hamstring lengthening includes increasing fixed knee flexion contracture, increased knee flexion at foot contact, increased knee flexion in midstance, and seating difficulties causing sliding out of the wheelchair with supple lumbar kyphosis.

Procedure

1. An incision is made midline between the hamstring muscles approximately 4 cm proximal to the knee crease. Excision is extended through the subcutaneous tissue until the fascia is encountered (Figure S4.1.1).
2. By palpation on the medial side with the hip flexed 90° and the knee in maximum extension, the tendon of the semitendinosus is very prominent. A longitudinal incision of the peritendon is performed and the tendon is visualized easily. A transection of the semitendinosus tendon is performed (Figure S4.1.2).
3. After the tenotomy of the semitendinosus, a longitudinal incision is made in the base of the tendon sheath, and the tendon sheath surrounding the fascia and tendon of the semimembranosus is encountered. The fascia of the semimembranosus is on the medial side of the thigh, and the muscle belly is toward the midline. With good cleaning of the fascia and excellent retraction, an incision is made circumferentially around the medial side of the semimembranosus, making the first incision as far proximal as possible in the wound. A second circumferential incision then is made around the semimembranosus, approximately 2 to 3 cm distal to the first incision (Figure S4.1.3). The fascia is only present in the medial half of the muscle's circumference. The popliteal angle is checked, and if it is 30° or less, foot progression angle is less than 20° external, and the transmalleolar axis-to-thigh



Figure S4.1.1

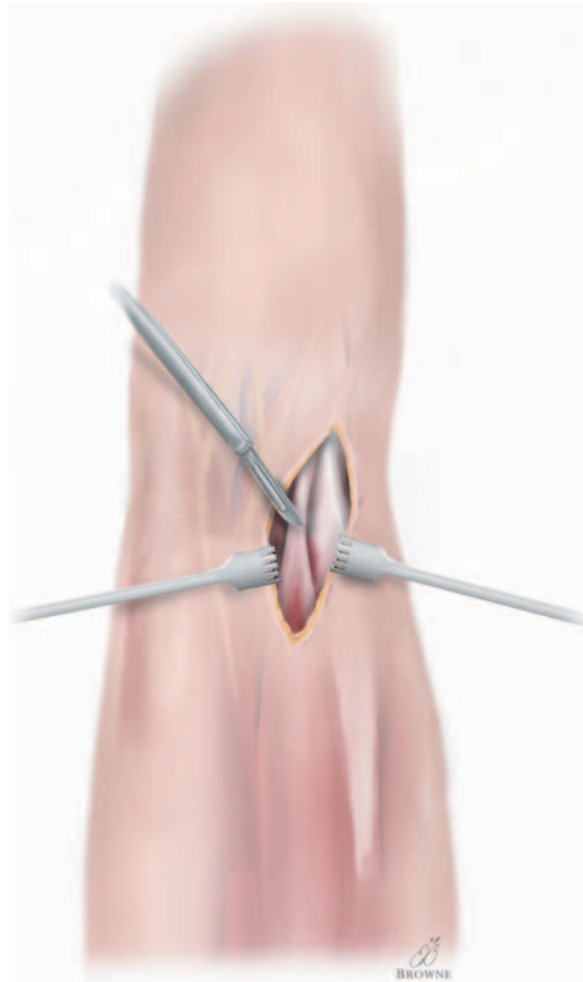


Figure S4.1.2

angle is less than 30° external, no further lengthenings are indicated. If all these criteria are not met, a biceps femoris lengthening should be performed.

4. The biceps is lengthened by palpation through the same wound on the lateral side, where a longitudinal incision will expose the nice, shiny fascia overlying the biceps. The fascia of the biceps is on the lateral side and tends to have a horizontal component that goes into the muscle, which needs to be incised as well. Again, a proximal fasciotomy is performed first, and then a second, more distal fasciotomy is performed if indicated. Do not dissect to the posterior medial side of the biceps as a way to avoid the common peroneal nerve (Figure S4.1.4). If the popliteal angle is still greater than 40° and the medial side palpation demonstrates that the gracilis is contracted, attention again should be directed to the medial side.
5. The gracilis is palpated by feeling a structure that is more medial and superficial on the medial side. A longitudinal incision in the subcutaneous tissue will expose the gracilis, and a myofascial lengthening can be performed easily (Figure S4.1.5).

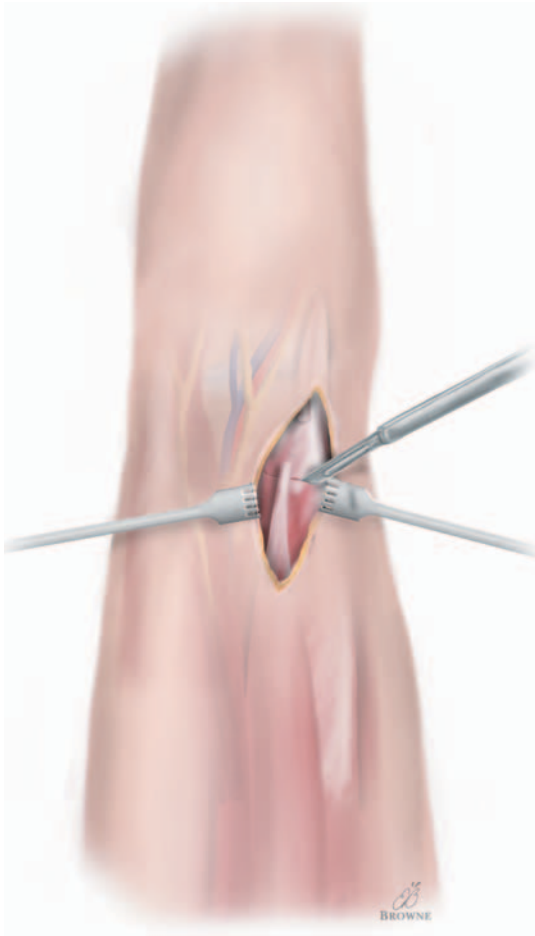


Figure S4.1.3

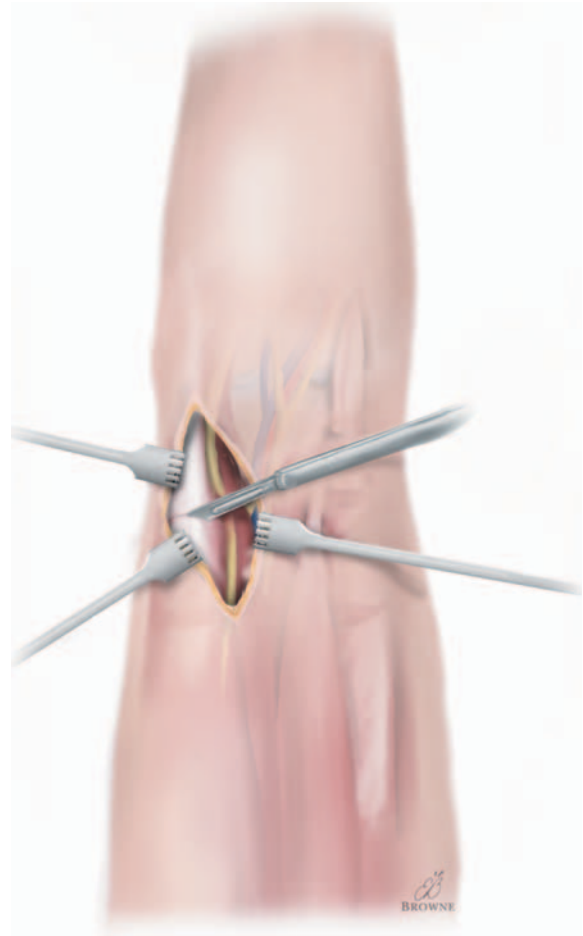


Figure S4.1.4

6. The surgical wound then is closed in two layers, first with a careful closure of the subcutaneous tissue, and then subcuticular closure of the skin. The skin is covered with a watertight dressing. The patient then is placed in knee immobilizers, either in 24 to 48 hours, or immediately at the conclusion of the procedure. Immediate active and passive range of motion is begun 48 hours after the surgical procedure.

Postoperative Care

Soft Velcro-closing knee immobilizers are used postoperatively for 8 to 12 hours per day. The knee immobilizers may be used full time for several days to get the child accustomed to the orthotics; however, active and passive range of motion should be encouraged, and a significant amount of time out of the orthotic is to be encouraged as a mechanism to avoid knee stiffness in extension. Wearing of the knee immobilizer is encouraged at nighttime for 3 months, or as long as the child tolerates the orthotics. The physical therapist should be warned of possible sciatic nerve palsy if the surgeon feels that the release places the nerve at risk. This is most important in revision lengthenings or in those children with severe contractures who gained large lengthenings.

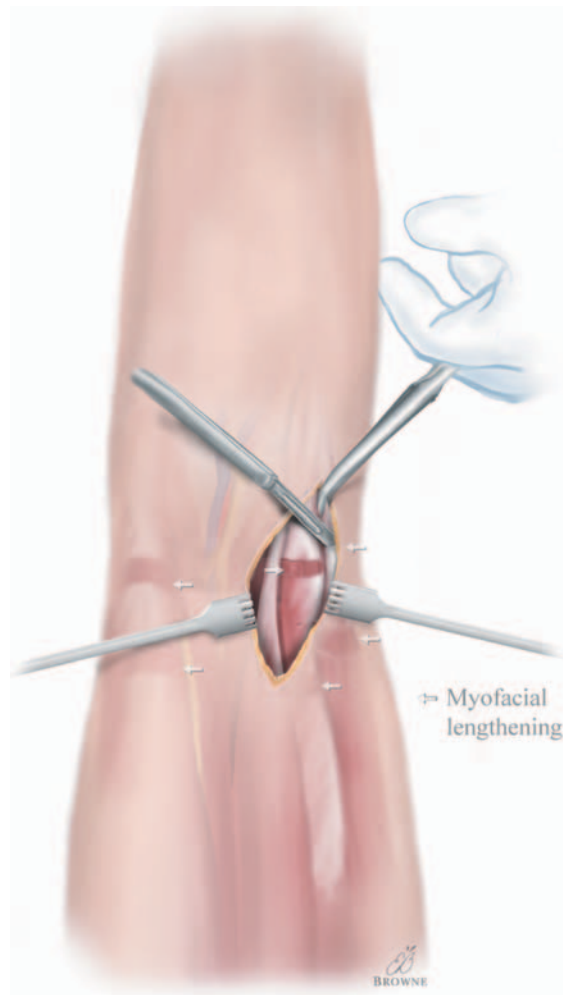


Figure S4.1.5

2. Rectus Transfer

Indication

Rectus transfer is indicated to improve toe dragging and stiff knee gait. Specific indications include a complaint of toe drag, increased activity during swing phase of the rectus femoris on EMG, decreased knee flexion in swing phase, and late peak knee flexion in swing phase. The rectus transfer is performed with the child lying in the supine position.

Procedure

1. An incision is made starting distally 2 cm proximal to the patella in the midline. The incision is carried from distal to proximal approximately 30°, and angled to the medial side for 3 cm in length (Figure S4.2.1).
2. The incision is carried through the subcutaneous tissue until the bursa overlying the quadriceps tendon has been opened and the tendon exposed. The quadriceps tendon should be cleanly exposed from the proximal pole of the patella until the muscle belly of the rectus can be seen.

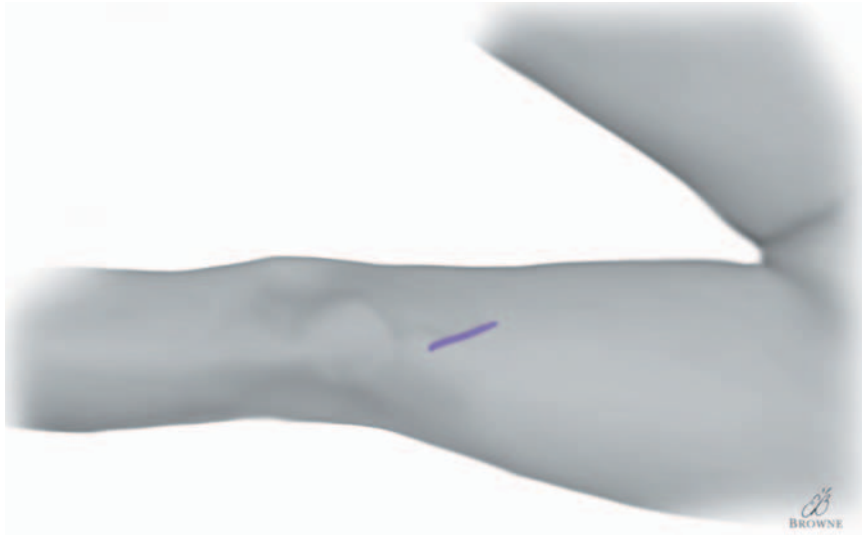


Figure S4.2.1

3. At the proximal end of the incision, the interval between the vastus medialis and the rectus muscle is identified. A hemostat is passed underneath the rectus tendon above the vastus intermedius tendon to the lateral border of the rectus. An incision then starts distally just proximal to the patella and is carried proximally. The incision should start 5 to 7 mm off the midline on the medial side and is carried proximally at a depth of 2 to 3 mm, exiting at the junction between the vastus medialis and rectus muscle. This longitudinal incision should not cut into muscle tissue of the vastus medialis but should be entirely within the tendon. A similar incision 5 to 7 mm on the lateral side of the midline is started distally and carried proximally, exiting at the intermuscular septum between the vastus lateralis and the rectus. Neither the medial nor the lateral longitudinal incisions should enter the knee joint (Figure S4.2.2).
4. Now the hemostat can be pulled distally, elevating the rectus muscle until it inserts into the vastus intermedius. Utilizing a knife with sharp dissection, the rectus muscle is freed from its insertion on the vastus intermedius distally to the level of the patella and then is released.
5. Finger palpation of the underbelly of the rectus then is utilized, with the finger stripping distally to make certain that all components of the rectus muscle have been released distally (Figure S4.2.3).
6. Utilizing a slowly absorbable suture, the defect created in the residual quadriceps tendon by removal of the rectus tendon now is closed. This closing involves suturing the tendon of the vastus medialis to the tendon of the vastus lateralis (Figure S4.2.3).
7. Exposure of the sartorius is performed by subcutaneous dissection around the medial side of the thigh, inside the fascia of the vastus medialis. Carrying the dissection through the subcutaneous tissue instead of under the fascia makes the rectus muscle less likely to scar down, but it will be much more prominent, especially in a slender child. As the dissection is carried posterior, the intermuscular septum is encountered. Utilizing a dull instrument, such as a hemostat, the intermuscular septum is opened and stripped proximally and distally. In the subcutaneous tissue, the sartorius muscle and its enveloping fascia can be palpated. The enveloping fascia of the sartorius is opened as well. The

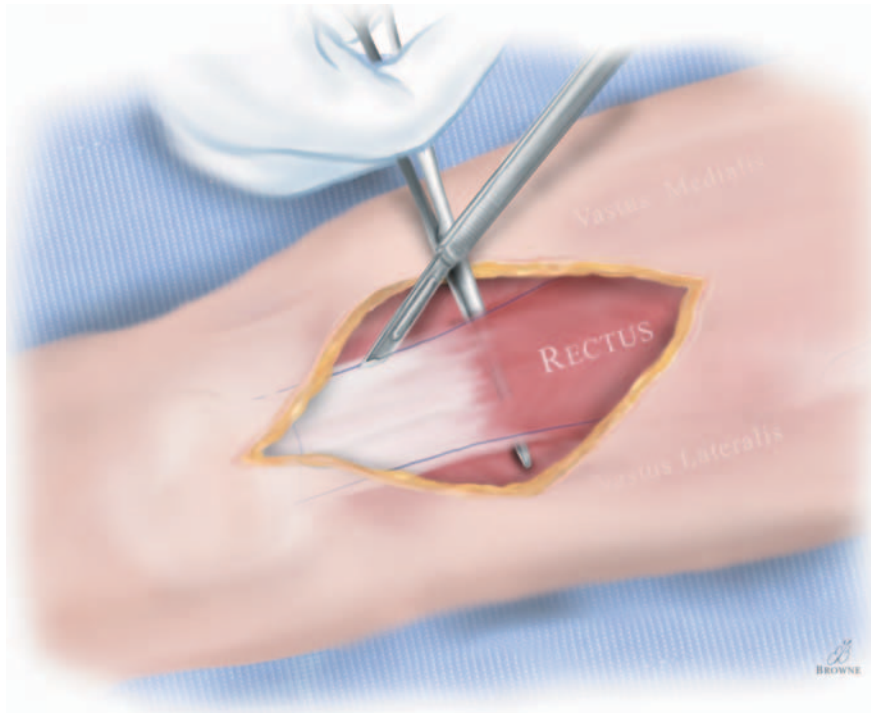


Figure S4.2.2

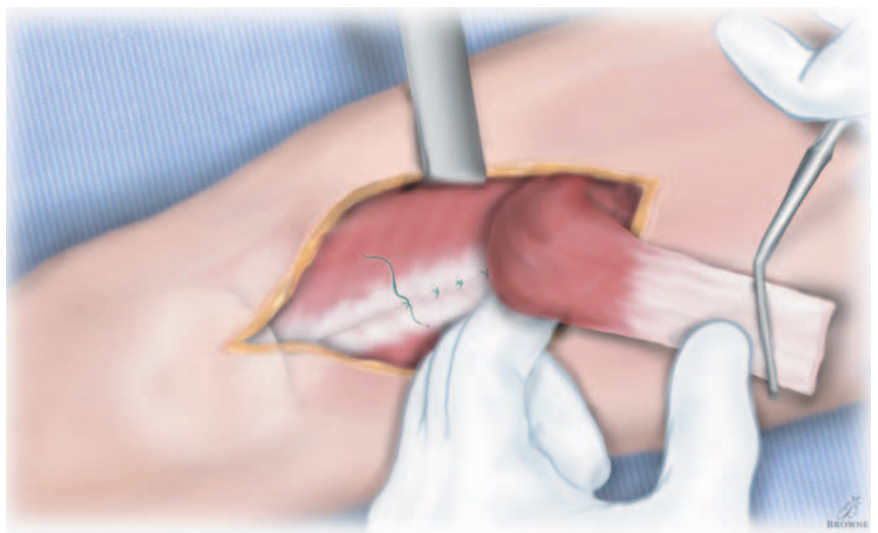


Figure S4.2.3

sartorius fascia has to be opened proximally, usually by digital dissection, at least into the mid thigh to free the muscle and allow easy exposure for the transfer (Figure S4.2.4).

- 7A. Another alternative is to expose the semitendinosus for transfer to the rectus. This exposure occurs by making a small incision in approximately the mid thigh posteriorly, and the semitendinosus is identified. A small incision is made distally just at the level of the knee crease, the tendon is transected through the proximal incision,

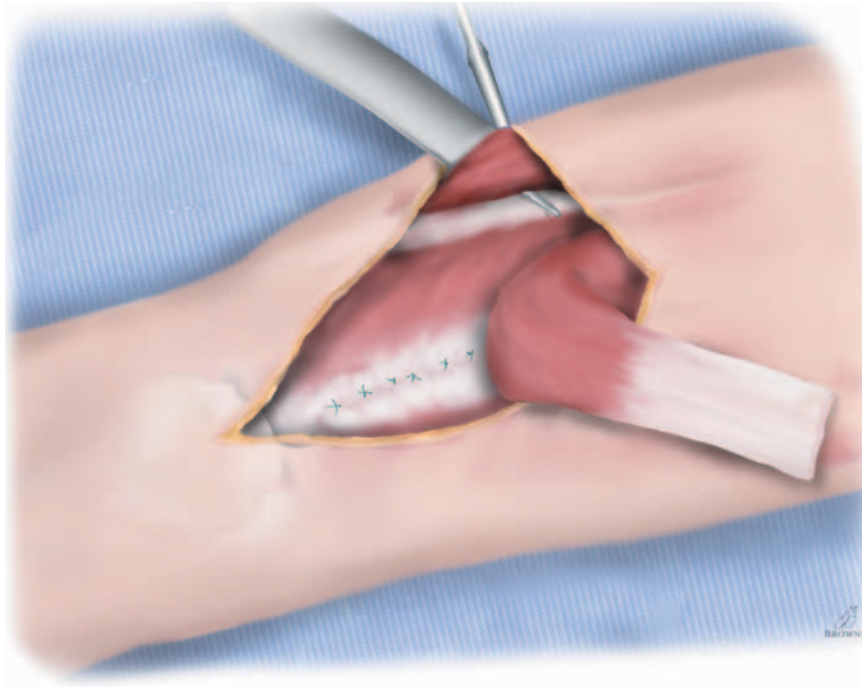


Figure S4.2.4

and then the tendon is pulled out distally. Next, a tendon passer is introduced from the anterior knee wound into the distal posterior knee wound and the semitendinosus is pulled through the subcutaneous tissue into the proximal wound (Figure S4.2.5).

8. For transfer to the sartorius, the sartorius muscle is identified and a right-angle clamp is placed from medial to lateral, through the mid-substance of the sartorius muscle. The rectus muscle is placed into this clamp and pulled through the opening in the sartorius muscle,

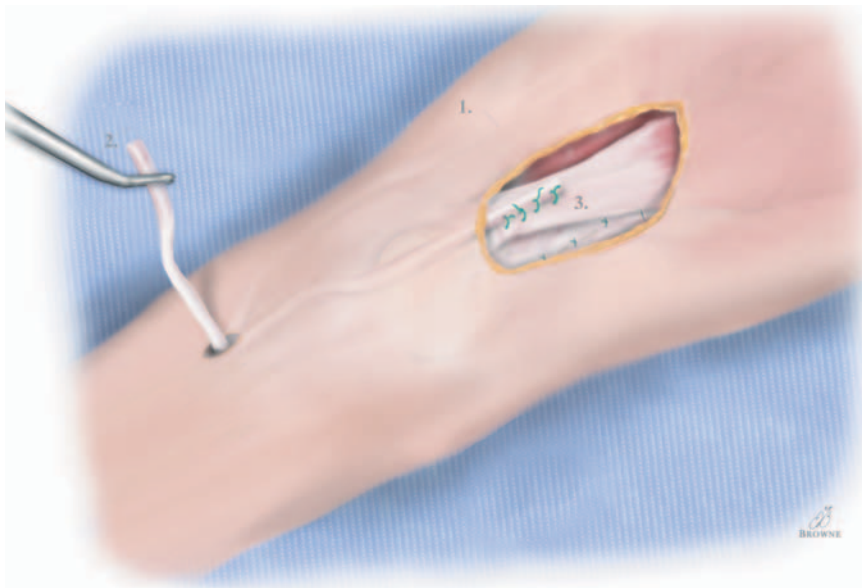


Figure S4.2.5

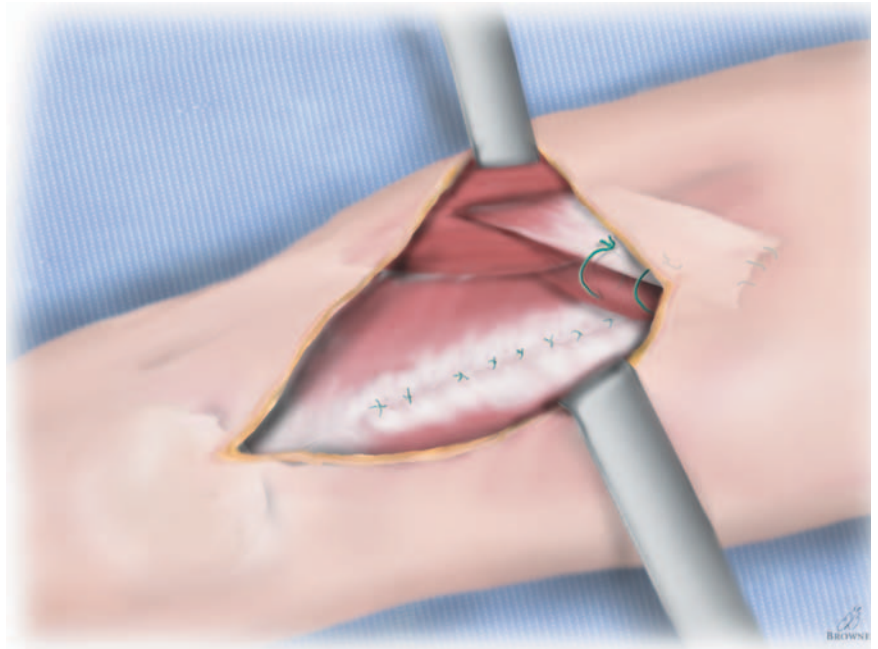


Figure S4.2.6

looped back on it, and sutured with absorbable suture (Figure S4.2.6). Alternatively, the rectus tendon is sutured to the semitendinosus (Figure S4.2.5).

9. The skin is closed, paying particular attention to closing the subcutaneous fascia of the anterior thigh wound. This wound has a tendency to spread, so diligent closure of the subcutaneous tissue and its subcutaneous enveloping fascia is very important.

Postoperative Care

The child's main problem following rectus transfer is a high rate of severe spasticity in the transferred muscle. Diligent control of spasticity with the use of postoperative diazepam is important. Another option is botulinum toxin injected into the rectus muscle during the procedure, however it will take 2 to 3 days to be effective. No postoperative immobilization is required. Full range of motion and weight bearing are allowed.

3. Posterior Knee Capsulotomy

Indication

Posterior knee capsulotomy is recommended for fixed knee flexion contractures between 10° and 30° . These capsulotomies are performed in combination with hamstring lengthening, which should be performed first. Most capsulotomies can be performed through the medial side alone (Figure S4.3.1). If it is thought that there is not enough release of the posterior capsule from the medial side, a separate lateral incision can also be used (Figure S4.3.2). These incisions and exposures are the same as those used to perform open posterior horn menisectomies, which were common before the advent of arthroscopy.

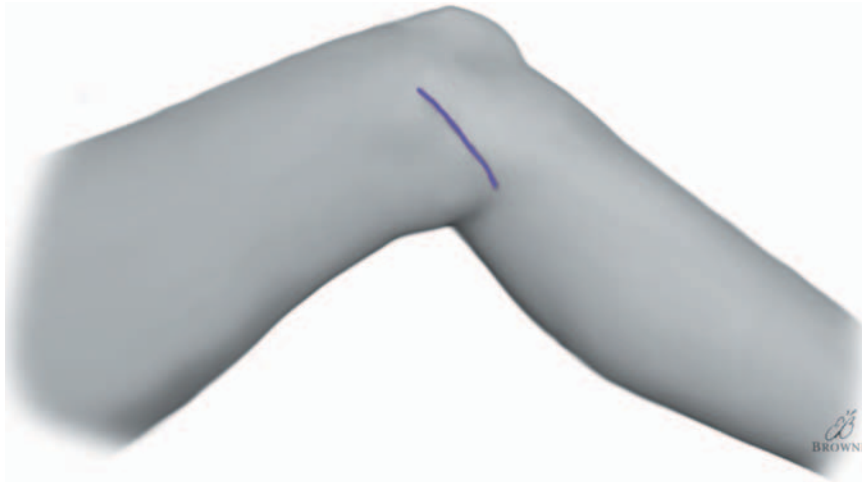


Figure S4.3.1




Figure S4.3.2

Procedure

1. The incision for posterior knee capsulotomy is made on the medial side with the knee flexed 60° . An incision of 4-cm length is made over the posterior medial corner of the knee at right angles to the knee joint. This incision is the typical incision used for open excision of the posterior horn of the medial meniscus, except some increased distal extension is required for exposure of the medial head of the gastrocnemius (Figure S4.3.1).
2. Opening the subcutaneous tissue distally, and by palpation, the medial head of the gastrocnemius can be identified anterior to the pes anserinus tendons. The enveloping fascia of the gastrocnemius is opened and a myofascial lengthening, or tenotomy if no muscle is encountered on the medial head of the gastrocnemius, is performed. In this exposure, the muscle belly will be superficial and the tendon is deep to the exposure (Figure S4.3.3).

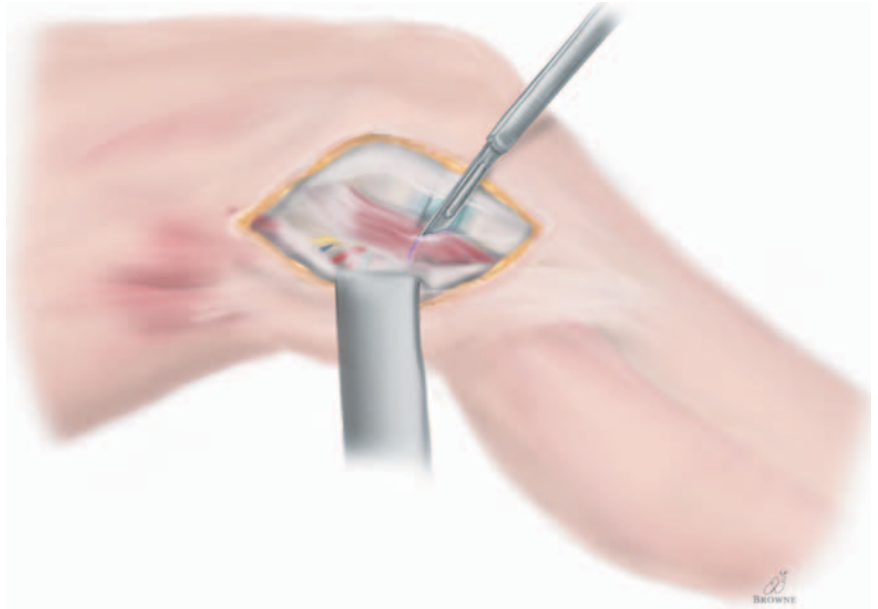

Figure S4.3.3

3. The knee joint capsule is opened superior to, and at the posterior medial corner behind, the medial collateral ligament. After opening of the knee capsule, the meniscus is identified inferiorly (Figure S4.3.4).
4. Using a flat elevator, such as a Cobb elevator, the posterior capsule then is cleaned all along its posterior border proximal to the tibia. A

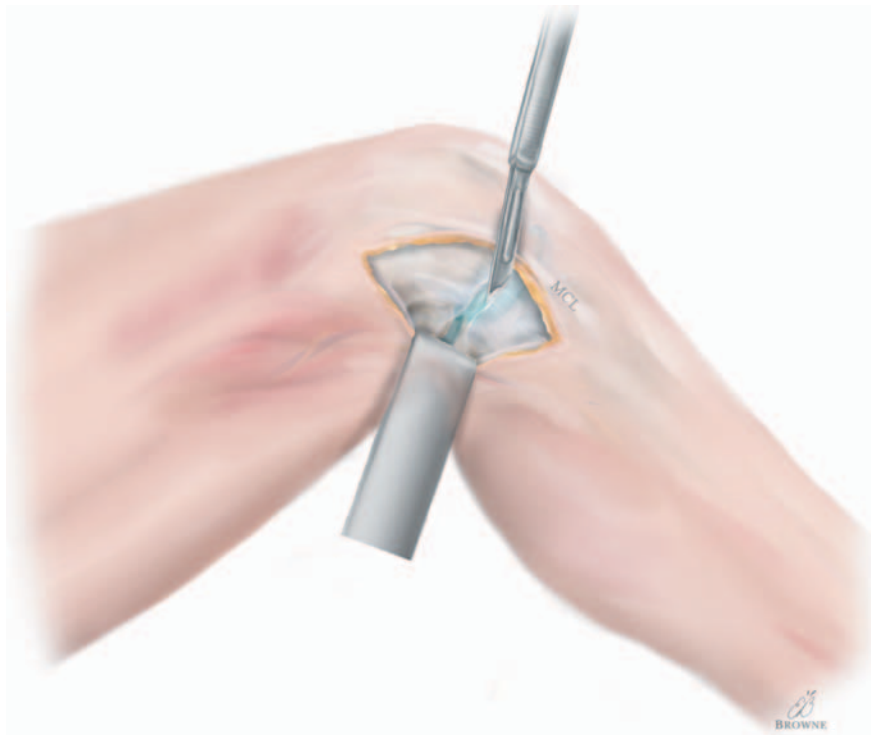


Figure S4.3.4

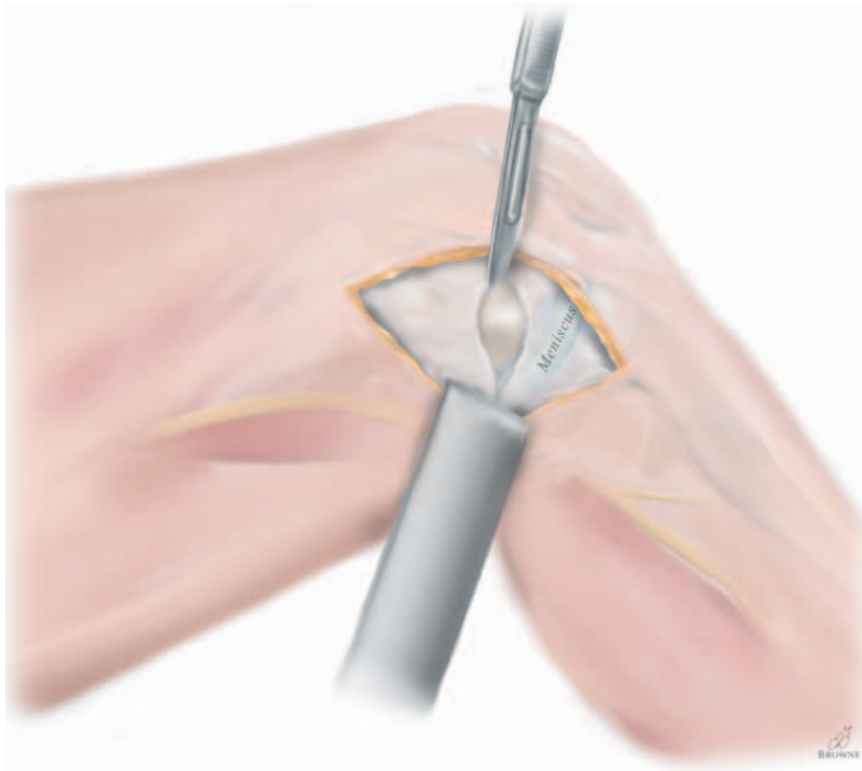


Figure S4.3.5

- deep retractor is placed into this space, retracting the neurovascular structures and all muscles posterior. Scissors or a knife can be utilized to cut the posterior capsule, making sure that the meniscus is protected inferiorly along the posterior border to the intercondylar notch (Figure S4.3.5).
5. Using a blunt retractor and the Cobb elevator, the posterior capsule of the lateral compartment also can be cleaned, always keeping the knee flexed at least 90° to avoid undue tension on the nerves or vessels of the popliteal fossa. After good clean exposure of capsule in the lateral compartment is performed, heavy scissors or a knife is used to perform a posterior capsulotomy in the lateral compartment (Figure S4.3.6). By palpation, one can make sure that the capsule is incised above the meniscus.
 6. After this capsular incision, if significant contracture remains, palpation should be utilized to determine whether the contracture is due to cruciate ligaments in the intercondylar notch or to continued contracture on the lateral side. If the contracture is due to cruciate ligaments in the intercondylar notch, a knife is utilized and these are transected. If the contracture is still thought to be due to posterior lateral capsule, a separate exposure of the posterior lateral corner should be performed (Figure S4.3.2).
 7. Exposure of the lateral capsule also is performed by using the exposure typically used as an open exposure of the posterior horn of the lateral meniscus. The capsule again is opened at the posterior lateral corner in the same fascia as was used on the medial side, and using blunt dissection, the soft tissue is stripped off the capsule. The capsule then is excised from the posterior edge of the lateral collateral ligament

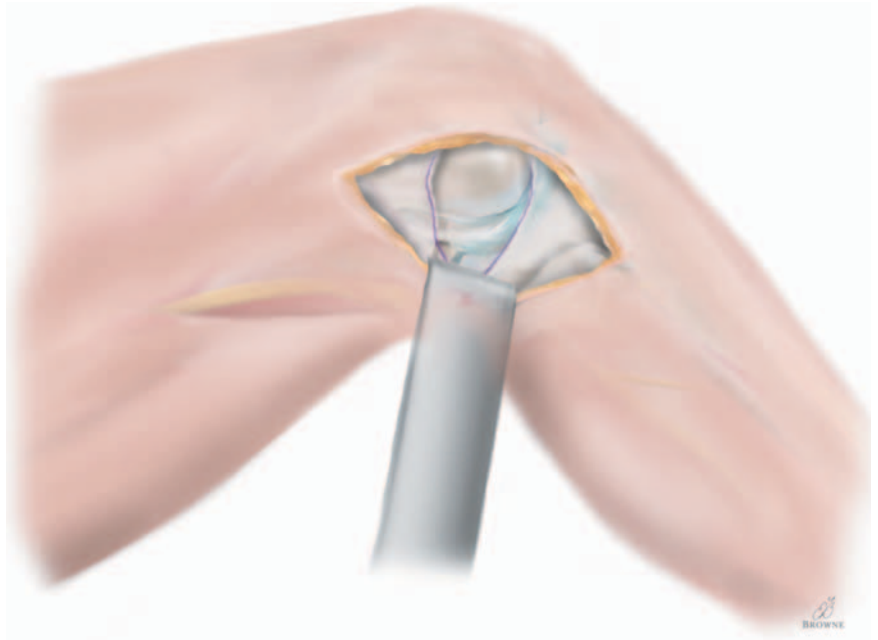


Figure S4.3.6

around into the intercondylar notch. For individuals who are concerned, or not very familiar with the anatomy, separate exposure of the peroneal nerve will add an extra level of safety, although this is not routinely necessary.

8. Wound closure is performed by diligent closure of the subcutaneous tissue, but no capsular closure.

Postoperative Care

A bulky dressing should be applied, applying pressure to help control some of the capsular bleeding that occurs postoperatively. A knee extension cast or a knee immobilizer should be applied immediately at the end of the operative procedure. Postoperative management includes careful neurovascular inspection to make sure there is no sciatic nerve palsy. By the third or fourth day, the cast and soft dressing should be removed and active and passive range of motion of the knee initiated. The knee is continued in extension splinting full time except when passive range-of-motion exercises are being performed. Usually, a step-lock knee hinge knee-ankle-foot orthosis (KAFO) is fitted for use for 6 months to prevent recurrent contracture, especially in a child who has a tendency to want to sit with knee flexion.

4. Repair of Dislocation of the Patella

Indication

Surgical correction is recommended for recurrent dislocation of the patella that is causing knee pain for a sitting child or knee instability for an ambulatory child. The indication for repair and the repair itself are very similar to that which occur in normal adolescence.

Procedure

1. An anterior midline incision is made, extending down from the distal pole of the patella 2 or 3 cm proximal to the patella.
2. The lateral side of the patella is exposed and the lateral retinaculum is incised, preventing incision of the underlying synovium. The retinacular incision is carried proximally, with some release of the vastus lateralis if necessary, until the patella rests in the midline without any undue tension.
3. The vastus medialis obliquus is elevated from its insertion into the patella and distal quadriceps tendon, leaving the medial retinaculum and capsule intact.
4. If a high quadriceps angle is present and the growth plate has closed, the insertion of the tibial tubercle is elevated with an osteotomy (Figure S4.4.1) and fractured distally, then swung to the medial side and fixed with one screw (Figure S4.4.2).
5. If the growth plate is still open, the semitendinosus is detached proximally by making a small incision in the midhigh posteriorly, and an incision also is made distally just distal to the knee joint capsule where the tendon is palpated to cross. The semitendinosus is excised proximally and pulled into the distal wound and is left attached at its origin in the pes anserinus tendon.
6. A tendon passer is passed from the anterior wound in the subcutaneous plane to the distal posterior wound, and the semitendinosus tendon is delivered into the proximal wound. The semitendinosus then is woven into the medial insertion of the patellar ligament and sutured across to the lateral side of the patella.
7. The vastus medialis is advanced medially and distally and sutured to the superior aspect of the patella (Figure S4.4.3). The wound is closed with good subcuticular closure.
8. A leg cylinder cast with the knee in almost full extension is placed, and the knee is kept immobilized in full extension for 4 weeks.

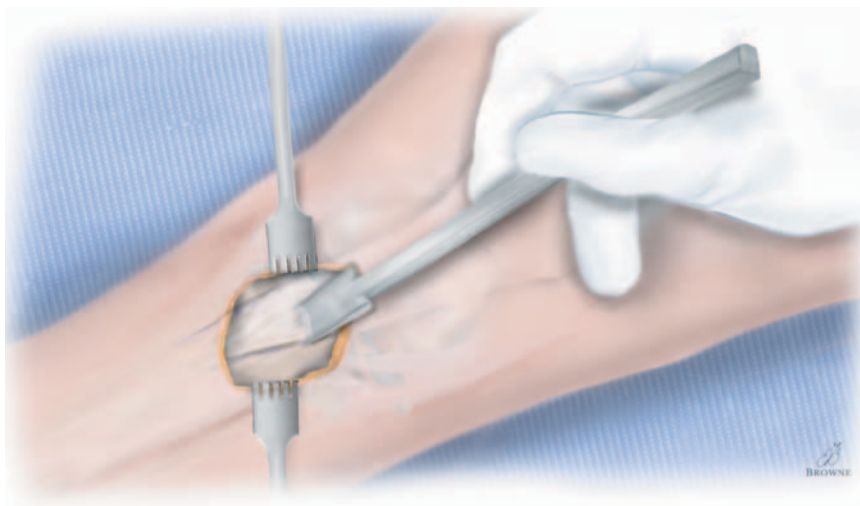


Figure S4.4.1

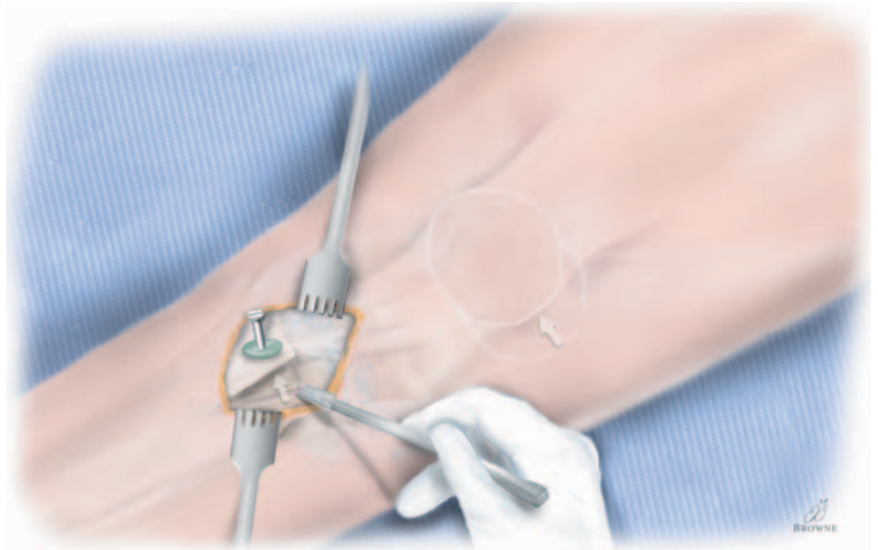


Figure S4.4.2

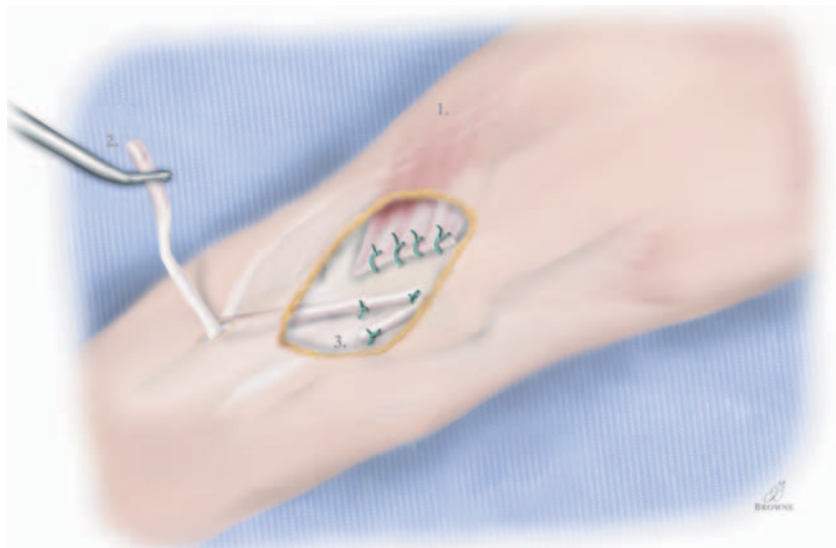

Figure S4.4.3

Postoperative Care

The postoperative management includes maintaining the knee in a cast allowing full weight bearing, and starting active range of motion and strengthening 6 weeks postoperatively when the cast is removed.

5. Tibial Osteotomy with Cast

Indication

Children who have an open growth plate with significant internal or external tibial torsion that causes problems with gait should have correction. The tibial osteotomy is performed at the distal tibia, and immobilization is done with a pins-in-cast technique.

Procedure

1. A stab incision is made on the medial side of the tibia 1 cm proximal to the distal tibial epiphysis.
2. A 3.2-mm drill bit with a drill sleeve is introduced into the wound, and multiple drillholes are made in the distal tibia in a fanning fashion (Figure S4.5.1).
3. Utilizing an angular bending moment focused at the multiple drillholes, the tibia is fractured. Derotation is performed.
4. If more than 30° of tibial osteotomy is required, this similar technique is used to produce a fracture of the fibula 2 to 4 cm proximal to the tibial osteotomy on the lateral side.
5. A 1.5- or 2-mm drill tip K-wire is introduced in the proximal tibia 2 to 3 cm distal to the tibial epiphysis. This wire is allowed to protrude both medially and laterally.
6. A short-leg cast is applied, incorporating the proximal tibial pin and aligning the foot with the thigh for a zero thigh-foot angle with correction of distal tibial valgus if necessary (Figure S4.5.2).
7. A postoperative radiograph is obtained, and if residual valgus angulation is present, the cast should be wedged (Figure S4.5.3).

Postoperative Care

Postoperatively, a sole is applied to the child's walking cast and the child is allowed to weight bear as soon as tolerated. At 3 to 4 weeks, when radiographs demonstrate some visible callus formation, the proximal tibial pin is removed. Typically, the cast is left on for 6 to 8 weeks with the child weight bearing fully. At 6 to 8 weeks, when full healing is demonstrated, the cast is removed and the child is allowed to go to weight bearing as tolerated with full rehabilitation.



Figure S4.5.1



Figure S4.5.2

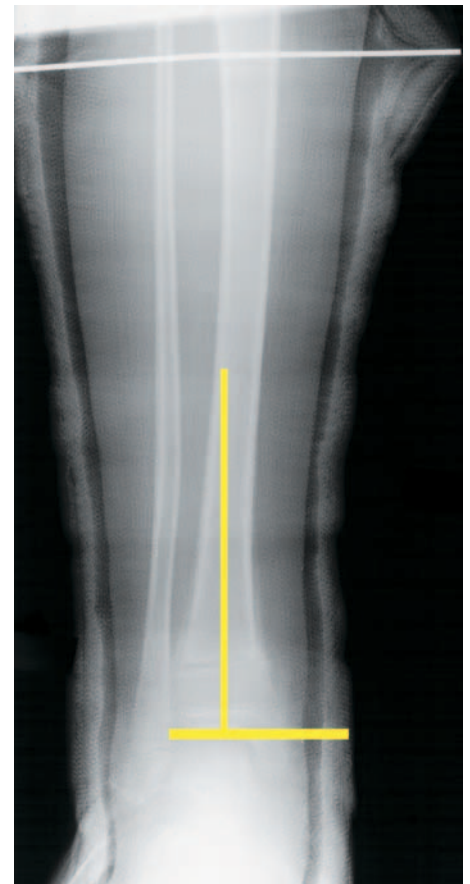


Figure S4.5.3

6. Tibial Osteotomy with Intramuscular Nail

Indication

For individuals whose growth plates have closed and are fully mature and are found to have internal or external tibial torsion that requires correction, tibial osteotomy is performed best utilizing an intramedullary nail. The pins-in-cast technique occasionally yields a delayed union requiring 4 to 6 months of cast wear.

Procedure

1. The osteotomy is performed at the junction of the distal end and middle third of the tibia. This area is visualized under fluoroscopy and a transverse drillhole is placed to fenestrate the tibia.
2. A standard exposure is made to the anterior medial aspect of the tibia for intramedullary nailing. The guidewire is inserted into the tibia, the tibia is reamed in the standard fashion, and an intramedullary nail of the appropriate size is chosen and driven into the tibia just proximal to where the initial drillhole was placed.
3. Utilizing the drill in a fan-shaped fashion, multiple holes are made at this level of the tibia (Figure S4.6.1).

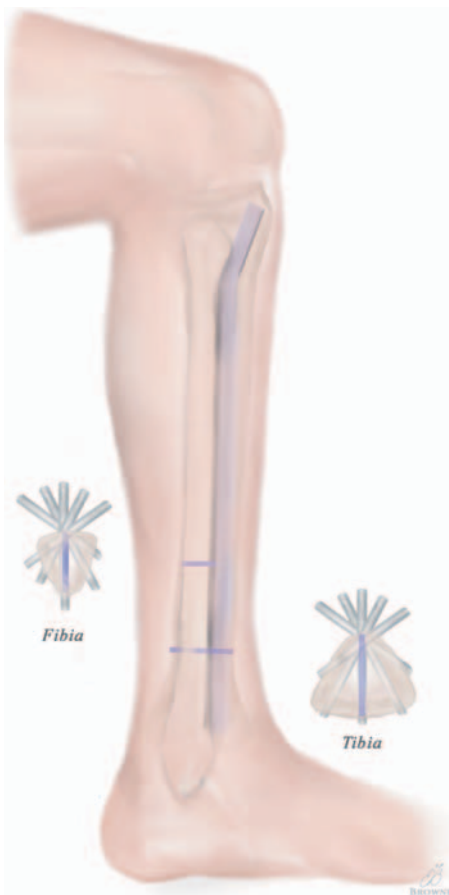


Figure S4.6.1

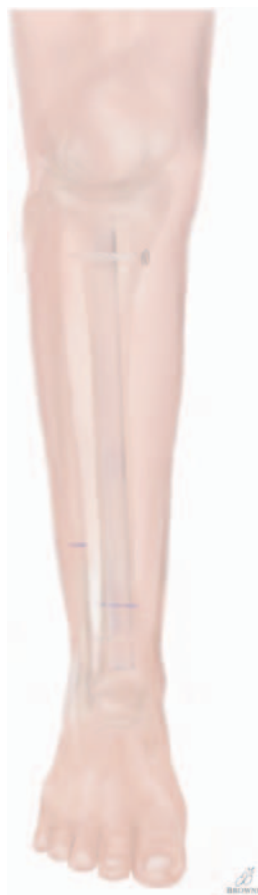

Figure S4.6.2

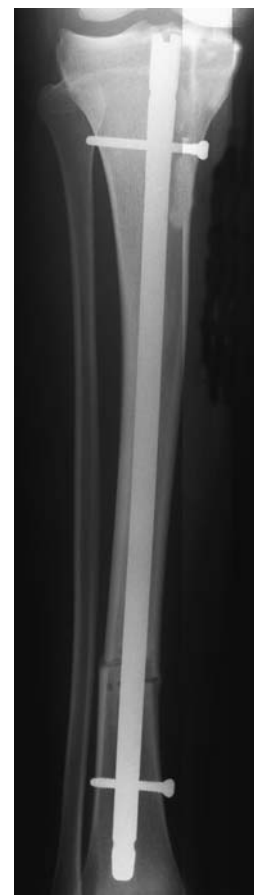

Figure S4.6.3

4. The tibia is fractured with manual force concentrated at this area. Derotation then is performed.
5. The tibial nail is driven across the osteotomy site and into the distal fragment to just proximal to the tibial plafond. While the tibial nail is introduced, care is taken to make sure that there is no varus or valgus deformity of the distal fragment. Fluoroscopic evaluation is required.
6. Proximal and distal transfixion screws are applied (Figures S4.6.2 and S4.6.3).
7. The wounds are closed in the standard fashion.

Postoperative Care

The wounds are covered with waterproof dressings. The child then is mobilized with weight bearing as tolerated, encouraging full weight bearing as quickly as possible. If additional foot procedures or other soft-tissue procedures about the foot were performed, a short-leg walking cast may be needed. The intramedullary nail or transfixion screws are removed postoperatively only if they cause discomfort.

7. Patellar Advancement

Patellar advancement is primarily an operative procedure that is performed only in combination with distal femoral osteotomy, either concomitantly or, if it has been overlooked, as a follow-up operative procedure. For this reason, patellar advancement is presented as part of the distal femoral osteotomy procedure. However, if the procedure is to be performed as an independent procedure, it can be done through a transverse incision at the distal pole of the patella (Figures S4.7.1 and S4.7.2), with the remaining aspect of the procedure being the same as shown in Figures S4.8.11 and S4.8.12.

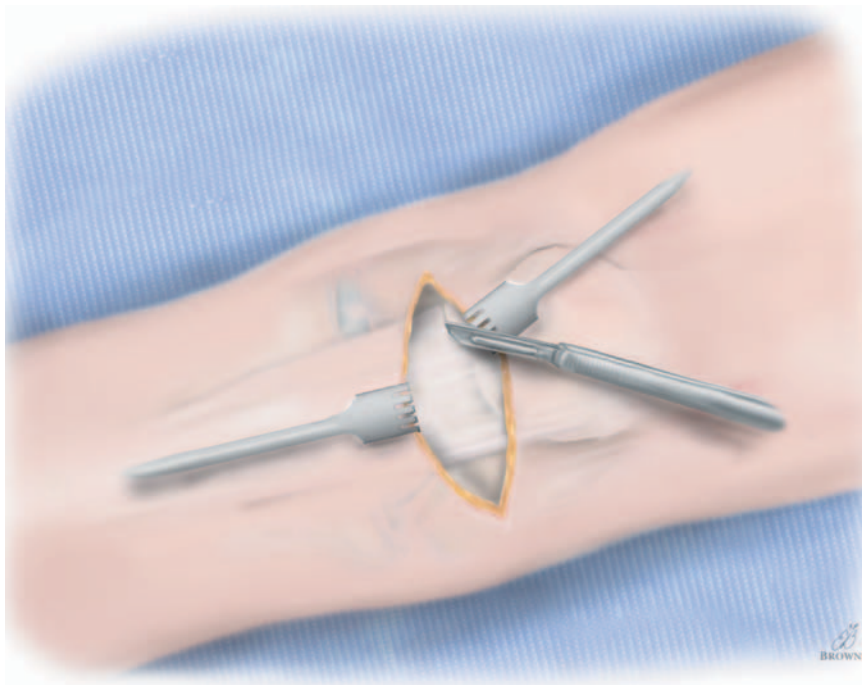


Figure S4.7.1

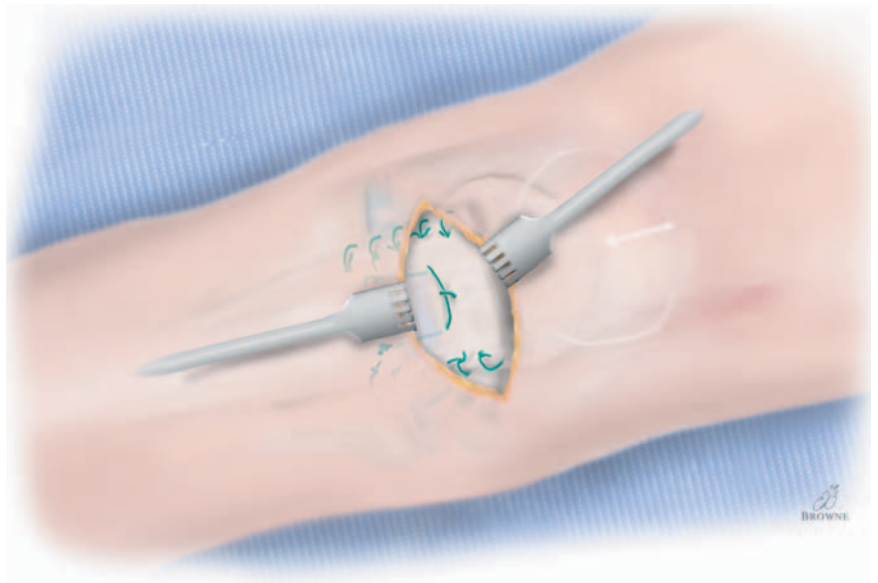


Figure S4.7.2

8. Distal Femoral Osteotomy

Indication

Distal femoral osteotomy is required for knee flexion contractures that are greater than 30°. Derotation and varus-valgus realignment also may be performed at the same time. This osteotomy may be performed with open or closed growth plates, although the fixation is easier if the growth plates are closed.

Procedure

1. The incision is made along the lateral aspect of the distal thigh and carried anterior to the middle of the patellar ligament. The incision needs to extend proximally to approximately the junction of the middle and distal third of the thigh (Figure S4.8.1).
2. The incision is carried down to the knee capsule, which is opened all the way anteriorly to the patellar ligament. The incision then is carried proximally and posteriorly along the edge of the vastus lateralis (Figure S4.8.2). Incision in the periosteum is performed, and subperiosteal dissection allows full exposure of the lateral and anterior femur. Subperiosteal dissection also can be extended circumferentially around the femur in the distal third above the metaphysis. Then, the patella can be dislocated or subluxated to the medial side, exposing the whole distal femur.
3. Insertion of a guidewire at the level of the blade plate is a helpful step. The guidewire is inserted parallel to the distal femoral condyle and parallel to the anterior femur. This guidewire is inserted with visual inspection, but also can be checked with fluoroscopic control (Figure S4.8.3).
4. After insertion of the guidewire, the guidewire should be cut off to allow approximately 3 to 4 cm of wire to be exposed laterally. If the

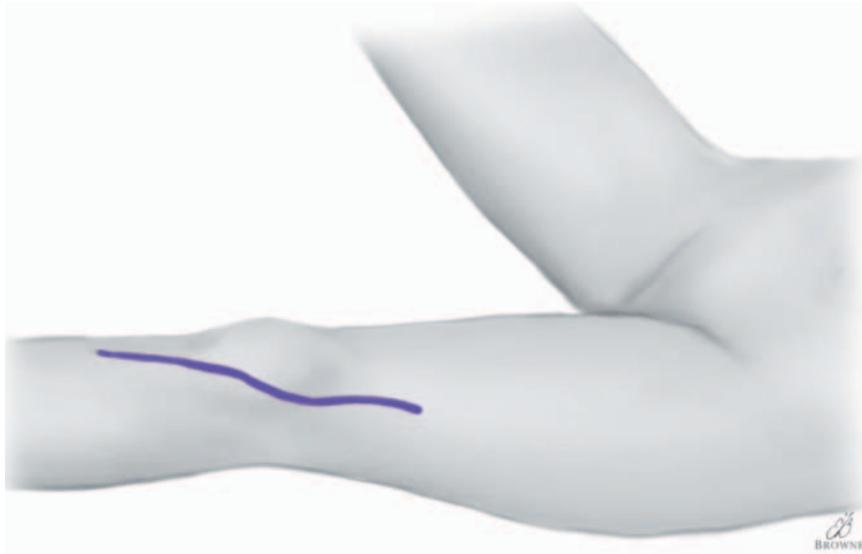


Figure S4.8.1

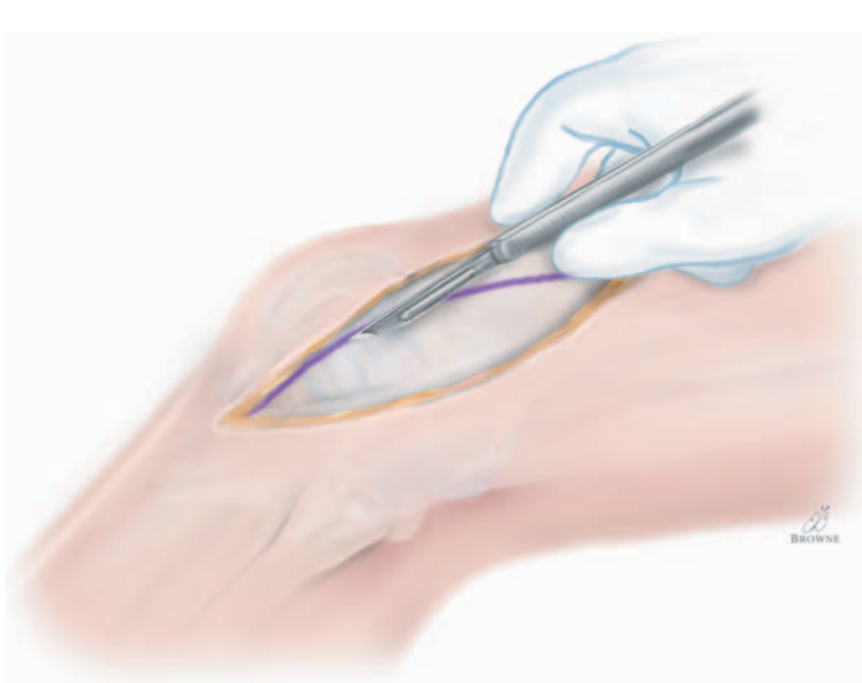


Figure S4.8.2

- growth plate is open, the wire can be inserted distal to the growth plate. The blade plate chisel then is inserted just proximal to this wire in the plane parallel to the tibia, with the tibia in maximum extension.
5. The chisel for the blade plate is inserted under visual control and can be checked with the fluoroscope. The level of the chisel insertion should be immediately proximal to the growth plate if the child still has an open growth plate, or should be inserted so that it will be just above the notch of the femoral condyles if the growth plate is closed. Medial lateral insertion should be parallel to the distal femoral

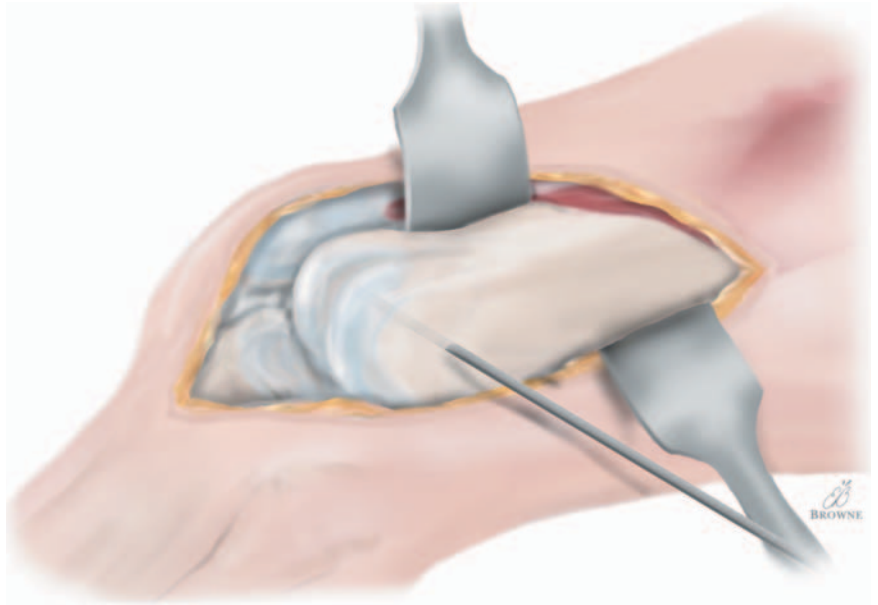


Figure S4.8.3

condyles. If varus-valgus correction is desired, the chisel is still inserted parallel to the distal femoral condyles. With the knee in maximum extension, the flat side of the chisel should be at a right angle (Figure S4.8.4, label B) to the long axis of the tibia (Figure S4.8.4, label A). This angle will correct the flexion contracture. Then, the chisel is introduced from lateral to medial until it just can be palpated on the medial side.

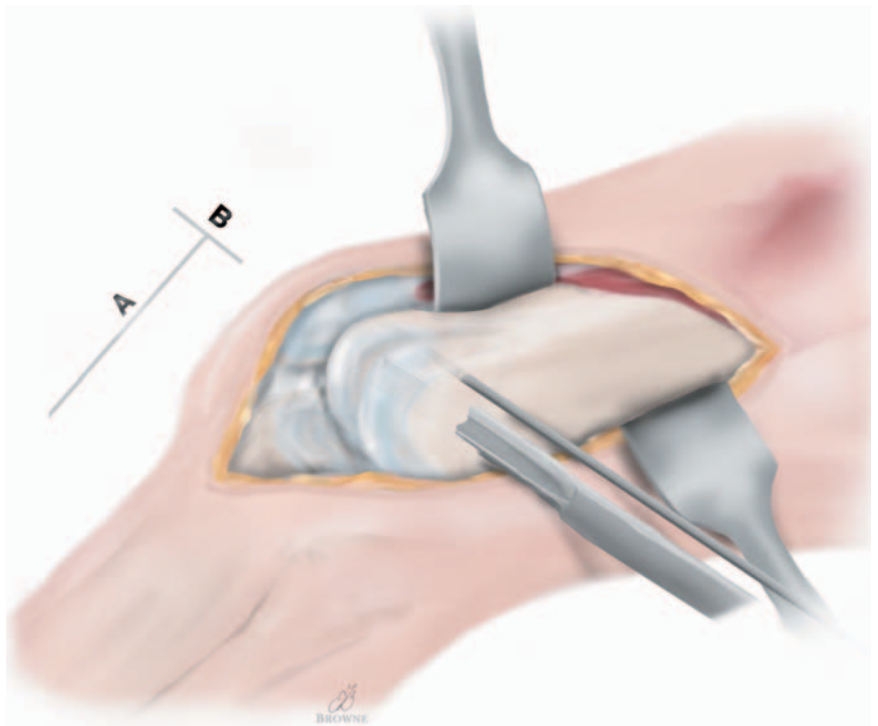


Figure S4.8.4

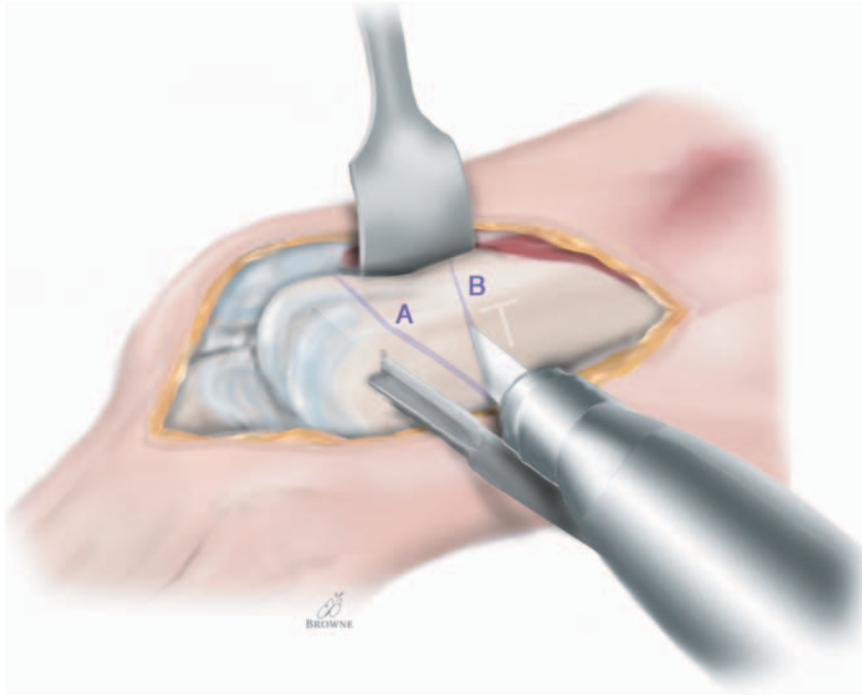


Figure S4.8.5

6. Utilizing an oscillating saw, the distal osteotomy is made parallel to the inserted chisel 12 to 15 mm proximal to the chisel (Figure S4.8.5, A).
7. The proximal osteotomy is made transverse to the proximal femur at the level where the distal osteotomy ends (Figure S4.8.5, B). This osteotomy will now remove a significant anterior wedge from the femur (Figure S4.8.6). After removal of this wedge, full extension of the knee should be possible with minimal tension. If full extension is still not possible, additional transverse resections of the proximal femur should be performed. In some severe contractures, an additional several centimeters of resected femur may be required.
8. After the correct amount of femur has been resected, and due to the obliquity of the distal osteotomy, a large posterior spike will be present on the distal fragment. This large posterior fragment can be transected; however, care should be taken not to remove an excessive amount because it will cause weakening of the distal fixation (Figures S4.8.7 and S4.8.8).
9. The chisel is removed and the blade plate will be inserted. Blade plate size typically is chosen as an offset right-angle hip plate. Because of the shortening, the distal femoral osteotomy configuration causes the bone surface on the distal end to be larger than the proximal end. For most adults, the adult-sized condylar blade plate is preferred. For adolescents or children in middle childhood, the adolescent-sized plates are ideal. The length of the blade plate is chosen to avoid penetration on the medial side, and this can be checked best under fluoroscopic control with the introduction of the chisel, and measuring the depth of chisel insertion (Figure S4.8.7).
10. The osteotomy is reduced, taking care to reduce the anterior surface of the osteotomy so the patellar femoral groove will not develop an offset. With major shortening requirements, the circumference of the

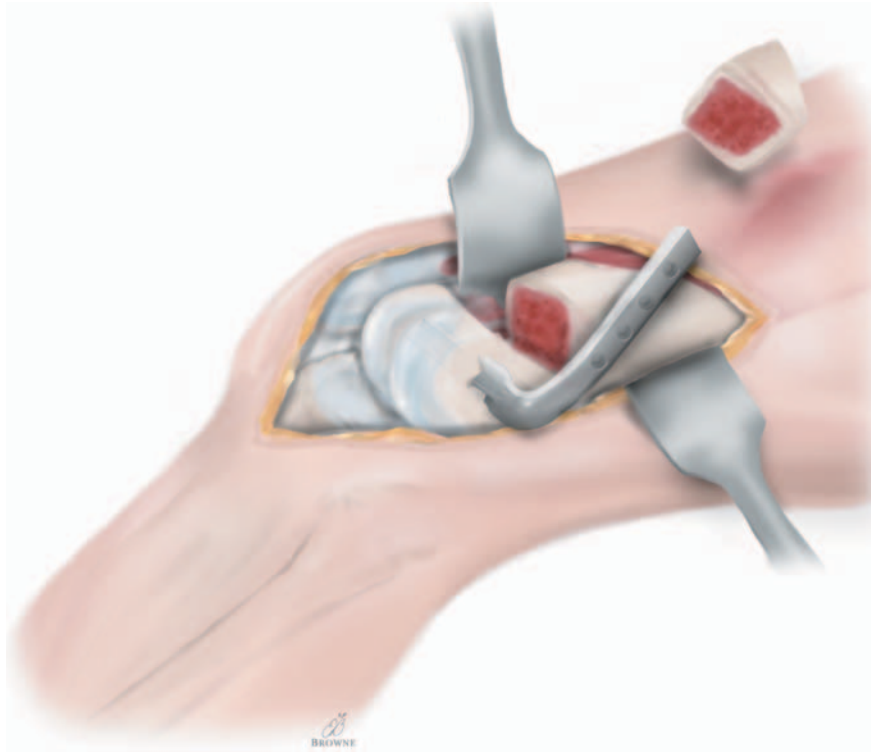


Figure S4.8.6

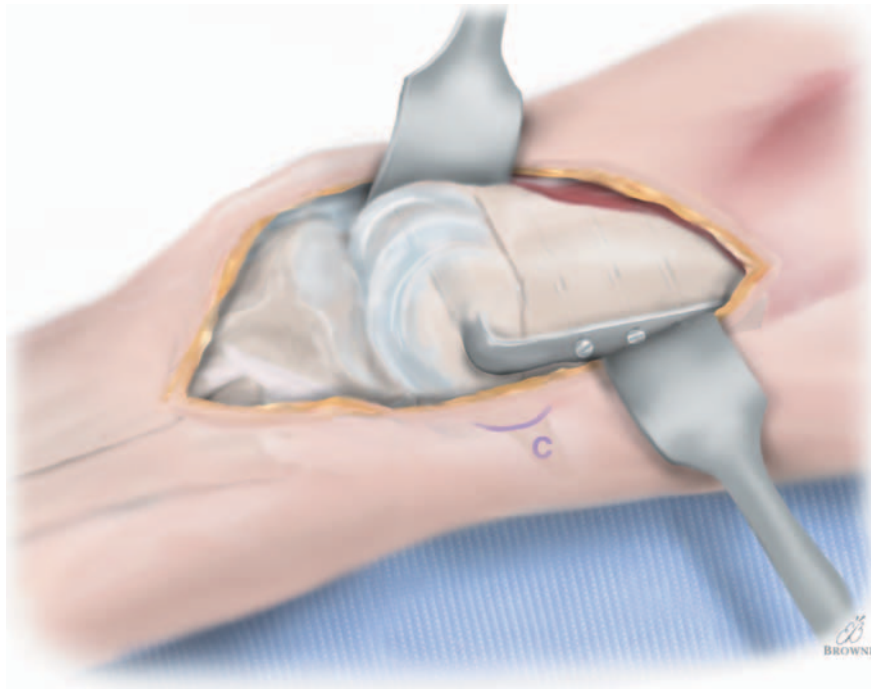


Figure S4.8.7

proximal fragment sometimes is much less than the circumference of the distal fragment. The reduction should be performed in the midline with the anterior cortices aligned. Then, the osteotomy is compressed, using the compression holes and the side plate. The removed bone then can be fragmented and placed alongside the osteotomy to fill in the major defects (Figure S4.8.9).

11. Advancement of the patellar ligaments usually is required because of the significant shortening that has occurred due to correction of major flexion contractures. If the growth plate of the proximal tibia is closed, the patellar ligament insertion on the tibial tubercle can be advanced by utilizing an osteotomy and resecting the tibial tubercle. The incision has to be extended distally, and this bone block advanced distally to the point where 90° of knee flexion is allowed. The bone is roughened and a screw with a washer is inserted to hold the bone block with the inserted patellar ligament (Figure S4.8.10).
12. If the tibial epiphysis is open, the use of patellar ligament plication is another alternative, and can be used for adults as well. This plication is performed by obliquely transecting the patellar ligament and then overlapping it and suturing the ligament with heavy absorbable sutures so its length is such that the knee can just barely flex to 90° (Figure S4.8.11).
13. The wounds are closed, being careful to perform a good closure of the lateral capsule.

Postoperative Care

For the child with good stable fixation by patellar advancement and good bony fixation, the knee is immobilized in a knee immobilizer only. Immediate

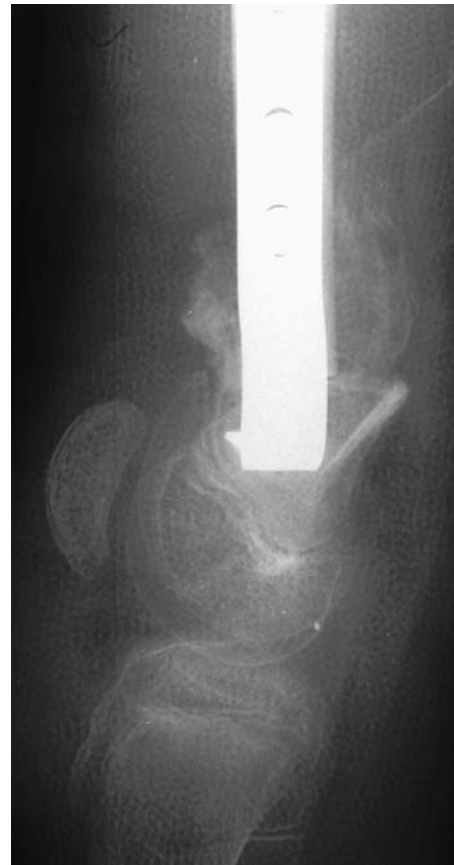


Figure S4.8.8

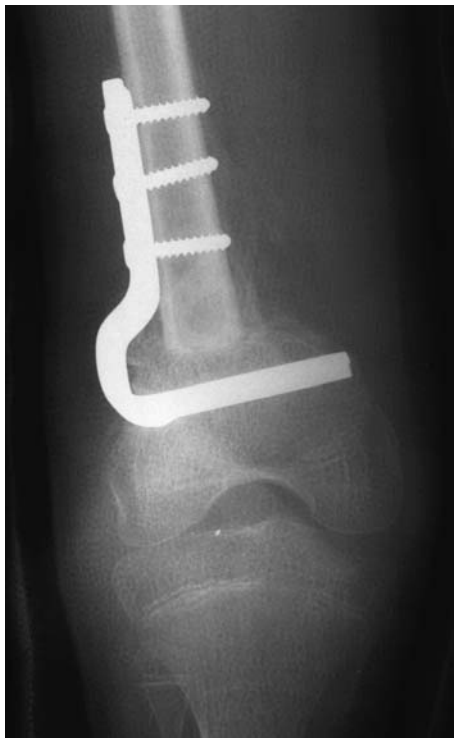

Figure S4.8.9

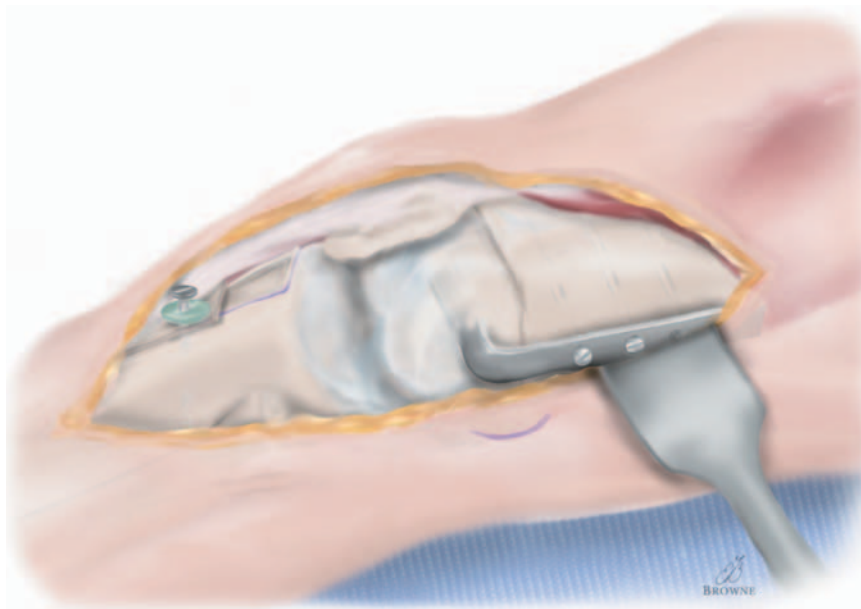


Figure S4.8.10

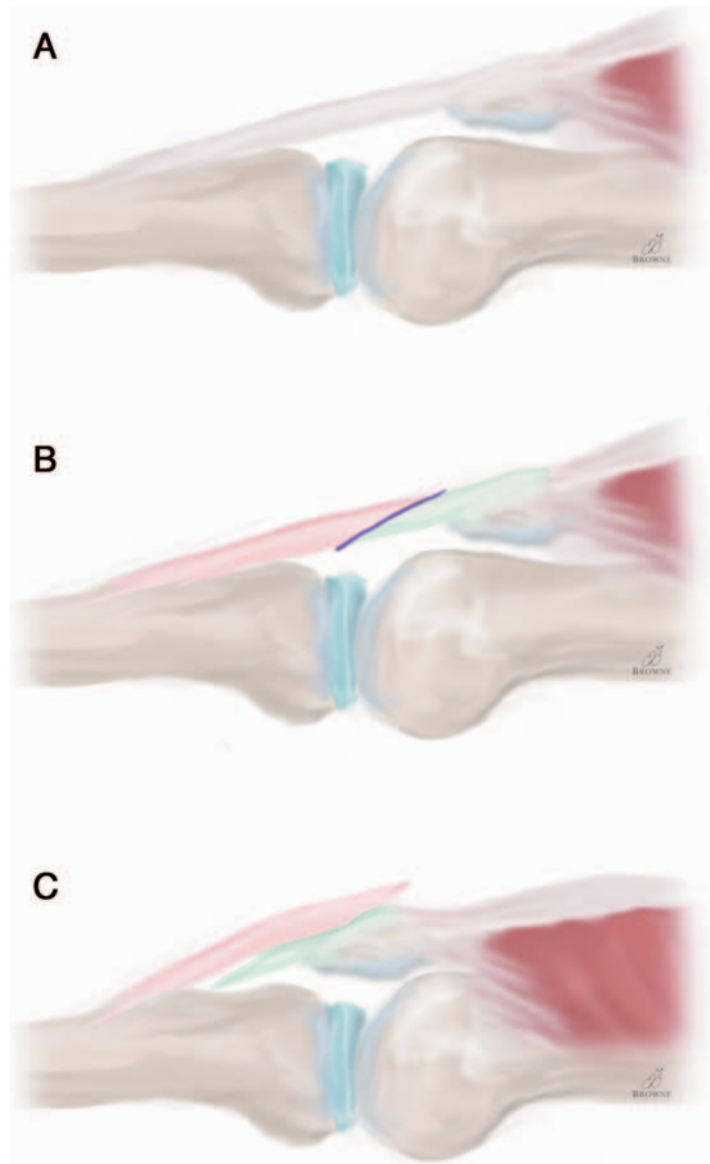


Figure S4.8.11

range-of-motion exercises are begun, avoiding knee flexion past 45° . For children who have had patellar ligament plication, or whose bones are less strong, the knee is immobilized in a knee cylinder cast. The knee cast may be split and used as a bivalve cast, which can be removed typically between 2 to 4 weeks, and gentle passive range-of-motion exercises begun. Weight bearing is allowed either immediately postoperatively if the fixation is sufficiently stable, or started at 4 to 6 weeks postoperatively. Knee extension splinting is required usually for 6 months, especially at nighttime to prevent recurrent deformity.

Foot and Ankle Procedures

1. Ankle Epiphysiodesis Screw

Indication

This procedure is used to provide a temporary unilateral epiphysiodesis to treat ankle valgus in a child with enough growth remaining for the valgus to correct.

Procedure

1. The procedure is done under fluoroscopic control introducing a guidewire through the superficial tip of the medial malleolus with the goal of the screw entering the epiphysis at its medial border. Then, the pin is introduced across the epiphyseal plate 5 mm from the medial edge of the epiphysis.
2. A 4.5-mm cannulated screw then is introduced over the guidewire. The screw length should be long enough to contact the contralateral cortex, or should provide good fixation in the metaphyseal bone. The screw is countersunk slightly into the medial malleolus so it is not superficially prominent (Figure S5.1.1).

Postoperative Care

Postoperative care requires no immobilization for this procedure. Careful postoperative monitoring with radiographs is required every 4 to 6 months, and the screw should be removed as soon as full correction to very mild overcorrection has been achieved. Do not allow overcorrection of more than 3° to 5°.

2. Subtalar Fusion

Indication

Subtalar fusion is indicated to treat planovalgus foot deformities in children with hypotonia or severe planovalgus collapse, especially in individuals who are marginal ambulators. Because subtalar fusion may cause some growth decrease in the hindfoot, the procedure should not be used on very young feet. Age 5 to 7 years is the typical age when this procedure is first considered.

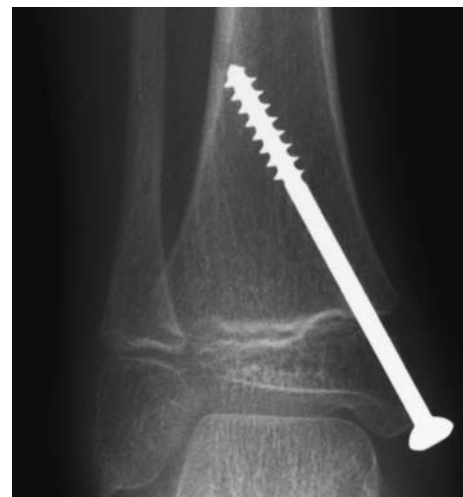

Figure S5.1.1

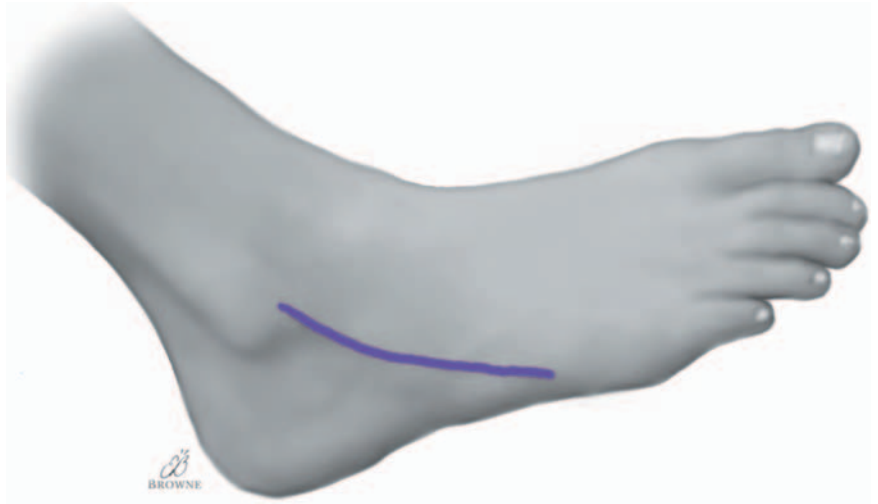


Figure S5.2.1

Procedure

1. The incision is made just anterior to the peroneus brevis tendon and then curved proximally to the anterior border of the lateral malleolus. Distally, the incision is extended and curved slightly toward the plantar surface at the base of the fifth metatarsal if needed (Figure S5.2.1).
2. A subcutaneous incision is carried down to just anterior to the peroneus brevis where a sharp incision in the periosteum is made (Figure S5.2.2).
3. Subperiosteal dissection using a knife or sharp dissector is used to elevate all the soft tissue out of the sinus tarsi including the insertion of the peroneus tertius. All the soft tissue is excised or reflected distally until the capsule of the calcaneocuboid joint is well exposed. All

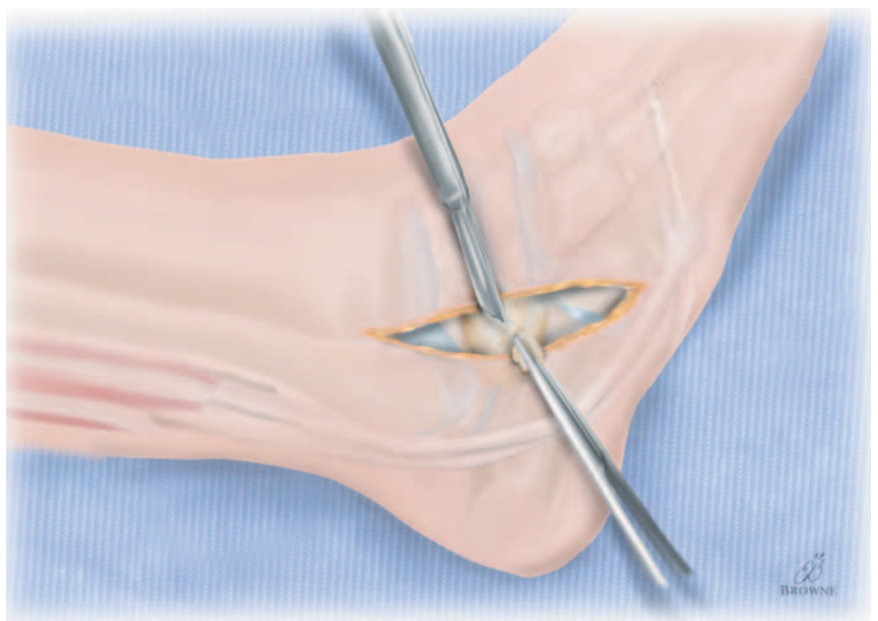


Figure S5.2.2

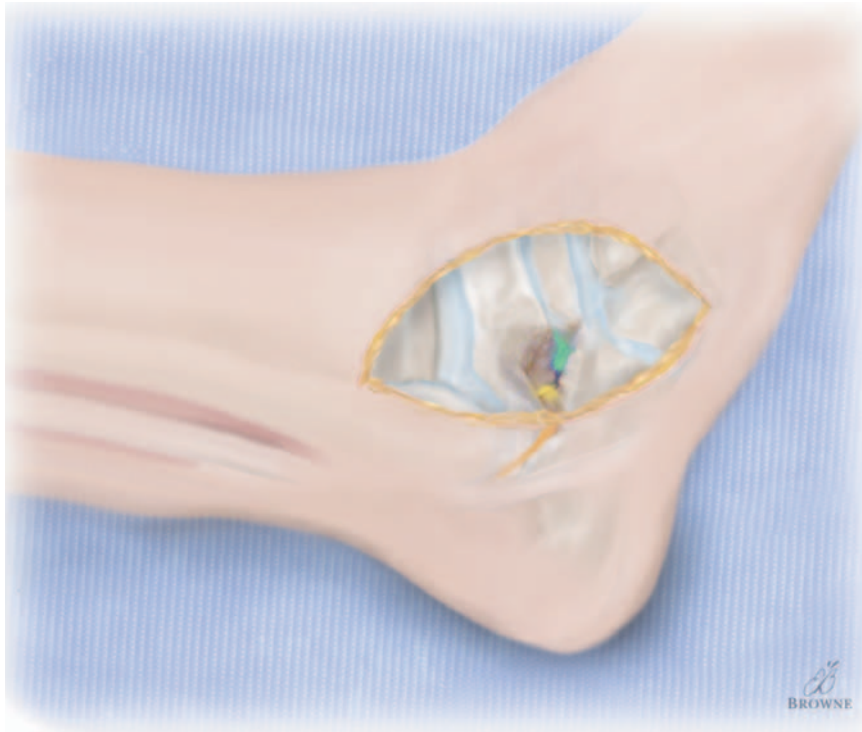


Figure S5.2.3

soft-tissue capsules of the posterior, middle, and anterior facets are removed from the sinus tarsi until there is excellent visualization of anterior, middle, and posterior facet cartilage.

4. The cartilage is removed from the anterior and middle facets, being very careful not to remove any bone. Cartilage in the anterior central part of the posterior facet is removed with a curette. No cartilage is removed from the lateral or medial aspect of the posterior facet to avoid loss of height of the calcaneus talus relationship (Figure S5.2.3).
5. A medial incision is made just lateral to the tibialis anterior and curved medially over the anterior insertion of the tibialis posterior. The incision is extended through the subcutaneous tissue to the neck of the talus (Figure S5.2.4).
6. The talar neck and talonavicular joints are exposed so the head of the talus is well visualized and the ankle joint can be palpated (Figure S5.2.5).
7. A guidewire is introduced through an insertion site on the anterior medial aspect of the talar neck, which will allow the wire to transfix the talar neck at 40° to 45° (Figure S5.2.6). If this is an adolescent or adult foot that is nearly full size, a 7-mm cannulated screw with a washer is used (Figure S5.2.7, Screw A). If this is a middle childhood-sized foot, a 4.5-mm cannulated screw should be used. The introduction site of the guidewire should be 5 to 10 mm proximal to the cartilage of the head of the talus.
8. After the tip of the guidewire is introduced into the neck of the talus, the lateral side is visualized again, and the relationship of the calcaneus to the talus is reduced into the desired position with 30° to 40° of calcaneal dorsiflexion relative to the talus (Figure S5.2.7, angle C). The anterior aspect of the calcaneus should be parallel to the anterior aspect of the head of the talus. The anterior facet should be reduced.

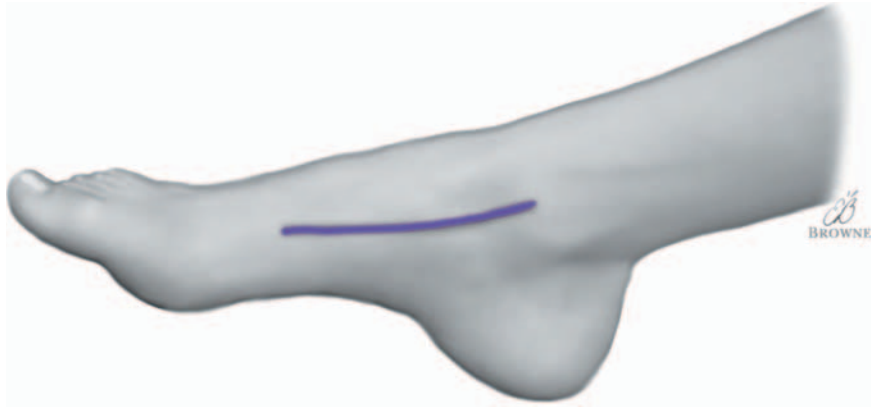


Figure S5.2.4

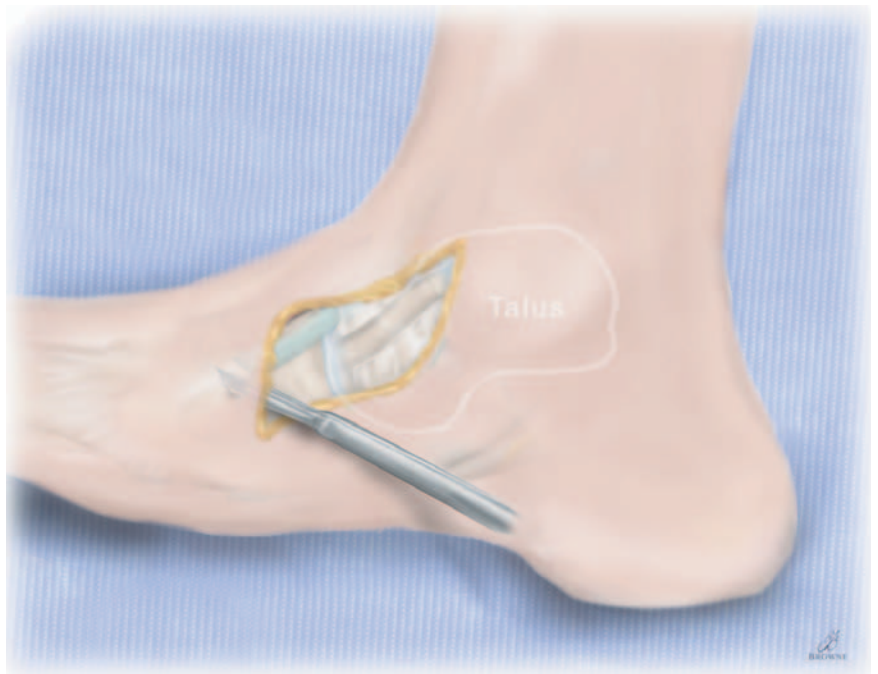


Figure S5.2.5

The guidewire now is advanced across the neck of the talus transversely across the foot so it crosses the reduced anterior facet, crosses the calcaneus, and exits the calcaneus at the inferior lateral border of the calcaneus approximately 5 mm posterior to the calcaneocuboid joint (Figure S5.2.6).

9. Bone graft is placed into the sinus tarsi and the denuded posterior facet area (Figure S5.2.8).
10. If this is an adult-sized foot, a second pin is introduced through the anterior incision from directly anterior on the neck of the talus, directed at the calcaneal tuberosity. A 7-mm cannulated screw is introduced so that its head can be countersunk slightly into the anterior neck of the talus, but the screw should not exit posterior or it will cause irritation if it is palpable. This screw will cross the center of the posterior facet (Figures S5.2.7, Screw B and S5.2.9, Screw B).

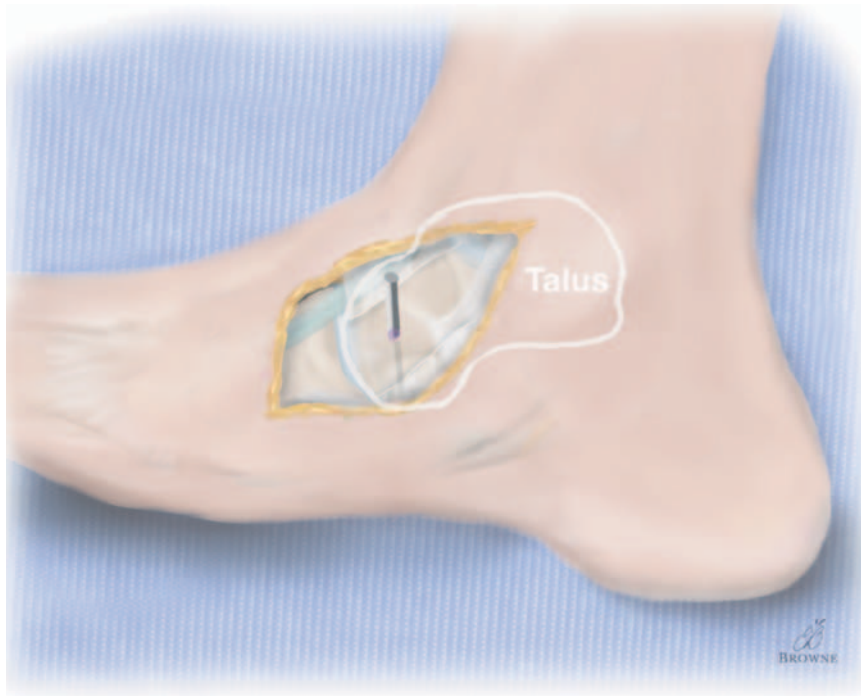


Figure S5.2.6

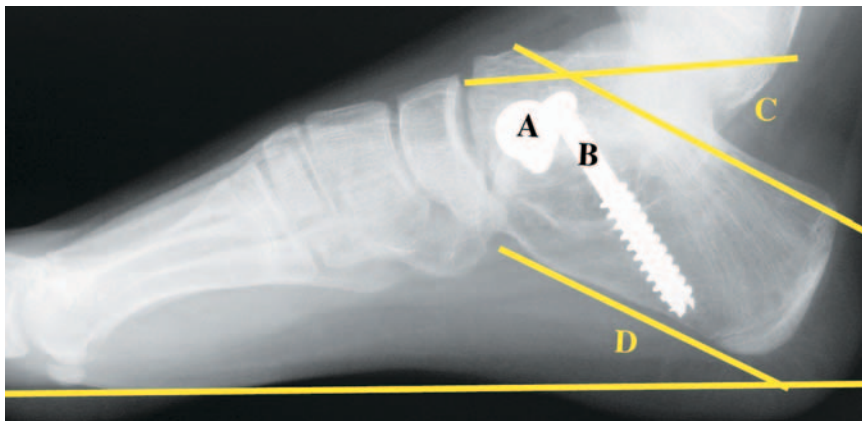


Figure S5.2.7

11. At this time, careful review of the relationship of the calcaneus is performed again to make sure that the desired 30° to 40° of calcaneal dorsiflexion relative to the talus has occurred (Figure S5.2.7, angle C). The talus should be in 10° to 20° of plantar flexion relative to the tibia with a neutral ankle position. If this position is not possible and more equinus is present, a gastrocnemius or tendon Achilles lengthening needs to be performed, based on physical examination.
12. Following fixation of the hindfoot, careful evaluation of the forefoot is required to make sure that there is no first ray elevation or significant dorsal or medial bunion. Pressure on the forefoot should cause ankle dorsiflexion.
13. If forefoot pressure causes first ray elevation, or abduction and dorsiflexion of the lateral column through the calcaneocuboid joint,

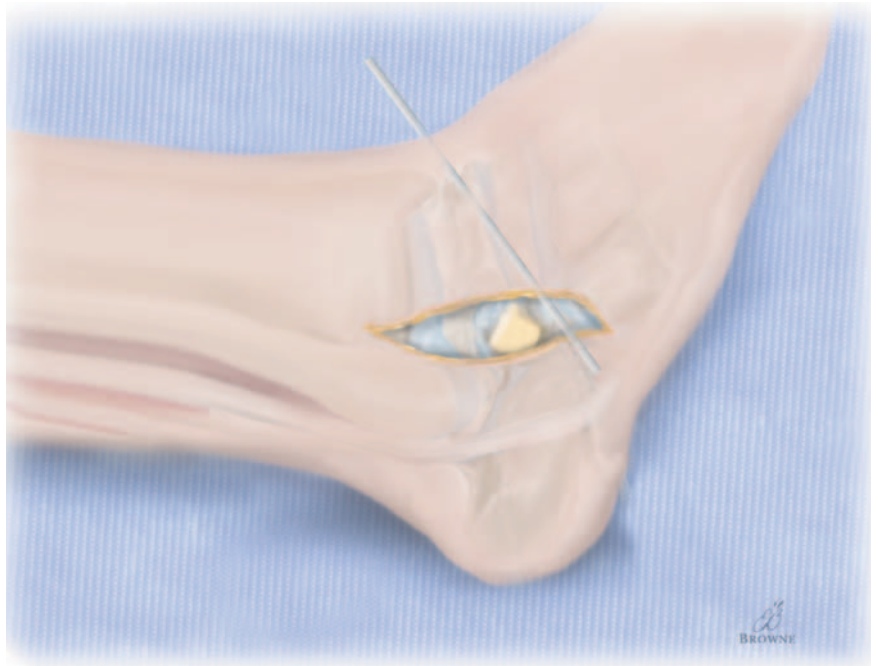


Figure S5.2.8

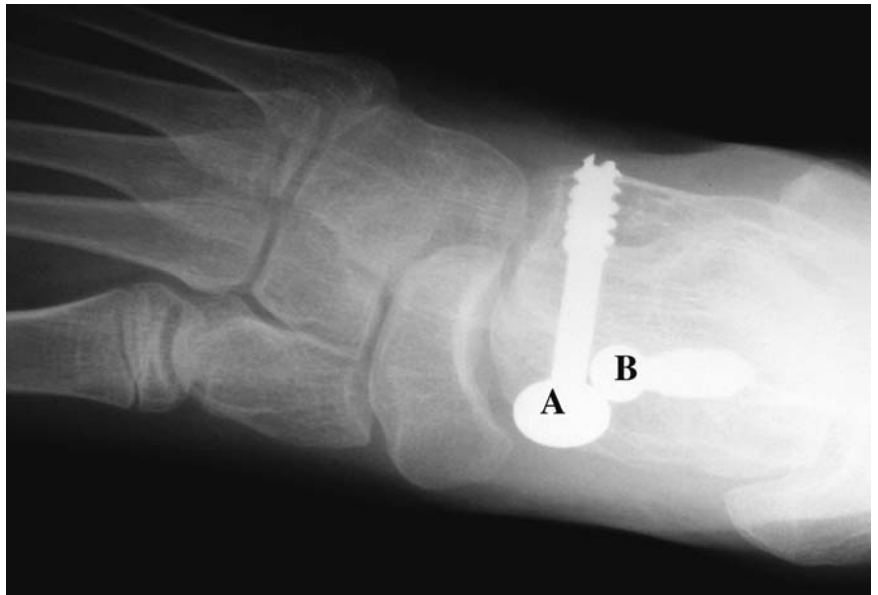


Figure S5.2.9

these deformities have to be corrected by the appropriate procedures defined next.

14. Attention is directed to the medial aspect, where the arch should be palpated, and if the tuberosity of the navicular is very prominent, the insertion of the tibialis posterior should be excised from the navicular without excising any cartilage.
15. Then, the navicular tuberosity is excised parallel to the edge of the head of the talus and the navicular cuneiform joint.

16. The insertion of the tibialis posterior is reattached with heavy suture, which is sutured through the bone of the navicular and cuneiform.
17. The skin is closed with a rapid absorbable suture, usually using plain gut suture both medially and laterally.

Postoperative Care

Postoperative management includes the use of a short-leg, full weightbearing cast for 6 to 8 weeks. Weight bearing is allowed as soon as pain is tolerated. After the cast is removed, no orthotics are used until it is determined whether the foot is in a stable position, or the child needs orthotics for ankle control or a tendency for foot collapse.

3. Lateral Column Lengthening Through the Calcaneus

Indication

Calcaneal lengthening is indicated for children who are high-functioning ambulators and whose hindfoot valgus, external rotation, and posterior facet subluxation deformity are supple and of mild to moderate severity. Options for correction of the lateral column shortening and abduction include calcaneal lengthening between anterior and middle facets, opening wedge of the anterior lateral corner of the calcaneus, calcaneocuboid fusion with lengthening, or a medial displacement varus calcaneal tuberosity osteotomy (Figure S5.3.1). Excision of the fifth metatarsal tuberosity may be added if it is noted to be prominent.

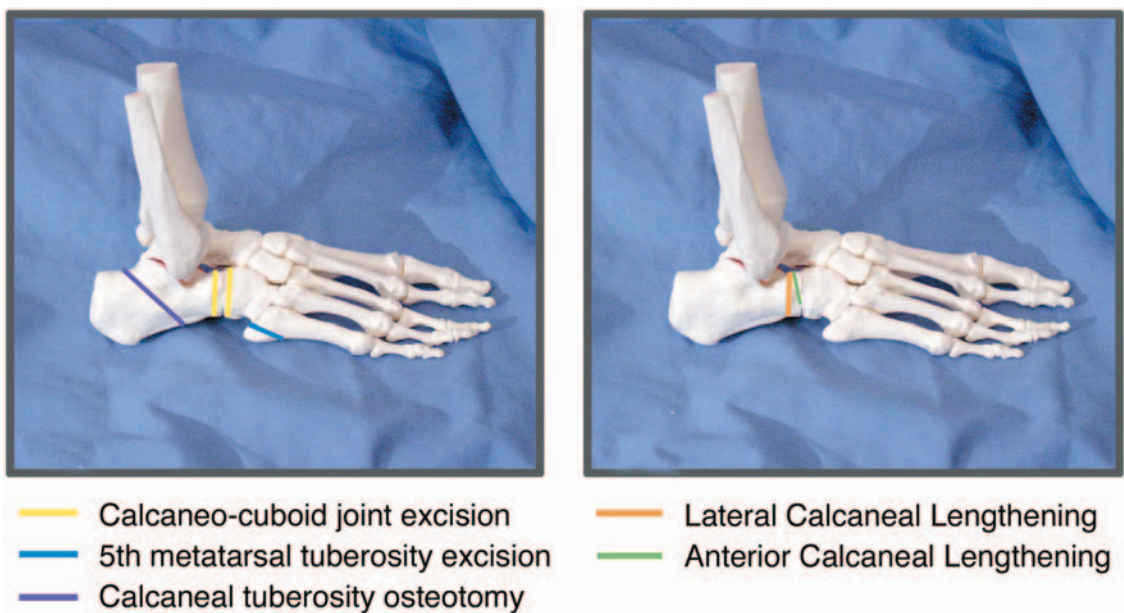


Figure S5.3.1

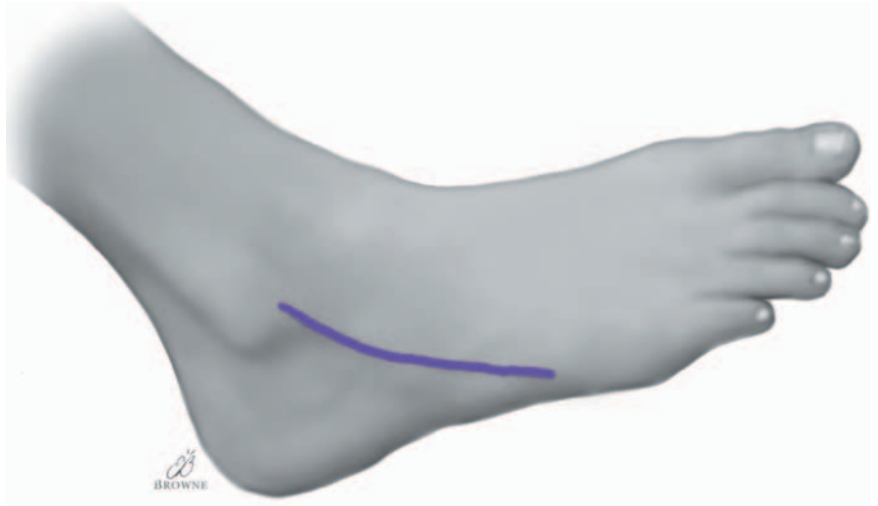


Figure S5.3.2

Procedure

1. The skin and subcutaneous exposure with cleanout of the sinus tarsi is the same as for the subtalar fusion (Figure S5.3.2).
2. The interval just anterior to the middle facet is identified in the sinus tarsi.
3. Subperiosteal dissection is performed on the lateral calcaneus from the capsular insertion of the calcaneocuboid joint anterior and then extended posterior to the middle of the calcaneal tuberosity. Subperiosteal dissection is undertaken around the inferior border of the lateral calcaneus.
4. A retractor is placed around the inferior border of the lateral calcaneus.
5. An oscillating saw is used and the calcaneus is transected in the transverse plane at the level just anterior to the middle facet (Figure S5.3.3, M). If the medial side of the calcaneus is not completely transected with the saw, it should be completed with an osteotomy (Figure S5.3.3).
6. The osteotomy now should be free and easy to be distracted, usually using a lamina spreader at the superior lateral corner of the osteotomy. The osteotomy is spread until the foot appears to be corrected.
7. If the peroneus brevis is contracted limiting the amount of opening of the osteotomy, a separate incision is made 6 to 8 cm proximal to the tip of the lateral malleolus, and the peroneus tendon is exposed posterior to the fibula. If good muscle belly is present, a myofascial lengthening is made; however, if only tendon is encountered, a Z-lengthening of the peroneus brevis is performed. Never lengthen the peroneus longus (Figure S5.3.4).
8. By spreading the osteotomy with a Cobb elevator or lamina spreader, the forefoot should swing into adduction and supination should correct. The peroneal arch should be recreated and stable. The osteotomy is distracted until the forefoot adduction and supination have been corrected, usually requiring approximately 10 mm of lateral opening. Overcorrection is not advised.
9. Using the amount of distraction as a guide, bank bone or the patient's iliac crest bone is harvested and shaped into a trapezoid with the wide area pointing lateral and superior in the osteotomy. The graft

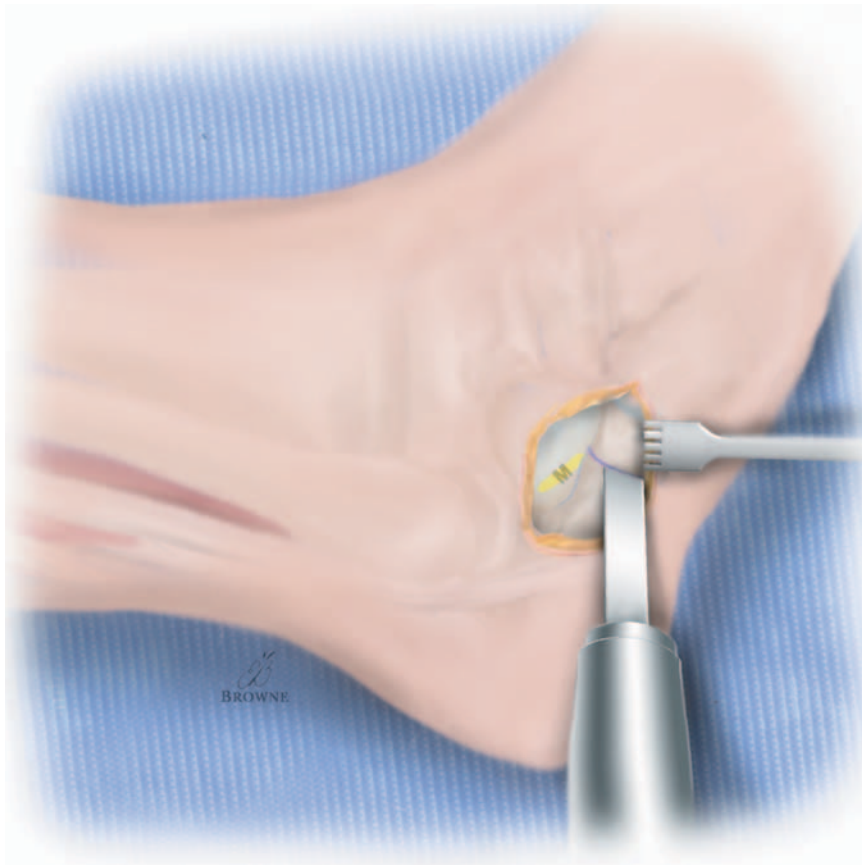


Figure S5.3.3

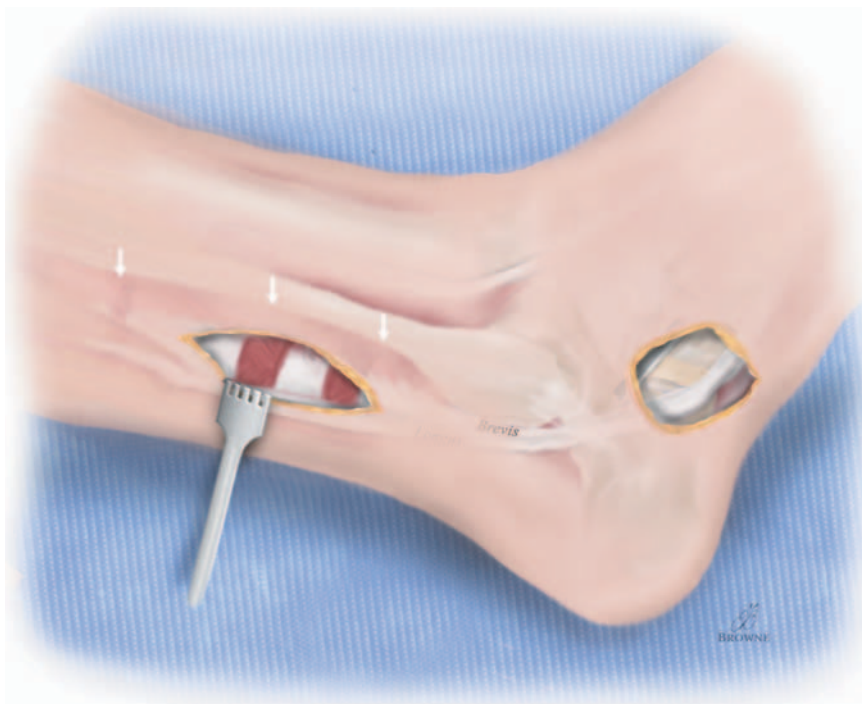


Figure S5.3.4

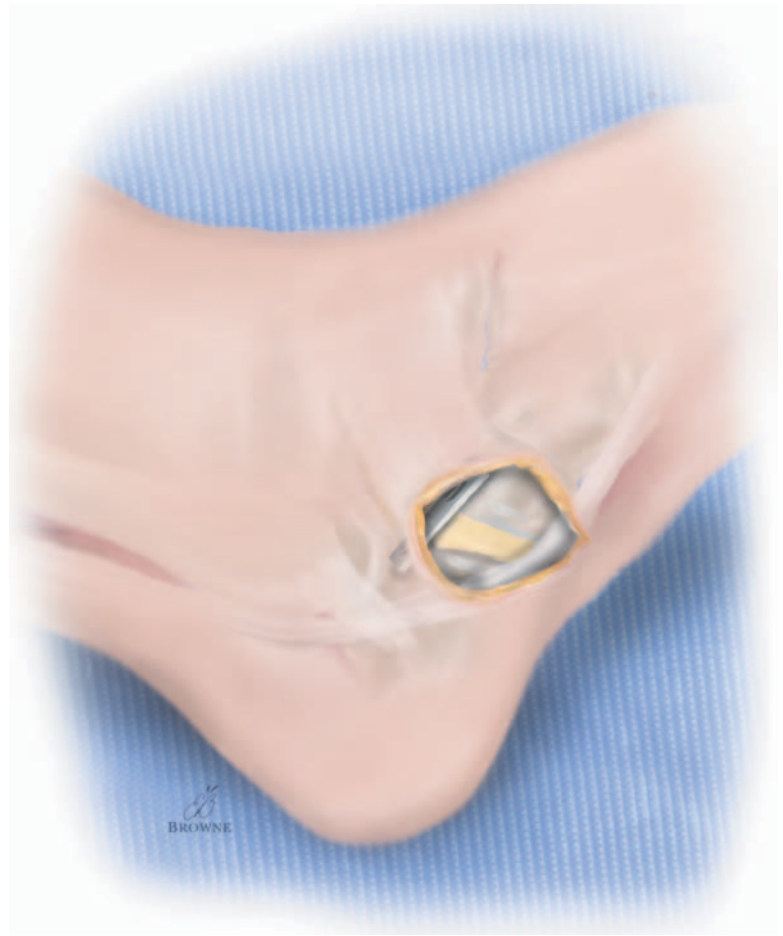

Figure S5.3.5

is inserted until it is slightly countersunk and is stable. Usually, the width of this graft is approximately 1 cm on the wide side and 5 mm on the narrow end, but the specific size should be determined by the amount of distraction needed (Figure S5.3.5).

10. The osteotomy is fixed with a longitudinal K-wire or with a two-hole semitubular plate (Figure S5.3.6).
11. The foot again is assessed carefully to determine if there is any first ray elevation of the medial column, especially to determine if first ray elevation occurs with dorsiflexor pressure on the plantar surface.
12. Also, if dorsiflexor pressure causes forefoot abduction and dorsiflexion through the lateral column at the calcaneocuboid joint, this deformity also needs to be corrected. Additional medial and lateral column correction is performed utilizing procedures discussed in calcaneocuboid joint lengthening and forefoot supination and medial ray elevation procedures.

Postoperative Care

The foot is immobilized in a short-leg walking cast with a good mold to hold the foot in its corrected position and to mold in both medial and lateral longitudinal arches. The toes are kept in the dorsiflexed position with a toe plate. The child is allowed weight bearing as tolerated, and the cast is required usu-

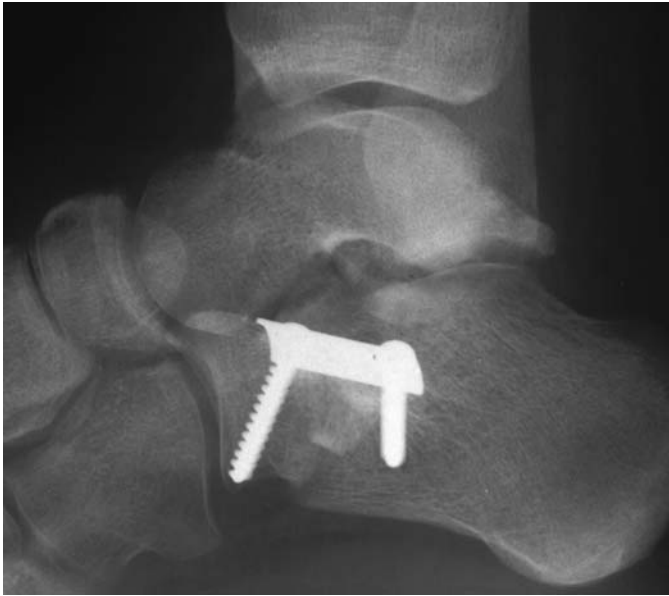

Figure S5.3.6

ally for 6 to 8 weeks until healing of the osteotomy has occurred. Following cast removal, the child is allowed to weight bear as tolerated, initially without the use of an orthotic. If the foot has a tendency to not be completely stable, an in-shoe orthotic, such as a supramalleolar orthotic, is prescribed.

4. Lateral Column Lengthening Through the Calcaneocuboid Joint

Indication

Lateral column lengthening through the calcaneocuboid joint can be combined with subtalar fusion or can be performed as an isolated procedure. If lateral column lengthening through the calcaneocuboid joint is performed with a subtalar fusion, after the subtalar fusion has been performed the indication for lateral lengthening is determined by significant lateral subluxation and abduction of the forefoot when pressure is placed on the plantar surface of the forefoot. Calcaneocuboid joint fusion lengthening as an isolated procedure is indicated when the child has substantial dorsiflexion through the midfoot with moderate hindfoot deformity. This procedure is performed typically as an isolated procedure only in adolescents or young adults.

Procedure

1. The exposure is via the distal end of the incision used for the subtalar fusion. The incision is carried anteriorly and curved toward the plantar aspect of the first metatarsal insertion of the area of the peroneus brevis. Subcutaneous incision is carried down to the calcaneocuboid joint, which is opened, and the capsule of the calcaneocuboid joint is removed along its whole lateral border and anterior border with good exposure. The calcaneocuboid joint usually demonstrates severe rounding over the distal end of the calcaneus with lateral and superior subluxation of the cuboid.

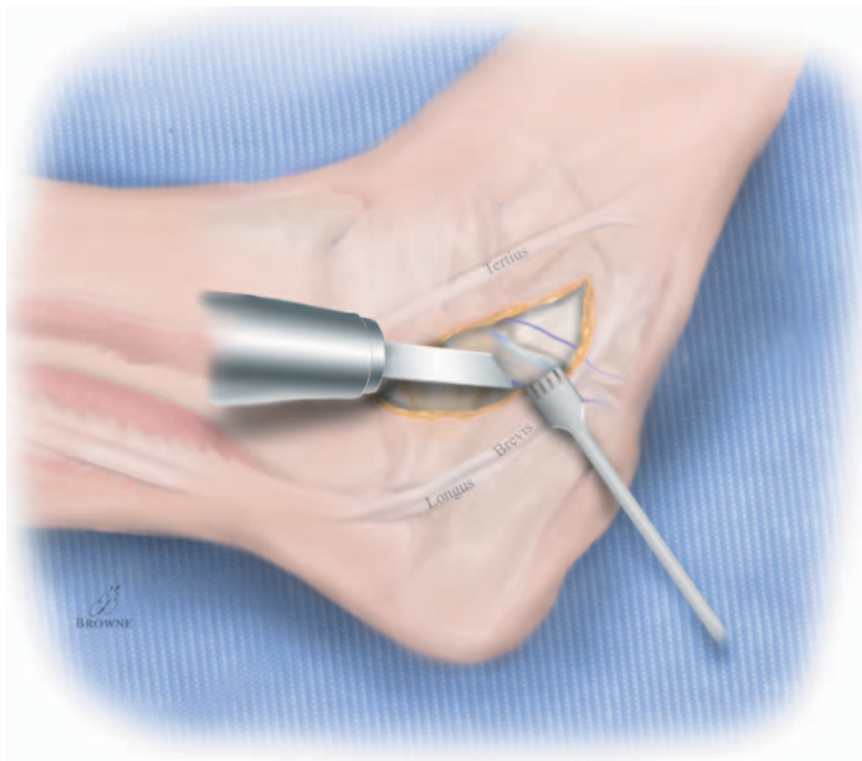


Figure S5.4.1

2. An oscillating saw is utilized, and the cartilage at the distal end of the calcaneus is transected in a plane that is at right angle to the hindfoot with the subtalar joint reduced. The cartilage of the proximal end of the cuboid is resected in a plane that is at right angles to the longitudinal plane of the forefoot (Figure S5.4.1).
3. A lamina spreader is inserted into this resection and spread until the foot is reduced with creation of the lateral peroneal arch, correction of the forefoot abduction, and dorsiflexion. The amount of distraction needed to correct the foot is measured.
4. Bone graft is prepared utilizing tricortical iliac crest bank bone or the patient's own harvested bone. A trapezoidal-shaped piece of bone, measuring 1.5 cm on its wide end and 1 cm on the narrow end, usually is required. However, the specific size of the bone is determined based on the distraction needed to correct the deformity. Care must be taken not to overcorrect the deformity, which is easy to do at this level.
5. The wide end of the trapezoidal bone graft is placed superior to create a capstone on the apex of the lateral peroneal arch. The cuboid should be elevated so its anterior surface is parallel to the anterior surface of the tip of the calcaneus.
6. A three- or four-hole semitubular plate is contoured across the anterior aspect of the arthrodesis site and fixed with screws in the calcaneus and cuboid (Figures S5.4.2 and S5.4.3).
7. Then, the forefoot is assessed carefully, especially evaluating the presence of prominence of the navicular and elevation of the first ray for forefoot supination deformities or a dorsal bunion. If these deformities are noted to be present, they have to be corrected as indicated.

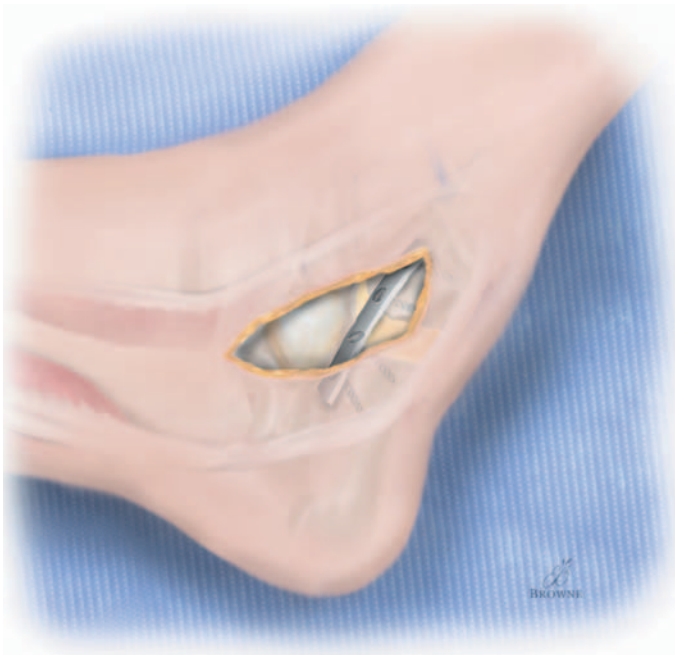


Figure S5.4.2

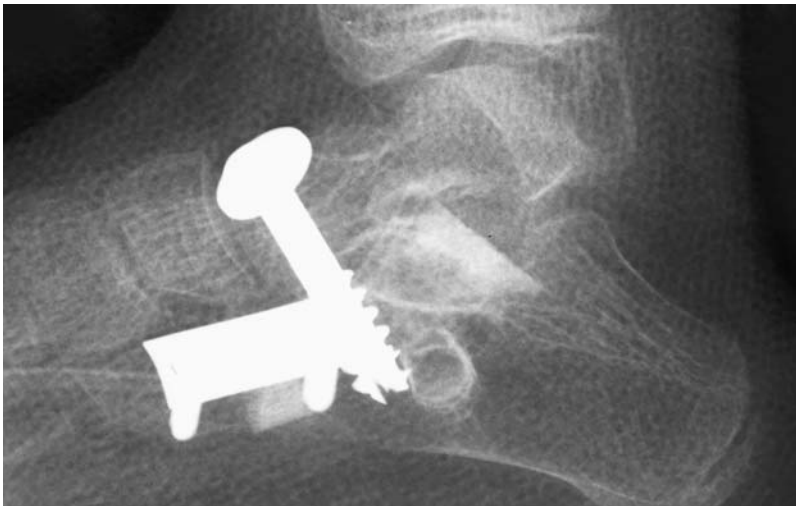


Figure S5.4.3

Postoperative Care

The child is placed in a short-leg walking cast with careful contour of both the lateral and medial longitudinal arches. Toes are placed in an elevated toe plate and the child is allowed weight bearing as tolerated. Union of the arthrodesis site usually requires 8 to 10 weeks of immobilization.

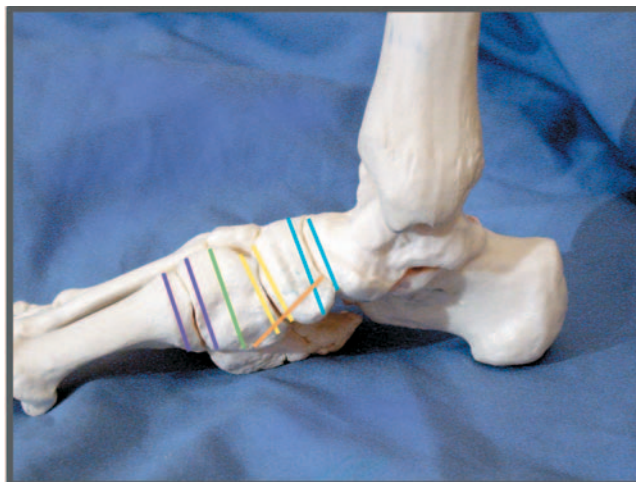
5. Medial Column Correction: Forefoot Supination and First Ray Elevation

Indication

The indications for addressing forefoot supination or elevation of the first ray are based on the severity of the deformity. The child with a severely deformed planovalgus foot will need to have the medial column stabilized. Those individuals who have the hindfoot and lateral column stabilized but continue with instability or residual deformity of the medial column are indicated for reconstruction. If pressure on the plantar surface of the metatarsal heads under anesthesia causes predominant elevation of the first ray, this collapse will also occur when the child weight bears. If under anesthesia the foot sits at rest with forefoot supination and first ray elevation, it will only get worse when the child is awake with active muscles. In these situations correction of the medial column is recommended. Depending on the severity of the foot and the location of the deformity, correction may require a combination of joint fusion or osteotomies for correction (Figure S5.5.1).

Procedure

1. The medial column is approached by an incision from the anterior aspect of the talonavicular joint across the midmedial surface of the cuneiform and first metatarsal to the distal level of the midfirst metatarsal (Figure S5.5.2).
2. The soft tissue is dissected sharply down to the talonavicular, cuneiform, and first metatarsal. The talonavicular joint is opened.
3. The tibialis posterior is reflected from its insertion into the navicular, being careful to avoid incising through cartilage but staying within the mass of the tendon. Usually, a large tuberosity of the navicular is noted. The soft-tissue dissection is carried down, not in-



- Navicular tuberosity excision
- Medial cuneiform osteotomy
- Talo-navicular joint excision
- Naviculo-cuneiform joint excision
- Cuneiform-metatarsal joint excision

Figure S5.5.1

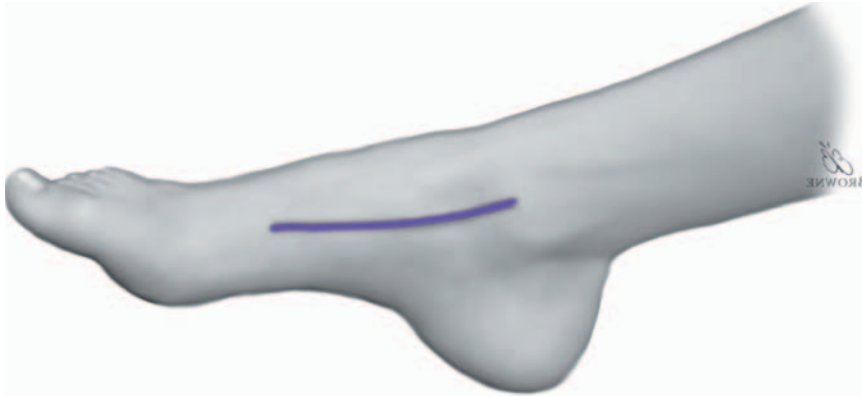


Figure S5.5.2

volving the periosteum, to the cuneiform first metatarsal joint (Figure S5.5.3).

4. An oscillating saw is utilized and the navicular tuberosity is transected parallel to the medial border of the head of the talus, exiting in the middle of the cuneiform. This transection will resect the medial border of the navicular cuneiform joint. The bone is removed, leaving no fragments behind (Figure S5.5.4).
5. In the anterior aspect of the wound, the tibialis anterior is exposed and its insertion on the first metatarsal is identified and transected close to the bone (Figure S5.5.3).
6. Careful inspection of the source of the instability is performed. If the navicular cuneiform joint is relatively stable, but there seems to be a permanent deformity of the medial column with elevation of the first ray, an osteotomy is planned for the middle of the medial cuneiform (Figure S5.5.5).

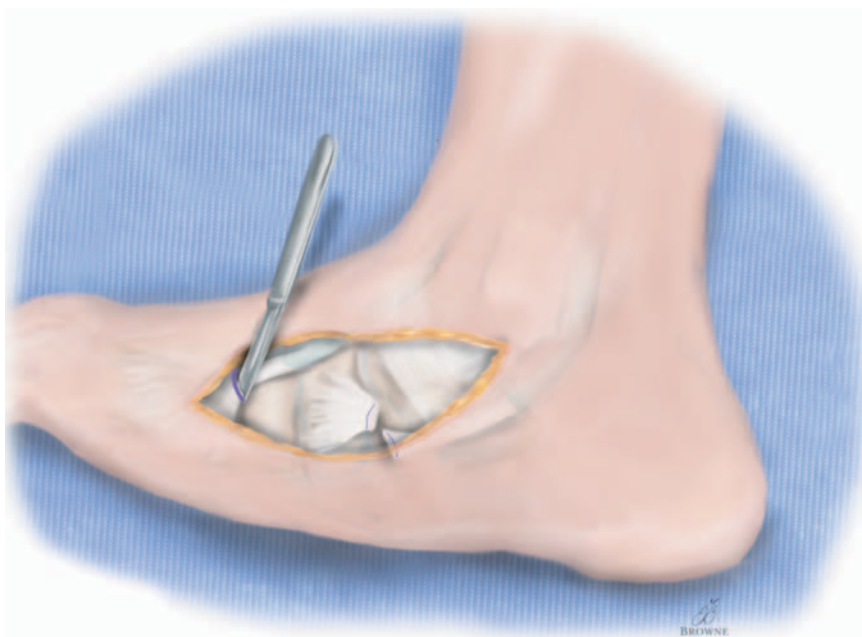

Figure S5.5.3

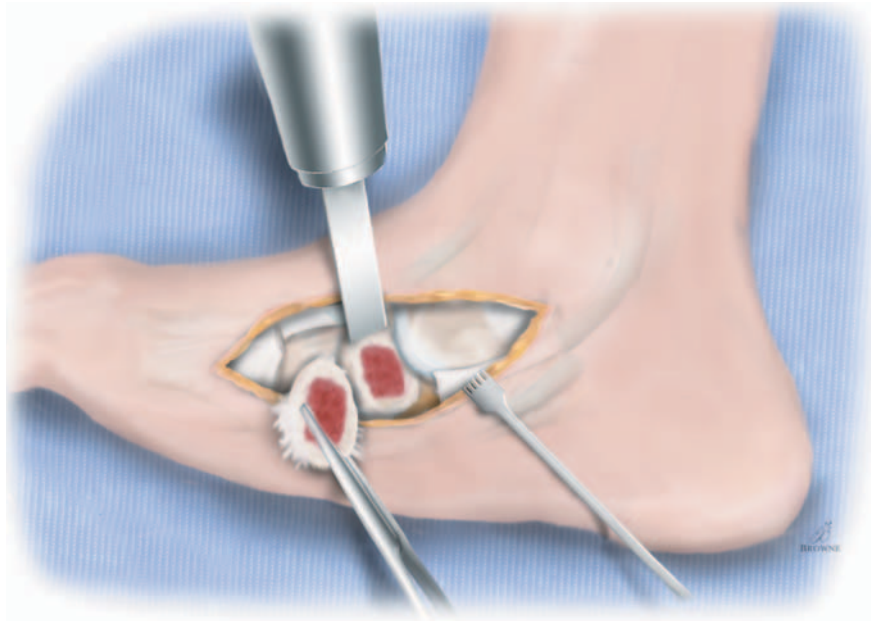


Figure S5.5.4

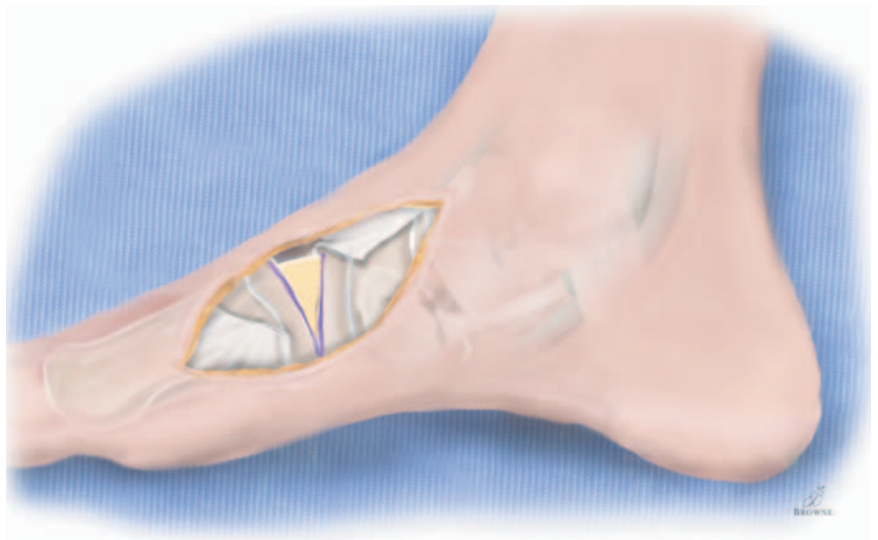


Figure S5.5.5

7. If gross instability of the medial cuneiform is noted with movement of the first ray, the medial cuneiform navicular joint will be excised and fused (Figure S5.5.6).
8. If gross instability is noted in the talonavicular joint, the cartilage will be removed in anticipation of fusing the talonavicular joint (Figure S5.5.7).
9. If instability is noted at the first ray cuneiform joint, the cartilage is removed in anticipation of fusion.
10. If a medial cuneiform osteotomy is performed, an osteotomy is made utilizing an oscillating saw in the middle of the cuneiform. The dorsal aspect of the cuneiform is spread open and the foot is examined

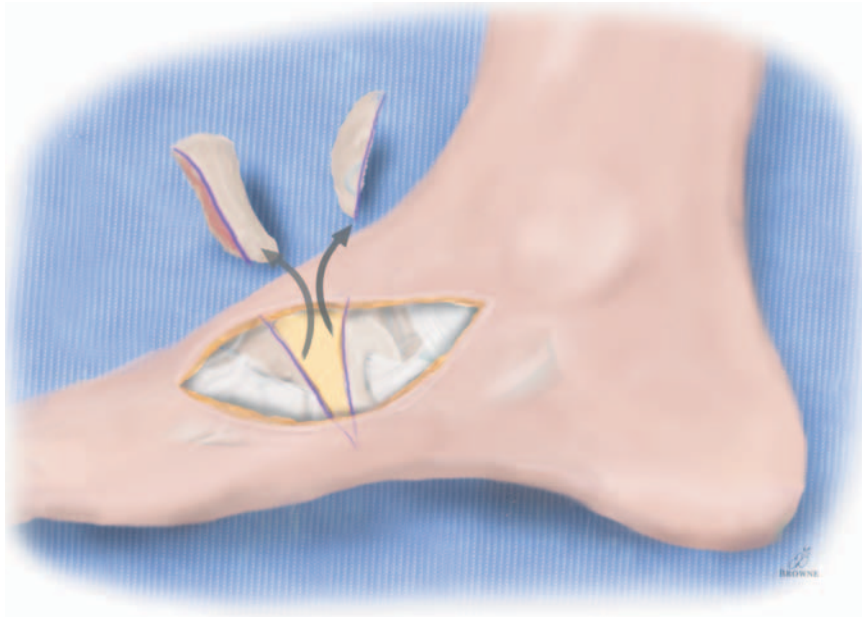


Figure S5.5.6

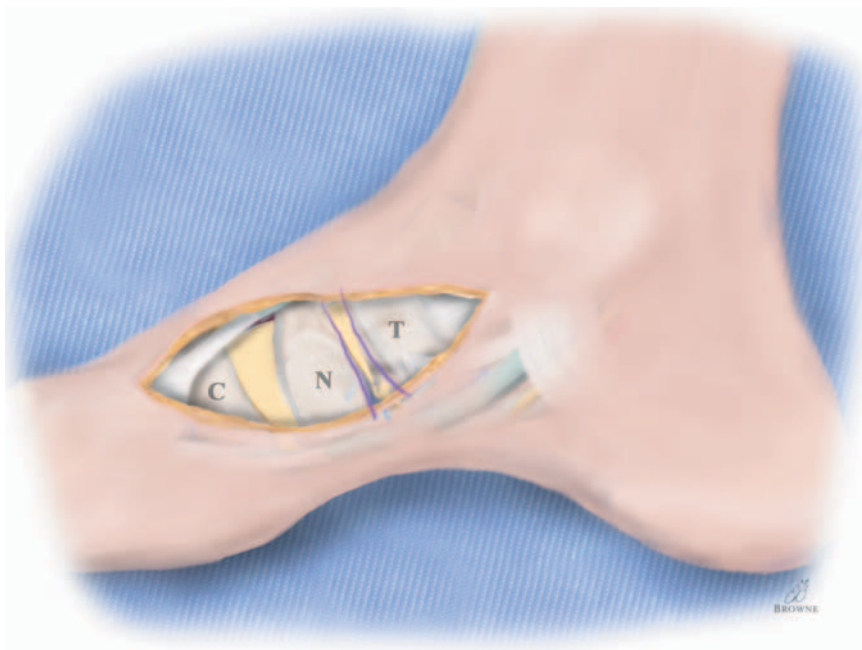


Figure S5.5.7

again to make sure there is depression of the first ray. This osteotomy is held in its open position with either bone graft from the resected navicular tuberosity or from bank bone. The osteotomy is stabilized with a K-wire (Figure S5.5.8).

11. If navicular cuneiform joint instability is noted, which is the most common problem, the joint is resected utilizing an oscillating saw, avoiding resection of any excessive bone (Figure S5.5.6). The joint then is distracted until the first ray elevation is corrected. The amount

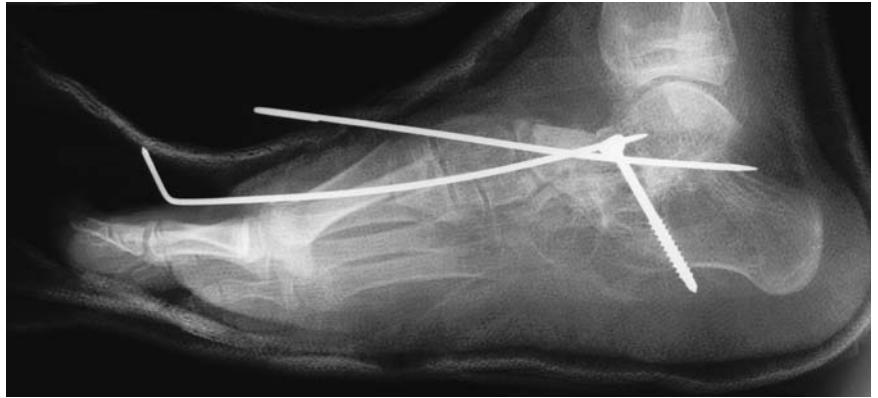


Figure S5.5.8

of distraction required is measured, and a bone graft is obtained either from the excised navicular tuberosity or from bank bone. This bone is inserted into the excised joint and is stabilized with a longitudinal K-wire introduced through the first metatarsal and driven across the osteotomy site into the head of the talus (Figure S5.5.8). Another option in a full adult size foot is to excise the navicular cuneiform joint with a slight plantar medial-based wedge. Then do a closing reduction and stabilize the fusion with a plantar medial-based two-hole semitubular plate (Figures S5.5.9, 5.5.10).

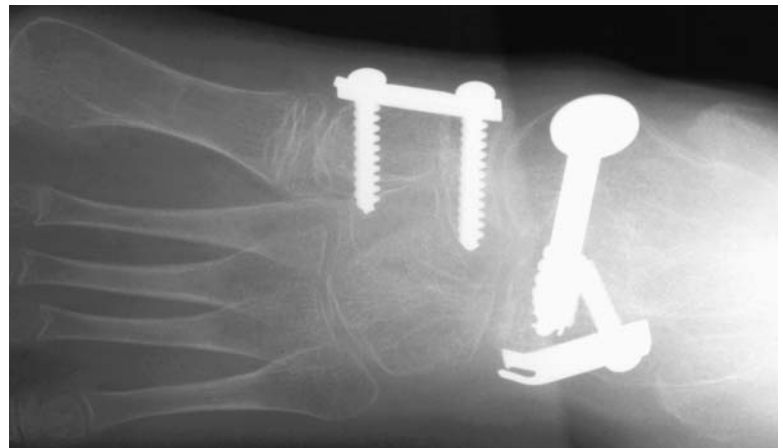


Figure S5.5.9

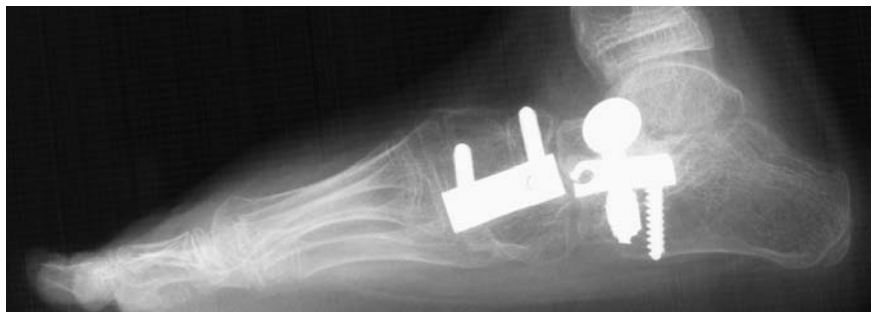

Figure S5.5.10

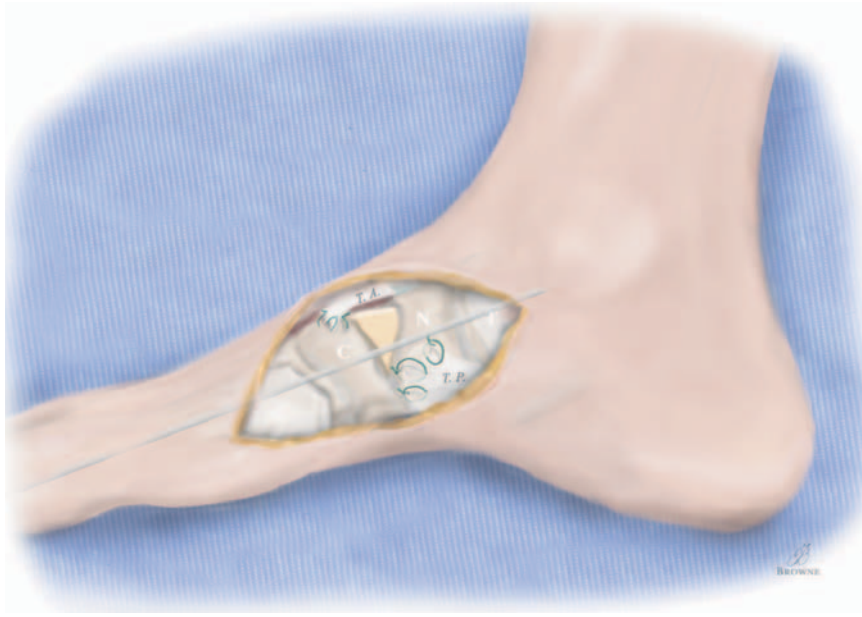


Figure S5.5.11

12. If the talonavicular joint is noted to be unstable or have severe degenerative changes, it is denuded of its cartilage. Talonavicular fusion in children with spastic planovalgus feet is performed only in combination with navicular first cuneiform fusions. Therefore, the length lost by removal of the joint is made up by the bone graft, which is inserted into the navicular medial cuneiform joint.
13. If substantial instability is present in the medial cuneiform first metatarsal joint, the cartilage is removed and bone graft is inserted as needed to correct the first ray elevation.
14. For joint fusions of the navicular cuneiform joint, or osteotomy of the cuneiform, stabilization is provided by a heavy K-wire introduced through the first metatarsal and driven across the fusion site (Figure S5.5.11).
15. If the entire medial column requires fusing, the immobilization should be performed with a plantar-based plate, with fixation from the neck of the talus into the first metatarsal. Care should be taken to get the correct alignment, as this fusion will not allow any change postoperatively (Figures S5.5.12 and S5.5.13). This approach provides excellent correction for severe deformities, but is rarely required for high level ambulators.
16. The bones on the dorsum of the foot are exposed laterally to the lateral cuneiform. A heavy absorbable suture is used and passed into the bone of the lateral cuneiform to which the tibialis anterior is secured (Figure S5.5.11).
17. The tibialis posterior and plantar fascia flap, which has been created with the removal of the tibialis posterior, now is advanced distal and anterior as far as it will reach, with sutures into the navicular and cuneiform (Figure S5.5.11).

Postoperative Care

The child is immobilized in a short-leg walking cast with good molding of the medial and lateral longitudinal arches. The short-leg cast should have a

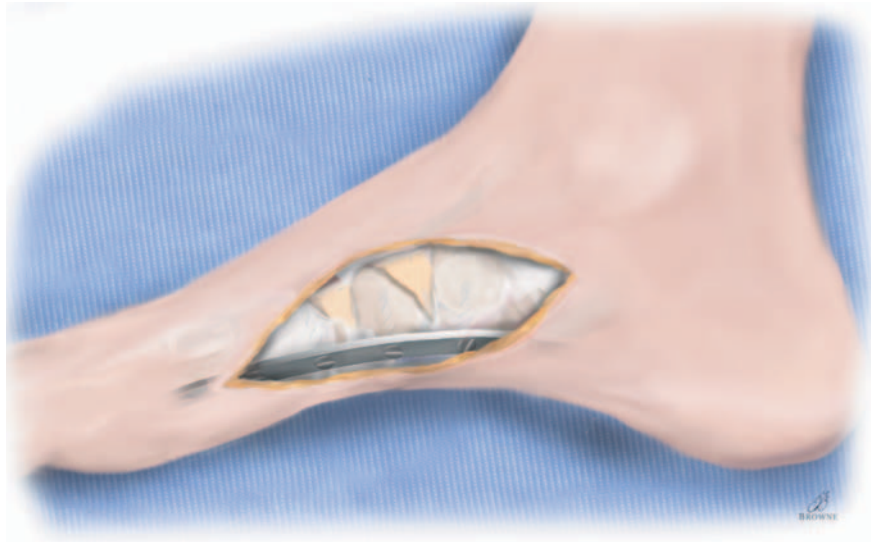


Figure S5.5.12

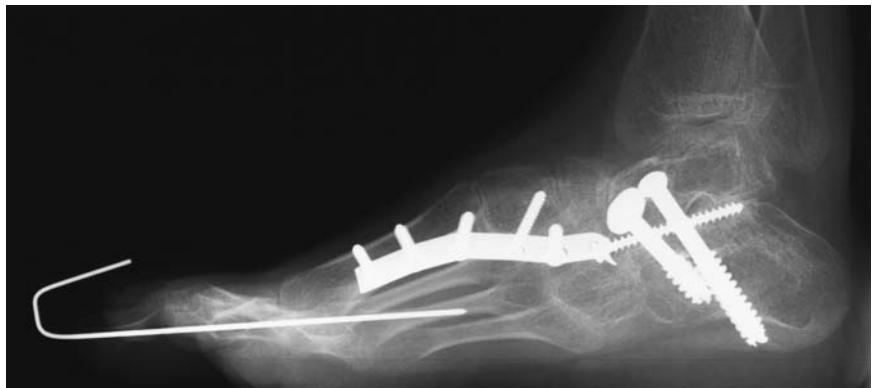

Figure S5.5.13

toe plate with the toes elevated, but care should be taken not to put pressure on elevation of the first ray. Immobilization is usually necessary for 8 weeks until fusion occurs. The pins are usually left in place for the entire 8 weeks, although if they start irritating the child, they may be removed several weeks before removal of the cast. After removal of the cast, in-shoe orthotics, such as supramalleolar orthotics, may be prescribed if the child is having problems with maintaining stable stance. Usually, regular shoe wear can be prescribed.

6. Triple Arthrodesis

Indication

Triple arthrodesis is indicated for severe foot deformities, especially for those feet in marginal or nonambulatory individuals (Figure S5.6.1). This is a combination of subtalar fusion, calcaneocuboid lengthening fusion, and medial column repair (Figure S5.6.2).

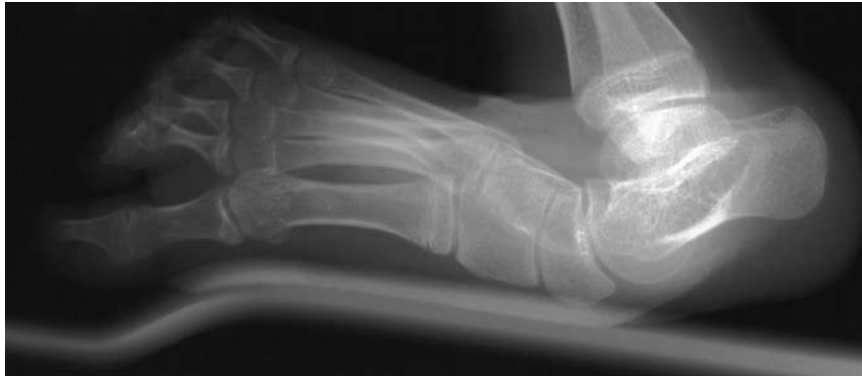

Figure S5.6.1

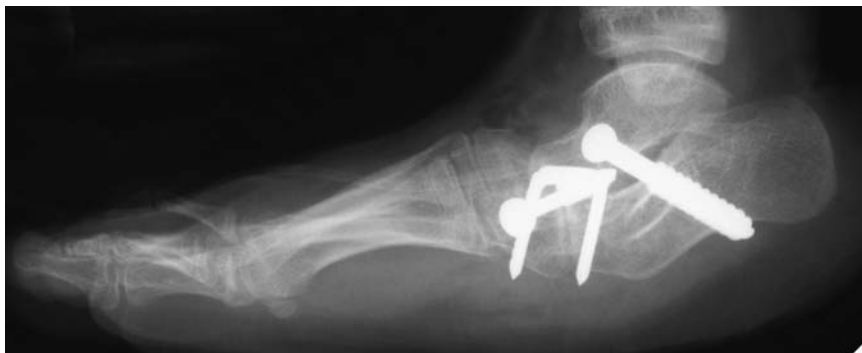

Figure S5.6.2

Procedure

1. The subtalar joint is exposed and fused as described in the section on subtalar arthrodesis.
2. The calcaneocuboid joint is exposed and fused as defined in the lateral column lengthening through the calcaneocuboid joint.
3. The medial column is exposed and fused as described in the section on correction on forefoot supination and first ray elevation.
4. Gastrocnemius lengthening or tendon Achilles lengthening is performed as indicated by a physical examination demonstrating insufficient dorsiflexion.

Postoperative Care

The foot is immobilized in a short-leg walking cast and weight bearing is permitted as tolerated, dictated by the degree of the individual's pain. Typical cast immobilization is required for 8 to 12 weeks, and postoperative orthotics are prescribed only if necessary to stabilize the ankle joint.

7. Gastrocnemius Lengthening

Indication

Indications for gastrocnemius lengthening are individuals who have dorsiflexion, limitations of less than neutral with the knee fully extended, but

passive dorsiflexion with the knee flexed to at least neutral. Large discrepancies in contractures will demonstrate a difference of 20° to 30° between the gastrocnemius and soleus, as defined by the difference between dorsiflexion with knee flexed and knee extended. Moderate differences are 10° to 20°, and mild differences are less than 10°. Gastrocnemius lengthening has a lower risk of overcorrection. Examination under anesthesia should be used to help determine the degree of fixed contracture (Figure S5.7.1).

Procedure

1. The incision is made in the calf at the posterior medial border of the calf. By visual inspection, the outline of the distal end of the gastrocnemius is identified. If there is a severe discrepancy in contracture, the incision is made directly at the end of the gastrocnemius crease. A longitudinal incision of approximately 2 to 3 cm in length is made (Figure S5.7.2, 3).
2. If there is a mild difference in contracture with the goal of performing some soleus lengthening, the incision is made several centimeters more distal (Figure S5.7.2, 2), and if there is a mild gastrocnemius contracture with moderate difference, the incision is made approximately 2 cm more proximally (Figure S5.7.4, 4).
3. For fixed contracture of both muscles, the incision is over the medial aspect of the tendon Achilles (Figure S5.7.2, 1).
4. The incision is carried through the subcutaneous tissue and the fascia overlying the gastrocnemius is identified (Figure S5.7.3).

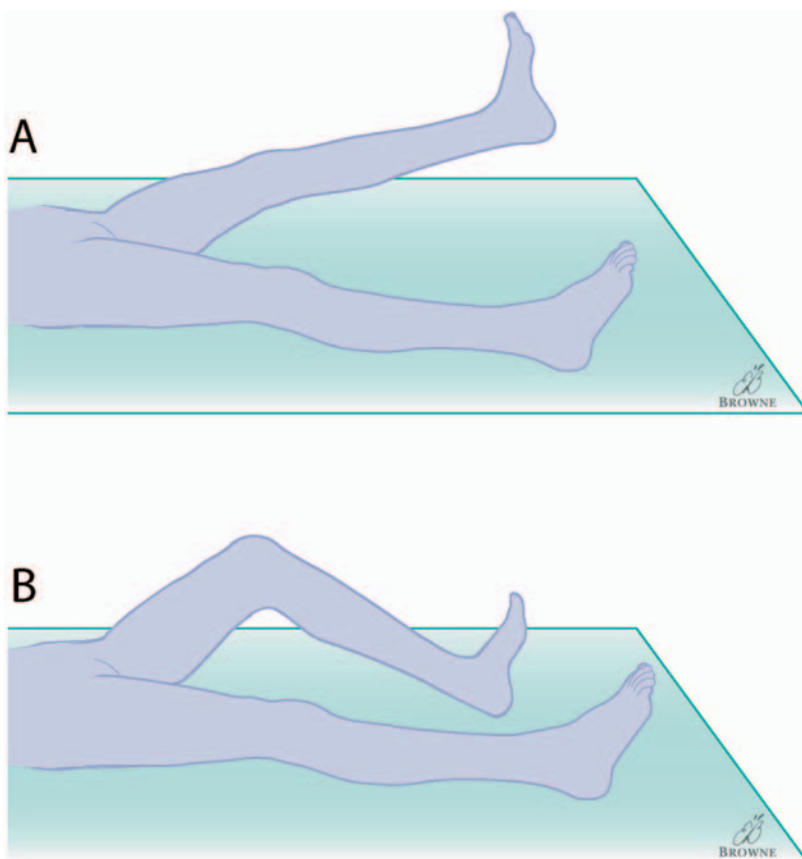


Figure S5.7.1

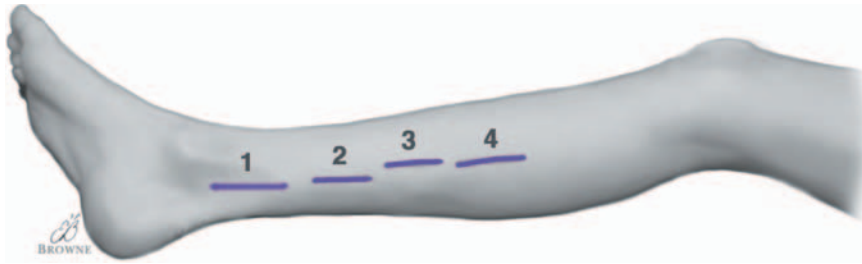


Figure S5.7.2

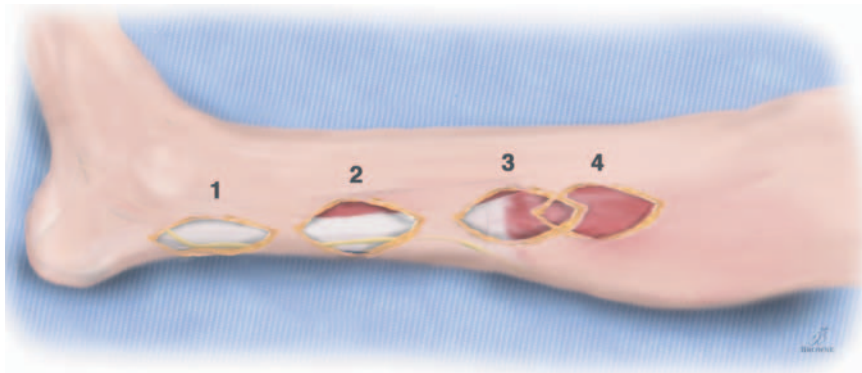


Figure S5.7.3

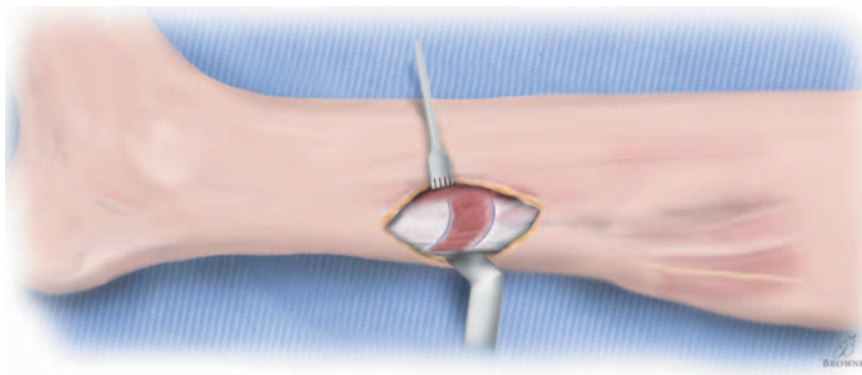


Figure S5.7.4

5. The interval between the gastrocnemius and soleus is identified and explored to its lateral border. If the incision is distal to the conjoined tendon of the gastrocnemius, the dissection is carried across the superior border of the gastrocnemius (Figure S5.7.4). Care is taken to avoid the sural nerve and keep it with the subcutaneous tissue.
6. For severe differences in contracture, the tendon of the gastrocnemius is resected from the soleus completely (Figure S5.7.5). For moderate differences in contracture, especially with a milder contracture of less than 10° or 15°, the interval between the gastrocnemius and the soleus is identified and only the fascia on the deep surface of the gastrocnemius is incised (Figure S5.7.6). For mild contractures of the soleus with a mild difference in contracture, the fascia overlying the conjoined tendon of the gastrocnemius is incised transversely (Figure S5.7.7).

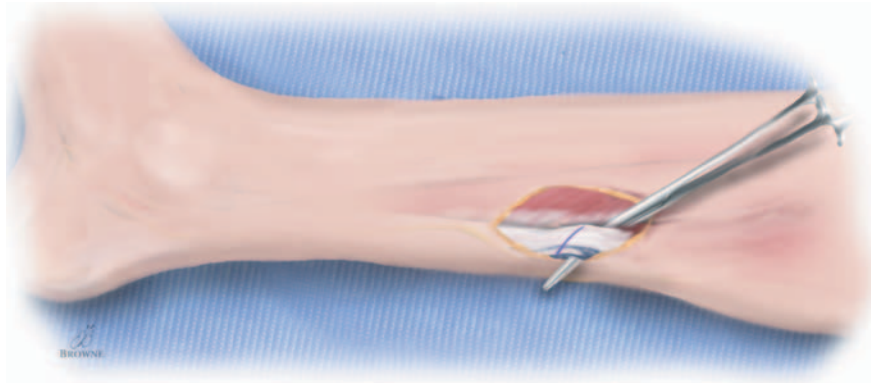


Figure S5.7.5

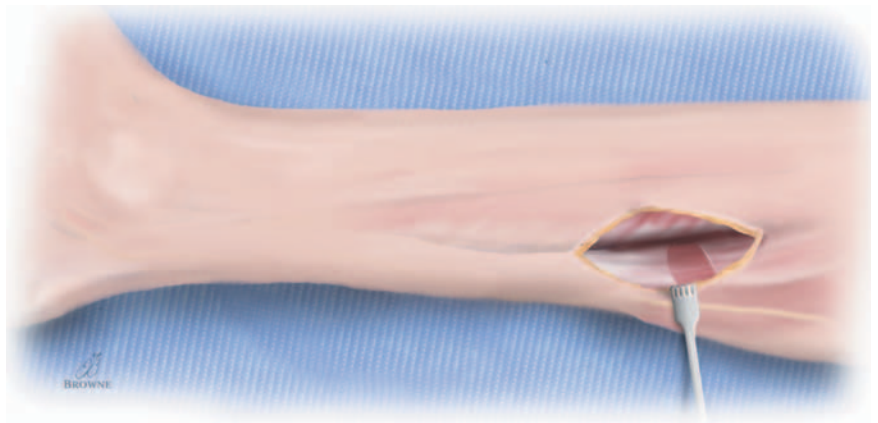

Figure S5.7.6

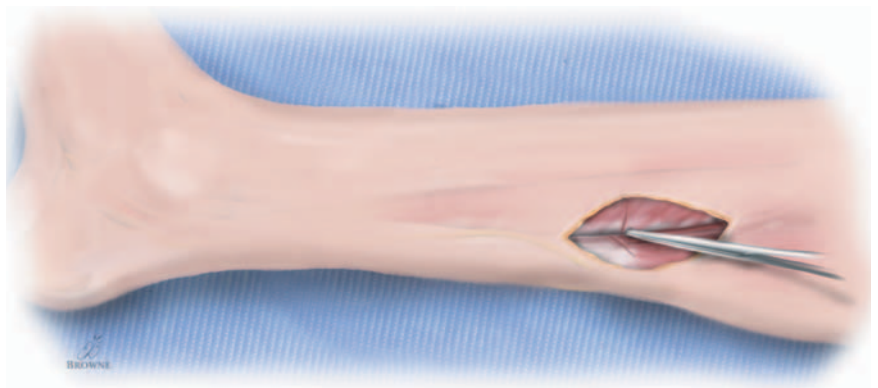


Figure S5.7.7

7. Subcutaneous tissue with its subcutaneous fascia is closed in one layer, and then subcuticular skin closure is applied.

Postoperative Care

The foot is immobilized in a short-leg cast with the ankle dorsiflexed approximately 10° . If the child has a tendency to lie with the knee flexed, a

knee immobilizer is used to maintain the extension. Ambulation is encouraged. The cast is removed at 4 weeks, and the child is encouraged to ambulate without orthotics for 1 month. If plantar flexion or hyperdorsiflexion tend to occur at this point, appropriate orthotics are prescribed.

8. Tendon Achilles Lengthening

Indication

Tendon Achilles lengthening is indicated for those individuals with severe contractures involving the soleus, in which there is at least -10° of dorsiflexion with knee flexion present. This is most commonly indicated in hemiplegia or severe quadriplegia.

Procedure

1. The incision is made in the medial aspect just anterior to the bulk of the tendon Achilles (Figure S5.8.1). **DO NOT MAKE THE INCISION DIRECTLY POSTERIOR.** These direct posterior incisions often cause rubbing on the backs of shoes. The incision is carried down to the subcutaneous tissue by sharp dissection into the peritenon of the tendon Achilles. Then, the soft tissue is retracted posteriorly.
2. A knife is utilized and a longitudinal cut is made through the mid-substance of the tendon Achilles over 3 to 4 cm, with the distal end detached medially if the child has varus tendency and laterally if the child has valgus tendency (Figure S5.8.2). The contralateral side is detached proximally.
3. The tendon is allowed to slide into lengthening and is repaired with a running, absorbable suture (Figure S5.8.3). The tendon should be repaired with the foot in -10° of dorsiflexion so that there is some tension on the muscle with the foot at neutral position.
4. Subcutaneous tissue is closed, and skin is closed with a subcuticular closure.

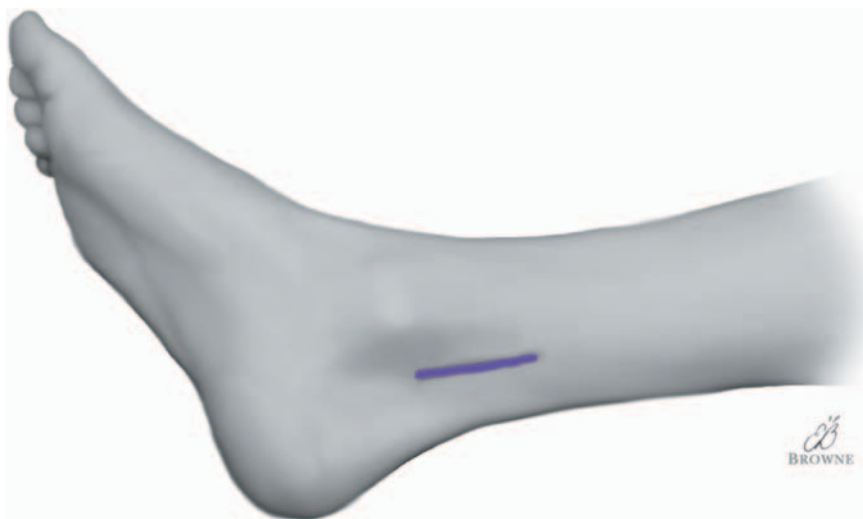

Figure S5.8.1

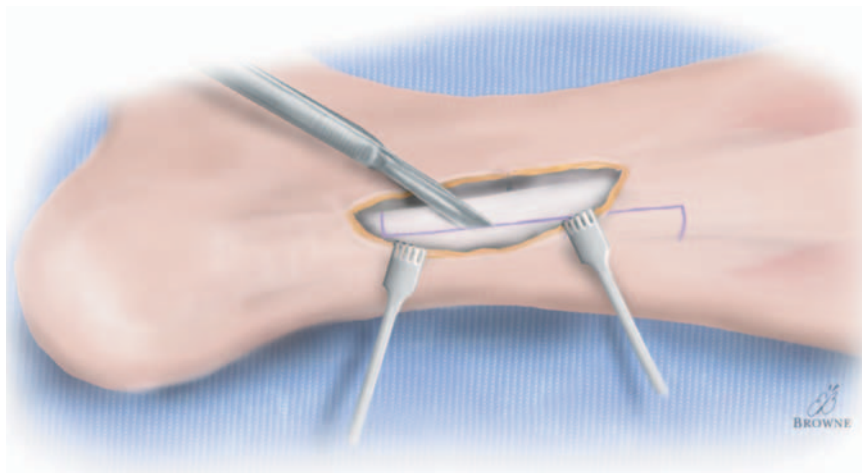


Figure S5.8.2

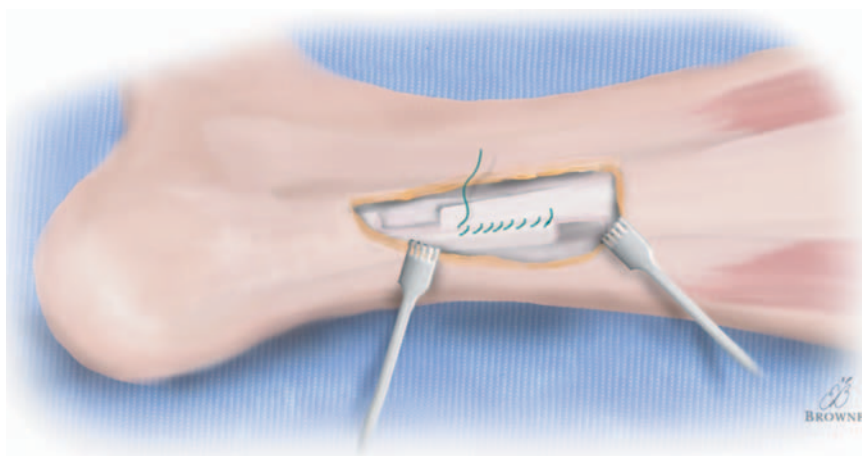


Figure S5.8.3

Postoperative Care

The child is immobilized in a short-leg walking cast for a minimum of 4 weeks. The foot should be positioned in neutral dorsiflexion. No additional dorsiflexion is recommended after Z-lengthening. When the cast is removed, the child is allowed to be full weight bearing. Evaluation 4 to 6 weeks after cast removal should be used to determine whether further orthotics are indicated.

9. Tibialis Posterior Lengthening or Split Transfer

Indication

Split tibialis posterior transfer is indicated for an ambulatory, hemiplegic in middle childhood or older child in whom the tibialis posterior is the cause of varus foot positioning in stance phase. Lengthening of the tibialis posterior is indicated for individuals with fixed contractures of the tibialis posterior and foot varus, especially in children with diplegia or quadriplegia.

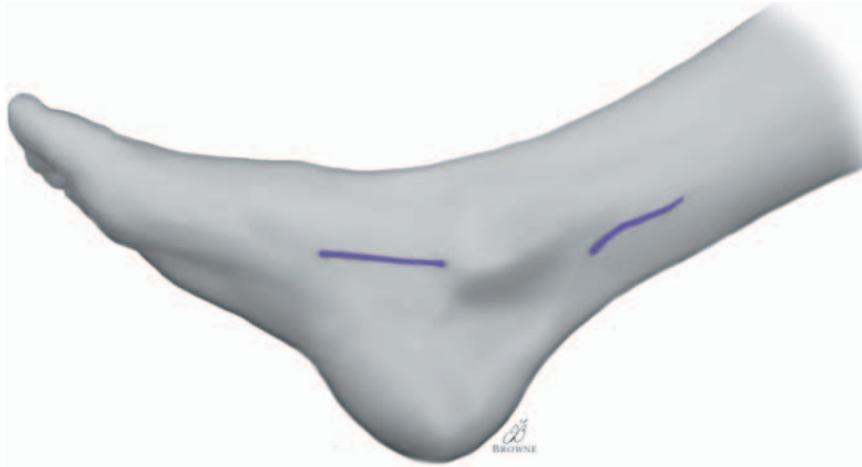


Figure S5.9.1

Procedure

1. An incision is made at the posterior border of the tibia on the medial side starting 2 to 4 cm proximal to the medial malleolus and extending for a total length of 4 cm (Figure S5.9.1).
2. The incision is extended through the subcutaneous tissue and the deep fascia is opened. The tibialis posterior is identified and cleaned of its peritenon. If muscle lengthening is to be performed, a slightly more proximal incision should be used. The muscle then is exposed, and if a large amount of muscle belly is present, an intramuscular lengthening is performed, usually with two incisions, one proximal and one approximately 2 cm further distal. The tendon of the tibialis posterior tends to be internal in the muscle, so care has to be taken that all parts of the tendon are incised at the level intended.
3. If only tendon is identified and a lengthening is to be performed, a Z-cut should be made in the tendon of the tibialis posterior (Figure S5.9.2), allowed to distract, and the Z-cut sutured with absorbable running suture (Figure S5.9.3).
4. If split tendon transfer is indicated, a second incision is made distally 1 cm distal to the tip of the medial malleolus and carried distally across the anterior medial border of the talonavicular joint and the talus (Figure S5.9.1).
5. Subcutaneous tissue is opened and the insertion of the tibialis posterior is cleaned with careful cleaning into the tunnel, posterior to the medial malleolus but avoiding cutting the retinaculum of the tendon sheath.
6. The insertion site of the tibialis posterior is identified and an incision is made, starting as far proximal as possible, and then carried distal across the insertion site at the midpoint of the tendon (Figure S5.9.4, line 2).
7. As the anterior part of the tibialis posterior is flaring, another incision is made in the tendon starting at the anterior border of the tendon, maintaining the same width across the insertion of the whole width of the navicular (Figure S5.9.4, line 1). This anterior half of the tibialis posterior is held elevated, and its undersurface is cut to have a straight tendon across the insertion site removed. Some cartilage of the navicular tuberosity may be included in this distal end.

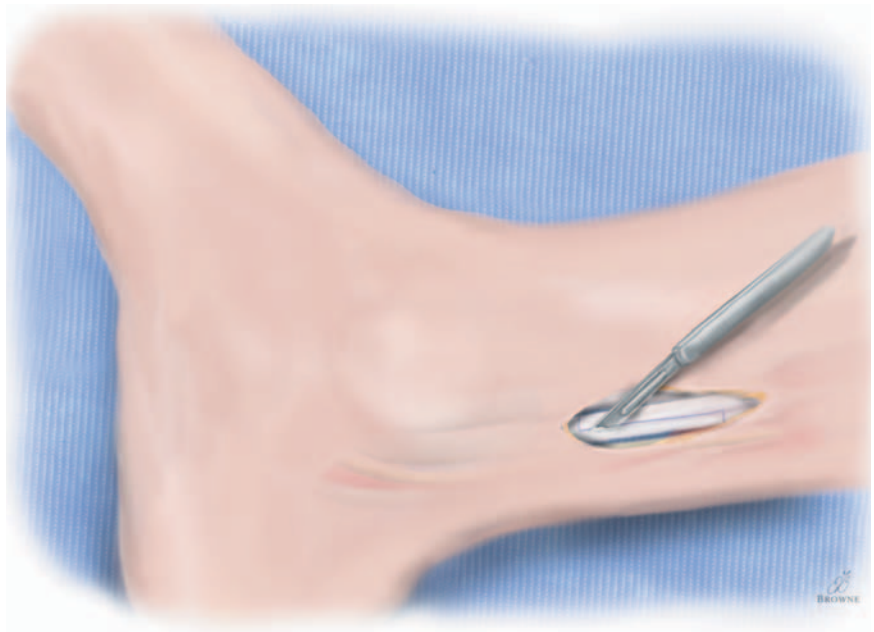

Figure S5.9.2

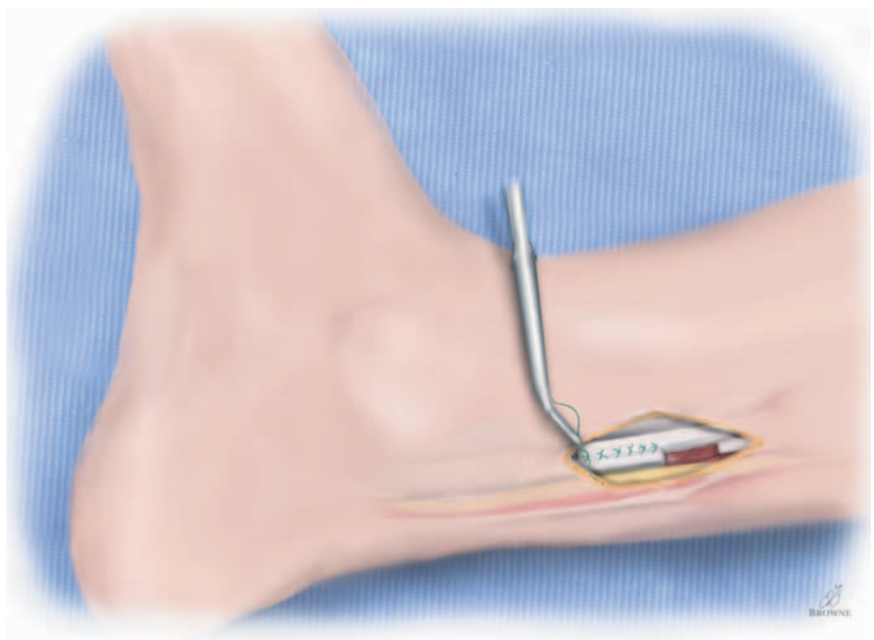


Figure S5.9.3

- The tendon should end with a sharp end and not with a large bulbous piece of tendon (Figure S5.9.4, line 1).
8. An absorbable suture now is introduced, utilizing a half-hitch Kessler suture into the distal tendon.
 9. A small tendon passer is introduced into the proximal incision and brought inside the sheath of the tibialis posterior through its posterior tibial tunnel into the distal wound. Minimal resistance should be encountered in passing this tendon passer. The sheath of the tibialis posterior can be slightly dilated first with a large hemostat.

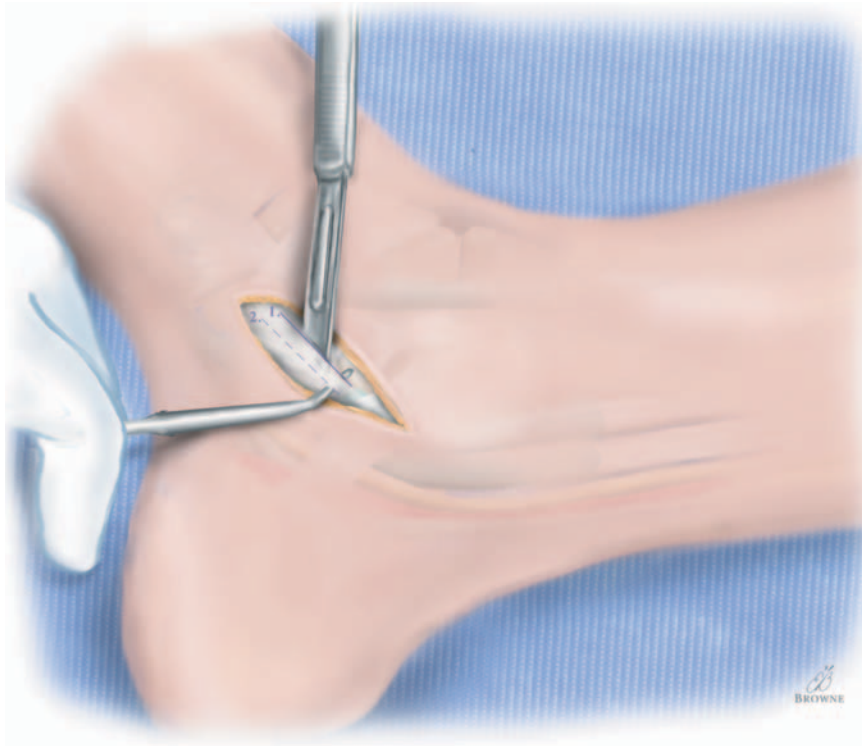


Figure S5.9.4

10. The suture attached to the end of the tendon is drawn into the proximal wound, so the end of the tendon can be pulled back utilizing the suture. Then, attention is directed at the distal end where very careful attention is made to ensure that the tendon end starts to feed into the tendon tunnel without having an accordion effect (Figure S5.9.5, 1). The tendon is drawn into the proximal wound, and utilizing force, it should be splitting in the midline proximally (Figure S5.9.5, 2). If the tendon is not splitting completely in the midline, it should be guided using a sharp knife to split it into the midline as far proximally, using digital dissection, as possible into the calf.
11. The lateral incision is made from 1 cm distal to the tip of the lateral malleolus along the anterior border of the peroneus brevis tendon distally, almost to the insertion of the peroneus brevis (Figure S5.9.6). The peroneus brevis tendon is exposed and cleaned of its peritenon.
12. Attention is directed to the medial side where a retractor is placed along the posterior aspect of the tibia, retracting the neurovascular bundle and the flexor muscles. The retractor is extended posterior and lateral until the fibula is palpated.
13. A tendon passer is introduced in the distal lateral wound along the peroneus brevis tendon posterior to the lateral malleolus (Figure S5.9.7) and then directed posterior to the fibula and across the posterior aspect of the tibia so it presents in the proximal medial wound (Figure S5.9.8).
14. The suture that had been attached to the tibialis posterior tendon is pulled through this track using the introduced tendon passer. A hemostat, or another large clamp, is clamped onto the suture and the track can be dilated further from the medial to the lateral side. This

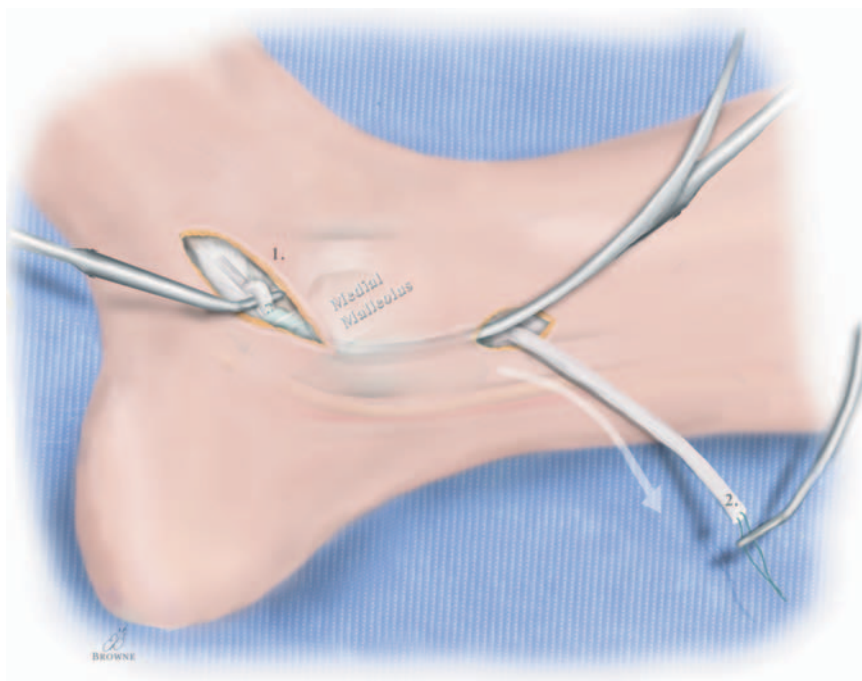


Figure S5.9.5

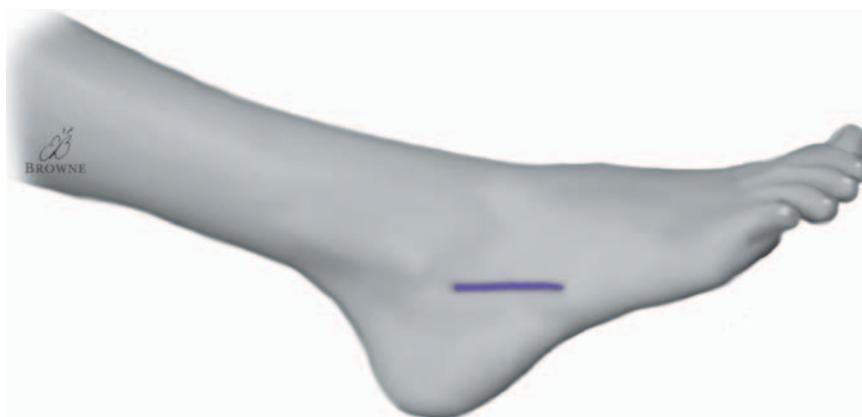


Figure S5.9.6

- dilation then allows the tendon to pass easily distal and laterally behind the fibula to be drawn out inferior in the distal lateral wound.
15. The medial wounds are now closed after examination to determine whether there is a need for tendon Achilles or gastrocnemius lengthening, which, if indicated, are performed.
 16. The cleft from the removal site of the tibialis posterior on the medial side should be closed with one or two sutures to avoid the residual tibialis posterior subluxating further inferior (Figure S5.9.8).
 17. Attention now is directed to the lateral side where the tibialis posterior tendon should be woven into the peroneus brevis using a Pulvertaft weave. The foot is held in an overcorrected position with dorsiflexion and hindfoot abduction and valgus. After an initial suture in the Pulvertaft weave, the position is checked and the foot should rest in neutral to very slight overcorrection. If it does not, the

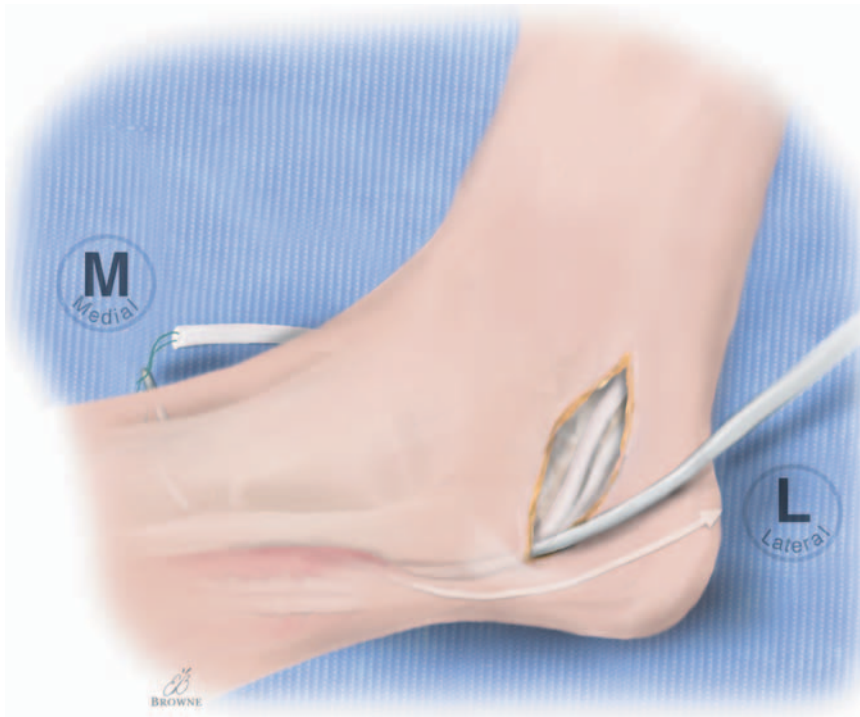


Figure S5.9.7

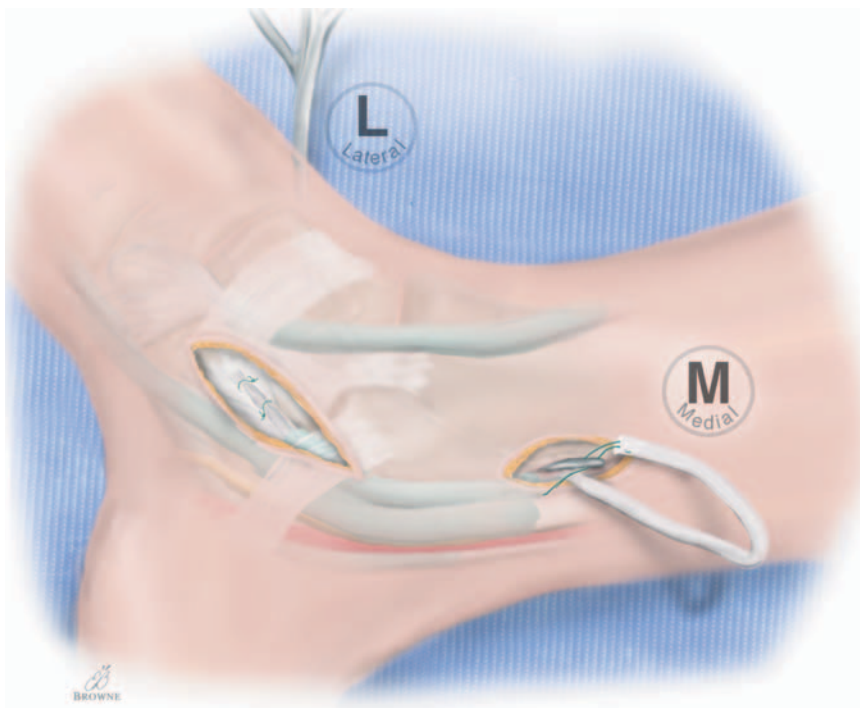


Figure S5.9.8

suture in the distal end of the tibialis posterior is utilized by anchoring it further distal into the insertion of the peroneus brevis to further increase the tension on the transferred half. Additional sutures are used to secure the transfer (Figure S5.9.9).

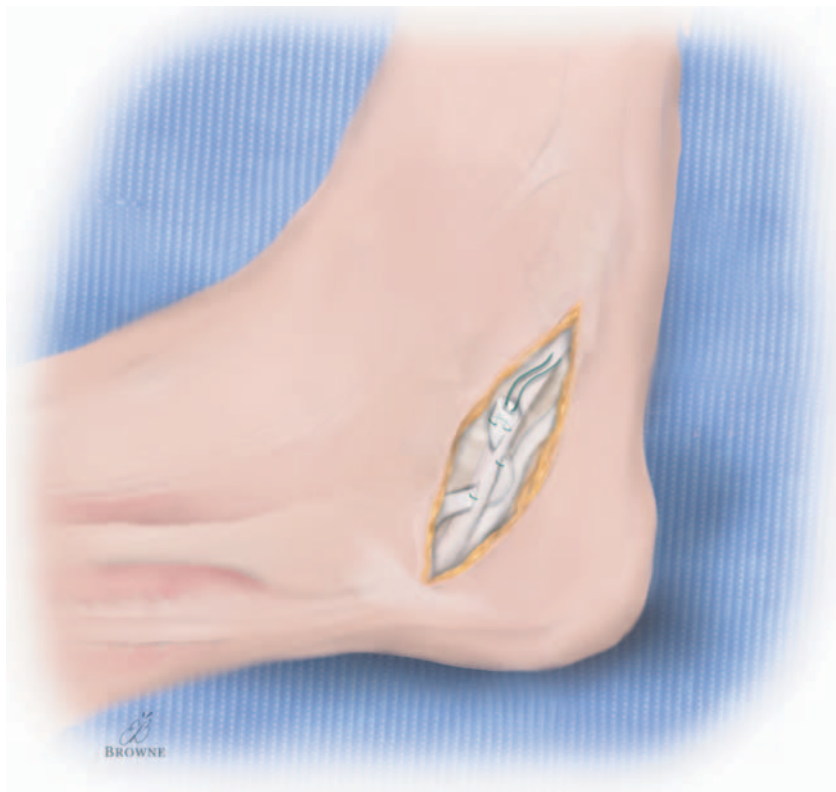

Figure S5.9.9

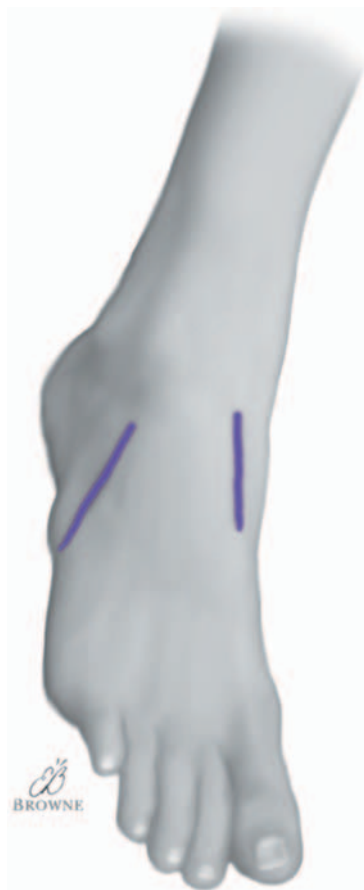


Figure S5.10.1

Postoperative Care

The child is immobilized in a postoperative cast with slight overcorrection into dorsiflexion and varus, but no more dorsiflexion than 5° or 10°, and the forefoot abduction and valgus also should be only of a minimal amount. Weight bearing is permitted as soon as tolerated. Cast immobilization is required for 4 weeks, and after cast removal, orthotics are determined by the position of the foot.

10. Split Tibialis Anterior Transfer

Indication

The indications for tibialis anterior transfer are based on the tibialis anterior contribution to forefoot varus. Most commonly this is swing phase varus of the foot or varus in early stance phase with a tibialis anterior muscle that is overactive in stance or constantly on. Tibialis anterior overpull also leads to forefoot supination and first ray elevation; however, the tibialis anterior transfer to treat first ray elevation is addressed in the section on correction of forefoot supination and first ray elevation.

Procedure

1. An incision is made along the line of the tibialis anterior distal to the ankle joint line toward its insertion on the first metatarsal (Figure S5.10.1).

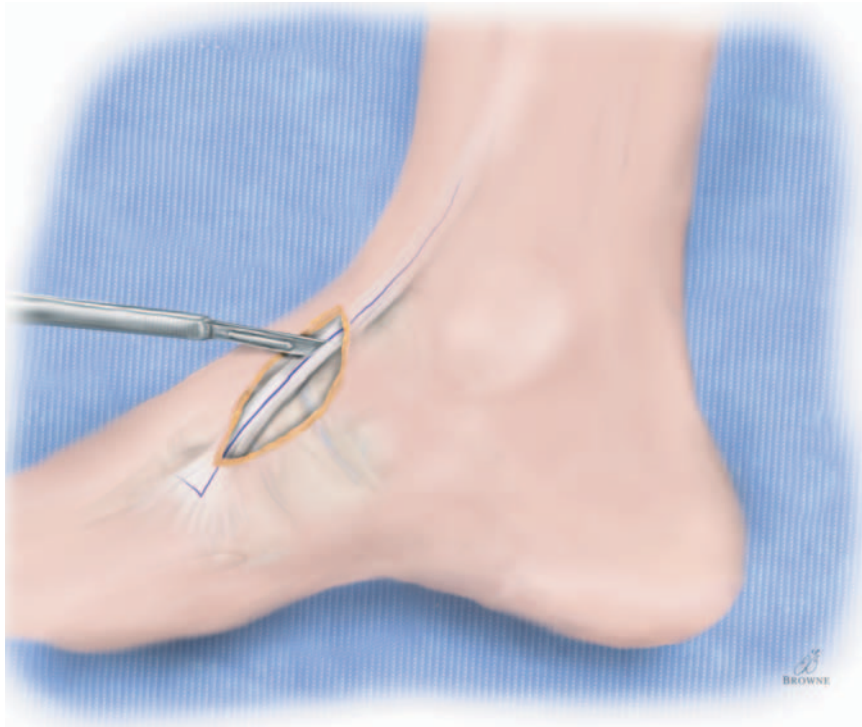


Figure S5.10.2

2. The tibialis anterior tendon usually is split transferred, therefore, a longitudinal incision is made in the tendon, carried distally, and the lateral half of the tendon is resected from its insertion into the first metatarsal. The transfer is split proximally, opening the anterior ankle retinaculum (Figure S5.10.2).
3. An incision is made from the fifth metatarsal base extending posterior and dorsal toward the sinus tarsi (Figure S5.10.1).
4. The peroneal tendon sheath is opened and the peroneus longus tendon is identified. The split transfer should be to the cuboid or the peroneus longus, which is the direct opposing muscle of the tibialis anterior, not to the peroneus brevis, which is the opposing muscle of the posterior tibialis.
5. The tibialis anterior transferred slip also may be sutured into the dorsum of the cuboid as well; however, this is often more difficult because the tendon frequently is thinned and barely long enough to reach well into the substance of the cuboid.
6. A longitudinal incision in the midline of the peroneus longus tendon is made from where it exits the tunnel under the fibula to where it goes under the foot at the first metatarsal cuneiform joint. One half of the tendon is transected as far proximally as possible.
7. The subcutaneous tissue is elevated along the anterior and dorsum of the foot toward the ankle joint, with the removed half of the tibialis anterior tendon identified and brought into the lateral wound. Kessler sutures are placed through the ends of both tendons (Figure S5.10.3).
8. The foot is held in a slightly overcorrected dorsiflexed position and the tibialis anterior and peroneal longus tendon slips are sutured together using a running absorbable suture. Tension is increased or decreased to maintain the foot in a slightly overcorrected position when it is released.

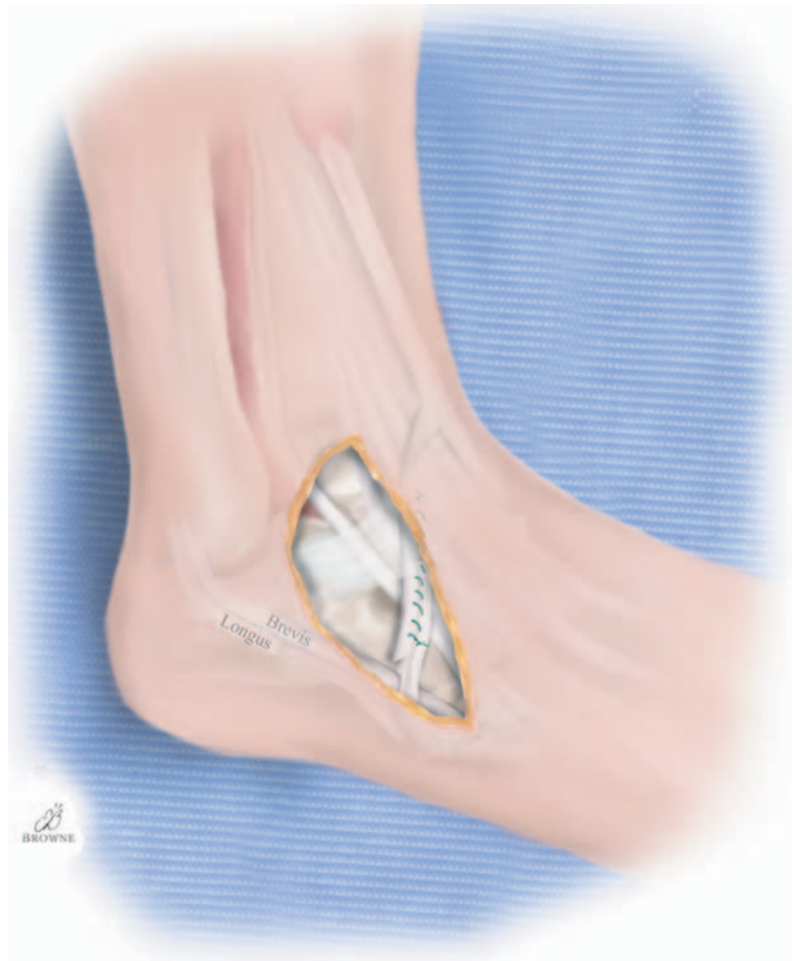

Figure S5.10.3

Postoperative Care

The child is placed in a slightly overcorrected position with less than 10° of dorsiflexion and mild overcorrected valgus position. Weight bearing is allowed as tolerated, cast immobilization is continued for 4 weeks, and orthotic use following that is based on the foot position.

11. Lengthening of the Tibialis Anterior

Indication

In some situations, the tibialis anterior develops severe contractures, which often are combined with gastrocnemius and soleus contractures. However, some children with extensor posturing positioning will develop contracture of the tibialis anterior as the predominant deformity causing hyperdorsiflexion. This may be a contributing factor in crouch gait or calcaneal pressure problems from pushing on the footrest of a wheelchair.

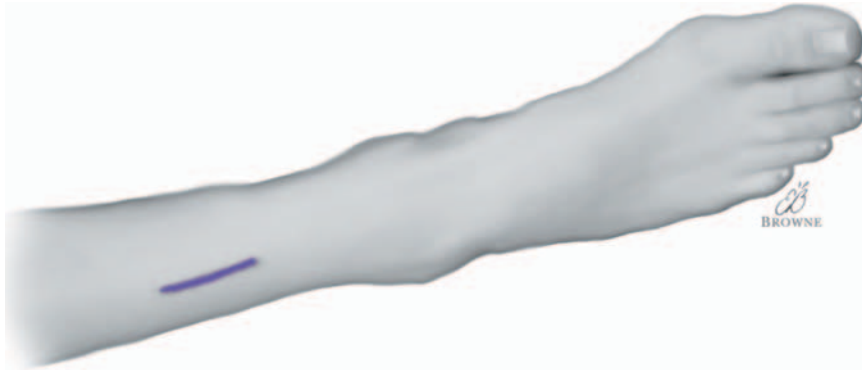

Figure S5.11.1

Procedure

1. Incision is made in the midanterior calf area just off to the lateral border of the anterior ridge of the tibia. An incision of 2 to 3 cm is carried down through the subcutaneous tissue and the fascia of the anterior tibialis is opened (Figure S5.11.1).
2. The tendon of the tibialis anterior tends to be within the muscle, and if there is a large muscle belly, the muscle fibers have to be split to find the tendon.
3. The tendon is identified and myofascial lengthening is performed at two levels by transecting all the fibrous tissue.
4. If only tendon is identified, a Z-lengthening is performed (Figure S5.11.2).

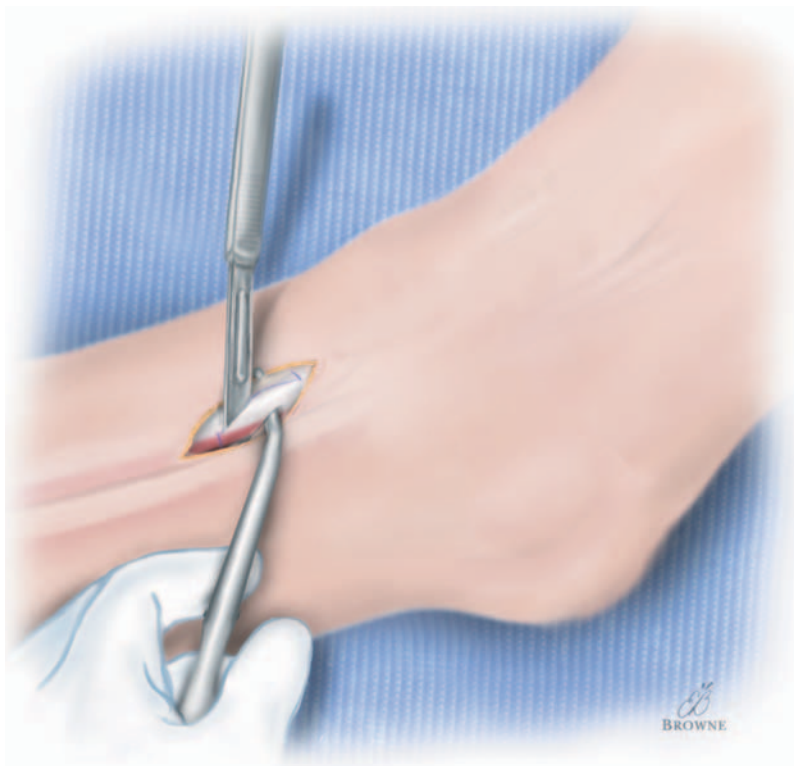


Figure S5.11.2

Postoperative Care

Most individuals can be treated with a splint, however, if severe dorsiflexion is present combined with other procedures, it may be necessary to use cast immobilization. Overcorrection seldom is a problem because of associated fixed contractures of the toe extensors and ankle capsule.

12. Bunion Correction

Indication

Indications for bunion correction include significant cosmetic concern or painful forefoot bunion deformities. If the child is a high-level ambulator with a supple bunion, correction by soft-tissue lengthening and bone alignment is recommended. If the child is a nonambulator or has a severe bunion with degenerative arthritis, first metatarsal phalangeal fusion is recommended.

Procedure

1. Incision on the medial side of the foot is carried from the middle of the metatarsal across the anterior medial surface of the first metatarsal phalangeal joint to the level just proximal to the interphalangeal joint of the great toe (Figure S5.12.1).
2. Subcutaneous tissue dissection carries down to the bone into the joint of the metatarsal phalangeal joint. A distal-based flap is left attached to the proximal phalanx and detached from the metatarsal, being careful to remove only a thin layer of fascia and joint capsule (Figure S5.12.2).
3. At the border of the joint, a knife is utilized and the medial border of the thickened cartilage and bursa overlying the distal metatarsal is resected sharply. A saw seldom needs to be used for adolescent bunions or spastic bunions in the same way it is used for adult bunions (Figure S5.12.3).
4. If the joint surface looks good and the child is a functional ambulator, attempts at a realignment procedure are preferred.
5. An incision is made on the medial side between the first and second toes, carried down through the subcutaneous tissue, and the tendons of the adductor hallucis and the flexor hallucis brevis are identified where they insert into the sesamoid and the capsule.
6. A knife is utilized and these tendons are resected sharply off their insertion. The medial capsule of the first metatarsal phalangeal joint is opened, and the sesamoid is visualized (Figure S5.12.4).




Figure S5.12.1

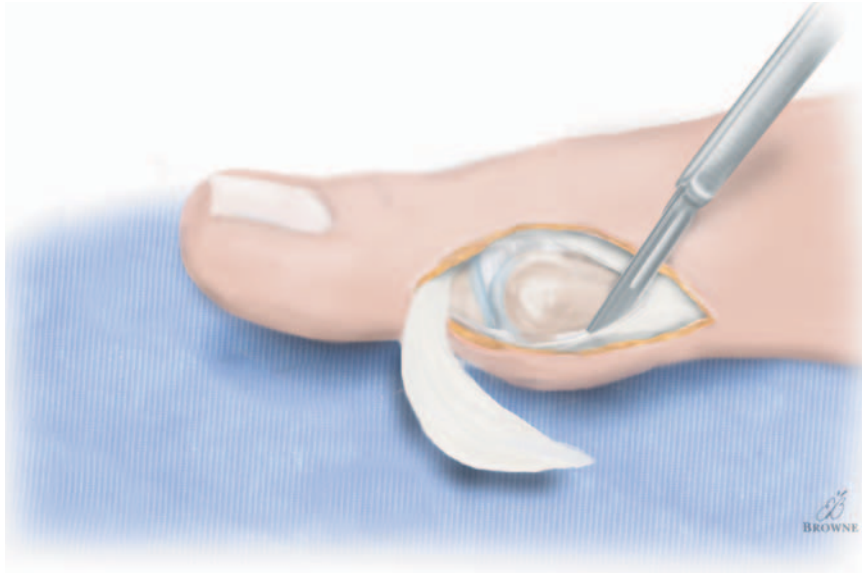


Figure S5.12.2

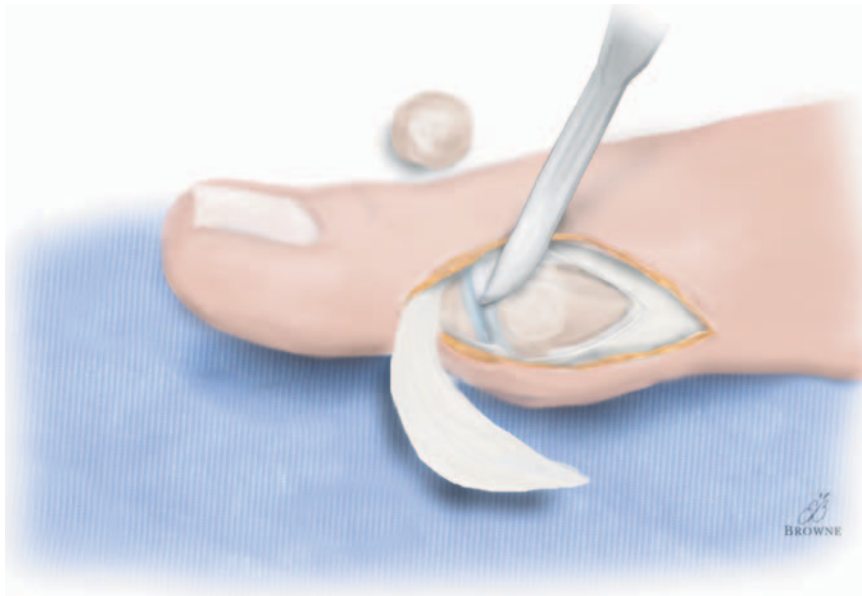


Figure S5.12.3

7. If the radiograph demonstrates a significant metatarsus primus varus, usually greater than 10° , an osteotomy of the metatarsal is required (Figure S5.12.5).
8. If the radiograph demonstrates significant valgus of the proximal phalanx, a proximal phalangeal osteotomy is required (Figure S5.12.6).
9. The first metatarsal osteotomy is performed by making a separate dorsal incision just lateral to the extensor hallucis longus tendon and carried down to the subcutaneous tissue. Subperiosteal dissection is undertaken of the medial half of the first metatarsal, avoiding the epiphysis if the epiphysis is opened.
10. Retractors are placed on the medial and lateral side of the first metatarsal, and a proximally directed dome osteotomy is performed at

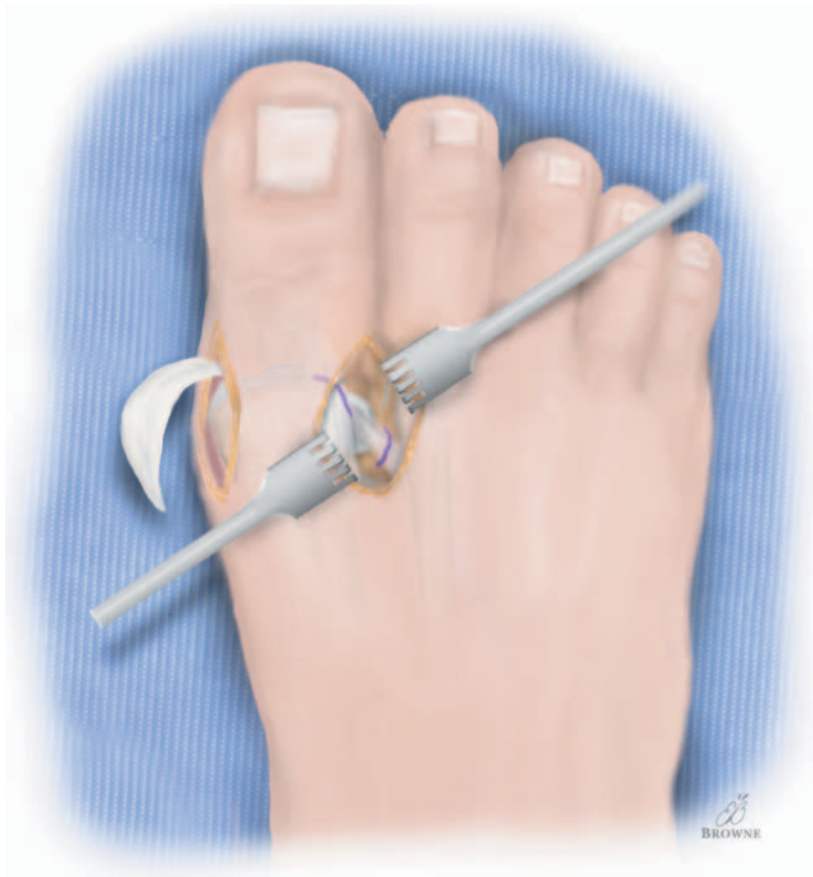

Figure S5.12.4

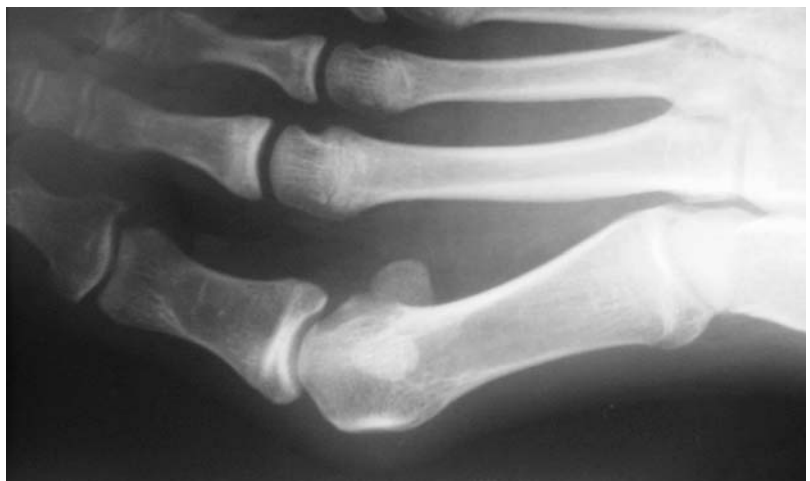

Figure S5.12.5

the proximal end of the first metatarsal utilizing an oscillating dome-shaped saw blade. This osteotomy should be directly vertical to the longitudinal axis of the foot and therefore will be oblique from dorsal proximal to plantar distal in the metatarsal.

11. The metatarsus primus varus is corrected by pressure on the lateral border of the proximal first metatarsal and medial pressure on the

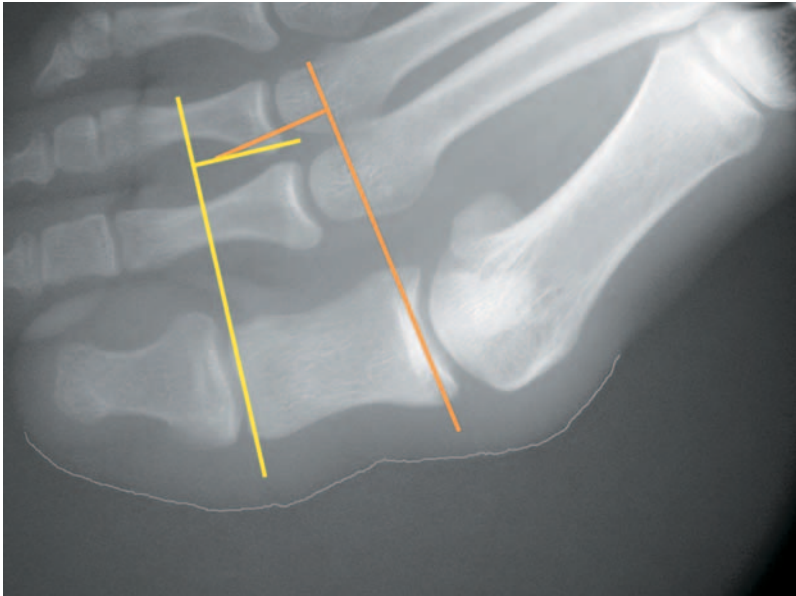


Figure S5.12.6

distal metatarsal. The osteotomy is fixed with an intrafragmentary screw going from dorsal to plantar, or it can be fixed with cross K-wires (Figures S5.12.7, S5.12.8).

12. If the proximal phalanx is in valgus, an osteotomy is made at the distal middle third section of the proximal phalanx using a small oscillating saw. A medial-based wedge is removed, leaving the lateral cortex intact. Then, a fracture of the lateral cortex is produced with correction of the valgus deformity, and the osteotomy is stabilized with a K-wire (Figure S5.12.9).
13. There is overlapping of the plantar medial joint capsule to align the sesamoids under the distal end of the first metatarsal (Figure S5.12.10).
14. The first metatarsal joint is now aligned to neutral, and the distal-based flap is sutured back to the metatarsal to maintain this correction (Figure S5.12.11).
15. All the wounds are closed and a soft dressing is applied, with a bulky dressing between the first and second metatarsal.

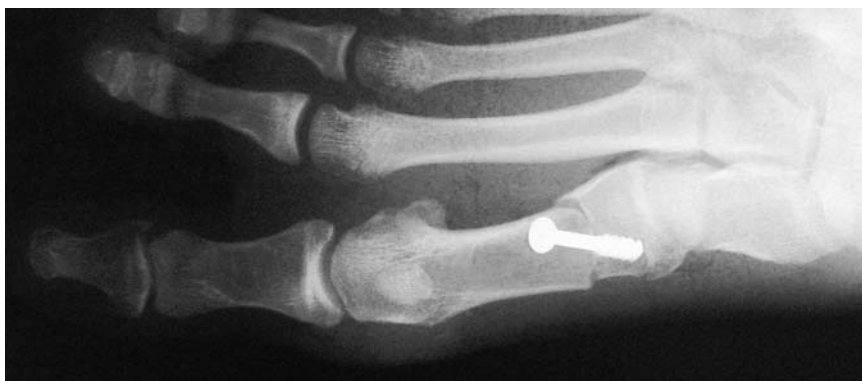

Figure S5.12.7

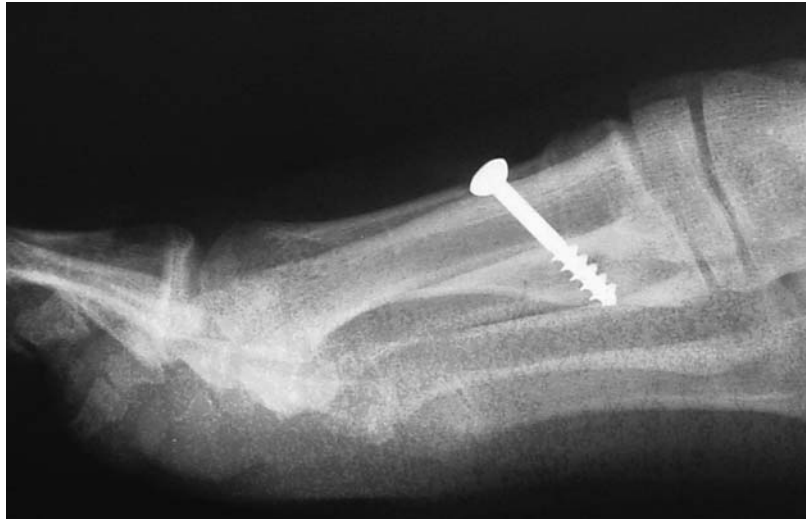

Figure S5.12.8

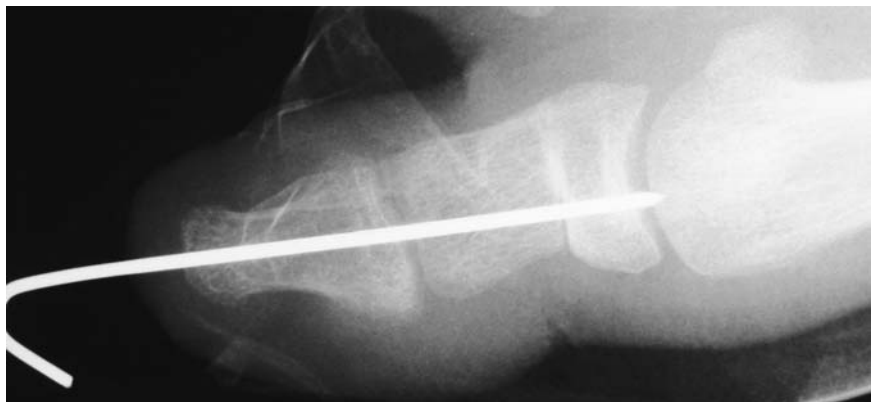


Figure S5.12.9

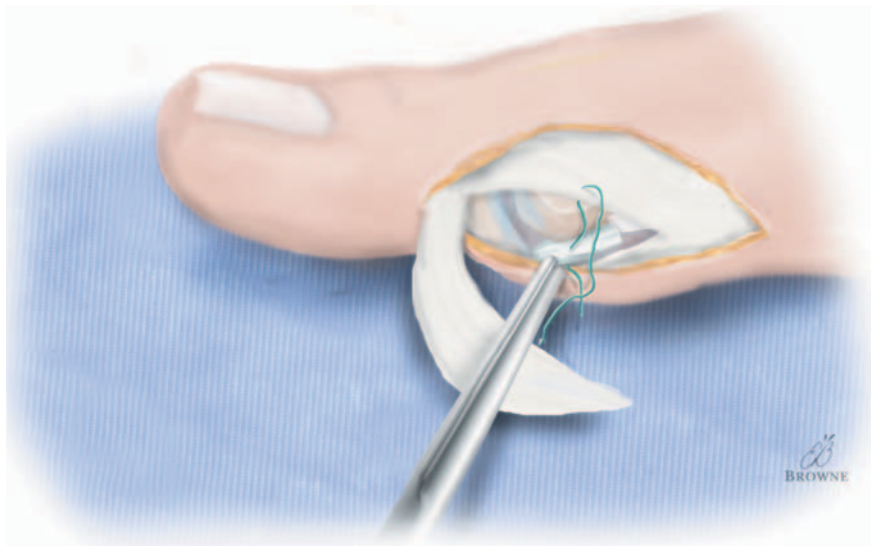


Figure S5.12.10

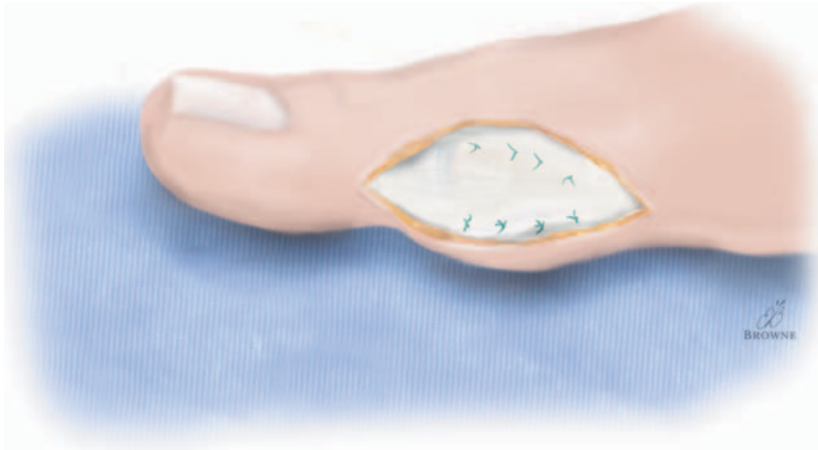

Figure S5.12.11

16. Usually, a short-leg cast is applied because this procedure almost always is performed in combination with hindfoot correction. A small wrap is placed around the great toe to hold it in correct alignment. Overcorrection is to be avoided. Immobilization is required for 4 to 6 weeks until the osteotomies have healed. Postoperative orthotic use usually is not indicated.

Addendum

- A1. If the articular surface has severe degenerative changes, or if the child is a nonambulator, a metatarsal phalangeal joint fusion is indicated.
- A2. Cartilage should be removed utilizing an oscillating saw and resecting only the distal half of the articular surface of the first metatarsal. This cartilage should be transected in a plane that will be vertical with the foot, usually with a 15° to 20° dorsal angulation to the longitudinal axis of the metatarsal.
- A3. This distal phalanx then has its cartilage and surface resected parallel to the distal phalanx. The two flat surfaces now will meet with the toe being in approximately 15° to 20° of dorsiflexion relative to the longitudinal axis of the metatarsal. Additional dorsiflexion at the first metatarsal phalangeal joint is indicated if there is any weight bearing on the proximal phalanx with the foot in neutral position.
- A4. If this is a fully adult-sized patient, the ideal fixation is performed by using a 6.5-mm cancellous screw entering from the proximal plantar surface of the first metatarsal and crossing into the phalanx. This screw provides excellent fixation but only works in an adult-sized foot (Figure S5.12.12). The hole for this screw is drilled retrograde from the middle of the distal end of the metatarsal. The hole in the metatarsal is also tapped retrograde. A hole in the middle of the phalanx is opened with the drill, but tapping in not usually required.
- A5. The other option for fixation is to use crossed K-wires or to use a four-hole plate on the dorsum of the metatarsal phalangeal joint.

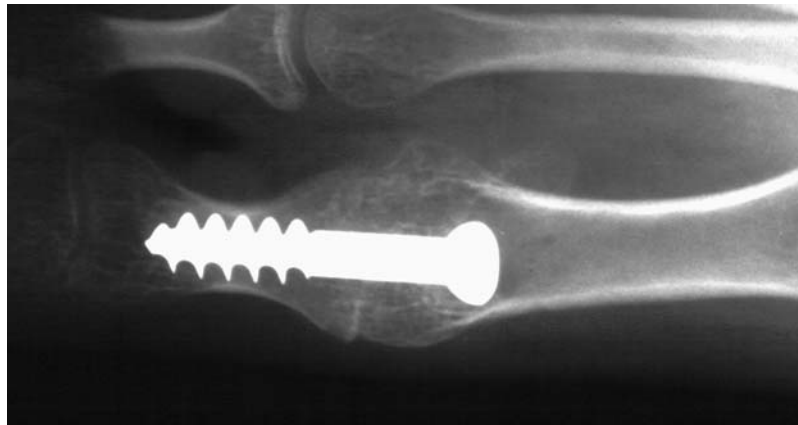

Figure S5.12.12

Postoperative Care

For both the osteotomies and fusions, a well-molded cast with a walking heel is used for 4 to 8 weeks. Weight bearing is encouraged. After the cast is removed, full activity is allowed as tolerated.

13. Correction of Clawed Toes

Indication

Correction of claw toes in children with CP is only required if the toes are having nail problems from chronic pressure or are painful in shoes.

Procedure

1. If contracted flexor tendons are present with the clawed toes demonstrating flexion of the metatarsal phalangeal joint and interphalangeal joints, a direct plantar tenotomy with a number 11 knife is used, and the flexor tendons are cut just distal to the metatarsal phalangeal joint (Figure 5.13.1).
2. This cut should allow full correction of the toes, and if any contractures still are present in the joints, the correction can be fixed with K-wires crossing the interphalangeal joints and extended into the metatarsal joint if needed. Only 2 to 3 weeks of fixation with K-wires is necessary.
3. If the clawed toes are cocked up with extension of the first metatarsal phalangeal joint and flexion of the interphalangeal joint, resection of the proximal interphalangeal joint usually is required. This resection is made through a middorsal incision with the joint being resected utilizing a rongeur. Then, the toes are corrected and fixed with K-wires for approximately 4 weeks (Figure S5.13.2).

Postoperative Care

No cast immobilization is needed. Soft dressings are usually used for 3 weeks.

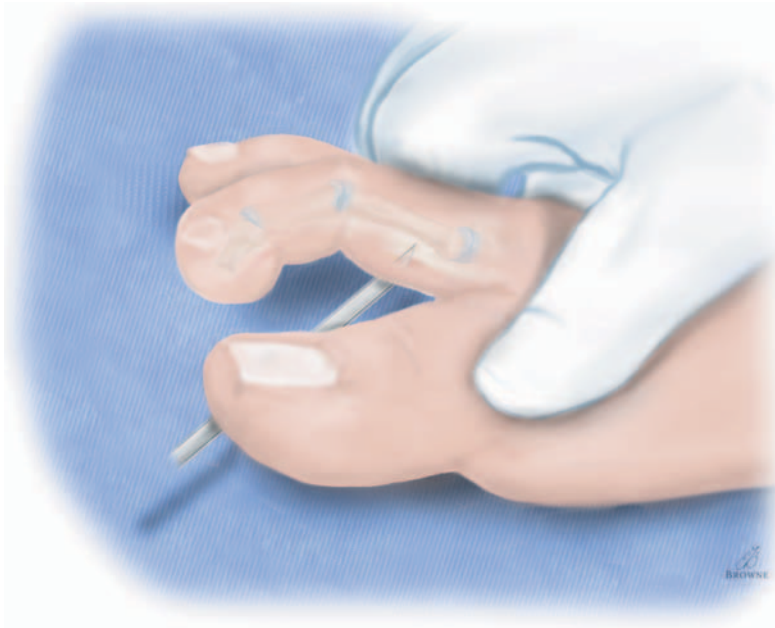

Figure S5.13.1

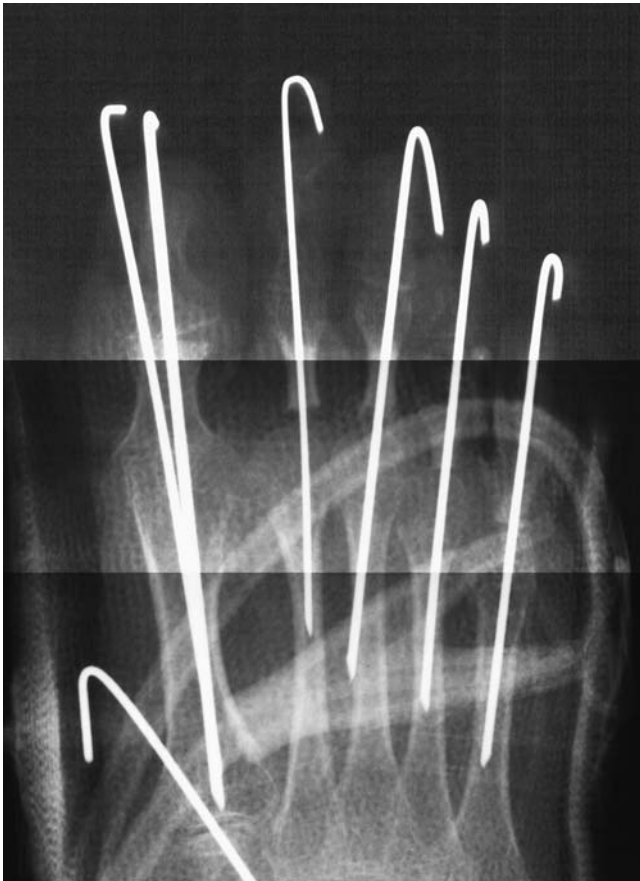


Figure S5.13.2

14. Medial Border Great Toenail Resection

Indication

This procedure is indicated if there have been repeat inflammations with an ingrown toenail.

Procedure

1. The incision is made at the medial border where the toenail flattens, going through the toenail into the distal end of the phalanx, and has

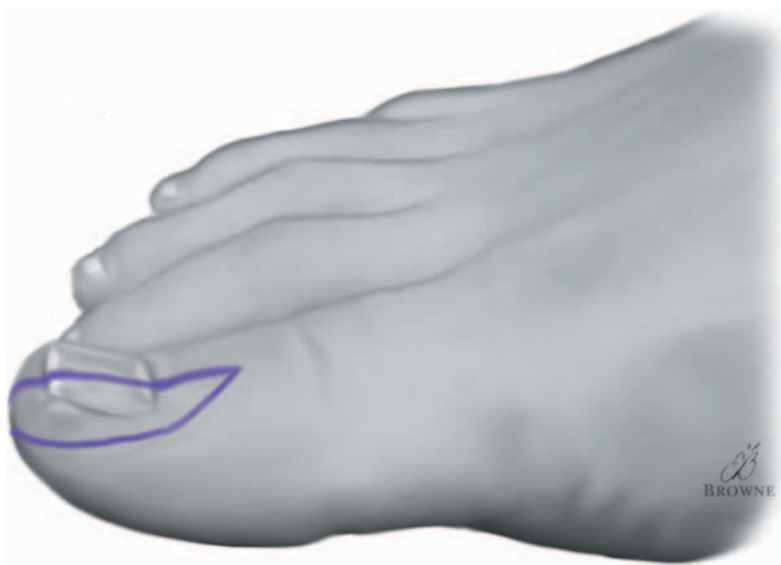


Figure S5.14.1

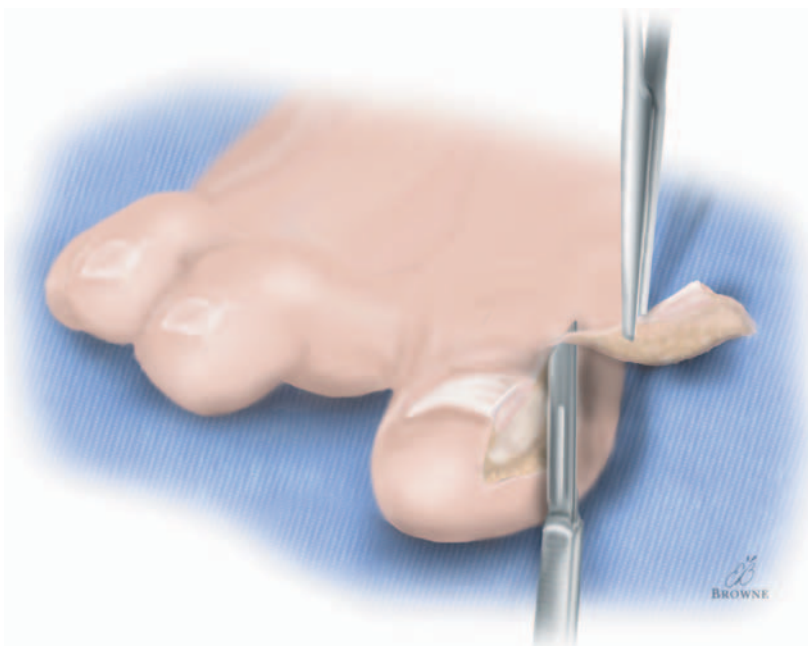


Figure S5.14.2

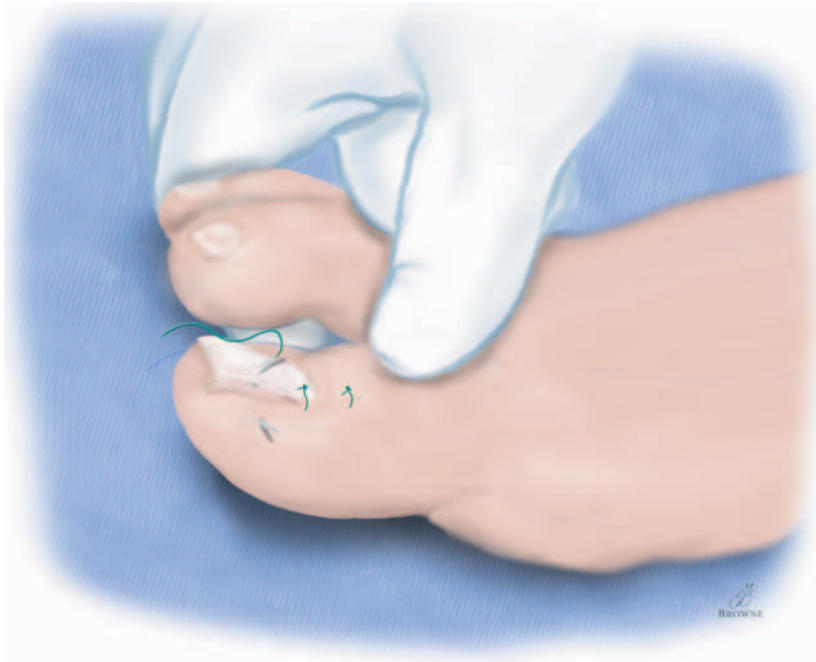


Figure S5.14.3

to extend proximally at least 5 to 7 mm past the skin surface. The skin then is incised further medially, away from the border of the nail, so that it meets proximally and distally to form a wedge resection (Figure S5.14.1).

2. The wedge is removed and the base, especially proximally, is cauterized to kill any residual nail bed cells (Figure S5.14.2).
3. Several sutures are used for loose approximation (Figure S5.14.3).

Postoperative Care

A soft dressing is used for 2 weeks. The foot is then soaked twice daily until the eschar is removed and the wound appears well healed.

Index

- A**
- Abdominal mass, spine presenting as, 457
- Abduction wedges, for wheelchairs, 217–218, 218*f*
- Abductor pollicis, palmaris longus or brachioradialis transfer to, 890–891, 891*f*
- Ablative surgery, as athetosis treatment, 133
- Accidents, as cerebral palsy cause, 11
- Acetabuloplasty, shelf, 557–558, 557*f*, 559*f*
- Acetabulum
- in anterior hip dislocation, 579, 584, 587
 - dysplasia of
 - after hip subluxation surgery, 538
 - hypotonic hip disease-related, 627, 628, 628*f*
 - osteotomy treatment of, 551, 556
 - planovalgus-related, 745–746
 - spastic hip disease-related, 746
 - as spastic hip subluxation cause, 524
 - false, 576, 576*f*
 - fractures of, 70, 70*f*
 - in hip reconstruction, 547, 550
 - inadequate reconstruction, 552
 - in hip subluxation, 525, 527*f*, 529*f*, 534
 - computed tomographic scan of, 532
 - in reconstructive treatment, 547
 - as protrusio acetabuli, 70, 70*f*, 594, 595, 595*f*
 - windblown hip deformity-related, 603
 - Unit rod perforation of, 474, 476–478
- Acetabulum pedis, in planovalgus collapse of, 748
- dysplasia of, 745–746, 747*f*
- Acetaminophen, as postoperative pain treatment, 82
- in combination with codeine, 88
- Acetazolamide, 84*t*
- Achilles' tendon
- anterior transposition of, as ankle equinus treatment, 715–716
 - incompetent, as ankle dorsiflexion contracture cause, 321–322
 - tenotomy of, 667
 - historical background of, 708
- Achilles' tendon
- anterior transposition of, as ankle equinus treatment, 715–716
- Achilles' tendon lengthening
- as ankle dorsiflexion treatment, 359
 - as ankle equinus treatment, 713–715
 - complications of, 717–719, 718–719*f*
 - as claw toe treatment, 787–788
 - as hemiplegic gait type 2 treatment, 345
 - implication for cavus treatment, 777
 - overlengthening in, 776
 - surgical technique in, 1003–1004, 1003–1004*f*
- Acidosis, lactic, 37*t*
- Aciduria
- argininosuccinic, 36*t*
 - glutaric, 35*t*
 - type 1, 38
 - 4-hydroxybutyric, 36*t*
- Activities of daily living (ADLs)
- effect of spasticity on, 108
 - functional, evaluation of, 840
- Acupressure, 175
- Acupuncture, 175
- Adaptive devices. *See also* Assistive devices
- definition of, 169
 - prescriptions for, 170
- Adductor brevis muscle, as internal rotator muscle, 619*f*
- Adductor longus, as internal rotator muscle, 619*f*
- Adductor pollicis
- myotomy of, 421, 421*f*
 - spasticity of, 418, 419
 - treatment of, 419–420
- ADELI suit, 176
- Adolescent growth spurt
- balance development during, 137
 - femoral anteversion during, 623
 - femoral neck shaft angle during, 620, 622
- Adolescents
- back-kneeing in, 370
 - crouched gait in, 362–371
 - treatment of, 363–370
 - foot deformities in, 312, 313–314*f*
 - hip subluxation in, 529*f*, 530
 - occupational therapy for, 165
 - patellofemoral pain in, 693–694
 - patient-controlled analgesia in, 82
 - physical therapy for, 162
 - planovalgus in, 743
 - quadruplegic ambulation in, 372–373
 - shoulder contracture treatment in, 397, 398, 398*f*
 - upper-extremity functional development in, 391
 - varus foot deformity in, 732–733
 - windblown hip deformity treatment in, 602–603
- Adrenoleukodystrophy, 37*t*
- X-linked, 37*t*
- A.I. du Pont Hospital for Children (AIDHC)
- Clinic Scale, 834, 835*t*
 - occupational therapy clinic evaluation worksheet, 845–847*f*
- Air embolism, spinal surgery-related, 466
- Alcohol injections, as spasticity treatment, 118, 122
- Alcohol use, as neurologic defect cause, 38
- Alpers syndrome, 37*t*
- Alpha-2-adrenergic receptor blockers, 110
- Alternative medicine, 16, 176–177

- Amblyopia (“lazy eye”), 30–31
 eye patch treatment of, 158
- Amino acid metabolism disorders, 35*t*
- Amitriptyline
 as arthritis-related pain treatment, 653
 as postoperative sleep disorder treatment, 87*t*
- Amphetamine, 87*t*, 88
- D-Amphetamine, 87*f*, 88
- Analgesia, postoperative, 88
- Anesthesia, 79–80
 asthma exacerbation during, 468
 in children on ketogenic diet, 89
 hypotensive, 471
 in spinal fusion, 450
- Ankle
 in gait abnormalities, 319–322
 in normal gait, 293–295, 294*f*
 power output function of, 319–320, 320*f*
 “shock absorber” function of, 319, 320*f*
 plantar flexion prepositioning of, 320
- Ankle dorsiflexion
 in diplegia, 359
 measurement of, 53, 55*f*
 in normal gait, 294
 during swing phase, 321–322
- Ankle epiphysodesis screw, 979, 979*f*
- Ankle equinus, 667, 708–722
 as balance deficit cause, 139
 contractures associated with, 322*f*, 523
 etiology of, 709–710, 709*f*
 evaluation of, 53, 55*f*, 711–712, 712*f*
 knee extension contracture-related, 685
 natural history of, 711
 secondary pathology of, 710
 tertiary changes in, 710–711
 treatment of, 708, 712–717, 713*f*, 714*f*, 715*f*, 716*f*
 with botulinum toxin injections, 713, 716–717
 complications of, 717–722, 718–721*f*
 with gastrocnemius neurectomy, 118
 historical background of, 667, 708
 with orthopedic shoes, 182
 with orthotics, 182, 190, 322
- Ankle-foot orthoses (AFO), 182, 190–197, 191–192*f*, 193*f*, 194*f*, 195*f*, 198*f*
 as ankle dorsiflexion treatment, 322
 as ankle equinus treatment, 713, 713*f*
 as ankle plantar flexion prepositioning treatment, 320
 anterior ankle strap, 196–197, 198*f*
 articulated
 ground reaction, 194, 195*f*
 as hemiplegic gait pattern type 2 treatment, 345
 comparison with tone-reducing casts, 158
 custom-molded, 190, 191–193*f*
 dorsiflexion-limiting, as plantar flexor insufficiency treatment, 722
 flexible leaf-spring, as hemiplegic gait pattern type 1 treatment, 344
 full calf height, as equinovarus foot deformity treatment, 727
 ground reaction (GRAFO), 182, 193–194, 194*f*
 articulated, 194 195*f*
 as overlengthened plantar flexor treatment, 721, 721*f*
 as plantar flexor insufficiency treatment, 721, 721*f*, 722
 half-height, 195
 hinged, 190, 193
 contraindications to, 192–193
 molded (MAFO), 182
 motor control effects of, 123
 as patella alta treatment, 691
 with plantar flexion-limiting ankle hinge, 194*f*
 for preambulatory children, 192, 194*f*
 for quadriplegic patients, 56, 371
 solid, 190, 193
 modifications of, 198*f*
 for quadriplegic patients, 56
 terminology related to, 190
 with toe plate, as bunion treatment, 780
 twister cable use with, 188
 as unstable foot treatment, 311
 wraparound, 195–196
- Ankle jerk reflex, 104
- Ankle orthoses. *See also* Ankle-foot orthoses (AFOs)
 as ankle equinus treatment, 713, 713*f*
 as ankle plantar flexion prepositioning treatment, 320
 for hypotonia management, 127
 as spasticity treatment, 123
- Ankle procedures. *See* Foot and ankle procedures
- Ankle reflex, 106
- Ankle restraints, lateral, 371
- Ankle valgus, 667–668, 704–708, 704–722
 diagnostic evaluation of, 705, 711–712, 712*f*
 etiology of, 709–710, 709*f*
 natural history of, 705, 711
 planovalgus associated with, 704, 705, 705*f*, 707–708, 707–708*f*
 radiographic evaluation of, 704, 704*f*
 secondary pathology of, 710
 subtalar fusion-related, 768
 tertiary changes in, 710–711
 tibial torsion associated with, 705, 706, 706*f*
 treatment of, 705, 706–708, 706–708*f*, 712–717, 713*f*, 714*f*, 715*f*
 complications of, 717–722, 718–721*f*
- Anterior cruciate ligament tears, 694–695
- Anterior release
 as kyphosis treatment, 454, 454*f*
 as lordosis treatment, 460
 as scoliosis treatment, 451–452
- Antibiotic therapy, for postoperative wound infections, 491, 493, 494, 495
- Anticholinergic drugs, as dystonia treatment, 129
- Antiepileptic medications
 side effects of, 83–84, 84*t*
 bone density loss, 58, 66–68
 gingival hyperplasia, 57
 in surgical patients, 79, 83–84, 84*t*
 in spinal surgery patients, 468, 471
- Anti-inflammatory drugs. *See also* Nonsteroidal anti-inflammatory drugs
 as hip pain treatment, 566
- Antispasticity medications. *See also* specific antispasticity medications
 intrathecal administration of, 110–114, 111*f*, 113*f*
 oral administration of, 109–110, 109*t*
- Aquatic therapy, 811–816, 813*f*. *See also* Hydrotherapy; Swimming
 Bad Ragaz Ring Method of, 815–816
 contraindications to, 814*t*, 815
 Halliwick Method of, 815
 multidisciplinary approach in, 816, 818
 pool design/accessibility in, 816, 816*t*, 817*f*
 precautions in, 814*t*
 Watsu, 815
- Arch, medial, 770*f*
 collapse of, 776
 surgical correction of, 771
- Arginase deficiency, 36*t*
- Armspan measurement, 56
- Arthritis. *See also* Rheumatoid arthritis
 foot and ankle fusion-related, 768
 as hip pain cause, 69, 71
 hip surgery-related, 563, 565–566, 565–566*f*, 652–653
 of the radial head, 401
- Arthrodesis
 pantalar, 722, 777
 of subtalar joint, as planovalgus treatment, 760, 762–763, 762–765*f*
 triple
 as cavus treatment, 777

- as planovalgus treatment, 758, 760, 767, 767*f*
 - as severe foot deformity treatment, 998–999, 999*f*
- Arthrography, 533
- Arthrogryposis patients, power wheelchairs for, 210
- Arthroplasty
 - interposition, 946–949, 946–949*f*
 - resection, 567–568*f*, 570–571, 573–574, 573*f*
 - operative procedure in, 944–946, 944–946*f*
 - subtrochanteric, as anterior hip dislocation treatment, 587
- shelf
 - acetabular, 557–558, 557*f*
 - as limited hip range-of-motion cause, 656
- Arthroscopy, of the knee, 695
- Ashworth Scale, 104–105, 105*f*, 105*t*
 - comparison with Barry Albright Dystonia scale, 129
 - in gait analysis, 275, 275*t*
 - in hypotonia measurement, 126
 - in occupational therapy evaluations, 838, 839
 - in upper-extremity evaluations, 388
- Aspartylglycoaminuria, 35*t*
- Asphyxia, near, 38
- Aspiration
 - as reactive airway disease cause, 79, 468
 - in spinal fusion patients, 485
- Assistive devices, 818–821. *See also* Durable medical equipment for handwriting, 391
- Asthma, in spinal surgery patients, 468
- Asymmetric tonic neck reflex (ATNR), 41, 42, 42*f*, 44, 838
- Ataxia, 137–139
 - cavovalgus deformity associated with, 776
 - closed head injury-related, 33
 - definition of, 46, 137
 - hypotonia associated with, 137
 - inappropriate synaptic remodeling-related, 31
 - primary, 138
 - spasticity associated with, 137
 - treatment of, 138–139
 - orthoses, 140
 - physical therapy, 138–139
 - surgical, 139
- Athetosis, 132–136
 - definition of, 45, 132
 - development of, 306
 - differentiated from dystonia, 133
 - dystonia associated with, 306
 - fine motor skill task performance in, 394
 - gait abnormalities associated with, 306, 307, 373–374
 - physical therapy for, 135–136, 137
 - powered wheelchair use in, 205
 - prevalence of, 39
 - sensory motor effects associated with, 132–133
 - shoulder instability associated with, 397, 399
 - wrist extension contracture treatment in, 415
- Ativan. *See* Lorazepam
- Attention deficit disorder, pharmacotherapy for, 89
- Augmentative communication, 166, 241
- Augmentative communication devices, on wheelchairs, 222
- Augmentative communication evaluations, 152
- Autism, 31
- Avascular necrosis, postoperative, 654, 655, 655*f*
- Ayers technique, 155
- B**
- Babinski's pronation sign, 839*t*
- Back-kneeing, 687*t*
 - in adolescents or young adults, 370
 - ankle equinus-related, 710–711
 - diplegia-related, 356*f*, 361–362
 - in midstance phase, 323, 325
 - plantar flexion insufficiency-related, 722
 - in stance phase, 685
- Back pain. *See also* Low back pain
 - lordosis-related, 457, 458, 459–460
- Baclofen
 - contraindication as athetosis treatment, 133
 - intrathecal pump administration of, 110–114, 111*f*, 113*f*, 851–857
 - after dorsal rhizotomy, 117
 - baclofen overdose in, 856
 - complications of, 112–113, 114, 855–857
 - criteria for, 853–854
 - versus* dorsal rhizotomy, 851, 857
 - as dystonia treatment, 129, 131, 132
 - as extensor posturing treatment, 506
 - as hemiplegia type 4-related spasticity treatment, 352
 - outcomes in, 857
 - pump and catheter malfunction in, 142–143*f*, 856–857
 - pump implantation procedure in, 854–855, 855*f*, 908–912, 909–912*f*
 - screening trial in, 854
 - as spasticity treatment, 125
 - in upper-extremity surgery patients, 393
 - as windblown hip deformity treatment, 605
 - oral administration of, 109–110, 109*t*, 112, 114, 853
 - pharmacology of, 853
 - as spasticity treatment, 109–110, 109*t*
- Bad Ragaz Ring Method, of aquatic therapy, 815–816
- Balance
 - assessment of, 138
 - definition of, 46
 - development of, 137, 305, 808
- Balance deficits, 46, 46*f*, 137–140
 - ankle-foot orthoses-based improvement of, 190
 - as gait abnormalities cause, 304–305
- Balance exercises, 139
- Balance interventions, 808–809
- Ballismus
 - definition of, 45, 136
 - treatment of, 136, 137
- Barbiturates, as seizure treatment, 84*t*
- Barry Albright Dystonia (BAD) scale, 129
- Basal ganglia, role in motor control, 96, 97*f*
- Basal ganglion lesioning, as dystonia treatment, 129
- Basal ganglion lesions, athetosis-related, 132
- Bath chairs, 231, 233*f*
- Batten disease, 35*t*
- Bean bags, as positioning devices, 232
- Bechterew's sign, 839*t*
- Bed mobility, postoperative decrease in, 489–490
- Benzedrine. *See* Amphetamine
- Benzodiazepines
 - as dystonia treatment, 129
 - mood-stabilizing effects of, 87*t*, 88–89
 - as postoperative spasticity treatment, 87
 - as seizure treatment, 84*t*
- Beta-galactosidase deficiency, 34*t*
- Biceps
 - flexion contractures of, 399
 - lengthening of
 - myofascial, 398, 398*f*
 - as peroneal nerve injury cause, 679
 - Z-lengthening, as elbow flexion contracture treatment, 400
 - long head of, role in knee function, 670
 - overpull of, 695
 - transection of, as elbow flexion contracture treatment, 400
- Biceps femoris, long head of, in knee flexion contractures, 669
- Bidabe, Linda, 829

- Biofeedback, as ankle equinus treatment, 716
- “Birthday syndrome,” 22–23, 342–343
- Bisphosphonates, 68
- Bladder, neurogenic, 74–75
- Bladder control, 74
- Bladder dysfunction, 74–75
dorsal rhizotomy-related, 116
- Blindness, as posterior walker contra indication, 235
- Blix Curve (muscle length-tension relationship), 257–259, 259f
- Blood flow, peripheral, impaired, 75–76
- Blood loss. *See also* Hemorrhage
intraoperative, 471–473
bone decortication-related, 471, 472–473
coagulopathy-related, 469
from epidural space, 471–472
facetectomy-related, 471, 472
during spinal surgery, 469, 471–473
- Blood pressure. *See also* Hypertension; Hypotension
postoperative, 482–483
- Blood salvage, 471
- Blood transfusions
families’ refusal to allow, 501–502
during spinal surgery, 472–473
- Bobath, Berta, 805, 816
- Bobath, Karl, 805, 816
- Bobath technique. *See* Neurodevelopmental Therapy (NDT)
- Body temperature, in spinal fusion surgery patients, 449
- Body temperature regulation problems, 75–76, 75f, 789, 789f
in surgery patients, 79–80
- Bone decortication, as intraoperative blood loss cause, 471, 472–473
- Bone grafts, as postoperative fever cause, 491
- Bone growth, 57–58
- Bones
effect of hypotonia on, 126
effect of spasticity on, 108
- Bone scans
for bone density evaluation, 67
of low-energy fractures, 63, 70, 70f
for pain evaluation, 69, 69f
of subluxated hips, 532–533
- Botox. *See* Botulinum toxin injections
- Botulinum toxin injections
as ankle equinus treatment, 713, 716–717
as dystonia treatment, 129–130, 132
as elbow flexion contracture treatment, 399–400
as extensor posturing treatment, 505–506
as hamstring contracture treatment, 674
as hemiplegic gait pattern type 2 treatment, 345
as knee stiffness treatment, 689
lack of efficacy as scoliosis treatment, 443
as quadriplegic gait treatment, 371–372
as shoulder contraction treatment, 397
as spasticity treatment, 118, 120–122, 120f, 121f, 124–125, 852
in upper-extremity surgery patients, 392–393
as windblown hip deformity treatment, 606
as wrist extension contracture treatment, 410, 414
- Bowel control, 74
- Bowel dysfunction, dorsal rhizotomy-related, 116
- Brachialis
myofascial lengthening of, 398, 398f
transection of, as elbow flexion contracture treatment, 400
- Brachioradialis
flexion contractures of, 399
transection of, as elbow flexion contracture treatment, 400
- Brachioradialis transfer
to the abductor pollicis, 890–891, 891f
as wrist flexion contracture treatment, 415
- Bracing, 182
in hip abduction, as windblown hip deformity cause, 603, 606f
inefficacy for scoliosis prevention, 437
of trunk, weaning from, 813
- Brain
central program generator (CPG) of, 100, 103, 306–307
embryonic development of, 29f, 97
defects in, as cerebral palsy cause, 28, 30–31, 30f
role in motor control, 96, 97f
synapse formation and remodeling in, 30–31
- Brain imaging studies, for cerebral palsy diagnosis, 47, 48f
- Brain injury
developmental aspects of, 41
as hyperextension posturing cause, 579
- Bronchospasms, dorsal rhizotomy-related, 116
- Bruininks-Osterestky Test of Motor Proficiency, 809
- Bunions, 108, 737, 737f
development of, 779f
diagnostic evaluation of, 780
dorsal, 770, 771, 772–773f, 774–775f, 775
outcome of treatment of, 775–776
treatment of, 774–775f, 775
hallux valgus-related, 779–784, 779f
natural history of, 780
overcorrection of, 782, 782f
pathology of, 780
planovalgus-related, 748f, 779f
radiographic assessment of, 780–781, 780f, 781f
severity of, 780–781
treatment of, 780–781, 781f, 782–784f
complications of, 781, 784
operative procedure, 1014–1020, 1014–1020f
outcome of, 775–776, 781
untreated, 780
- Buoyancy, 812–813
- Bupivacaine
as arthritis-related pain treatment, 653
as hip pain treatment, 72
as postoperative pain treatment, 82
- Bursitis
femoral osteotomy blade plate-related, 651, 651f, 652, 652f
spinal fusion and instrumentation-related, 479, 487–488
- Buspirone, 87t, 89
- C**
- Calcaneal tuberosity, in planovalgus, 749, 749f
- Calcaneocuboid joint
fusion lengthening of, 989
as planovalgus treatment, 758, 759, 759f
in triple arthrodesis, 998, 999, 999f
lateral column lengthening through, 989–991, 990–991f
midfoot collapse at, 768
nonunion of, 768f
resection of, 774
with fusion, 741
- Calcaneus bone
deformity of, 721–722
lengthening of
lateral column, 985–989, 985–989f
as planovalgus treatment, 730f
as varus foot deformity treatment, 738
low-energy fractures of, 60
osteotomy of
closing wedge, 733, 734, 734f
as fixed heel varus treatment, 733, 734, 735f

- as planovalgus treatment, 760, 761, 761*f*, 766, 767, 767*f*
- as recurrent varus foot deformity treatment, 741–742
- as varus foot deformity treatment, 740
- in planovalgus, 748, 749*f*
- Calcium deficiency, 58
- Calcium supplementation, 66, 68
- Calf muscles, torque of, 709, 709*f*
- Callosities, 737, 737*f*
- Caloric intake, postoperative, 486
- Calorimetry, indirect, 282
- Canes, 237–239, 240*f*, 820–821
 - contraindication in ataxia, 139
- Cannabis, as spasticity treatment, 110
- Capsulodesis, volar, 426
- Capsulotomy
 - knee, as sciatic nerve palsy cause, 680, 681
 - knee posterior
 - indication for, 962
 - as knee flexion contracture treatment, 679–681
 - orthoses use following, 189–190
 - procedure in, 963–966, 963–966*f*
 - lateral, as bunion treatment, 781
- Carbamazepine
 - as dystonia treatment, 129
 - as seizure treatment, 83, 84*f*
- Carbonic anhydrase, as seizure treatment, 84*t*
- Carboxylase deficiency, 36*t*
- Cardiac arrest, in spinal surgery patients
 - as death cause, 466–467
 - hypotension-related, 473
- Cardiovascular conditioning, 308
- Care-providing community, 5–6
- Caries, dental, 57
- Carnitine deficiency, 37*t*
- Carpectomy, proximal row, 415, 416–417, 416–417*f*
 - operative procedure in, 880–883, 880–883*f*
- Car seats, 228, 229*f*
- Castle procedure, 574
- Casts
 - as ankle equinus treatment, 716–717, 716*f*
 - as foot sole ulcer cause, 791
 - as hip joint stiffness cause, 656
 - inhibition, 24
 - tone-reducing, 123, 158
 - as windblown hip deformity treatment, 601–602
- Cats
 - synaptic formation experiment in, 30
 - as *Toxoplasma gondii* host, 38
- Cavovalgus deformity, calcaneal, 776
- Cavovarus deformity, 719
- Cavus deformity, 776–778
 - fixed
 - Coleman block test evaluation of, 726–727
 - equinovarus-related, 724, 725, 725*f*
 - surgical treatment of, 777, 778*f*
- Central nervous system. *See also* Brain
 - development of, 97
 - role in motor function control, 96, 97*f*
 - feedback control mechanism in, 98–199, 99*f*
 - feed-forward control mechanism in, 98–199, 99*f*
 - open-loop control mechanism in, 99
- Central nervous system surgery
 - as athetosis treatment, 133
 - as dystonia treatment, 129
- Central program generator (CPG), 100, 103, 306–307
- Ceramide trihexoside deficiency, 34*t*
- Cerebellum, role in motor function control, 96, 97*f*
- Cerebral cortex, gyri formation in, 30, 30*f*
- Cerebral cortex, role in motor function control, 96, 97*f*
- Cerebral hemispheres, embryonic development of, 29*f*
- “Cerebral palsies,” 27
- Cerebral Palsies, The* (Miller and Clarke), 28
- Cerebral palsy. *See also* Diplegia; Hemiplegia; Quadriplegia
 - classification of, 39–40
 - by anatomic pattern, 39, 40–41
 - definition of, 3, 27
 - diagnosis of, 47
 - “blame” for, 8, 9, 11
 - delayed, 9, 11
 - failure to provide parents with, 11–12
 - physician-parent communication regarding, 11–12
 - diseases concurrent with, 77–78, 78*f*
 - as dual diagnosis, 27–28
 - epidemiology of, 39
 - etiology of, 27, 28–38
 - congenital etiologies, 28–31, 29*f*, 30*f*
 - neonatal etiologies, 31–32, 32*f*
 - postnatal etiologies, 32–38, 33*f*, 34–37*t*
 - evolutionary pathology of, 41–43*f*, 41–44
 - misdiagnosis of, 27
 - prevalence of, 39
 - prognosis of, 11
 - terminology of, 39–40
 - treatment goals in, 22–25
- Cerebral palsy clinics, 6
- Cerebrospinal fluid leaks
 - intrathecal baclofen-related, 113, 856
 - spinal surgery-related, 473
- Cervical instability, 34*t*
- Cervical spine deformities, 505–508
 - cervical posturing, 505–506, 506*f*, 507*f*
 - extensor posturing, 505–506, 506*f*
 - occipital sublaxation, 506, 507*f*
 - spondylolysis, 507
 - thoracic kyphosis/lordosis associated with, 507–508, 508*f*
- Chaddock’s wrist sign, 839*t*
- Chaos theory, 101–102, 101*f*
- Chaotic attractors, 101–102, 101*f*
 - in early childhood physical therapy, 161
- Cherry red spot myoclonus syndrome, 34*t*
- Chest tubes, placement in spinal surgery patients, 468, 471
- Child abuse and neglect, 59
 - as brain injury cause, 32–33, 33*f*
- Chloral hydrate, 85
- Chlorazepate, as spasticity treatment, 109*t*
- Cholangitis, postoperative, 486
- Chorea
 - definition of, 45, 136
 - treatment of, 136, 137
- Choriomeningitis, lymphocytic, 38
- Chronic pain syndrome, palliative treatment-related, 576, 578
- Circumferential wraps, as forearm pronation deformity treatment, 183, 184*f*
- Citrullinemia, 36*t*
- Clasp-knife stiffness, 47
- Claw toes, 741*f*, 787–788
 - tibialis posterior transfer-related, 741*f*
 - treatment of, 787–788, 1020, 1021*f*
- Clenched fist deformity, 387
- Clonazepam, 87*t*
 - half-life of, 88
 - as seizure treatment, 84*t*
 - as spasticity treatment, 109*t*
- Clonidine, as spasticity treatment, 109*t*, 110, 853
- Clorazepate, 84*t*
- Clostridium botulinum*, 120
- Clotting cascade, intraoperative monitoring of, 483
- Clubfoot deformities. *See also* Equinus
 - severe fixed spastic, 724, 725, 725*f*, 733, 736
- Coagulopathy, in spinal surgery patients, 469
 - as death cause, 467
 - as intraoperative blood loss cause, 469
 - postoperative, 483
 - prevention and treatment of, 471

- Cock-up toes, 787, 788
- Codeine, as postoperative pain treatment, 82, 83*t*
in combination with acetaminophen, 88
- Cognitive integration, evaluation of, 838
- Cognitive skills, relationship with motor function, 95
- Coleman block test, 726–727, 729*f*
- Colicystitis, postoperative, 485–486, 491
- Colon, Unit rod-related perforation of, 474
- Comfort care, for spinal deformity patients, 504–505
- Compartment syndrome
epidural anesthesia-related, 83
tibial osteotomy-related, 704, 792
- Computed tomography (CT)
of anterior hip dislocation, 579, 581*f*, 586*f*
for cerebral palsy diagnosis, 48*f*
in femoral neck anteversion measurement, 612–613, 613*f*, 615–616, 617–618*f*
in gait impairment diagnosis, 285–286
of hip dysplasia, 531–532
of hip subluxation, 531–532
of tibial torsion, 698, 699*f*
- Conductive education, 157
- Congenital cerebellar malformations, as ataxia cause, 137
- Congenital developmental deformities, as cerebral palsy cause, 28–31, 29*f*, 30*f*
- Congenital limb deficiency patients, power wheelchairs for, 210
- Connective tissue laxity, Down syndrome-related, 126
- Constipation, 74
postoperative, 85, 87, 486
- Contractures, 107
in athetosis patients, 133
biceps flexion, 399
brachioradialis flexion, 399
closed head injury-related, 33
of elbow, 108
splinting of, 833*t*
elbow flexion, 399–400
natural history of, 399
orthoses treatment of, 182
surgical release of, 871, 872*f*
treatment of, 396, 396*f*, 399–400, 871, 872*f*
equinovarus foot deformity-related, 724
equinus-related, 322*f*, 523
of fascia latae, 330
of fingers, 389*f*
finger flexion, 410, 412, 424–426
of flexor digitorum profundus, 424
of flexor digitorum sublimus, 424
forearm pronation, 183, 401
natural history of, 406
treatment of, 407–408
- of gastrocnemius
ankle equinus-associated, 708–709, 709*f*, 710
differentiated from soleus contractures, 708–709, 709*f*, 710
effect on gait, 319, 320
hemiplegia-associated, 731
planovalgus-associated, 727, 750
as subtalar joint collapse cause, 742
treatment of, 713–714, 714*f*
- of gluteus maximus, windblown hip deformity-related, 603
- of hamstrings
in athetosis patients, 133
botulinum toxin injection treatment of, 674
as crouched gait risk factor, 671, 673
electromyographic evaluation of, 676
hemiplegia gait type 3-related, 347–350, 348, 348*f*
hip hyperabduction-related, 596
as knee flexion contracture cause, 668–679
as kyphosis cause, 227, 227*f*
nighttime splinting treatment of, 190, 674, 674*f*, 676
passive stretching exercise treatment of, 673
popliteal angle measurement of, 671, 673, 673*f*
as quadriplegic gait cause, 372–373
as thoracic kyphosis cause, 452, 452*f*, 453
treatment of, 673–679
wheelchair seating management of, 228
- of hip abductors, 332
abduction bracing-related, 188
abductor lengthening treatment of, 940–943, 941–943*f*
after hip reconstructive surgery, 551
external rotation, 183
- of hip adductors, 331
after hip reconstructive surgery, 551
as leg length discrepancy cause, 645
- hip extension, knee extension contracture-related, 685
- hip flexion, 329, 596–599
as anterior pelvic tilt cause, 512
assessment and measurement of, 597–598, 597*f*, 598*f*
diplegia-related, 360
etiology of, 598
natural history of, 598
recurrent, 644–645
treatment of, 598–599
- hip internal rotation-related, 188–189, 333–334, 335, 335*f*, 607, 616, 618–619, 619*f*, 622–623
- as hip subluxation cause, 527–528
- of knee, 108
- knee extension, 108, 685–689
anterior hip dislocation-related, 579, 587
diagnostic studies of, 687, 689
fixed, 692–693
pathology of, 685–687, 686*f*
- knee flexion
during adolescence, 671
between 10° and 30°, posterior knee capsulotomy treatment of, 962–966, 963–966*f*
in athetosis patients, 133, 134
diagnostic and treatment algorithm for, 793*t*
diagnostic evaluations of, 671, 673, 673*f*
during early and middle childhood, 670–671
etiology of, 668–670
femoral condyle flattening associated with, 671, 672–673, 672*f*
greater than 30°, osteotomy treatment of, 972–978, 973–978*f*
hamstring contracture-related, 667*f*, 668–679, 669*f*, 670*f*, 674–676*f*
hemiplegia gait type 3-associated, 347
hip flexion contracture-associated, 599
knee-ankle-foot orthoses treatment of, 189–190, 189*f*
measurement of, 53
moderate, 679–682
natural history of, 671
sciatic nerve palsy associated with, 789–790
secondary pathology of, 670–671
severe, 668, 668*f*, 682–683
tertiary pathology of, 671, 672, 672*f*
treatment of, as sciatic nerve palsy cause, 789–790
uncorrected, 721
weight gain-related, 77
wheelchair seating management of, 228
- of minor toes, 787–788
- of peroneal tendon, planovalgus-related, 750
- of plantar flexor muscles, 726*f*
- of pronator, release or transfer treatment of, 873–874*f*
- of pronator quadratus, 401
myotomy treatment of, 408
- of pronator teres, 401

- of rectus muscles, 330, 685, 689
 recurrent, after hamstring lengthening, 678
 of shoulder, 108, 394–397
 extension and external rotation
 abduction, 395, 397
 internal rotation, 395, 396, 396*f*
 natural history of, 395, 395*f*
 treatment of, 396–397, 396*f*
 of soleus muscle
 Achilles' tendon lengthening treatment of, 713–714, 1003–1004, 1003–1004*f*
 differentiated from gastrocnemius contractures, 708–709, 709*f*, 710
 effect on gait, 319, 320
 as subtalar joint collapse cause, 742
 thumb adductor, 389
 extensor pollicis longus rerouting
 treatment of, 887–890, 888–890*f*
 of tibialis anterior
 planovalgus-related, 750
 treatment of, 1012–1014, 1013*f*
 of tibialis posterior, hemiplegic varus
 foot position associated with, 729
 upper-extremity, 387, 388*t*
 during middle childhood, 391
 physical examination of, 388, 389*f*
 splinting of, 832–834
 of wrist, 108
 wrist extension, 410–418
 finger flexion contractures associated with, 410, 412
 treatment of, 410–418
 wrist flexion, 182, 396, 396*f*
 finger flexion contractures associated with, 424, 425
 orthoses treatment of, 182–184
 severity classification of, 409
 surgical treatment of, 396, 396*f*, 410–414, 411*f*, 412*f*, 413–414*f*
 treatment of, 396, 396*f*
 treatment-related complications of, 415, 418
 Copper metabolism disorders, 37*t*
 Cornelia-DeLang syndrome, 831
 Coronal plane deformity, of the hip, 331–333
 Coxa valga, 607–616. *See also* Femoral anteversion
 apparent, 608, 611
 definition of, 608, 611
 etiology of, 619–620, 621, 622
 Craniosacral therapy, 176–177
 Crankshaft, 452, 488–489
 Crawford Small Parts, 840
 Crouched gait, 77, 667
 during adolescence and young adulthood, 362–371
 treatment of, 363–370
 causes of, 687*t*
 definition of, 362–363
 diagnostic studies of, 687, 689
 diplegia-related, 360–361, 711
 foot deformity-related, 309
 foot moment arm in, 317–318
 hamstring contractures-related, 671, 673
 as hinged ankle-foot orthoses contra-indication, 192–193
 knee flexion contracture-related, 682
 during middle childhood, 360–361
 midstance knee extension in, 323, 324–325, 324–325*f*
 midstance knee flexion in, 684
 muscle-strengthening exercise treatment of, 158
 patella alta associated with, 690–692, 692*f*
 planovalgus-related, 749
 Crutches, 235, 237–239, 240*f*, 820–821
 for ataxia patients, 139
 Crutch holders, on wheelchairs, 222
 Cuneiform, opening wedge osteotomy of, 771, 773*f*
 Cuneiform-metatarsal joint excision, 992
 Cuneonavicular joint
 medial, 770*f*
 medial column collapse at, 768
 in planovalgus deformity, 748–749
 supination deformity at, 770
 Cutaneous reflexes, 41
 Cyanosis, in feet, 789, 789*f*
 Cyclobenzapine, as spasticity treatment, 109*t*
 Cyproheptadine, as spasticity treatment, 110
 Cystathionine beta-synthase deficiency, 36*t*
 Cysts, pencephalic, 32
 Cytomegalovirus infections, 38
D
 Dance, as therapy, 175
 Dantrolene, as spasticity treatment, 109*t*, 119–120, 853
 Darvaset, 88
 Data reduction algorithms, in kinematic evaluations, 277–279, 278*f*
 Death, spinal surgery-related, 465–466, 467
 Denervation, therapeutic. *See also* Neurectomy
 botulinum toxin-related, 121
 as dystonia treatment, 119, 119*f*
 Dental care, 57
 Dental examination, for pain evaluation, 69
 Dental infections, 69
 Depakote, 87*t*, 88–89
 Desmopressin acetate, 471
 Development, normal, deviation from, 44–47, 45*t*, 46*f*
 Developmental hip dysplasia (DHD), 528
 arthrography in, 533
 as hip dislocation cause, 576, 576*f*, 631, 634
 valgus repositioning osteotomy
 treatment of, 576, 576*f*
 Developmental milestones, 44, 45*t*
 abnormalities in, 44, 45*t*, 47
 Dexedrine. *See* D-Amphetamine
 Diapers, 241
 Diazepam, 84*t*
 as athetosis treatment, 133
 half-life of, 87–88, 87*t*
 as hypoxia cause, 81
 postoperative administration of, 81
 as pain treatment, 82, 83*t*
 as sleep disorder treatment, 85
 as spasticity treatment, 82, 87–88
 side effects of, 81, 88
 as spasticity treatment, 82, 87–88, 109–110, 109*t*, 125, 853
 Dicarbamate, as seizure treatment, 84*t*
 Diet, ketogenic, for seizure control, 89
 Diet history, in spinal surgery patients, 468
 Dilantin, as gingival hyperplasia cause, 57
 Diphenhydramine, as dystonia treatment, 129
 Diplegia, 388
 ambulatory, lordosis associated with, 457, 459
 definition of, 40
 diagnosis of, 27–28
 Duchenne's muscular dystrophy-related, 27–28
 equinovarus foot deformity associated with, 725, 727–728*f*, 743
 gait abnormalities associated with, 352, 354–371
 crouched gait, 360–371
 knee recurvatum, 361–362
 during middle childhood, 360–362
 toe walking, 352, 354–360, 357*f*, 358*f*, 712, 712*f*
 hemiplegia associated with, 40
 initiation of standing in, 743
 patient management in, 78–87
 outpatient management, 78
 surgical management, 78–87, 80*f*, 83*t*, 84*t*, 86*f*, 86*t*
 planovalgus collapse associated with, 710
 planovalgus foot deformity associated with, 725, 727–728*f*, 730, 730*f*
 prevalence of, 39
 scoliosis associated with, 499

- Diplegia (*continued*)
 varus foot deformity associated with complications of treatment of, 741
 treatment of, 736, 737–739, 737–739*f*, 740, 741*f*
- Disability, definition and classification of, 39, 40, 40*t*
- Disease, concurrent with cerebral palsy, 77–78, 78*t*
- Diseases of the Nervous System in Childhood* (Aicardi), 33
- Divalproex, 83, 84*t*
- Doman-Delacato technique, 156
- Dopamine receptor-blocking drugs, as dystonia treatment, 129
- Double bump pelvic motion, 340, 341
- Down syndrome, 31
 connective tissue laxity associated with, 126
 hip dislocations associated with, 632–633, 632–633*f*, 635
 hypotonia associated with, 126
 sensory integration treatment in, 155
- Drooling, athetosis-related, 133
- Dual-energy X-ray absorptiometry (DXA), 66–68
- Duchenne's muscular dystrophy, 27–28
- Duodenal obstruction, 486
- Duodenal ulcers, in spinal surgery patients, 468
- Durable medical equipment. *See also* Orthotics; Wheelchairs
 definition of, 181
 floor positioning devices, 232–235, 234*f*
 parapodiums, 233, 235
 prone standers, 56, 233, 819, 819*f*
 standers, 232–233, 234*f*
 supine standers, 56, 127, 233, 234*f*
 lifts, 240–241
 prescriptions for, 181
 tax deductions for, 241
 walking aids, 235–239
 for ataxia patients, 139
 canes, 239, 820–821
 for crouched gait patients, 363, 364–366, 364–366*f*
 crutches, 235, 237–239, 240*f*, 820–821
 gait trainers, 237, 238–239*f*, 240*f*, 820
 walkers, 235–236, 235*f*, 236*f*, 237*f*
- Dural leaks, spinal surgery-related, 473
- Dwyer instrumentation
 as pelvic obliquity cause, 497, 498*f*
 as scoliosis treatment, 443
- Dynamic Systems Theory, 100–102, 101*f*, 103, 805
 applied to early childhood physical therapy, 161
 applied to foot deformities, 723
 in Neurodevelopmental Therapy, 805
- Dynamometers, 840
- Dysplasia
 acetabular
 after hip subluxation surgery, 538
 hypotonic hip disease-related, 627, 628, 628*f*
 osteotomy treatment for, 551, 556
 planovalgus-related, 745–746
 spastic hip disease-related, 746
 as spastic hip subluxation cause, 524
 developmental hip, 631, 634
 hip dislocations associated with, 576, 576*f*, 634
- Dystonia, 127–132
 athetosis-related, 306
 cervical extensor posturing as, 505, 506
 closed head injury-related, 33
 definition of, 45, 127–128
 differentiated from
 athetosis, 133
 spasticity, 45, 104, 128–129, 394
 etiology of, 32
 as foot deformity cause, 130–131
 gait disorders associated with, 374
 generalized, 127–128, 129, 131–132
 localized, 127–128, 129, 132
 secondary effects of, 128–129
 shoulder instability associated with, 399
 spasticity associated with, 128
 treatment of, 129–132
 with botulinum toxin injections, 129–130, 132
 with upper-extremity surgical denervation, 119, 119*f*
 volitionally-controlled, 128
- E**
- Early childhood
 occupational therapy during, 165
 physical therapy during, 160–161
 planovalgus during, 743, 744–745*f*
 upper-extremity functional development during, 391
- Ectoderm, 29*f*
- Education, of children with disabilities, 168–169
 least restrictive environment in, 171
- Educational system, as care support provider, 5, 5*f*, 6
- Education for All Handicapped Children Act, 168
- Eggers procedure, 678
- Elastic wraps, 189
- Elbow
 radial head dislocation in, 400–401
 natural history of, 400–401
 treatment of, 401, 402–405*f*
 splinting of, 833–834, 833*f*
- Elbow contractures, 108
 flexion contractures, 399–400, 831
 natural history of, 399
 orthoses treatment of, 182, 183
 splinting treatment of, 399
 surgical release treatment of, 393, 396*f*, 399–400, 871, 872*f*
 splinting of, 399, 833*t*
- Elbow flexor release
 as elbow flexion contracture treatment, 393, 396*f*, 399–400, 871, 872*f*
 as radial head dislocation treatment, 401
- Elbow orthoses, 183, 184*f*
- Electrical stimulation therapy, 157–158, 809–810
 for ankle equinus, 716
 for athetosis, 133
 contraindication as scoliosis treatment, 442
 neuromuscular electrical stimulation (NES), 157, 809–810
 as spasticity treatment, 117–118
 transcutaneous electrical nerve stimulation (TENS), 157–158, 809
- Electrocautery, 471
- Electroencephalographic evaluation, of seizures, 69
- Electromyography (EMG)
 for equinovarus foot deformity evaluation, 726
 in gait analysis, 281, 282*t*
 for hamstring contracture evaluation, 676
 prior to muscle transfer, 392
 for rectus muscle activity evaluation, 685
 for spasticity evaluation, 105
 for thumb adductor evaluation, 418
 for varus foot deformity evaluation, 732–733, 736
 for wrist flexion evaluation, 409
- Embolism, pulmonary, postoperative, 654, 656
- Emula cream, 121
- Encephalocele, anterior or posterior, 28
- Encephalomalacia, multicystic, 32
- Encephalopathy
 hypoxic-ischemic, 31–32
 metabolic, 32, 33
- Endoderm, 29*f*
- Endotracheal intubation, postoperative, in spinal fusion patients, 450, 484
- Endotracheal tubes, movement or dislodgment of, 468
- Enforced-use therapy, 158–159
- Epidural analgesia/anesthesia, postoperative, 81, 82
 effect on neurovascular monitoring, 83

- Epidural space, intraoperative opening of
 as blood loss cause, 471–472
 as dural leak cause, 473
- Epiphysiodesis, ankle screw, 979, 979f
- Equilibrium reactions, 46f
- Equinovarus, 108, 723–733
 cavus associated with, 776, 777
 diagnostic evaluation of, 726–727
 diplegia-related, 743
 foot orthoses treatment of, 197
 hemiplegic gait-related, 346–347
 natural history of, 725, 727
 secondary pathology of, 724
 tertiary changes in, 724, 725, 725f,
 762–763, 762–763f
 tibial torsion-associated, 703
 treatment of, 727, 729–733
- Equinus
 contractures associated with, 523
 shortened gastrocnemius associated
 with, 322f
 hemiplegic gait-related, 345–346
 treatment of, as external foot rotation
 cause, 318, 318f
- Erectile dysfunction, baclofen-related,
 114
- Esophagitis, 71
- Ethosuximide, 84t
- Euler angles, 277–278, 278f
- Excitogenic injury, as synaptic remodeling
 cause, 31
- Extensor hallucis longus, as tibialis
 anterior substitute, 784
- Extensor indicis transfer, as type 2 thumb
 deformity treatment, 420
- Extensor pollicis longus, rerouting of,
 887–890, 888–890f
- Extensor posturing, at the cervical spine,
 505–506, 506f
- External fixators, as severe knee flexion
 contracture treatment, 683
- Extubation, postoperative, 483–484
- Eye, neurologic development of, 153
- F**
- Fabry's disease, 34t
- Facetectomy, as intraoperative blood loss
 cause, 471, 472
- Falls
 in ataxia patients, 139, 140
 protective response to, 138–139, 304
- Family, of cerebral palsy patients. *See*
 Parents, of cerebral palsy patients
- Fascia latae, 683–684
 contractures of, 330
- Fazano technique, of laminectomy, 115,
 115f, 453, 453f, 499
- Feeding. *See also* Nutrition
 during postoperative period, 84–85,
 485
- Feeding clinics, occupational therapists'
 role in, 166
- Feeding seats, 230, 230f
- Felbamate, 84t
- Feldenkrais, Moshi, 177
- Feldenkrais therapy, 176, 177
- Femoral anteversion, 524. *See also*
 Coxa vara
 at birth, 616
 definition of, 611
 etiology of, 616, 618–619
 in hip subluxation, 527, 532
 measurement of, 611–616
 with computed tomography,
 612–613, 613f, 615–616,
 617–618f
 with fluoroscopy, 615, 616
 with magnetic resonance imaging,
 615–616
 with radiography, 612
 with ultrasound, 532, 613–615,
 614f, 616
 natural history of, 622–623
 physical examination of, 611–612,
 612f
 recurrence of, 622–623
 tibial torsion associated with, 700, 703
 torsional malalignment associated
 with, 311
 treatment of, 623–626
 with muscle lengthening, 602–603
- Femoral condyles, knee flexion
 contracture-related flattening of,
 671, 672–673, 672f, 682
- Femoral derotation
 with an intramedullary nail, 949–952,
 950–951f
 avascular necrosis associated with,
 655, 655f
 proximal, 624
- Femoral distal metaphysis, fractures of
 low-energy, 59–60, 67, 67f
 postoperative, 653–654, 653f
- Femoral epiphysis, eccentric ossification
 of, 528
- Femoral head
 bone mineral density of, 57
 in hip subluxation, 524, 525, 527f,
 528, 529f, 532
 in reconstructive treatment, 547–548
 resection of (Girdlestone procedure),
 571, 571f, 574
- Femoral neck fractures
 occult fractures, 533
 stretching exercises-related, 62, 65, 65f
- Femoral neck shaft angle. *See also*
 Coxa valga
 in hip subluxation, 525
 proximal femoral epiphysis in, 620,
 622, 622f
- Femoral neck valgus, 524
 determination of, 525, 527, 527f
 in hip dislocation, 525, 527, 527f, 529f
- Femoral rotation, with hip extension,
 measurement of, 311
- Femoral shaft, low-energy fractures of,
 60, 61, 64
- Femur
 fractures of
 distal, hip subluxation surgery-
 related, 545
 distal metaphyseal, 59–60, 67, 67f,
 653–654, 653f
 femoral osteotomy-related,
 639–640, 640f
 during hip rehabilitation, 566
 knee extension, 679
 low-energy, 59–61, 60f, 61f
 low-energy distal metaphyseal,
 59–60, 67, 67f, 790
 postoperative, 545, 653–654, 653f
 internal torsion of. *See* Femoral
 anteversion
 torsional malalignment of, 108
- Fever, postoperative, 484, 490–491
- Fibula, in planovalgus deformity, 748
- Fingers. *See also* Thumb
 contractures of, 389f
 deformities of, surgical treatment of,
 833t
 extension of
 inadequate, 425
 patterns of, 393
 flexion contractures of, 410, 412,
 424–426
 physical examination of, 388–389
 swan neck deformity of, 426–427
 tight flexion of, 831
- First ray
 depression of, 769f
 elevation of, 724, 769f
 medial column correction of,
 992–998, 992–998f
 in midfoot supination, 770, 771
 relationship with dorsal bunions,
 775
- Flexibility assessment, spinal, 52–53,
 52f, 53f
- Flexor carpi radialis lengthening, as wrist
 extension contracture treatment,
 410, 412, 415
- Flexor carpi ulnaris transfer, to extensor
 carpi radialis brevis (Green trans-
 fer), 410–411, 411f, 412,
 414–415, 831–832, 844
- failure of, 418
 operative procedure in, 874–880,
 875–879f
- Flexor digitorum profundus, contractures
 of, 424

- Flexor digitorum profundus lengthening, as finger flexion contracture treatment, 425
- Flexor digitorum sublimus, contractures of, 424
- Flexor digitorum superficialis lengthening, as finger flexion contracture treatment, 425
- Flexor hallucis, tenotomy of, 775
- Flexor hallucis longus, Jones' transfer of, 787
- Flexor hallucis longus lengthening, as claw toe treatment, 787–788
- Flexor pollicis brevis, spasticity of, 418
- Flexor pollicis longus, spasticity of, 418
- Flexor pronator slide, as finger flexion contracture treatment, 425
- Flexor superficialis, tenodesis of, as swan neck deformity treatment, 426, 427
- Floor mobility, postoperative decrease in, 489–490
- Floor positioning devices, 232–235. *See also* Standers
- Fluoroscopy, for femoral anteversion measurement, 615, 616
- Folate acid, as neural tube defect prophylaxis, 28
- Folate metabolism defect, 36*t*
- Foot. *See also* Ankle; Forefoot; Hindfoot; Midfoot; Toe deformities
- cold and discolored, 75–76, 75*f*, 789, 789*f*
- deformities of, 108
- diagnostic and treatment algorithm for, 794–796*t*
- dystonic, 130–131, 132
- recurrent, 790
- secondary adaptations to, 309
- wheelchair seating management of, 228
- effect of torsional malalignment on, 311, 314, 315–317, 315–317*f*
- external rotation of, planovalgus deformity-associated, 314, 317
- in gait abnormalities, 309–318, 319–322, 338*f*
- low-energy fractures of, 63–64
- moment arm at, 311
- in crouched gait, 317–318
- effect of torsional malalignment on, 311, 314, 315–317, 315–317*f*
- in knee flexion, 322–323
- in normal gait, 667
- as moment arm for ground reaction force, 311, 314
- primary function of, 309
- as stable, stiff segment, 309
- stability mechanisms of, 769*f*
- temperature instability in, 75–76, 75*f*, 789, 789*f*
- unstable, 309
- treatment of, 311
- Foot and ankle procedures, 979–1023
- Achilles tendon lengthening, 1003–1004, 1003–1004*f*
- ankle epiphysiodesis screw, 979, 979*f*
- bunion correction, 1014–1020, 1014–1020*f*
- clawed toes correction, 1020, 1021*f*
- complications of, 789–792
- gastrocnemius lengthening, 999–1003, 1000–1002*f*
- lateral column lengthening through the calcaneocuboid joint, 989–991, 990–991*f*
- through the calcaneus, 985–989, 985–989*f*
- medial border great toenail resection, 1022–1023, 1022–1023*f*
- medial column correction, 992–998, 992–998*f*
- split tibialis anterior transfer, 1010–1012, 1010–1012*f*
- subtalar fusion, 753, 756–757*f*, 756–758, 764, 979–985
- as calcaneal valgus treatment, 777
- complications of, 766, 768*f*
- indication for, 979
- with internal fixation, 766
- operative procedure in, 980–984*f*, 980–985
- as planovalgus treatment, 730*f*, 771, 772–773*f*
- postoperative care in, 985
- in triple arthrodesis, 998–999, 999*f*
- tibialis anterior lengthening, 1012–1014, 1013*f*
- tibialis posterior lengthening or split transfer, 1004–1010, 1005–1010*f*
- triple arthrodesis, 998–999, 999*f*
- Foot orthoses, 197–200, 199–201*f*
- for hypotonic management, 127
- intramalleolar, 198, 200*f*
- prescriptions for, 245–247*f*
- supramalleolar, 198, 200*f*, 727
- Foot placement response, 42–43, 43*f*
- Foot progression angle
- malrotation of, 311–318
- in tibial torsion, 699–700
- Foot surgery. *See* Foot and ankle procedures
- Foot varus, 309
- Force plate, 279–280, 279*f*, 282
- Forearm
- pronation contractures of, 183, 401
- natural history of, 406
- treatment of, 407–408
- supination of, forearm pronation treatment-related, 408
- Forearm ruler, 56, 57*f*
- Forefoot
- abduction of, 769*f*
- adduction of, cavovarus-associated, 776
- deformities of, 667–668, 779
- in planovalgus, 750
- supination of, 766, 768–771
- outcome of treatment of, 775–776
- treatment of, 770–774, 772–773*f*, 775–776*f*, 992–998, 992–998*f*
- valgus of, 769*f*
- varus of, 724, 769*f*
- differentiated from hindfoot varus, 729*f*
- tibialis anterior transfer treatment of, 1010
- Fractures
- acetabular, 70, 70*f*
- femoral
- distal, hip subluxation surgery-related, 545
- distal metaphyseal, 59–60, 67, 67*f*, 653–654, 653*f*
- femoral osteotomy-related, 639–630, 640*f*
- during hip rehabilitation, 566
- knee extension, 679
- low-energy, 59–61, 60*f*, 61*f*
- low-energy distal metaphyseal, 59–60, 67, 67*f*, 790
- postoperative, 639–640, 640*f*, 653–654, 653*f*
- of lateral metatarsals, 724
- low-energy, 58, 59–66, 790
- diagnosis in noncommunicative children, 59–63, 60*f*, 61*f*, 62*f*, 63*f*
- diagnosis of, 790
- prevention of, 66–68
- as repeated fractures, 64, 67, 67*f*
- rolled cotton dressing for, 63, 66*f*
- treatment of, 63–64, 66, 66*f*
- untreated, 59, 60, 60*f*
- occult, 69
- radial, as forearm pronator treatment complication, 408
- stress
- of metatarsals, 726*f*
- of patella, 62, 687, 688, 688*f*
- tibial
- during hip rehabilitation, 566
- subtalar fusion-related, 766
- trochanteric, femoral osteotomy-related, 640–642, 641–642*f*
- Fragile X syndrome, 31
- Fresh-frozen plasma transfusions, 471
- Fucosidosis, 35*t*

- Functional ability, scoring scales of, 834–836, 835*t*, 836*t*
- Functional electrical stimulation (FES), 157
- Functional mobility, M.O.V.E.^(TM) (Mobility Opportunities Via Education) curriculum in, 828–831, 830*f*
 contraindications to, 829
- Fundoplication, 73
- Fuzzy logic, 100
- G**
- Gabapentin, 84*t*
- Gait, 251–386
 basic science of, 251–252
 biomechanics of, 252–253, 253*f*
 bone mechanics of, 266
 feedback control of, 46*f*
 feed-forward control of, 46*f*
 global body mechanics of, 269–285
 balance subsystem, 270
 cognitive subsystem, 269–270
 energy production, 270–271
 motor control, 271
 structural stability, 271–272
 joint mechanics of, 266–269
 joint motor mechanics, 267–268, 267*f*
 in multiple-joint muscles, 268–269
 in single-joint muscles, 268
 muscle anatomy of, 257, 258*f*
 muscle length-tension relationship (Blix Curve) in, 257–259, 259*f*
 muscle mechanics of, 254–257
 alterations in, 259–266
 connective tissue mechanics, 263–264, 264*f*
 energy production, 254–256, 254*f*, 255*f*
 force production, 256, 256*f*
 increasing excursion, 262–263
 muscle control alterations, 259–260
 muscle excursion, 261–262
 muscle fiber types in, 257
 muscle force-generating capacity, 260–261
 muscle-tendon unit growth, 264–266
 normal, 288–303
 ankle in, 293–295, 294*f*
 cycle functions in, 302–303
 foot segment in, 295
 gait cycle of, 288–289, 290–291*f*
 HAT body segments in, 290–293, 292*f*, 293*f*, 295, 302, 303
 hip in, 296, 299*f*, 301, 302–303
 joint functions in, 300–301
 knee in, 295–296, 296*f*, 297*f*, 301, 302–303
 locomotor body segments in, 290, 291–292
 pelvis in, 298–300, 301, 301*f*
 stance phase of, 289–290, 291*f*
 swing phase of, 290, 291*f*
- Gait abnormalities
 ankle in, 319–322
 ataxia-related, 139
 athetosis-related, 306, 307, 373–374
 balance deficiencies-related, 304–305
 complications of treatment of, 374–378
 gait analysis-related, 375
 multiple procedures-related, 76–377
 rehabilitation-related, 377
 surgery planning-related, 375–376
 surgical execution-related, 377
- diplegia-related, 352, 354–371
 crouched gait, 360–361
 knee recurvatum, 361–362
 during middle childhood, 360–362
 toe walking, 352, 354–360, 357*f*, 358*f*, 712, 712*f*
- foot in, 309–318
- hemiplegia-related, 343–352
 tendon lengthening treatment of, 345–347
 type 1 gait pattern, 344, 344*f*
 type 2 gait pattern, 345
 type 3 gait pattern, 347–350, 348, 348*f*
 type 4 gait pattern, 350–351
- knee in, 322–329, 338*t*, 350
 as stiff gait, 326–328, 350, 684–685
- motor control deficiencies-related, 305–307
- motor power deficiencies-related, 307–308
- movement-disordered gait, 373–374, 374
- neurologic basis of, 45
- quadriplegia-related, 371–373
- spasticity-related, 108, 125
- treatment of
 algorithm for, 379–382*t*
 “birthday syndrome” approach in, 342–343
 energy use measurement evaluation of, 378
 monitoring the outcome of, 377–378
- Gait analysis
 applications of, 287–288
 in ataxia, 138
 complications of, 375
 electromyography in, 281, 282*t*
 gait impairment diagnosis in, 285–287
 kinematic evaluations in, 276–279
 accuracy of, 279
 data reduction algorithms in, 277–279, 278*f*
 optical measurements in, 276–277, 277*f*
 kinetic evaluations in, 279–281, 279*f*, 280*f*
 measurement techniques in, 272
 oxygen consumption measurement in, 282–285, 284*f*
 patient history in, 272, 273*t*, 286
 pedobarograph use in, 282, 283*f*
 physical examination in, 272–275, 285
 global function measures in, 272–273, 274*t*
 motor control assessment in, 273, 274*t*
 muscle strength assessment in, 275
 muscle tone assessment in, 275, 275*t*
 passive range-of-motion assessment in, 275
 videotaping in, 276, 276*f*, 286
- Gait Analysis, Normal and Pathological Function* (Perry), 288
- Gait analysis laboratories, as physical therapy setting, 164
- Gait trainers, 237, 238–239*f*, 240*f*, 820
 for quadriplegic patients, 371
 in M.O.V.E.^(TM) (Mobility Opportunities Via Education) curriculum, 830, 831*f*
- Gait training, with pool walking, 813*f*
- β -Galactocerebrosidase deficiency, 34*t*
- Galactosialdosis, 35*t*
- β -Galactosidase deficiency, 34*t*
- Galveston technique, in spinal instrumentation, 443
- Gamma-aminobutyric acid, 852
- Gamma-aminobutyric acid receptor blockers, 109
- Gangliosidoses, 34*t*
- Gastric ulcers, 73, 468
 in spinal surgery patients, 468
- Gastritis, 72, 468
- Gastrocnemius
 contractures of
 ankle equinus-associated, 708–709, 709*f*, 710, 711
 differentiated from soleus contractures, 708–709, 709*f*, 710
 effect on gait, 319, 320
 hemiplegia-associated, 731
 planovalgus-associated, 727, 750
 as subtalar joint collapse cause, 742
 treatment of, 713–714, 714*f*
 equinus surgery-related insufficiency of, 719
 in knee flexion contractures, 669, 669*f*
 measurement of, 711
 neurectomy of, as ankle equinus treatment, 118, 715
 in normal gait, 294–295
 premature contraction of, 319, 320

- Gastrocnemius (*continued*)
 proximal, tenotomy of, 714–715, 715f
 spastic, botulinum toxin injection
 treatment of, 121, 121f
- Gastrocnemius lengthening, 999–1003,
 1000–1002f
 as ankle dorsiflexion treatment, 359
 as ankle equinus treatment, 713–714,
 714f
 complications of, 717
 repeat, 717
 in ataxia patients, 139
 complications of, 717, 791
 as hemiplegic gait type 2 treatment,
 345, 346, 346f
 implication for cavus treatment, 777
 as premature gastrocnemius contrac-
 tion treatment, 319, 320
- Gastrosoleus, 724
- Gastroesophageal reflux
 oral bisphosphonates-related, 68
 postoperative, 78–79, 469
 preoperative, 79, 468, 469, 485
- Gastrointestinal pain, hip pain-associated,
 71–73
- Gastrostomy tube feedings, thora-
 colubar sacral orthosis use and,
 186–187
- Gaucher's disease, 34t
- Gelfoam, 471, 472, 473
- Gemellus muscle, contractures of, 619
- Genitourinary disorders, 74–75
- Gillette Functional Assessment Question-
 naire, 378
- Gingivitis, 57
- Girdleston resection, revision of, 571,
 571f, 574
- Global Motor Function Measure
 (GMFM), 274t
- Gluteus maximus
 contractures of, windblown hip
 deformity-related, 603
 as external rotator muscle, 619
- Gluteus medius, as internal rotator
 muscle, 619f
- Gluteus medius transfer, as femoral
 anteversion treatment, 626
- Gluteus minimus, as internal rotator
 muscle, 619f
- Glycine, as spasticity treatment, 110
- Glycoprotein metabolism deficiency, 34t
- GM1 gangliosidosis, 34t
- Goniometers, 671
- Gordon's finger sign, 839t
- Gracilis, in knee flexion contractures,
 668–669
- Grand mal seizures, Unit rod resistance
 to, 468
- Grasp reflexes, 41, 41f. *See also* Hand
 grasp; Toe grasp reflex; Toe grip
- Greater trochanter, femoral osteotomy-
 related fractures of, 640–642,
 641–642f
- Great toe
 extended, 784–788
 hallux valgus of, as bunion cause,
 779–784
 medial border toenail resection in,
 1022–1023, 1022–1023f
- Green's Scale, 834
- Green transfer, 410–411, 411f, 414–415,
 831–832, 844
 failure of, 418
 operative procedure in, 874–880,
 875–879f
- Groin incisions, antibiotic prophylaxis
 for, 80
- Grood-Suntay technique, of kinematic
 evaluation, 278
- Gross Motor Function Measure
 (GMFM), 138, 273, 378, 808,
 809
- Ground reaction force
 foot as moment arm for, 311, 314
 measurement of, 279–280, 279f, 280f
- Growth hormone, abnormal regulation
 of, 76
 as bone mass loss cause, 58
- Growth measurement, 56–57, 57f
- Guardianship, 171–173
- H**
- Hair loss, postoperative, 486, 487f
- Halliwick Method, of aquatic therapy,
 815
- Hallux, extended, 784–788
- Hallux valgus, as bunion cause, 779–784
- Halo, pelvic leg, spinal instrumentation-
 related, 487, 488f
- Hamstring contractures, 331
 in athetosis patients, 133
 botulinum toxin injection treatment
 of, 674
 as crouched gait risk factor, 671, 673
 electromyographic evaluation of, 676
 hamstring lengthening treatment of,
 674–676, 675f, 675t
 complications of, 340, 340f,
 678–679
 contracture recurrence rate in, 678
 outcome of, 677–678, 677f, 678f
 postoperative management of,
 676–677
 procedure in, 676
 proximal, 677, 679
 variations of, 678
- hemiplegia gait type 3-related,
 347–350, 348, 348f
- hip hyperabduction-related, 596
 as hip subluxation treatment, 674
- as knee flexion contracture cause,
 668–679
 as kyphosis cause, 227, 227f
 night splinting treatment of, 190, 674,
 674f, 676
 passive stretching exercise treatment
 of, 673
 popliteal angle measurement of, 671,
 673, 673f
 as quadriplegic gait cause, 372–373
 as thoracic kyphosis cause, 452, 452f,
 453
 treatment of, 673–679
 wheelchair seating management of,
 228
- Hamstring lengthening, 955–956, 956f,
 957f
 in athetosis patients, 133
 as diminished knee extension treat-
 ment, 327–328
 as hamstring contracture treatment,
 682–683
 complications of, 678–679
 contracture recurrence rate in, 678
 outcome of, 677–678, 677f, 678
 postoperative management of,
 676–677
 procedure, 676
 proximal, 677, 679
 variations of, 678
 as hyperlordosis cause, 340, 340f
 indications for, 674, 675t, 676
 knee extension orthotic use after, 190
 postoperative care in, 957
 proximal, with adductor and iliopsoas
 lengthening, 913–918, 914–917f
- Hamstrings
 effect on knee flexion and extension,
 326f, 327–328
 length measurement of, 671, 673,
 673f
 in spastic hip subluxation, 524, 525
 spasticity of, as kyphosis cause, 227f
- Hand. *See also* Fingers; Thumb
 functional evaluation of, 388–390,
 390f, 834–836
 spastic deformity patterns of, 393, 394
- Hand and wrist orthoses, 183–184, 184f
- Hand grasp
 developmental stages of, 836, 837f
 efficient, 841f
 evaluation of, 840, 841–844f
 forced, 839t
 inefficient, 842–844f
 patterns of, 393
- Hand grasp/release, photographic evalua-
 tion of, 848
- Hand grip reflex, 41f
- Handicaps, definition and classification
 of, 39, 40, 40t

- Hand orthoses, 183
 resting splints, 184–185, 185*f*
 swan neck splints, 185–186, 186*f*
 thumb splints, 185, 186*f*
- Handwriting aids, 391
- Harrington rod instrumentation, 500
 as pelvic obliquity cause, 497, 498*f*
 as scoliosis treatment, 443
- HAT body segments
 definition of, 290–291
 in hip lurch, 341, 341*f*
 in normal gait, 292–293, 292*f*, 293*f*,
 295, 298, 299, 301, 302, 303,
 342, 342*f*
- Head, inability to hold up, 507, 508*f*
- Head trauma. *See also* Brain injury
 ataxia-related, 139
 as cerebral palsy cause, 32–33, 33*f*
- Heart block, as amitriptyline contra-
 indication, 87*f*
- Heel rise, premature, 77, 731, 732*f*
- Heel varus, 724
 fixed, 733, 734–735*f*
- Heel whip, 335
- Height measurement, 56
- Hematoma, proximal hamstring
 lengthening-related, 679
- Hemiplegia, 388
 Achilles' tendon lengthening in, 1003
 back-kneeing associated with, 711
 definition of, 40, 343
 diplegia associated with, 40
 double, 40
 elbow flexion contracture release in,
 400
 enforced-use therapy for, 158–159
 equinovarus foot deformity associated
 with, 723, 724, 725
 forearm pronation contractures associ-
 ated with, 401, 407*f*
 functional deformities associated with,
 387
 functional finger development in, 387
 gait abnormalities associated with
 tendon lengthening treatment of,
 345–347
 in type 1 hemiplegia, 344, 344*f*,
 355*f*
 in type 2 hemiplegia, 345, 355*f*
 in type 3 hemiplegia, 347–350, 348,
 348*f*, 355*f*
 in type 4 hemiplegia, 350–351, 355*f*
 gastrocnemius and soleus contraction
 patterns in, 710
 gastrocnemius contractures associated
 with, 711
 patient management in, 78–87
 outpatient management, 78
 surgical management, 78–87, 80*f*,
 83*t*, 84*t*, 86*f*, 86*t*
- planovalgus foot deformity associated
 with, 731, 731*f*
 prevalence of, 39
 scoliosis associated with, 499
 soleus contractures associated with,
 711
 thumb abduction associated with, 185
 toe walking associated with, 309,
 310–311*f*
 uninvolved body side in, 393
 varus collapse associated with, 710
 varus foot deformity associated with,
 729, 731, 732*f*
 tibialis posterior transfer treatment
 of, 736
- Hemoglobin levels
 intraoperative, 471
 postoperative, 482–483
- Hemorrhage
 cerebral
 as cerebral palsy cause, 31
 germinal matrix, 31, 32*f*
 intraventricular, 28, 31, 32*f*
 periventricular-intraventricular,
 31, 32*f*
 in premature infants, 28
 intraoperative, in spinal surgery
 patients, 466, 469, 471–473
- Hemothorax, postoperative, 484*f*
- Herpes simplex infections, neonatal, 38
- Hilgenreiner's line, 532*f*
- Hindfoot
 in planovalgus, 750
 valgus deformity of, 743, 769*f*
 as bunion cause, 779
 diplegia-associated, 743
 varus deformity of, 724, 769*f*
 differentiated from forefoot varus,
 729*f*
 stiffness associated with, 741
- Hip
 dystonia at, 131
 in gait abnormalities, 329–335, 338*t*
 coronal plane deformity, 331–333
 sagittal plane in, 329–331
 transverse plane deformity,
 333–335, 335*f*, 347, 350, 351
 hypotonic, 523, 626–631
 etiology of, 627
 hip adduction angle in, 535
 natural history of, 627
 treatment of, 627–631, 629–631*f*
 spastic, 523–666
 anteversion, 607
 complications of, 635–657
 computer modeling studies of, 26*f*,
 524, 525
 developmental dysplasia in, 631, 634
 diagnostic evaluation of, 531–533,
 531*f*, 532*f*
 evaluation and treatment algorithm
 for, 657–661*t*
 hip dislocation prevention in,
 533–534
 hyperabduction deformity of, 523,
 594–596, 595*f*
 natural history of, 528–531, 529*f*
 pathomechanics of, 524–525, 526*f*
 posterosuperior hip subluxation,
 524–578
 windblown hip deformity, 523,
 600–607
 treatment of, 602–606
- Hip abduction, 108
 evaluation of, 53, 53*f*
 in gait abnormalities, 331, 332–333
 in hip subluxation, 531, 531*f*
- Hip abduction angle, in hip subluxation,
 534, 535
- Hip abduction orthoses, 188
 as windblown hip deformity cause,
 603, 606*f*
- Hip abductor contractures, 332
 abduction bracing-related, 188
 abductor lengthening treatment of,
 940–943, 941–943*f*
 after hip reconstructive surgery, 551
 external rotation, 183
- Hip abductor lengthening, 940–943,
 941–943*f*
- Hip adduction, 108, 331–332
 asymmetric pelvic rotation-associated,
 339–340
 as scissoring gait cause, 334*f*
- Hip adductor contractures, 331, 594,
 595, 595*f*, 596
 as hip subluxation cause, 527–528
 as leg-length discrepancy cause, 645
- Hip adductor lengthening
 complications of, 545–546
 hip abduction orthosis use prior to,
 188
 in hip reconstruction, 550, 551, 552
 as hip subluxation treatment,
 534–535*f*, 534–541, 536*f*, 552,
 554, 555*f*
 operative procedure in, 537
 outcome of, 537–541, 542, 542*f*
 with proximal hamstring lengthening,
 913–918, 914–917*f*
 as revision procedure, 952–953*f*,
 952–954
- Hip adductors
 in spastic hip disease, 524, 525
 in hip subluxation, 527–528
 wound infections of, 636
 hip reconstructive procedures-
 related, 560
- Hip dislocations, 108
 in adults, 530–531

- Hip dislocations (*continued*)
- anterior, 578–593
 - as anterior pelvic tilt cause, 512–513
 - clinical presentation of, 578–579
 - etiology of, 579
 - hypotonic hip disease-related, 627
 - as knee extension contracture cause, 579, 587
 - knee extension contracture-related, 685
 - misdiagnosed as posterolateral hip dislocation, 579, 589
 - natural history and treatment of, 579–583
 - Pemberton-type pelvic osteotomy treatment of, 936–940, 937–940f
 - posterior dislocation associated with, 590–591, 591f
 - recurrent, 592
 - type I, 452, 579–582, 580–582f, 583–584, 685
 - type II, 582–583, 583f, 584–588, 585–587f, 594
 - type III, 588–589f, 588–593, 590–593f
 - coxa valga-related, 620
 - as degenerative arthritis cause, 69, 71
 - developmental hip dysplasia-related, 576, 576f, 634
 - Down syndrome-associated, 632–633, 632–633f, 635
 - femoral anteversion associated with, 623
 - inferior, 593–594, 593f
 - as leg length discrepancy cause, 646
 - natural history of, 528–531, 529f
 - posterior, hypotonic hip disease-related, 627
 - posterolateral
 - anterior hip dislocation misdiagnosed as, 579, 589
 - clinical presentation of, 578
 - posterosuperior, 524, 607
 - preventive treatment of, 533–541
 - quadriplegia-related, prevention of, 54, 56
 - reconstructive treatment of, 547, 548f
 - recurrent, 644–645
 - repeat early, 562–563f
 - total hip replacement-related, 568, 569–570f
- Hip dysplasia, 523
- computed tomographic scans of, 531–532
 - developmental, 631, 634
 - hip dislocations associated with, 576, 576f, 634
 - spastic, 524
- Hip extension
- deficiency of, 330
 - evaluation of, 53, 54f
 - with hip abduction measurement, 531, 531f
 - with radiography, 531, 532f
 - with ultrasound, 532
- etiology of, 524–525
- secondary pathology of, 525, 527–528
 - tertiary pathology of, 528, 529f
- femoral anteversion associated with, 623
- femoral neck shaft angle in, 621, 621f
- hamstring lengthening treatment of, 674
- inferior, 593–594, 593f
- migration index in, as varus osteotomy indication, 551
- migration percentage in, 529f, 530, 531, 532f
- posteroperative, 537–539, 540–541, 540t
- natural history of
- during adolescence, 529f, 530
 - during adulthood, 530–531
 - during childhood, 528, 529f, 530
- pain associated with, 529f, 530–531
- palliative treatment of, 566–578
- complications of, 576, 578
 - with femoral head resection, 571, 571f, 574
 - with femoral valgus osteotomy, 574, 575, 575f
 - with Girdleston resection, 571, 571f, 574
- goals of, 566
- with hip fusion, 574, 577, 577f
 - with interposition arthroplasty, 569, 571–572, 571f, 572f, 575, 575f
 - with resection arthroplasty, 567–568f, 570–571, 573–574, 573f
 - with subtrochanteric valgus osteotomy, 574, 576, 576f
 - with total hip replacement, 568, 569–570f
 - with valgus osteotomy, 574, 576, 576f
- pathomechanics of, 524–525, 526f
- posterosuperior, 524–578
- preventive treatment of, 533–541
- with abduction orthosis, 544–545
 - with adductor lengthening, 534–535f, 534–541, 536f
 - with adductor transfer, 541
 - with botulinum toxin injections, 543–544
 - complications of, 545–546, 546f
 - with dorsal rhizotomy, 544
 - with iliopsoas transfer, 541
 - with intrathecal baclofen, 544
- progression rate of, 530
- Hip extension contractures, knee extension contracture-related, 685
- Hip extensors, weakness in, 329, 330f
- Hip flexion, evaluation of, 53, 54f
- Hip flexion contractures, 329, 596–599
- as anterior pelvic tilt cause, 512
 - assessment and measurement of, 597–598, 597f, 598f
 - diplegia-related, 360
 - etiology of, 598
 - natural history of, 598
 - recurrent, 644–645
 - treatment of, 598–599
- Hip flexors, weakness in, 330–331
- Hip fusion, palliative, 574, 577, 577f
- Hip guides, as walker attachments, 236
- Hip joint reaction force, 524–524, 526f
- Hip lurch, 341, 341f
- Hip orthoses, 188, 189f
- Hip pain
- arthritis-related, 69, 71
 - gastrointestinal pain associated with, 71–73
 - heterotopic ossification-related, 648–649f, 650
 - palliative treatment of, 72, 73, 73f
 - postoperative, 650–654, 651f, 652f, 653f
 - subluxation-related, 529f, 530–531
 - treatment of, 71, 72
- Hippotherapy (horseback riding), 123–124, 173–174, 810–811, 811t, 812f
- Hip rotation
- definition of, 333
 - evaluation of, 53, 53f
 - external rotation deformity, 334, 336–337f
 - internal rotation contractures, 333–334, 335, 335f, 607, 616, 618–619, 619f
 - elastic wrap-based control of, 189
 - natural history of, 622–623
 - as twister cable contraindication, 188–189
 - major role of, 329
 - in normal gait, 296, 298, 299f, 301, 302–303
 - postoperative stiffness of, 656
- Hip subluxation
- acetabulum in, 525, 527f, 529f, 534
 - computed tomographic scan of, 532
 - in reconstructive treatment, 547
 - coxa valga-related, 620
 - as degenerative arthritis cause, 69, 71
 - diagnostic evaluation of, 531–533
 - with arthrography, 533
 - with bone scans, 532–533
 - with computed tomography scans, 531–532

- reconstructive treatment of, 547–566
 complications of, 559–566
 failure of, 552–553*f*
 indications for, 547–548
 outcome of, 550–551
 as pain treatment, 549, 550*f*, 551
 with varus osteotomy, 551
 recurrent, 629–631, 629–631*f*
 treatment of, 533–578
 indications for, 534–535
- Hip surgical procedures, 913–954
 abductor lengthening, 940–943,
 941–943*f*
 adductor and iliopsoas lengthening
 with proximal hamstring lengthening, 913–918, 914–917*f*
 arthroplasty
 interposition, 946–949, 946–949*f*
 resection, 944–946, 944–946*f*
 complications of
 avascular necrosis, 654, 655, 655*f*
 degenerative arthritis, 565–566,
 565–566*f*, 652–653
 distal fixation fractures, 642–644,
 643–644*f*
 femoral osteotomy nonunion,
 637–639, 638*f*
 femoral osteotomy-related,
 637–645, 638*f*, 640–645*f*
 femoral shaft fractures, 645*f*
 femur fractures, 639–640, 640*f*
 heterotopic ossification, 646–650,
 648–649*f*, 650*f*
 hip joint stiffness, 656
 hip pain, 650–654, 651*f*, 652*f*,
 653*f*
 leg length discrepancy, 645–646
 pulmonary embolism, 654, 656
 recurrent contractures, dislocations,
 and subluxations, 629–631,
 629–631*f*, 644–645
 thrombophlebitis, 654, 656
 trochanteric fractures, 640–642,
 641–642*f*
 femoral derotation with an intra-
 medullary nail, 949–952,
 950–951*f*
 iliopsoas lengthening
 over the pelvic rim approach in,
 919–920, 919–920*f*
 with proximal hamstring lengthening,
 913–918, 914–917*f*
 Pemberton-type pelvic osteotomy,
 936–940, 937–904*f*
 peri-iliac pelvic osteotomy, 931–936,
 931–936*f*
 proximal femoral osteotomy, 920–930,
 921–930*f*
 revision adductor lengthening,
 952–953*f*, 952–954
 unilateral, as windblown hip deformity
 cause, 600
 Hoffmann's sign, 839, 839*t*
 Home-based physical therapy, 163
 Home modifications, 241
 Homeobox gene defects, 28
 Home social environment, 324–325
 Homocystinuria, 36*t*
 Hook and rod spinal instrumentation,
 as scoliosis treatment, 452
 Horseback riding, 123–124, 173–174,
 810–811, 811*t*, 812*f*
 House classification system, of spastic
 thumb deformities, 419–422
 H-reflex, 98, 98*f*, 106
 H-response, 105
 Human immunodeficiency virus (HIV)
 infection, 38
 Humeral metaphysis, proximal, low-
 energy fractures of, 59–60
 Humerus, proximal, low-energy fractures
 of, 61, 63, 63*f*
 Hunter's syndrome, 34*t*
 Hurler's syndrome, 34*t*
 Hydantoin, as seizure treatment, 84*t*
 Hydrocephalus, 28, 30
 Hydrotherapy, 174. *See also* Swimming
 Hyperabduction, 594–596, 595*f*
 postoperative, 546
 Hyperactivity, pharmacotherapy for,
 87*t*, 89
 Hyperalimentation, central venous,
 485–486
 Hyperbaric oxygen therapy, 176
 Hyperbilirubinemia, athetosis associated
 with, 132
 Hyperextension posturing, brain injury-
 related, 579
 Hyperextension reflex, 44
 Hyperglycemia, nonketotic, 36*t*
 Hyperkinetic pattern, 132
 Hyperlordosis
 dorsal rhizotomy-related, 461–463,
 462–463*f*, 499
 as intraoperative epidural hemorrhage
 risk factor, 472
 Hyperphenylalaninemia, 35*t*
 Hyperreflexia
 hypotonia-related, 126
 spasticity-related, 47, 106
 Hypersensitivity, postoperative, of the
 foot, 791
 Hypertension, knee flexion contracture
 release-related, 681–682
 Hypertonia
 aquatic therapy for, 811–812
 spasticity-related, 107
 Hypotension
 intraoperative, 471
 postoperative, 482–483
- Hypotonia. *See also* Hip, hypotonic
 anatomic mixed tone pattern of, 126
 Ashworth scale measurement of, 126
 ataxia associated with, 137
 cavovagis deformity associated with,
 776
 definition of, 47, 104, 126
 hyperreflexia associated with, 126
 local mixed tone pattern of, 126
 plantar flexor insufficiency associated
 with, 721–722
 secondary effects of, 126
 treatment of, 126–127
 spasticity-related, 107
 of the trunk, athetosis-related, 133
- Hypoxia
 diazepam-related, 81
 morphine-related, 81
 neonatal, 31–23
 in spinal surgery patients, 468
- Hysterectomy, 76
- I**
- Ibuprofen
 as postoperative pain treatment, 85,
 87*t*, 88
 use in self-injurious patients, 89
- Ileus, dorsal rhizotomy-related, 116
- Iliopsoas
 heterotopic ossification in, 649, 650*f*
 as internal or external rotator muscle,
 619*f*
 in spastic hip subluxation, 524
 Iliopsoas lengthening, 534–535,
 534–535*f*
 as diplegic hip flexion contracture
 treatment, 360
 as hip flexion contracture treatment,
 598
 over the pelvic rim approach in,
 919–920, 919–920*f*
 with proximal hamstring lengthening,
 913–918, 914–917*f*
 Iliopsoas tenotomy, as hip flexion con-
 tracture treatment, 598–599
 Iliopsoas transfer, as hip subluxation
 treatment, 541
- Iminostilbenes, as seizure treatment,
 83–84, 84*t*
- Impairments
 definition and classification of, 39–40,
 40*t*
 functional, 39–40
- Incompetency, determination of,
 172–173
- Individual education programs (IEPs),
 168, 170
- Individuals with Disabilities Education
 Act, 168
- Infants, physical therapy with, 160, 161*t*

- Infant stimulation programs, 151, 160
 Infection
 as microencephaly cause, 28
 as neurologic disorder cause, 38
 postnatal, as cerebral palsy cause, 32
 Ingrown toenails, surgical correction of, 1022–1023, 1022–1023*f*
 Inpatient rehabilitation setting, for physical therapy, 163–164
 Intermedullary metabolism disorders, 33, 38
 Intermedullary nailing, 64
 Interosseous membrane, tibialis posterior transfer through, 740, 741*f*
 In-toeing, diplegia-related, 737
 Intramedullary nailing, in femoral derotation, 949–952, 950–951*f*
 Intrathecal pump administration, of antispasticity medication. *See* Baclofen, intrathecal pump administration of
 Intravascular fluid space, intraoperative expansion of, 471
 Intravascular fluid volume
 intraoperative contraction of, 471
 low, as hypotension cause, 473
 Intravenous access, in spinal fusion patients, 450
 Intravenous lines, as sepsis cause, 490
 Intravenous pump holders, on wheelchairs, 222
In utero positioning, as tibial torsion cause, 696, 698*f*
 in very young children, 500–501
 Isokinetic exercise programs, 807, 808, 808*t*
 Isotonic exercise programs, 807, 807*t*, 808
- J**
- Jebson hand test, 389, 390, 840
 John G. Leach School, 831
 Jumper's knee, 687
- K**
- Kano, Jigaro, 177
 Kearns-Sayre syndrome, 37*t*
 Kernicterus, athetosis associated with, 132
 Ketazolam, as spasticity treatment, 109*t*
 Ketogenic diet, for seizure control, 89
 Ketorolac, 87*f*
 Key pinch, 419, 421, 421*f*
 Kidney obstruction, as pain cause, 71, 71*f*
 Kinematic evaluations
 accuracy of, 279
 data reduction algorithms in, 277–279, 278*f*
 optical measurements in, 276–277, 277*f*
 Kinesthesia, evaluation of, 838
 Kinetic evaluations, in gait analysis, 279–281, 279*f*, 280*f*
 Kinetics, definition of, 280*f*
 Kleist's hooking sign, 839*t*
 Klippel and Weil thumb sign, 839, 839*t*
 Klonopin. *See* Clonazepam
 Knee. *See also* Menisci; Patella
 in cerebral palsy, 667
 contractures of, 108
 crossing over of, 334*f*
 dystonia at, 131
 in gait abnormalities, 322–329, 338*t*, 350. *See also* Knee, stiffness in
 intraarticular derangements of, 696
 knee capsulotomy-related instability of, 682
 ligament injuries in, 694–695
 loose bodies in, 696
 low-energy fractures of, 63–64
 metaphyseal fractures, 62, 62*f*
 mechanical instability of, 694–696, 695*f*
 in normal gait, 295–296, 296*f*, 297*f*, 301, 302–303, 3232
 stability of, 667
 stiffness in, 326–328, 350, 684–685
 dynamic, 689–690, 689*f*
 rectus transfer treatment of, 326, 328, 328*f*, 958–962, 959–962*f*
 role in knee stability, 694
 wound infections in, 790
 Knee-ankle-foot orthoses (KAFO), 189–190, 189*f*
 Knee blocks, anterior, on wheelchairs, 227, 227*f*
 Knee capsulotomy, posterior, 962–966, 963–966*f*
 Knee extension
 at foot contact, 322, 327–328, 329*f*
 during terminal swing phase, 327
 Knee extension contractures, 108, 685–689
 anterior hip dislocation-related, 579, 587
 diagnostic studies of, 687, 689
 fixed, 692–693
 pathology of, 685–687, 686*f*
 Knee extensor muscles, 683–684
 in stiff knee gait, 684–685
 Knee flexion
 in diplegia, 359
 at foot contact, 322–323, 322–327
 in gait abnormalities, 322–328, 328*f*
 inadequate, 683–684
 in midstance, 684
 moderate, 679–682
 Knee flexion contractures, 668–684
 during adolescence, 671
 between 10° and 30°, posterior knee capsulotomy treatment of, 962–966, 963–966*f*
 in athetosis patients, 133, 134
 diagnostic and treatment algorithm for, 793*t*
 diagnostic evaluations of, 671, 673, 673*f*
 during early and middle childhood, 670–671
 etiology of, 668–670
 femoral condyle flattening associated with, 671, 672–673, 672*f*
 greater than 30°, osteotomy treatment of, 972–978, 973–978*f*
 hamstring contracture-associated, 668–679
 diagnostic evaluation of, 671, 673, 673*f*
 etiology of, 668–671, 669*f*, 670*f*
 natural history of, 671
 treatment of, 673–679, 674–676*f*, 677*f*
 hemiplegia gait type 3-associated, 347
 hip flexion contracture-associated, 599
 knee-ankle-foot orthotics treatment of, 189–190, 189*f*
 measurement of, 53
 moderate, 679–682
 natural history of, 671
 sciatic nerve palsy associated with, 789–790
 secondary pathology of, 670–671
 severe, 668, 668*f*, 682–683
 tertiary pathology of, 671, 672, 672*f*
 treatment of, as sciatic nerve palsy cause, 789–790
 uncorrected, 721
 weight gain-associated, 77
 wheelchair seating management of, 228
 Knee flexors
 in knee flexion contractures, 668–670, 669*f*
 moment arm length of, 669, 669*f*
 Knee immobilizers, 190, 190*f*
 postoperative use of, 957
 Velcro closure, 674, 674*f*
 Knee jerk reflex, 104
 Knee operative procedures, 955–978
 distal femoral osteotomy, 972–978, 973–977*f*
 hamstring lengthening, 955–956, 956*f*, 957, 957*f*
 patellar advancement, 971, 972*f*
 patellar dislocation repair, 966–968, 967–968*f*
 posterior knee capsulotomy, 962–966, 963–966*f*
 rectus transfer, 958–962, 959–962*f*

- tibial osteotomy
with casting, 968–969, 969f
with intramuscular nails, 970–971, 970f
- Knee orthoses, 189–190, 189f
- Knee recurvatum, 361–362
- Knee subluxation, rotatory, 695f
- Knupfer exercises, in aquatic therapy, 815–816
- Krabbe's disease, 34t
- Kufs' disease, 35t
- Kyphosis, 452–457
dorsal rhizotomy-related, 116
etiology of, 452–453
hamstring contracture-related, 227, 227f, 452, 452f, 453
hamstring spasticity-related, 227f
lumbar, seating-related pressure in, 217f
midthoracic, anterior hip dislocation-related, 579, 580–582f, 583
natural history of, 453
thoracic, with lower cervical lordosis, 507–508, 509f
thoracolumbar
 junctional, 499
 rhizotomy-related, 480–481, 480–481f
treatment of, 453
 with anterior spinal release, 904
 conservative, 453–456, 455f, 456f
 with spinal orthoses, 187, 187f
 surgical, 456–457, 904
 wheelchair seating in, 227, 227f
- L**
- Labyrinthine reflex, 41, 42f
- Laminectomy
with dorsal rhizotomy, 115, 115f
 as lordosis cause, 453, 460–464, 462–464f
Fazano technique in, 115, 115f, 453, 453f, 499
 as kyphosis cause, 453, 453f
 as spondylolithesis and spondylolysis cause, 499
- Lamotrigine
as seizure treatment, 84t
as spasticity treatment, 110
- Lateral block test, 726–727, 729f
- Lateral column fusion, 774, 775f
- Lateral column lengthening, 753, 754–755f
complications of, 766, 768f
outcome of, 760
through the calcaneocuboid joint, 989–991, 990–991f, 999
through the calcaneus bone, 985–989, 985–989f
- “Lazy eye” (amblyopia), 30–31
eye patch treatment of, 158
- Least restrictive environment, for education, 171
- Leg drop test, 54f, 103, 105
- Leg length discrepancy, 351–352, 353, 353f
 hip surgery-related, 645–646
- Leigh syndrome, 37t
- Leri's sign, 839t
- Lesch-Nyhan syndrome, 37t
- Lesioning procedures. *See also* Neurectomy
 as dystonia treatment, 129
- Leukodystrophy
 globoid cell (Krabbe's disease), 34t
 metachromatic, 34t
- Lever arm disease, 314, 317–318, 684
- Levodopa, as dystonia treatment, 129
- Life-saving treatment, parental refusal of, 449
- Lifts, 240–241
 for gait trainers, 239f
- Limb deficiencies, congenital, power wheelchair use in, 210
- Lioresal. *See* Baclofen
- Lissencephaly, 27, 30, 30f, 126
- Little, William John, 667, 708
- Local anesthetics, as postoperative pain treatment, 82
- Loose bodies, in the knee, 696
- Lorazepam, 84t, 87t
 half-life of, 88
- Lordoscoliosis, windblown hip deformity-related, 600
- Lordosis. *See also* Hyperlordosis
 anterior spinal release treatment of, 904
 cervical, thoracic kyphosis associated with, 507–508, 508f
 dorsal rhizotomy-related, 116, 116f
 lumbar, 457–466
 conservative treatment of, 460
 etiology of, 457, 459
 natural history of, 459–460
 orthotic treatment of, 460
 surgical treatment of, 460–464, 462–464f
 thoracic kyphosis-associated, 512, 516, 516f
 wheelchair seating modifications in, 458, 460
 postoperative neuritic pain associated with, 487
 wheelchair seating in, 227, 458, 460
- Low back pain, flexion lumbosacral orthosis treatment of, 188, 188f
- Low-carbohydrate diet, for seizure control, 89
- Lower-extremity orthoses, 188–200
 ankle-foot orthoses (AFO), 190–196, 191–192f, 193f, 194f, 195f, 198f
 elastic wraps, 189
 foot orthoses, 197–200, 199–201f
 hip orthoses, 188, 189f
 knee orthoses, 189–190, 189f
 twister cables, 188–189
- Lumbar flexion jacket, 188, 188f
- Lumbar sacral flexion orthoses (LSO), as spondylolithesis treatment, 509, 510, 510f
- Luque system, of spinal instrumentation
 scoliosis progression associated with, 488–489
 as scoliosis treatment, 443, 444, 444f
- Lyme disease, knee involvement in, 696
- M**
- Macroencephaly, 28, 30
- Magnetic resonance imaging (MRI)
 for cerebral palsy diagnosis, 47, 48f
 for femoral anteversion measurement, 615–616
 for gait impairment diagnosis, 285
- Malacia, tracheal, 485
- Malnutrition, as spinal surgery contraindication, 467–468
- Malpractice lawsuits, 8
- Mannosidosis, 35t
- Maple syrup urine disease, 35t
- Marijuana, as spasticity treatment, 110
- Maroteaux-Lamy's syndrome, 34t
- Martial arts, 175
- Massage therapy, 175–176
 in Votja therapy, 156
- Mathematical modeling, in kinetic measurement, 280–281
- Maturation theory, of motor control, 100, 103
- Mayer's sign, 839t
- Meckel's syndrome, 28
- Medial column correction, 992–998, 992–998f
 in triple arthrodesis, 998, 999, 999f
- Medicaid, 207
- Medical equipment. *See also* Durable medical equipment
 definition of, 169
- Medical system, relationship with special education system, 168–169
- Megaloencephaly, 28, 30
- Meningitis, bacterial, 38
- Meningomyelocele, 6, 28
- Menisci, tears of, 694–695, 696
- Menstrual cycling, 76
- Mental retardation
 inappropriate synaptic remodeling-related, 31
 sensory integration treatment in, 155
- Mephenytoin, 84t
- Mephobarbital, 84t

- Mesoderm, 29*f*
- Metabolic neurologic disorders
classification of, 33, 34–37*t*
intermedullary metabolism disorders,
33, 38
metallic metabolism disorders, 33
storage disorders, 33, 38
- Metacarpal phalangeal joint fusion, of
the thumb, 886–887, 887*f*
- Metachromatic leukodystrophy, 34*t*
- Metallic metabolism disorders, 33
- Metatarsal bones
lateral, equinovarus-related fractures
of, 724
stress fractures of, 62, 726*f*
- Metatarsal phalangeal joints
extended, 787
fusion of
as bunion treatment, 781, 785–786*f*
nonunion of, 781, 784
- Methosuximide, 84*t*
- Methylphenidate, 87*t*, 88
- Microencephaly, 28
- Middle cerebral artery, occlusion of, in
neonates, 27
- Middle childhood
occupational therapy during, 165
physical therapy during, 161–162
planovalgus during, 743
upper-extremity functional develop-
ment during, 391
windblown hip deformity treatment
during, 602
- Midfoot, subtalar fusion-related collapse
of, 768
- Midfoot break, 309
- Midfoot deformities. *See also* Subtalar
and midfoot deformities
midfoot supination, 768–771
outcome of treatment of, 775–776
- Minnesota Rate of Manipulation
(MMRT) Test, 840
- Mitochondrial cytopathy, 37*t*
- Mitochondrial fatty acid defects, 37*t*
- Mitochondrial myopathy, 37*t*
- Mobility Opportunities Via Education
(MOVE) Program, 164, 164*f*
- Mobilization, postoperative, 84–85
- MODEMS questionnaire, 378
- Monoplegia, definition of, 41
- Mood stabilizers, 87*t*, 88–89
- Moro reflex, 42, 42*f*
- Morphine
in combination with diazepam, 88
as hypoxia cause, 81
as postoperative pain treatment, 81,
82, 83*t*, 87*t*, 88
- Morquio's syndrome, 34*t*
- Motor activity, neurologic control of,
95–150
- Motor development
hierarchical theory of, 152–153, 154,
155
impairment of, developmental aspects
of, 44–47, 45*t*, 46*f*
recapitulation theory of, 155
subsystems theory of, 153
- Motor evoked potentials (MEPs), intra-
operative, 479
- Motor function, importance of, 95
- Motor function control
assessment of, in gait analysis, 273,
274*t*
central motor program generator
concept of, 45
development of, 306
- Motor function control disorders
as gait abnormalities cause, 305–307
treatment of, 136–137
- Motor function control system
center of gravity positioning by, 342,
342*f*
neurologic control of, 95–96
automatic, 96
chaotic attractors in, 101–102, 101*f*
dynamic systems model of, 100–102,
101*f*, 103, 107–108, 805
feedback control mechanism of,
98–100, 99*f*
feed-forward control mechanism of,
99–100, 99*f*
fuzzy logic model of, 100
maturation theory of, 100, 103
open-loop control mechanism of, 99
unified theory of, 102–103
volitional, 96
as peripheral nervous system
component, 96
subsystems of, 103
- Motor impairments
diagnostic implications of, 27–28
durable medical equipment-based
treatment of, 181–249
encephalocele-related, 28
encephalopathy-related, 95
- Motor neurons, alpha, excitability of,
105
- Motor skills, maturation of, 97
- Movement, evaluation of, 838
- Movement disorders. *See also* Athetosis;
Ballismus; Chorea; Dystonia
definition of, 45, 127
as gait disorders, 373–374
pathology of, 127
- M.O.V.E.^(TM) (Mobility Opportunities
Via Education) curriculum,
828–831, 830*f*
contraindications to, 829
- Mucopolysaccharidoses, 34*t*
- Mucopolysaccharidoses, 34*t*
- Multiple births, as cerebral palsy risk
factor, 39
- Multiple carboxylase deficiency, 36*t*
- Muscle lengthening. *See also* specific
muscle lengthening procedures
dystonia as contraindication to, 129
- Muscle length-tension relationship (Blix
Curve), 257–259, 259*f*
- Muscle modeling, of hamstring contrac-
tures, 673
- Muscles. *See also* specific muscles
effect of spasticity on, 106*f*, 107–108
hypotonic, 126
- Muscle strength, 107
assessment of, in gait analysis, 275
- Muscle-strengthening exercises, 158,
806–808
aquatic, 813–814
- Muscle tone
abnormalities of, 47
definition of, 103, 104
evaluation/measurement of, 104–105,
105*t*, 838
in gait analysis, 275
reduction of, as windblown hip defor-
mity treatment, 605–606
in spasticity, 106
viscoelastic dampening in, 103–104
- Muscle transfers. *See also* specific muscle
transfers
dystonia as contraindication to, 129,
131
electromyography prior to, 392
- Muscle weakness, 107
as gait abnormalities cause, 307–307
- Musculoskeletal surgery, as athetosis
treatment, 133
- Myelotomy, as spasticity treatment, 118
- Myofascial lengthening
of the biceps, 398, 398*f*
of the brachialis, 398, 398*f*
as hip flexion contracture treatment,
599
- Myofascial release therapy, 175
- N
- Naloxone, 87*t*, 88
- Naltrexone, 87*f*, 90
- Naproxen, 73, 85
as postoperative pain treatment, 87*t*,
88
use in self-injurious patients, 89
- Nasogastric tube feedings
for nighttime feedings, 468
postoperative, 486
- National Center for Medical Rehabilita-
tion Research, 39–40
- Navicular tuberosity excision, 992, 993,
994*f*

- Naviculo-cuneiform joint excision, 992, 996, 996*f*
- Near drowning, 38, 621
- Near hanging, 38
- Neck stiffness, spinal surgery-related, 489
- Necrosis, avascular, hip reconstruction-related, 563–564
- Nemours Foundation, 172
- Neonates, cerebral palsy in, 11
- Nerve conduction velocity, age-related increase in, 98
- Nerve injuries, hamstring lengthening-related, 679, 680
- Nerve palsies, hamstring lengthening-related, 679, 680
- Nerves, effect of spasticity on, 106–107
- Nervous system. *See also* Central nervous system; Peripheral nervous system anatomy of, 95–96
- Neural tube, 97
- Neural tube defects, 28, 29*f*
- Neurectomy
 - anterior branch obturator, 118
 - of forearm motor nerves, 415
 - of gastrocnemius, as ankle equinus treatment, 118, 175
- Neuritic pain, lumbar lordosis treatment-related, 464
- Neurodevelopmental Therapy (NDT), 154, 805–806, 816
- Neurologic disease, progressive, 76–77
- Neurologic maturity, development of, 44
- Neuromotor junction injections, as spasticity treatment, 120–122, 121*f*
- Neuromuscular electrical stimulation (NES), 809–810
 - as ankle equinus treatment, 716
- Neurovascular monitoring, postoperative, 82–83
- Niemann-Pick disease, 34*t*
- Nonsteroidal anti-inflammatory drugs, 87*f*
 - injectable, 87*t*, 89
 - as postoperative pain treatment, 87*t*, 88
- Nonunion
 - of metatarsal phalangeal joint fusions, 781, 784
 - osteotomy-related, 683
 - spinal fusion-related, 488, 488*f*, 489*f*
 - subtalar fusion-related, 766, 768*f*
 - tibial, 703–704
- No resuscitation order/status, 447, 504–505
- North American Riding for the Handicapped Association (NARHA), 810
- Nutrition
 - in quadriplegic patients, 56–58
 - in spinal surgery patients, 467–468
 - postoperative, 485, 486, 490
- Nutritional assessment, 57
 - preoperative, 79
- Nutritional supplementation, in spinal surgery patients, 449
- O**
- Obturator nerve ablation, as spasticity treatment, 118
- Occupational therapist assistants (OTAs), 166
- Occupational therapists, preoperative evaluations by, 392
- Occupational therapy
 - cerebral palsy scoring scales used in, 834–838, 835*t*, 836*t*
 - extremity evaluations in, 831–851
 - functional abilities evaluations in, 834–836, 835*t*, 836*t*
 - overall evaluations in, 836–838, 837*f*
 - overlap with
 - physical therapy, 151
 - speech therapy, 152
 - postoperative goals in, 848
 - prescriptions for, 165–166
 - upper-extremity evaluations in
 - of functional development, 391
 - functional outcome prediction in, 848, 850
 - informational/instructional handouts in, 848, 850*t*, 851*t*
 - postoperative, 844–851, 849*f*, 850–851*t*
 - preoperative, 838–844, 841–844*f*
- Olendronates, 68
- Opisthotonic patterning, 128
- Optical measurements, in kinematic evaluations, 276–277, 277*f*
- Oral motor dysfunction management, 166
- Oral motor reflex, 839*t*
- Orthopedist-educator relationship, 170
- Orthopedists
 - interaction with physical therapists, 166–167
 - interaction with special educational system, 168
 - role in physical therapy, 166–167
 - therapy prescriptions from, 169–170
- Orthoses, 181, 182–200
 - ankle
 - as ankle equinus treatment, 713, 713*f*
 - as ankle plantar flexion prepositioning treatment, 320
 - as hypotonia treatment, 127
 - as spasticity treatment, 123
 - ankle-foot (AFO), 182, 190–196, 191–192*f*, 193*f*, 194*f*, 195*f*, 198*f*
 - contraindication as lordosis treatment, 460
 - as dystonia treatment, 132
 - elastic wraps, 189
 - elbow, 183, 184*f*
 - foot, 197–200, 199–201*f*, 199*f*
 - as foot progression angle malrotation treatment, 318
 - as hypotonia treatment, 127
 - intramalleolar, 198, 200*f*
 - prescriptions for, 245–247*f*
 - supramalleolar, 198, 200*f*, 727
- hand and wrist, 183–184, 184*f*
 - resting splints, 184–185, 185*f*
 - swan neck splints, 185–186, 186*f*
 - thumb splints, 185, 186*f*
- hip, 188, 189*f*
- hip abduction, 188
 - as windblown hip deformity cause, 603, 606*f*
 - as windblown hip deformity treatment, 603, 605
- knee, 189–190, 189*f*
- knee-ankle-foot (KAFO), 189–190, 189*f*
- for kyphotic patients, 455–456
- lower-extremity, 188–200
 - as plantar flexion treatment, 140
- problem-based understanding of, 197*t*
- purpose of, 182
- shoulder orthoses, 183
 - as spasticity treatment, 123, 124–215
- spinal, 186–188, 187*f*, 188*f*
- terminology of, 182
- twister cables, 188–189
- upper-extremity, 182–186
 - as varus foot deformity treatment, 736
- as windblown hip deformity treatment, 601–602, 603, 605, 607*f*
- Ossification, heterotopic, postoperative, 545, 546
 - dorsal rhizotomy-related, 116
- hip surgery-related, 646–650
 - adductor lengthening-related, 646–647, 648–649, 648–649*f*
 - as hip joint stiffness cause, 656
 - as hip pain cause, 648–649*f*, 650
 - hip reconstructive procedures-related, 563, 568
 - prophylactic treatment of, 647, 649, 650
 - treatment of, 649–650, 650*f*
 - resection arthroplasty-related, 573–574
- Unit rod instrumentation-related, 474, 477*f*
- Osteochondroma, 285
- Osteogenesis imperfecta patients, power wheelchairs for, 210
- Osteomalacia
 - quadriplegia-associated, 57, 58
 - treatment of, 66–68

- Osteopenia
 as distal femoral knee extension fracture cause, 679
 hypotonia-related, 126
 knee flexion contracture-associated, 683
 quadriplegia-associated, 57, 58
- Osteoporosis
 diagnosis and treatment algorithm for, 90f
 as distal femoral knee extension fracture cause, 679
 hypotonia-associated, 126
 knee flexion contracture-associated, 683
 as low-energy fracture cause, 64
 quadriplegia-associated, 57–58
 treatment of, 66–68
- Osteotomy
 calcaneal
 as fixed heel varus treatment, 733, 734, 735f
 as midfoot supination cause, 770
 as planovalgus treatment, 760, 761, 761f, 766, 767, 767f
 as recurrent varus foot deformity treatment, 741–742
 as varus foot deformity treatment, 740
 calcaneal tuberosity, 985–989, 985–989f
 Chiari, 557f, 558
 as limited hip range-of-motion cause, 656
 poor outcome of, 560, 560f, 656
 Dega, 550, 556–557
 distal extension, as patella alta treatment, 691
 distal femoral
 in combination with patellar advancement, 971
 in combination with varus-valgus realignment, 972
 as femoral anteversion treatment, 624
 operative procedure in, 972–978, 973–977f
 distal femoral extension, as knee flexion contracture treatment, 682–683
 extension, as hip flexion contracture treatment, 599
 extraarticular, as planovalgus treatment, 760
 femoral
 complications of, 637–645, 638f, 640–645f
 as hip pain cause, 651–652, 651f
 medial plate protrusion in, 651–652
 nonunion of, 637–639, 638f
 as plate bursitis cause, 651, 651f, 652, 652f
 proximal, 920–930, 921–930f
 as windblown hip deformity treatment, 602
 wound infections associated with, 561, 561f, 635, 636–637
 femoral derotation, 554
 as femoral anteversion treatment, 623, 624
 varus, 552–553f
 femoral proximal, 920–930, 921–930f
 femoral valgus, 574, 575, 575f
 of first cuneiform, 771, 773f
 in hip reconstruction, 550
 as hip subluxation treatment, 559–560
 humeral
 derotation, 869, 870–871f
 as shoulder contracture treatment, 397, 398, 398f
 medial cuneiform, 992, 994–995, 996f
 midshaft, as femoral anteversion treatment, 624, 625f
 pelvic, 554, 556f
 as infection cause, 560, 562
 intraarticular extension of, 564
 wound infections associated with, 635–636
- Pemberton, 556–557, 557f
 as anterior acetabular dysplasia treatment, 551, 556
 as anterior hip dislocation treatment, 585–587f, 587, 590, 936–940, 937–904f
 complications of, 564
 operative procedure in, 936–940, 937–904f
 use in hip reconstruction, 551, 556
 peri-ileal, 550, 556–557, 557f, 558
 complications of, 564
 as hypotonic hip disease treatment, 629–631, 630–631f, 632–633, 632–633f
 operative procedure in, 931–936, 931–936f
 proximal femoral, 920–930, 921–930f
 proximal phalangeal, 771, 773f
 as bunion treatment, 781
 Salter redirection, 557f, 558
 San Diego, 550
 Steel, 557f, 558
 subtrochanteric valgus, 574, 576, 576f
 Sutherland, 557f
 tibial
 with cast, 968–969, 969f
 as compartment syndrome cause, 792
 foot-to-thigh angle as indication for, 318
 as peroneal nerve palsy cause, 792
 as tibial torsion treatment, 700–704, 701–702f
 as vascular infarction cause, 791
- valgus
 palliative, 574, 576, 576f
 shortening, as windblown hip deformity treatment, 603, 604–605
 varus, as leg length discrepancy cause, 645–646
 varus repositioning
 as hip subluxation treatment, 551
 as inferior hip dislocation treatment, 593, 593f, 594
- Outpatient clinics, physical environment of, 51
- Outpatient management, 51–53
- Outpatient setting, for physical therapy, 163
- Oxazolindione, as seizure treatment, 84t
- Oxcarbazepine, 84t
- Oxycodone hydrochloride, as postoperative pain treatment, 88
- Oxygen consumption measurement, in gait analysis, 282–285, 284f
- Oxygen saturation, postoperative monitoring of, 81
- P**
- Pain
 crouch gait-related, 691, 692f
 hip pain, 651, 651f, 653
 hip dislocation-related, 547–548, 548f, 549, 550f, 551
 hip reconstructive procedures-related, 563, 565–566f
 hip subluxation-related, 529f, 530–531, 548, 549, 550f
 hip subluxation surgery-related, 545
 in noncommunicative children, 69–74
 neuritic pain, lumbar lordosis treatment-related, 464
 nonoperative, in noncommunicative children, 68–74, 91t
 gastrointestinal, 69, 71–74
 genitourinary, 74–75
 hip pain, 69–74
 pain workup algorithm in, 91t
 palliative treatment-related, 576, 578
 patellofemoral, 693–694
 postoperative, 78, 79, 81–83, 83t
 in severely mentally retarded patients, 87t
 for sleep disturbance management, 85
 spinal fusion-related, 480–481, 487
- Palliative treatment, of painful, dislocated or degenerated hips, 72, 73, 73f, 566–578
 complications of, 576, 578

- with femoral head resection, 571, 571*f*, 574
- with femoral valgus osteotomy, 574, 575, 575*f*
- with Girdleston resection, 571, 571*f*, 574
- goals of, 566
- with hip fusion, 574, 577, 577*f*
- with interposition arthroplasty, 569, 571–572, 571*f*, 572*f*, 575, 575*f*
- with resection arthroplasty, 567–568*f*, 570–571, 573–574, 573*f*
- with subtrochanteric valgus osteotomy, 574, 576, 576*f*
- with total hip replacement, 568, 569–570*f*
- with valgus osteotomy, 574, 576, 576*f*
- Pallidotomy
- as dystonia treatment, 129
 - as extensor posturing treatment, 506
- Palmaris longus transfer
- to the abductor pollicis, 890–891, 891*f*
 - as type 2 thumb deformity treatment, 420
- Palmo-mental reflex, 839*t*
- Pamidronate disodium, 67, 68
- Pancreatitis
- chemical, 485
 - hemorrhagic, 483, 485
 - postoperative, 485, 491
- Parachute reflex, 42, 43*f*
- absence of, 44
- Paralysis, meningomyelocele-related, 28
- Paramethadione, 84*t*
- Paraplegia, definition of, 41
- Parapodiums, 233, 235
- Parents, of cerebral palsy patients
- care-providing community for, 5–6, 5*f*
 - divorce rate in, 4
 - emotional response patterns of, 8–11
 - medical decision-making by, 15–20
 - about spinal fusion surgery, 446–447, 449
 - need to assign blame, 8, 9, 11, 15, 18, 19–20
 - stress experienced by, 4–5, 8
- Passive stretching exercises, 124
- as ankle equinus treatment, 716
- Patella
- catastrophic failure of, 687
 - dislocation of, 693–694
 - treatment of, 966–968, 967–968*f*
 - proximal migration of, in knee extension contractures, 686, 687
 - stress fractures of, 62, 687, 688, 688*f*
 - subluxation of, 693–694
- Patella alta, 690–692, 692*f*, 693
- Patellar advancement, 971, 972*f*
- Patellar ligament, plication of, 691–692
- Patellar tendon, elongated, in crouched gait syndrome, 691
- Patient management, 51–93
- in diplegic and hemiplegic pattern patients, 78–87
 - outpatient management, 78
 - surgical management, 78–87, 80*f*, 83*t*, 84*t*, 86*f*, 86*t*
 - medication use during postoperative period, 87–89, 87*t*
 - nonoperative pain management, in noncommunicative children, 68–74
 - gastrointestinal pain, 69, 71–74
 - genitourinary pain, 74–75
 - hip pain, 69–74
 - pain workup algorithm in, 91*t*
 - outpatient, 51–53, 78
 - in quadriplegic pattern patients
 - of concurrent diseases, 77–78, 78*f*
 - gastroesophageal reflux and aspiration, 72–73
 - hip dislocation prevention, 54, 56
 - low-energy fractures, 58, 59–66, 60*f*, 61*f*, 62*f*
 - during maturation and puberty, 76
 - of neurological deterioration, 76–77
 - of osteoporosis and osteomalacia, 66–68
 - poor peripheral blood flow, 75–76
 - temperature regulation problems, 75–76
- Patterning therapy, 30–31, 156
- Peabody Developmental Scales of Fine Motor Skills, 809, 835, 840
- Pectineus myotomy, as hip flexion contracture treatment, 599
- Pediatric Evaluation of Disability Inventory (PEDI), 378
- Pediatric therapists, training programs for, 153
- Pedicle screws
- in dorsal rhizotomy, 499
 - in lordosis spinal surgery, 461, 462*f*
- Pedobarograph, 282, 283*f*, 309, 726, 729*f*, 751
- Pelvic malalignment, 509–516
- anterior pelvic tilt, 338*t*, 340, 512–515
 - diplegia-related, 360
 - etiology of, 512–513
 - natural history of, 513
 - treatment of, 515
 - pelvic obliquity, 341, 341*f*, 509–512
 - asymmetric, 338*t*
 - definition and measurement of, 509–510, 511*f*
 - Dwyer instrumentation-related, 497, 498*f*
 - etiology of, 510–511
 - fixed, 509–510
 - flexible, 509
- Harrington rod instrumentation-related, 497, 498*f*
- hip abduction-related, 331
- in hip subluxation, 530
- infrapelvic, 510–511, 513–515, 513–515*f*, 606, 608*f*, 609
- as leg length discrepancy cause, 646
 - natural history of, 511
 - in normal gait, 300, 301*f*
 - seating accommodations in, 512
 - seating-related pressure in, 217*f*
 - spinal fusion-related, 495, 497–498*f*
 - suprapelvic, 510, 606, 608*f*, 609
 - treatment of, 469, 470*f*, 511–512, 513–515, 513–515*f*
 - wheelchair seating management of, 228
 - windblown hip deformity-related, 600, 601, 606, 608*f*, 609–610*f*
- pelvic rotation
- asymmetric, 339–340
 - excessive, 335, 338*t*
 - malalignment in, 515
 - torsional malalignment in, 311
 - posterior pelvic tilt, 340–341
- Pelvic obliquity. *See* Pelvic malalignment, pelvic obliquity
- Pelvis
- in gait abnormalities, 335, 338*t*, 339–342
 - gait analysis of, 335
 - in normal gait, 291–292, 292*f*, 293*f*, 298–300, 301, 301*f*
 - osteoporotic, 475
 - Unit rod-related perforation of, 473–474, 475*f*, 476–478
 - acetabular, 476–478
 - lateral, 474, 476, 477*f*
 - medial, 474, 475, 475*f*
- Pennsylvania Bi-Manual test, 840
- Pentaplegia, 41
- Peptic ulcers, 72
- Perception, evaluation of, 838
- Percoset, 88
- Peripheral nerve lesioning, as spasticity treatment, 118
- Peripheral nervous system
- development of, 198
 - role in motor control, 96
- Peripheral nervous system surgery, as dystonia treatment, 130–131
- Peritonitis, 74
- Perkins' line, 532*f*
- Peroneal muscle
- electromyographic activity in, 742
 - spastic and overactive, 742
 - varus deformity of, 131

- Peroneal nerve
 biceps tendon lengthening-related injury to, 679
 tibial osteotomy-related palsy of, 792
- Peroneal tendon contractures, planovalgus-related, 750
- Peroneus brevis muscle
 in equinovarus foot deformity, 723–724
 in foot stability, 769*f*
- Peroneus longus muscle, 724
 in foot stability, 769*f*
 in forefoot supination, 768, 770
 in medial arch maintenance, 770*f*
- Peroxisomal disorders, 37*t*
- Personality characteristics, evaluation of, 838
- Perthes' disease, 635
 arthrography in, 533
- Peto, Andreas, 157
- Peto technique, 157
- Phenacemide, 84*t*
- Phenobarbital, 83, 84*t*
 as intraoperative hemorrhage risk factor, 471
- Phenol injections, as spasticity treatment, 118, 119, 122
- Phensuximide, 84*t*
- Phenyl blocks, as windblown hip deformity treatment, 606
- Phenylketonuria (PKU), 35*t*
- Phenytriazone, as seizure treatment, 84*t*
- Phenytoin, 84*t*
- Photography, use in occupational therapy evaluations, 848, 849*f*
- Physical Capacities Evaluation (PCE), 840
- Physical examination
 in gait analysis, 272–275, 285
 global function measures in, 272–273, 274*t*
 motor control assessment in, 273, 274*t*
 of motor control function, 306
 muscle strength assessment in, 275
 muscle tone assessment in, 275, 275*t*
 in outpatient evaluations, 52–53, 52*f*, 53*f*, 54*f*, 55*f*
 in pain evaluations, 69–70
 preoperative, 79
- Physical therapist assistants (PTAs), 166
- Physical therapists
 “grandmother” role of, 12–13
 relationship with orthopedists, 166–167
- Physical therapy, 151, 152–164
 for ataxia, 138–139
 for athetosis, 135–136, 137
 current approach in, 159–163
 evaluation of effectiveness of, 152
 goal setting in, 159–160
 home-based, 163
 inpatient, 163–164
 orthopedist's role in, 166–167
 outpatient, 163
 overlap with occupational therapy, 151
 postoperative, 84, 85
 postoperative pain experienced during, 653–654
 school-based, 164
 settings for, 163–164
 for shoulder contractures, 398
 for spasticity, 123–124
 during specific age periods
 adolescence, 162
 early childhood, 160–161
 infancy, 160
 middle childhood, 161–162
 young adulthood, 163
 techniques in
 conductive education (Peto technique), 157
 electrical stimulation, 157–158
 enforced-use, 158–159
 muscle-strengthening exercises, 158
 Neurodevelopmental Therapy (NDT), 154, 805–806
 patterning therapy (Doman-Delacato technique), 156
 sensory integration approach (Ayers technique), 155
 sensory motor treatment approach (Rood technique), 155
 tone-reducing casts, 158
 Votja therapy, 155–156, 175
 theoretical basis for, 145, 152–153, 155
 therapeutic relationship in, 153
- Physician-educator relationship, 170
- Physician-parent relationship, 12, 13–15
 dysfunctional, 14–15
- Pinch strength, 840
- Piriformis muscle contractures, 619
- Pituitary hypophyseal axis, 76
- Planovalgus, 77, 108, 309, 312, 719, 742–768, 753, 979–985
 ankle plantar flexor contracture-associated, 710, 710*f*
 ankle valgus associated with, 704, 705, 705*f*, 707–708, 707–708*f*
 diagnostic evaluation of, 750–751, 751*f*
 diplegia-associated, 725, 727–728*f*, 737–738, 738*f*
 etiology of, 742–743
 external foot rotation-associated, 314, 317
 foot orthotic treatment of, 197
 genetic factors in, 743
 hemiplegia-associated, 345–346, 730, 730*f*, 731, 731*f*
 indication for, 979
 natural history of, 743, 744–745*f*
 orthoses treatment of, 198, 200*f*, 766
 pathologic anatomy of
 in ambulators, 743, 745–749, 746*f*, 747*f*, 748*f*
 in nonambulators, 749–750, 750*f*
 pathology of
 primary, 745–747, 747*f*
 secondary, 718–720, 718–720*f*, 748, 750
 tertiary, 748–749, 748*f*, 749*f*, 750
 postoperative care in, 985
 quadriplegia-associated, 372
 racial factors in, 743
 spontaneous correction of, 743, 744–745*f*
 surgical treatment of, 751–768
 with calcaneal osteotomy, 760, 761, 761*f*, 766, 767, 767*f*
 with calcaneocuboid lengthening fusion, 758, 759, 759*f*
 complications of, 766, 768
 indications for, 752
 with lateral column lengthening, 753, 754–755*f*, 760
 outcome of, 760
 with reconstructive procedures, 752–760, 754–757*f*, 759*f*
 with sinus tarsi implants, 760
 with subtalar fusion, 753, 756–757*f*, 756–758, 764, 771, 772–773*f*, 980–984*f*, 980–985
 sutures in, 792
 with triple arthrodesis, 758, 760, 767, 767*f*
 torsional malalignment in, 311
 varus overcorrection-related, 742
- Plantar fascia
 in planovalgus, 743
 role in medial arch maintenance, 770, 770*f*
- Plantar flexion, 769*f*
 ataxia-related, orthotics treatment of, 140
 premature, 727
 in ankle equinus, 711–712, 712*f*
- Plantar flexion-knee extension couple, 317*f*
- Plantar flexor contractures, 726*f*
- Plantar flexor muscles
 equinus surgery-related insufficiency of, 717–722, 718–719*f*
 surgical overlengthening of, 721
- Play chairs, 230, 231*f*
- Pleural effusions, postoperative, 484, 484*f*
- Plica, 696
- Pneumonia
 aspiration, dorsal rhizotomy-related, 116

- fractures as risk factor for, 59, 60, 60*f*
as mortality cause, 448
- Pneumothorax
postoperative, 484–485
spinal surgery-related, 468, 471
- Polymicrogyria, 30
- Pompe's disease, 35*t*
- Pool walking, 813*f*, 814
- Popliteal angle
in diplegia, 359
in hamstring length measurement, 671, 673, 673*f*, 674, 676
measurement of, 53, 55*f*
- Porencephaly, 32
- Positioning chair, for radiographic evaluation of scoliosis, 433, 434*f*
- Positive pressure nasal ventilation, postoperative, 483–484
- Postoperative management, 81
commonly used medications in, 87–89, 87*t*
- Posturing, cervical, 505–506, 506*f*, 507*f*
- Premature infants, intraventricular hemorrhage in, 28
- Prematurity, as cerebral palsy risk factor, 31
- Preoperative assessment, 79
- Pressure mapping, 216, 217*f*
- Pressure sores, 216
- Primidone, 84*t*
- Primitive reflexes, 41–43*f*, 41–44
development of, 97
persistent, 43–44, 47
preoperative evaluation of, 838
relationship with high-functioning cortical motor activities, 152–153
- Pronation, muscles involved in, 769*f*
- Pronator quadratus contractures, 401
myotomy treatment of, 408
- Pronator tendon release, as forearm pronator contracture treatment, 407
- Pronator teres
contractures of, 401
myotomy of, 408
release or transfer of, 407, 408, 873–874*f*
- Prone hip rotation test, 611, 612*f*
- Prone standers, 56, 233, 819, 819*f*
- Propoxyphene, as postoperative pain treatment, 88
- Proprioceptive neuromuscular facilitation (PNF), in aquatic therapy, 815–816
- Proprioceptive reflexes, 41–43
- Proteus* infections, postoperative, 496
- Protrusion acetabuli, 70, 70*f*, 594, 595, 595*f*
windblown hip deformity-related, 603
- Proximal interphalangeal joints
fusion of, 427
hyperextended, splint treatment of, 185–186, 186*f*
- Proximal pronator flexor slides, 407
- Pseudoarthrosis, spinal fusion revision of, 488*f*, 498–499
- Pseudo-Galezzi deformity, windblown hip deformity-related, 605
- Psychosocial skills, evaluation of, 838
- Puberty, premature or prolonged, 76
- Public Law 010-476, 168
- Public Law 94-142, 168
- Purdue Pegboard, 840
- Pyruvate dehydrogenase deficiency, 37*t*
- Q**
- Q-angle, 694
- Quadriceps, 683
- Quadriceps lengthening, as fixed knee extension contracture treatment, 692–693
- Quadriplegia, 388
Achilles' tendon lengthening in, 1003
bacterial meningitis-related, 38
definition of, 40
diagnosis of, 54
elbow flexion contractures associated with, 400
forearm pronation contractures associated with, 401
functional deformities associated with, 387
gait abnormalities associated with, 371–373
management of, 54, 56–68
osteomalacia associated with, 57, 58
osteopenia associated with, 57, 58
osteoporosis associated with, 57–58
patient management in
of concurrent diseases, 77–78, 78*t*
of gastroesophageal reflux and aspiration, 72–73
of low-energy fractures, 58, 59–66, 60*f*, 61*f*, 62*f*
during maturation and puberty, 76
of neurological deterioration, 76–77
of osteoporosis and osteomalacia, 66–68
of poor peripheral blood flow, 75–76
of temperature regulation problems, 75–76
peroneal muscle in, 742
prevalence of, 39
scoliosis associated with, 436–452, 436*f*, 437*f*, 438*f*, 439*f*
shoulder instability associated with, 397
windblown hip deformity associated with, 605
- Quality of Upper Extremity Skills Test (QUEST), 834–835
- R**
- Radial head dislocation, 400–401
natural history of, 400–401
treatment of, 401, 402–405*f*
- Radiation therapy, for heterotopic ossification, 568, 574, 650
- Radiography
for gait impairment diagnosis, 285
for hip subluxation evaluation, 531, 532*f*
pelvic, in Unit rod instrumentation, 477–478
- Radius, fractures of, 408
- Ragged red muscle fibers, 37*t*
- Range of motion, spasticity-related decrease in, 106*f*
- Range-of-motion exercises, passive, 124
- Range-of-motion measurement, upper-extremity, 388, 838–839
- Reactive airway disease
aspiration-related, 468
postoperative management of, 78–79
- Recapitulation of species theory, 156
- Rectus contractures, 685, 689
- Rectus femoris contractures, 330
- Rectus femoris lengthening, 599
- Rectus femoris transfer, anterior thigh scars caused by, 790
- Rectus muscle
function of, 684
as knee stiffness/stiff gait cause, 326, 328, 328*f*, 684–685, 689, 689*t*
- Rectus transfer, 958–962, 959–962*f*
in dystonia, 131
indication for, 684, 684*f*
postoperative care in, 962
as stiff knee treatment, 326, 328, 328*f*, 689–690, 958–962, 959–962*f*
- Reflexes
preoperative evaluation of, 838
upper-extremity, evaluation of, 838, 839*t*
- Reflexology, 175
- Refsum's disease, 37*t*
- Rehabilitation inpatient programs, physical therapy component of, 163–164
- Rehabilitation techniques, 803–861.
See also Occupational therapy;
Physical therapy
aquatic therapy, 811–816, 813*f*
Bad Ragaz Ring Method of, 815–816
contraindications to, 814*t*, 815
Halliwick Method of, 815
multidisciplinary approach n, 816, 818

- Rehabilitation techniques (*continued*)
 pool design/accessibility in, 816, 816*t*, 817*f*
 precautions in, 814*t*
 Watsu, 815
 assistive devices, 818–821
 balance interventions, 808–809
 electrical stimulation techniques, 809–810
 horseback riding (hippotherapy), 123–124, 173–174, 810–811, 811*t*, 812*f*
 M.O.V.E.^(TM) (Mobility Opportunities Via Education) curriculum, 828–831, 830*f*
 contraindications to, 829
 muscle-strengthening exercises, 806–808, 807*t*, 808*t*
 Neurodevelopmental Therapy (NDT), 805–806
 Resistive exercises, aquatic, 813–814
 Respirators, wheelchairs supports for, 222
 Respiratory chain disorders, 37*t*
 Respiratory compromise, postoperative, 81
 Respiratory depression, diazepam/morphine-induced, 88
 Respiratory failure, postoperative, 483–484
 Respiratory infections, postoperative, 490
 Respiratory problems, spinal surgery-related, 468, 471
 as death cause, 467
 Rett syndrome, 27, 31
 Rheumatoid arthritis
 diplegia-associated, 77
 knee involvement in, 696
 Rhizomelic chondrodysplasia punctata, 37*t*
 Rhizotomy, central, as spasticity treatment, 115–116
 Rhizotomy, dorsal, 115–117
 complications of, 116–117, 116*f*
 dural tears, 473
 hyperlordosis, 461–463, 462–463*f*, 499
 kyphosis, 453, 453*f*, 459–460
 lordosis, 453, 460–464, 462–464*f*
 thoracolumbar kyphosis, 480–481, 480–481*f*
 contraindication in mild quadriplegia, 371
versus intrathecal pump-administered baclofen, 851, 857
 as knee recurvatum treatment, 362
 with laminoplasty, 116, 116*f*
 with laminectomy, 115, 115*f*, 116
 Fazano technique in, 115, 115*f*, 453, 453*f*, 499
 outcome of, 116–117, 116*f*
 posterior, as spinal deformity cause, 499
 as windblown hip deformity treatment, 605–606
 Rhythmic activities, as spasticity therapy, 124
 Rickets, 58, 58*f*
 Riluzole, as spasticity treatment, 110
 Ritalin. *See* Methylphenidate
 Rood, Margaret, 155
 Rood technique, 155
 Rooting reflex, 41
- S**
 Salla disease, 35*t*
 Sandhoff's disease, 34*t*
 Sanfilippo's syndrome, 34*t*
 Sartorius muscle, 668
 Sartorius muscle lengthening, as hip flexion contracture treatment, 599
 Scar formation, knee wound infection-related, 790
 Scheie's syndrome, 34*t*
 Schizencephaly, 28
 School-based therapy, 164, 164*f*, 169–170
 Sciatica, spinal fusion-related, 487
 Sciatic nerve, proximal hamstring lengthening-related injury to, 679, 680
 Sciatic nerve palsy, 134
 knee capsulotomy-related, 680, 681
 treatment of, 789–790
 Scissoring gait, 331
 control of, 188, 189*f*
 definition of, 334*f*
 differentiated from hip internal rotation gait, 333
 quadriplegic gait-related, 372
 Scoliosis, 108
 armspan measurement in, 56
 as aspiration risk factor, 485
 diplegic pattern cerebral palsy-related, 499
 etiology of, 433–434
 flexibility assessment in, 446, 447*f*
 floor positioning devices use in, 232
 gastroesophageal reflux associated with, 72–73, 485
 hemiplegic pattern cerebral palsy-related, 499
 idiopathic, 437
 idiopathic pattern of, 433
 kyphosis associated with, 452
 lordosis associated with, 457
 lumbar, 436, 436*f*, 437*f*
 myelomeningocele, 443
 natural history of, 434–435
 neuromuscular pattern of, 433
 prevention of
 with bracing, inefficacy of, 437
 with thoracolumbar spinal orthoses, 440–442, 440*f*, 441*f*, 442*f*
 quadriplegia-related, 430–452, 436*f*, 437*f*, 438*f*, 439*f*
 radiographic examination of, 433, 434*f*, 436*f*, 438*f*
 positioning chair use in, 433, 434*f*
 seating methods in, 442
 as spinal fusion revision surgery cause, 488–489
 spinal instrumentation and fusion
 treatment of
 anesthesia during, 450
 complications of. *See* Spinal instrumentation and fusion, complications of
 end-to-end rod connector failure rate in, 469, 470*f*
 indications for, 446–447
 intraoperative preparation in, 450
 outcome of, 452
 postoperative management in, 450–451, 451*t*
 preoperative preparation for, 449–450
 preoperative workup in, 449
 as revision surgery, 488–489
 with Unit rod instrumentation, 436, 437*f*, 438, 439*f*, 443, 444–445, 444*f*, 452
 tracheal collapse in, 485
 treatment of, 435, 435*f*. *See also* Scoliosis, spinal instrumentation and fusion treatment of
 with anterior spinal release, 451–452, 904
 botulinum toxin, ineffectiveness of, 443
 electrical stimulation, ineffectiveness of, 442
 with hook and rod spinal instrumentation, 452
 with posterior spinal fusion with Unit rod, 894–903, 895–903*f*
 in revision surgery, 488–489, 501, 503–504, 503–504*f*
 with spinal orthotics, 186–187
 surgical, 443
 with thoracolumbar orthoses, 440–442, 440*f*, 441*f*, 442*f*
 with Unit rod instrumentation, 436, 437*f*, 438, 439*f*, 443, 444*f*
 treatment refusal in, 502, 504
 wheelchair adaptations for, 442
 wheelchair seating in, 223–226, 224*f*, 225–226*f*
 windblown hip deformity-related, 600, 601, 606, 609

- Scoring scales, for cerebral palsy
 evaluation
 for functional ability evaluation,
 834–836, 835*t*, 836*t*
 for overall evaluation, 836–838, 837*f*
- Screws, ankle epiphysiodesis, 979, 979*f*
- Seat belts, for wheelchairs, 218
- Seating. *See* Wheelchairs, seating
- Seating clinics, occupational therapists
 in, 166
- Seating systems. *See* Wheelchairs
- Seat restraint laws, 228
- Sebaceous nevus syndrome, 28, 30
- Second opinions, 15
- Seizures
 antiepileptic medication treatment of
 side effects of, 57, 58, 66–68,
 83–84, 84*t*
 in surgical patients, 79, 83–84, 84*t*,
 468, 471
 electroencephalographic evaluation of,
 69
 ketogenic diet treatment of, 89
 postoperative management of, 78–79,
 83–84, 84*t*
 in spinal surgery patients, 468
- Self-injurious behavior, naltrexone treat-
 ment of, 87*f*, 89
- Semimembranous muscle
 in knee flexion contractures, 669
 in knee function, 669–670
- Semitendinosus muscle
 in knee flexion contractures, 669
 in knee function, 669–670
 surgical lengthening of, 676, 678
 transfer to the femur, 678
- Sensory deficiencies, 46
 preoperative evaluation of, 393
- Sensory integration, assessment of, 838
- Sensory integration approach, in physical
 therapy, 155
- Sensory motor treatment, in physical
 therapy, 155
- Sensory system, effect of aquatic exercise
 on, 813
- Sepsis, postoperative, 490, 491
- Shaken baby syndrome, 32–33, 33*f*
- Shiatsu, water-based version of, 815
- Shoes, orthopedic, 182
- Short stature, 76
- Shoulder
 dislocation of, 397
 painful, 397, 399
 treatment of, 399, 833*t*
 elevation and protraction of, 395
 excessive external rotation of, 831,
 833*t*
 instability of, 397
 treatment of, 399, 833*t*
 splints for, 833*t*
 subluxation of, 397
 treatment of, 399
- Shoulder adductor lengthening, 398,
 865, 866–869*f*
- Shoulder contractures, 108, 394–397
 extension and external rotation
 abduction, 395, 397
 internal rotation, 395, 396, 396*f*
 natural history of, 395, 395*f*
 treatment of, 396–397, 396*f*
- Shoulder orthoses, 183
- Shriners' Hospital (South Carolina)
 Upper Extremity Test (SHUE),
 835–836
- Shriners' Hospital System, 172
- Shunts
 intraventricular, preoperative assess-
 ment of, 449, 450*f*
 ventriculoperitoneal
 implications for baclofen therapy,
 854
 as pain cause, 68, 69, 74
 preoperative assessment of, 79, 80,
 80*f*
- Sialidosis, 34*t*
 type 1, 34*t*
- Side bending test, 446, 447*f*
- Silfverskiöld test, 708, 709*f*, 710
- Sinusitis, 68–69, 69*f*, 74
- Sinus tarsi implants, as planovalgus
 treatment, 760, 764
- Sitting difficulties, kyphosis-related, 453,
 454, 454*f*
- Skin breakdown
 effect of wheelchair seating on, 206
 wheelchair footrest-related, 733,
 736
- Sleep disturbances
 postoperative, 85, 86*f*, 86*t*, 87*t*, 563
 spasticity-related, 125
- Slipped capital femoral epiphysis, 635
- Sly's syndrome, 34*t*
- Soccer, as therapy, 175
- Societal limitations, 40
- Soleus muscle
 contractures of
 Achilles' tendon lengthening treat-
 ment of, 713–714, 1003–1004,
 1003–1004*f*
 differentiated from gastrocnemius
 contractures, 708–709, 709*f*, 710
 effect on gait, 319, 320
 as subtalar joint collapse cause, 742
 measurement of, 711
- Somatosensory evoked potentials
 (SSEPs), intraoperative, 479
- Somatosensory system, role in balance
 development, 808
- Souque's sign, 839*t*
- Space suit therapy, 176
- Spasticity
 in adolescents, treatment of, 371
 adverse effects of, 852
 assessment of, 105
 with Ashworth Scale, 104–105, 105*f*
 ataxia associated with, 137
 athetosis associated with, 133–134
 benefits of, 108–109
 as chaotic attractor, 105, 106,
 107–108
 definition of, 47, 104, 852
 differentiated from dystonia, 45, 104,
 128–129, 374
 in upper-extremity surgery patients,
 394
 dystonia associated with, 128
 effect on bones, 108
 effect on muscle, 106*f*, 107–108, 109
 effect on nerves, 106–107
 effect on tendons, 107–108
 evaluation of, 141*t*, 838
 functional effects of, 105–106, 108,
 128
 gait disorders associated with, 125
 global, 124, 125
 idiopathic, 31
 local, 124–125
 postoperative, 81
 management of, 81–83, 83*t*
 prevalence of, 852
 severe, 853
 treatments for, 108–125
 alcohol injections, 122
 aquatic therapy, 811–812
 baclofen, 853–857
 botulinum toxin injections,
 120–122, 120*f*, 121*f*, 124–125,
 392–393, 852
 dantrolene sodium, 119–120
 dorsal rhizotomy, 115–117, 115*f*
 electrical stimulation, 117–118
 evaluation for, 124
 global approach in, 124–125
 horseback riding therapy, 174
 intrathecal medication, 110–114,
 113*f*
 local treatments, 124–125
 muscle tendon lengthening, 122
 myelotomy, 118, 119, 119*f*
 oral medication, 109–110, 109*t*
 orthotics, 123
 phenol injections, 122
 physical therapy, 123–124
 surgery, 852–853
 windblown hip deformity-related,
 605–606
 in young adults, treatment of, 371
- Special education, 168–169, 171, 172
- physician-educator relationship in,
 170

- Special education (*continued*)
 relationship with medical system, 168–169
 transitional planning in, 171–173
- Speech impairment, athetosis-related, 133
- Speech therapy, 151–152, 166
- Sphingomyelinase deficiency, 34*t*
- Spielmeier-Vogt-Sjogren disease, 35*t*
- Spina bifida, 6
 external rotation planovalgus collapse in, 704
- Spinal cord, role in motor control, 96, 97*f*
- Spinal cord-mediated activities, relationship with primitive reflexes, 152
- Spinal cord paralysis, as paraplegia, 41
- Spinal cord stimulators, 16
- Spinal deformities, 433–522. *See also*
 Kyphosis; Lordosis; Scoliosis
 comfort care for, 504–505
 diagnosis and treatment algorithm in, 517*t*
 dorsal rhizotomy-related, 499
- Spinal fusion. *See* Spinal instrumentation and fusion
- Spinal instrumentation and fusion
 in ambulatory children, 499–500, 500*f*
 blood loss during, 501
 in children on ketogenic diet, 89
 as comfort care, 504–505
 complications of, 465–505
 acetabular perforation, 476–478
 air embolism, 466
 aspiration, 485
 bleeding problems, 471–473
 bursitis, 487–488
 cardiac arrest, 466–467
 coagulopathy, 483
 colicystitis, 485–486
 constipation, 486
 crankshaft, 488–489
 duodenal obstruction, 486
 dural leaks, 473
 floor or bed mobility decrease, 489–490
 gastroesophageal reflux, 485
 hair loss, 486, 487*f*
 hemorrhage, 466
 hypotension, 482–483
 during immediate postoperative period, 467
 infections, 490–495
 intraoperative, 468–482
 mechanical problems, 487–490
 mortality, 465–466, 467
 neck stiffness, 489
 nonunion, 488, 488*f*, 489*f*
 nutritional factors in, 467–468
 operative wound infections, 490–495, 493–494*f*
 pancreatitis, 485
 pelvic leg halos, 488
 pelvic wall perforation, 473–474, 476
 during perioperative transition time, 466–467
 persistent fevers, 490–491, 493–494
 pneumo- or hemothorax and pleural effusion, 484–485
 poor nutrition, 486
 poor nutrition as risk factor for, 465
 postoperative, 482–495
 proximal end prominence, 487–488
 respiratory failure, 483–484
 respiratory problems, 468, 471
 rod fractures, 488, 489*f*
 rods of incorrect length-related, 478–479, 479*f*, 480–481, 480–481*f*
 self-limiting, 465
 sitting height changes, 489
 spinal cord dysfunction, 479, 482
 spinal pain, 480–481*f*, 487
 thromboembolism, 465
 wire prominence-related, 487–488
 wires pulling through laminae, 478
- families' refusal of, 502, 504
 families' refusal of blood transfusions for, 501–502
 as gastroesophageal reflux treatment, 73
 as kyphosis treatment, 456–457
 as lordosis treatment, 458–459*f*
 posterior, postoperative femoral neck fractures associated with, 62, 65, 65*f*
 revision, 495, 497–505
 of hardware failure, 499
 of pseudoarthrosis, 488*f*, 498–499
 of short spinal fusion, 495–497, 497–498*f*
 of torsional collapse, 444–445, 444–445*f*, 498
 as scoliosis treatment, 443
 in adolescents, 446
 anesthesia during, 450
 end-to-end rod connector failure rate in, 469, 470*f*
 family's decision-making about, 446–447
 Galveston technique, 443
 indications for, 446–447
 intraoperative preparation in, 450
 Luque technique, 443, 444, 444*f*
 postoperative management in, 450–451, 451*t*
 preoperative preparation for, 449–450, 450
 preoperative workup in, 449
- Unit rod instrumentation, 436, 437*f*, 438, 439*f*, 443, 444–445, 444*f*
 in very young children, 446
 somatosensory evoked potential monitoring during, 479, 482
 in very small older children, 501
- Spinal orthoses, 186–188, 187*f*, 188*f*
 thoracolumbar sacral orthosis (TLSO)
 bivalved, 187, 187*f*
 custom-molded, 440–441, 455–456
 lumbar flexion jacket, 188, 188*f*
 soft, 186–187, 187*f*, 441–442, 442*f*
 weaning from, 813
- Spinal pain, spinal fusion-related, 480–481, 487
- Spinal procedures, 894–912. *See also*
 Spinal instrumentation and fusion
 anterior spinal release, 904–908, 904–908*f*
 baclofen pump implantation, 908–912, 909–912*f*
 posterior spinal fusion with Unit rod, 894–903, 895–903*f*
- Spine
 compression fractures of, 61, 64, 64*f*
 flexibility assessment of, 52–53, 52*f*, 53*f*
 physical examination of, 52–53
 presentation as abdominal mass, 457
- Splints/splinting
 Benik thumb abductor, 832–833, 834
 dorsal wrist extension, 183–184
 as elbow contracture treatment, 833*t*
 as elbow flexion contracture treatment, 399
 as hamstring contracture treatment, 674, 674*f*, 676
 for hand, 184–186, 185*f*, 186*f*, 391
 nighttime ankle, for prevention of recurrent ankle equinus, 717
 for swan neck deformity prevention, 426, 427*f*
 upper-extremity, 832–834
 for contractures, 832–834
 dorsal wrist cock-up, 832, 833*t*
 following muscle transfer surgery, 832
 volar, 183–184
 wrist, 183–184, 184*f*
 wrist cock-up, 840, 844
- Spondylolisthesis, 508–509
 dorsal rhizotomy-related, 116
 lumbar, 508–509
 athetosis-related, 134–135
 laminectomy-related, 499
 lordosis associated with, 457
 as low back pain cause, treatment of, 188, 188*f*
 orthotic treatment of, 509, 510, 510*f*

- Spondylolysis, 509
 cervical, 507
 lumbar, 508, 509
 athetosis-related, 134–135, 509
 dorsal rhizotomy-related, 116
 laminectomy-related, 499
 as low back pain cause, 188, 188*f*
- Sports participation, 175
- Stair lifts, 241
- Standers, 232–233, 234*f*
 for quadriplegic patients, 371
 parapodiums, 233, 235
 prone, 233, 819, 819*f*
 for quadriplegic patients, 56
 supine, 233, 234*f*, 819
 for hypotonic children, 127
 for quadriplegic patients, 56
 upright, 819–820
 weight bearing in, 64, 66
- Staphylococcus aureus* infections, post-operative, 494
- Starvation, as surgery contraindication, 449
- Stepping reflexes, 42–43, 43*f*
- Step reflex, 42–43, 43*f*
- Stereognosis, evaluation of, 838
 postoperative, 844
- Sterling's sign, 839*t*
- Steroids
 as arthritis-related pain treatment, 653
 as degenerative arthritis treatment, 563, 565
- Stiff knee gait, 326–328, 350, 684–685, 689–690, 689*t*
 rectus transfer treatment of, 326, 328, 328*f*, 689–690, 958–962, 959–962*f*
- Stiffness, of hindfoot, varus deformity-related, 741
- Stimulants, 87*t*, 89
- Stomach distention, 486
- Stomach ulcers. *See* Gastric ulcers
- Storage disorders, 33, 34*t*, 38
- Strabismus, eyepatch treatment of, 158
- Strengthening exercises, for muscle weakness, 308
- Stretchers
 mobile, 448, 448*f*
 reclined, 226, 226*f*
- Stretching exercises
 as femoral neck fracture cause, 62, 65, 65*f*
 as low-energy fracture cause, 790
 as windblown hip deformity treatment, 601
- Stretch reflex, 104
- Strohmeyer, Louis, 667, 708
- Strokes, neonatal, 32
- Strumpell's pronation sign, 839*t*
- Subanterior superior iliac spine (SUBASIS) bar, 218–219, 218*f*
- Sublimis slip reinforcement, as swan neck deformity treatment, 891–893, 892–893*f*
- Subtalar and midfoot foot deformities, 722–733
 equinovarus, 108, 723–733
 etiology of, 722–723
- Subtalar joint
 anatomy of, 743, 746, 746*f*
 arthrodesis of, 760, 762–763, 762–765*f*
 collapse of, 742
 function of, 295
 fusion of, 753, 756–757*f*, 756–758, 764, 979–985
 as calcaneal valgus treatment, 777
 complications of, 766, 768*f*
 indication for, 979
 with internal fixation, 766
 as planovalgus treatment, 730*f*, 771, 772–773*f*
 postoperative care in, 985
 procedure, 980–984*f*, 980–985
 in triple arthrodesis, 998, 999, 999*f*
 motion of, 295
 valgus of, 667–668
- Succinimides, as seizure treatment, 84*t*
- Succinylcholine, spasticity-related resistance to, 107
- Sucking reflex, 41, 41*f*
 development of, 97
- Sulfite oxidase deficiency, 36*t*
- Sunburn, effect on anterior thigh scars, 790
- Supine position
 during intraoperative cardiac arrest, 473
 scoliosis-related, 447
- Supine standers, 233, 234*f*, 819
 for hypotonic patients, 127
 for quadriplegic patients, 56
- Surgery
 complications of
 management plan for, 20
 physician-family discussion of, 20, 21
 recommendations for, 18, 20
- Sutures, in planovalgus deformity correction, 792
- Swallowing studies, 166
- Swan neck deformity, 390*f*, 426–427, 831
 finger and wrist extension in, 838
 finger contracture treatment-related, 426
 treatment of, 390*f*
 with volar plate advancement and sublimis slip reinforcement, 891–893, 892–893*f*
- Swan neck splints, 185–186, 186*f*
- Swimming
 for physical conditioning, 308
 as therapy, 174, 810–811, 811*t*, 812*f*
- Symmetric tonic neck reflex (ATNR), 41–42, 838
- Symmetry impulse index, 726
- Sympathetic reflex dystrophy, 791
- Synapses, formation and remodeling of, 30–31
- Synaptic plasticity, 30
- Syndrome of inappropriate antidiuretic hormone (SIADH), 483
- T**
- Talar plateau, in planovalgus deformity, 747*f*
- Talectomy, 725, 725*f*, 736
- Talonavicular joint, 770
 excision of, 992, 997
- Talus, low-energy fractures of, 60
- Tay-Sachs disease, 34*t*
- Tegretol, 83–84, 87*t*, 88–89
- Tendon lengthening, 831
 as hemiplegic gait treatment, 345–347
 as spasticity treatment, 122
- Tendons. *See also* specific tendons
 effect of spasticity on, 107–108
- Tenotomy
 Achilles tendon, 667
 historical background of, 708
 adductor, wound infections of, 636
 of proximal gastrocnemius, 714–715, 715*f*
 of semitendinosus muscle, 676, 678
- Tensor fascia lata muscle, as external rotator muscle, 619*f*
- Testicles, undescended, 74
- Tetrahydrobiopterin deficiencies, 36*t*
- Tetrazepam, as spasticity treatment, 109*t*
- Therapeutic relationship
 with physical therapists, 12–13
 with physicians, 13–15
 dysfunctional, 14–15
- Therapist assistants, 166
- Therapy. *See also* Occupational therapy; Physical therapy; Speech therapy
 acupuncture, 175
 alternative medicine, 176–177
 for athetosis, 135–136
 hippotherapy (horseback riding), 123–124, 173–174, 810–811, 811*t*, 812*f*
 hydrotherapy (swimming), 174, 308, 810–811, 811*t*, 812*f*
 hyperbaric oxygen therapy, 176
 martial arts, 175
 massage and myofascial release therapy, 175–176
 prescriptions for, 169–170

- Therapy (*continued*)
 space suit therapy, 176
 sports, 175
- High-foot axis, measurement of, 53, 55*f*
- Thoracolumbar sacral orthoses (TLSO)
 bivalved, 187, 187*f*
 custom-molded
 for kyphotic patients, 455–456
 for scoliosis prevention, 440–441
 lumbar flexion jacket, 188, 188*f*
 for scoliosis prevention, 440–442,
 440*f*, 441*f*, 442*f*
 inefficacy of, 440
 soft, 186–187, 187*f*
 corset-type, 441–442, 442*f*
 weaning from, 813
- Thrombin, 471
- Thromboembolism, spinal surgery-
 related, 465
- Thrombophlebitis, postoperative, 654,
 656
- Thumb
 cortical position of, 420, 422
 functional development of, 387
 metacarpal phalangeal joint fusion of,
 886–887, 887*f*
 physical examination of, 388–389
- Thumb abduction
 evaluation of, 840
 palmaris longus or brachioradialis
 transfer treatment of, 890–891,
 891*f*
 passive, 389
 splint treatment of, 185, 186*f*
- Thumb adduction, 831
 extensor pollicis longus rerouting treat-
 ment of, 887–890, 888–890*f*
 metacarpal
 with metacarpophalangeal joint
 flexion, 420
 with metacarpophalangeal joint
 hyperextension, 420
 with metacarpal extension, 418
- Thumb adductor contractures, 389
- Thumb adductor lengthening, 883–884,
 883–884*f*
- Thumb deformities
 House classification system-based
 treatment of, 419–422, 419–424,
 419*f*
 type 1 deformity, 419–420, 421,
 421*f*
 type 2 deformity, 420
 type 3 deformity, 420, 422, 422*f*
 type 4 deformity, 420, 422, 423,
 423*f*
 splinting of, 832–833
 surgical treatment of, 833*t*
 thumb-in-palm deformity, 389
 diagnostic evaluation of, 418
 natural history of, 418
 treatment of, 419, 424
- Thumb hyperextension, metacarpal, 422,
 422*f*
- Thumb splints, 185, 186*f*
- Tibia
 fractures of
 during hip rehabilitation, 566
 low-energy, 59–61, 62, 63–64
 subtalar fusion-related, 766
 torsional malalignment of, 108
- Tibialis anterior
 in equinovarus foot deformity, 724
 in foot stability, 769*f*
 in hemiplegic gait pattern type 1, 344,
 344*f*
 in hemiplegic gait pattern type 2, 347
 lengthening of, 1012–1014, 1013*f*
 in medial arch maintenance, 770*f*
 transfer of, in forefoot supination
 treatment, 993, 993*f*
- Tibialis anterior contractures,
 planovalgus-related, 750
- Tibialis anterior transfer
 as midfoot supination treatment, 771
 split
 operative procedure, 1010–1012,
 1010–1012*f*
 as varus foot deformity treatment,
 733, 740
 as varus foot deformity treatment,
 741–742
- Tibialis posterior
 in equinovarus foot deformity,
 723–724
 in foot stability, 769*f*
 in hemiplegic gait type 2, 346, 347
 transposition of, as varus foot defor-
 mity treatment, 740
 varus deformity of, 131, 740
- Tibialis posterior advancement, as mid-
 foot supination treatment, 771
- Tibialis posterior contractures, hemi-
 plegic varus foot position asso-
 ciated with, 729
- Tibialis posterior lengthening,
 1004–1010, 1005–1010*f*
 as varus foot deformity treatment, 736,
 740, 741–742
- Tibialis posterior transfer, split
 operative procedure, 1004–1010,
 1005–1010*f*
 as varus foot deformity treatment, 736,
 737–739, 737–739*f*, 740
- Tibial metaphysis
 distal, low-energy fractures of, 60
 proximal, low-energy fractures of,
 59–60
- Tibial osteotomy
 with cast, 968–969, 969*f*
 as compartment syndrome cause, 792
 foot-to-thigh angle as indication for,
 318
 with intramuscular nails, 970–971,
 970*f*
 as peroneal nerve palsy cause, 792
 as tibial torsion treatment, 700–704,
 701–702*f*
 as vascular infarction cause, 791
- Tibial shaft, low-energy fractures of, 60
- Tibial torsion, 667–668, 696–704, 698*f*
 ankle equinus-associated, 711
 ankle valgus-associated, 705, 706,
 706*f*
 diagnostic evaluation of, 698–700,
 700*f*
 diplegia-related, 359
 external, 316
 planovalgus-related, 749
 femoral anteversion-associated, 622
 foot progression angle in, 699–700
 internal, 316
 intrauterine positioning-related, 696,
 698, 698*f*
 kinematic definition of, 699
 measurement of, 311, 314
 natural history of, 698
 planovalgus-associated, 742–743
 tibial osteotomy treatment of,
 700–703, 701–702*f*
 complications of, 703–704
 outcome of, 703
 pre- and postoperative kinetics in,
 701, 702*f*
 torsional malalignment in, 311
 transmalleolar axis in, 699
 transmalleolar axis-to-thigh angle in,
 699, 700, 700*f*
- Tibia-to-fibula cross-union, tibial
 osteotomy-related, 704
- Tilt boards, 234*f*
- Tizanidine, as spasticity treatment, 109*t*,
 110, 853
- TLSO. *See* Thoracolumbar sacral
 orthoses (TLSO)
- Toe deformities, 667–668, 779
 cock-up toes, 787, 788
 of the great toe
 extended hallux, 784–788
 hallux valgus, 779–784
 of minor toes, 787–788
- Toe dragging
 inadequate ankle dorsiflexion-related,
 322
 rectus transfer treatment of, 958–962,
 959–962*f*
- Toe grasp reflex, 97
- Toe grip reflex, 41*f*
- Toenails, ingrown, 788
- Toe strike, as initial foot contact, 319

- Toe walking
 ataxia-related, 139, 140
 ballerina-type, 777
 diplegia-related, 352, 354–360, 712*f*, 737
 compared with idiopathic walking, 712
 mild, 352, 354
 moderate, 354–355
 severe, 355–356
 treatment of, 356–360, 357*f*, 358*f*
 hemiplegia-related, 309, 310–311*f*, 345
 as planovalgus cause, 748
 Toilet seating, 230–231, 232*f*
 Tonic neck reflexes, 838
 Top-Down Motor Milestone Test, 829
 Total hip replacement, palliative, 568, 569–570*f*
 Toxic agents, as neurologic deficit cause, 38
Toxoplasma gondii, 38
 Toy cars, battery-powered, 211, 211*f*
 Trachea, malacia of, 485
 Tracheostomy, postoperative, 483
 Transcutaneous electrical nerve stimulation (TENS), 157–158, 809
 Transitional planning, 171–173
 Transmalleolar axis, 698
 measurement of, 53, 55*f*
 Transmalleolar axis-to-thigh angle, 699, 700, 700*f*
 Transverse plane deformities, of the hip, 333–335, 335*f*
 hemiplegic gait type 2-associated, 347
 hemiplegic gait type 3-associated, 350
 hemiplegic gait type 4-associated, 351
 Trauma, as brain injury cause, 32–33, 33*f*
 Tremor, definition of, 45
 Trendelenburg gait, 341, 341*f*
 Triceps release, 398
 Tricycles, therapeutic, 241, 241*f*
 Trihexiphenidyl, as dystonia treatment, 119, 129, 130, 130*f*, 131
 Trimethadione, 84*t*
 Triplegia, 40
 Tromner's sign, 839*t*
 Trunk, hyponia of, as kyphosis cause, 452–453
 Trunk orthoses, for kyphotic patients, 455–456
 Twins, cerebral palsy prevalence rate in, 39
 Twister cables, 188–189
 as femoral anteversion treatment, 624–625
 Two-point discrimination test, 389
 Tyrosinemia, 36*t*
- U
 Ulcers, on sole of foot, 791
 Ultrasound
 for developmental hip dysplasia evaluation, 532
 for femoral anteversion measurement, 532, 613–615, 614*f*, 616
 for tibial torsion evaluation, 698–699
 Unit rod instrumentation
 in ambulatory children, 500
 as colon perforation cause, 474
 as kyphosis treatment, 456–457
 as lordosis treatment, 458–459*f*, 460–461, 462–464*f*, 463*f*
 pelvic leg-related halo effect associated with, 487, 488*f*
 as pelvic perforation cause, 473–474, 475*f*, 476–478, 477*f*
 acetabular perforation, 474, 476–478
 lateral perforation, 474, 476, 477*f*
 medial perforation, 474, 475–476*f*
 as pleural effusion cause, 484*f*
 resistance to grand mal seizures, 468
 rod fractures associated with, 488, 489*f*
 as scoliosis treatment, 436, 437*f*, 438, 439*f*, 443, 444–445, 444*f*, 452, 894–903, 895–903*f*
 end-to-end rod connector failure rate in, 469, 470*f*
 University of California Biomechanics Laboratory (UCBL) orthotic, 198, 200*f*
 Upper-extremity deformities
 diagnosis and treatment algorithm for, 428–429*t*
 functional classification of, 389–390
 functional development of, 387, 388*t*
 functional evaluation of, 388
 physical examination of, 388–389
 surgical treatment of, 831–832, 833*t*
 occupational therapy evaluations following, 844–851, 849*f*, 850–851*f*
 occupational therapy evaluations prior to, 838–844, 841–844*f*
 Upper-extremity denervation, as dystonia treatment, 119, 119*f*
 Upper-extremity occupational therapy evaluations
 functional abilities evaluations, 834–836, 835*t*, 836*t*
 functional development evaluations, 391
 functional evaluations, 834–836, 835*t*, 836*t*
 during adolescence, 391
 during early and middle childhood, 391
 goal setting in, 390–391
 functional outcome prediction in, 848, 850
 informational/instructional handouts in, 848, 850*t*, 851*t*
 overall evaluations, 836–838, 837*f*
 postoperative, 844–851, 849*f*, 850–851*t*
 preoperative, 838–844, 841–844*f*
 Upper-extremity orthoses, 182–186
 elbow orthoses, 183, 184*f*
 hand and wrist orthoses, 183–184, 184*f*
 shoulder orthoses, 183
 spinal orthoses, 186–188, 187*f*, 188*f*
 Upper-extremity reflexes, evaluation of, 838, 839*t*
 Upper-extremity surgical procedures, 865–893
 age considerations in, 394
 elbow flexion contracture release, 871, 872*f*
 extensor pollicis longus rerouting, 887–890, 888–890*f*
 flexor carpi ulnaris transfer for wrist flexion deformity, 874–880, 875–879*f*
 humeral derotation osteotomy, 869, 870–871*f*
 metacarpal phalangeal joint fusion of the thumb, 886–887, 887*f*
 palmaris longus or brachioradialis transfer to the abductor pollicis, 890–891, 891*f*
 preoperative evaluation for, 392
 of intelligence and mental status, 393–394
 occupational therapy-based, 838–844, 841–844*f*
 of sensory deficits, 393
 of voluntary control, 393, 394*f*
 pronator teres release or transfer, 873–874*f*
 proximal row carpectomy and/or wrist fusion, 880–883, 880–883*f*
 shoulder adductor lengthening, 865, 866–869*f*
 spasticity control during, 392–393
 thumb adductor lengthening, 883–884, 883–884*f*
 webspace lengthening and Z-plasty, 884–886, 885–886*f*
 Upper motor neuron syndrome, 852
 Urea cycle disorders, 36*t*
 Urinary calculi, 74
 Urinary catheterization
 epidural anesthesia-related, 81
 as urinary tract infection risk factor, 82
 Urinary incontinence, 74
 Urinary retention, 74
 dorsal rhizotomy-related, 116
 intrathecal baclofen-related, 856

- Urinary tract infections
postoperative, 82, 490
recurrent, 74
- V**
- Valgus, 696, 697, 697*f*
cavus associated with, 776
of femoral neck, 524
determination of, 525, 527, 527*f*
hip dislocation-associated, 525, 527, 527*f*, 529*f*
of foot, 667–668
of forefoot, 769*f*
of hindfoot, 743, 769*f*
as bunion cause, 779
diplegia-associated, 743
of knee, 696, 697, 697*f*
orthotic treatment of, 198, 200*f*
pedobarograph measurement of, 283*f*
of subtalar joint, 667–668
- Valgus foot collapse, 729
- Valium. *See* Diazepam
- Valproate sodium, as intraoperative hemorrhage risk factor, 471
- Valproic acid, 84*t*
- Vans, with wheelchair lifts, 489
- Varicella zoster infection, *in utero*, 38
- Varus, 696
in adolescents, 732–733
with the appearance of clubfeet, 725, 725*f*, 733, 736
fixed heel, 733, 734–735*f*
of foot, 309
of forefoot, 724, 769*f*
differentiated from hindfoot varus, 729*f*
tibialis anterior transfer treatment of, 1010
of heel, 724
fixed, 733, 734–735*f*
hemiplegia-associated, 729, 731, 732*f*
tibialis posterior transfer treatment of, 736
of hindfoot, 724, 769*f*
differentiated from forefoot varus, 729*f*
stiffness associated with, 741
overcorrection of, 741, 742
pedobarograph measurement of, 283*f*
with tibialis posterior and peroneal muscles, 131
tibialis posterior-related, 1004
treatment of, 727, 729
complications of, 741–742
with orthotics, 198, 736
with tibialis posterior tendon lengthening, 736, 740
- Varus-valgus realignment, in combination with distal femoral osteotomy, 972
- Vascular infarction, osteotomy-related, 791
- Vastus muscle
contractures of, 685
in knee flexion contractures, 684
- Vault, 320, 320*f*, 321*f*
- Vestibular system
effect of aquatic exercise on, 813
role in balance development, 808
- Vests, weighted, 136
- Vibrators, 124
- Videotaping, in gait analysis, 276, 276*f*, 286
- Viral infections. *See also* specific viral infections
prenatal and neonatal, as neurologic disorder cause, 38
- Viscoelastic dampening, in muscle tone, 103–104
- Visual system, role in balance development, 808
- Vitamin B₁₂ metabolism defect, 36*t*
- Vitamin D deficiency, 57
- Vitamin D supplementation, 66, 68
- Vitamin metabolism disorders, 36*t*
- Volar plate advancement, as swan neck deformity treatment, 891–893, 892–893*f*
- Votja therapy, 155–156, 175
- V-Y lengthening, of quadriceps muscle, as fixed knee extension contracture treatment, 692
- W**
- Waking aids
canes, 237–239, 240*f*, 820–821
contraindication in ataxia, 139
- Walkers, 235–236, 235*f*, 236*f*, 237*f*
front, 820
for hemiplegia type 4 patients, 352
initial evaluation for use of, 818–819
mechanical lift, 831*f*
posterior, 820
thigh and foot guide attachments on, 188, 189*f*
- Walking. *See also* Gait
balance deficits during, 138
neurologic control of, 99–100
prognosis for, 43–44
- Walking aids, 235–239, 242*t*, 820
for ataxia patients, 139
canes, 239, 820–821
crouched gait patients' use of, 363, 364–366, 364–366*f*
crutches, 235, 237–239, 240*f*, 820–821
for ataxia patients, 139
gait trainers, 237, 238–239*f*, 240*f*, 820
walkers, 235–236, 235*f*, 236*f*, 237*f*
- Walking speed, velocity attractors in, 101
- Watsu, 815
- Webspace lengthening, 884–886, 885–886*f*
- Weight bearing
effect on bone growth, 57–58
in spasticity, 108
in standers, 64, 66
- Weight gain, adverse effects of, 77
- Weight measurement, 56
- Weights, therapeutic use of, by athetosis patients, 136
- Wheelchair lifts, 229
- Wheelchairs, 200–232, 821–828
abduction wedges on, 217–218, 218*f*
abductors on, 822*t*
anterior knee blocks on, 227, 227*f*
anterior knee pads on, as windblown hip deformity treatment, 603, 605, 607*f*
armrests on, 214, 214*f*
attachments on, 222
backrests on, 824*t*
base of, 206, 216, 216*f*
standard, with large wheels, 207–208, 207*f*
standard, with one-arm self-propelling feature, 209
standard, with small wheels, 207
stroller-base, 203–205, 203*f*, 206–207
for blind children, 210
children's attitudes toward, 200, 201
for children who are dependent in all transfers, 205–206
for children who are exercise ambulators/transfer standers, 204–205, 205*f*
for children with some ambulatory ability, 203–204
for clubfeet patients, 733, 736
cosmetic appearance of, 222–223
cost of, 826*f*
crutch holders on, 222
cushions on, 825*t*
desks on, 231–232
documentation of medical need for, 823–824, 827–828
effect on cardiovascular endurance, 307–308
effect on walking ability, 200–201, 208, 208*f*, 208*t*
foot buckets on, 733, 736
foot positioners on, 825*t*
footrests on, 213–214, 213*f*
as skin breakdown cause, 733, 736
frames of, 213, 213*f*
guidelines for, 821–823*t*
for hamstring contracture patients, 228
headrests on, 221, 221*f*
health insurance coverage for, 207, 223
for hemiplegia type 4 patients, 352

- for hip disorder patients, 227–228
 - hip guide restraints on, 216
 - hip guides on, 822*t*
 - inappropriate, 202
 - knee adductors on, 822*t*
 - knee blocks on, 822*t*
 - for knee flexion contracture patients, 228
 - as knee flexion contracture risk factor, 671
 - for kyphosis patients, 227, 227*f*, 453–454, 456*f*
 - lap trays on, 205, 205*f*, 222, 826*t*
 - for kyphotic patients, 455, 456*f*
 - laterals, 821*t*
 - for lordosis patients, 227
 - low-energy fracture occurrence in, 61–62
 - Medicaid coverage for, 207
 - parental attitudes toward, 200–201
 - for pelvic obliquity patients, 228, 512
 - pelvis positioning straps on, 823*t*
 - postoperative adjustments on, 451
 - power, 209–213
 - battery-powered toy cars as, 211, 211*f*
 - controller mechanisms of, 209–210, 210*f*
 - criteria for, 211*t*
 - use by athetosis patients, 135–136
 - wheel base of, 212–213, 212*f*
 - prescriptions for, 202–203, 223, 243–244*t*
 - for scoliosis patients, 223–226, 224*f*, 225–226*f*, 442
 - seatbelt rigidizers on, 823*t*
 - seat belts and restraints on, 218–219, 218*f*, 823*t*
 - seating, 214–221, 214*f*
 - for anterior trunk support, 219–221, 220*f*
 - for back support, 204*f*, 219
 - back-to-seat angle of, 222
 - barrel-shaped, 229
 - base for, 216, 216*f*
 - as bath chairs, 231, 233*f*
 - with closed-cell t-foams, 216
 - customized modular, 214–215, 216
 - durability of, 222–223
 - feeding seats, 230, 230*f*
 - for foot deformity management, 228
 - formfitting, custom-molded, 214–216
 - with gel pads, 216
 - inappropriate, 214, 214*f*
 - for lateral trunk support, 219, 220*f*
 - as play chairs, 230, 231*f*
 - pressure mapping of, 216, 217*f*
 - seating clinics, 201–202
 - toilet seating, 230–231, 232*f*
 - shoulder harnesses on, 220–221, 822*t*
 - for kyphotic patients, 453, 454, 455
 - shoulder retractor pads on, 822*t*
 - shoulder straps on, 822*t*
 - special, 229–232
 - for spinal deformity patients, 489
 - summer/winter bracket hardware on, 821*t*
 - swing-away hardware on, 821*t*
 - during transportation, 228–229, 229*f*
 - trunk positioners on, 822*t*
 - van lifts for, 489
 - for windblown disorder patients, 227–228, 227*f*
 - for windblown hip deformity patients, 603, 605
- Wheelchair swings, 241, 241*f*
- Wheelchair vans, 229
- Wilson disease, 37*t*
- Windblown hip deformity, 600–607
- abduction contracture treatment in, 940–943, 941–943*f*
 - adducted posture in, 607–608
 - coxa valga associated with, 620
 - etiology of, 600
 - in asymmetric neurologic involvement, 600, 601, 602
 - in symmetric neurologic involvement, 600–601
 - hip reconstructive surgery-related, 551, 552–553*f*
 - treatment of
 - with abductor lengthening, 940–943, 941–943*f*
 - in adolescence, 602–603
 - in adults, 603
 - indications for, 602
 - in middle childhood, 602
 - with muscle lengthening, 602–603
 - with orthotics, 603, 605
 - with tone reduction, 605–606
 - wheelchair seating management of, 227–228, 227*f*
- Wolff's law, 620
- World Health Organization, “Classification of Impairments, Disabilities, and Handicaps” report, 39, 40, 40*t*
- Wound infections
- baclofen intrathecal pump-related, 112–113, 113*f*
 - on the feet, 792
 - in the knee, 790
 - postoperative, 490–495
 - acute deep, 491–495, 493–494*f*
 - antibiotic therapy for, 491, 493, 494, 495
 - as fever cause, 490–491
 - hamstring lengthening-related, 678–679
 - hip reconstructive procedures-related, 559–562, 561*f*
 - hip subluxation surgery-related, 545–546
 - hip surgery-related, 635–637
 - physician-patient discussion of, 21
 - superficial, 491
- Wrist contractures, 108
- Wrist deformities, surgical treatment of, 833*t*
- Wrist extension
- patterns of, 393
 - physical examination of, 388, 389*f*
- Wrist extension contractures, 410–418
- finger flexion contractures associated with, 410, 412
 - treatment of, 410–418
- Wrist flexion, range-of-motion in, 838
- Wrist flexion contractures, 396, 396*f*, 408–410, 831, 833*t*
- finger flexion contracture-associated, 424, 425
 - flexor carpi ulnaris transfer treatment of, 874–880, 875–879*f*
 - natural history of, 409
 - orthotic treatment of, 182, 183–184
 - severity classification, 409
 - treatment of, 396, 396*f*, 410–414, 411*f*, 412*f*, 413–414*f*, 424
 - treatment-related complications in, 415, 418
- Wrist fusion, 880–883, 880–883*f*
- as wrist extension contracture treatment, 413–414, 413–414*f*, 415
 - as salvage procedure, 418
- Wrist orthoses, 183–184, 184*f*
- Wrist splints, 832, 833*t*
- postoperative, 840, 844
- Y**
- Young adults
- back-kneeing in, 370
 - crouched gait in, 362–371
 - treatment of, 363–370
 - occupational therapy for, 165–166
 - physical therapy with, 163
- Z**
- Zellweger syndrome, 37*t*
- Z-lengthening
- of biceps, as elbow flexion contracture treatment, 400
 - as finger flexion contracture treatment, 425
 - of gastrocnemius, as ankle equinus treatment, 713–714, 714*f*
 - of quadriceps, as fixed knee extension contracture treatment, 692
 - of semitendinous muscle, 678
 - as varus foot deformity treatment, 740
- Z-plasty, 884–886, 885–886*f*
- for web space deepening, 420, 421